



SOLUNUM BULUŞMALARI

TRABZON

21-22 Ekim 2023
Mercure Hotel, Trabzon

Pulmoner Nodül Yönetimi

Dr. Özlem Erçen Diken

Sağlık Bilimleri Üniversitesi,

Adana Tıp Fakültesi, Göğüs Hastalıkları AD

Pulmoner Nodül

3 cm'den küçük, etrafı havalanmış akciğerle çevrili, ilişkili lenfadenopati veya plevral efüzyon olmayan radyolojik densitedir.

Çeşitli klinik durumlarda artan BT kullanımı ile insidental olarak saptanır.

ABD'de yılda 1.6 milyon kişide pulmoner nodül saptanmaktadır.

Akciğer BT görüntülerinin %30'unda tespit ediliyor.

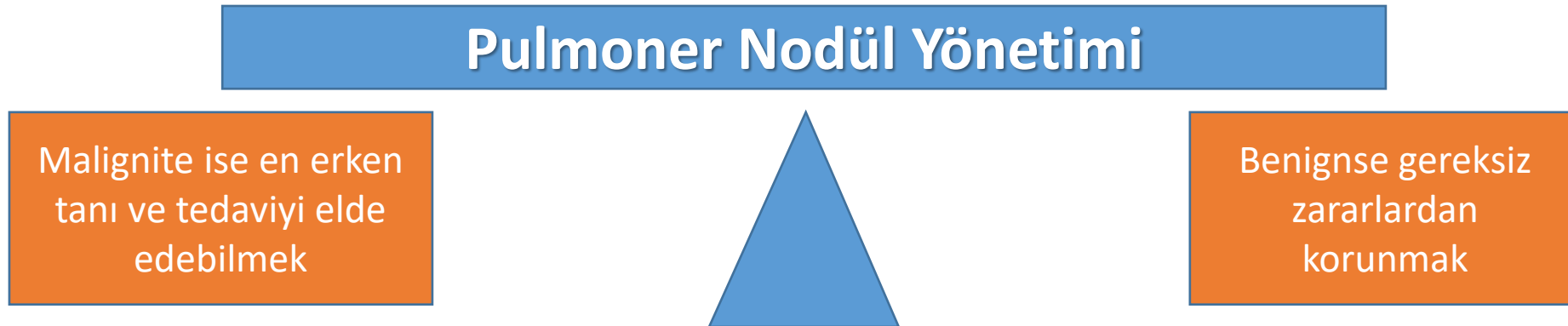
%95'inden fazlası benign nodüldür ve çoğu granülom ve intrapulmoner nodüllerdir.

Pulmoner nodülü olan hastaların %50'si birden fazla nodüle sahiptir.

Primer akciğer malignitesi, metastatik hastalık, enfeksiyöz olmayan bir inflamatuvar süreç, enfeksiyon veya önceki bir enfeksiyondan kalan skar nedeniyle olabilir.

Pulmoner Nodül Yönetim Seçenekleri

1. Daha fazla görüntülemeye gerek olmayabilir
2. Tekrarlayan radyografik görüntüleme, genellikle BT taraması
3. PET taraması
4. Bronkoskopik veya perkütan yoldan biyopsi örneğinin alınması
5. Cerrahi rezeksiyon veya SBRT ile doğrudan küratif tedaviye geçmek.



Pulmoner Nodüle Yaklaşım

Klinik karar vermede neler göz önüne alınmalıdır;

- Malignite olasılığı
- Hastanın performansı ve tedavi görme isteği (cerrahi rezeksiyon veya küratif radyoterapi, genellikle stereotaktik vücut radyoterapisi [SBRT]);
- Pnömotoraks, kanama ve tanısal olmayan numune alınması dahil teşhis prosedürlerinin riskleri
- Hastanın belirsizlik ve teşhis için beklemeden kaynaklanan sıkıntısı

Pulmoner Nodüllerin İzlenmesi- Malignite olasılığına göre

American College of Chest Physicians, Fleischner Derneği risk sınıflaması

Düşük risk kriterlerine göre;

- Daha genç yaştaki bireyler,
- Çok az veya hiç sigara içmeme öyküsü,
- daha küçük nodül boyutu,
- düzenli kenar boşlukları
- üst lob dışındaki konum.

Orta risk;

- Orta riskli bireylerin yüksek ve düşük risk kriterlerinin kombinasyonunu kullanırlar

Yüksek risk kriterlerine göre;

- Yaşlı bireyler,
- Ağır sigara öyküsü,
- Daha büyük nodül boyutu,
- Düzensiz veya spiküler
- Üst lob lokalizasyonu

Pulmoner Nodüllerin İzlenmesi- Malignite olasılığına göre

Risk
değerlendirme
için klinik karar
ya da risk
modelleri
kullanılabilir.

Brock Calculator

Nodule Characteristics

Nodule Size (1-30mm)
8

Nodule Count
1

Nodule Type
 Pure Ground Glass Part Solid
 Solid

Nodule in Upper Lobe
 Yes No

Spiculation
 Yes No

Patient Characteristics

Age (18-100)
45

Gender
 Male Female

Family History of Lung Cancer
 Yes No

Emphysema
 Yes No

Brock Model Probability
1.9%

Calculate

900 x 731

Table 2. Validated Risk Prediction Models for Evaluation of Pulmonary Nodules

Risk prediction model	Mayo Clinic model ¹⁷	Herder model ¹⁸	VA model ¹⁹	Brock University model ²	Cleveland Clinic model ²⁰
Nodule detection	Incidental nodule on chest radiograph	Incidental nodule on chest radiograph and PET scan was performed for further evaluation	Incidental nodule seen on chest radiographic confirmed on CT imaging +/- PET scan	Nodules detected on LDCT as part of lung cancer screening program	Incidental nodules referred to biopsy or resection
% Of nodules that were malignant in the cohort used to develop the model	23	57	54	5.5	66.5
Model variables	Age Smoking history History of extrathoracic malignancy ≥5 y ago Nodule diameter Spiculation Upper lobe location	Mayo Clinic model + FDG-PET uptake	Age Smoking history Time since quitting smoking Nodule diameter	Age Sex Family history of lung cancer Emphysema Nodule Size Nodule type Location Nodule count	Age Smoking history Upper lobe location Solid and irregular/spiculated nodule edges Emphysema FDG-PET avidity History of cancer other than lung
Area under the curve	0.83	0.88	0.79	≥0.94	0.75-0.81 (C-index)

Malignite Olasılığına göre Pulmoner Nodül Yönetimi

<%1: Ek test ve monitorizasyona gerek yoktur

%1-%5: BT ile takip

%5-%30: 3 ay sonra BT veya PET/BT ve/veya cerrahi dışı biyopsi

%30-%65: PET/BT ve/veya cerrahi dışı biyopsi

%65-%90: PET/BT ve/veya cerrahi dışı biyopsi veya torakoskopik cerrahi rezeksiyon

>%90: torakoskopik cerrahi rezeksiyon veya SBRT

Box 2. Individualized Pulmonary Nodule Management Based on Probability of Malignancy^{14-16,31-33a}

<1% No additional testing or monitoring needed.

1%-5% Monitoring with chest computed tomography (CT) per guideline recommendations, based on nodule size.

5%-30% Monitor with chest CT in 3 months or pursue additional testing with positron emission tomography (PET)/CT imaging

and/or a nonsurgical biopsy. Factors that favor monitoring include severe comorbidities, limited life expectancy, difficult nodule location, patient favors conservative management, slow growth rate, and low metabolic activity.

30%-65% Additional testing with PET/CT imaging and/or a non-surgical biopsy. Factors that favor guided bronchoscopy vs trans-thoracic needle biopsy include airway leading to the nodule, severe emphysema, available local expertise, and need to invasively stage the mediastinum.

65%-90% Additional testing with PET/CT imaging and/or a non-surgical biopsy or proceed directly to thoracoscopic surgical resection. Factors that favor surgical resection include low-yield nonsurgical biopsy location, excellent cardiopulmonary fitness, and patient favors aggressive management.

>90% Thoracoscopic surgical resection or stereotactic radiotherapy based on patient comorbidities and values.

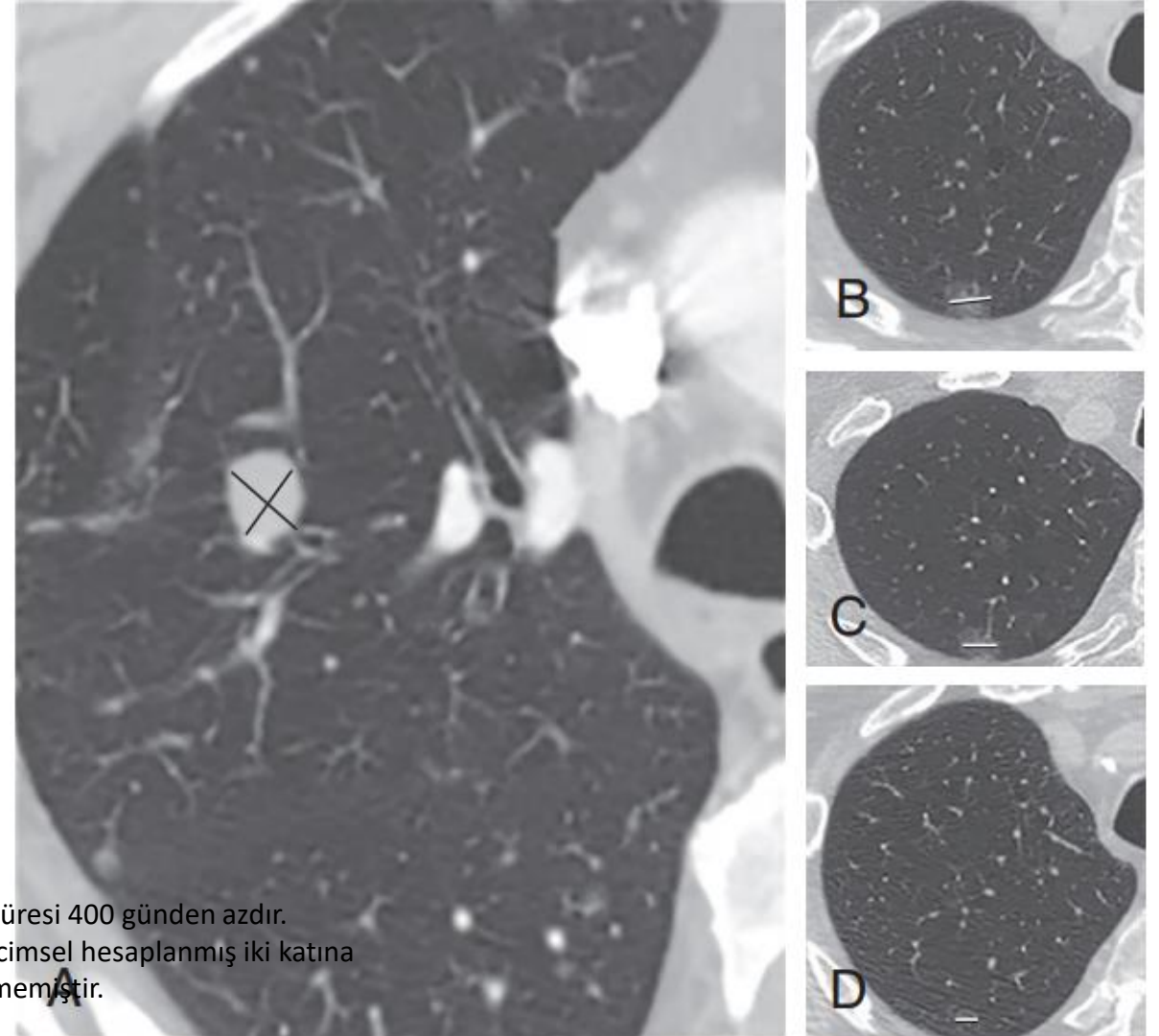
^a Probability of malignancy is estimated based on clinical experience or a validated risk prediction calculator.

Akciğer bilgisayarlı tomografisinde (BT) akciğer nodüllerinin uygun ölçümü.

İnce kesitli BT görüntüleri (kesit kalınlığı $\leq 1,5$ mm) üzerinde aksiyel düzlemde

A) Aynı düzlemdeki bir nodülün uzun eksen ölçümünün ve dikey maksimal kısa eksen ölçümünün (çizgiler) ortalaması.

(B–D) Seri muayeneler için, nodül büyümesi olup olmadığını daha güvenli bir şekilde belirlemek için mevcut muayene sadece en son muayene ile değil, aynı zamanda daha önceki muayenelerle de karşılaştırılmalıdır.

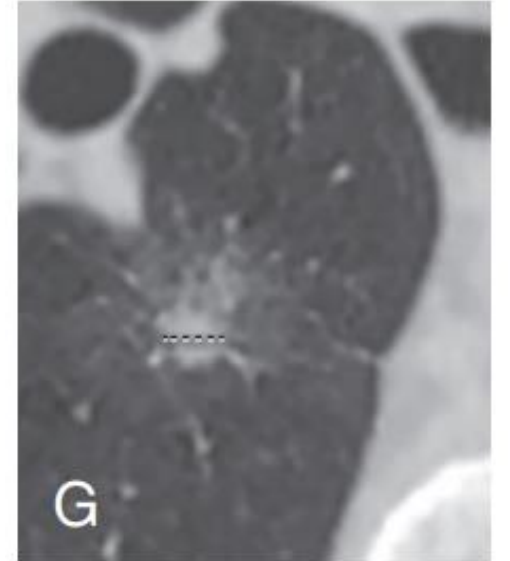
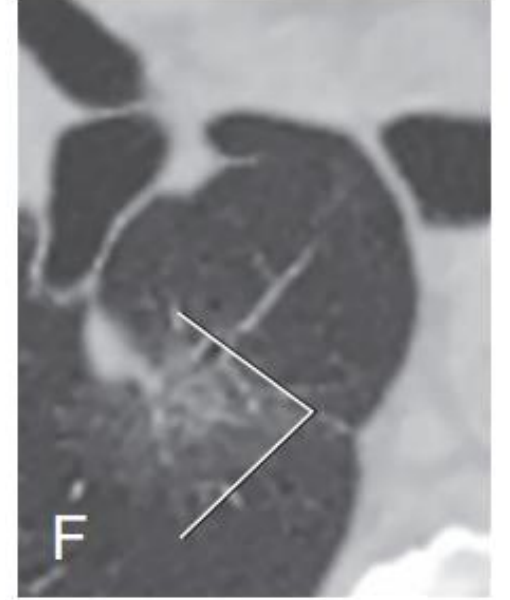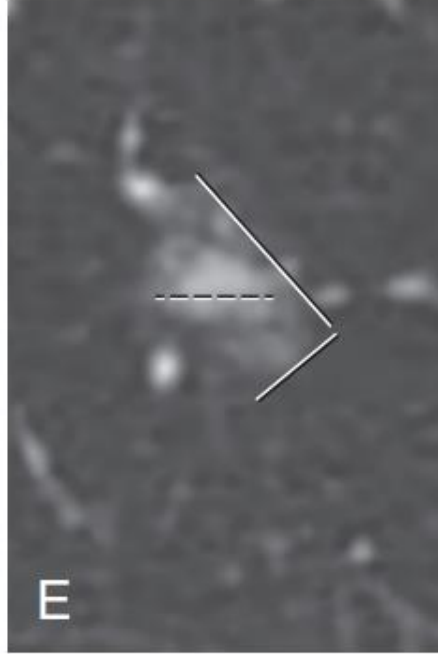


Solid nodüller için, daha sonra malign olduğu belirlenen nodüllerin çoğunluğunun hacim katlama süresi 400 günden azdır. Standart iki boyutlu (2B) ölçümlerini 3B hacimsel analizle karşılaştıran çalışmalar, malignite için hacimsel hesaplanmış iki katına çıkma süresi için daha iyi bir hassasiyet göstermiştir. Rutin olarak radyologlar tarafından kabul görmemiştir.

Akciğer bilgisayarlı tomografisinde (BT) akciğer nodüllerinin uygun ölçümü.

(E) Part-solid nodüller için, nodülün en uzun boyutunu gösteren düzlemde, buzlu cam ve varsa kistik bileşenler de dahil olmak üzere nodülün en büyük boyutu boyunca çift yönlü ölçümler (düz beyaz çizgiler) gerçekleştirin ve ardından solid alanı ölçün en uzun boyutun görselleştirildiği görüntüdeki nodülün bileşeni (kesik beyaz çizgiler).


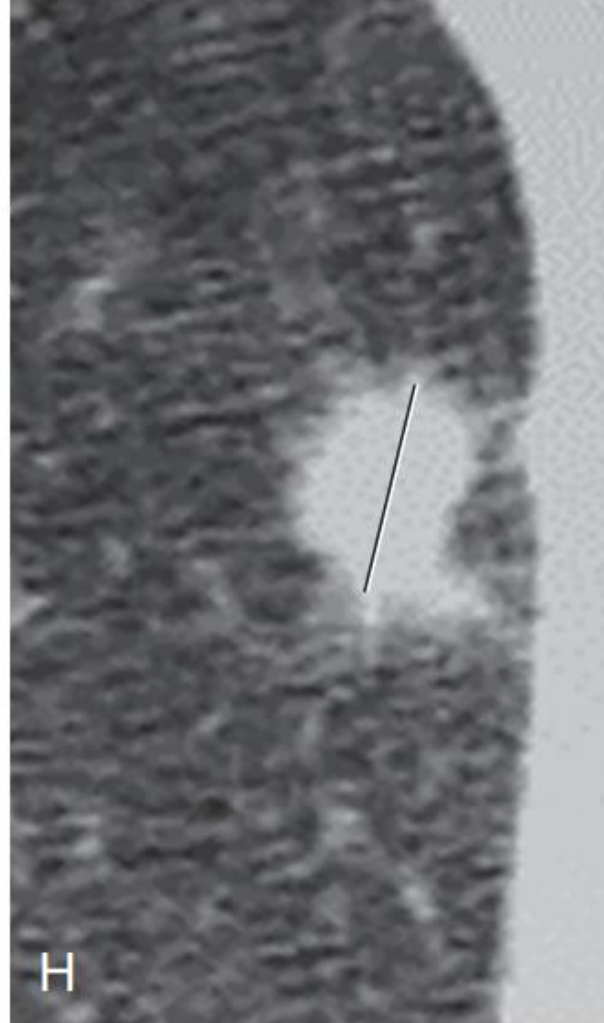
(F–G) Başka bir part-solid nodül örneğinde, partsolid nodülün solid kısmı (kesik çizgiler, G), nodülün en uzun boyutundan (düz beyaz çizgiler, F) farklı bir seviyededir.



Akciğer bilgisayarlı tomografisinde (BT) akciğer nodüllerinin uygun ölçümü.

(H) Spiküle nodüller için, spikülasyonları değil, sadece nodülün (çizginin) solid kısmını ölçün.

(I) <3 mm (ok) nodüller için nodülü ölçmeye çalışmayın. Nodülü referans olarak işaretleyin ve nodülü “mikronodül” olarak adlandırın.




Pulmoner Nodül Yönetimi- Kılavuzlar

- Fleischner Derneği **2017** yılında güncellendi. “Gereksiz takip muayenelerinin sayısını azaltmak” amacı ile daha fazla radyolog, klinisyen ve hastaya yönetim kararları verdi
- Multipl nodülü olan hastalar için yeni öneriler de dahil edildi.
- Kılavuzların yalnızca en az 35 yaşındaki erişkinlerde bulunan insidental nodüller için geçerli olduğu ve bağışıklığı baskılanmış veya bilinen bir ekstratorasik kanseri olan hastalar için geçerli olmadığı açıklandı.
- Çapı 6 mm'den küçük olan nodülleri takip etmek için yeni öneriler: akciğer kanseri için risk faktörü yoksa takibe gerek olmadığı; risk faktörleri varsa, takibin opsiyonel olduğu belirtildi.

Fleischner Society 2017 Erişkinlerde İncidental Tespit Edilen Pulmoner Nodüllerin Yönetimine Yönelik Kılavuzlar

Nodule Type	SIZE			Comments
	<6 mm (<100 mm ³)	6–8 mm (100–250 mm ³)	>8 mm (>250 mm ³)	
SOLID NODULES				
Single				
Low risk*	No routine follow-up	CT at 6–12 mo, then consider CT at 18–24 mo	Consider CT at 3 mo, PET/CT, or tissue sampling	Nodules <6 mm do not require routine follow-up in low-risk patients (recommendation 1A).
High risk*	Optional CT at 12 mo	CT at 6–12 mo, then CT at 18–24 mo	Consider CT at 3 mo, PET/CT, or tissue sampling	Certain patients at high risk with suspicious nodule morphology, upper lobe location, or both may warrant 12-mo follow-up (recommendation 1A).
Multiple				
Low risk*	No routine follow-up	CT at 3–6 mo, then consider CT at 18–24 mo	CT at 3–6 mo, then consider CT at 18–24 mo	Use most suspicious nodule as guide to management. Follow-up intervals may vary according to size and risk (recommendation 2A).
High risk*	Optional CT at 12 mo	CT at 3–6 mo, then at 18–24 mo	CT at 3–6 mo, then at 18–24 mo	Use most suspicious nodule as guide to management. Follow-up intervals may vary according to size and risk (recommendation 2A).

Fleischner Society 2017 Erişkinlerde İncidental Tespit Edilen Pulmoner Nodüllerin Yönetimine Yönelik Kılavuzlar

Nodule Type	SIZE		Comments
	<6 mm (<100 mm ³)	≥6 mm (>100 mm ³)	
SUBSOLID NODULES[†]			
Single			
Ground-glass	No routine follow-up	CT at 6–12 mo to confirm persistence, then <u>CT every 2 yr until 5 yr</u>	In certain suspicious nodules <6 mm, consider follow-up at 2 and 4 yr. If solid component(s) or growth develops, consider resection (recommendations 3A and 4A). 
Part-solid	No routine follow-up	CT at 3–6 mo to confirm persistence. If unchanged and solid component remains <6 mm, <u>annual CT should be performed for 5 yr</u>	In practice, part-solid nodules cannot be defined as such until ≥6 mm, and nodules <6 mm do not usually require follow-up. Persistent part-solid nodules with solid components ≥6 mm should be considered highly suspicious (recommendations 4A–4C).
Multiple	CT at 3–6 mo. If stable, consider CT at 2 and 4 yr	CT at 3–6 mo. Subsequent management based on the most suspicious nodule(s)	Multiple <6 mm pure ground-glass nodules are usually benign, but consider follow-up in selected patients at high risk at 2 and 4 yr (recommendation 5A).

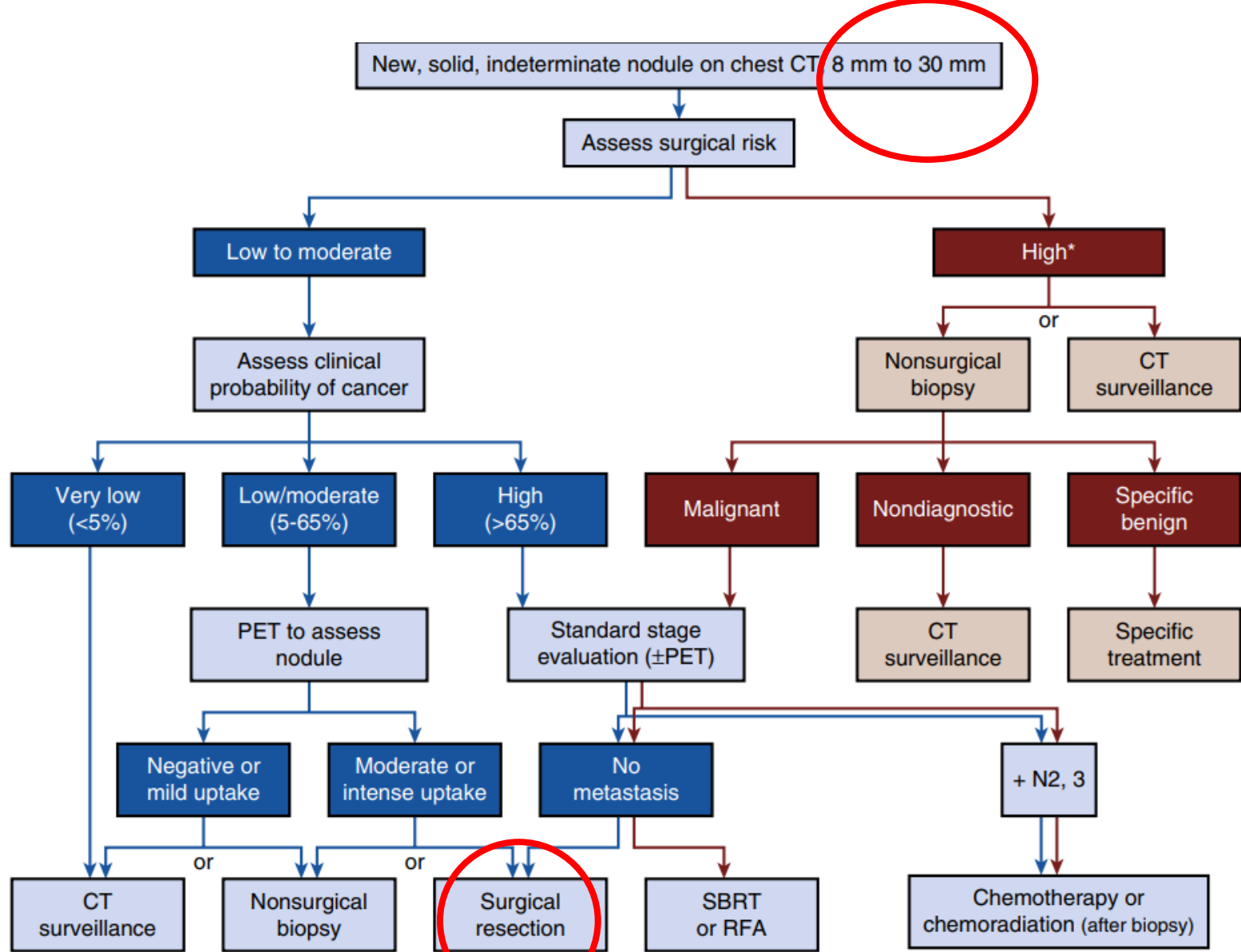


Figure 41.2 Management algorithm for individuals with solid nodules measuring 8 to 30 mm in diameter. *Among individuals at high risk for surgical complications, we recommend either nonsurgical biopsy, when the clinical probability of malignancy is moderate to high, or CT scan surveillance, when the clinical probability of malignancy is low to moderate. CT, computed tomography; PET, positron emission tomography; RFA, radiofrequency ablation; SBRT, stereotactic body radiotherapy. (From Gould MK, Donington J, Lynch WR, et al. Evaluation of individuals with pulmonary nodules: when is it lung cancer? Diagnosis and management of lung cancer, 3rd ed. American College of Chest Physicians Evidence-Based Clinical Practice Guidelines. *Chest*. 2013;143[suppl 5]:e93S–e120S.)

Lung-RADS sınıflandırma

- Nodülleri büyüklüklerine ve yeni veya büyümekte oldukları biliniyor olmalarına göre sınıflandırır.
- Lung-RADS kategori 1: Nodül bulgusu yok veya iyi huylu kalsifikasyon paterni olan bir nodül negatif olarak kabul edilir.
- Lung-RADS kategori 2: **küçük solid nodül (<6 mm), yeni solid nodül (<4 mm), part-solid nodül (<6 mm), nonsolid nodül (<30 mm), veya perifissüral nodül (<10 mm) benign bulgular olarak değerlendirilir ve malignite riski <1%. Yıllık tarama önerilir.**
- Lung-RADS kategori 3: 6-8 mm, yeni 4-6 mm, 6 mm üzeri partsolid solid komponent 6 mm altı, 30 mm üzeri nonsolid, %1-2 (6 ay)
- Lung-RADS kategori 4A: %5-15 (3 ay)
- Lung-RADS kategori 4B: >%15 (BT/PET-BT/ve-veya doku tanısı)

Lung-RADS

4A: Solid nodül: 8-15 mm veya büyüyen veya yeni 8mm altı

Partsolid nodül: 6 mm üzeri solid komponenti 6-8 mm arası veya yeni veya büyüyen 4 mm altı solid komponent Endobronşiyal nodül

4B: Solid nodül: 15 mm üzeri veya yeni veya büyüyen 8 mm üzeri

Partsolid nodül: 8 mm üzeri solid komponent veya yeni veya büyüyen 4 mm üzeri solid komponent

Wood DE, Kazerooni EA, Baum SL, et al. Lung Cancer Screening, Version 3.2018, NCCN Clinical Practice Guidelines in Oncology. J Natl Compr Canc Netw. 2018;16(4):412–441.

Category Descriptor	Lung-RADS Score	Findings	Management	Risk of Malignancy	Est. Population Prevalence
Incomplete	0	Prior chest CT examination(s) being located for comparison	Additional lung cancer screening CT images and/or comparison to prior chest CT examinations is needed	n/a	1%
		Part or all of lungs cannot be evaluated			
Negative No nodules and definitely benign nodules	1	No lung nodules			
		Nodule(s) with specific calcifications: complete, central, popcorn, concentric rings and fat containing nodules			
Benign Appearance or Behavior Nodules with a very low likelihood of becoming a clinically active cancer due to size or lack of growth	2	Perifissural nodule(s) (See Footnote 11) < 10 mm (524 mm ³)	Continue annual screening with LDCT in 12 months	< 1%	90%
		Solid nodule(s): < 6 mm (< 113 mm ³) new < 4 mm (< 34 mm ³)			
		Part solid nodule(s): < 6 mm total diameter (< 113 mm ³) on baseline screening			
		Non solid nodule(s) (GGN): < 30 mm (<14137 mm ³) OR ≥ 30 mm (≥ 14137 mm ³) and unchanged or slowly growing			
		Category 3 or 4 nodules unchanged for ≥ 3 months			
Probably Benign Probably benign finding(s) - short term follow up suggested; includes nodules with a low likelihood of becoming a clinically active cancer	3	Solid nodule(s): ≥ 6 to < 8 mm (≥ 113 to < 268 mm ³) at baseline OR new 4 mm to < 6 mm (34 to < 113 mm ³)	6 month LDCT	1-2%	5%
		Part solid nodule(s) ≥ 6 mm total diameter (≥ 113 mm ³) with solid component < 6 mm (< 113 mm ³) OR new < 6 mm total diameter (< 113 mm ³)			
		Non solid nodule(s) (GGN) ≥ 30 mm (≥ 14137 mm ³) on baseline CT or new			
Suspicious Findings for which additional diagnostic testing is recommended	4A	Solid nodule(s): ≥ 8 to < 15 mm (≥ 268 to < 1767 mm ³) at baseline OR growing < 8 mm (< 268 mm ³) OR new 6 to < 8 mm (113 to < 268 mm ³)	3 month LDCT; PET/CT may be used when there is a ≥ 8 mm (≥ 268 mm ³) solid component	5-15%	2%
		Part solid nodule(s): ≥ 6 mm (≥ 113 mm ³) with solid component ≥ 6 mm to < 8 mm (≥ 113 to < 268 mm ³) OR with a new or growing < 4 mm (< 34 mm ³) solid component			
		Endobronchial nodule			
Very Suspicious Findings for which additional diagnostic testing and/or tissue sampling is recommended	4B	Solid nodule(s) ≥ 15 mm (≥ 1767 mm ³) OR new or growing, and ≥ 8 mm (≥ 268 mm ³)	Chest CT with or without contrast, PET/CT and/or tissue sampling depending on the "probability of malignancy and comorbidities. PET/CT may be used when there is a ≥ 8 mm (≥ 268 mm ³) solid component.	> 15%	2%
		Part solid nodule(s) with: a solid component ≥ 8 mm (≥ 268 mm ³) OR a new or growing ≥ 4 mm (≥ 34 mm ³) solid component			
	4X	Category 3 or 4 nodules with additional features or imaging findings that increases the suspicion of malignancy	For new large nodules that develop on an annual repeat screening CT, a 1 month LDCT may be recommended to address potentially infectious or inflammatory conditions		
Other Clinically Significant or Potentially Clinically Significant Findings (non lung cancer)	S	Modifier - may add on to category 0-4 coding	As appropriate to the specific finding	n/a	10%

Table 1. Society Guidelines for the Management of Pulmonary Nodules

Nodule diameter	American College of Chest Physicians ^{15a}	Fleischner Society ^{14a}	Lung-RADS ^{16b}
Up to 6 mm	<p>≤4 mm: Low-risk: patient discussion, optional follow-up High-risk: follow-up CT scan at 12 mo (if stable no further follow-up)</p> <p>>4 to 6 mm: Low-risk: follow-up CT scan at 12 mo (if stable, no further follow-up) High-risk: follow-up CT scan at 6-12 mo (if stable, follow-up at 18-24 mo)</p>	<p><6 mm/<100 mm³: Low-risk: No follow-up High-risk: Optional follow-up CT in 12 mo</p>	<p><6 mm at baseline (or new nodule <4 mm on follow-up): return to annual screening (category 2)</p>
6 to 8 mm	<p>>6 to <8 mm: Low-risk: follow-up CT scan at 6-12 mo (if stable, follow-up at 18-24 mo) High-risk: follow-up CT scan 3-6 mo (if stable, then 9-12 mo and 24 mo)</p>	<p>6 mm to 8 mm/100 mm³ to 250 mm³: Low-risk: follow-up CT in 6-12 mo, then consider follow-up scan at 18-24 mo High-risk: follow-up CT in 6-12 mo, then repeat scan in 18-24 mo</p>	<p>≥6 mm to <8 mm at baseline (or new nodule 4 mm to <6 mm on follow-up): LDCT in 6 mo (category 3)</p>
8 mm or greater	<p>≥8 mm: Assess surgical risk and determine pretest probability of malignancy: Pretest probability <5%: surveillance CT in 3 mo Pretest probability 5%-65%: PET/CT scan to determine continued surveillance, nonsurgical biopsy, or surgical biopsy/resection Pretest probability >65%: referral for surgical biopsy or resection after appropriate staging workup</p>	<p>8 mm/>250 mm³: Low-risk: consider follow-up CT at 3 mo, PET/CT, or tissue sampling High-risk: consider follow-up CT at 3 mo, PET/CT, or tissue sampling</p>	<p>≥8 mm to <15 mm at baseline (or growing <8 mm or new nodule 6 mm to <8 mm on follow-up): 3-mo LDCT or PET/CT (category 4A) ≥15 mm (new or growing ≥8 mm): CT, PET/CT, and/or tissue sampling depending on probability of malignancy and comorbidities (category 4B)</p>

Abbreviations: CT, computed tomography; LDCT, low-dose CT; PET, positron emission tomography.

^a The American College of Chest Physicians criteria for low risk include individuals of younger age, little or no smoking history, smaller nodule size, regular margins, and location other than upper lobe. Criteria for high risk include individuals of older age, heavy smoking history, larger nodule size, irregular or spiculated margins, and upper lobe locations. Intermediate-risk individuals have a combination of high- and low-risk criteria. The Fleischner Society uses the same risk stratification as the American College of Chest Physicians.

^b Guideline is used for management of screen-detected pulmonary nodules as part of lung cancer screening program. The Lung-RADS guideline categorizes nodules based on their risk of malignancy: category 1 is a CT without any nodules; category 2 nodules have an average probability of malignancy <1%; category 3 nodules have an average probability of malignancy of 1%-2%; category 4A nodules, 5-15%; and category 4B >15%.

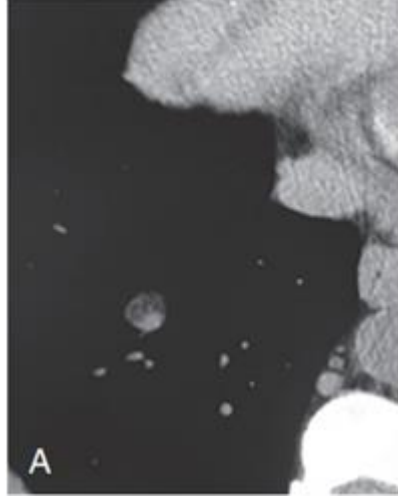
Table 3. Society Guidelines for the Management of Subsolid Pulmonary Nodules

American College of Chest Physicians ¹⁵	Fleischner Society ¹⁴	Lung-RADS ^{16a}
≤5 mm: no follow-up	<6 mm/<100 mm ³ : Ground-glass nodule: no routine follow-up Part-solid: no routine follow-up	Ground glass nodule <30 mm at baseline (or any size unchanged): return to annual screening (category 2) Part-solid nodule <6 mm at baseline: return to annual screening (category 2) Part-solid nodule <6 mm (new): follow-up CT scan at 6 mo (category 3)
>5 mm: Ground-glass nodule: follow-up CT scan at 12 mo then annual through 3 y Part-solid nodule: ≤8 mm solid component: follow-up CT scan at 3, 12, and 24 mo then annual until 5 y >8 mm solid component: follow-up CT scan at 3 mo, further evaluation with PET, nonsurgical biopsy, and/or resection if persists	≥6 mm/>100 mm ³ : Ground-glass nodule: follow-up CT scan 6-12 mo then every 2-5 y Part-solid nodule: follow-up CT scan 3-6 mo then annually for 5 y	Ground glass nodule ≥30 mm at baseline or new on follow-up: follow-up 6-mo CT (category 3) Part-solid nodule: Solid component <6 mm: follow-up CT at 6 mo (category 3) Solid component ≥6 to <8 mm or new or growing and <4 mm: follow-up CT at 3 mo (category 4A) Solid component ≥8 mm or new or growing and ≥4 mm: further evaluation (category 4B)

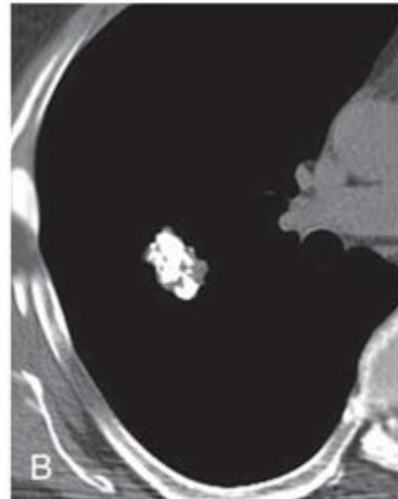
Benign Nodül Olgu Radyolojik Örnekleri

Hamartom

Lezyon içinde yağ →

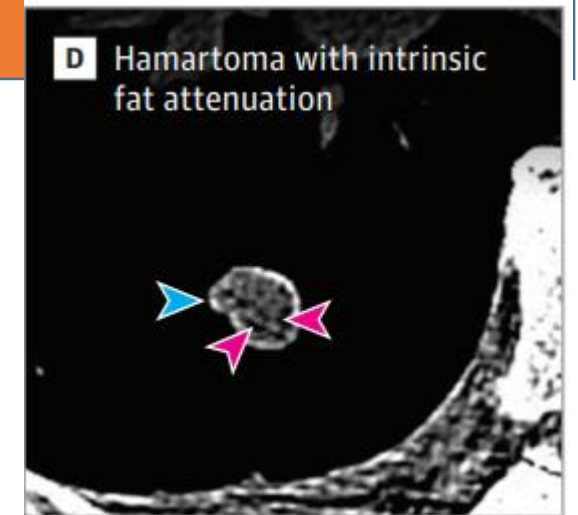


Popcorn patern →

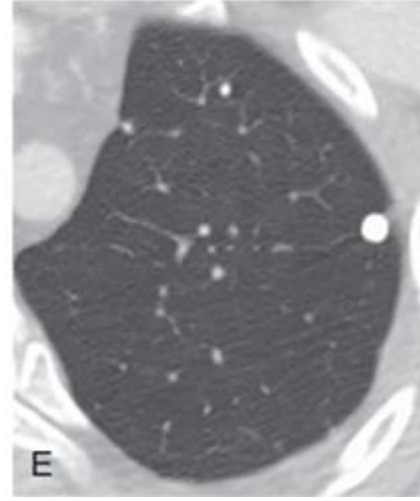
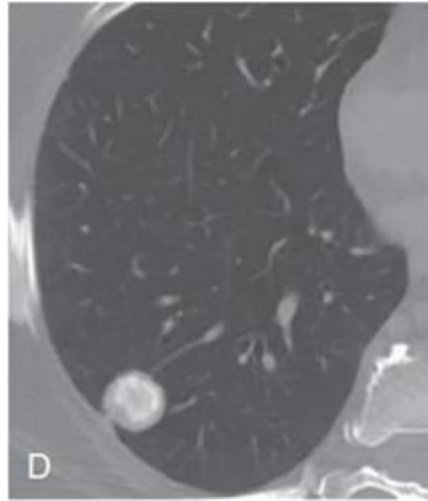
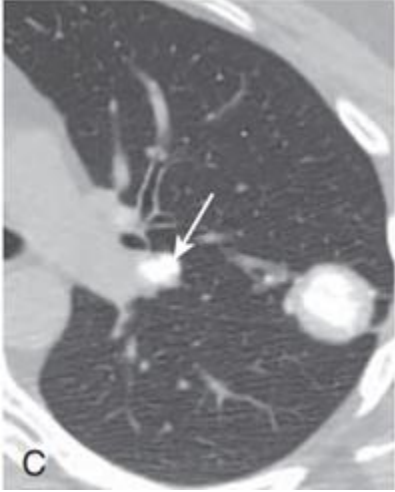


Pulmoner Hamartom:

- Yağ, epitel dokusu, fibröz doku ve kıkırdak dahil olmak üzere çeşitli dokulardan oluşabilen benign bir lezyondur.
- Tüm yoğunluklar her zaman mevcut olmasa da, bir nodül içinde görülen yağ ve kalsifikasyon pulmoner hamartom için tanı koydurucudur.



Nodülde Kalsifikasyon Olgu Radyolojik Örnekleri



Merkezi kalsifikasyon:

Granülom+ lenf nodu kalsifikasyonu

Laminer kalsifikasyon

Diffüz Kalsifikasyon

Benign

Diffüz, merkezi, laminer, popcorn kalsifikasyonlar postenfeksiyöz granülom ve hamartomu gösterebilir.

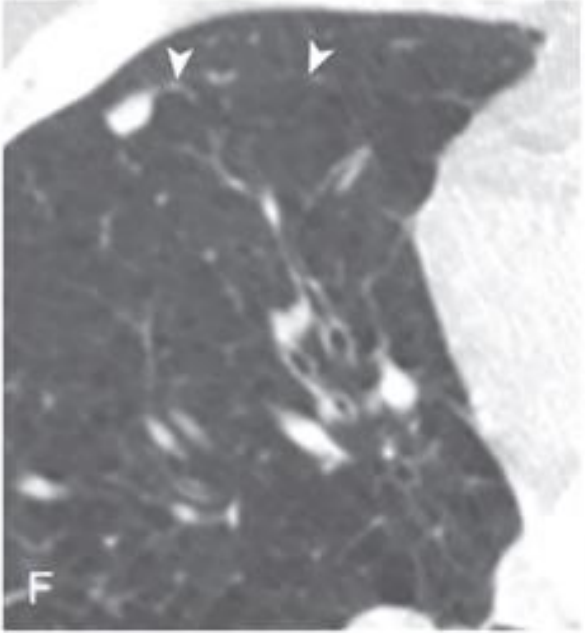
Malign

Noktasal veya eksantrik görünen kalsifikasyon paternleri daha çok malignite ile ilgilidir ve takip edilmelidir.

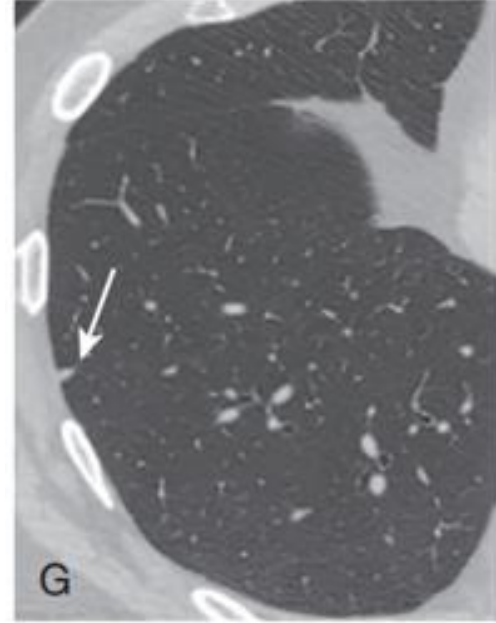
Benign Nodül Olgu Radyolojik Örnekleri

Perifissürel nodüller

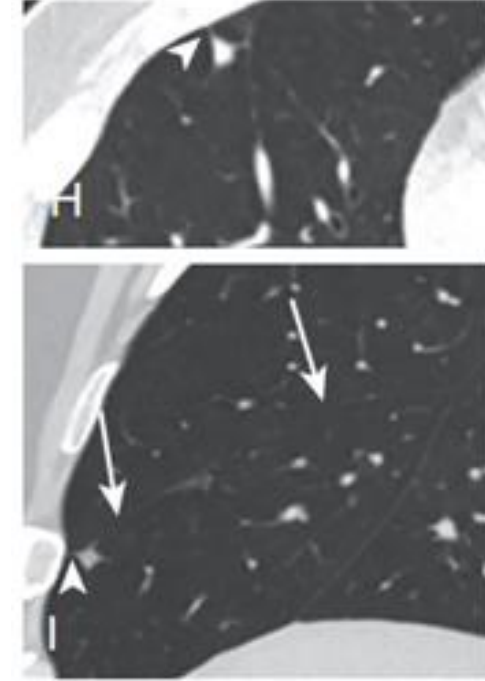
Perifissural alanda yer alan nodüller genellikle intrapulmoner lenf nodlarıdır.



Sağ minör fissürde

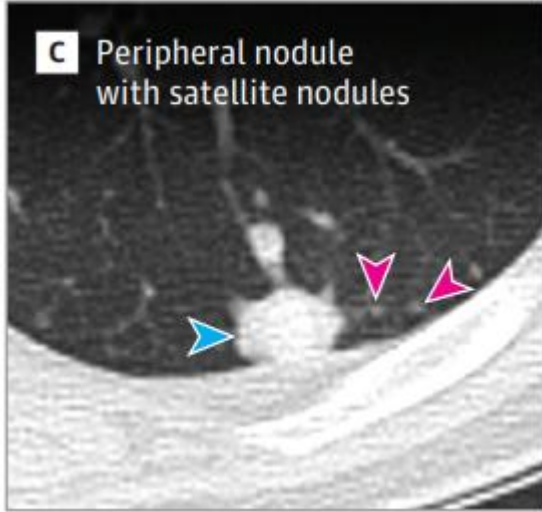


Visseral plevra ile geniş taban,
üçgen şekil

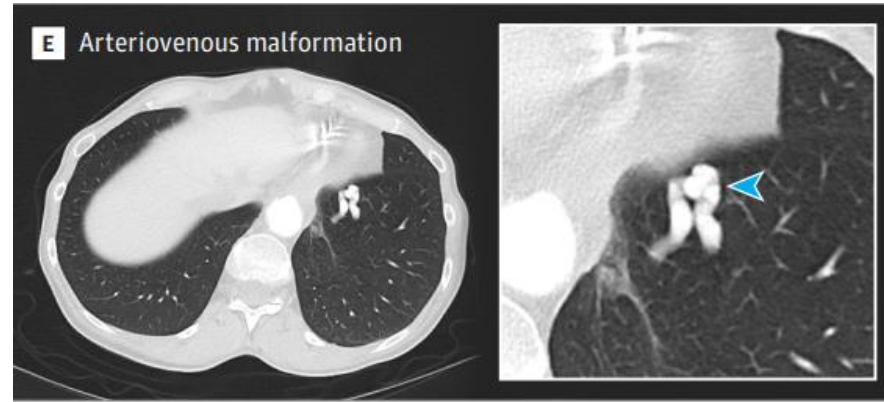


Nodülü viseral plevral yüzeye bağlayan
ince bir septum (ok başı) ile,
Nodül, minör fissürle temas eder, ancak
deforme etmez

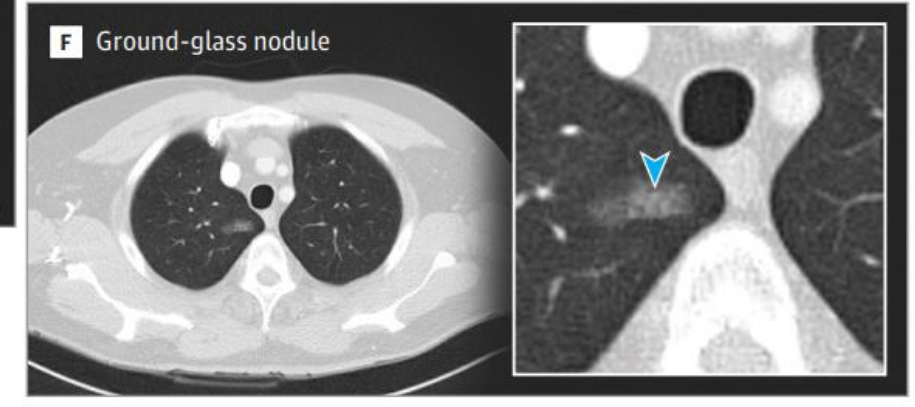Benign veya yavaş büyüyen nodüllere örnekler



Periferal nodül ve satellit nodüller
Granülamatöz süreç

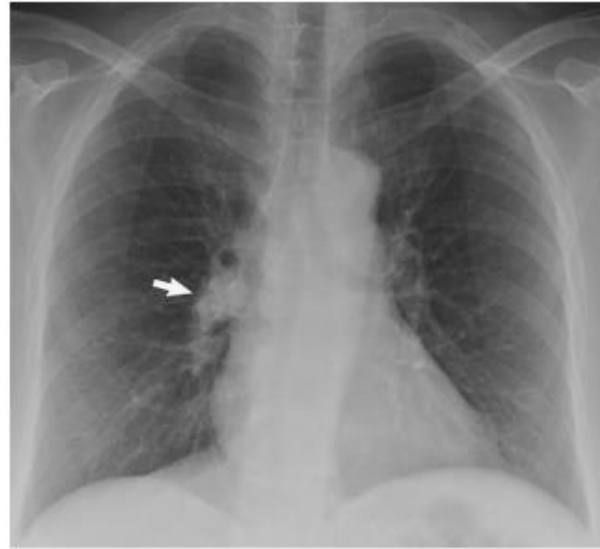


Arteriyovenöz malformasyon

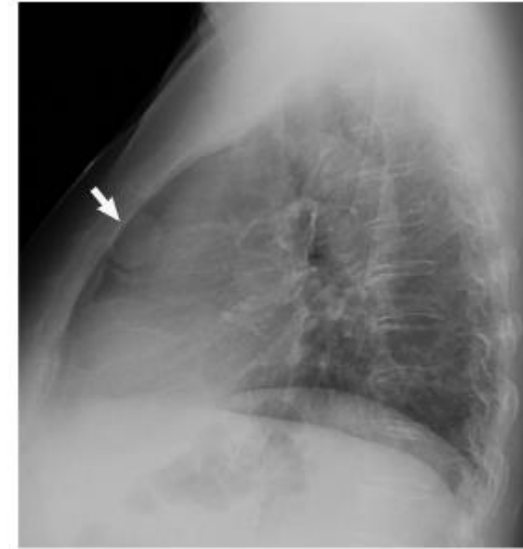

Buzlu cam nodül

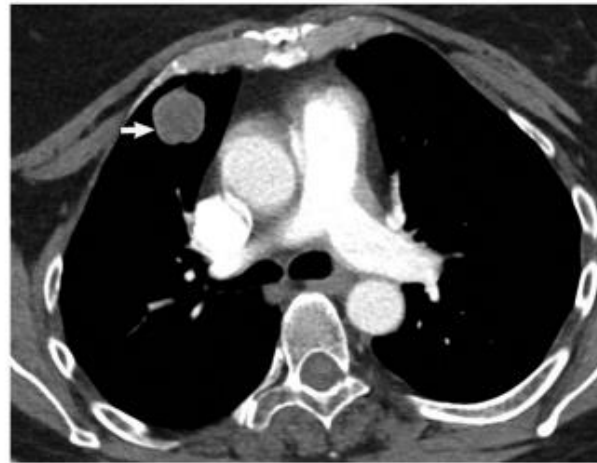
Görüntüleme- Akciğer filmi



(a)

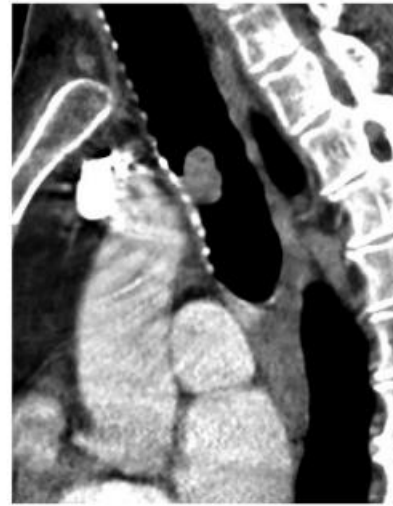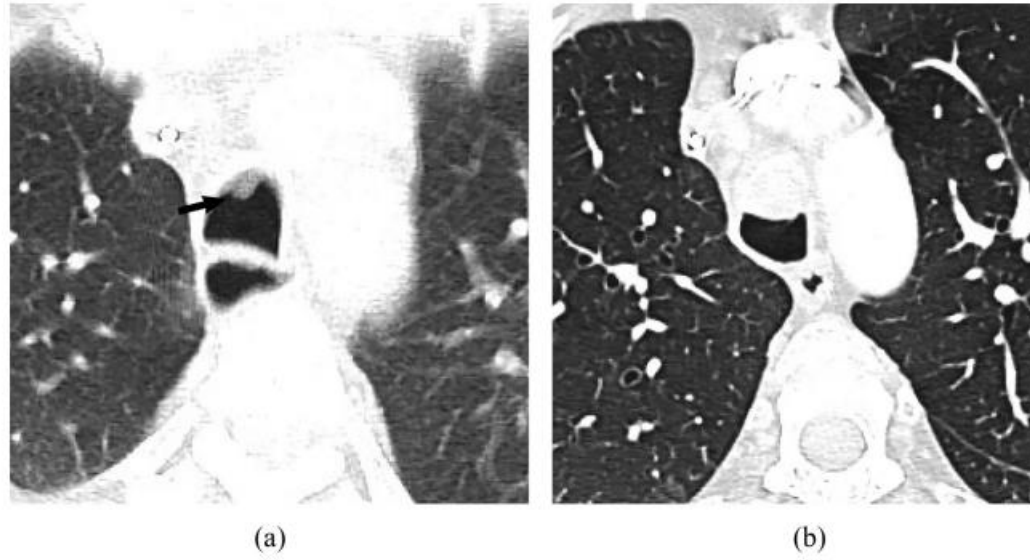


(b)



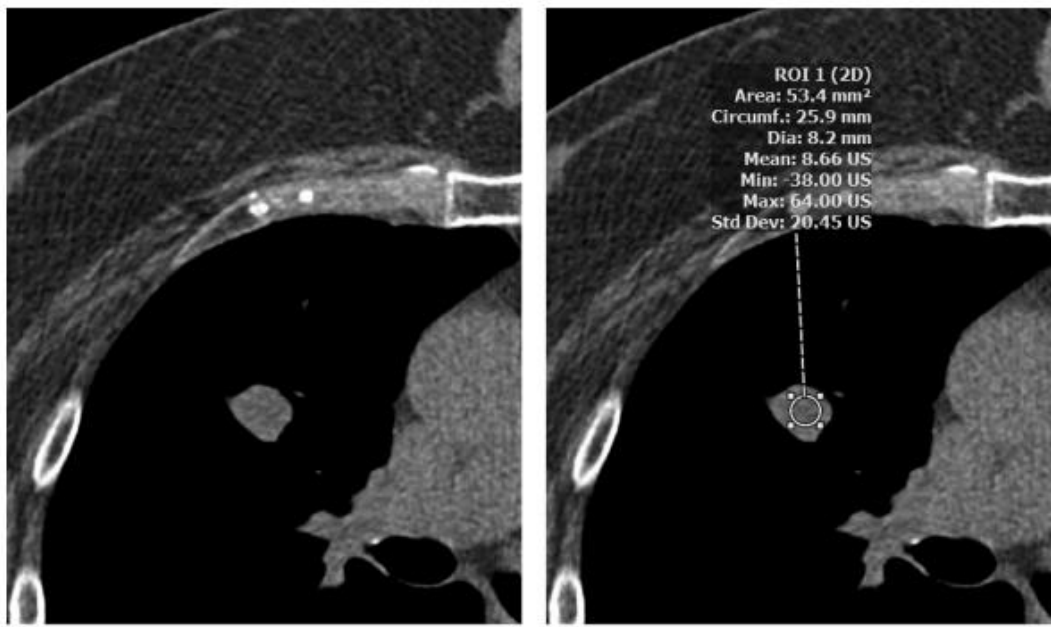
(c)

Figure 1 Perihilar region pitfall on chest radiograph. (A) PA chest radiograph performed on a 63-year-old woman shows a nodule (arrow) that is difficult to identify given it projects over the right hilum. The difference in attenuation and mild convexity of the right hilar region is an indicator of the possibility of a nodule or node in this region. (B) On the lateral radiograph, the nodule (arrow) is more evident projecting anteriorly. (C) Axial contrast-enhanced chest CT soft tissue image shows the nodule in the anterior segment of the right upper lobe (arrow).



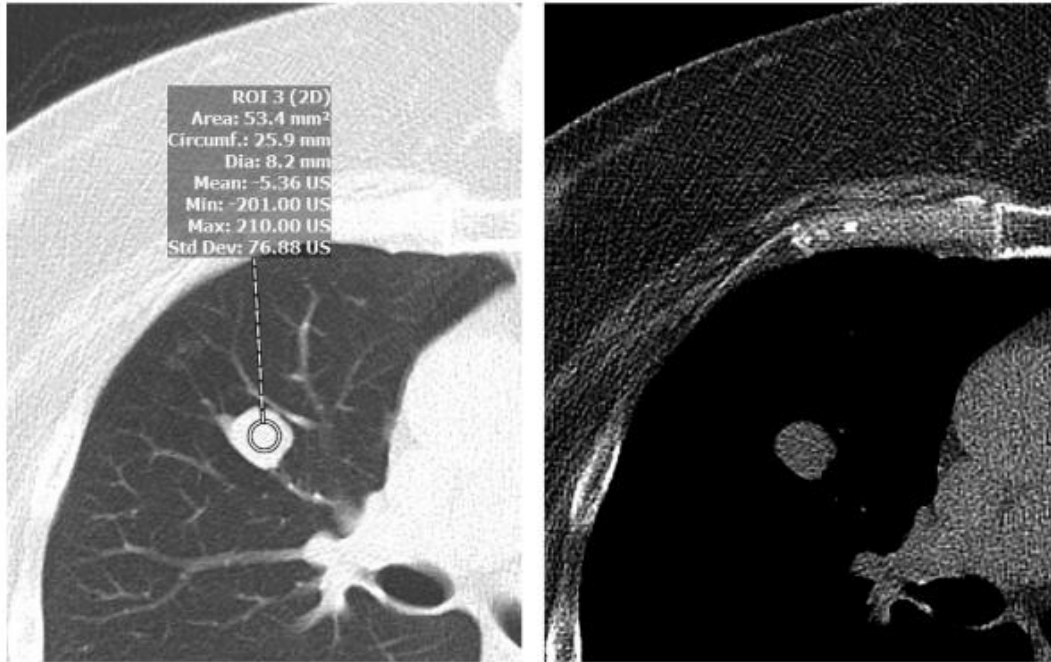
Havayolu nodülü

Figure 2 Airway nodule. (A) Axial CT image shows a subtle nodular area (arrow) in the anterior non-dependent trachea. (B, C) Contrast-enhanced chest CT images 4 months later demonstrate growth of the finding, with a round soft-tissue lesion in the anterior trachea on axial lung image (B). The airway location and nodular shape is better seen on sagittal soft-tissue window image (C).



(a)

(b)



(c)

(d)

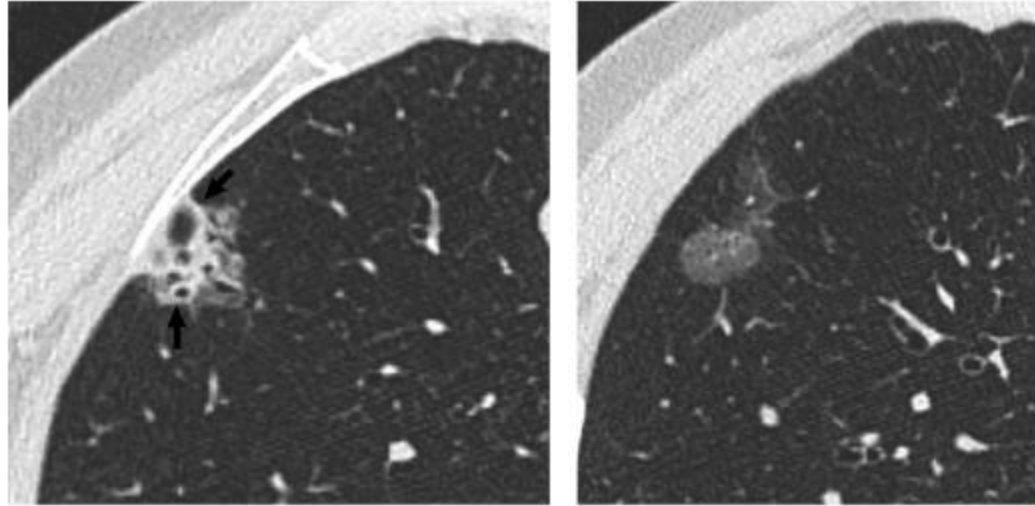
Solid nodül
Karsinoid tümör
Nekroz içeren düzgün sınırlı nodül

Karsinoid tümör ve HU ölçümü. 2 mm göğüs BT görüntüsü (A) (B) Ortalama Hounsfield birimi (HU) ölçümü yaklaşık 9 HU olup nekrozu düşündürür.

(C, D) 5 mm yüksek frekanslı akciğer (C) (D) 20 HU ile karşılaştırıldığında 77 HU deri altı dokusunda görüldüğü gibi makroskopik yağ (D) için beklendiği kadar düşük olmadığını gösterir.

Bilgisayarlı tomografide yoğunluk ölçüm değerleri (HU)
Hava -1000
Yağ -50 ile -100
Su 0
Kist 0 ile 20
Taze kan - pıhtı 40 ile 60
Nonkalsifiye nodül 40 ile 160
Kalsifiye nodül 200 üzeri
Kemik 1000

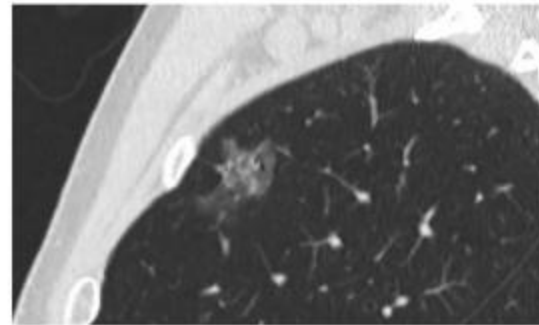
Figure 3 Carcinoid tumor and HU measurement. (A, B) Low-frequency algorithm reconstructed 2 mm chest CT image viewed in soft tissue windows with (A) and without (B) region of interest (ROI) placed on the nodule demonstrate a well-circumscribed, smoothly-marginated solid nodule with low attenuation in the center. The mean Hounsfield unit (HU) measurement is about 9 HU, suggesting necrosis. (C, D) On 5 mm high-frequency algorithm reconstructed image viewed under lung (C) and soft-tissue window settings (D), there is much greater image noise despite thicker image section thickness, with standard deviation (SD) of 77 HU, compared to the 20 HU on soft tissue images. Also note how the mean HU is lower (-5 HU) and can lead to pitfalls in attenuation characterization. Regardless, visual inspection shows that the low-attenuation areas are not as low as expected for macroscopic fat (D), as seen in the subcutaneous fat.



(a)

(b)

12 MM SOLID KOMPONENT
2.2 CM NODÜL



(c)

Part-solid nodül
İnvaziv adenokarsinom

Figure 4 Part-solid nodule representing an invasive adenocarcinoma. (A, B) Axial and (C) sagittal chest CT lung-window images show a part solid approximately 2.2 cm nodule with predominantly soft tissue component (A, arrow) that was over 50% of the nodule and maximal soft tissue dimension of approximately 12 mm that is difficult to measure due to amorphous shape, as seen on inferior axial image (B) and sagittal plane (C). Resection confirmed an acinar predominant adenocarcinoma with fibroelastotic scar.

Kalsifiye solid nodül
Malign karakter kalsifikasyon
KHDAK

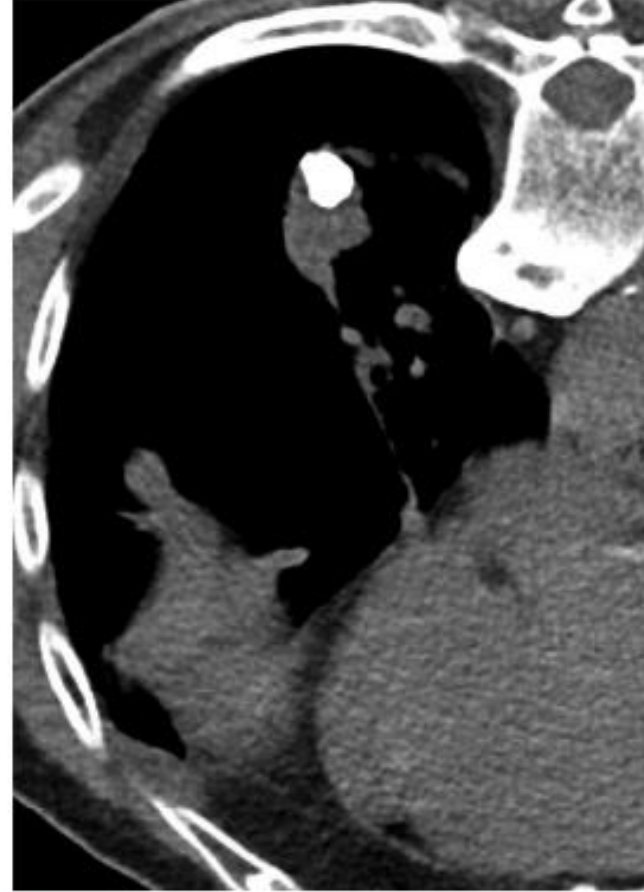


Figure 5 Prone soft-tissue image from CT-guided transthoracic lung biopsy shows a large calcification that is eccentrically located in a large nodule, an indeterminate calcification pattern. The nodule was confirmed to be a non-small cell lung cancer. Calcification presumably was a calcified granuloma that was in the region of lung cancer.

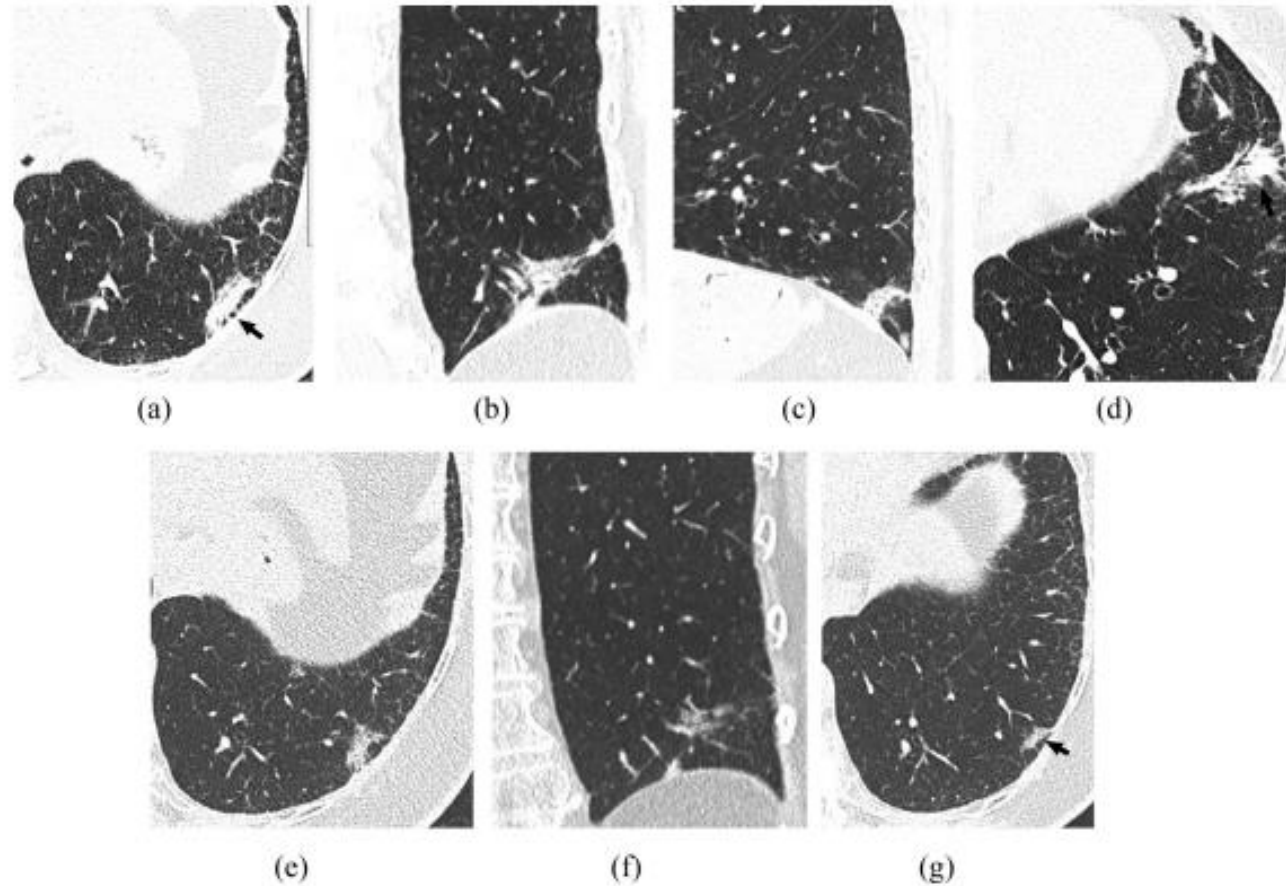
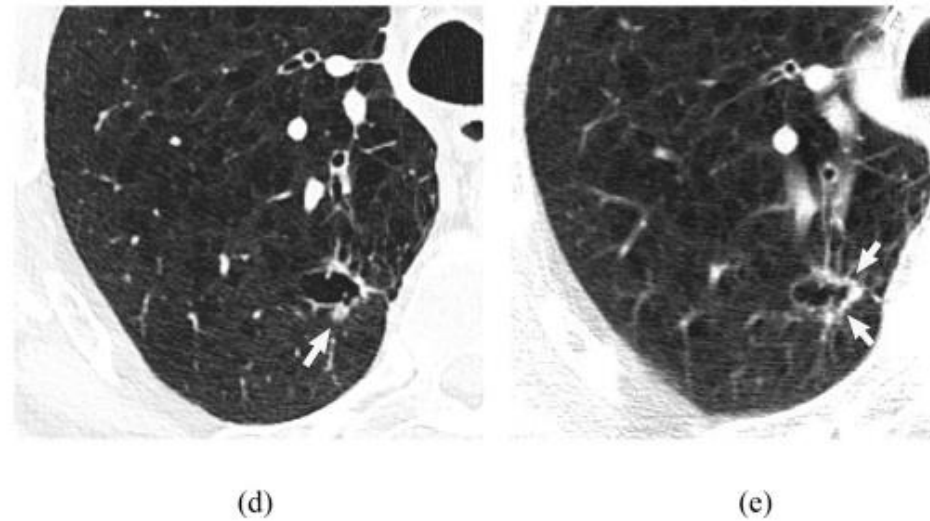
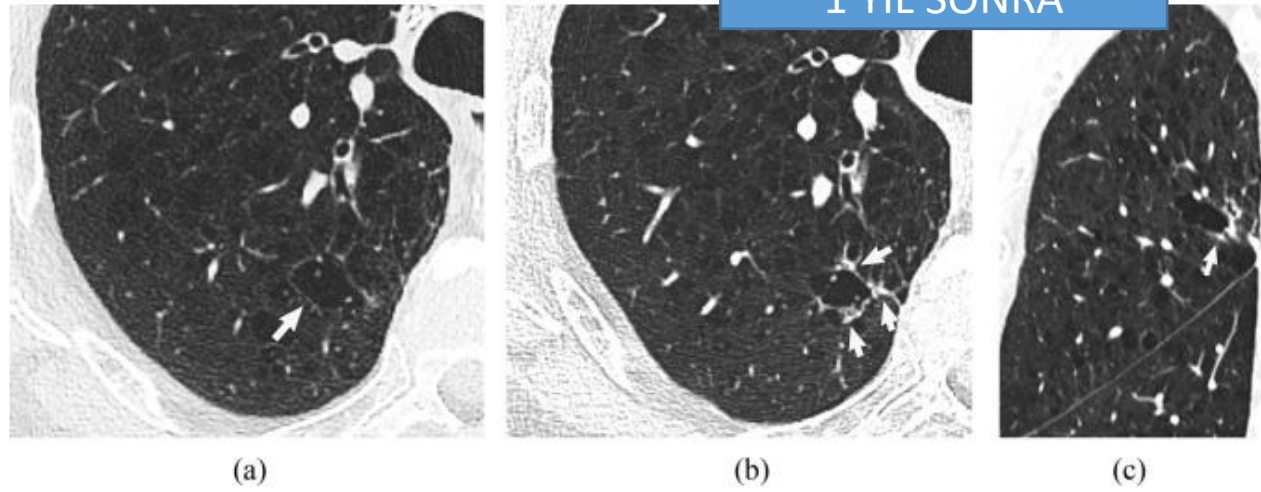


Figure 6 Amorphous appearing adenocarcinomas. (A, B, C) Axial (A), coronal (B), and sagittal (C) non-contrast chest CT images show an oblong triangular, predominantly soft-tissue focal opacity (arrow) in the posterolateral left lower lobe. (D) Additional oblong focal soft-tissue opacity (arrow) is present in the anterior left lower lobe (arrow). (E, F) Review of axial (E) and coronal (F) chest CT images from a year prior to the current study shows that the posterolateral nodular finding had grown between the two exams. This finding had been very linear (arrow) on an exam performed 1.5 years (G) prior to the current study. Biopsy of the posterolateral lesion revealed invasive mucinous adenocarcinoma. Both the posterolateral and anterior left lower lobe lesions were resected along with other foci which were mucinous and nonmucinous adenocarcinomas.

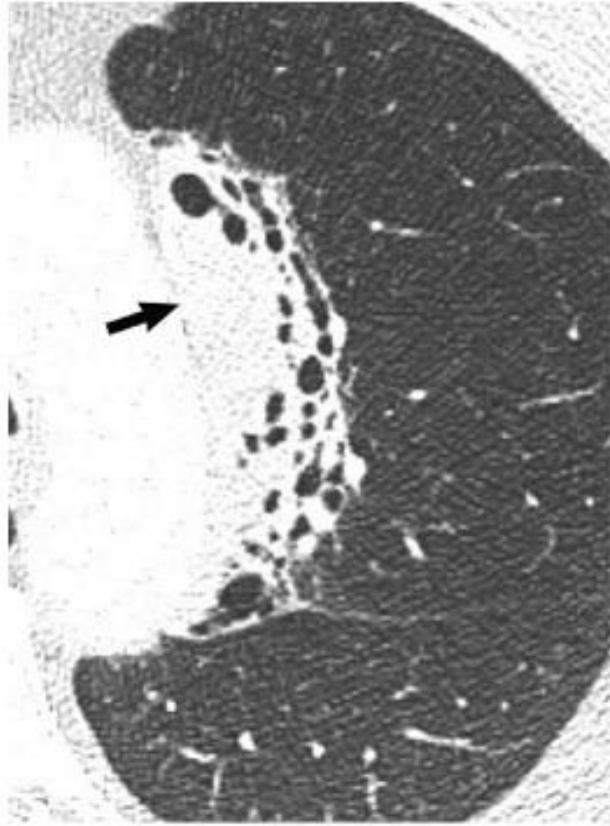
Adenokarsinom

1 YIL SONRA

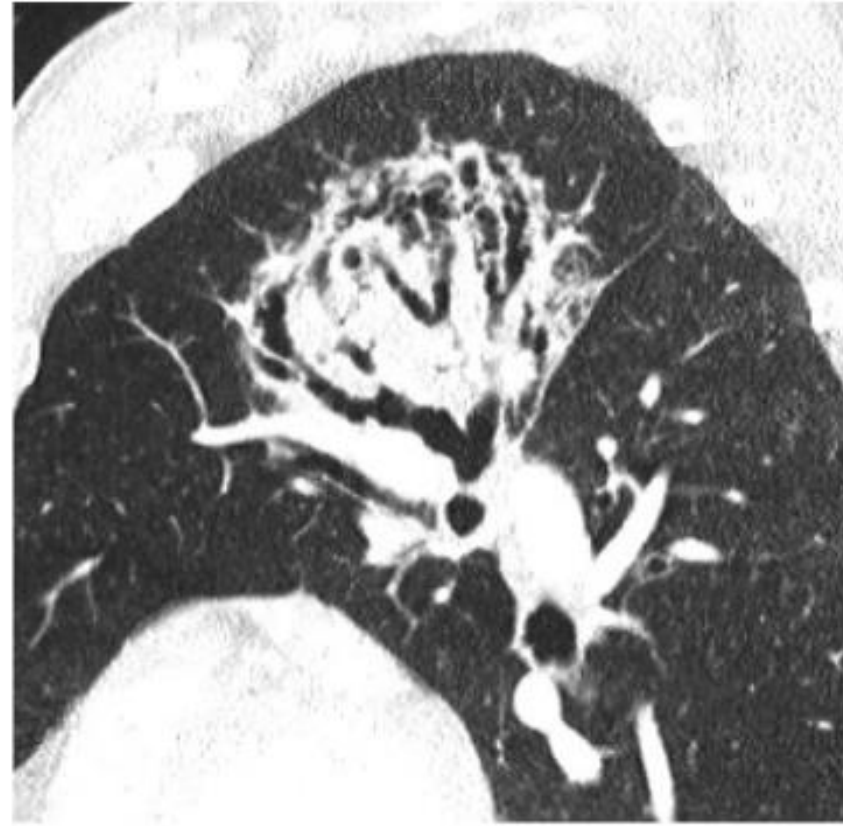

Kistik Malignite
Adenokarsinom

Figure 7 Cystic cancer. (A) 83-year-old-man with axial chest CT image showing a focus of emphysema in right upper lobe (arrow). (B, C) Chest CT 1 year later shows asymmetric mild soft-tissue thickening of the medial, anterior, and posterior walls (arrows) of emphysematous focus on axial image (B). The coronal image (C) better shows the nodular thickening (arrow) and discrete nature. (D) Chest CT one year later (2 years after first CT) shows mild increase in surrounding soft tissue with a nodular opacity currently evident posteriorly (arrow). (E) CT image from FDG PET CT 6 months later (2.5 years later) shows increased wall thickening (arrows) and mild decrease in the overall lesion size and cystic component. Resection demonstrated adenocarcinoma, acinar-predominant with lepidic and micropapillary patterns.



(a)



(b)

Marjinal zon
lenfoma

Figure 8 (A, B) Axial (A) and sagittal (B) chest CT images show a soft tissue ovoid mass-like area medially in the left upper lobe that has air bronchograms with architectural distortion, indicated by the bronchiectasis. An area (A, arrow) within the finding lacks air bronchograms. Given this and the mass-like appearance, sampling was performed confirming marginal-zone lymphoma.

3 AY SONRA

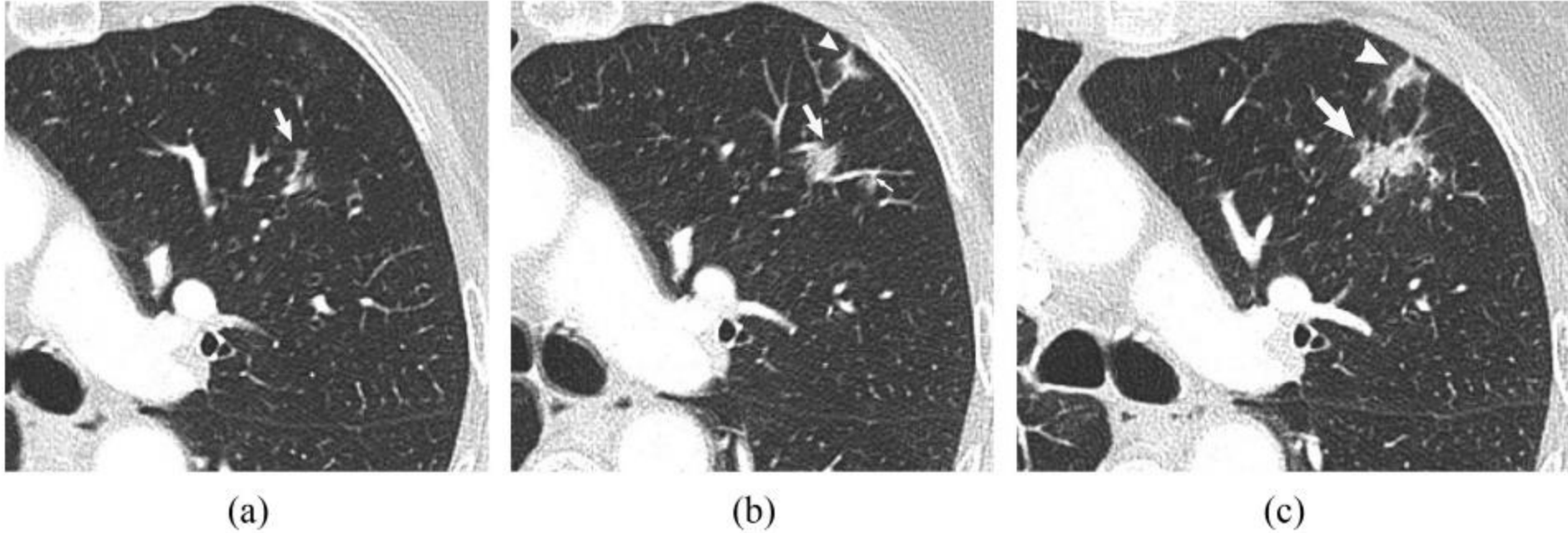


Figure 9 Branching and nodular malignancy. (A) In a 65-year-old woman with history of resected mucinous adenocarcinoma in the right lower lobe, chest CT axial images demonstrate a mild tubular branching opacity in the left upper lobe (A, arrow). (B) Chest CT image 3 months later shows increase in the finding to an irregular and nodular density (arrow), with a new adjacent slightly-branching opacity (arrowhead) and new part-solid nodular opacity (small arrow). (C) Axial chest CT image four months later shows increase in size of the finding that had presented initially as a tubular branching opacity (arrow) and in the more anterior finding (arrowhead). Although standardized uptake value (SUV) was 2, suggesting low metabolic activity, the interval enlargement and irregular morphology raised the possibility of malignancy, particularly in light of the patient's history of mucinous adenocarcinoma. CT-guided needle biopsy confirmed invasive mucinous adenocarcinoma.

Adenokarsinom

6 AY SONRA

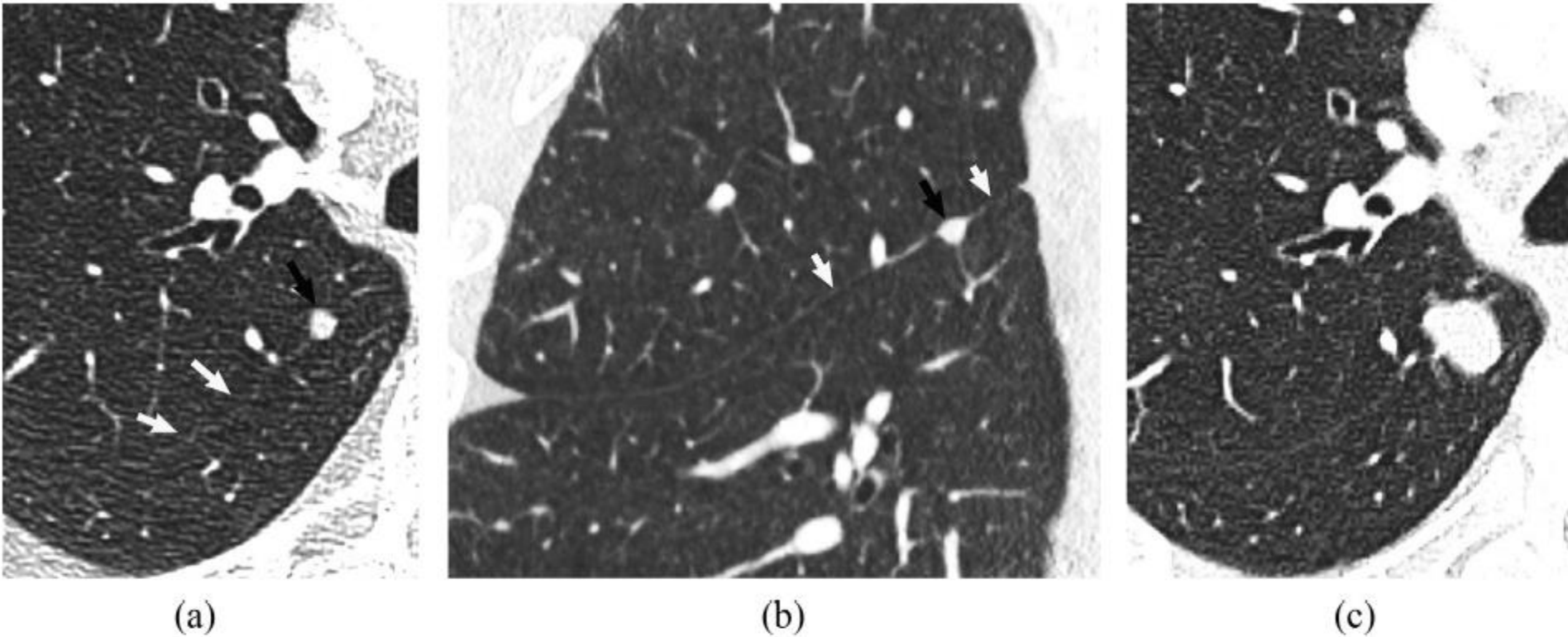


Figure 10 Nodule along fissure that is not a “perifissural” nodule. (A, B) Axial (A) and sagittal (B) chest CT images show a nodule in a patient with history of melanoma. The nodule is located in the right lower lobe superior segment (black arrow) and appears attached to the right major fissure (white arrows). A convex contour however is present at interface with the right major fissure. Also, the margin is mildly lobulated. The nodule therefore does not satisfy the criteria for a perifissural nodule. (C) Axial chest CT image 6 months later shows the nodule to have increased in size, with a more lobulated contour. The patient had metastatic melanoma. Also guidelines for perifissural nodules pertain to those without a malignancy history.

Metastatik melanom

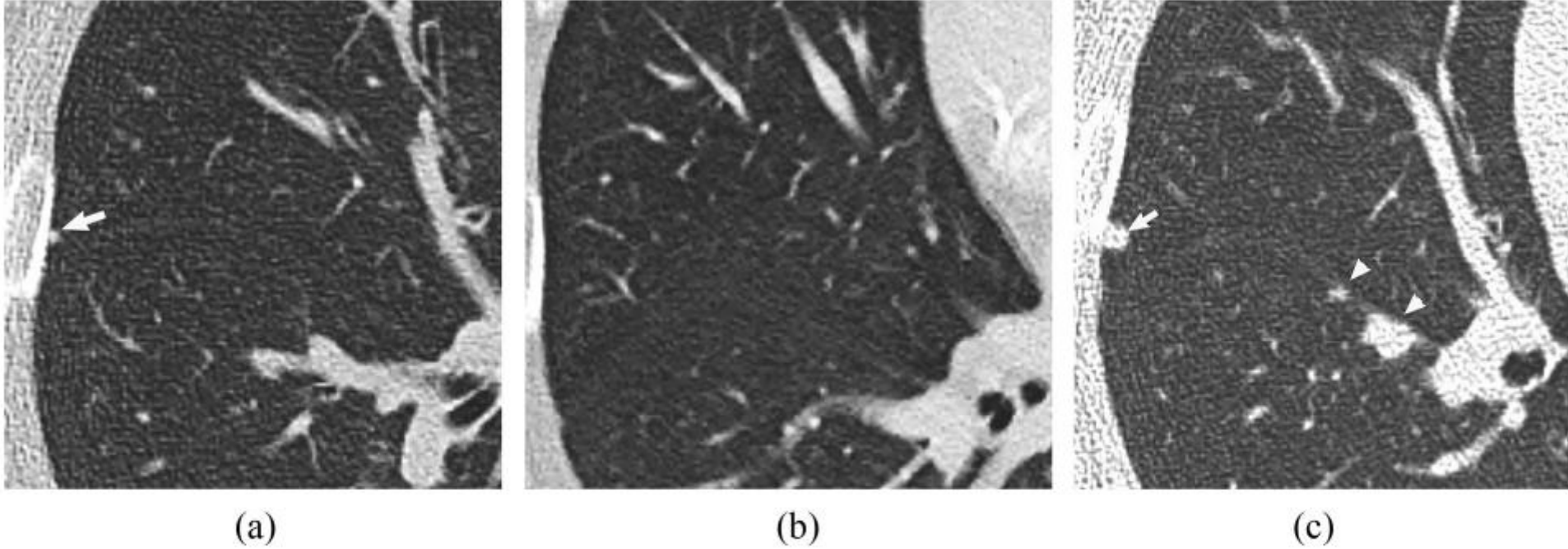


Figure 11 Small yet significant new micronodule. (A) Chest CT in a patient treated with lumpectomy 7 months prior for breast cancer shows a very small 2 mm nodule that developed since a prior CT one year prior (B). (C) Chest CT follow up 6 months later shows interval growth (arrow) and development of multiple other nodules (arrowheads). Despite small size, nodules in patients with cancer history have higher likelihood for malignancy. Note the development of the nodules adjacent to the fissure and the lobulated contour, which are not characteristic of “perifissural nodules.”

Meme kanseri öyküsü yeni bir
mikronodül
Metastatik

Sonuç

- Pulmoner nodül insidansı giderek artmaktadır.
- Pulmoner nodüllerin değerlendirilmesi ve yönetimi malignite olasılığının değerlendirmesi ile başlar.
- Solid nodüllerde, malignite olasılığı düşük olanlar, görüntüleme ile büyüme için izlenmelidir.
- Hastanın sağlık durumu ve nodül yeri cerrahiye uygun ise, yüksek riskli olarak belirlenenler cerrahi rezeksiyon için düşünülmelidir.
- Orta riskli bir nodülde, yönetim seçenekleri daha fazla değerlendirmeyi içerir. PET-BT ve/veya bilgisayarlı tomografi ve/veya biyopsi ile ve kararlar hasta tercihlerini içermelidir.
- Nonsolid nodüller, aynı zamanda saf buzlu cam opasiteleri olarak da bilinir. Malign olma olasılığı daha düşüktür, daha az sıklıkta daha uzun süreli görüntüleme ile takip edilmesi önerilir.
- Nodül yönetiminin geleceği muhtemelen biyobelirteçleri, gelişmiş bronkoskopik teknikleri, ekshale edilen nefes analizini ve deep machine learning içerecektir.

Teşekkürler



ASYOD
AKCİĞER SAĞLIĞI VE YEDİĞİN BİLİMİ DERNEĞİ
www.asyod.org

UASK 2024

Uluslararası Katılımlı
AKCİĞER SAĞLIĞI
KONGRESİ

6-9 Mart 2024
Sueno Deluxe Hotel,
Belek/Antalya

Sizin Sesiniz, Sizin Kongreniz...

