

Toraks HRCT'de Temel paternler

Prof Dr Polat Koşucu
KTÜ Tıp Fakültesi Radyoloji AD

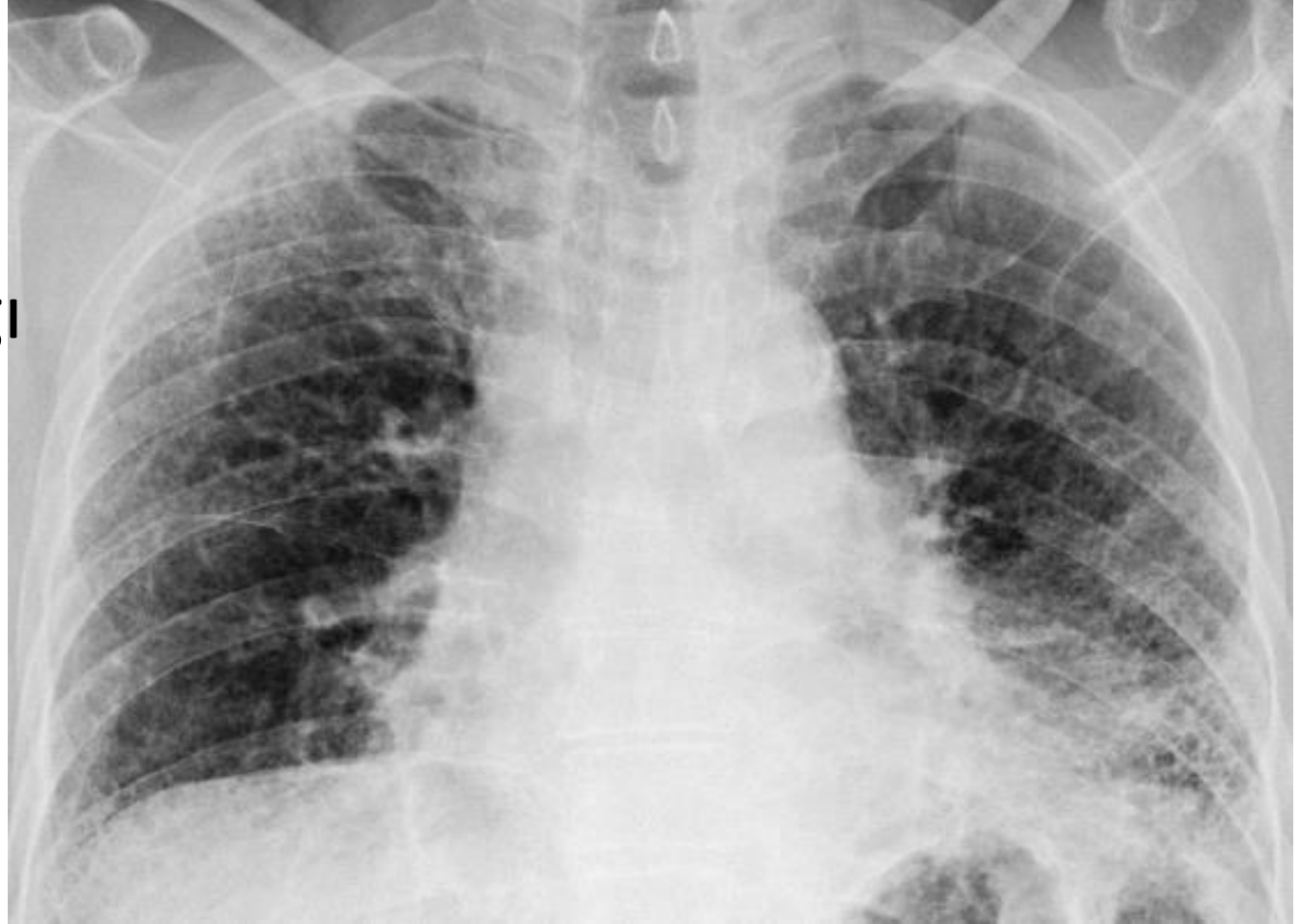HRCT paternleri

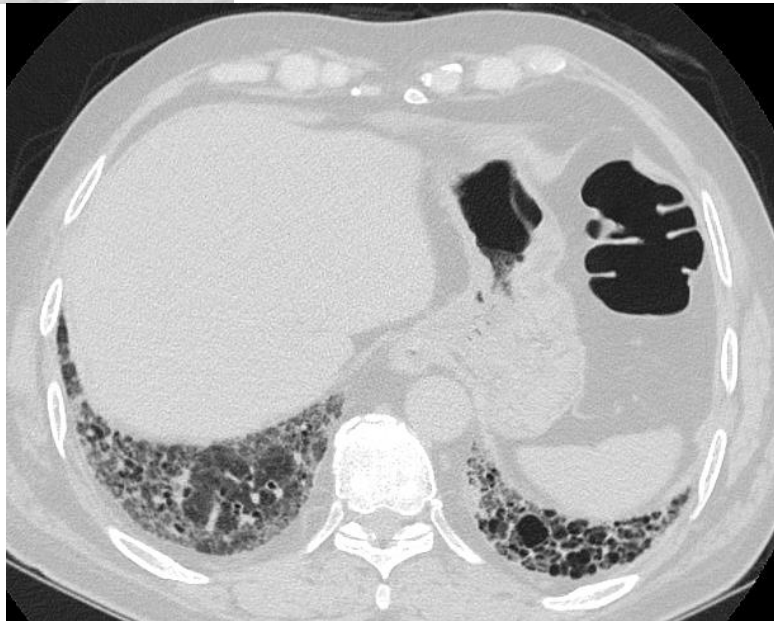
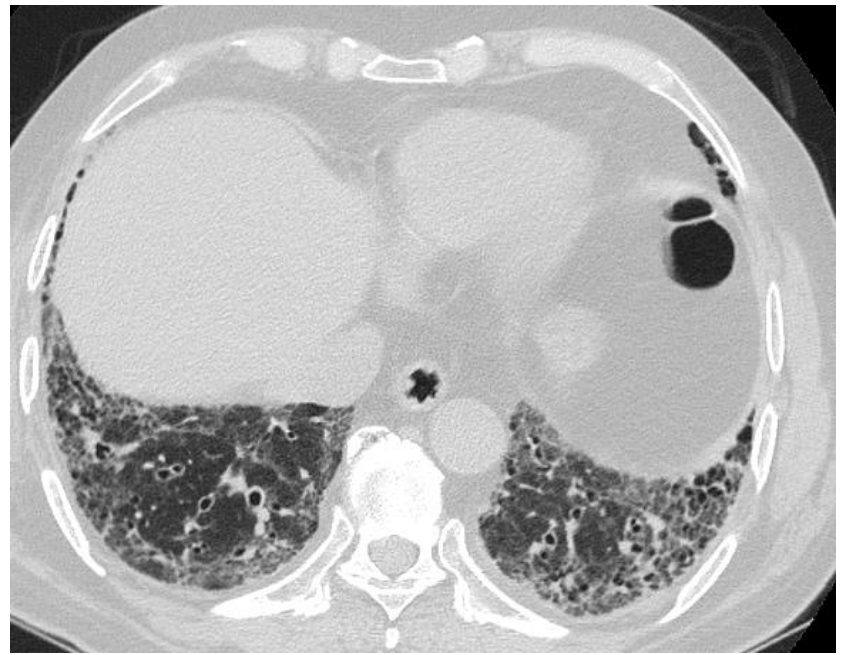
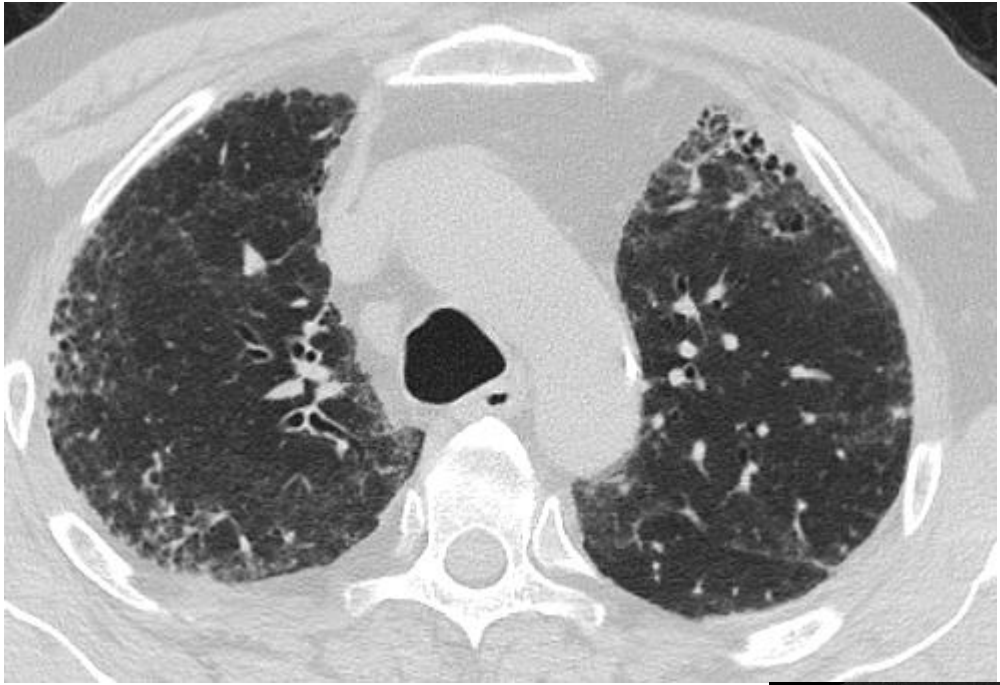
- Retiküler patern
- Nodüler patern
- Yüksek atenüasyon paterni
- Düşük atenüasyon paterni

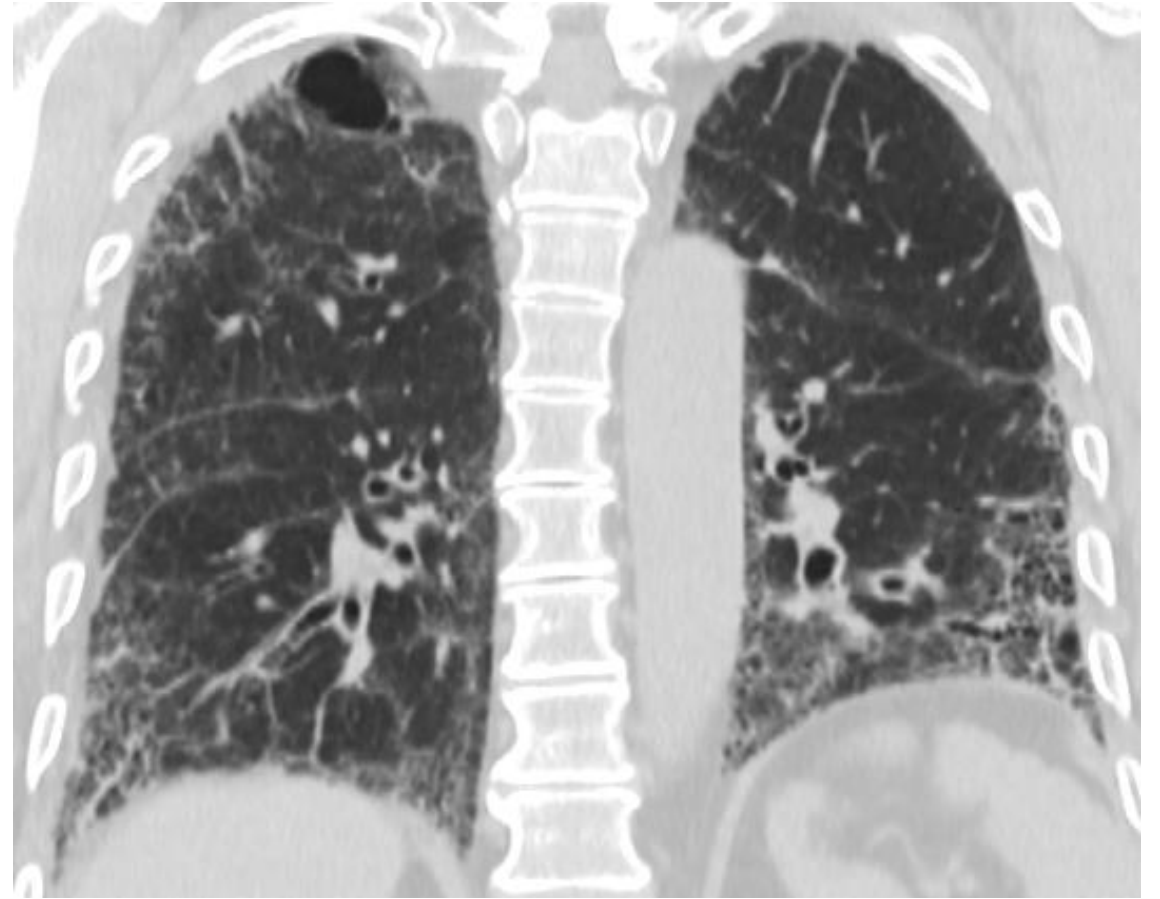
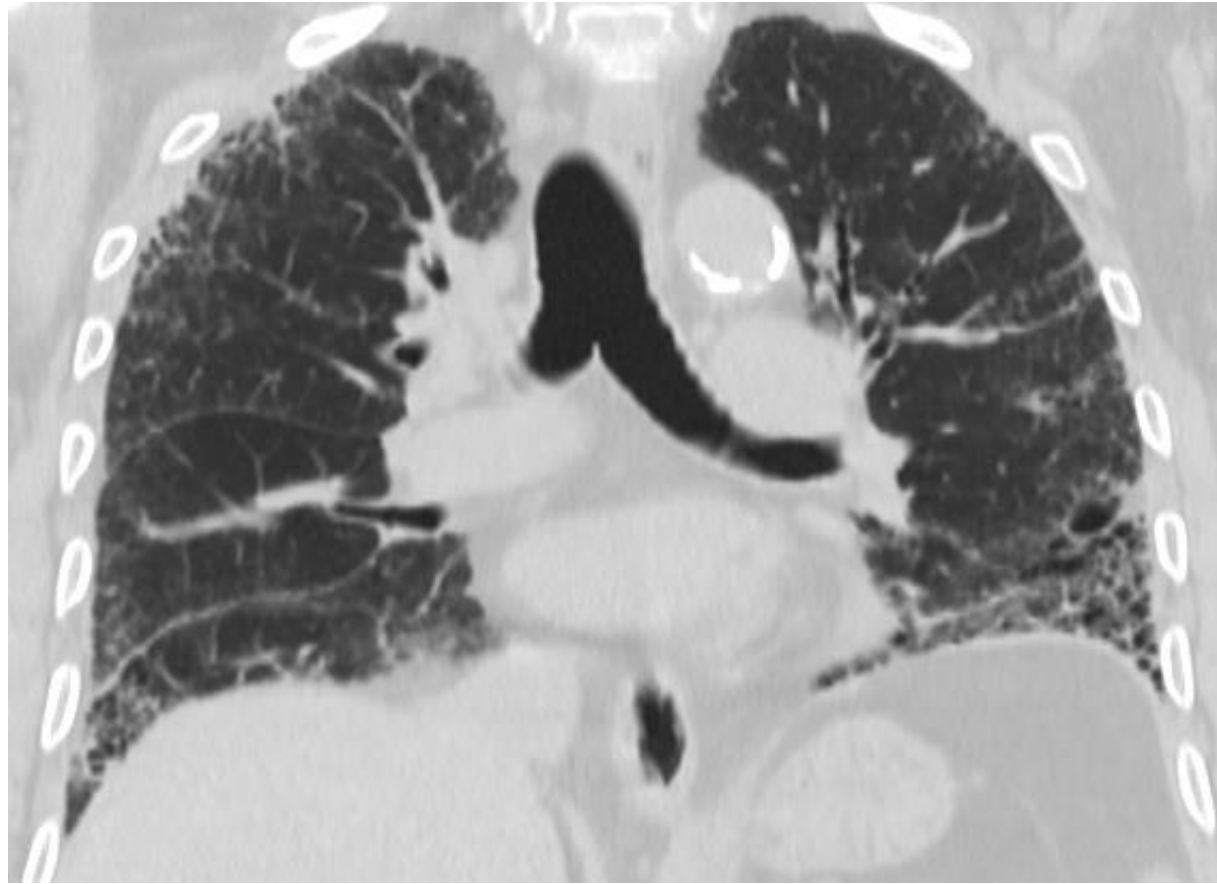Retiküler patern

- Septal kalınlaşma
- Bal peteđi

61 yaşında erkek
İnterstisiyel akciğer hastalığı

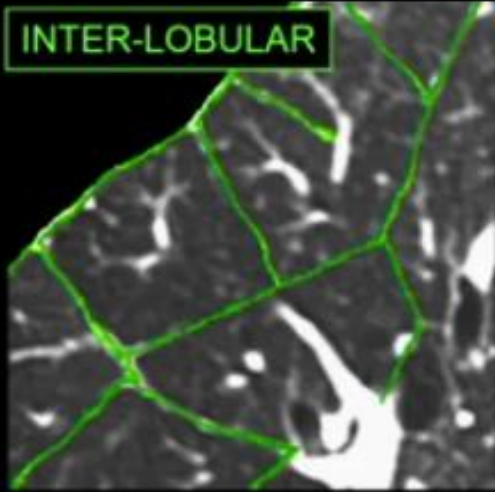




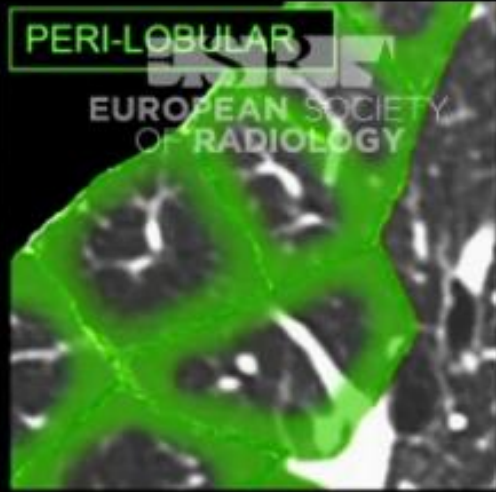

Düzgün	Nodüler ya da düzensiz
Lenfanjitik karsinoma	Lenfanjitik karsinom
İnterstisiyel pulmoner ödem	Lenfoma
Alveoler proteinozis	Sarkoidozis
	Silikozis

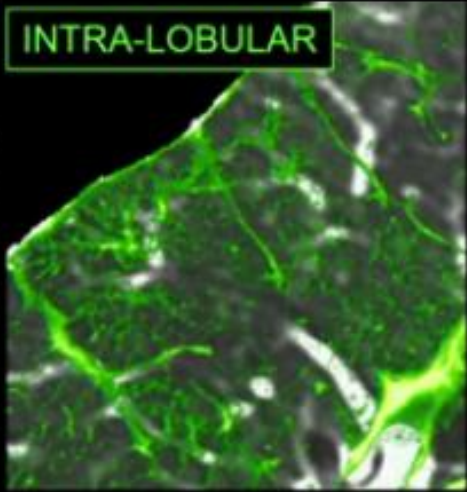
INTER-LOBULAR



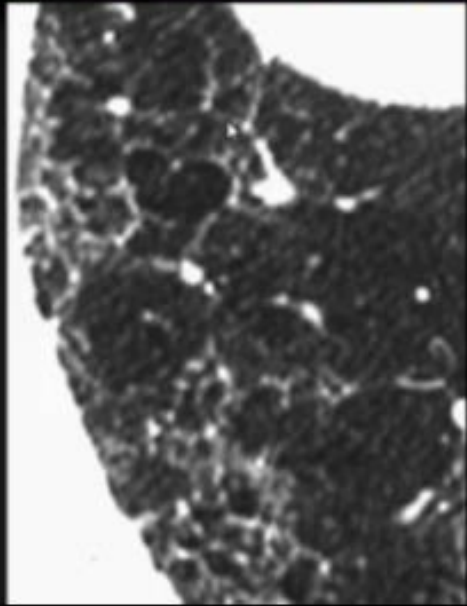
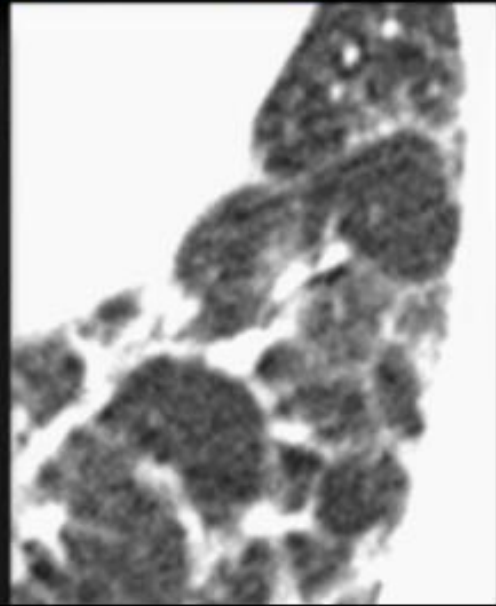
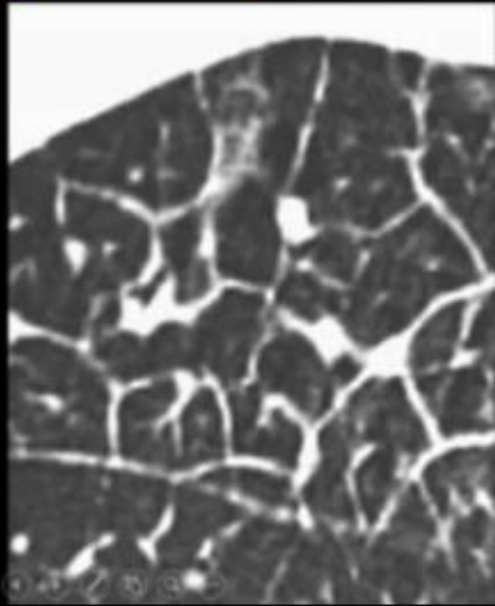
PERI-LOBULAR

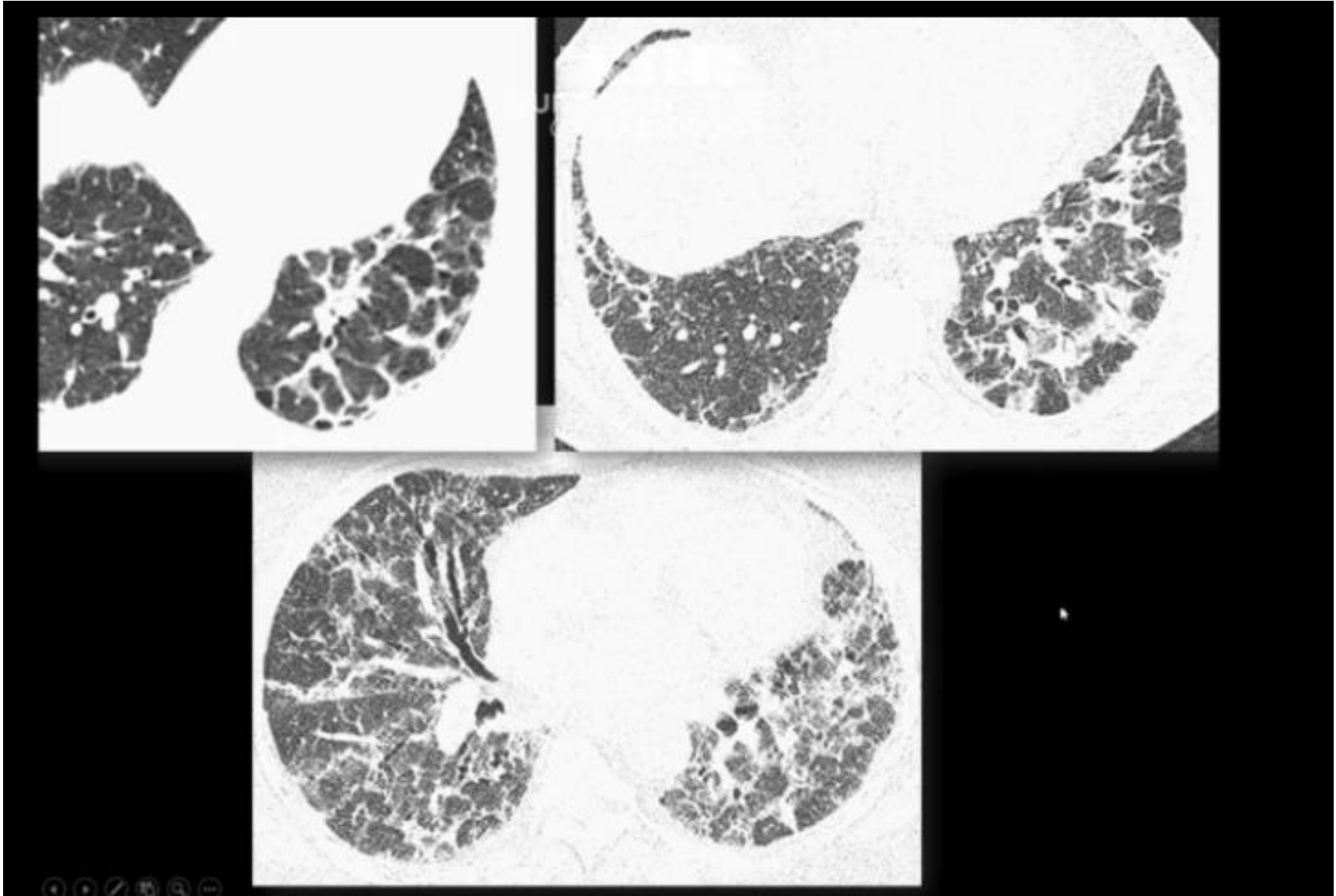


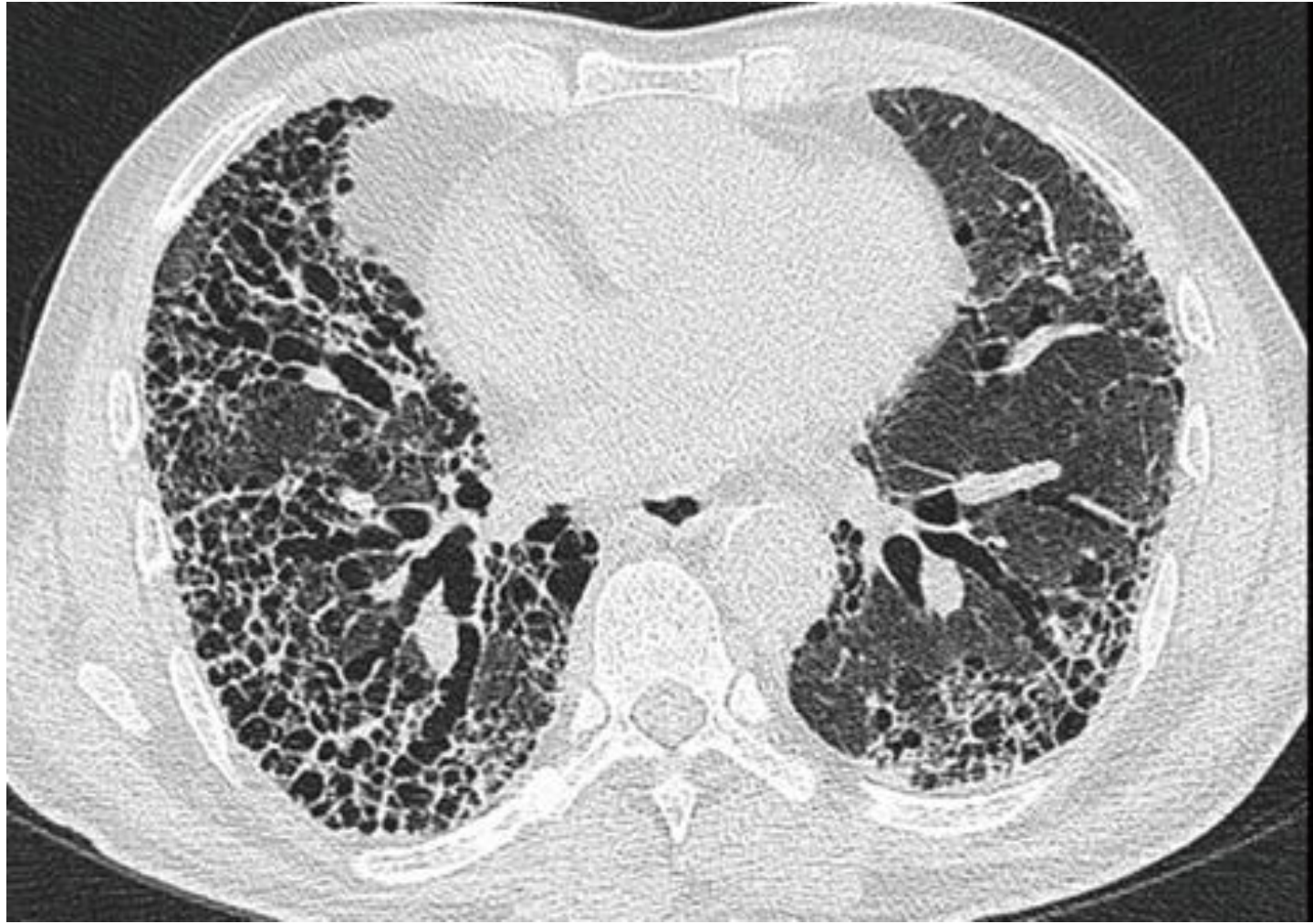
INTRA-LOBULAR

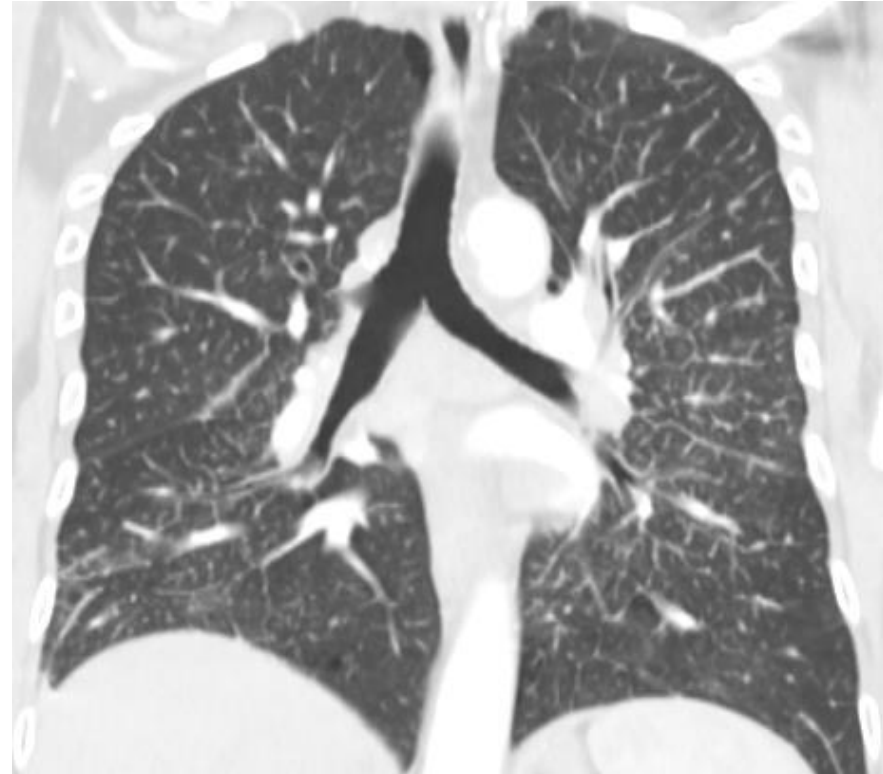
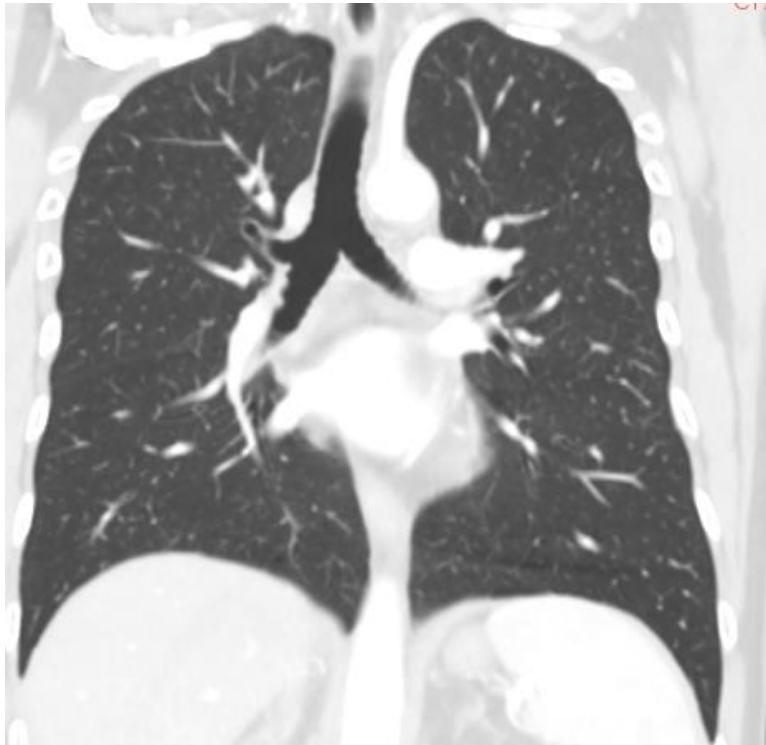
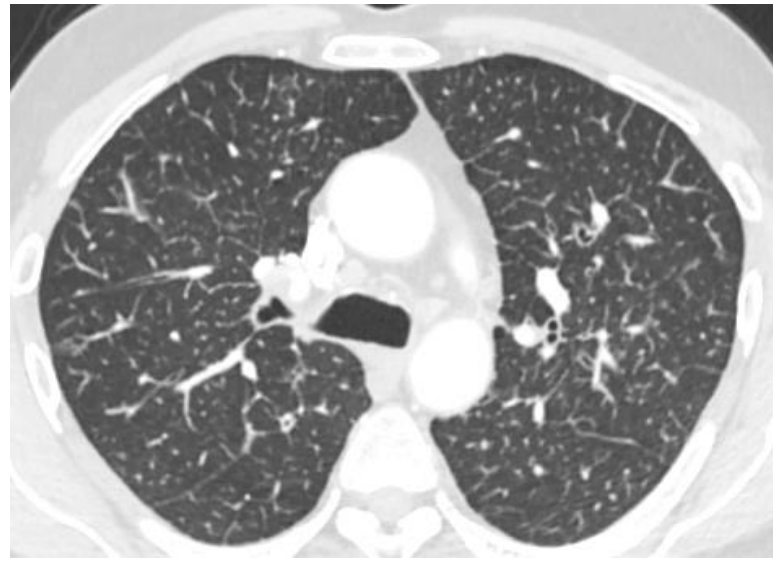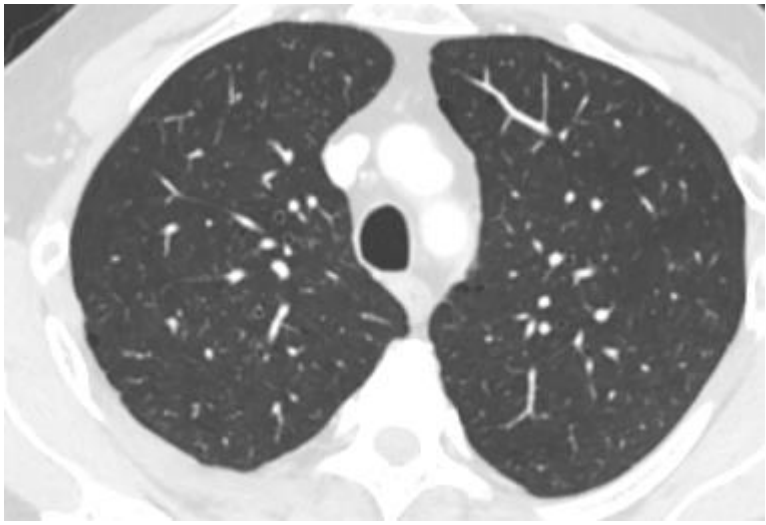


EUROPEAN SOCIETY OF RADIOLOGY



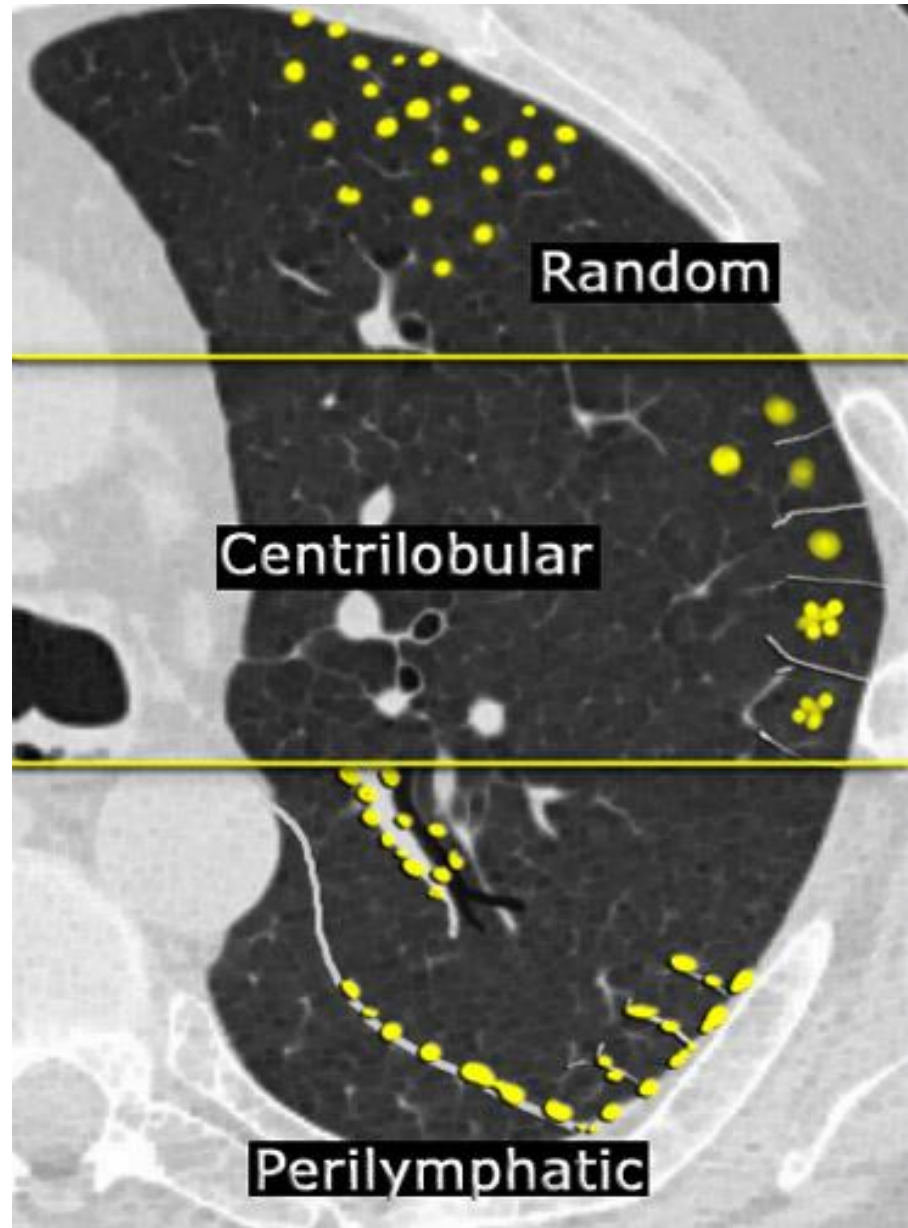






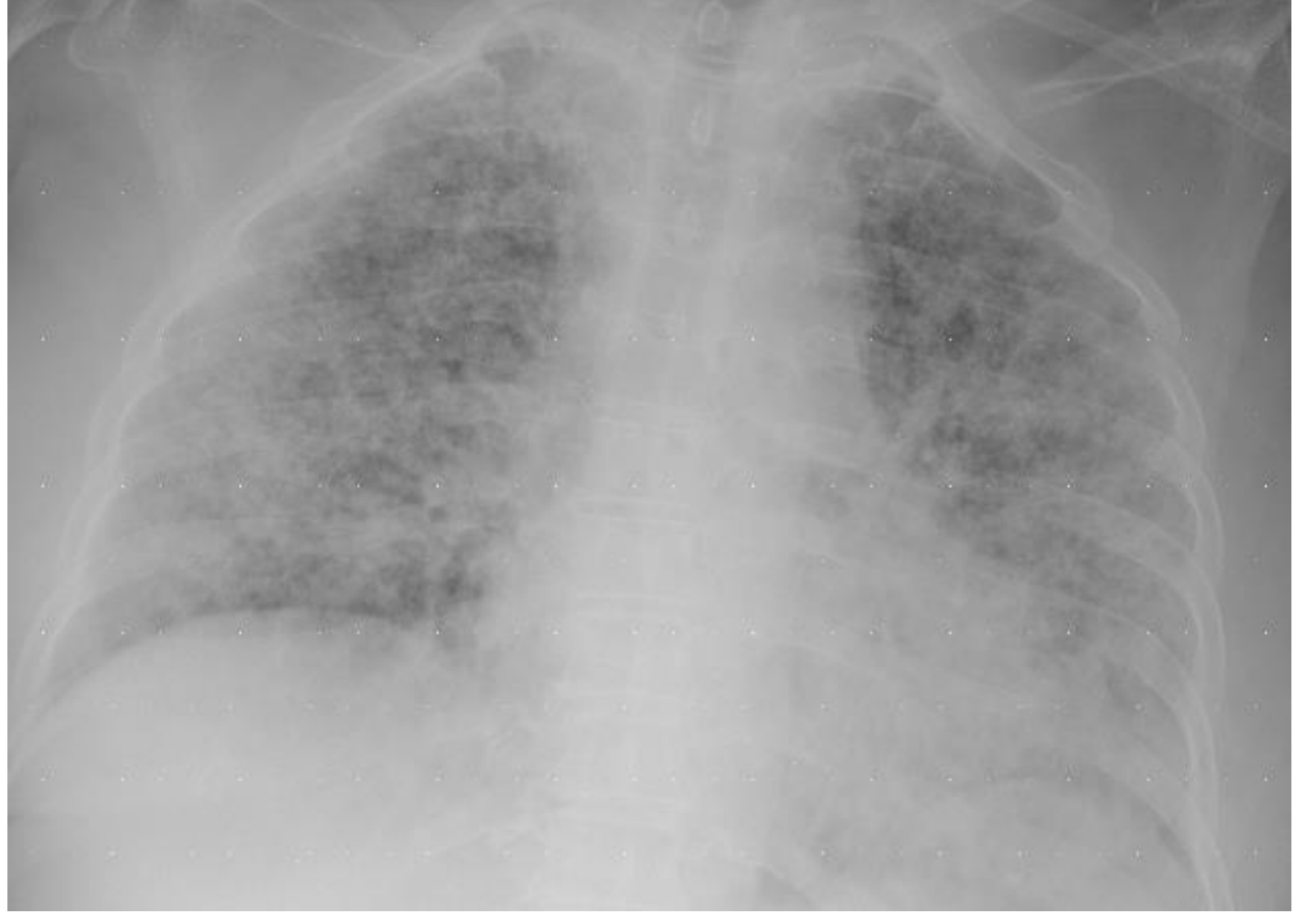Nodüler patern

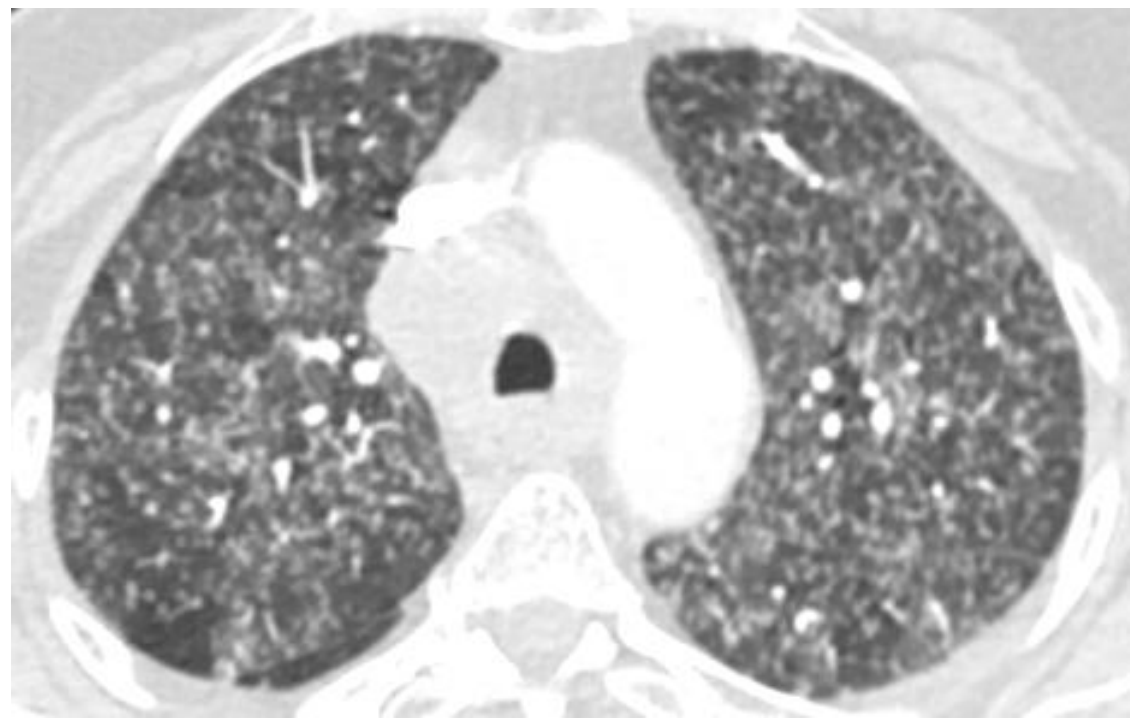
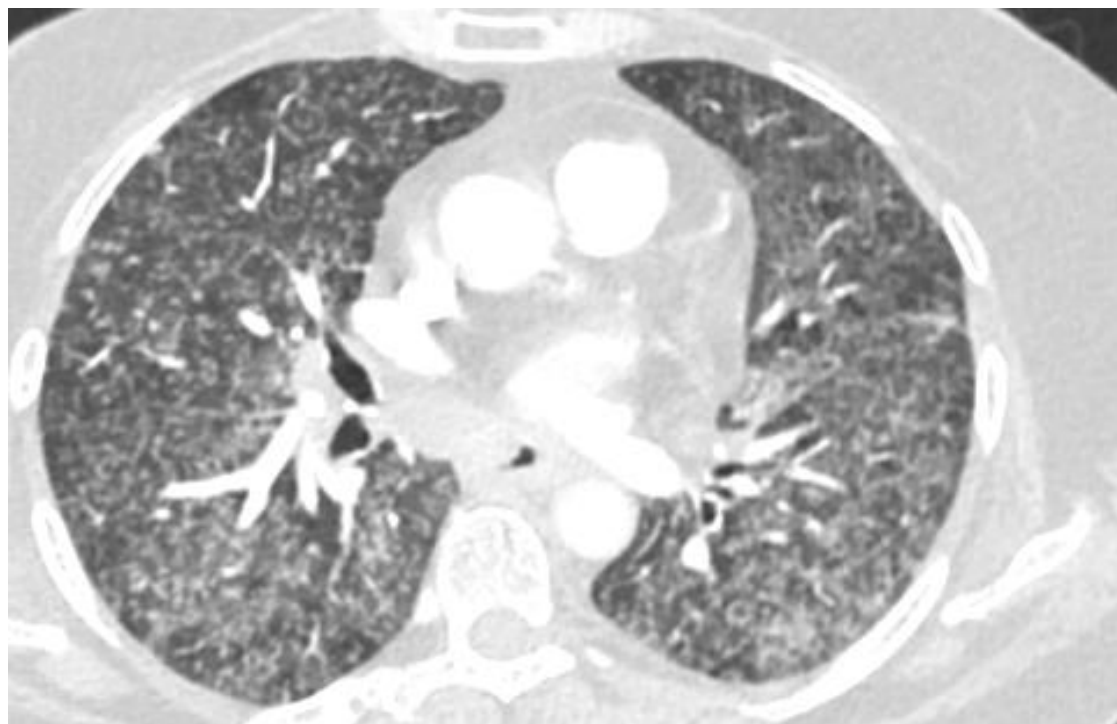
- Perilemfatik
 - Sarkoidozis
 - Lemfanjitik karsinoma
 - Silikozis
 - Kömür işçisi pnömokonyozu
 - Lip
 - Aspestozis
- Sentrilobüler
 - Hipersensivite pnömonisi
 - Respiratuar bronşiyolit
 - İnfeksiyöz hava yolu hastalığı
- Random
 - Hematojen metastaz
 - Miliyer tbc
 - Miliyer mantar hast
 - Sarkoidozis
 - Langerhans hücreli histiyositozis

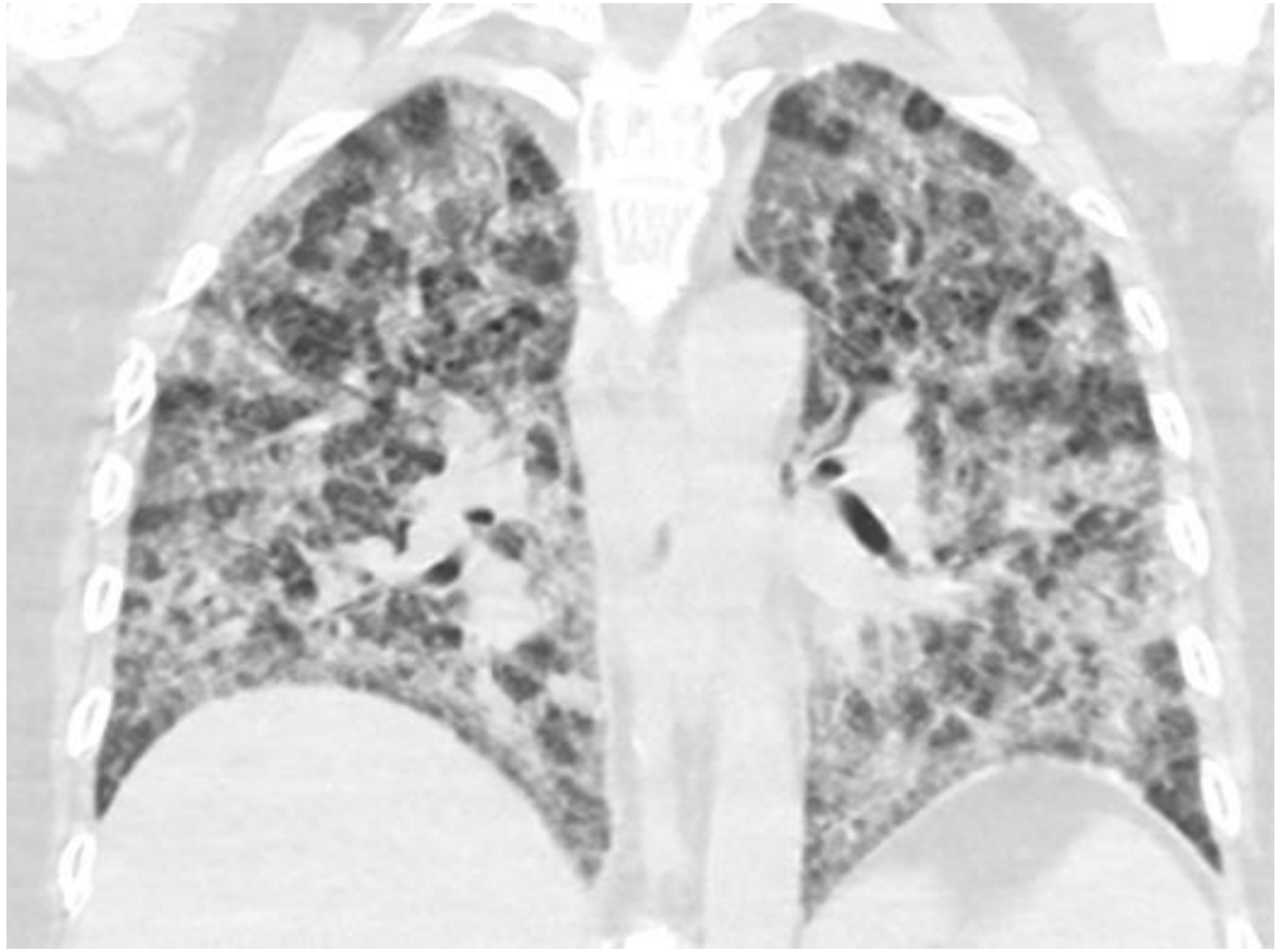


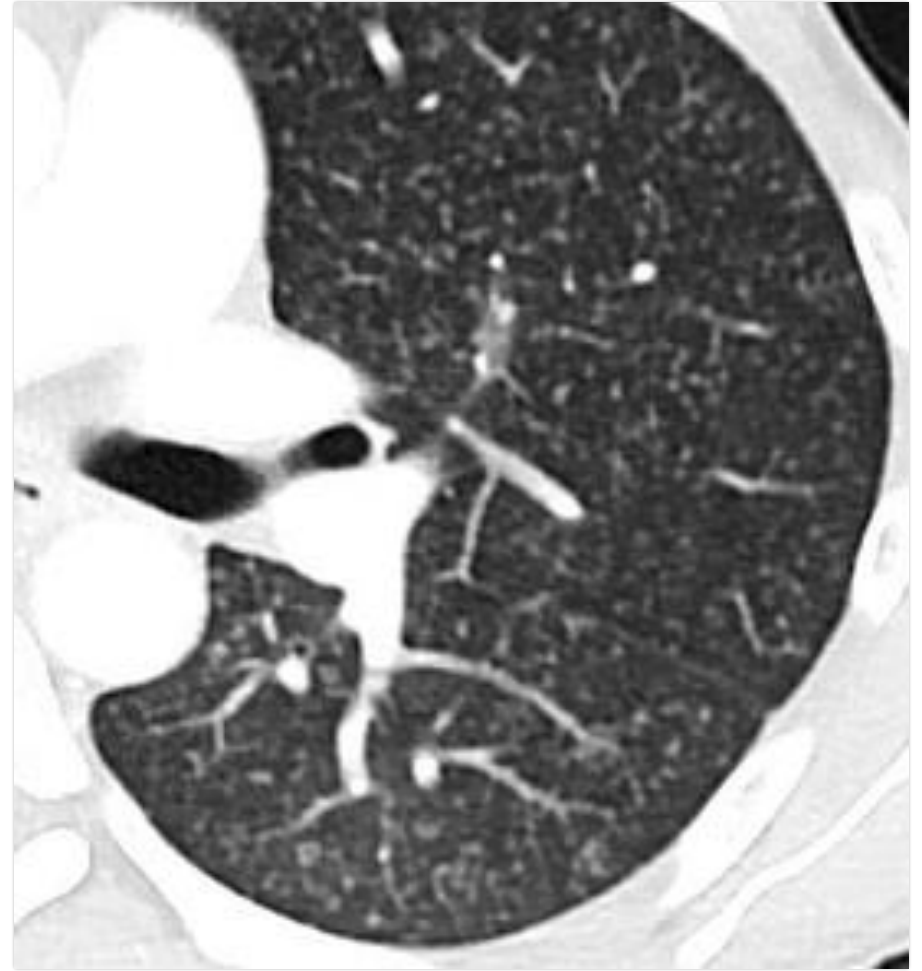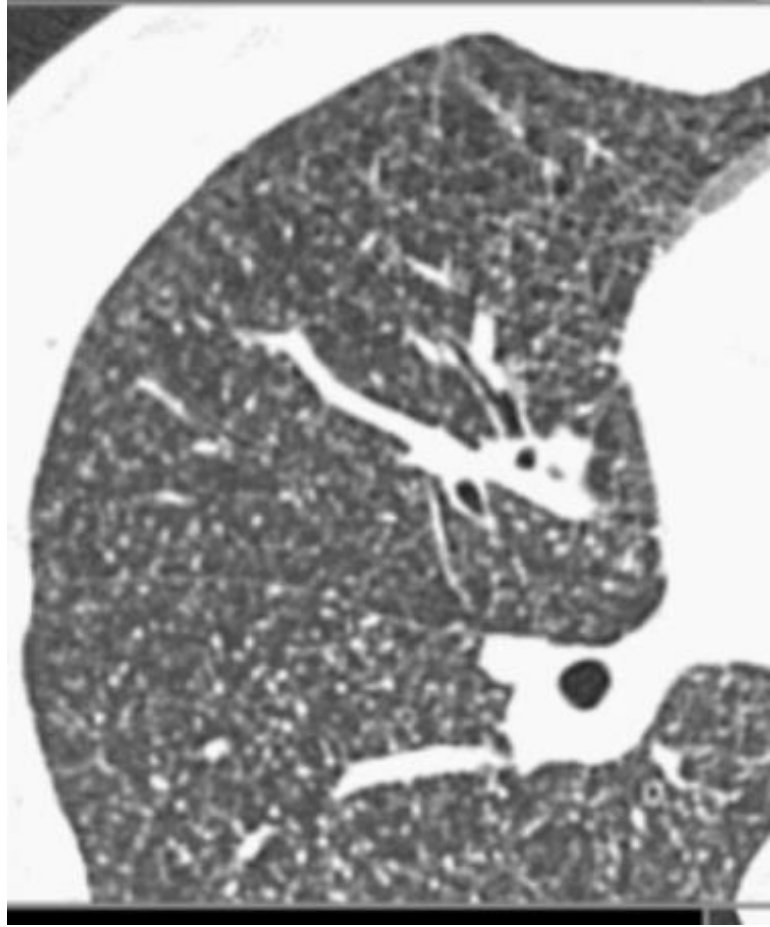
Radiology assistant

67 yaşında erkek
Ateş öksürük kilo kaybı

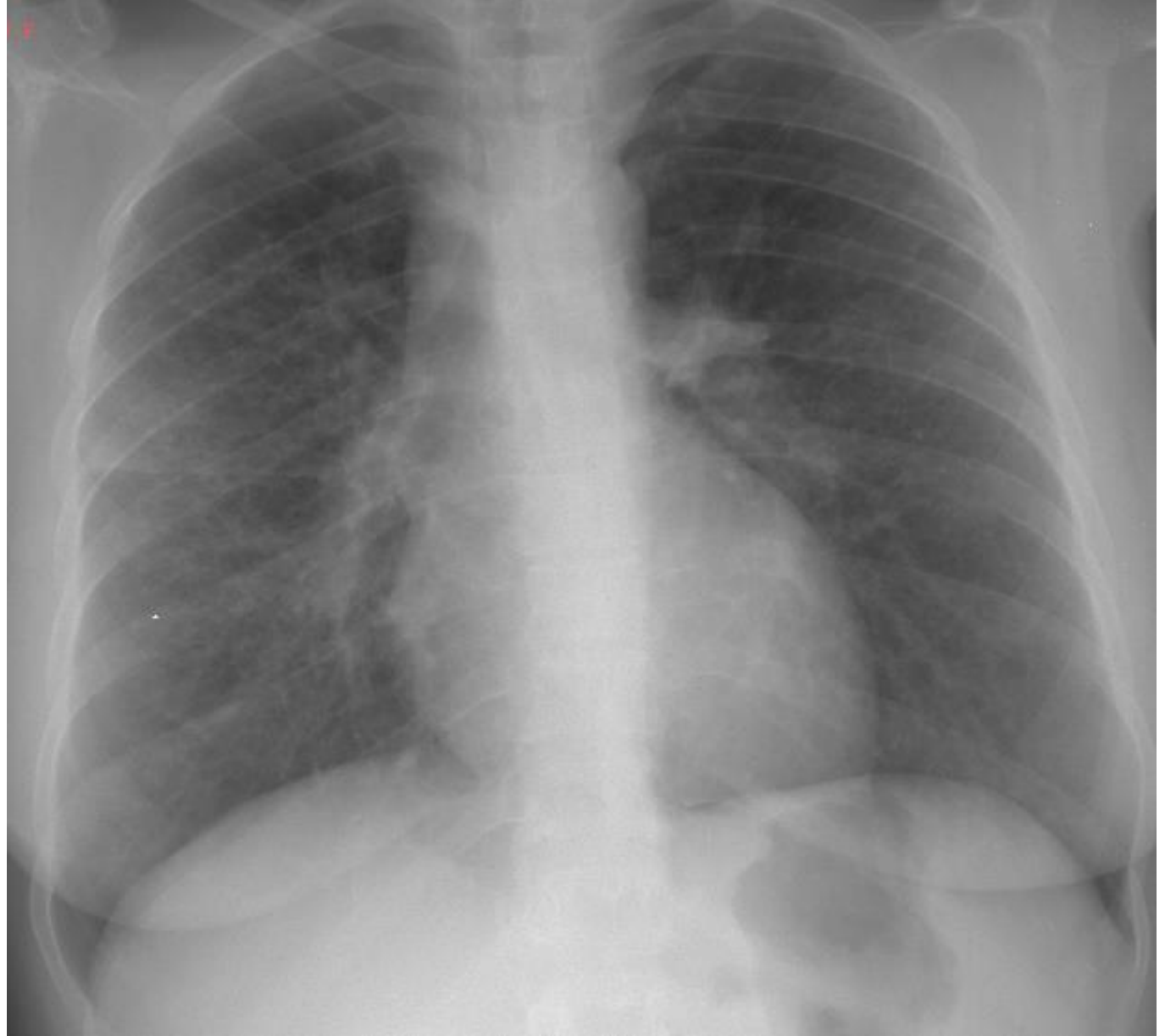

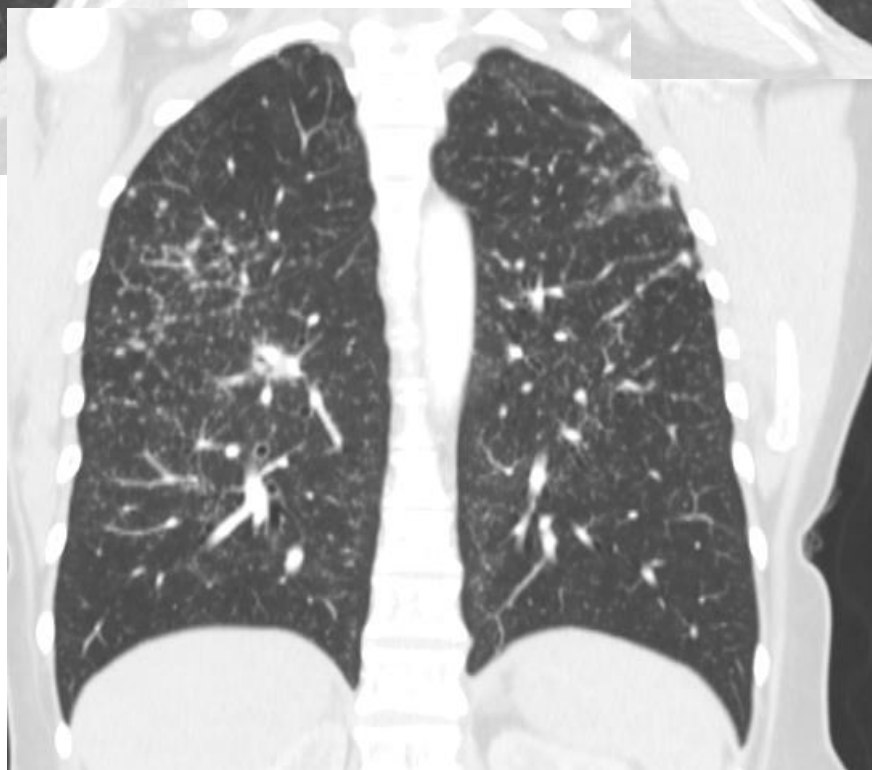
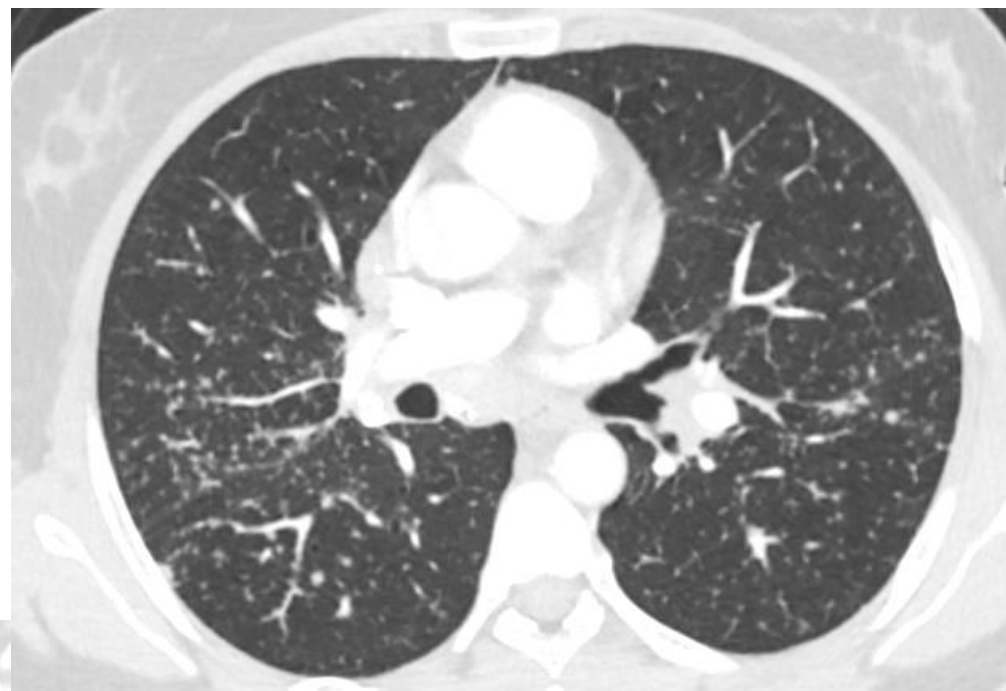

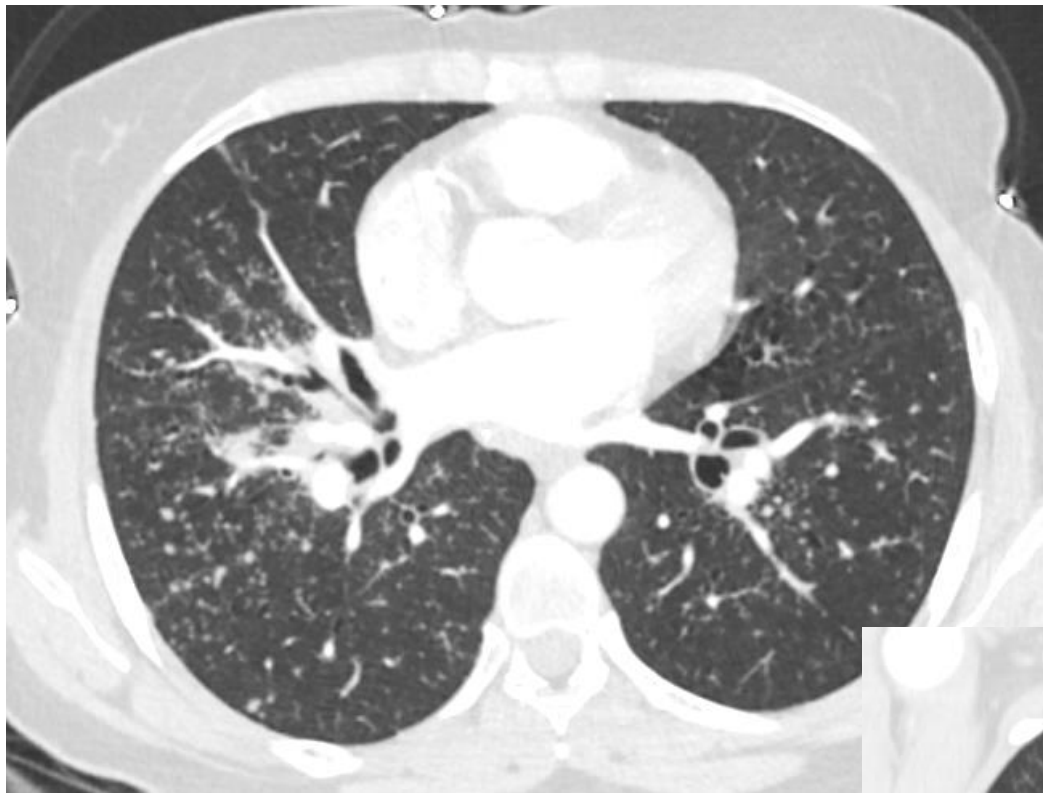
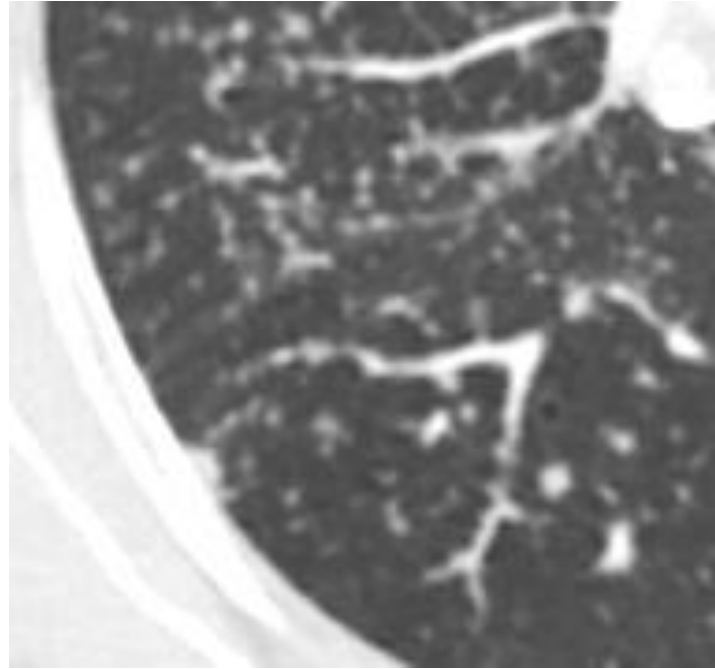
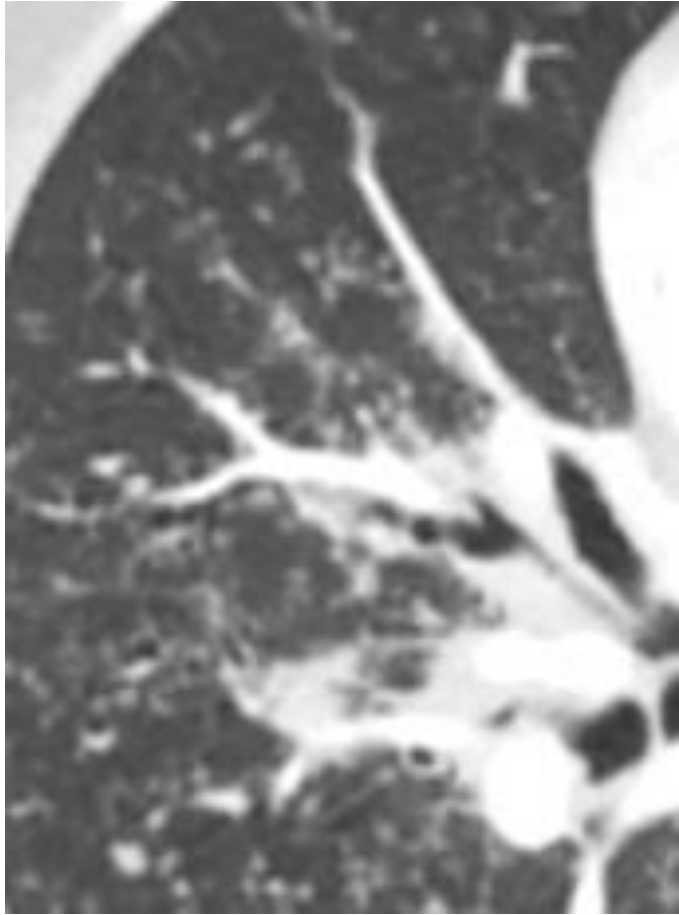


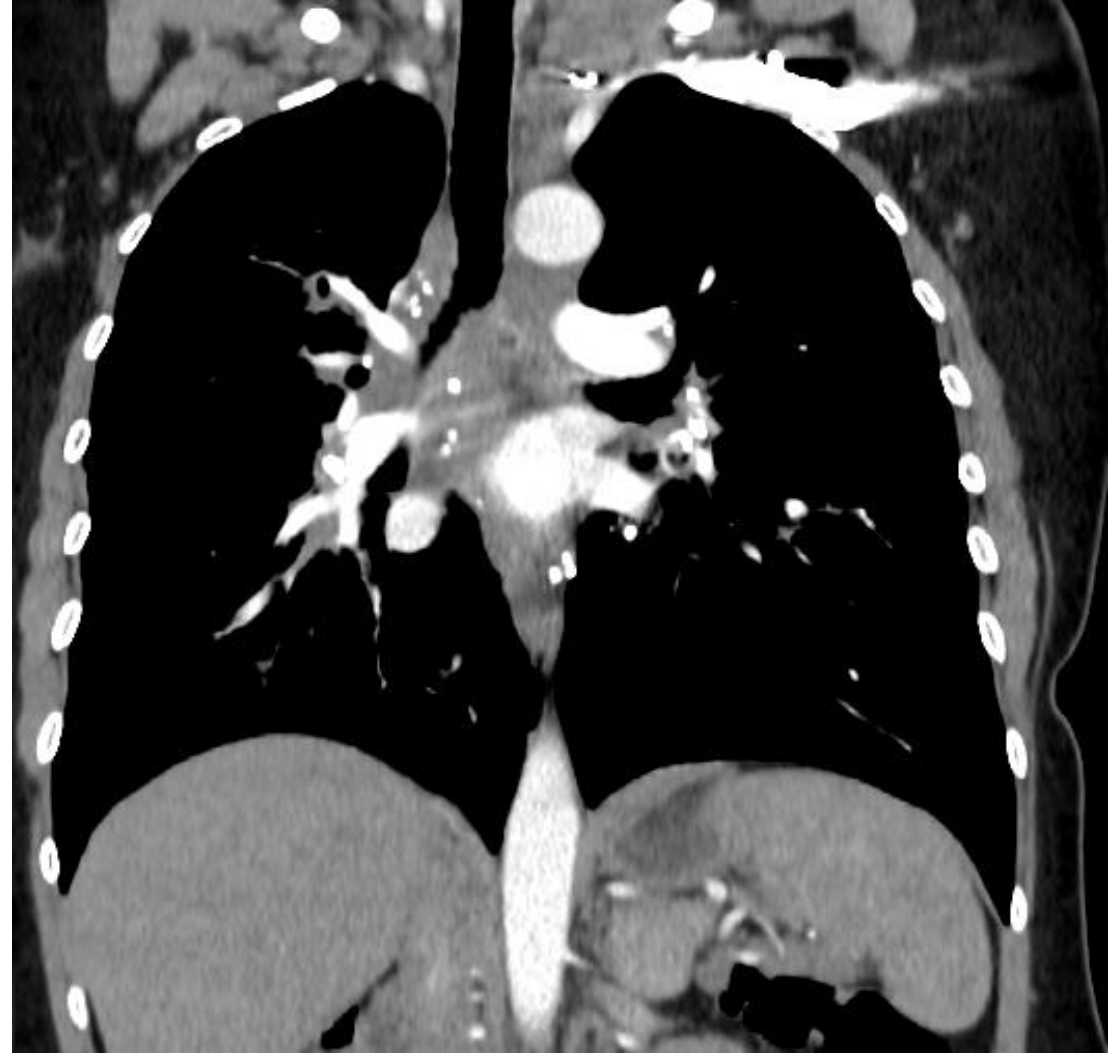


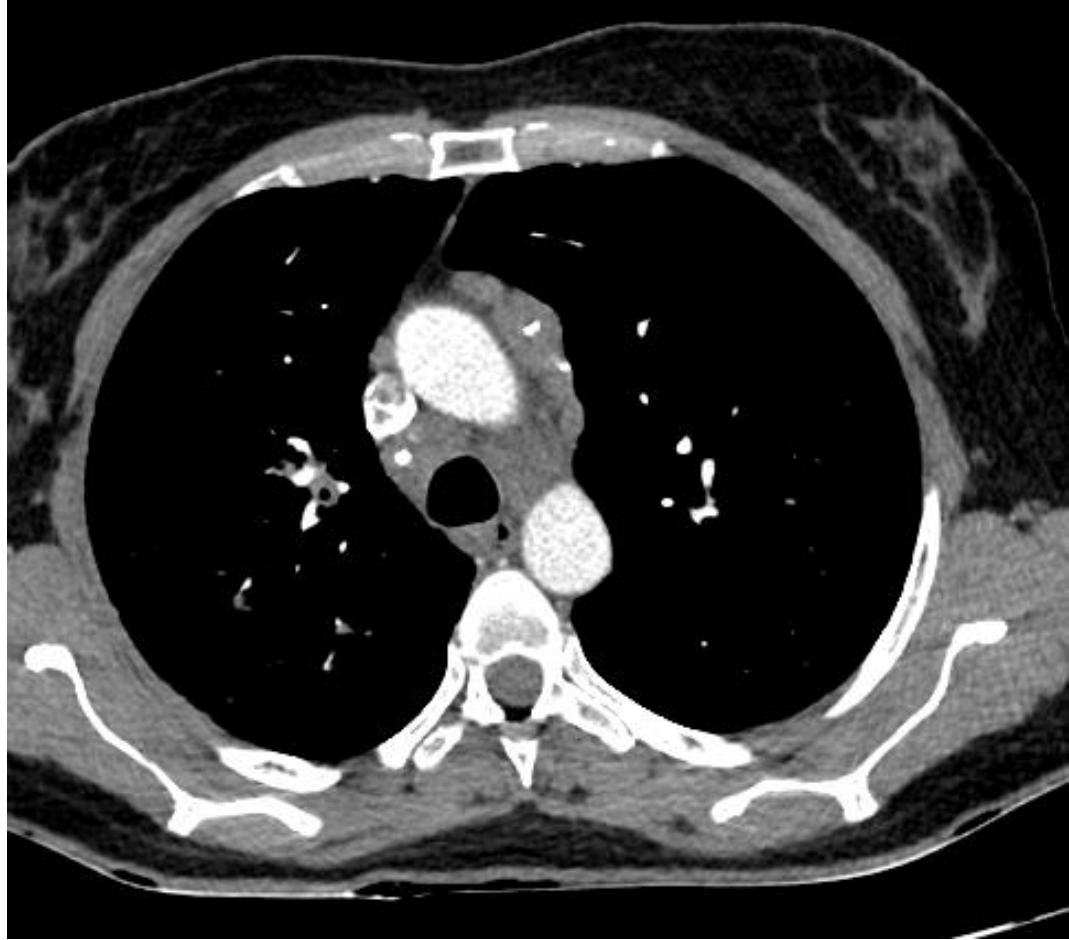48 yaşında kadın hasta
Öksürük , nefes darlığı

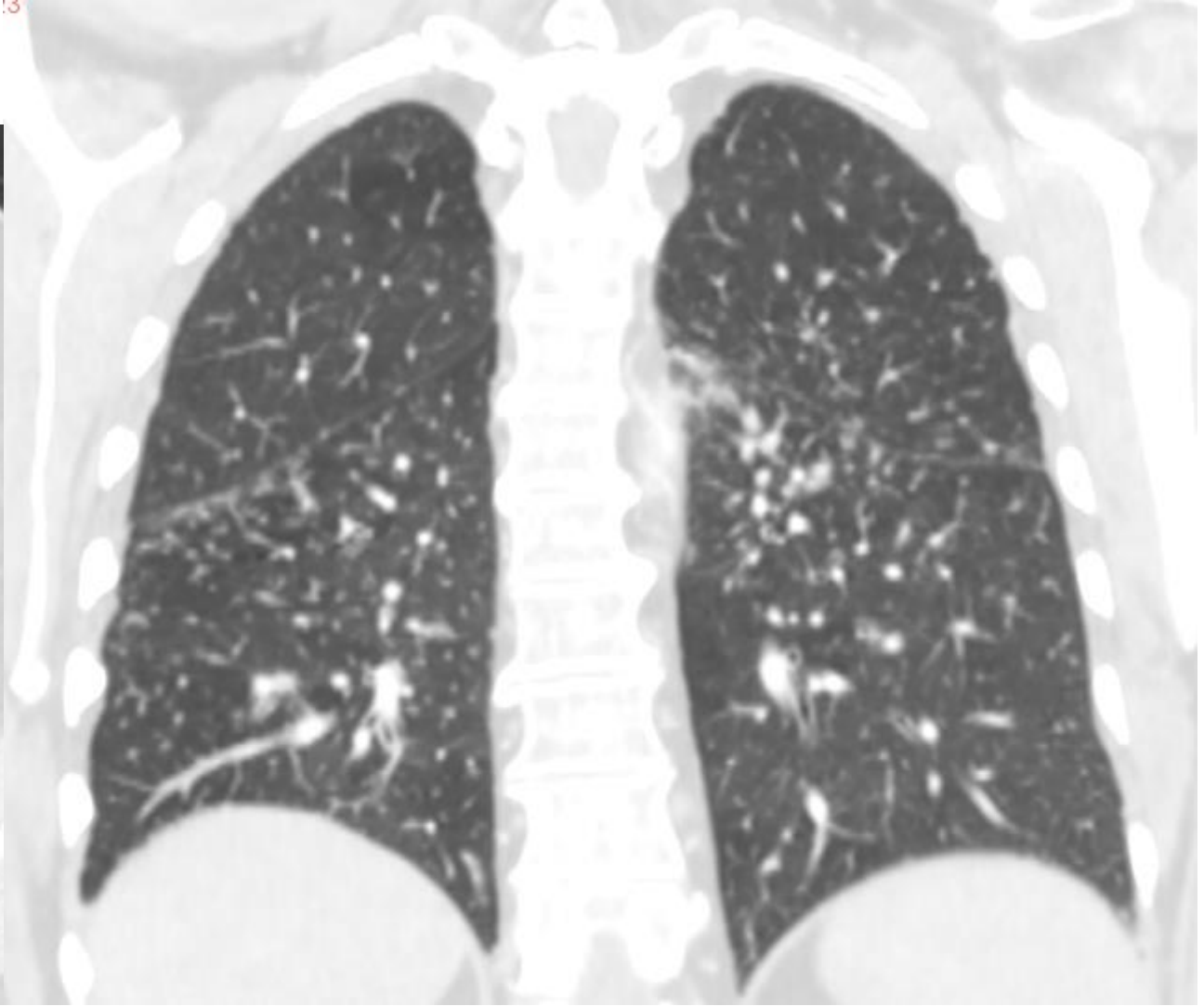
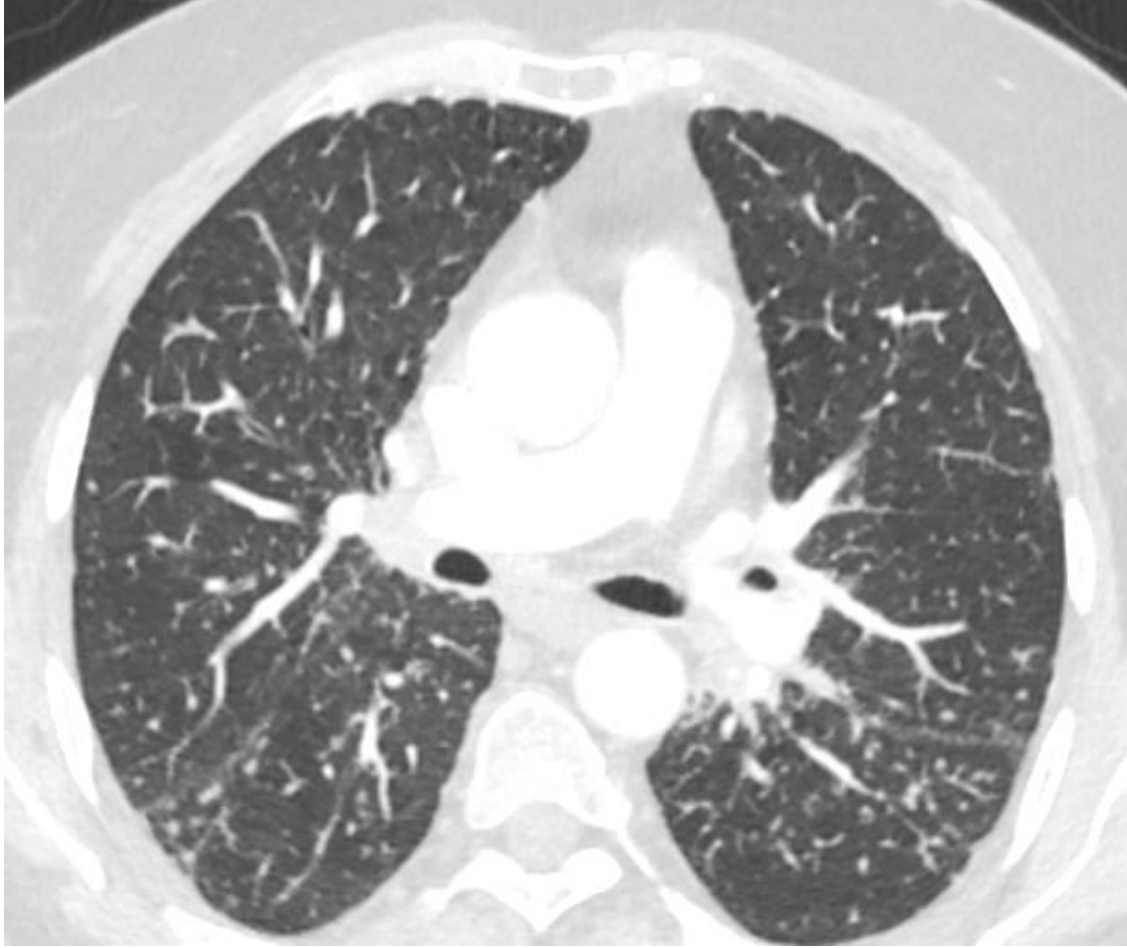







1.5

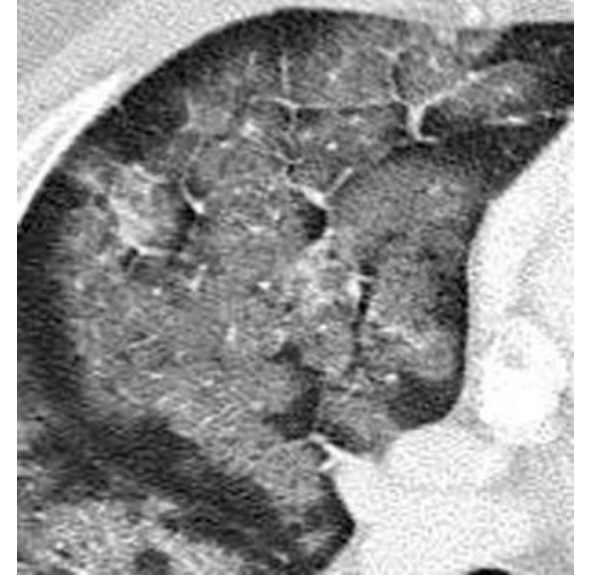
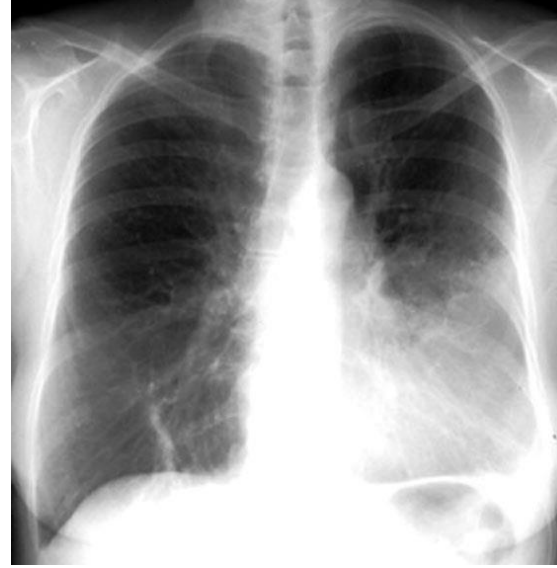

Yüksek atenuasyon paterni

- Buzlu cam dansitesi
- Konsolidasyon

Buzlu cam dansitesi

- Alveollerin tam olmayan dolumu ya da septal kalınlaşma ile oluşur
- Akciğer parankim yapısı izlenir



Buzlu cam dansitesi

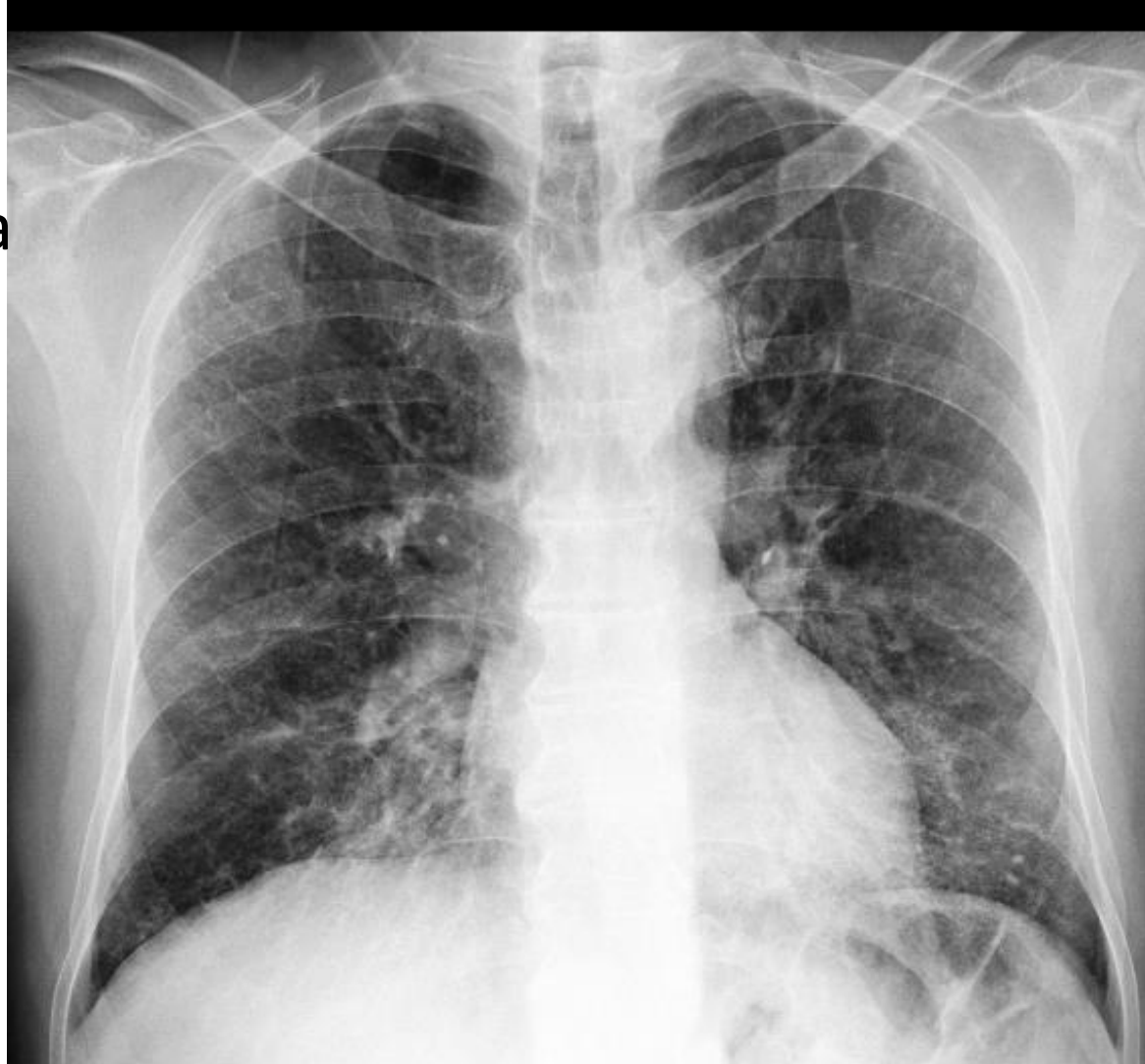Akut

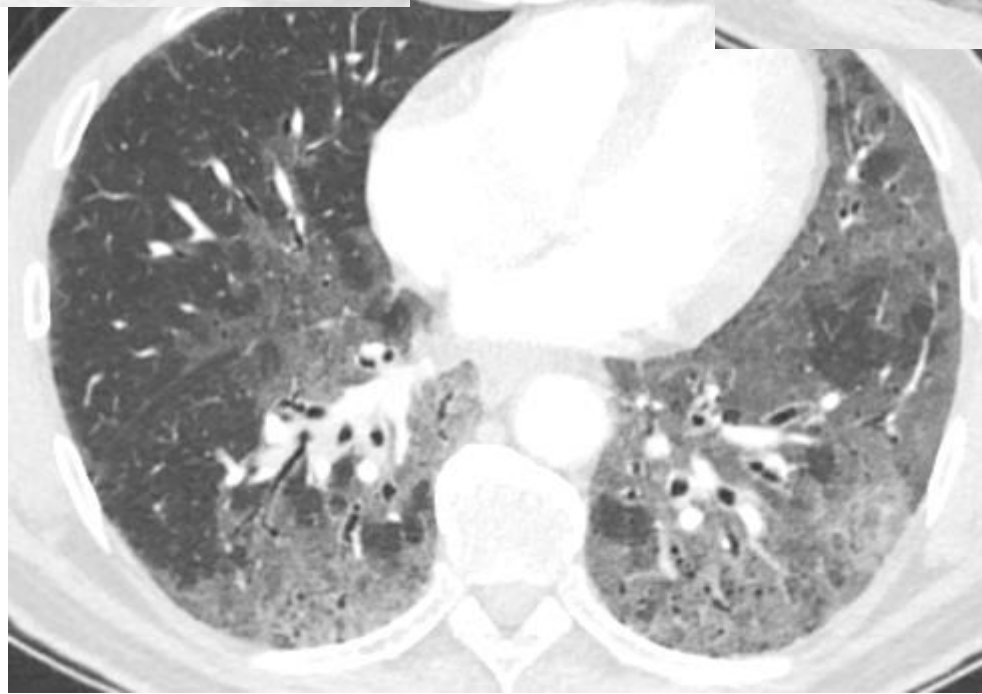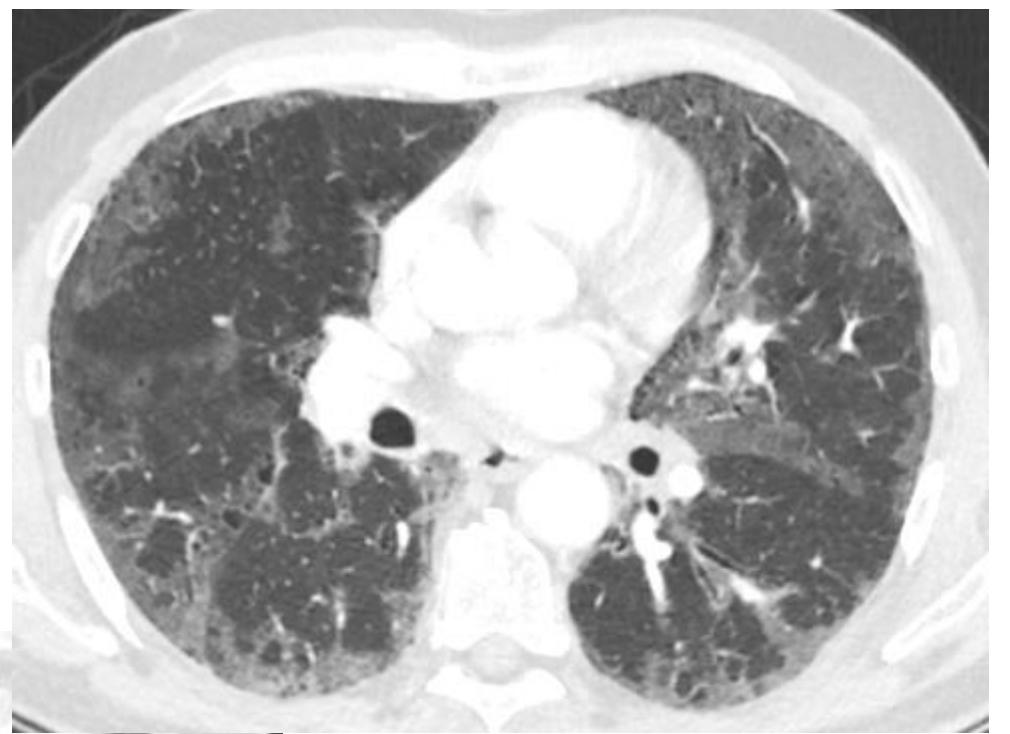
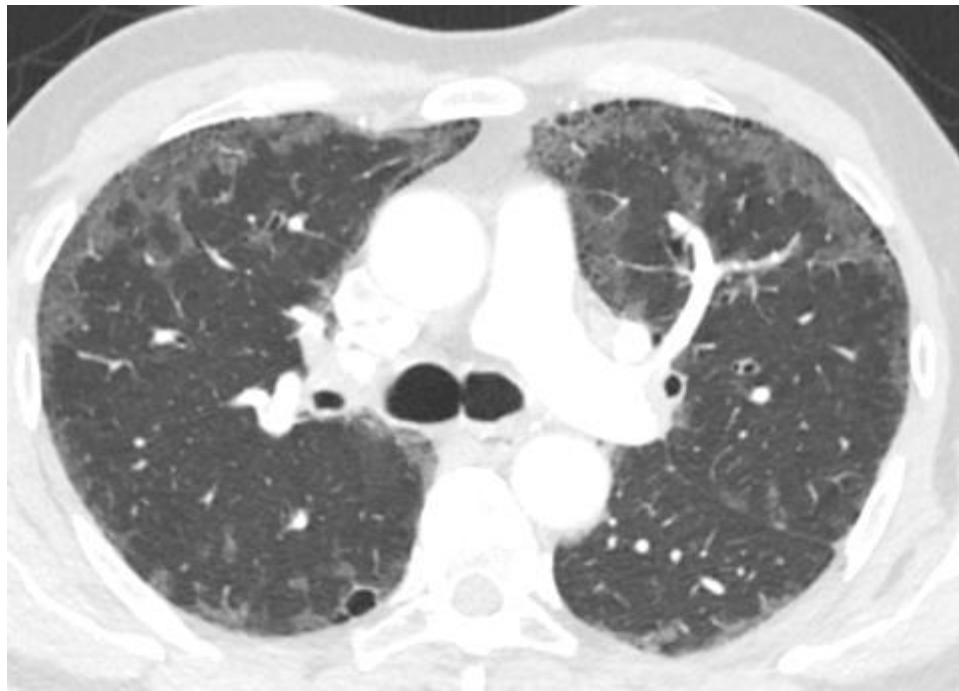
- Akciğer ödemi (Kalp yetmezliği-ARDS)
- Pulmoner hemoraji
- Pnömoni (PCP, mikoplazma, viral)
- Akut eozinofilik pn
- Hipersensitivite pn

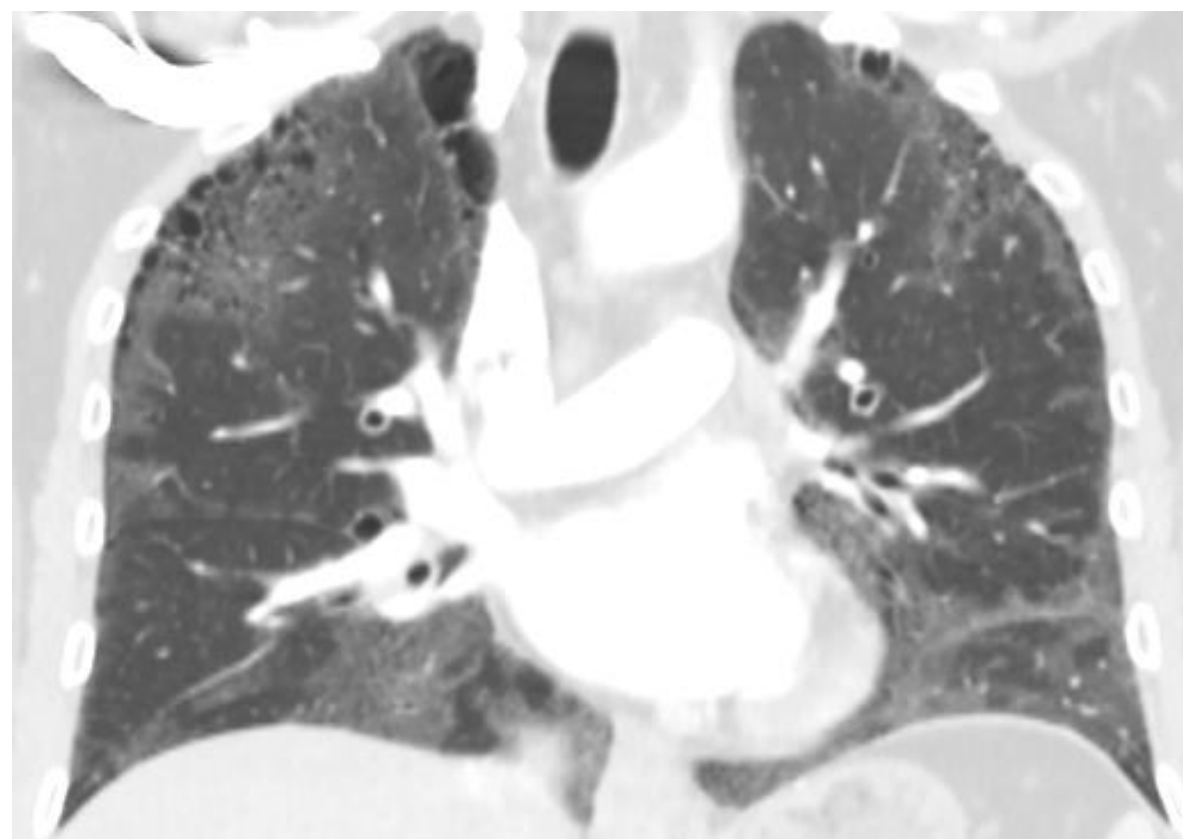
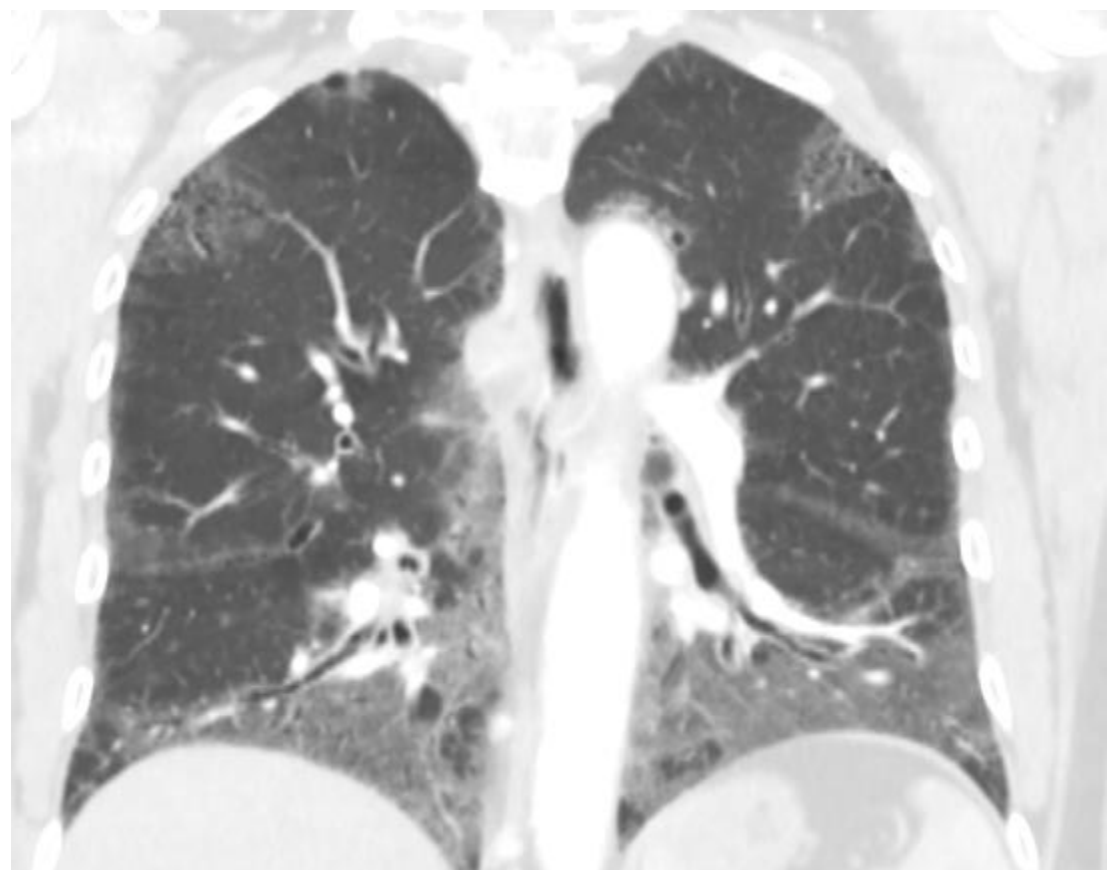
Kronik

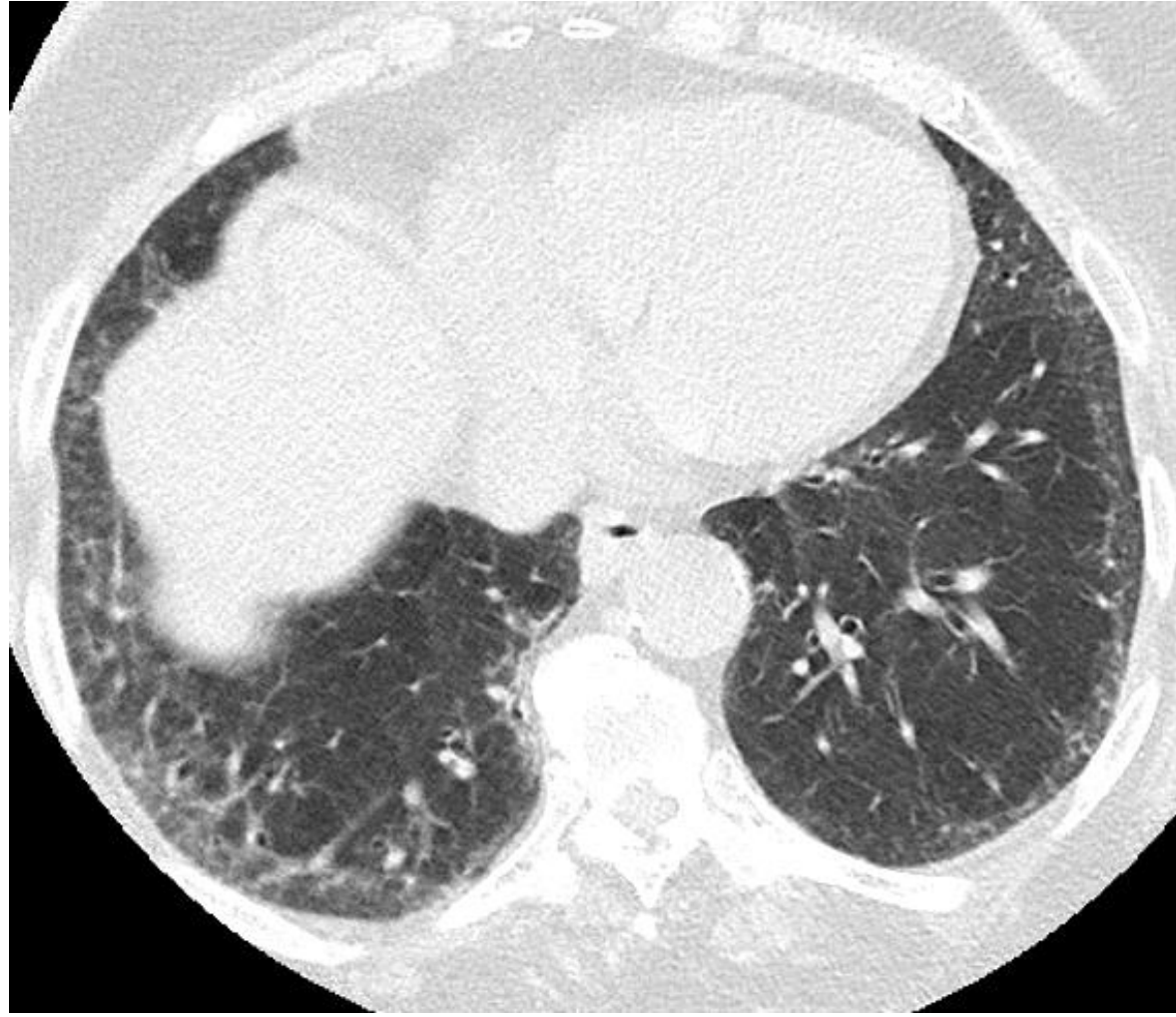
- Hipersensitivite pn
- Organize pn
- Kr eozinofilik pn
- Alveoler proteinozis
- Akciğer fibrozisi (NSIP, UIP)
- Bronkoalveoler karsinoma

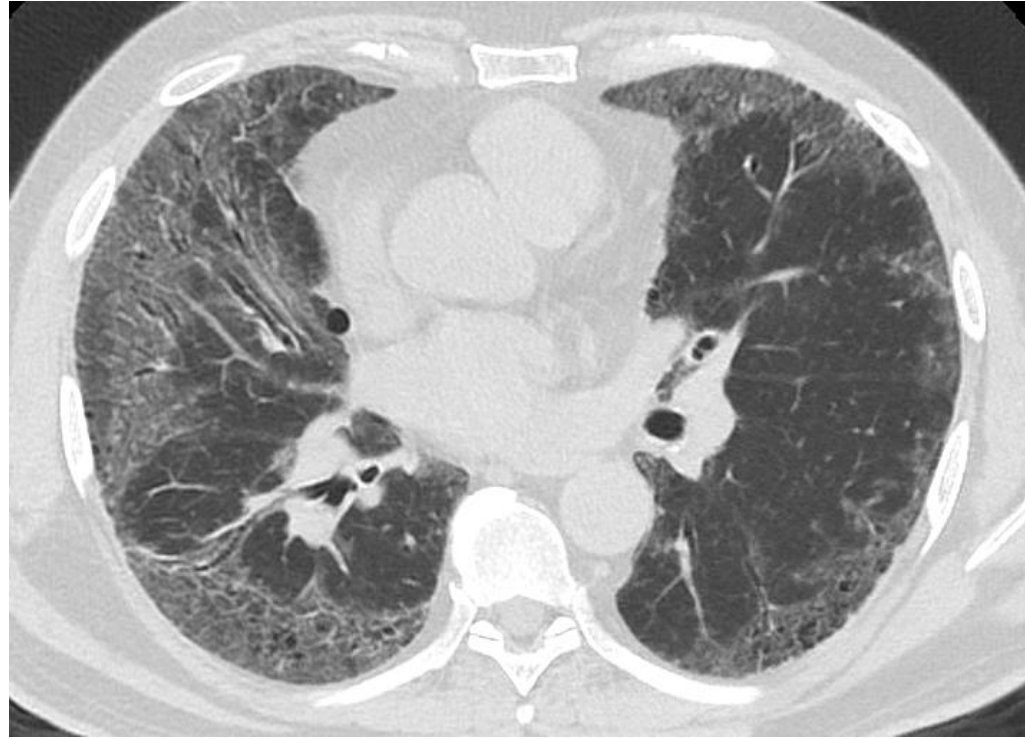
53 yaşında erkek hasta
nefes darlığı NSIP

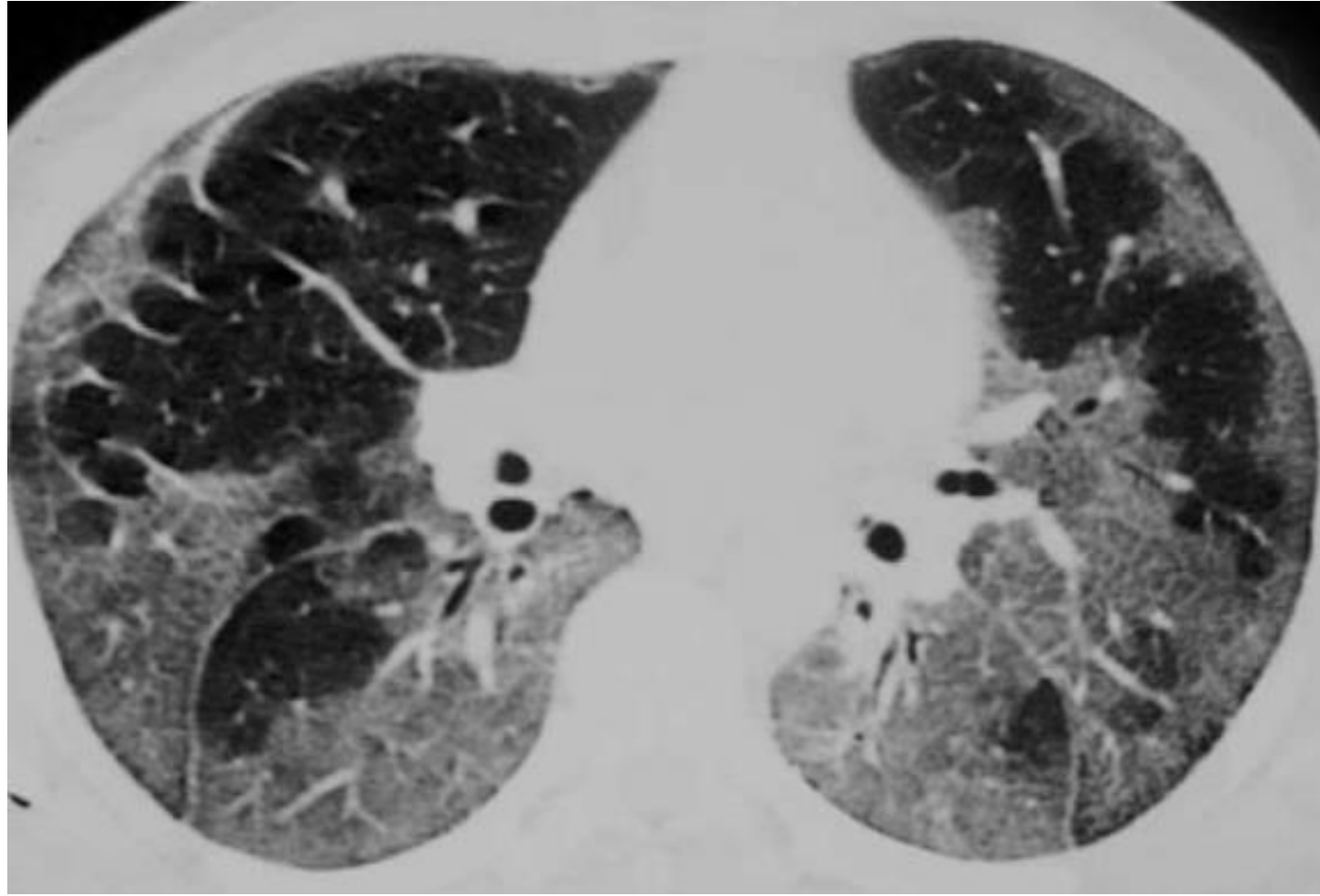


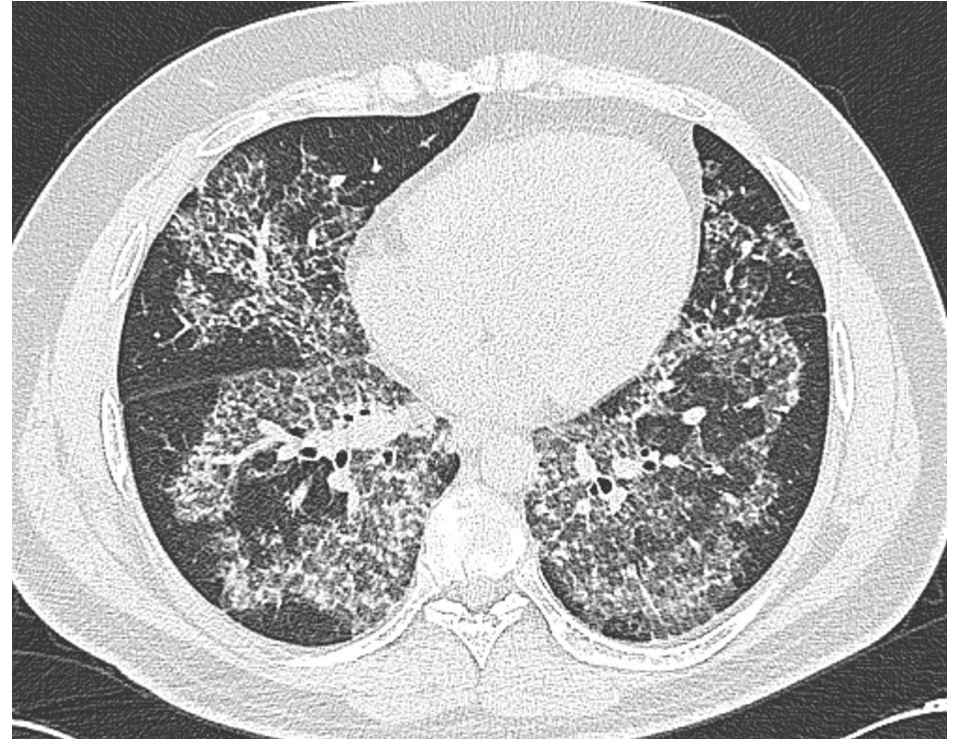
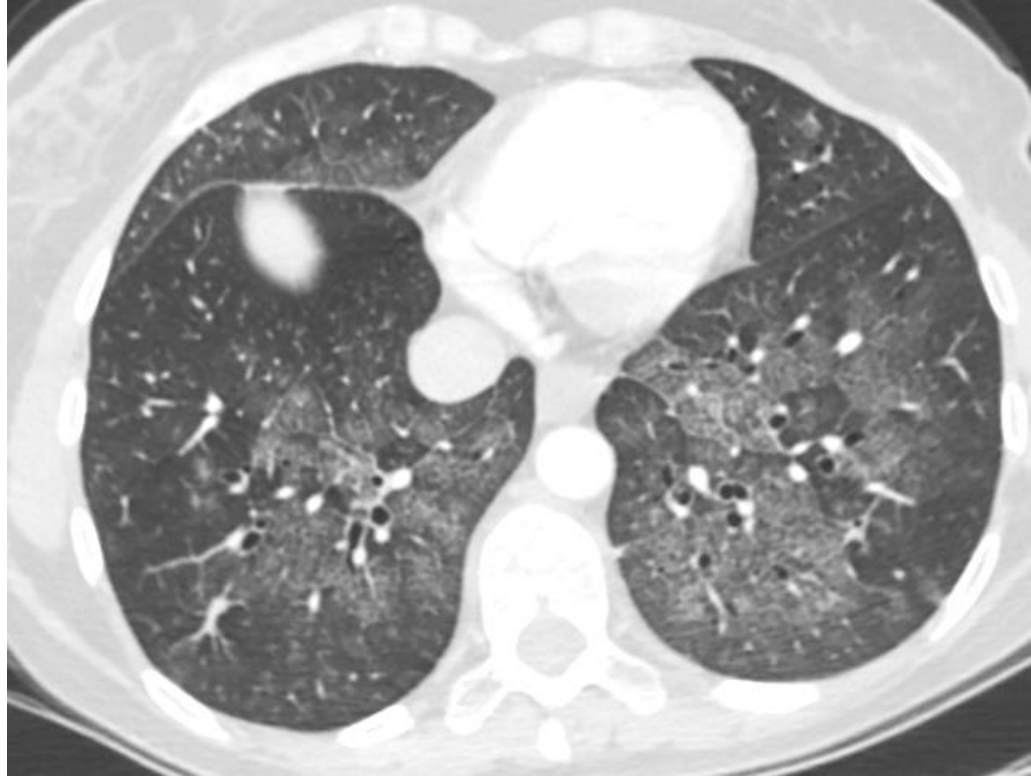








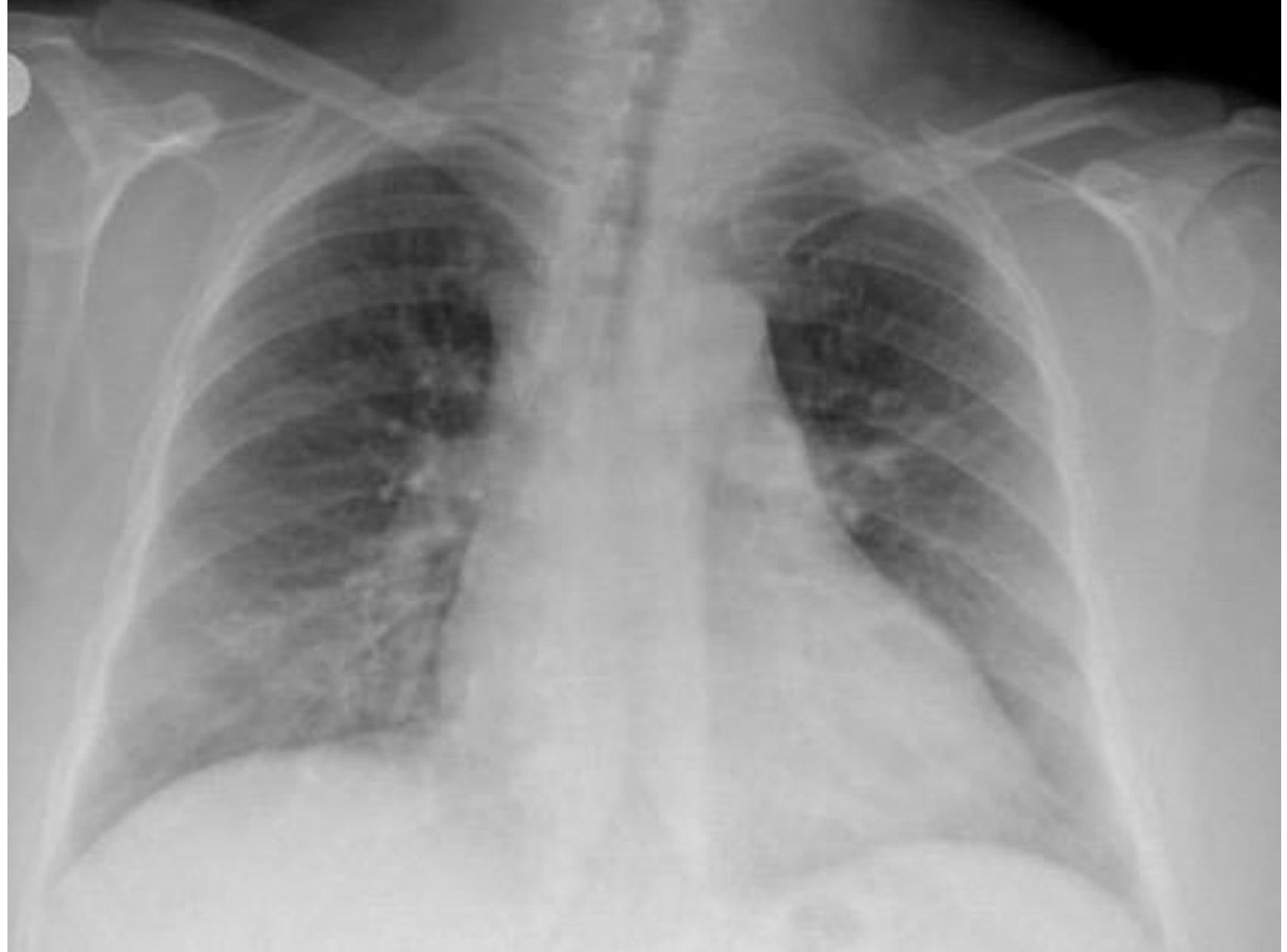


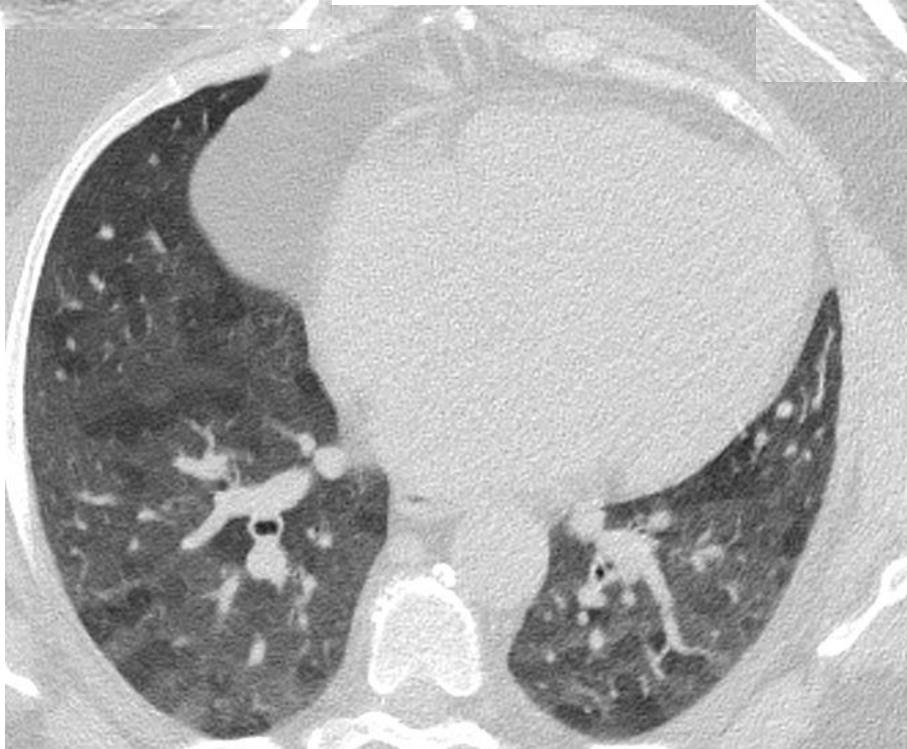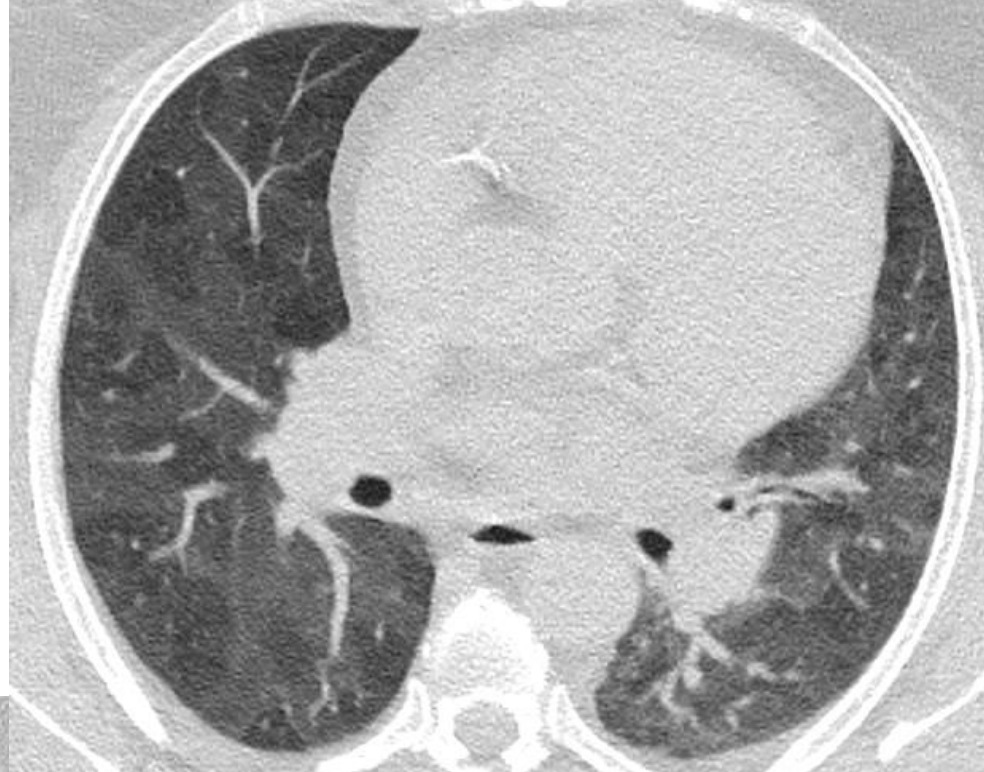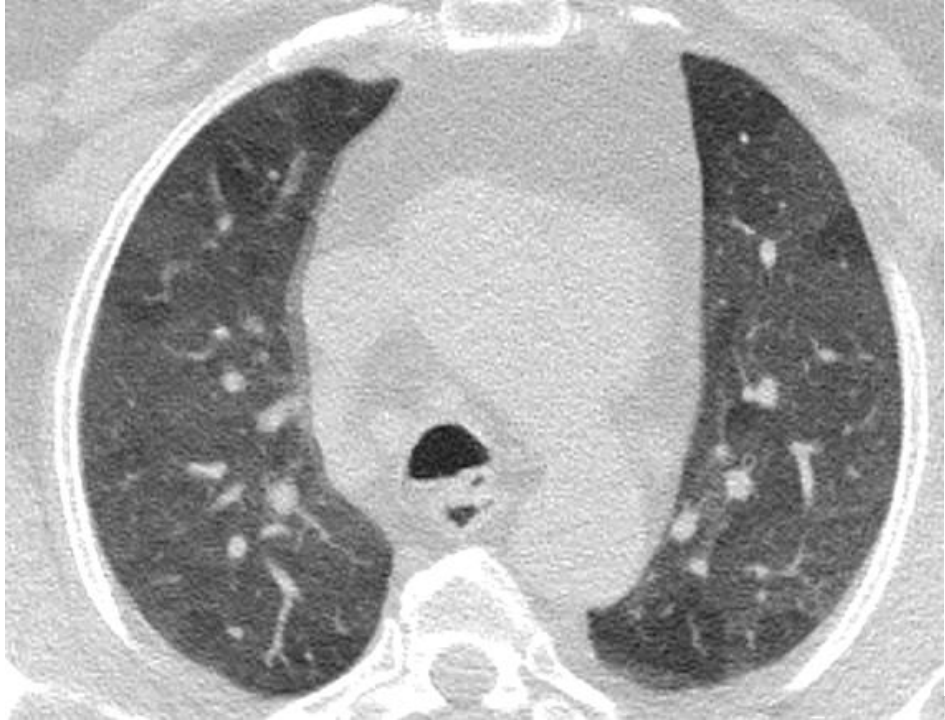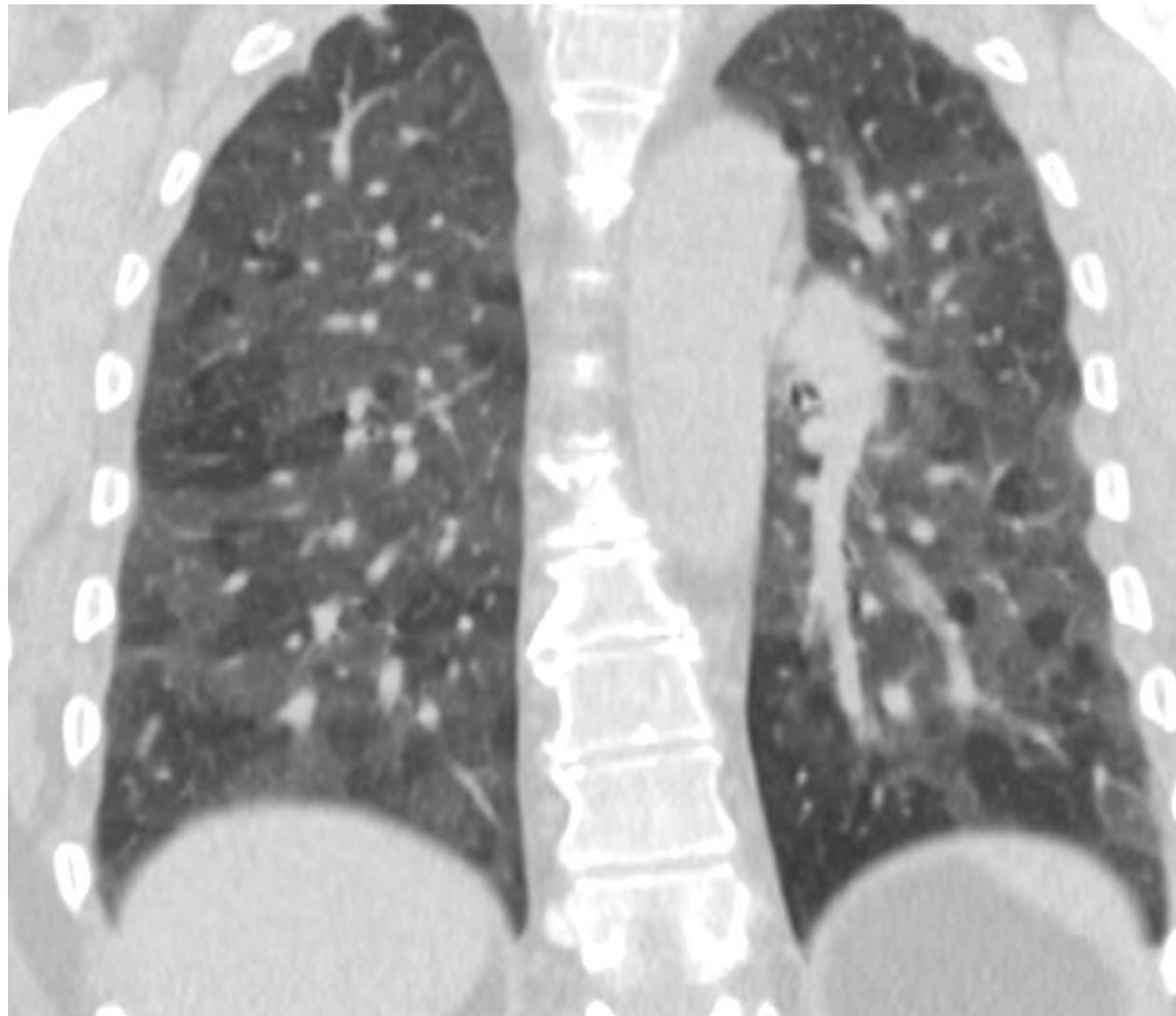
Mozaik atenüasyon

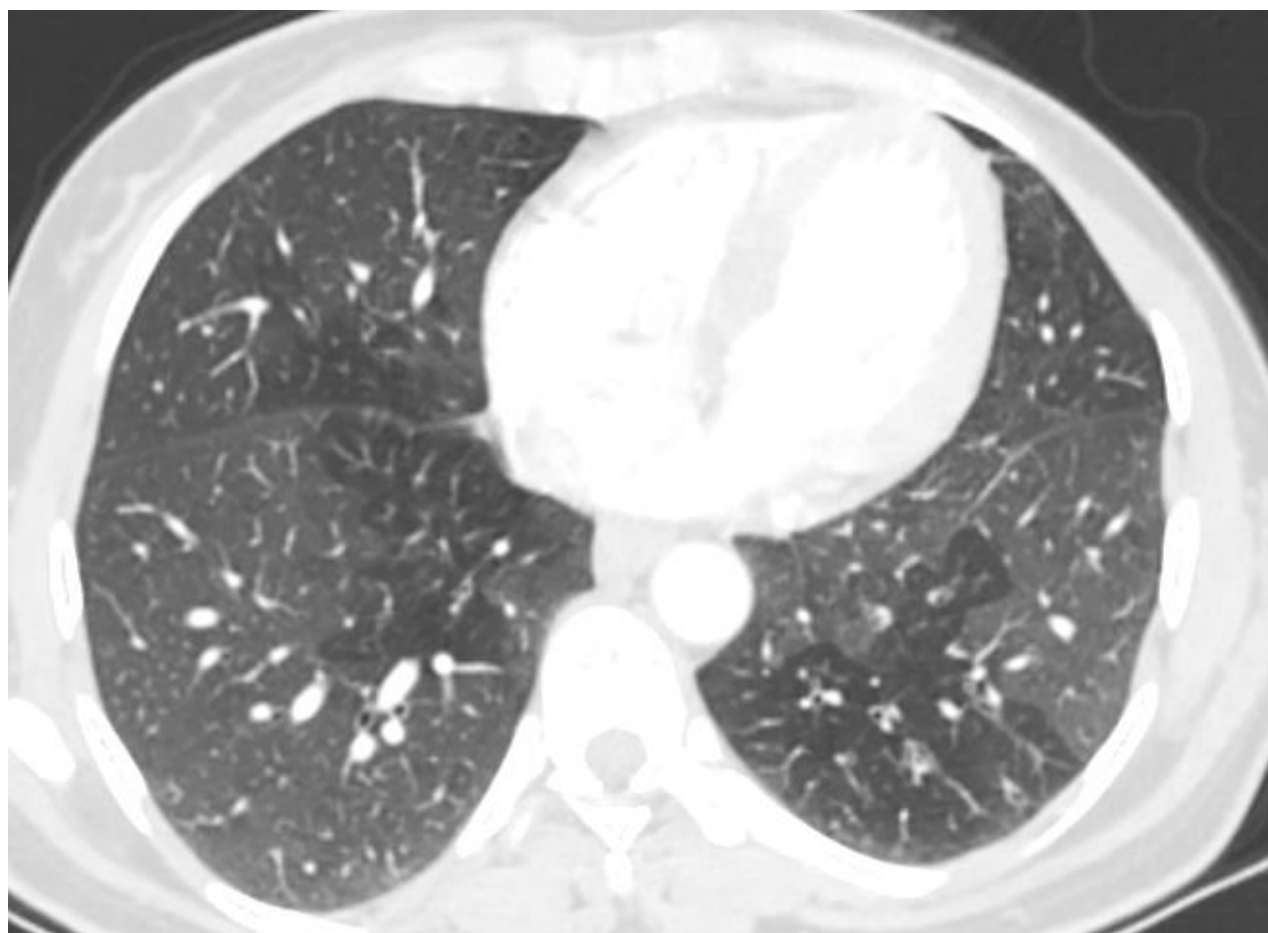
- Astım
- Bronşiolitis obliterans
- Hipersensitivite pn
- Pulmoner embolizm

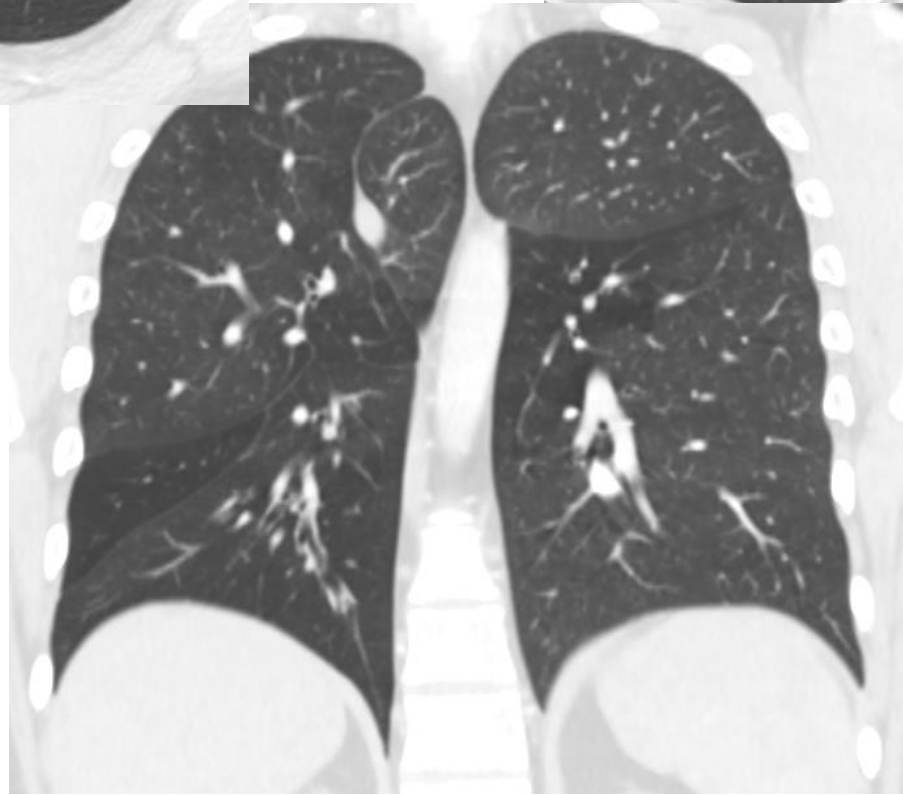
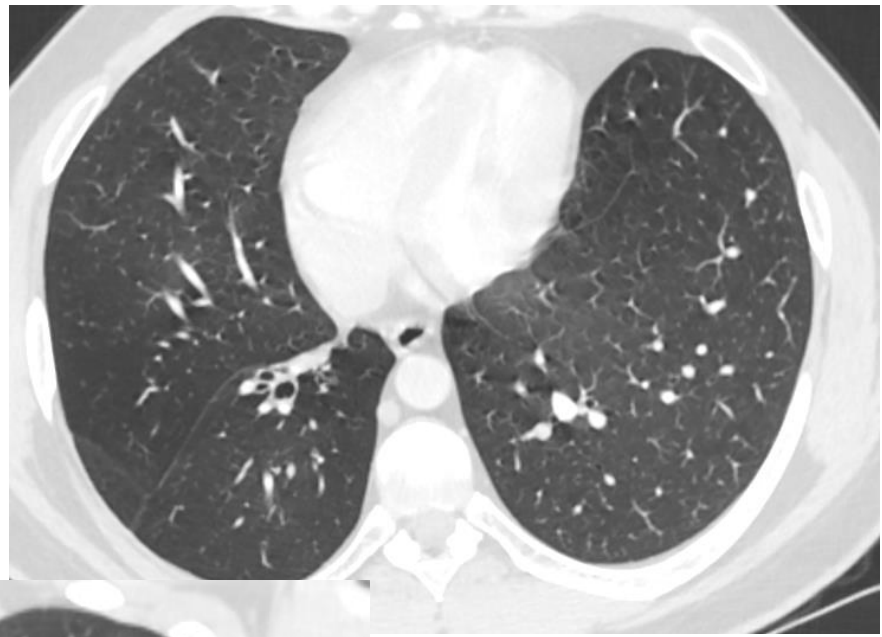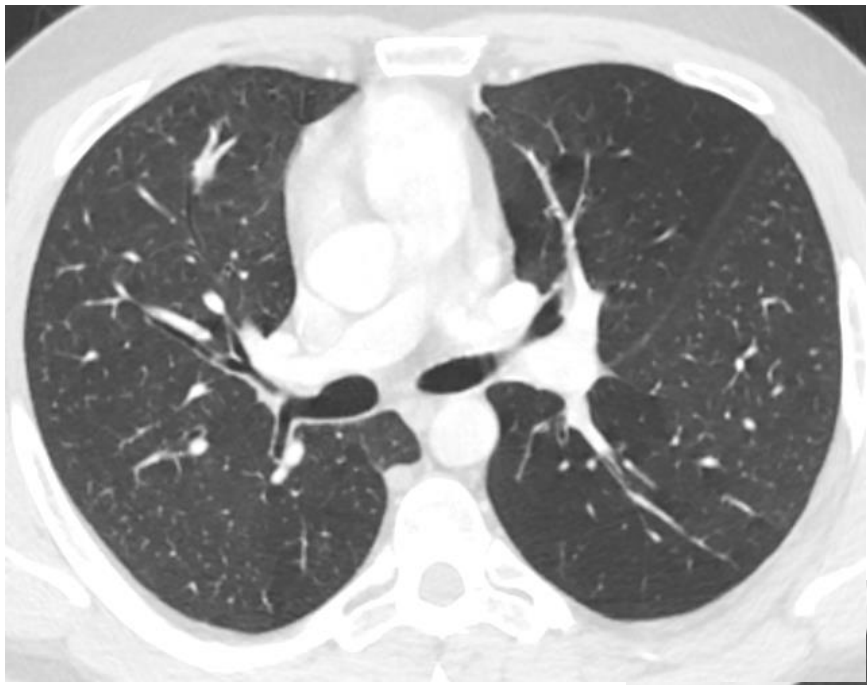51 y kadın hasta
Nefes darlığı
Astım

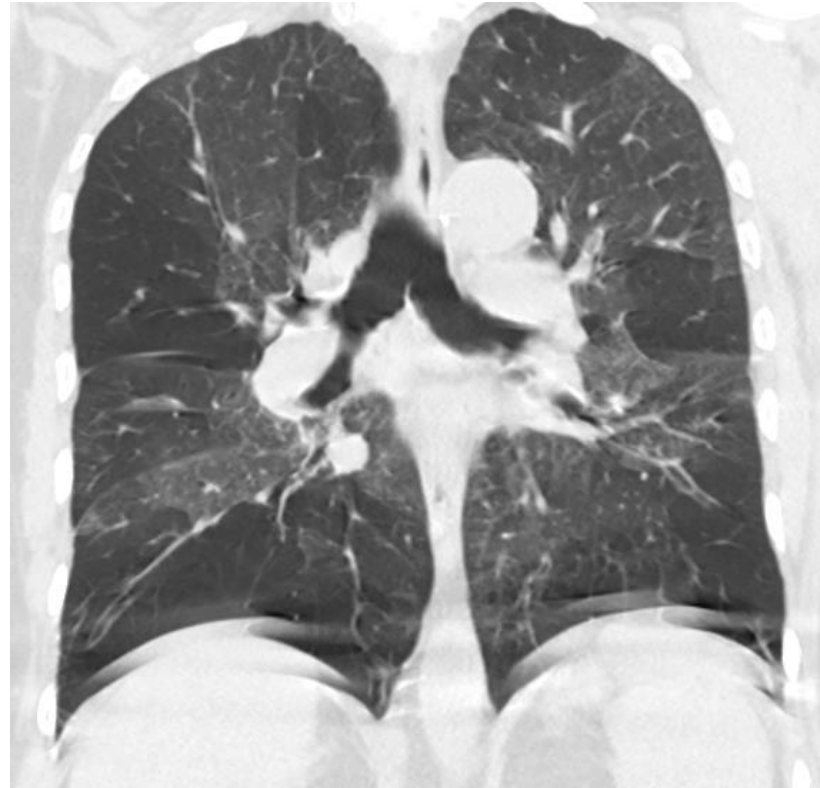
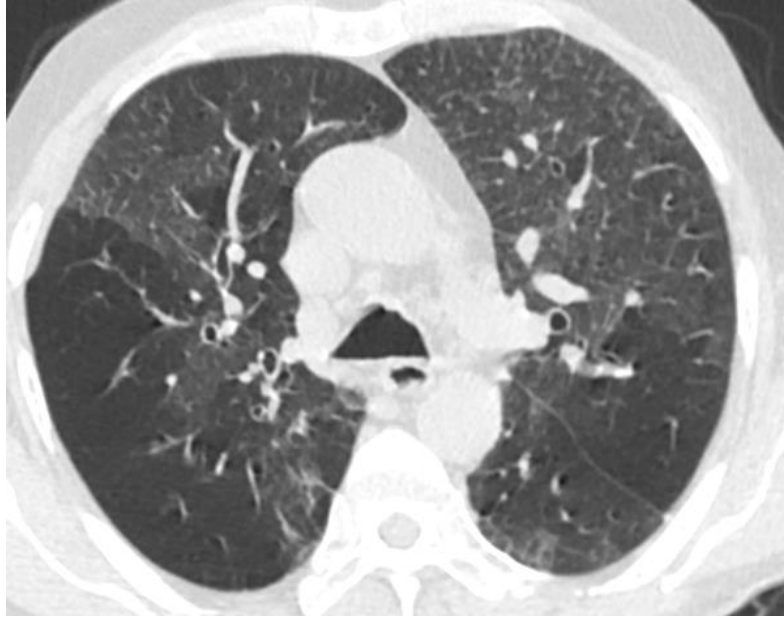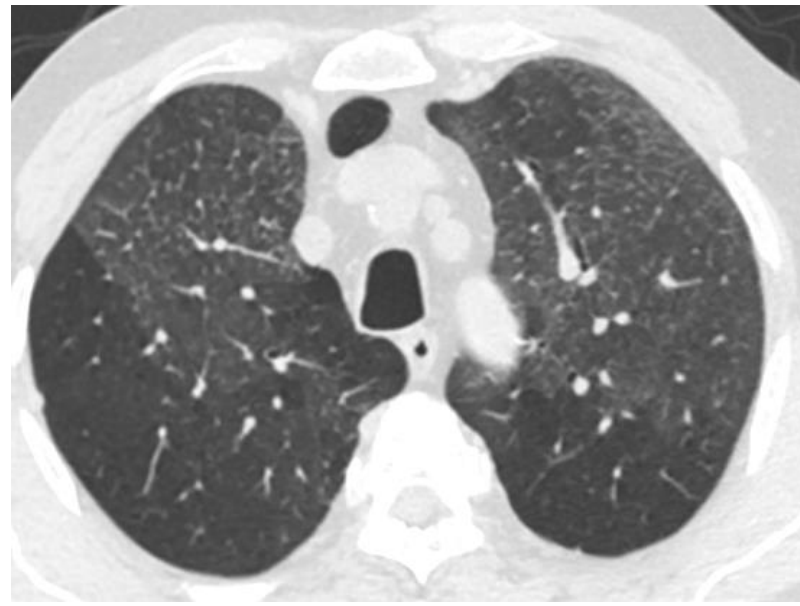
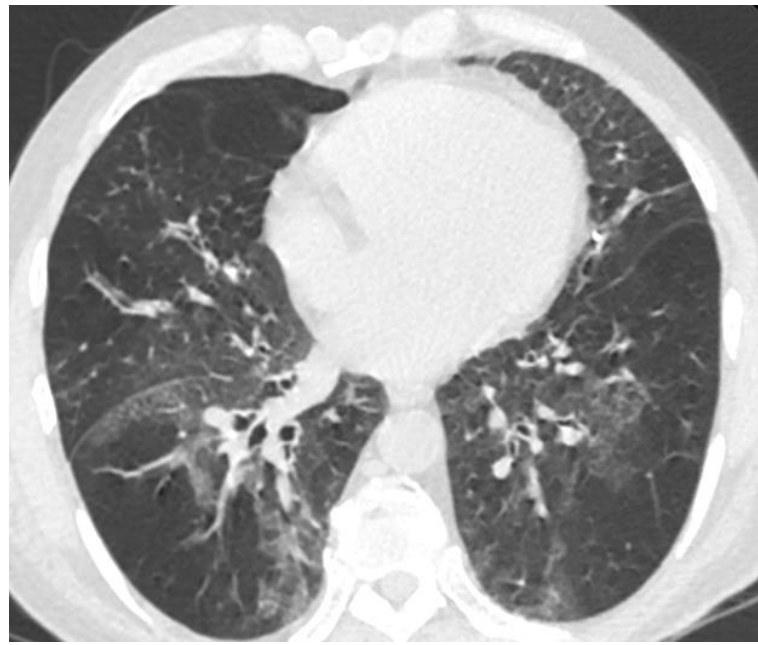


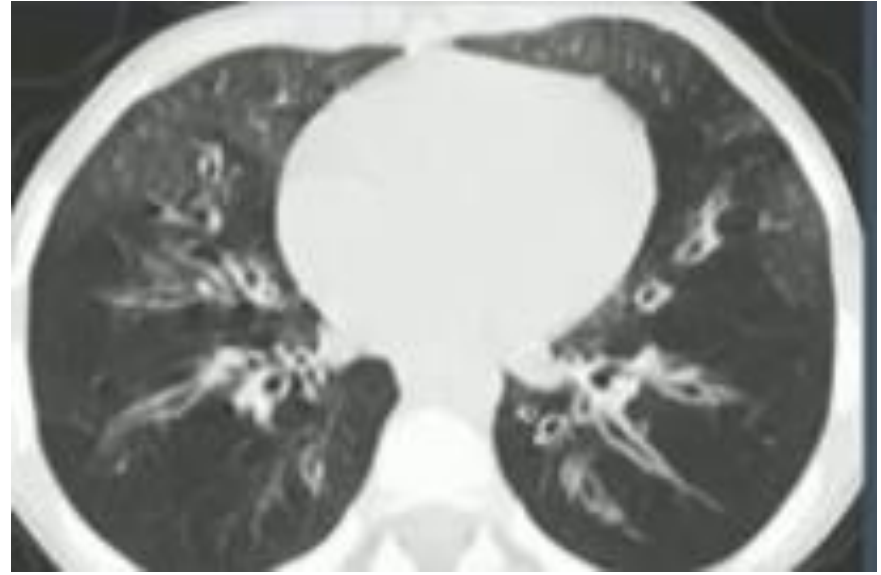
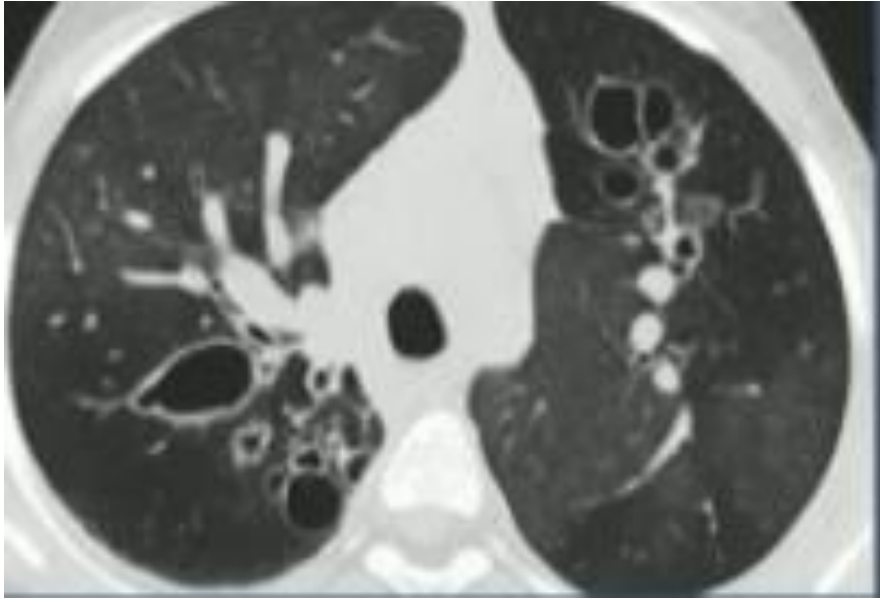






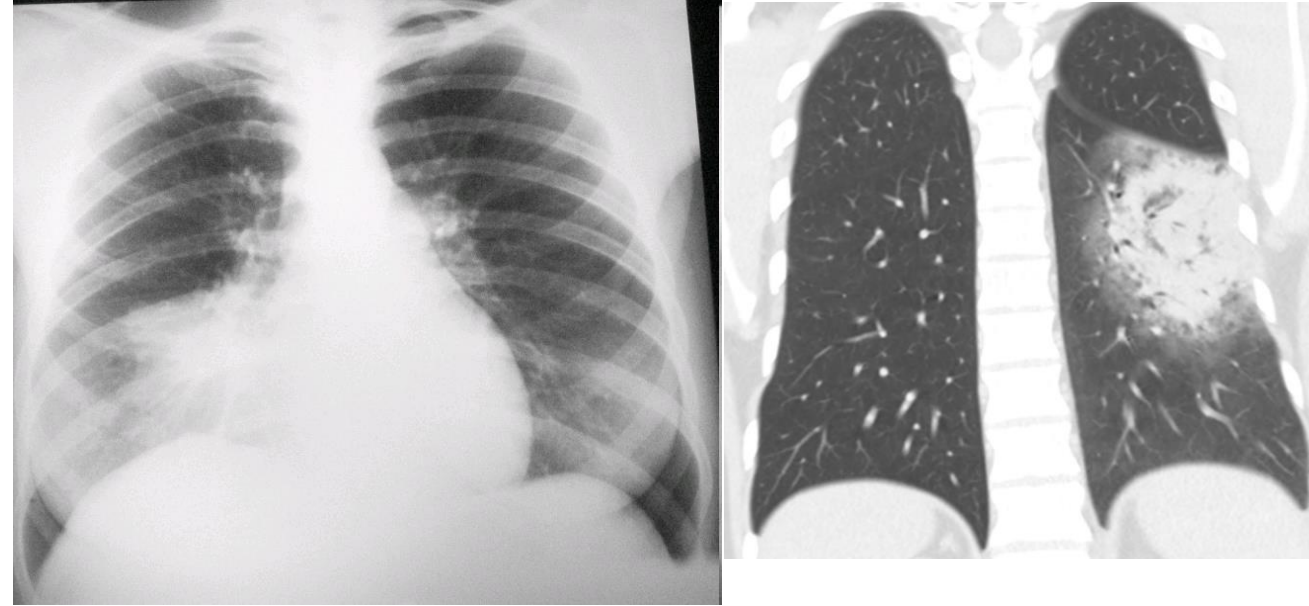






Konsolidasyon

- Alveollerde havanın yerini alan, sıvı, pü, hücre, kan, protein, ekzojen yağ
- Pnömoni demek değil
- Akciğer atenuasyonu azalmasıyla BT ve radyografilerde; bronş duvarı, interstisyel alan, damarlar ayırt edilmez

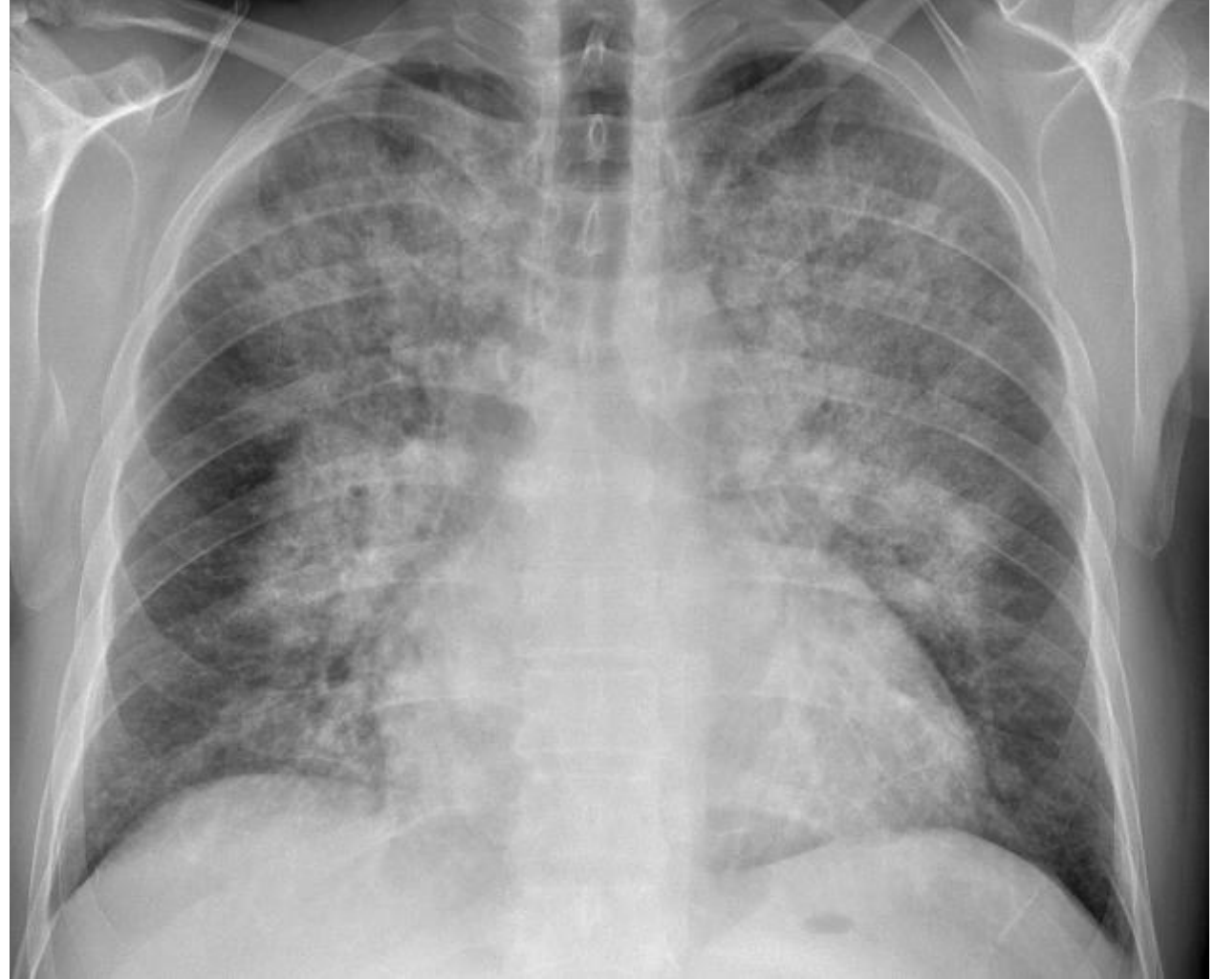


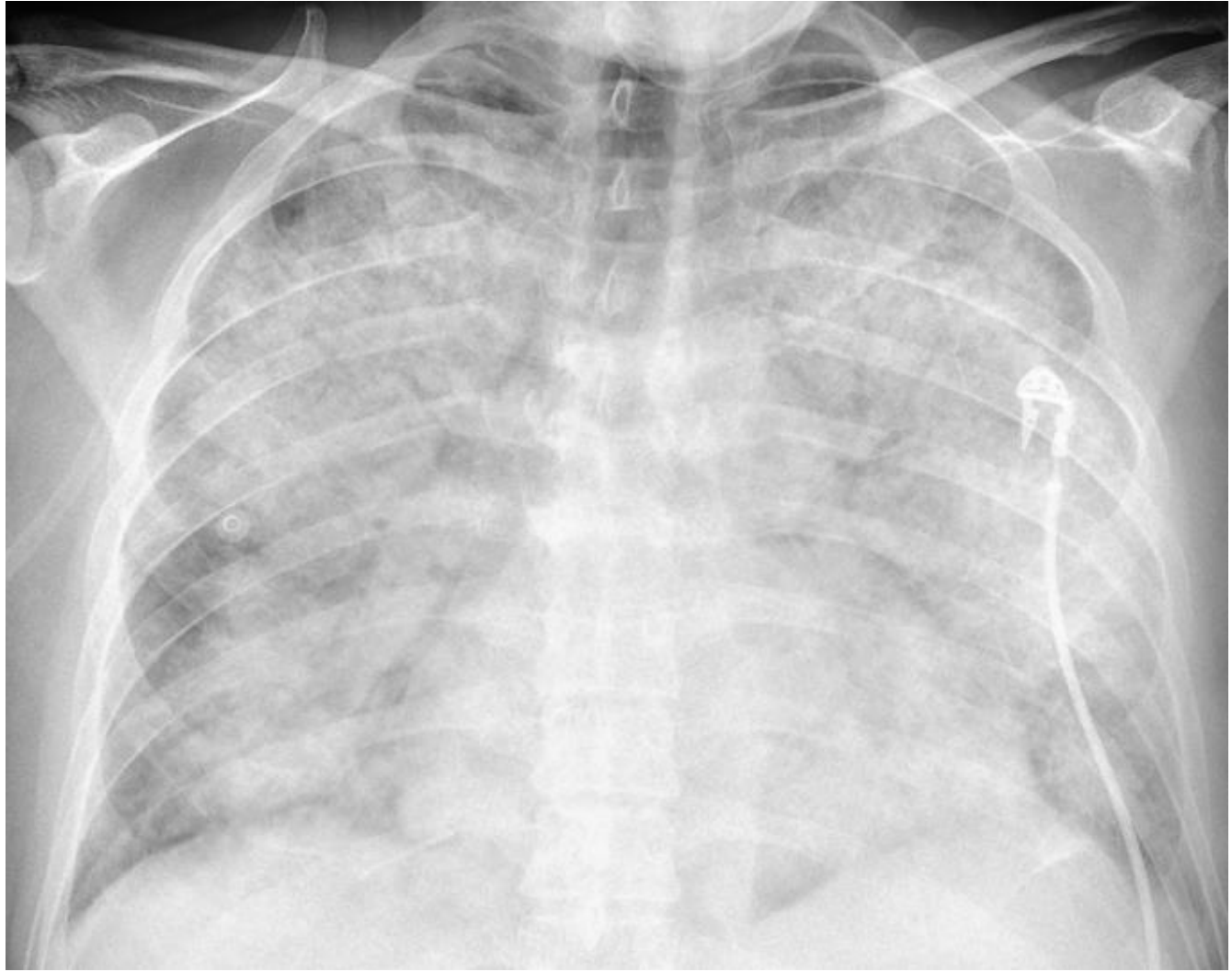
Konsolidasyon

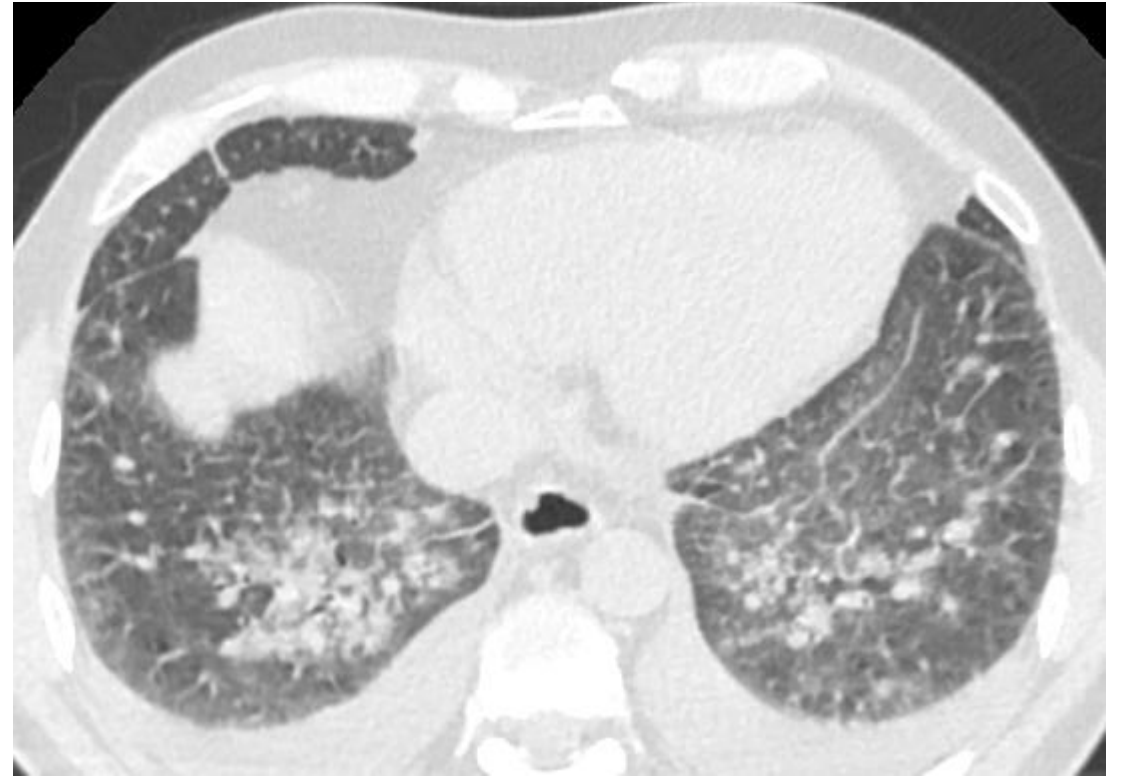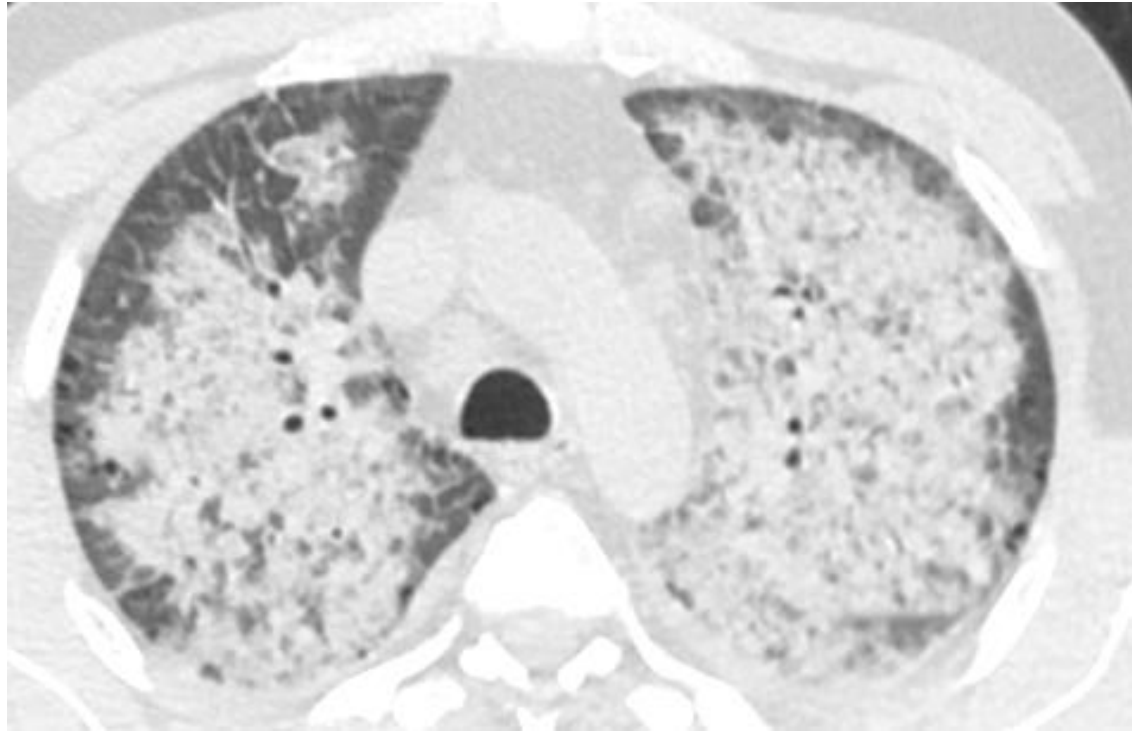Akut-kronik

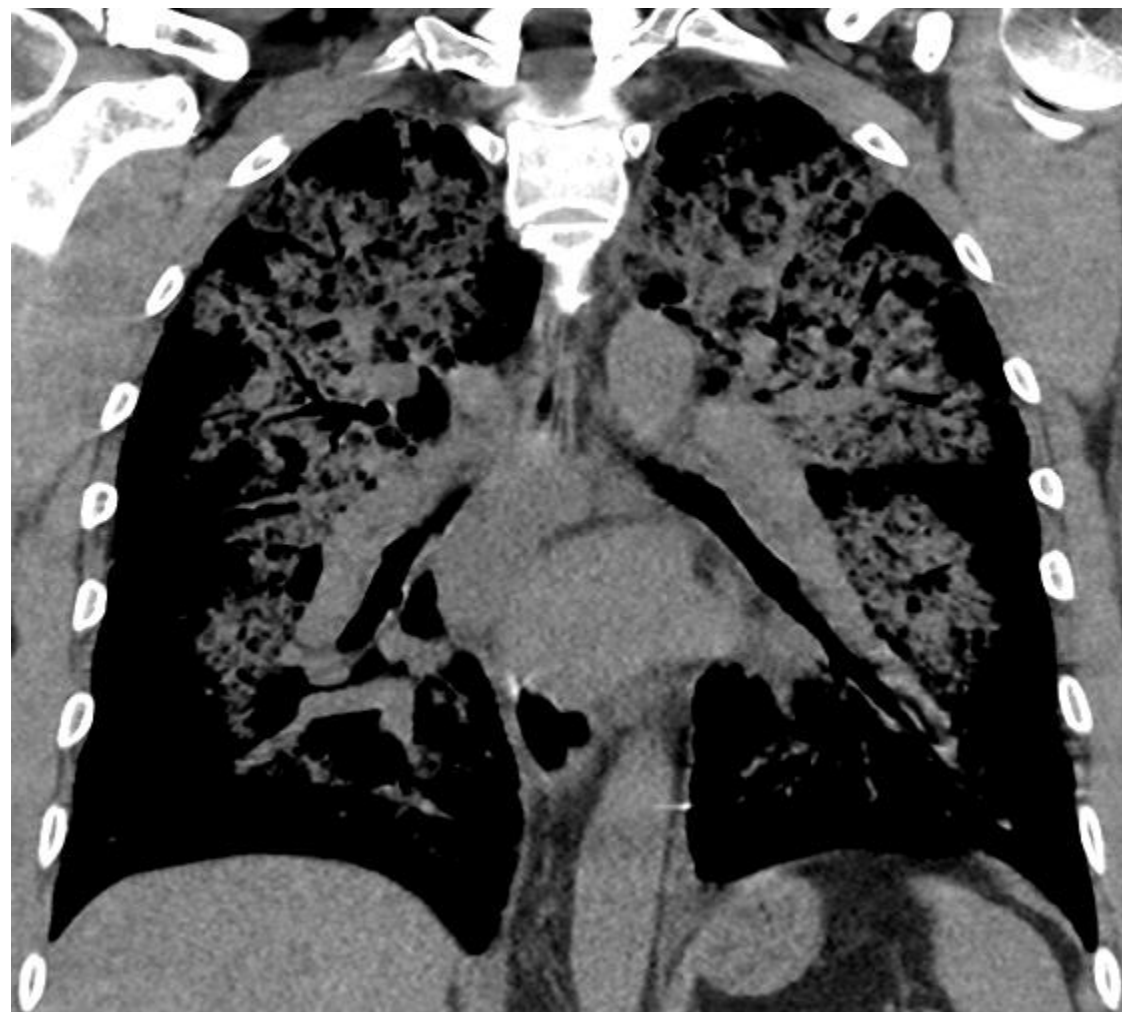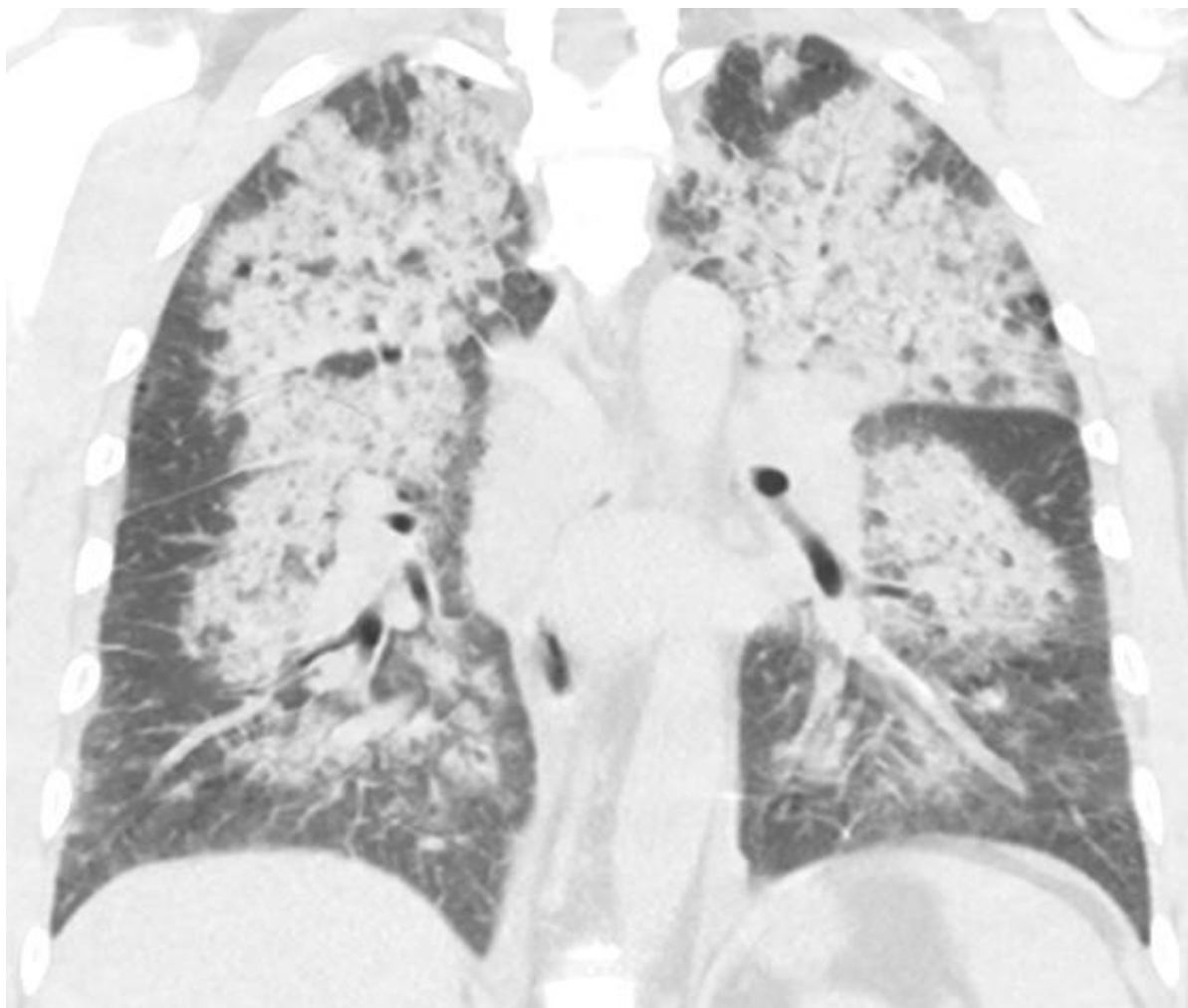
- Enfeksiyon
- Ödem
- Fibrozis
- Tümör
- Sarkodozis
- Hemoraji
- Akut, kronik eozinofilik pn
- Organize pn

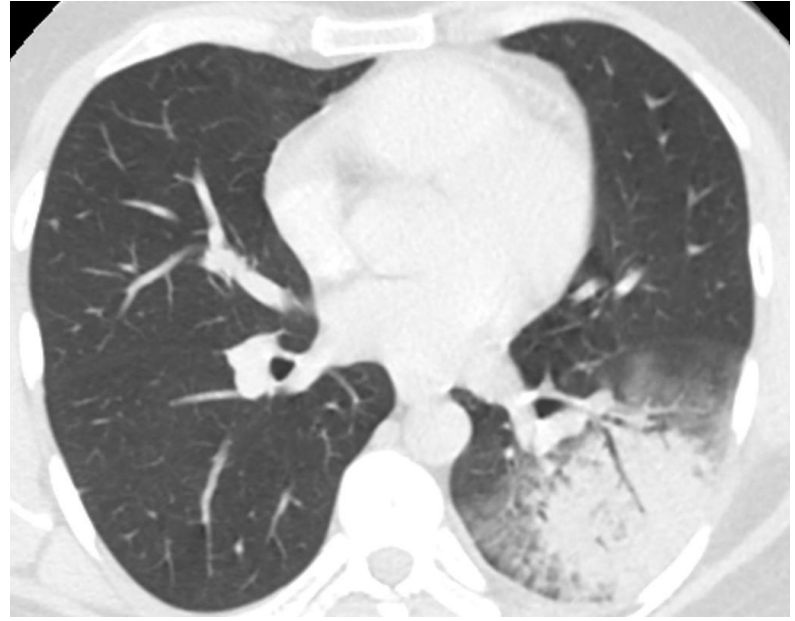
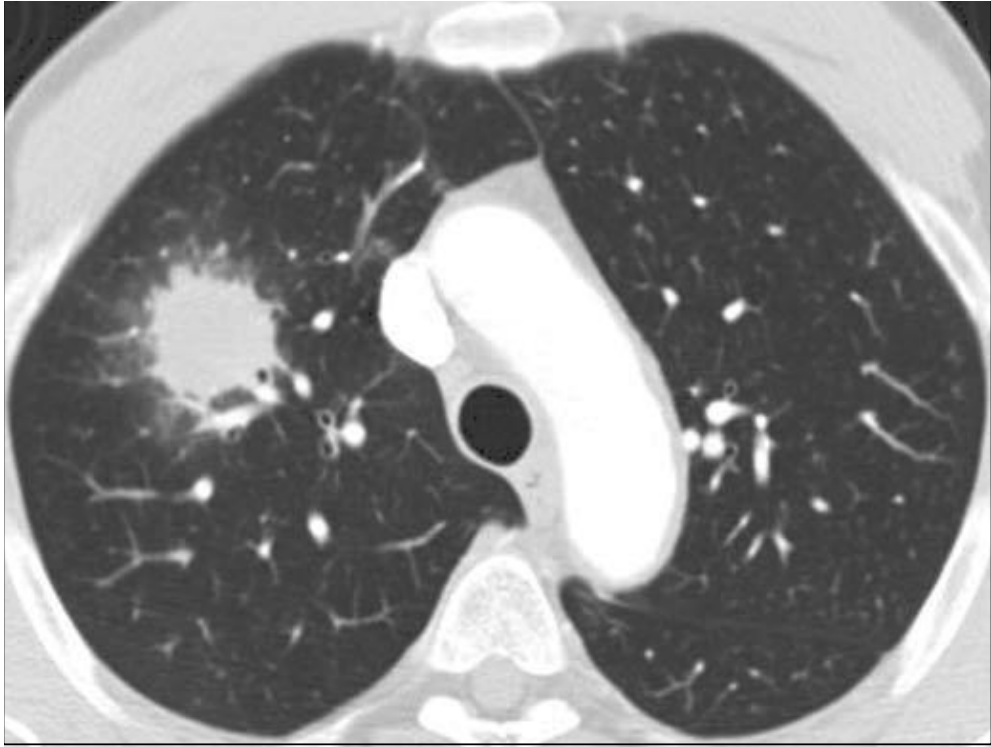
55 yaşında korener arter hastalığı, MI



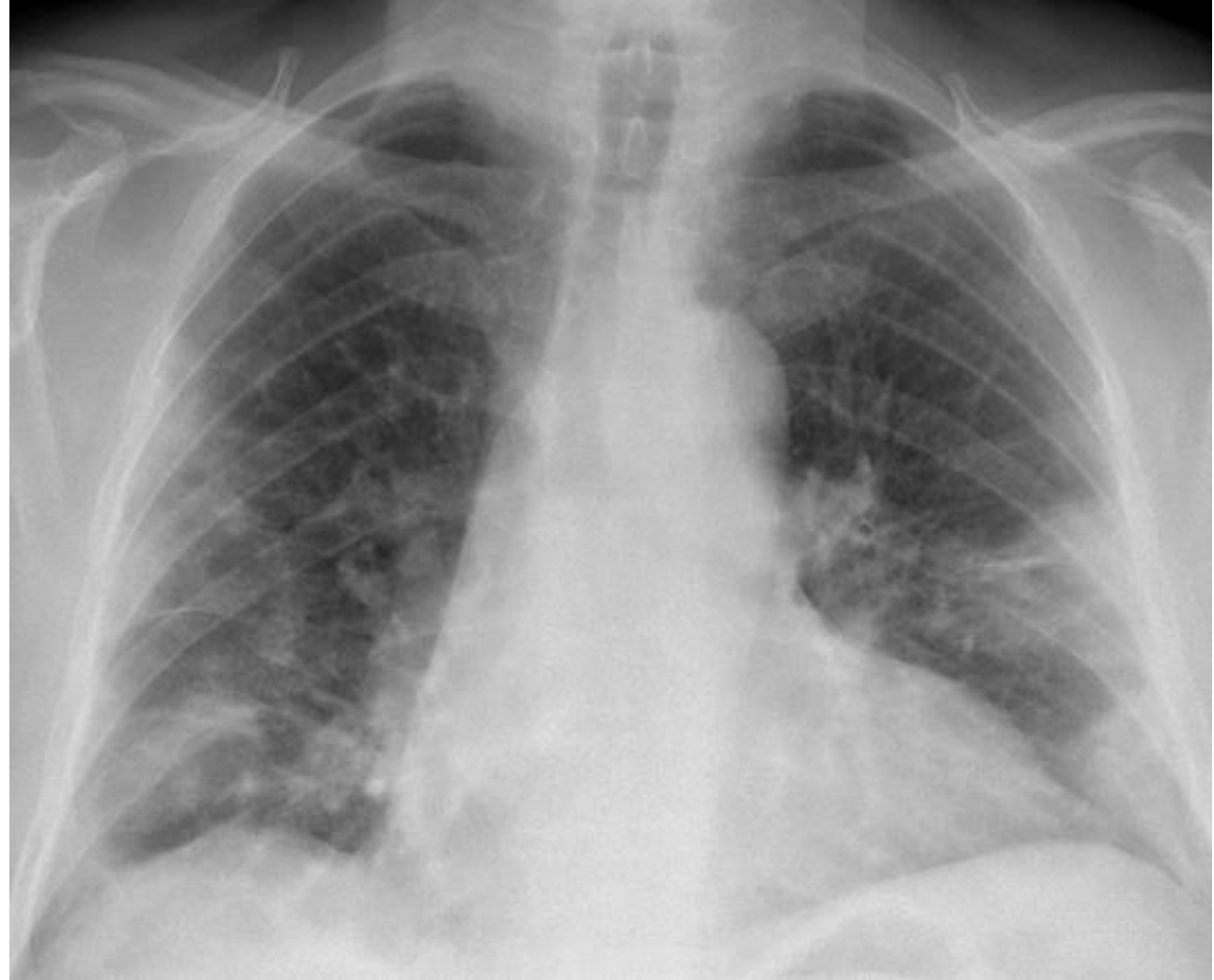

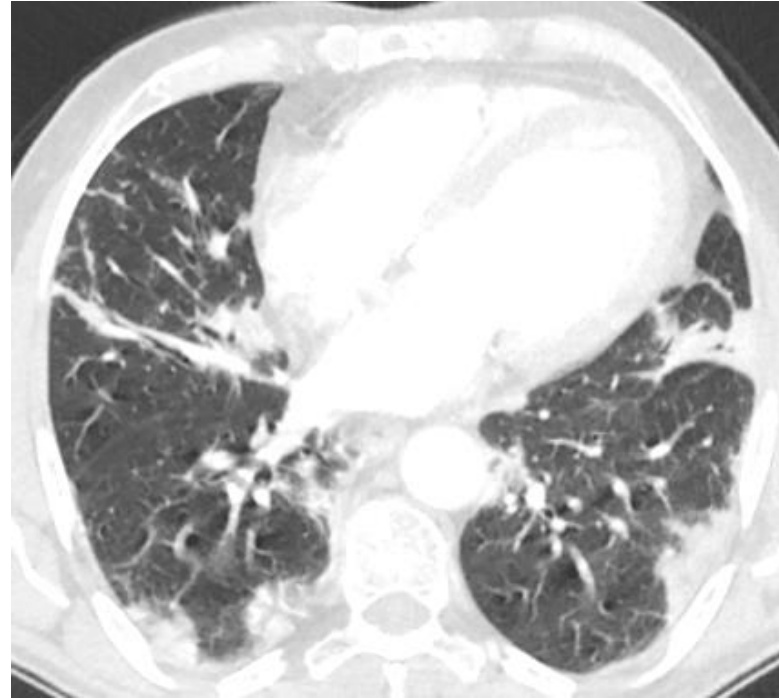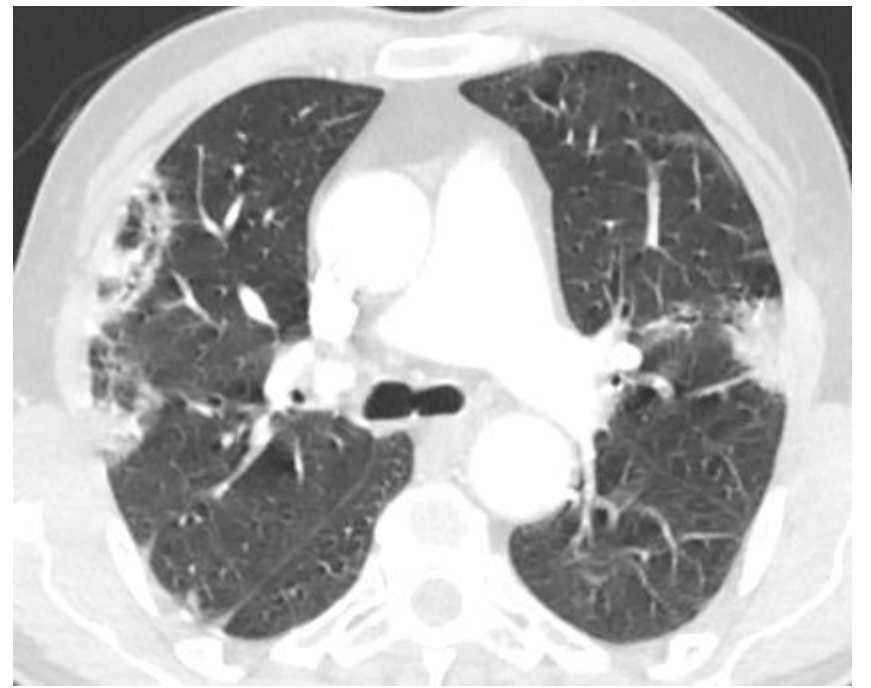


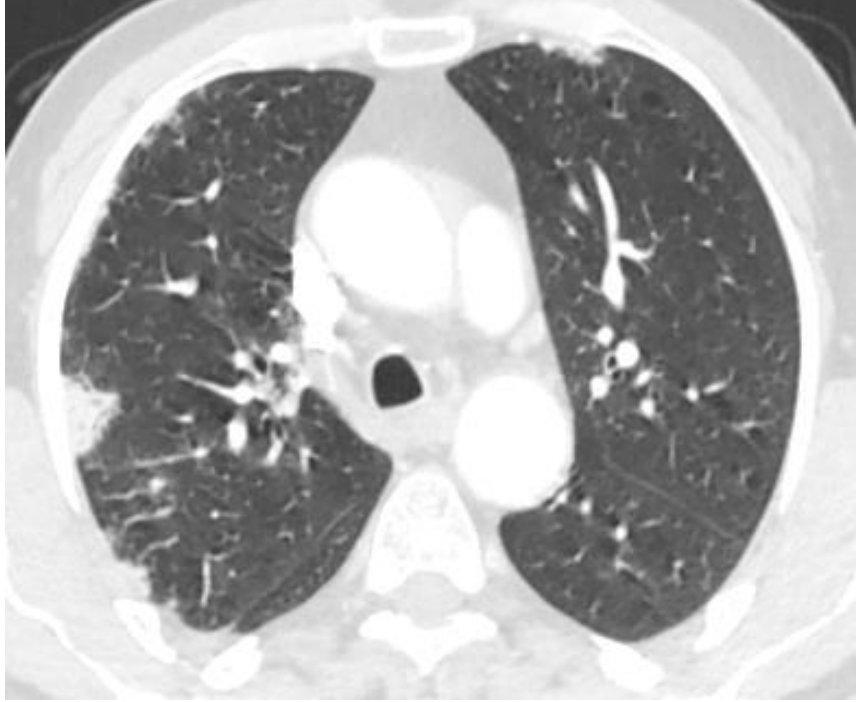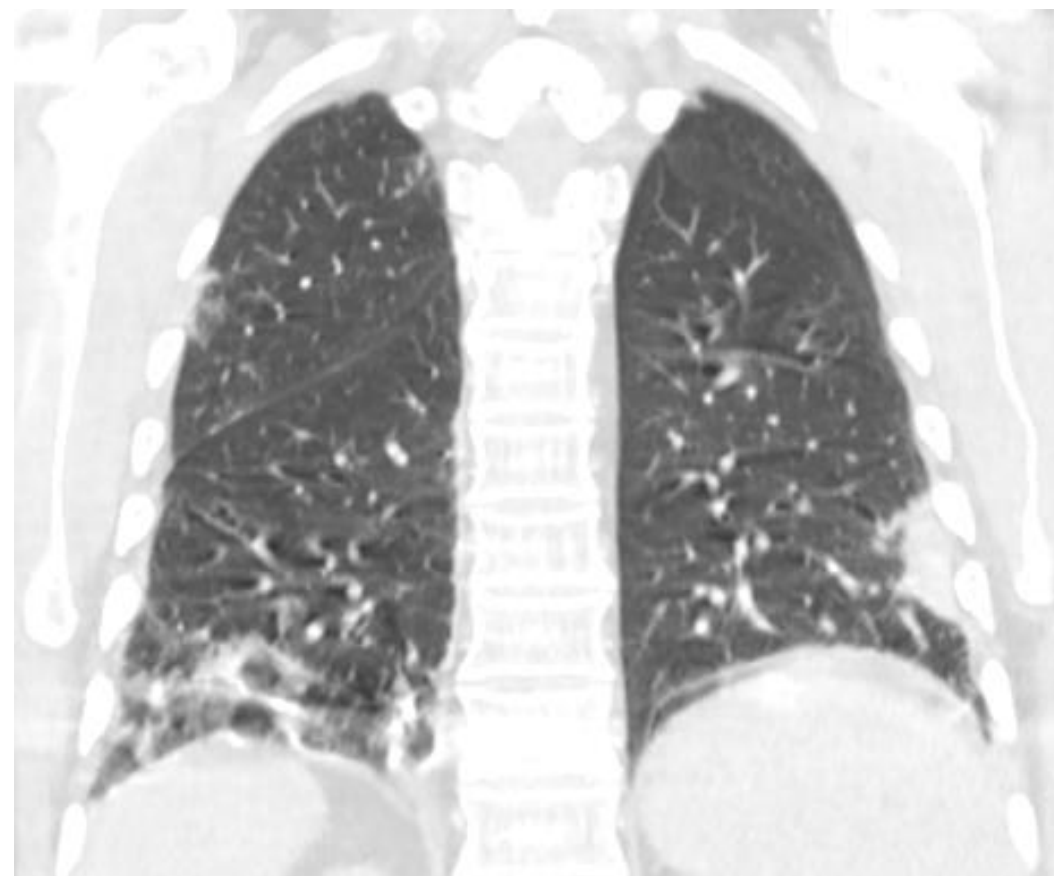
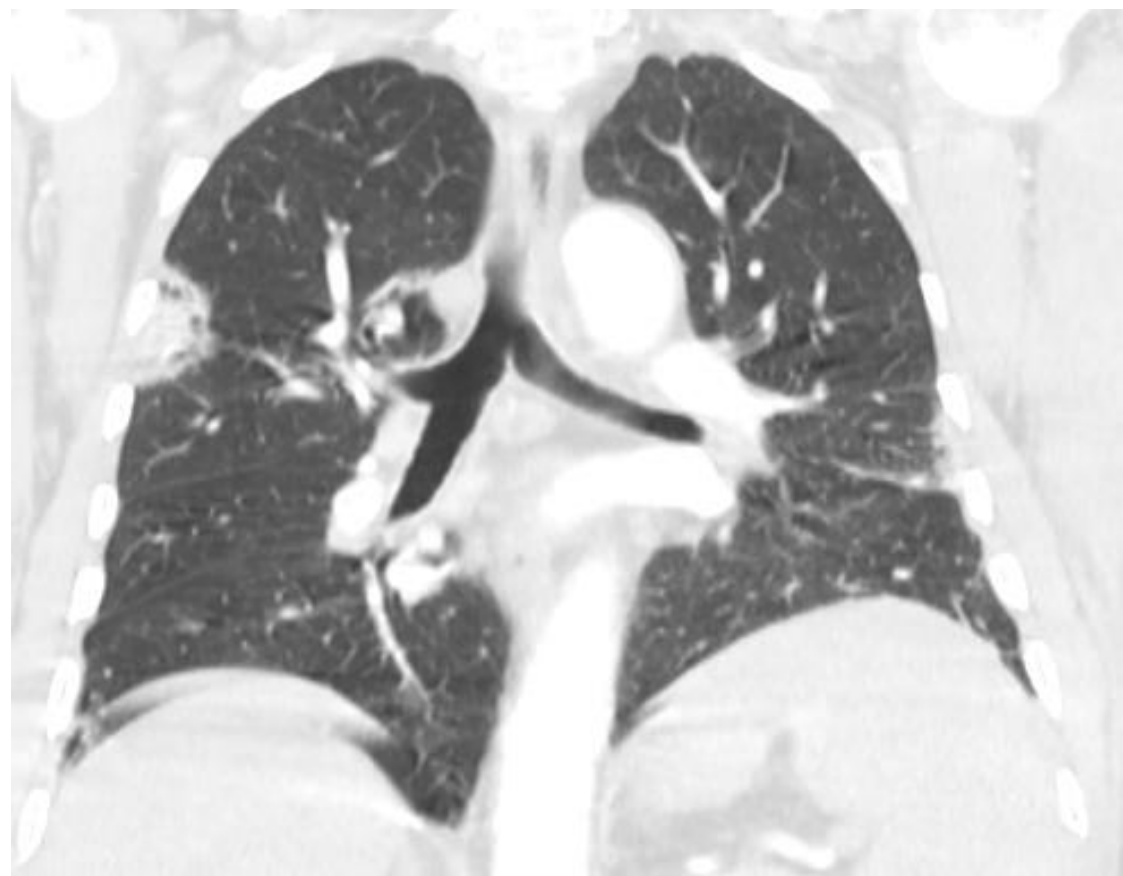


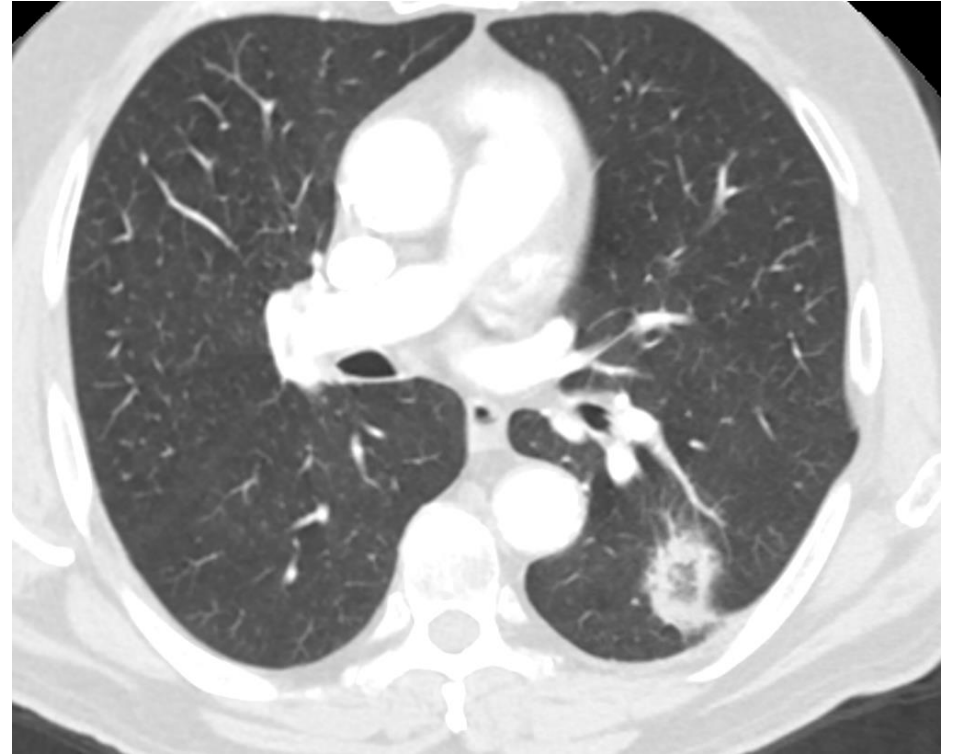
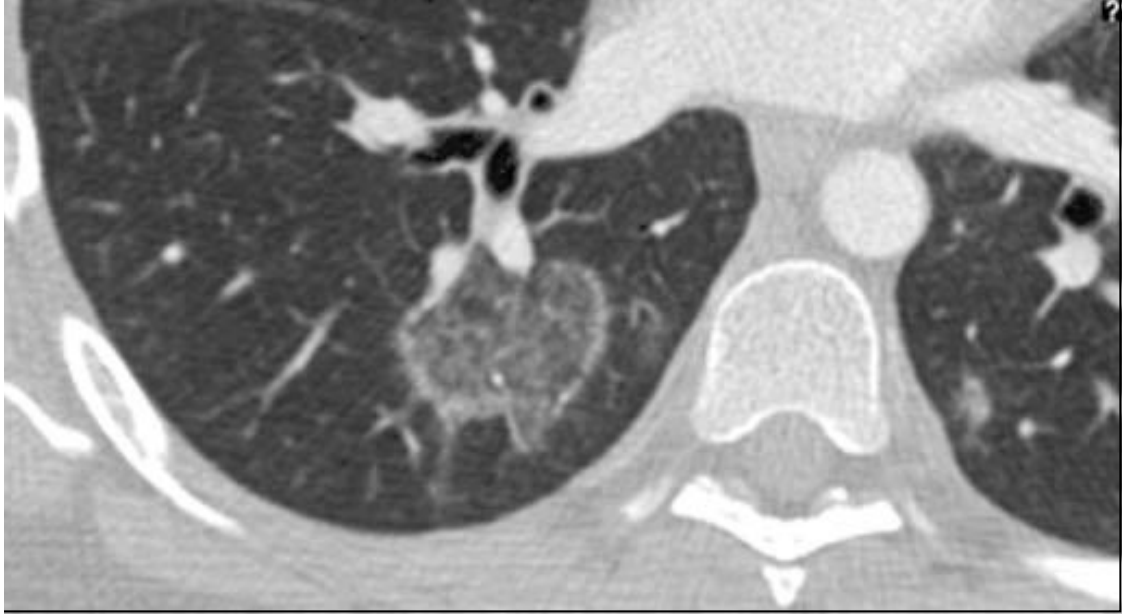


70 yaşında kadın hasta
Kemoterapi alıyor



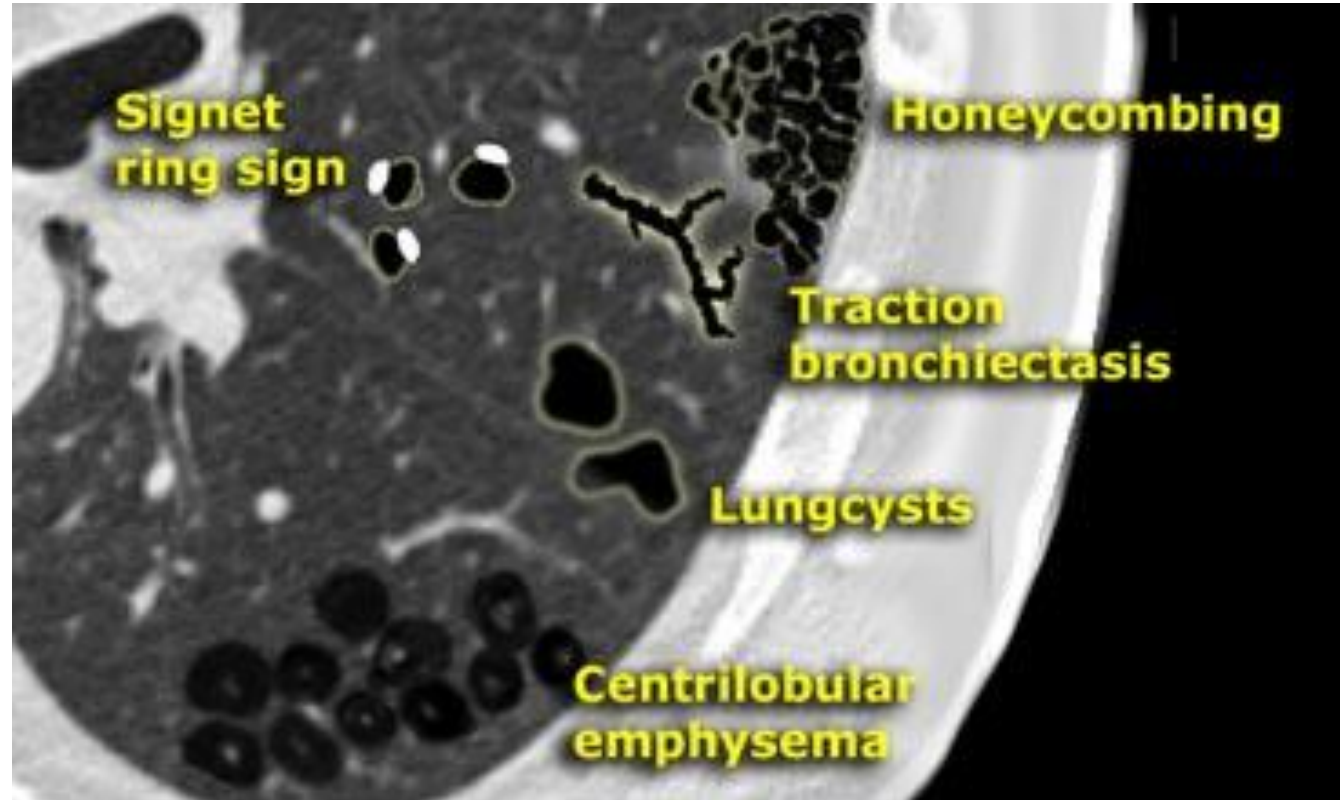






Düşük atenüasyon paterni

- Amfizem
- Akciğer kistleri (LASM, LIP, langerhans histiyosidozis)
- Bronşektazi
- Bal peteđi



Radiology assistant

67 yaşına erkek hasta



