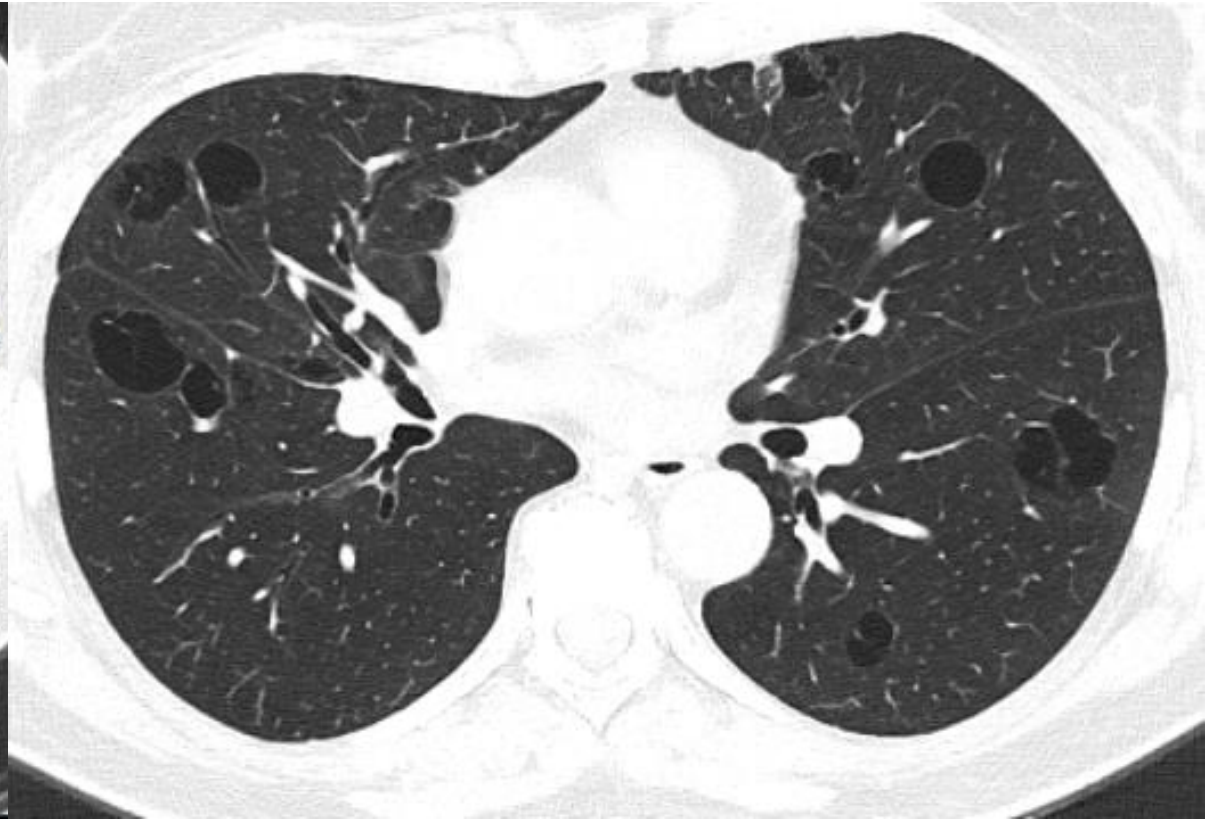
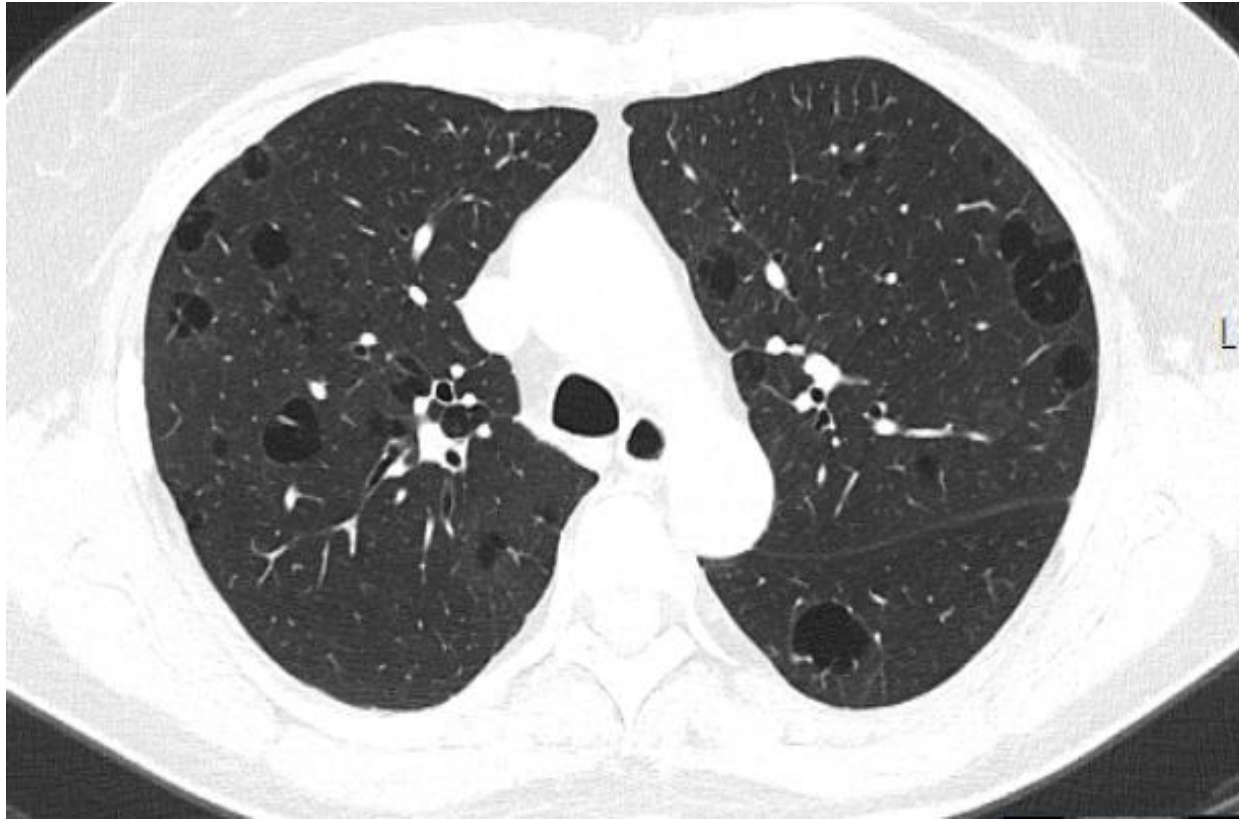


HRCT: OLGU ÖRNEKLERİ

DR RECEP SAVAŞ
EGE ÜNİVERSİTESİ TIP FAKÜLTESİ RADYOLOJİ AD,
İZMİR

HAVA KİSTLERİ

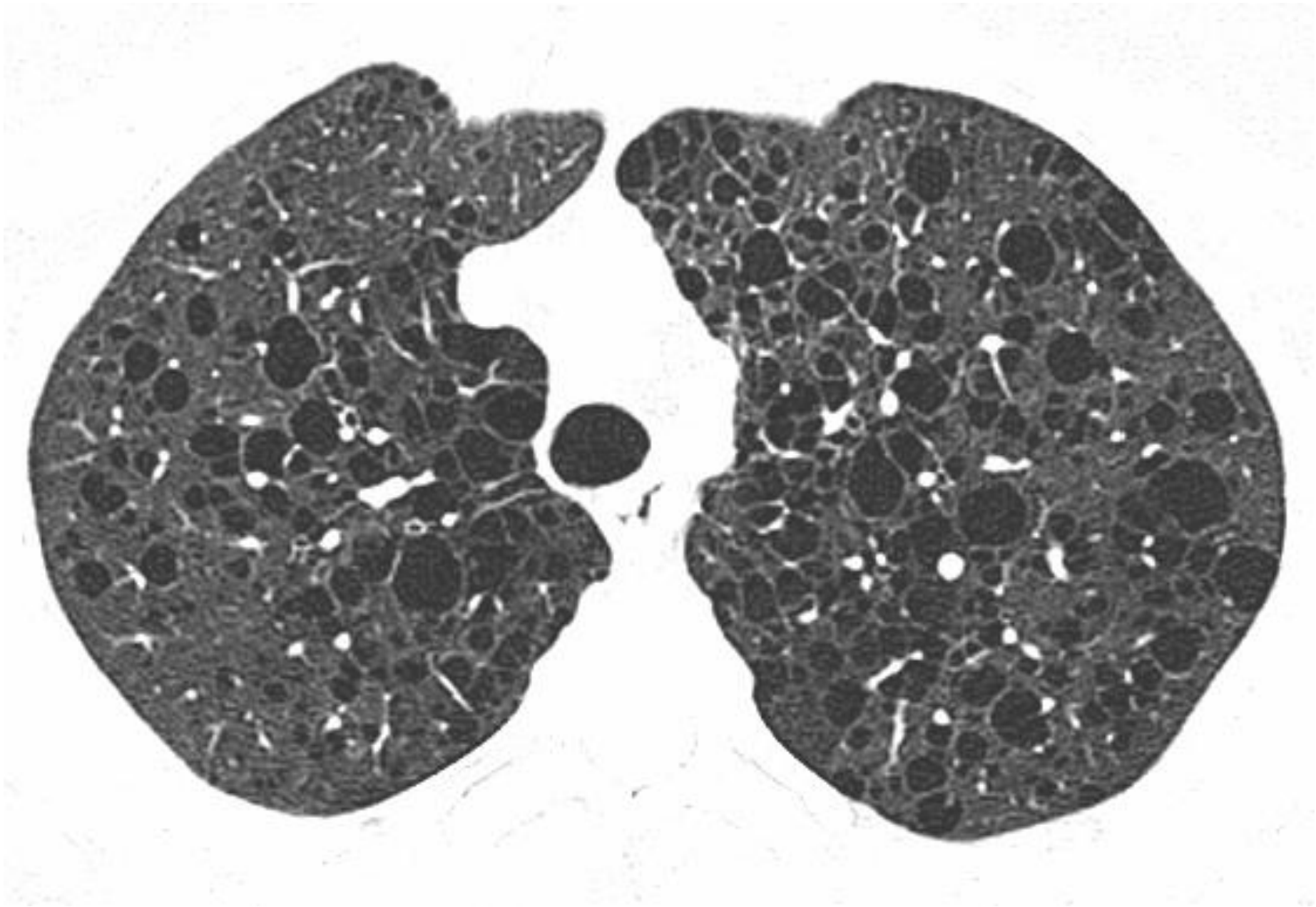

55 y E

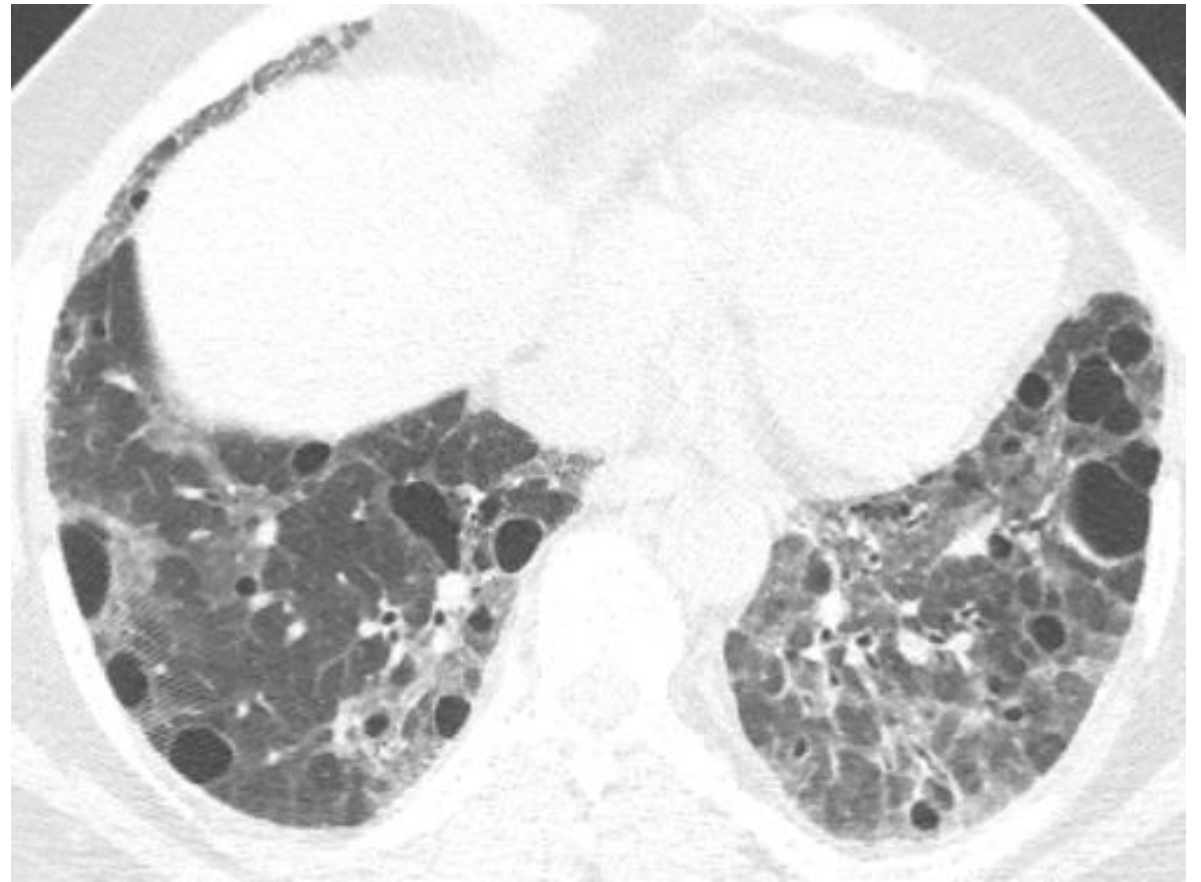
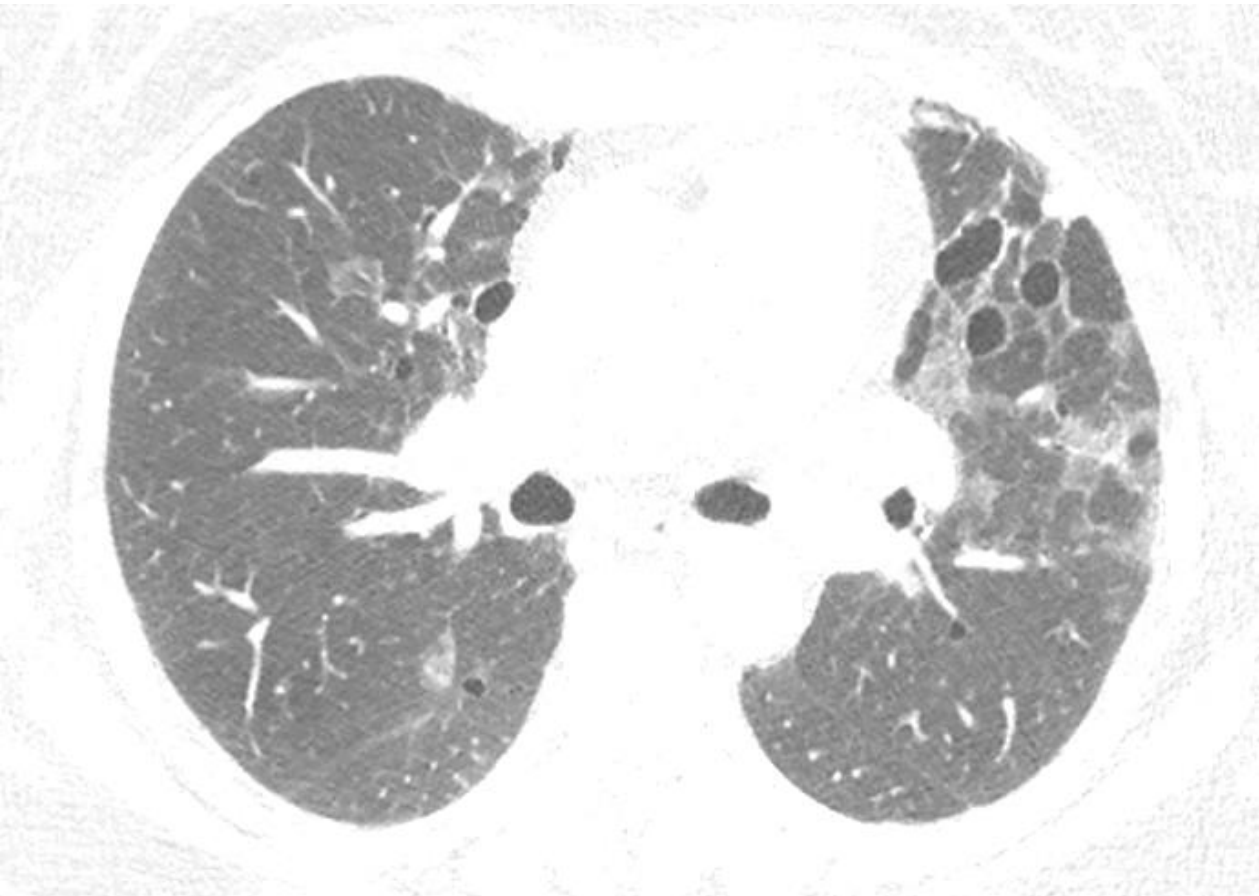
30.03.2022

NELER OLABİLİR?

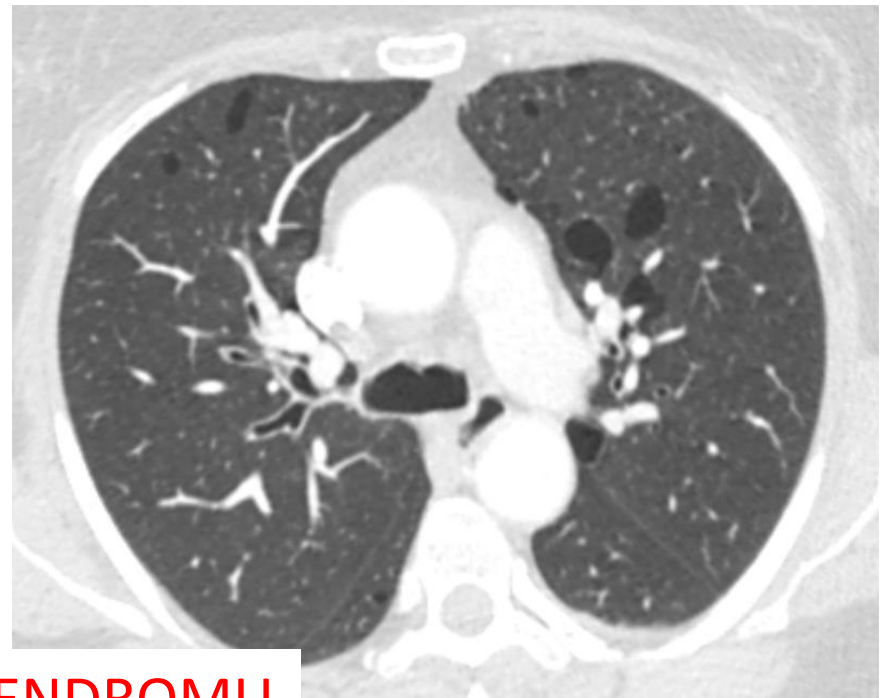
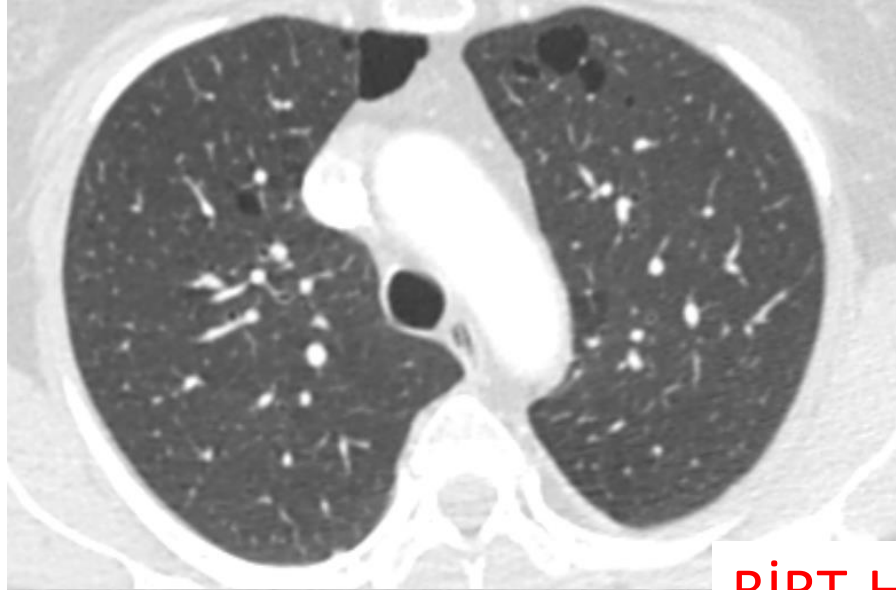- LAM
- LİP/DİP
- BHD SENDROMU
- AMİLOİDOZİS
- HAFİF ZİNCİR HASTALIĞI
- NÖROFİBROMATOZİS
- BALTOMA
- METASTAZ



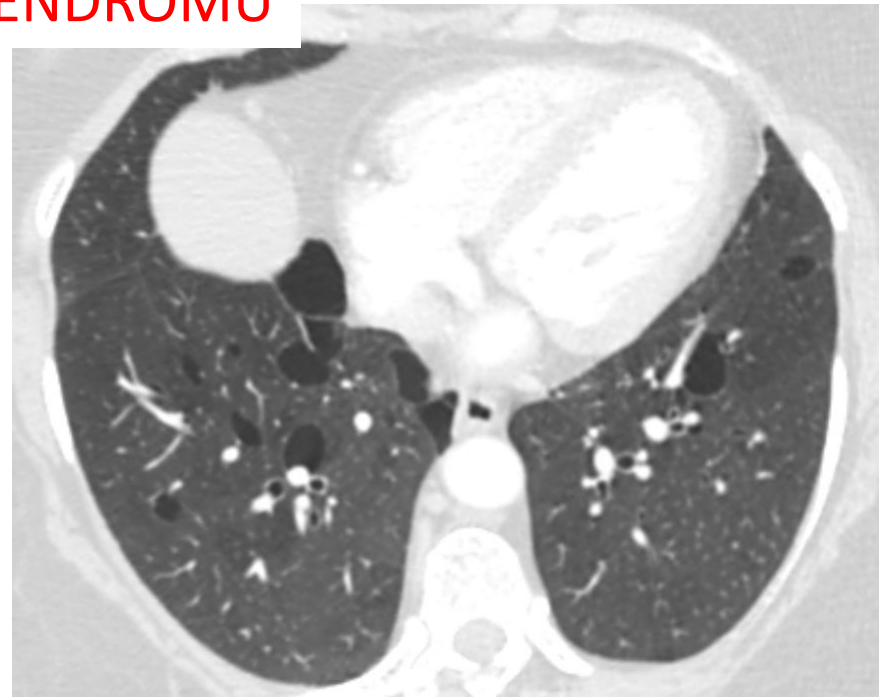
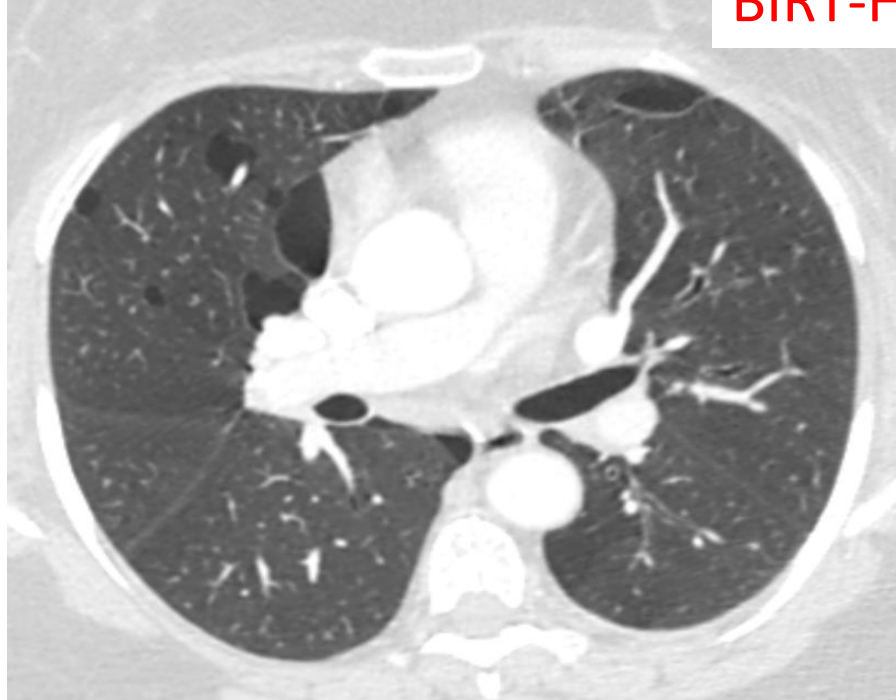
LAM

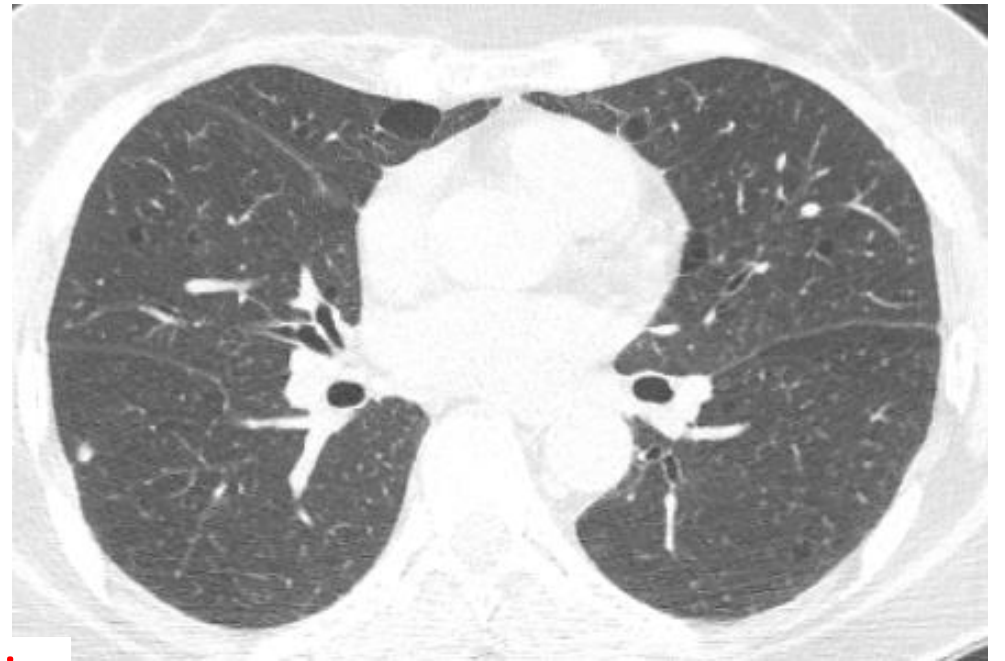
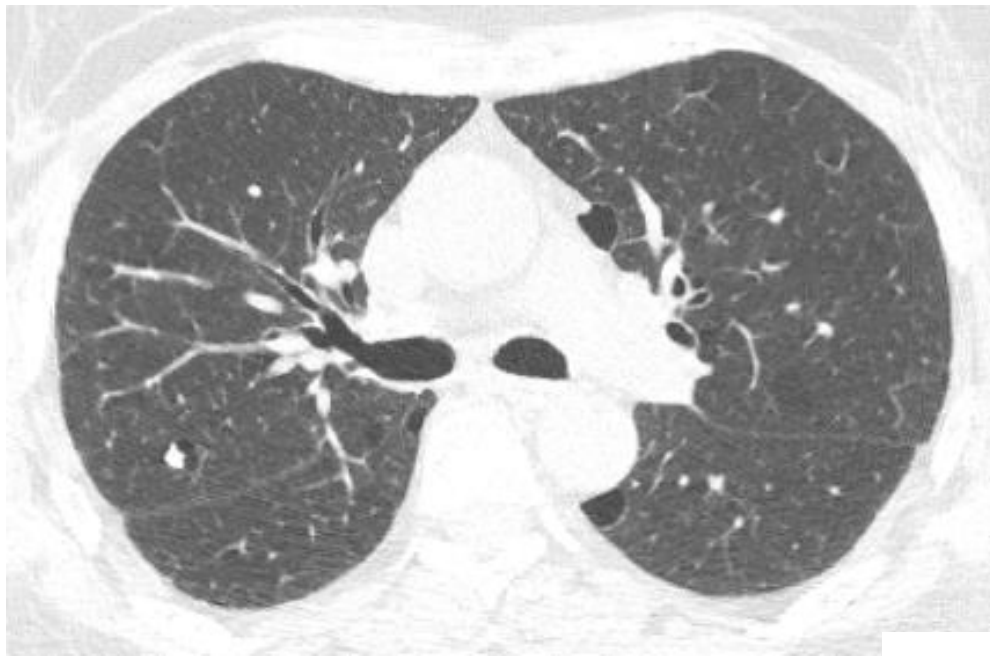
LIP

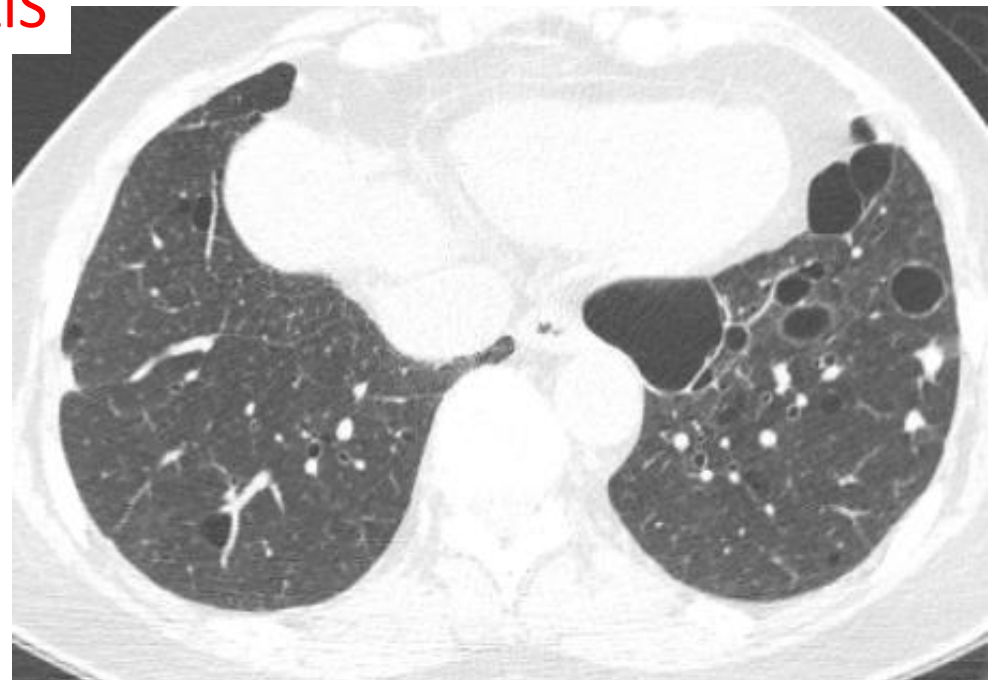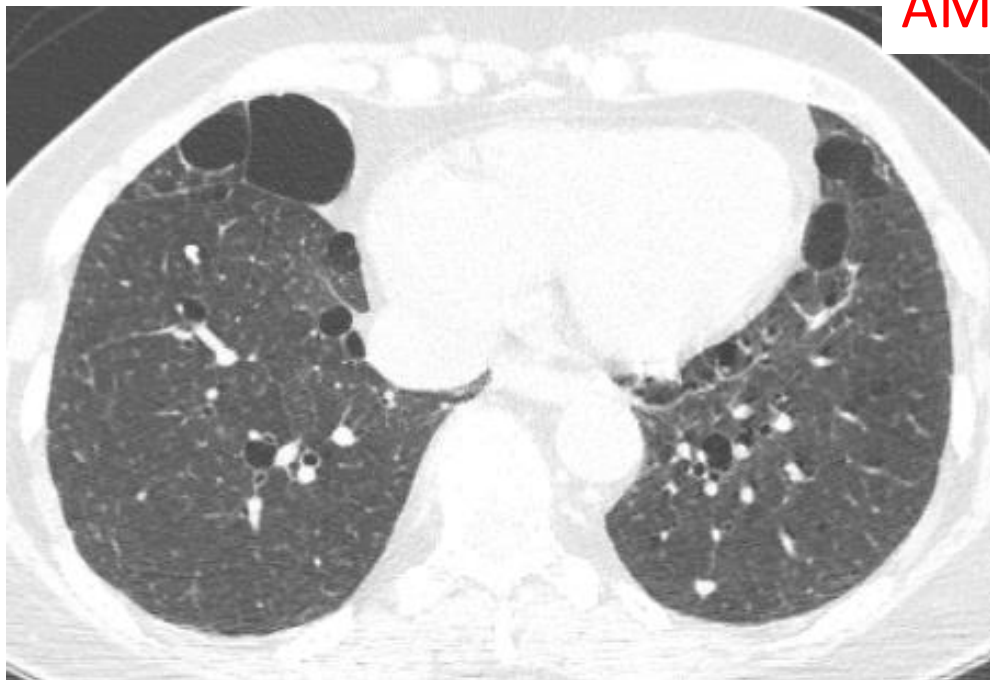


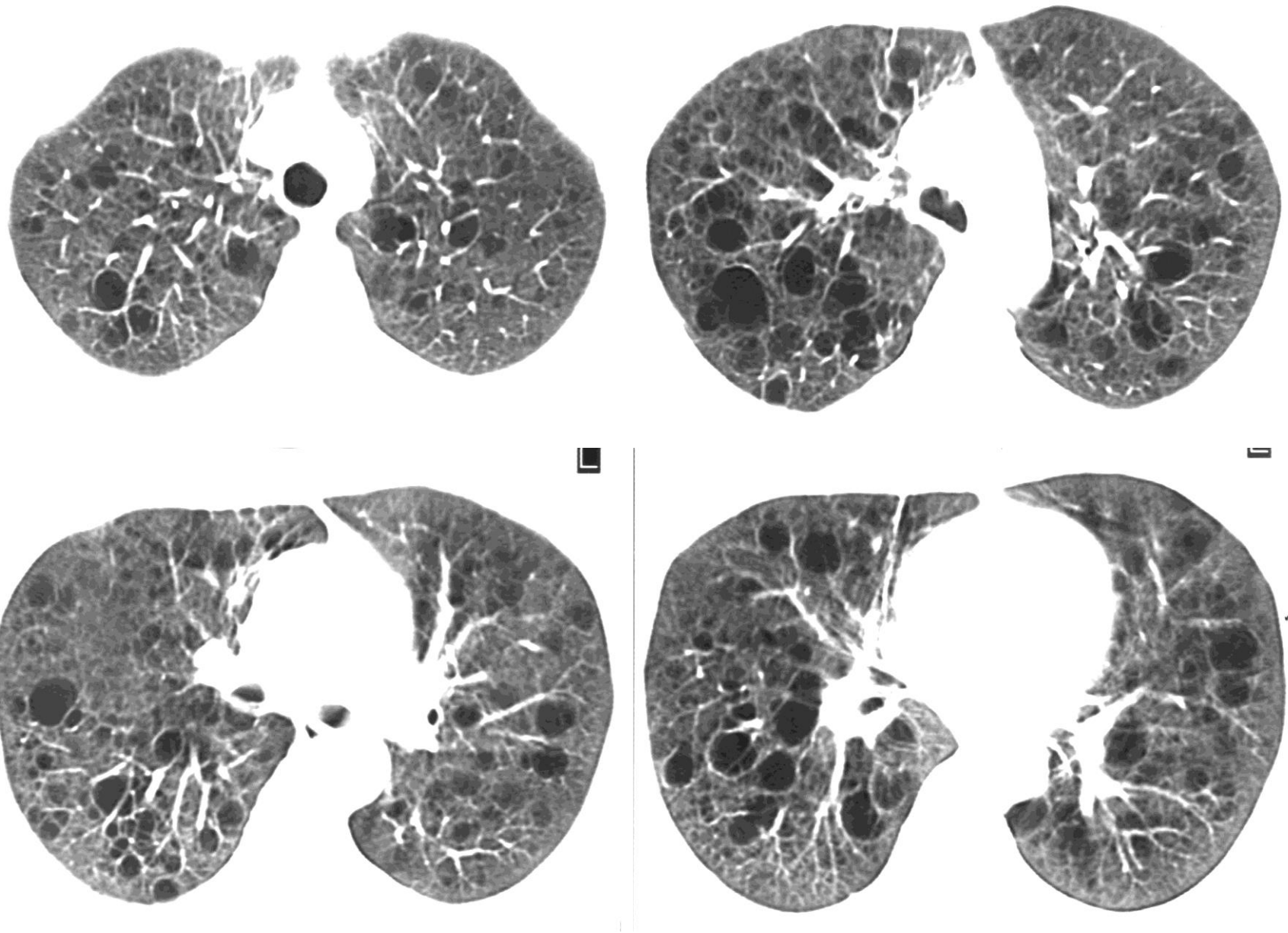
BİRT-HOGG-DUBE SENDROMU



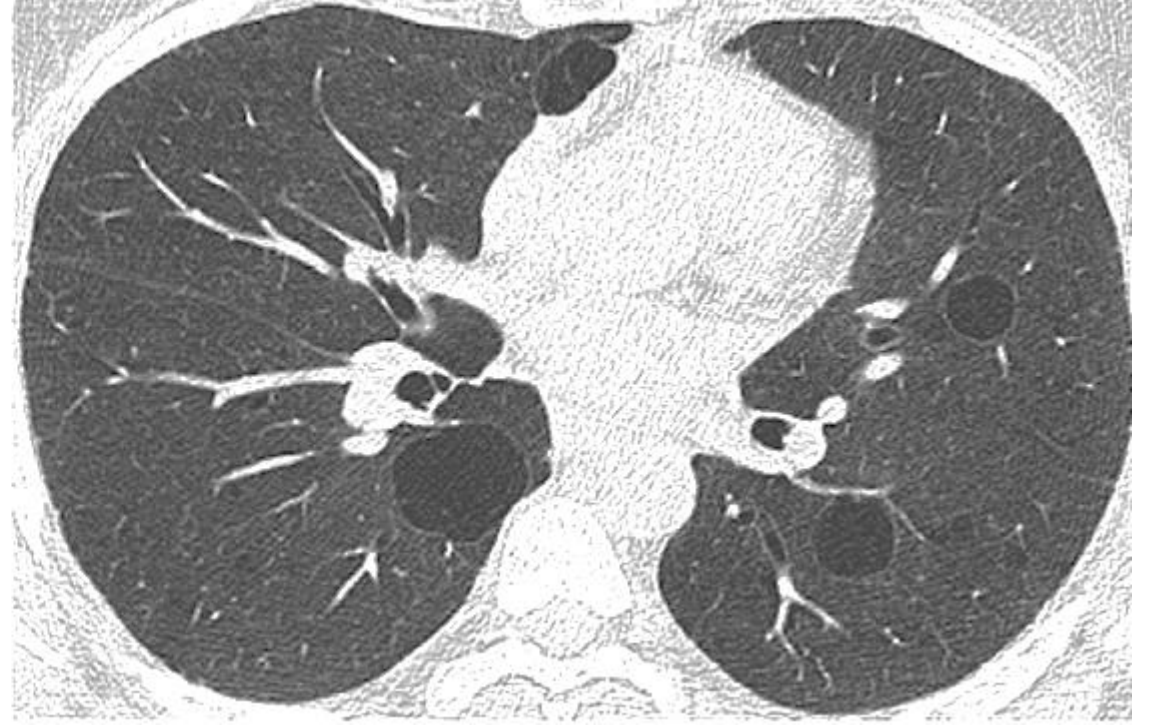
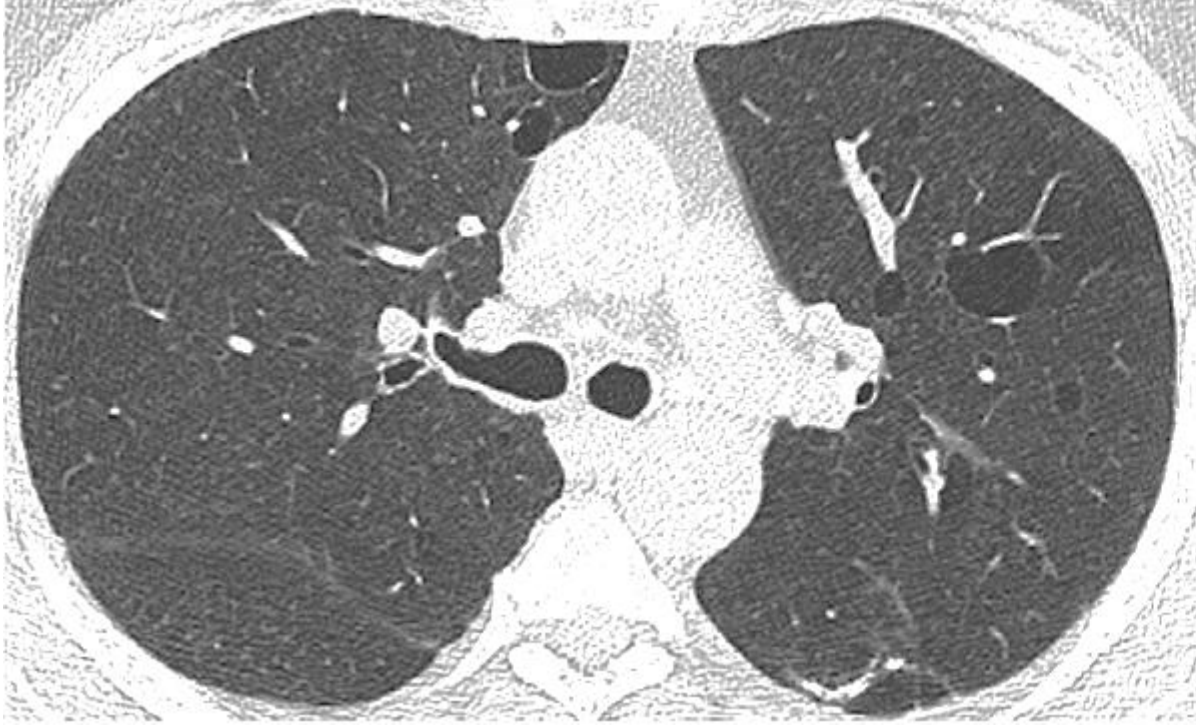

AMILOIDOZIS

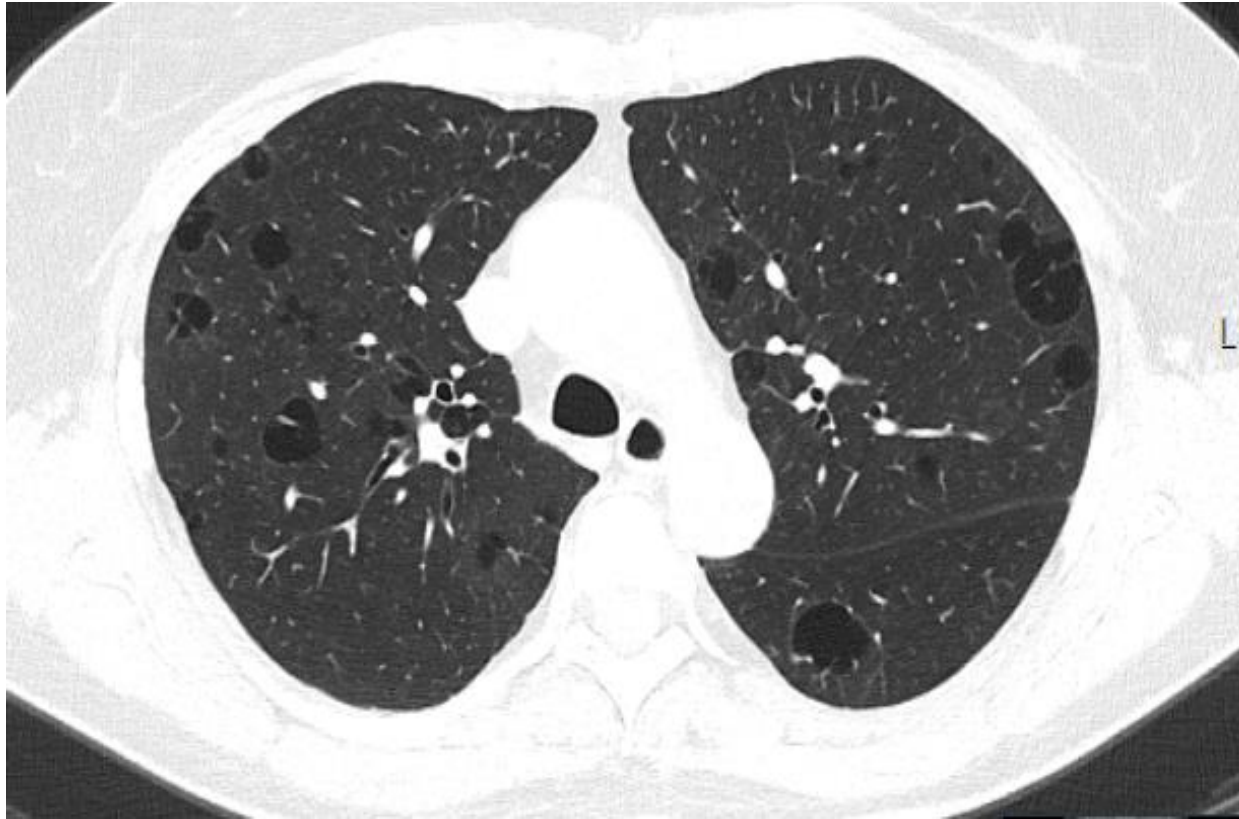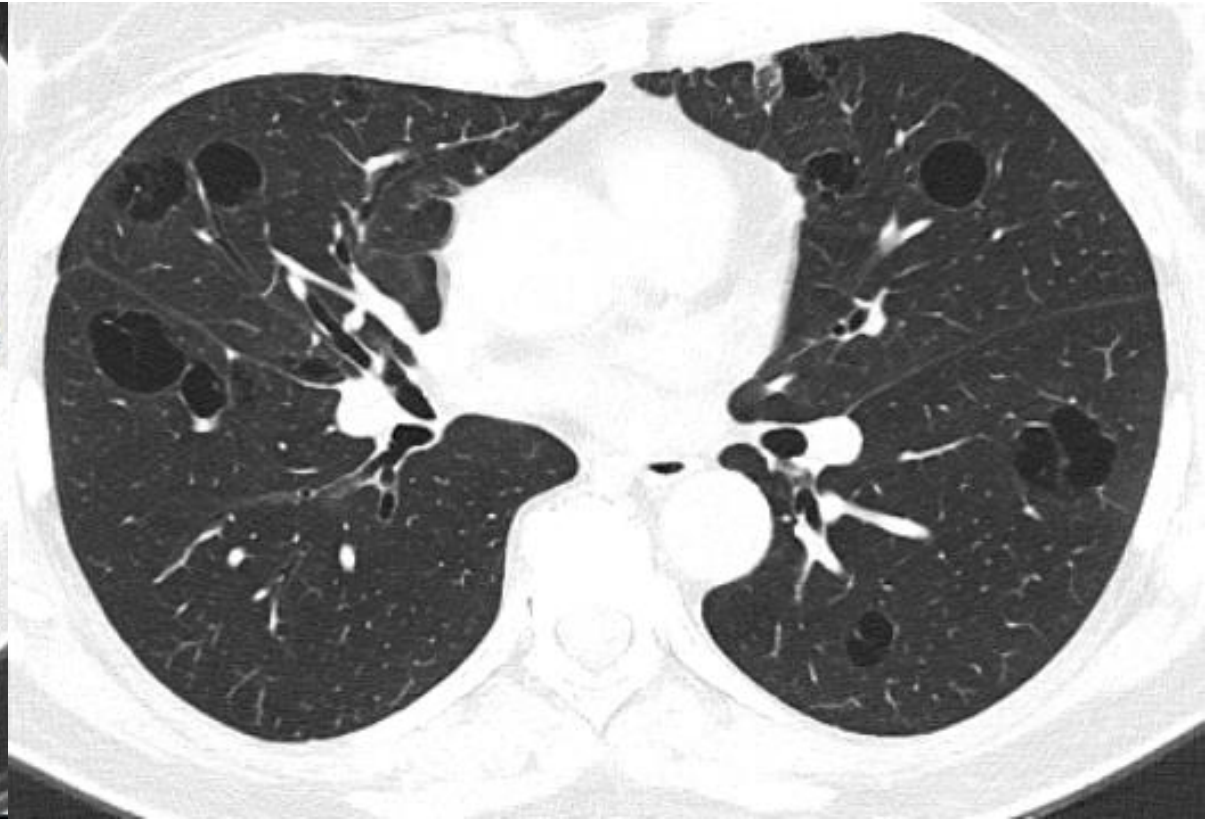




Nörofibromatozis

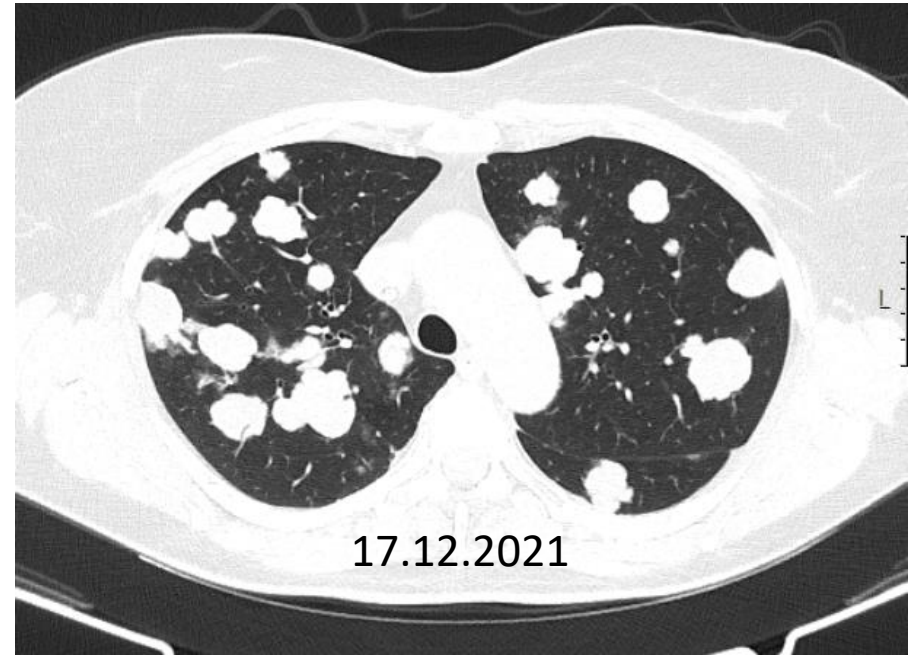
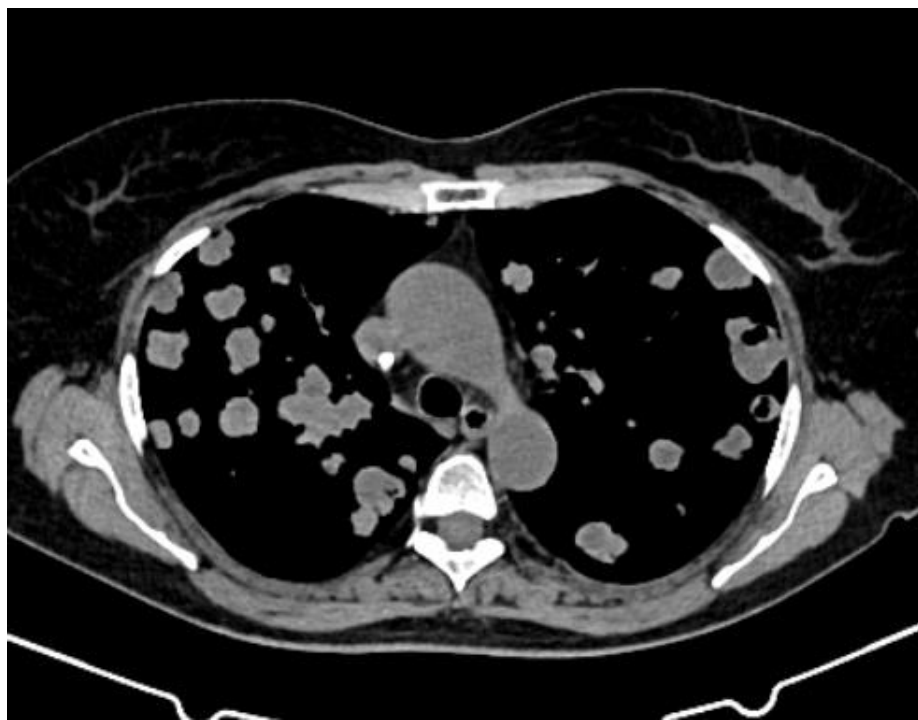

HAFİF ZİNCİR DEPO HASTALIĞI

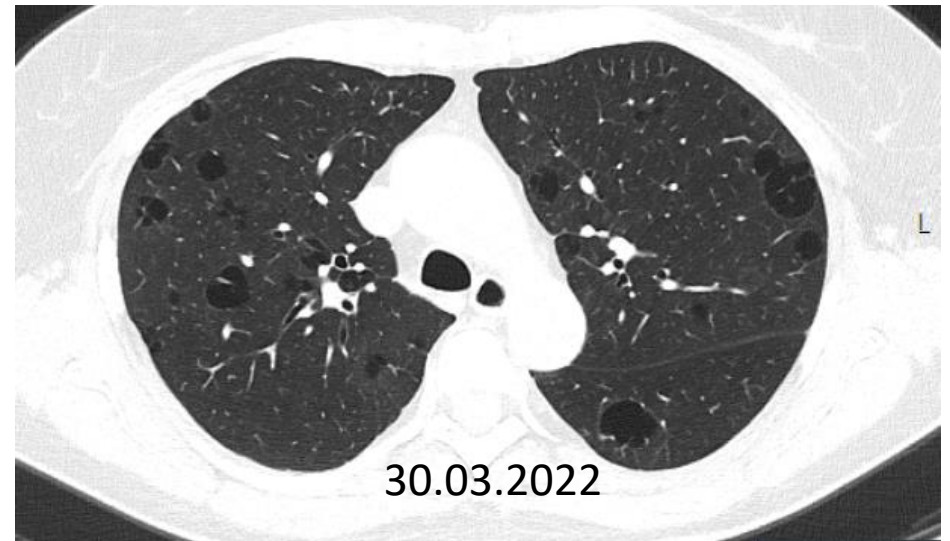
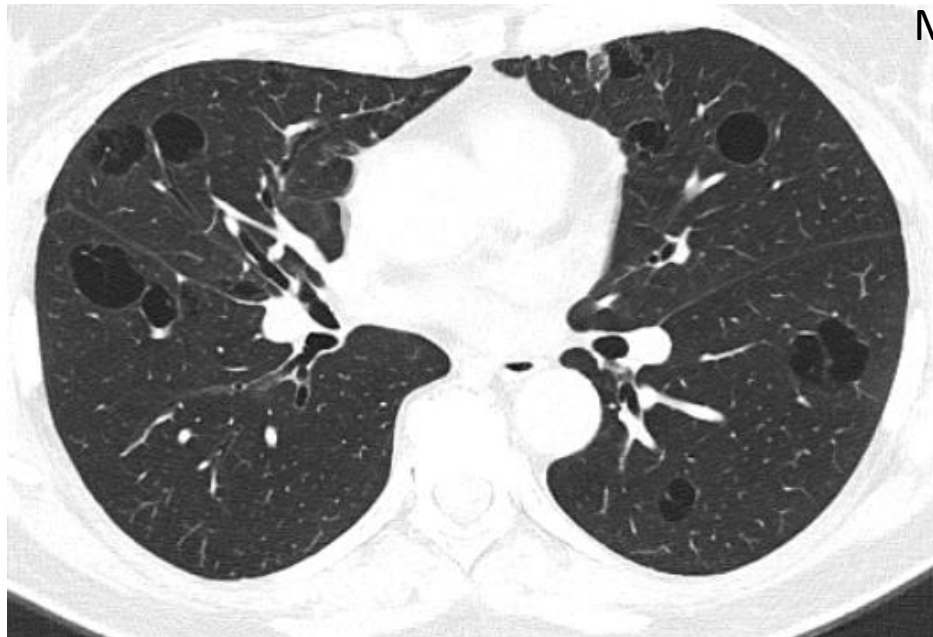

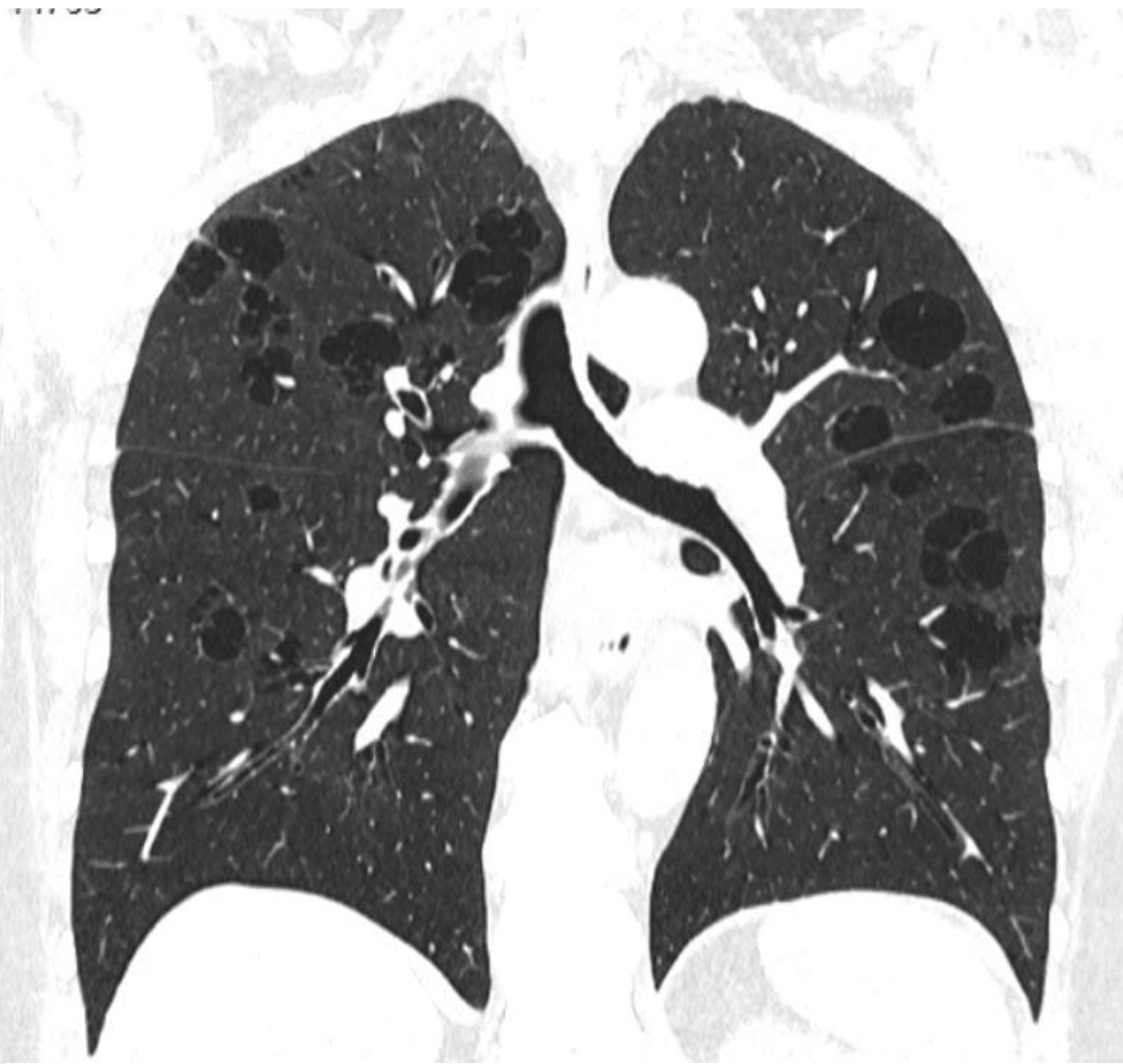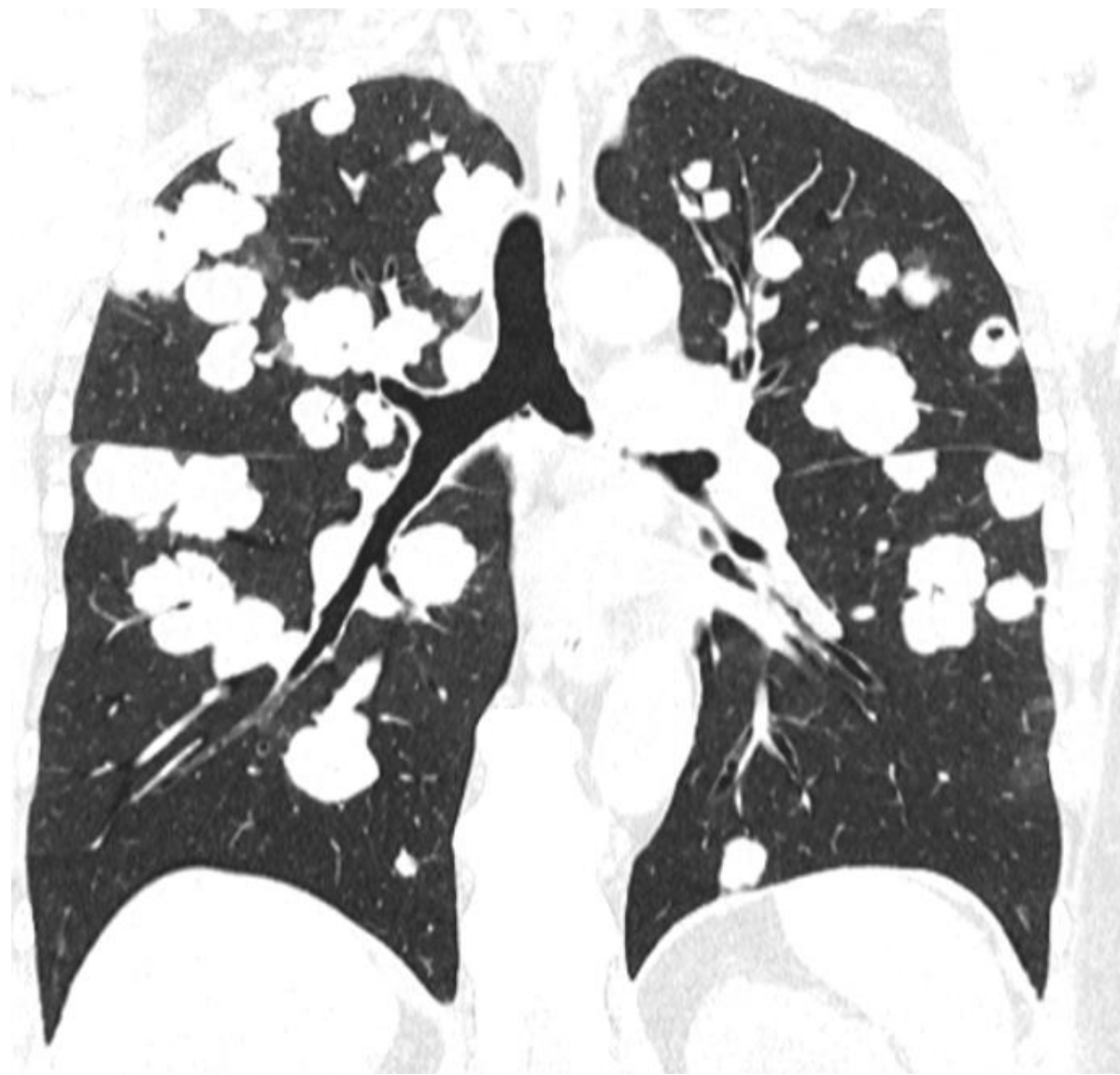
55 y E

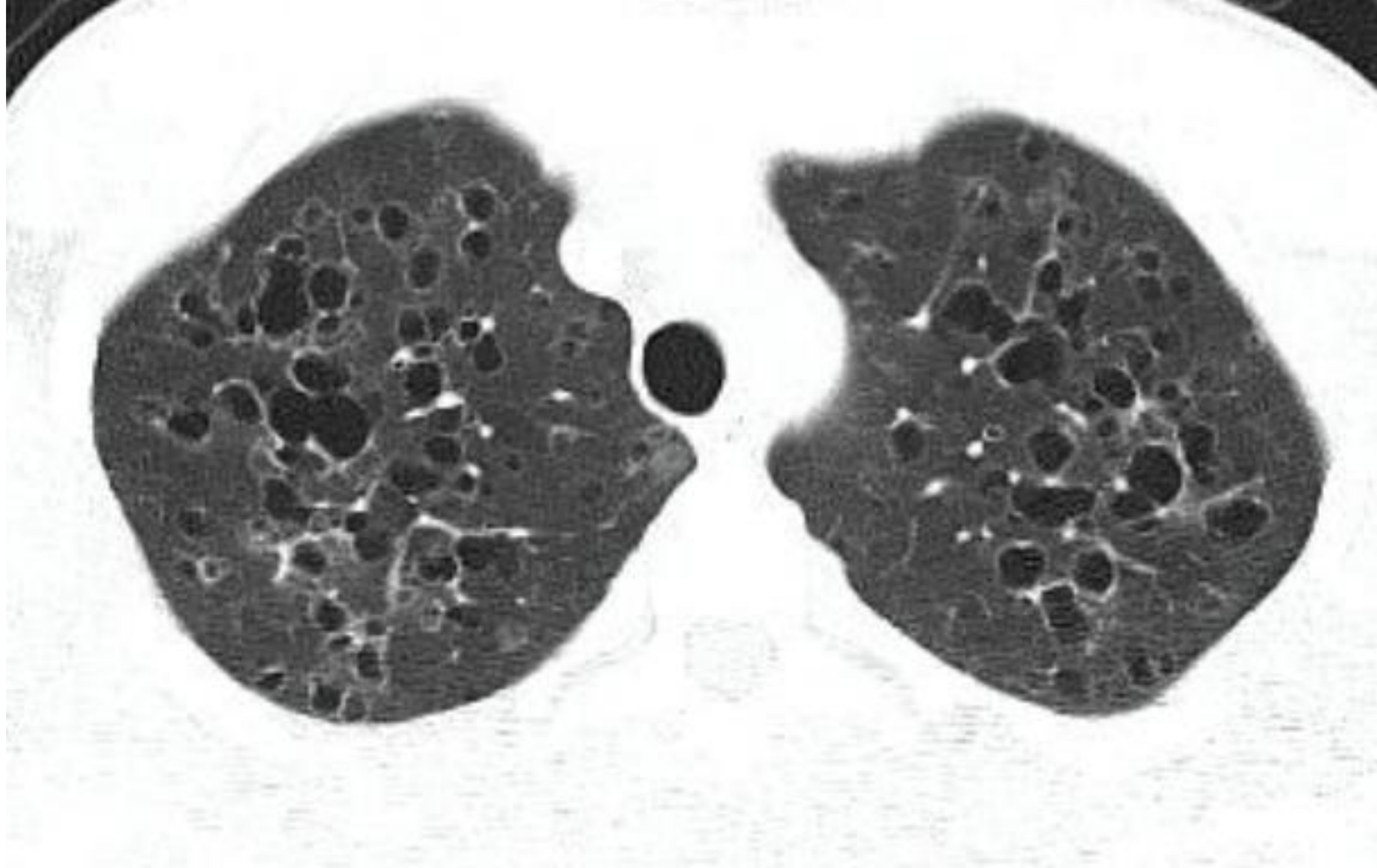
30.03.2022

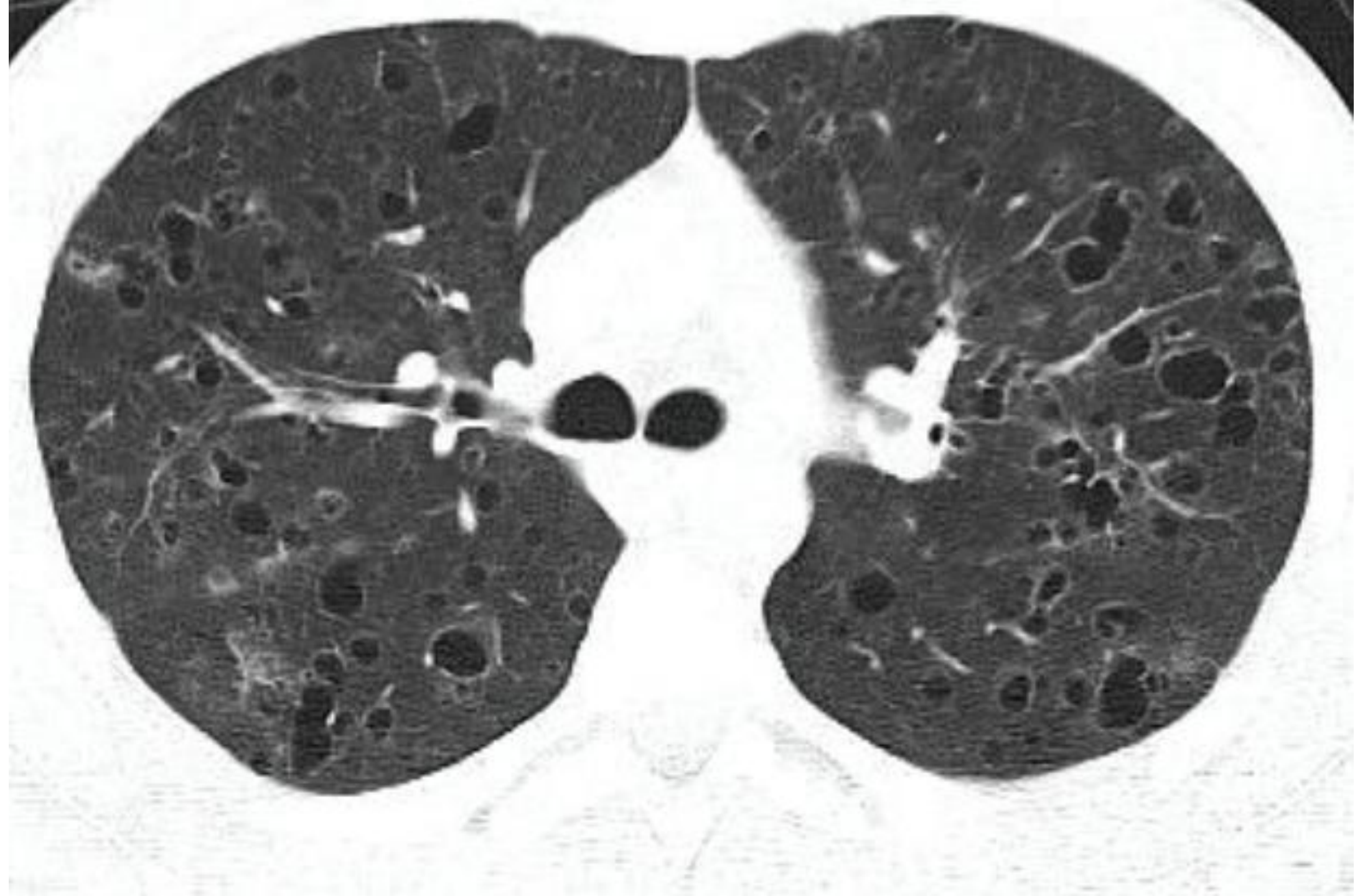

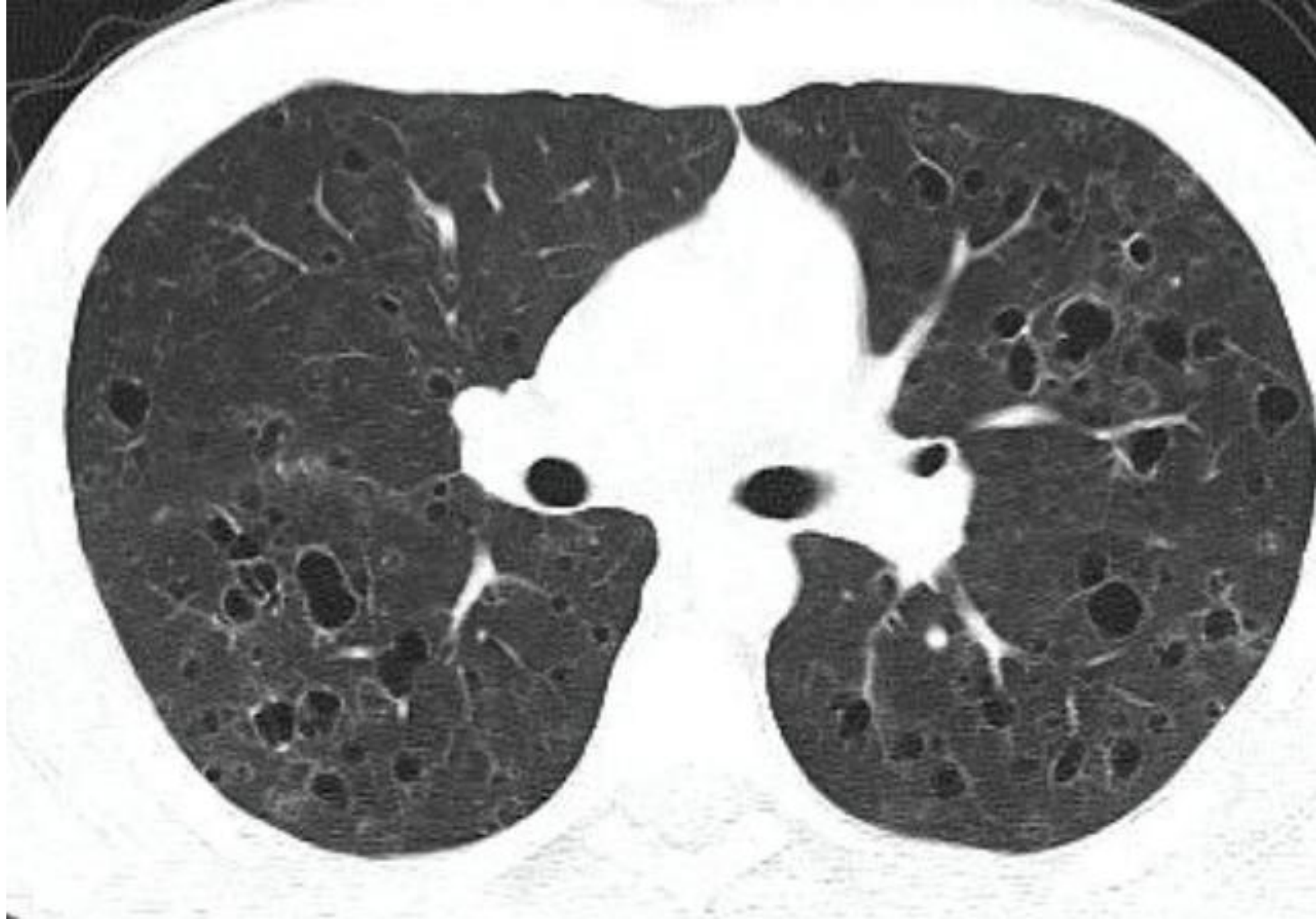MESANE CA

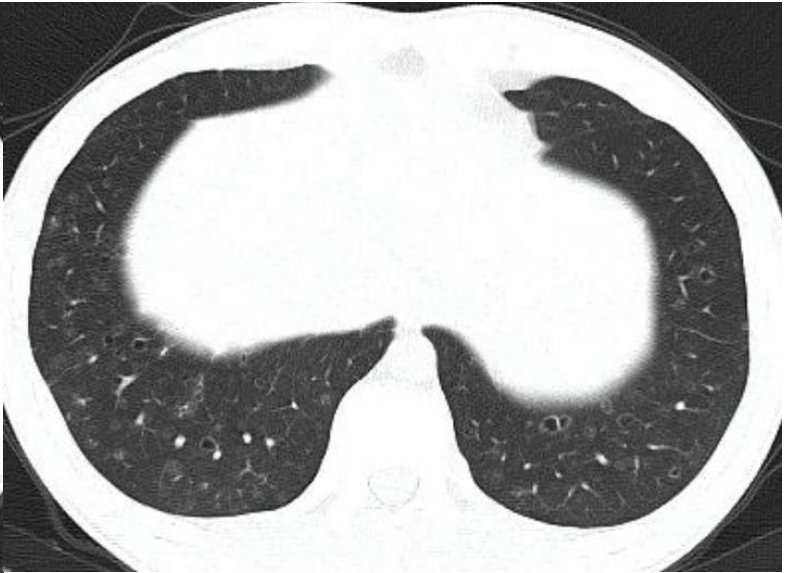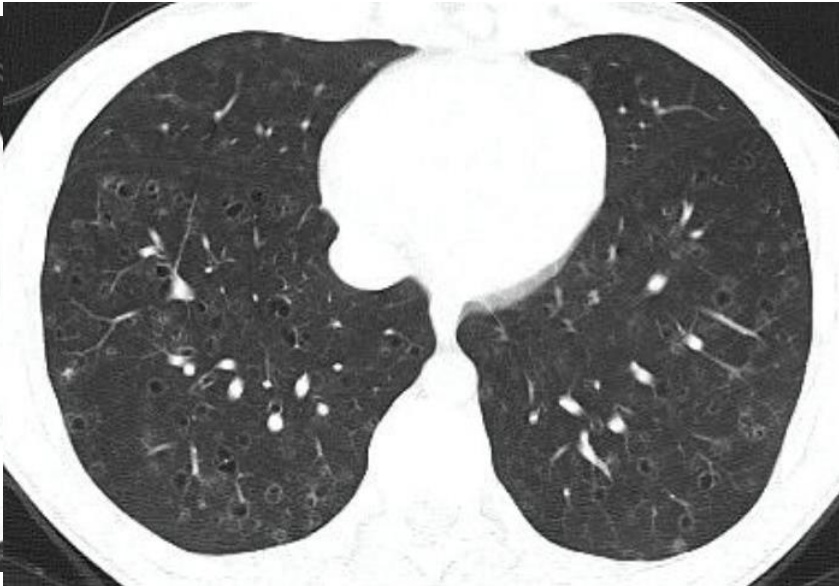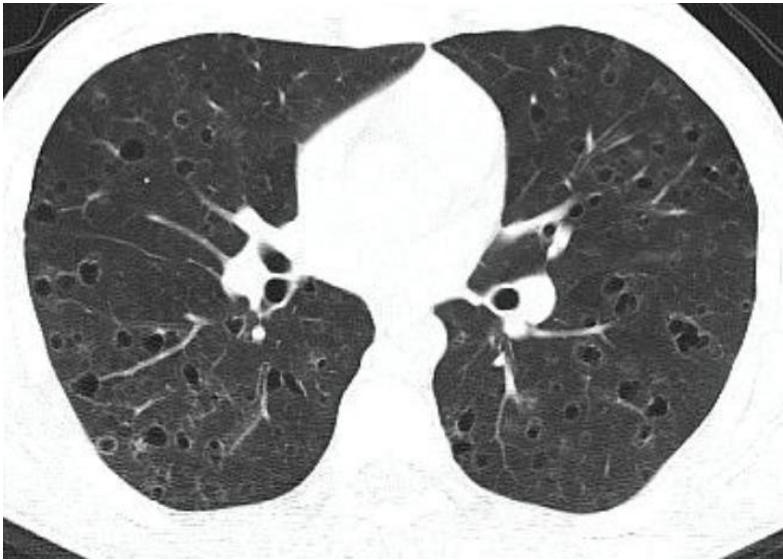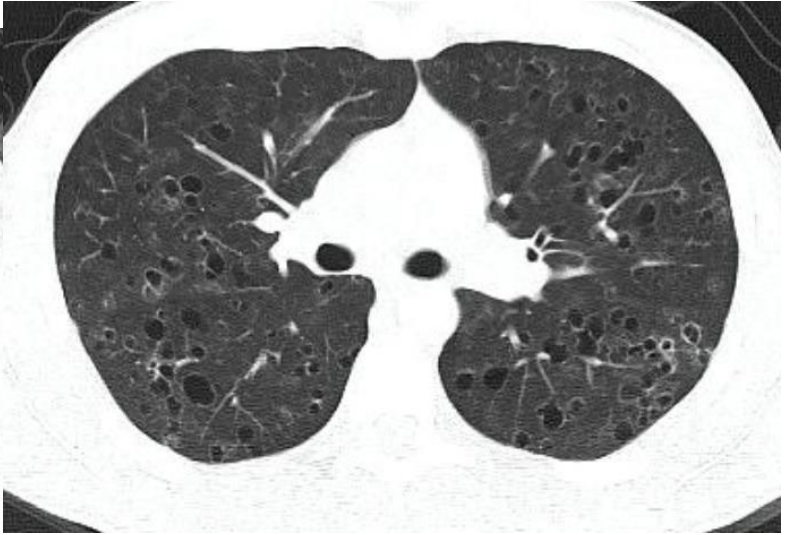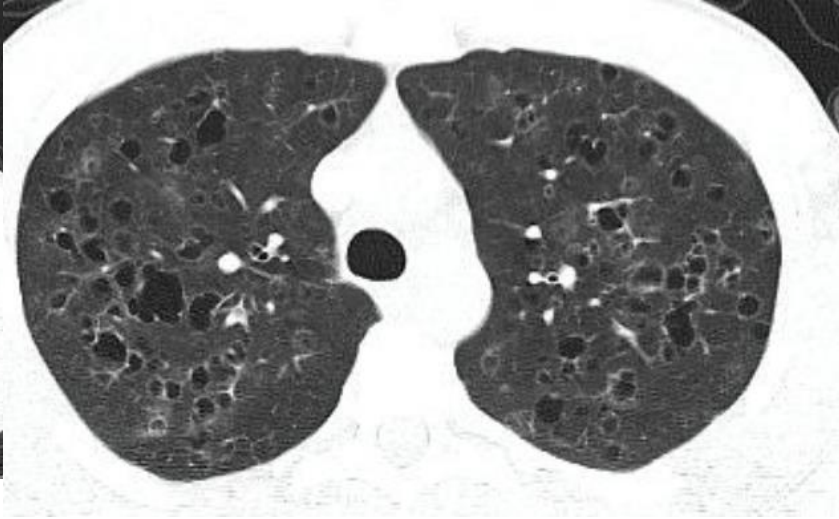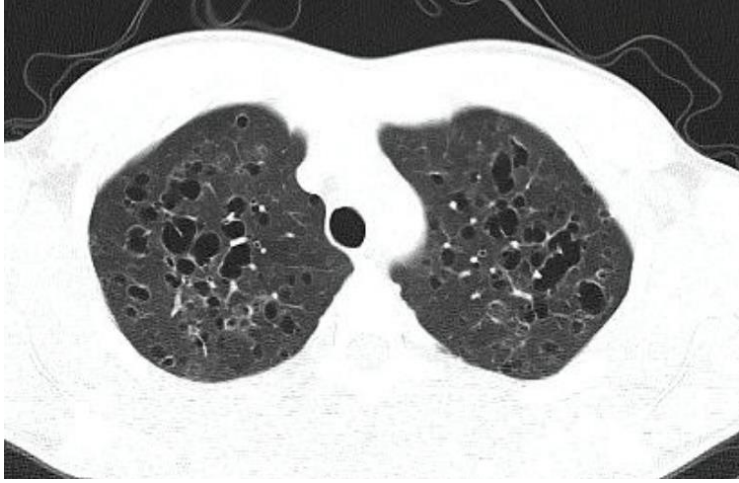


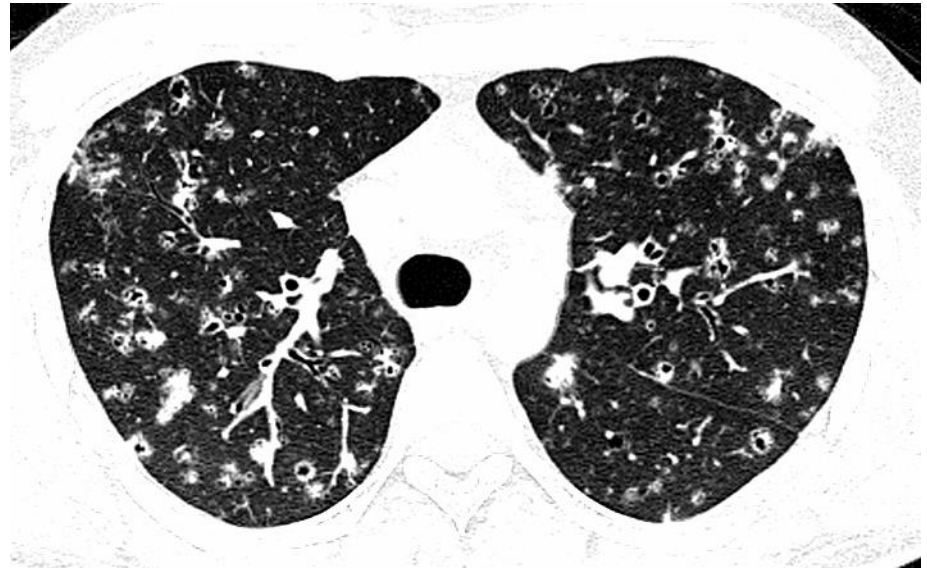
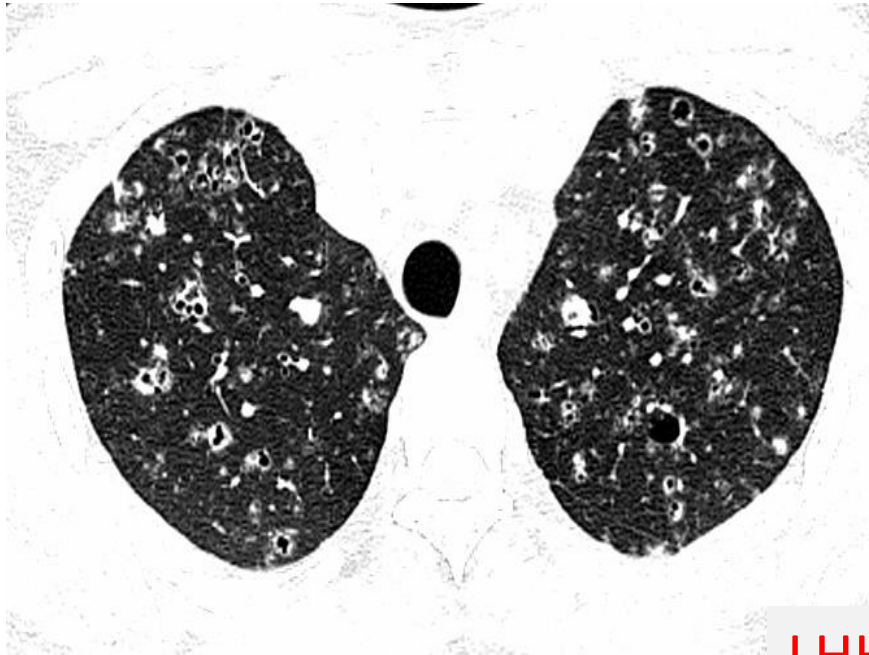




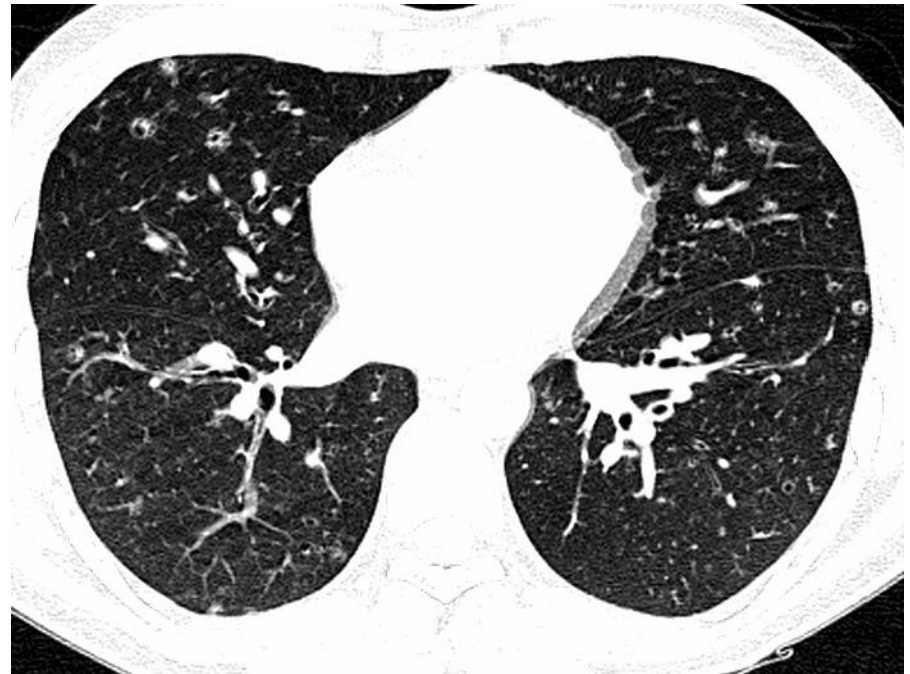


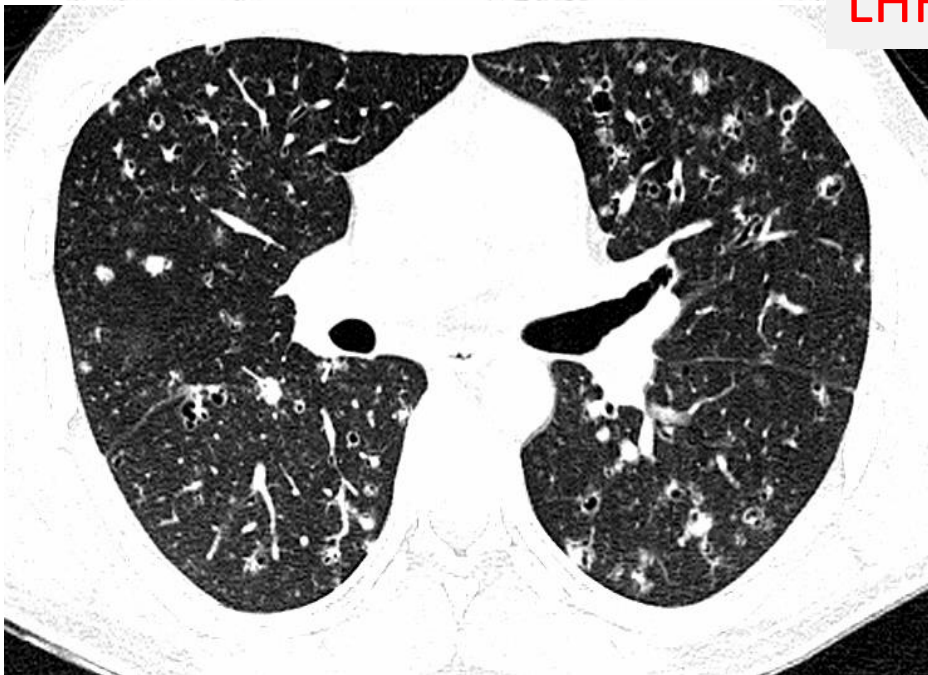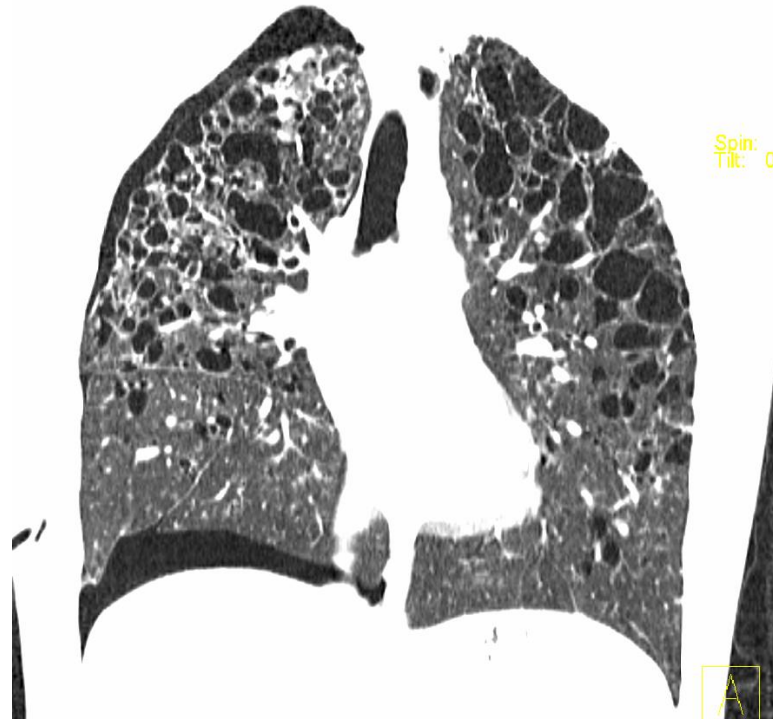
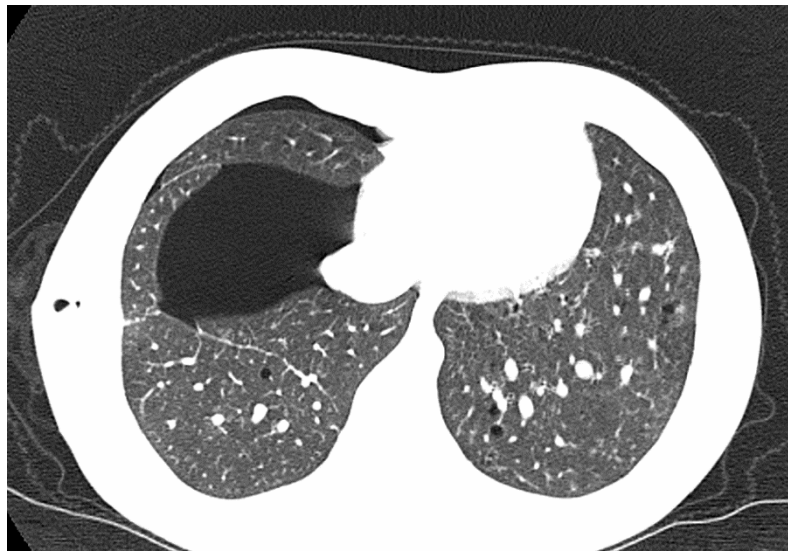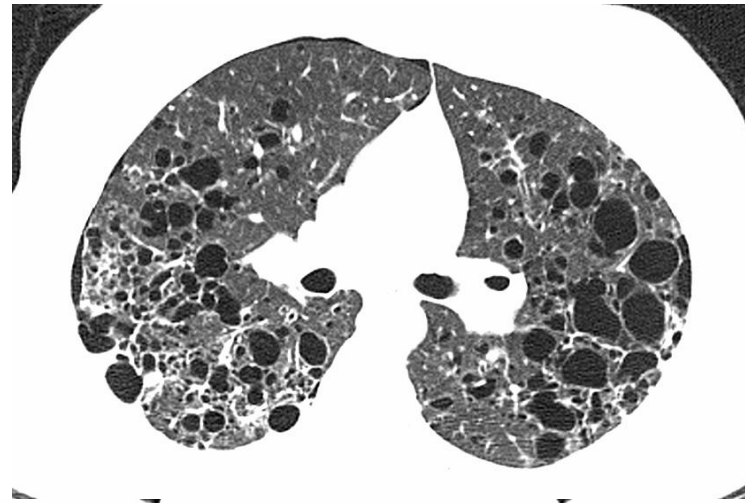
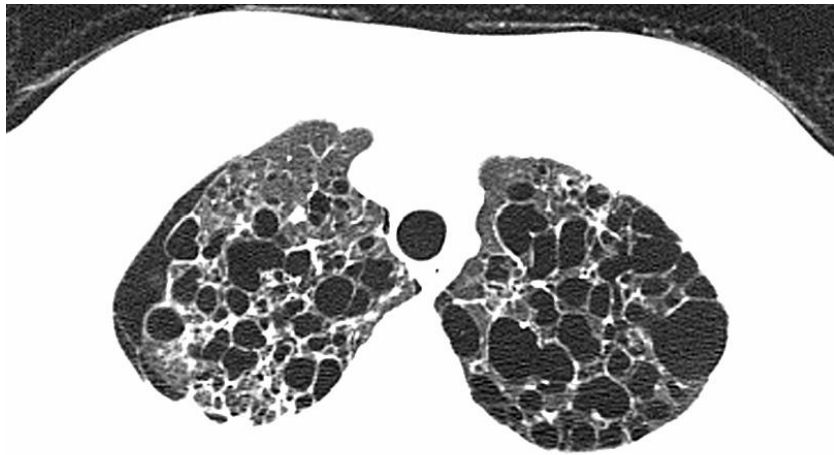






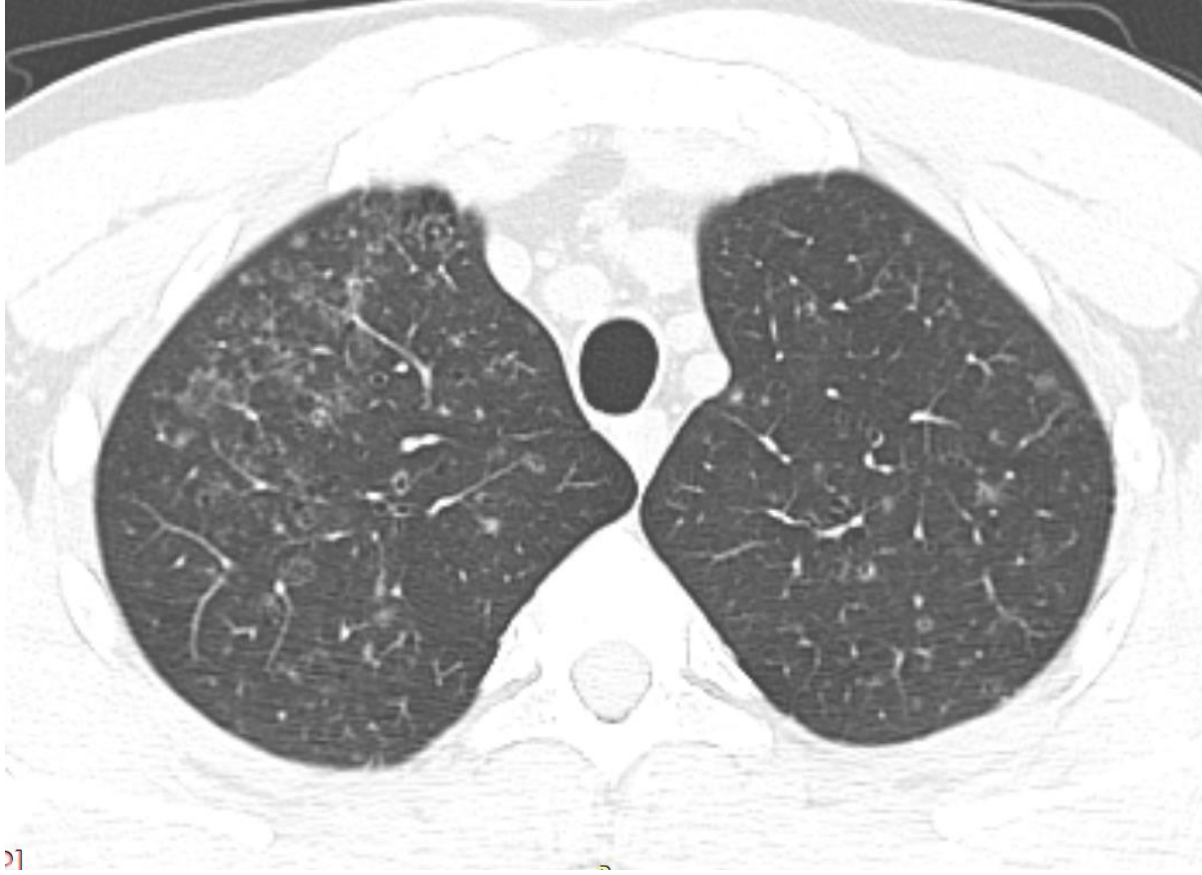LHH

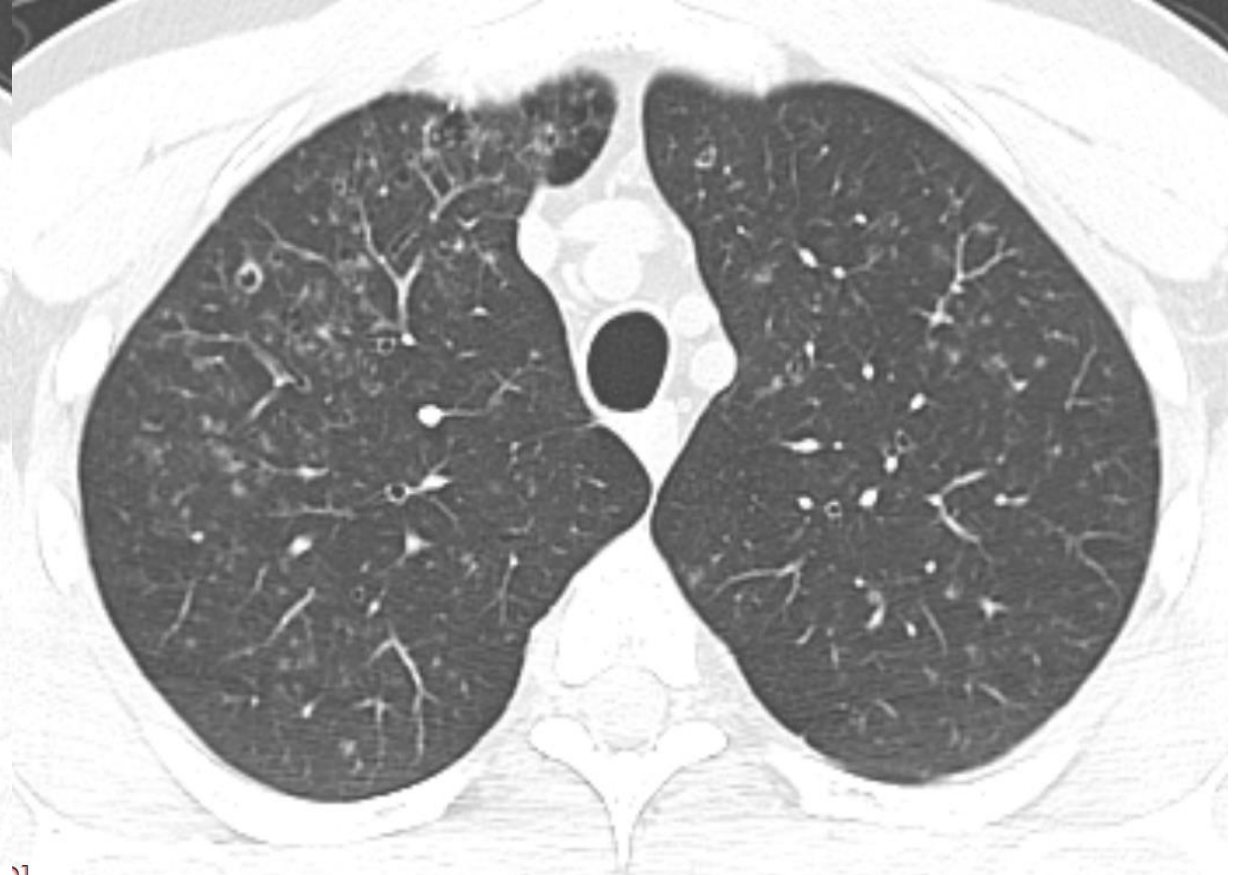



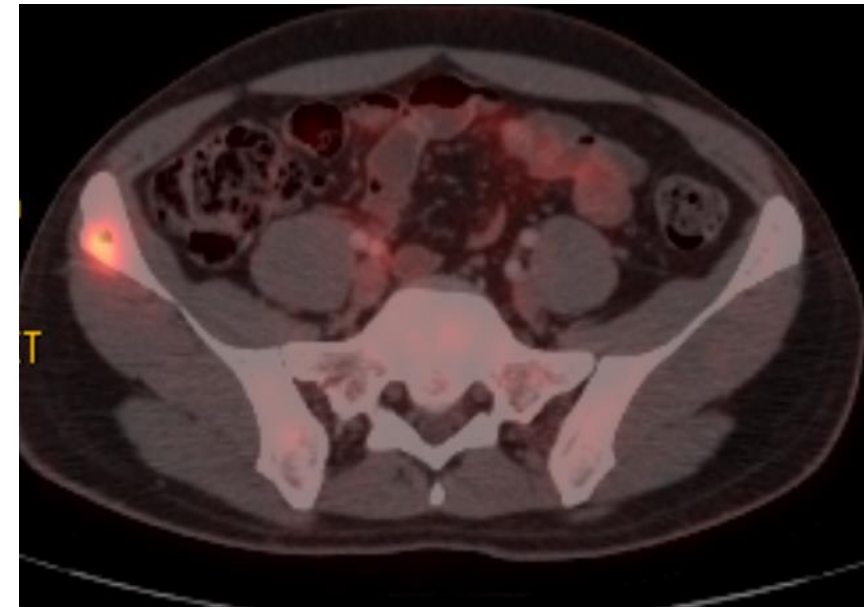
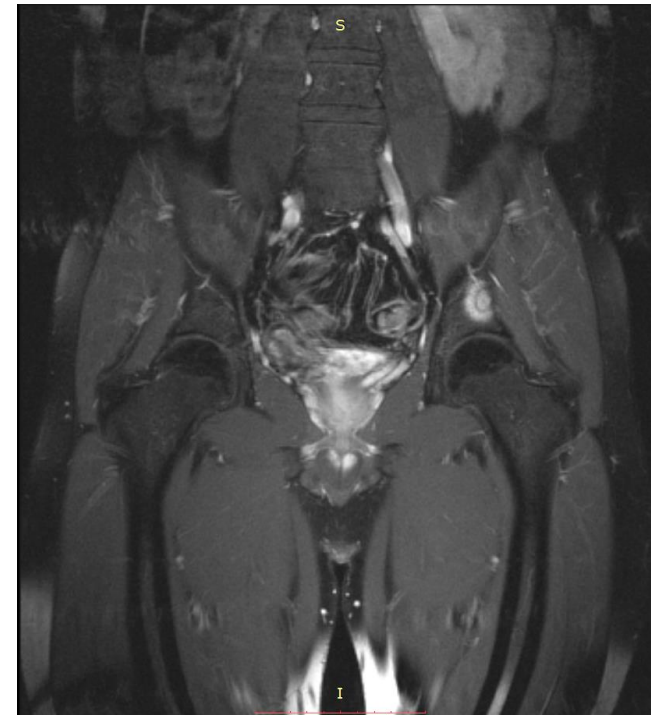
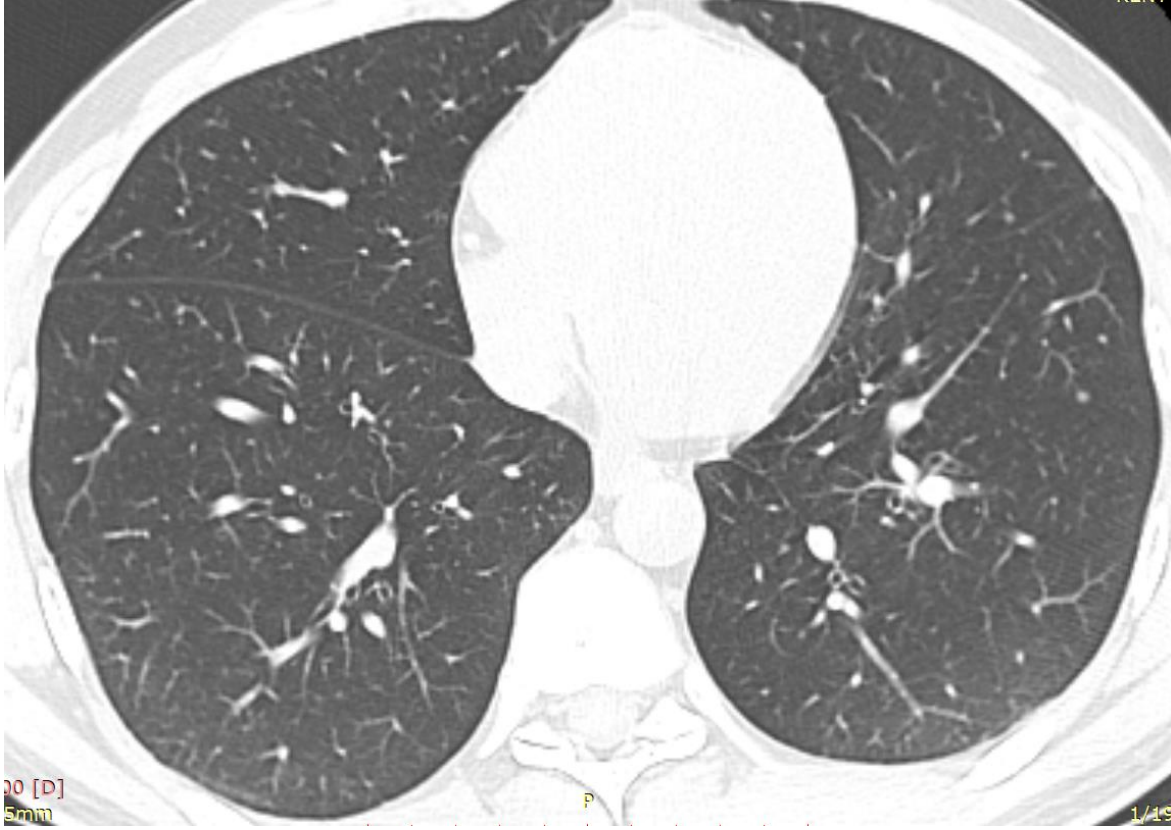
LHH



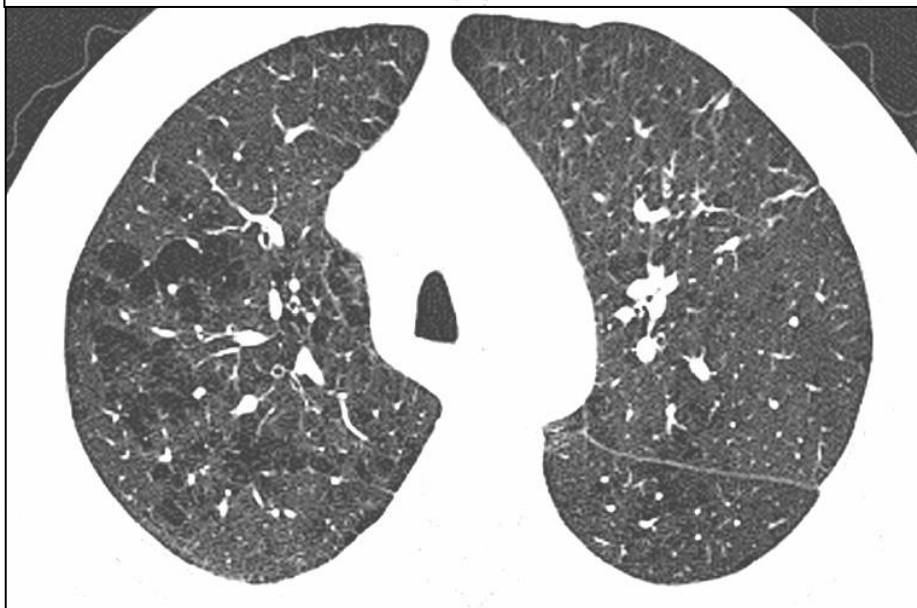
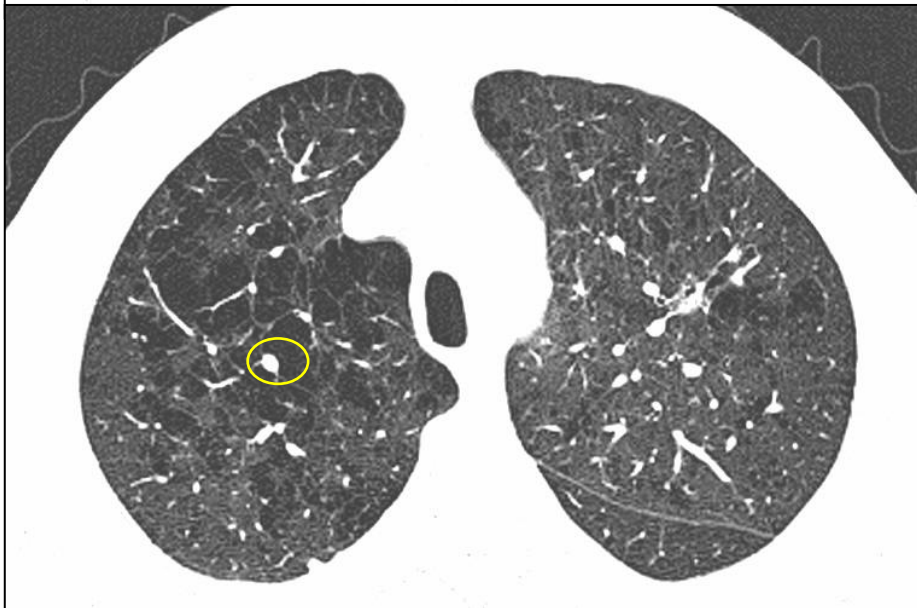
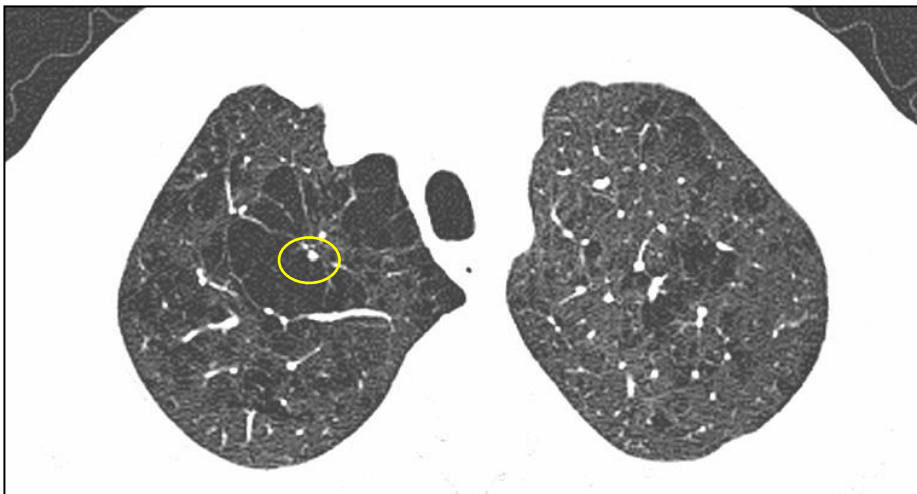
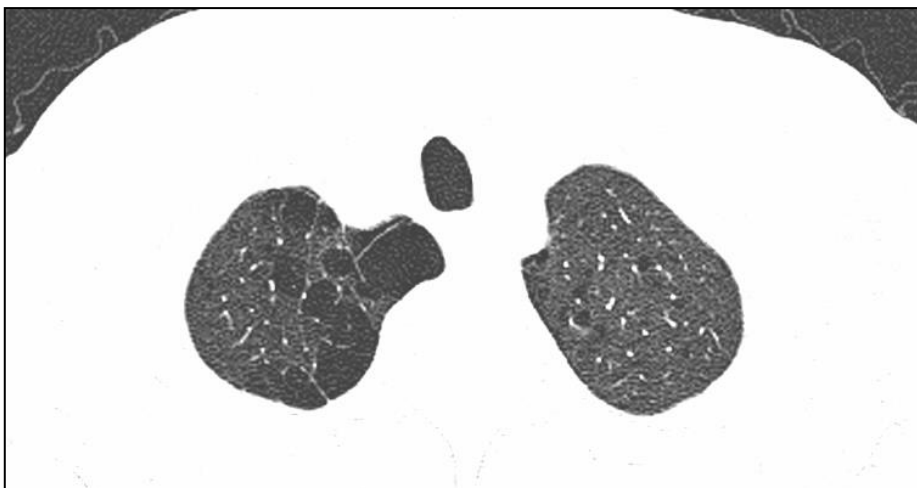
21

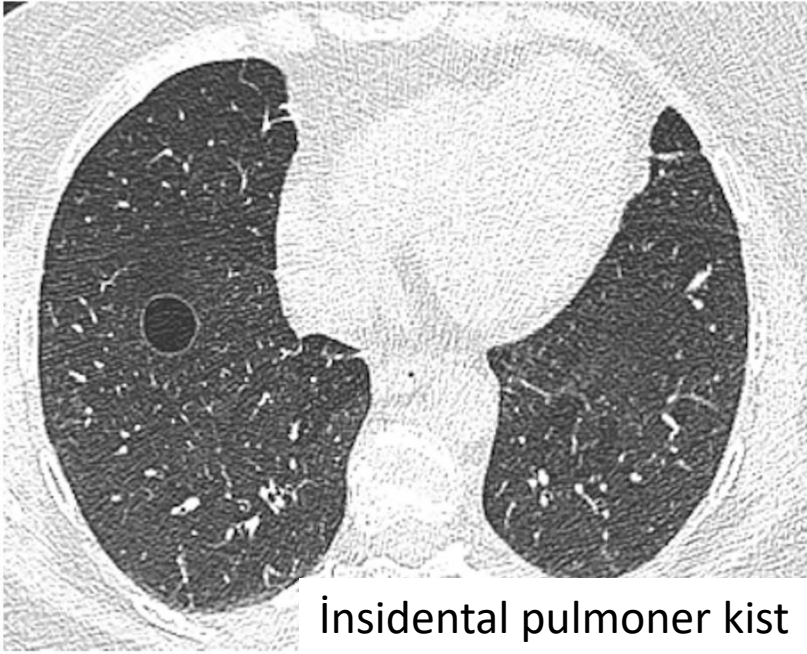


21

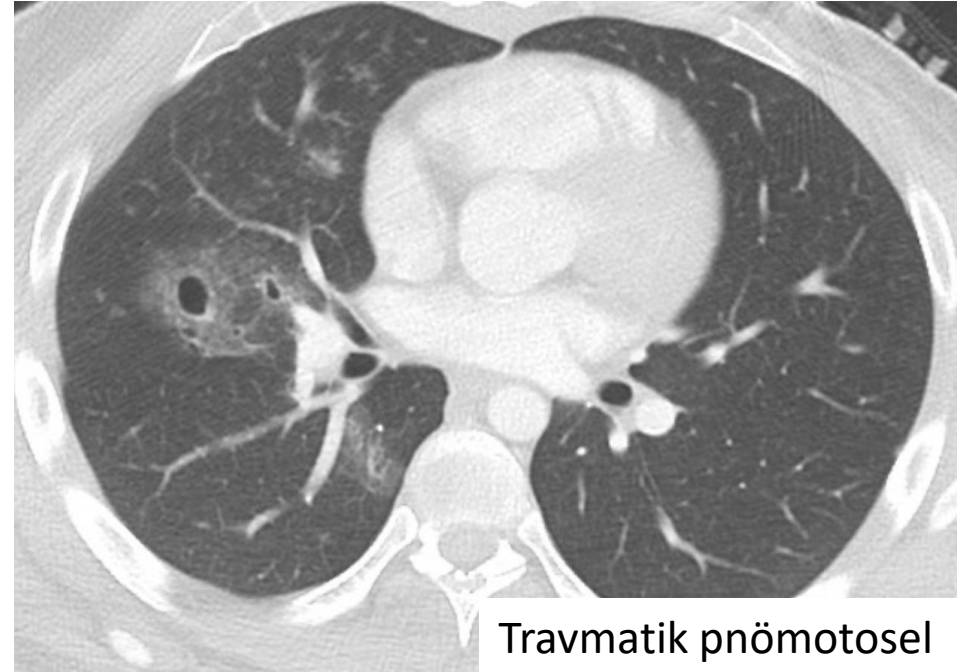


LANGERHANS HÜCRELİ HİSTİYOSİTOZ

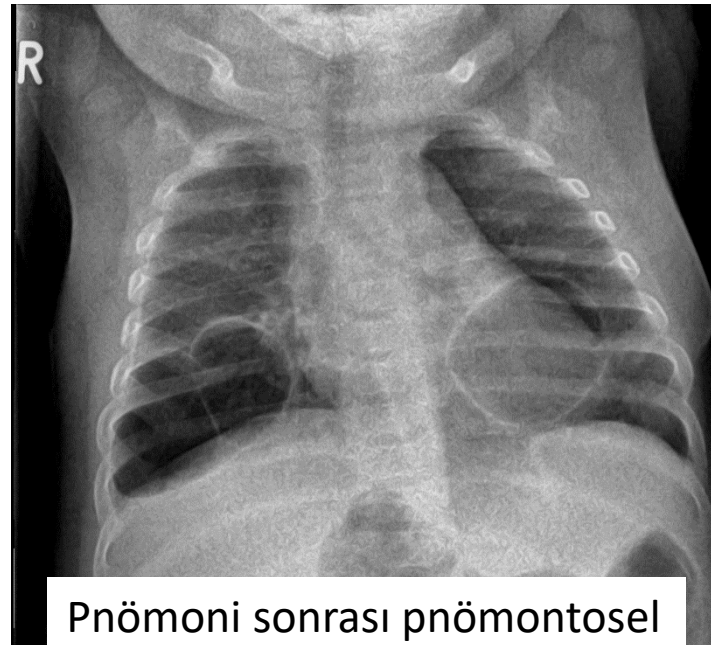




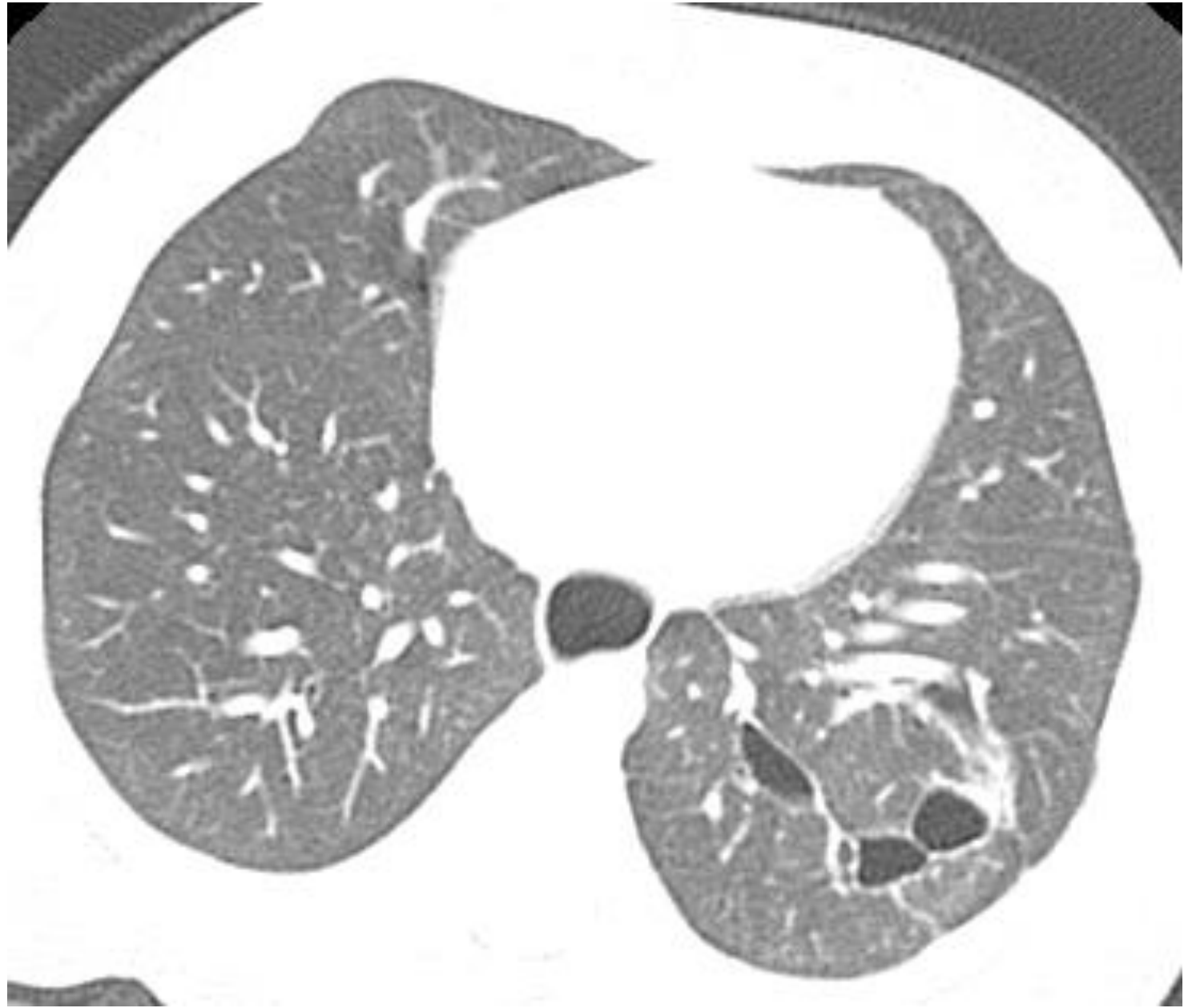İnsidental pulmoner kist

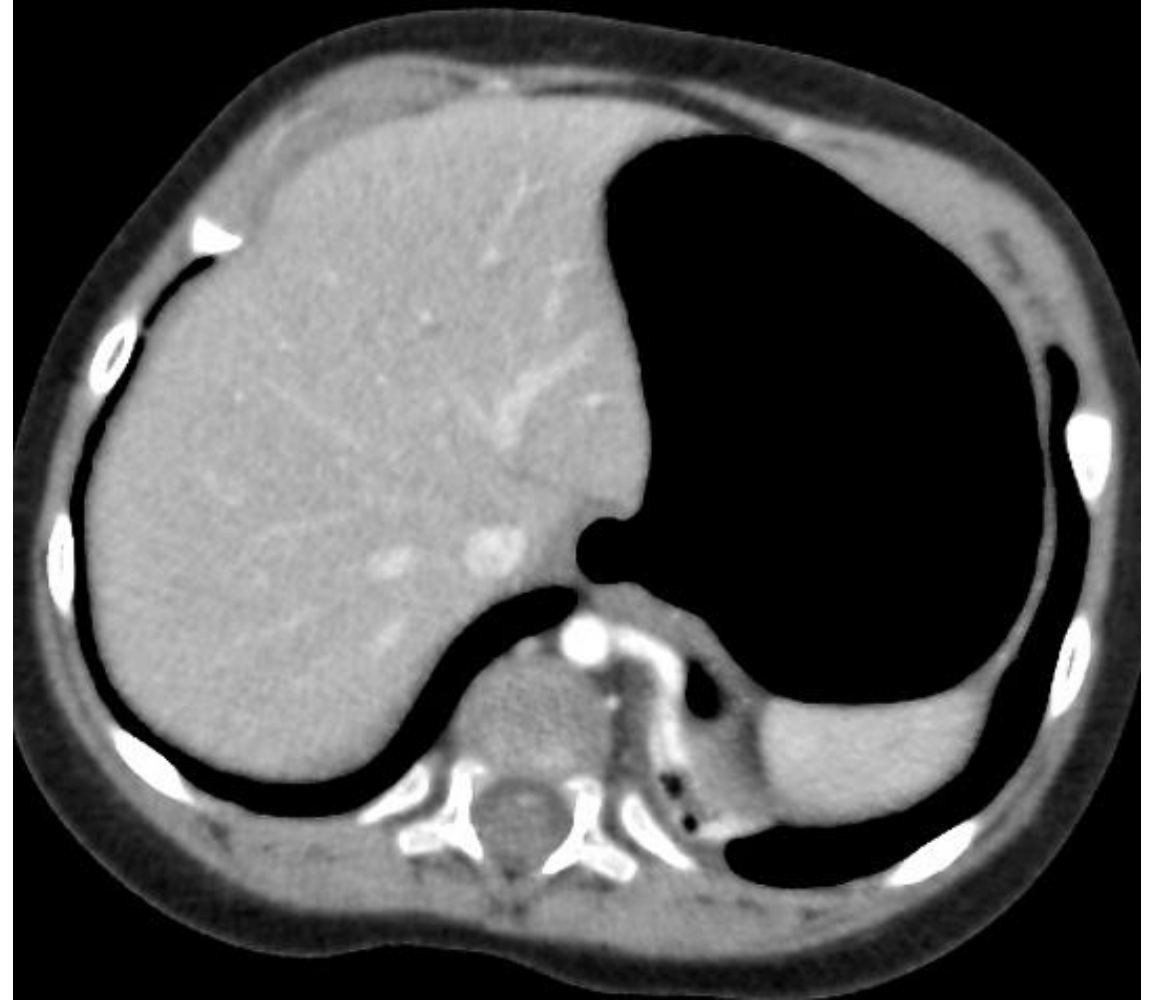
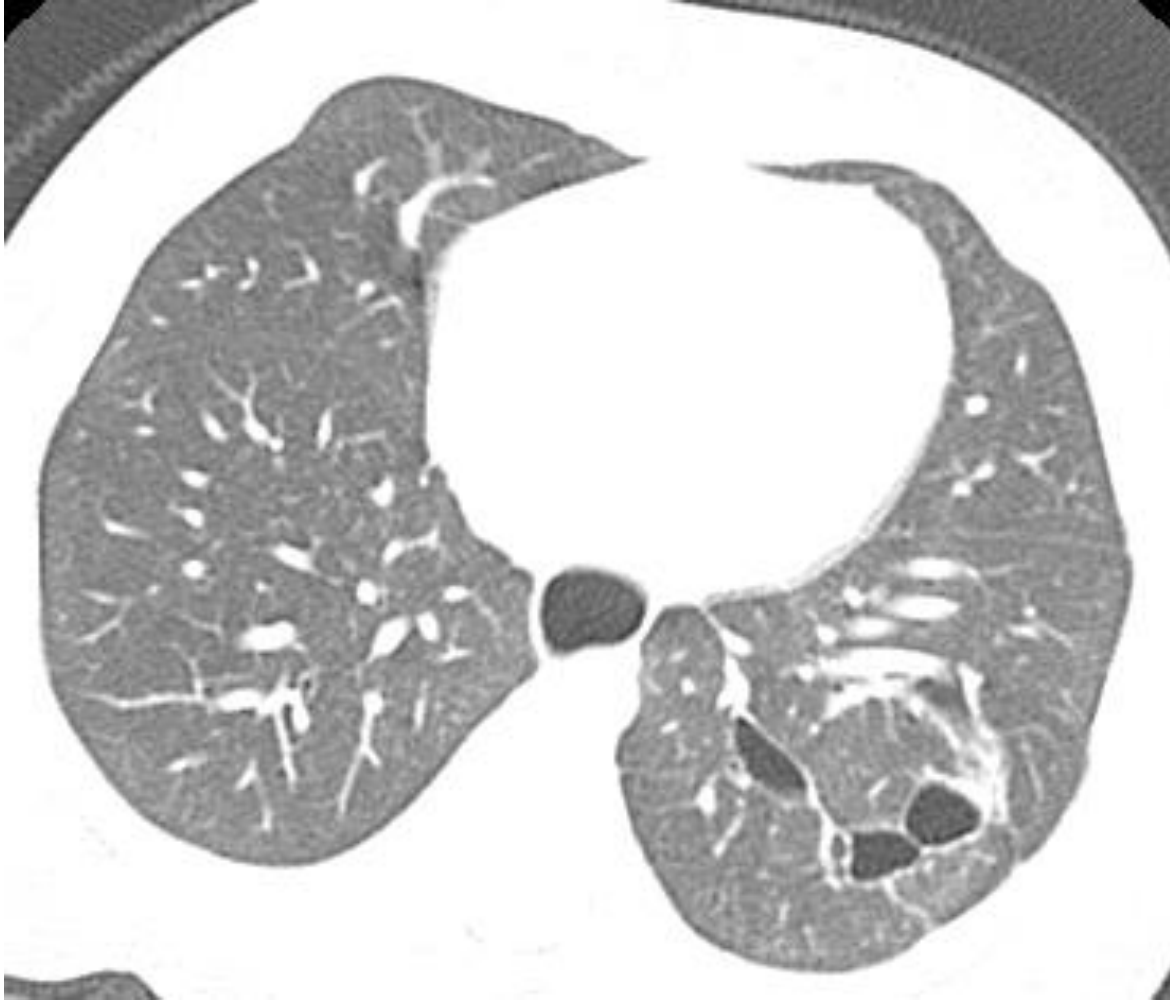
Travmatik pnömosel

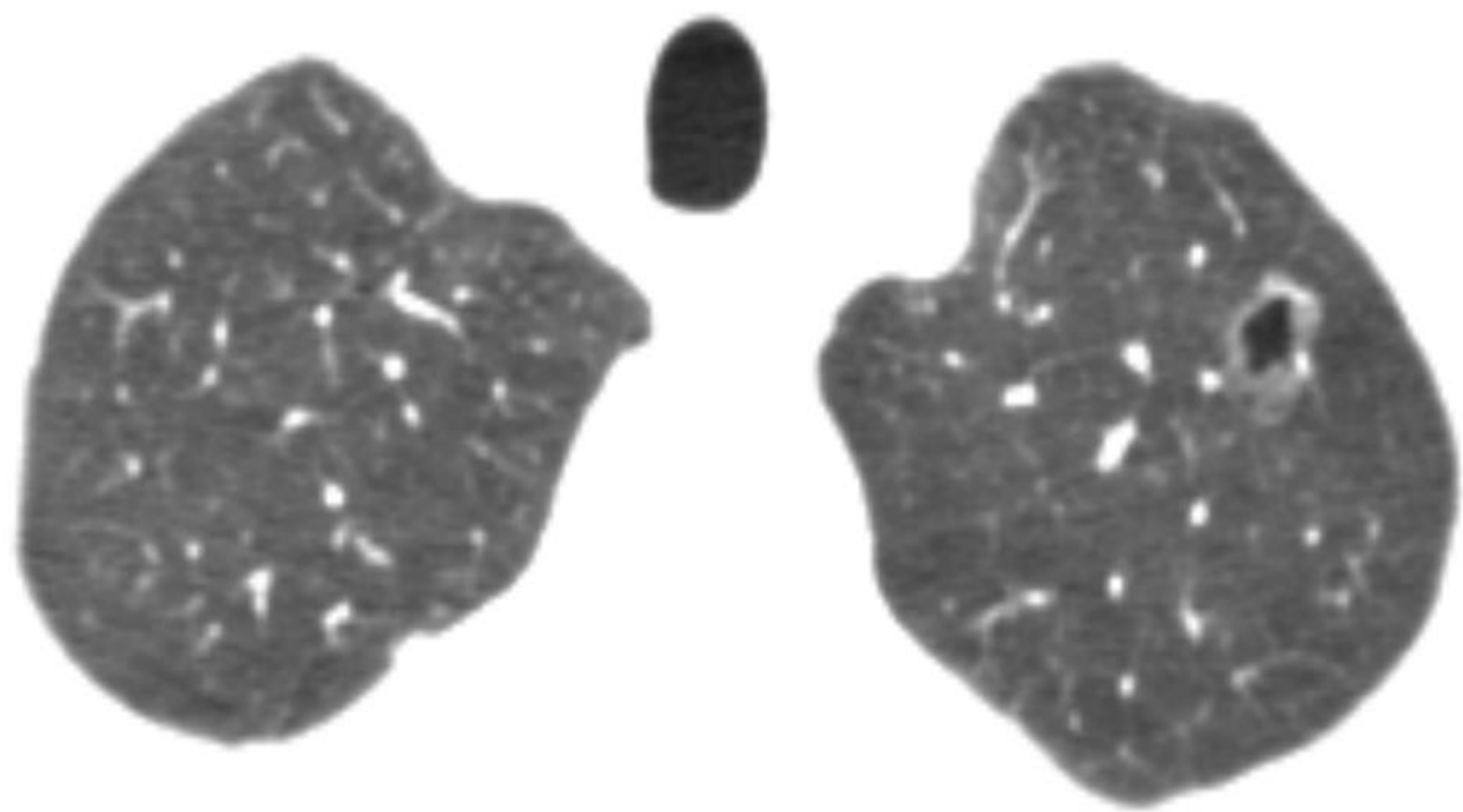



Pnömoni sonrası pnömotosel

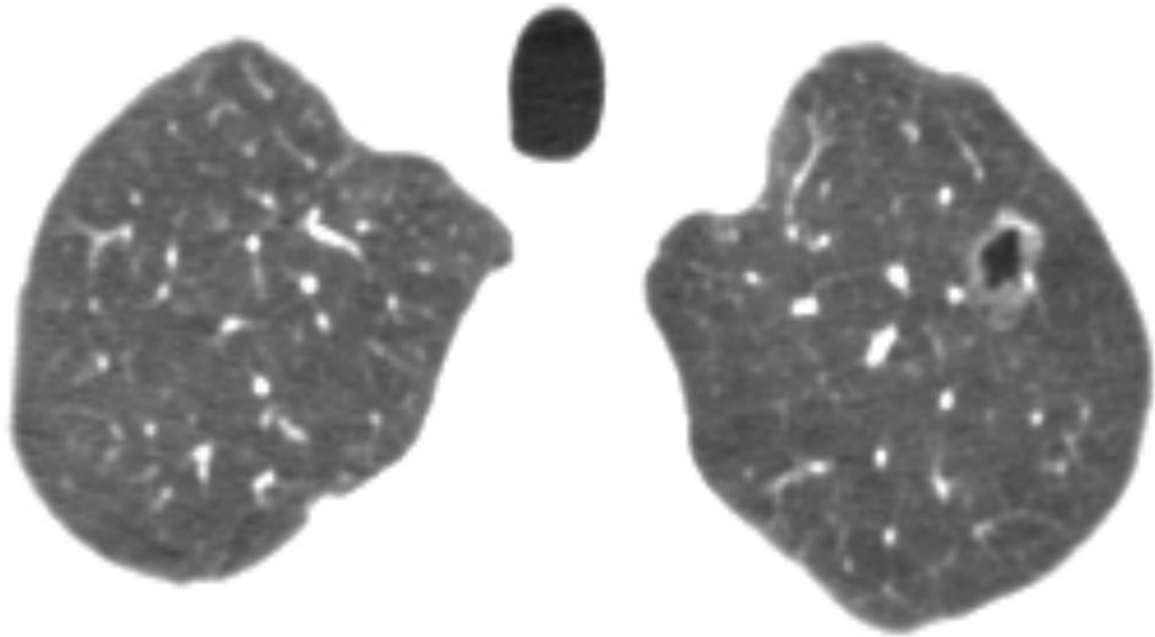




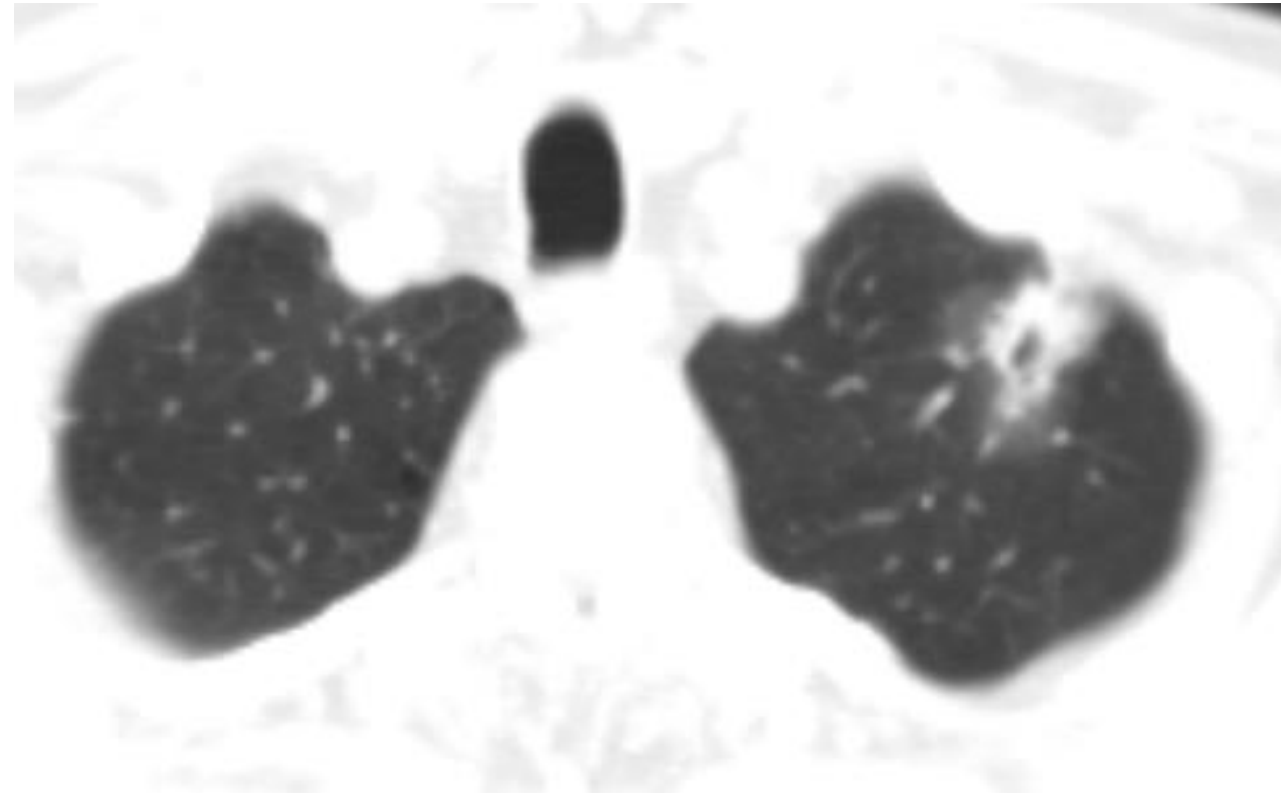
SEKESTRASYON



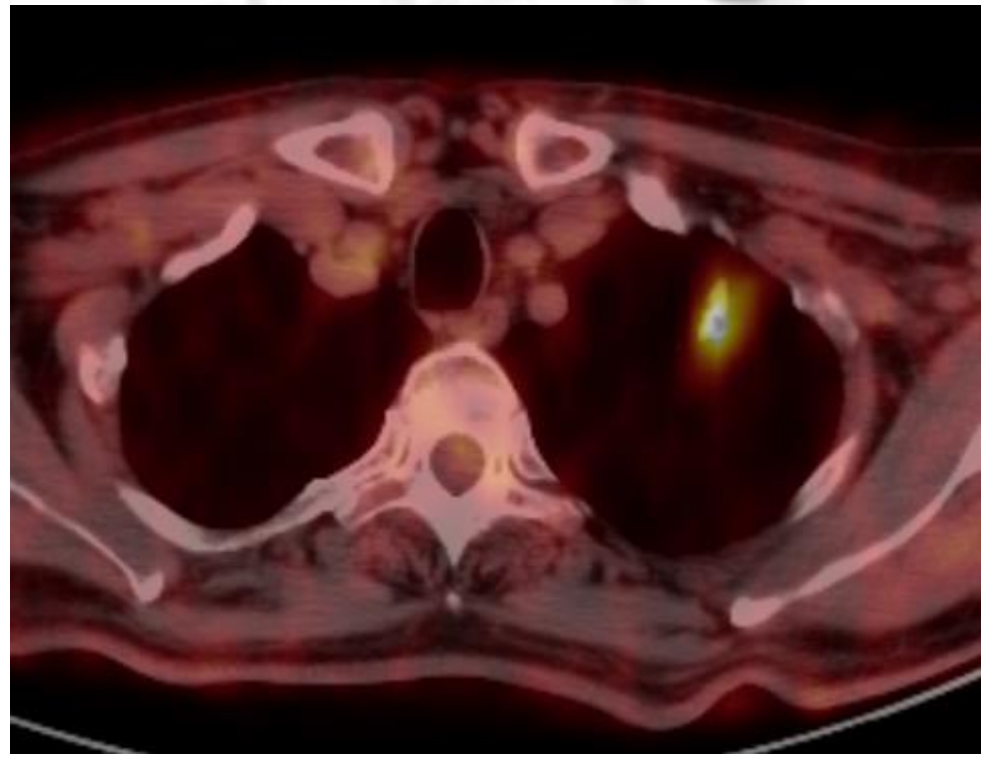
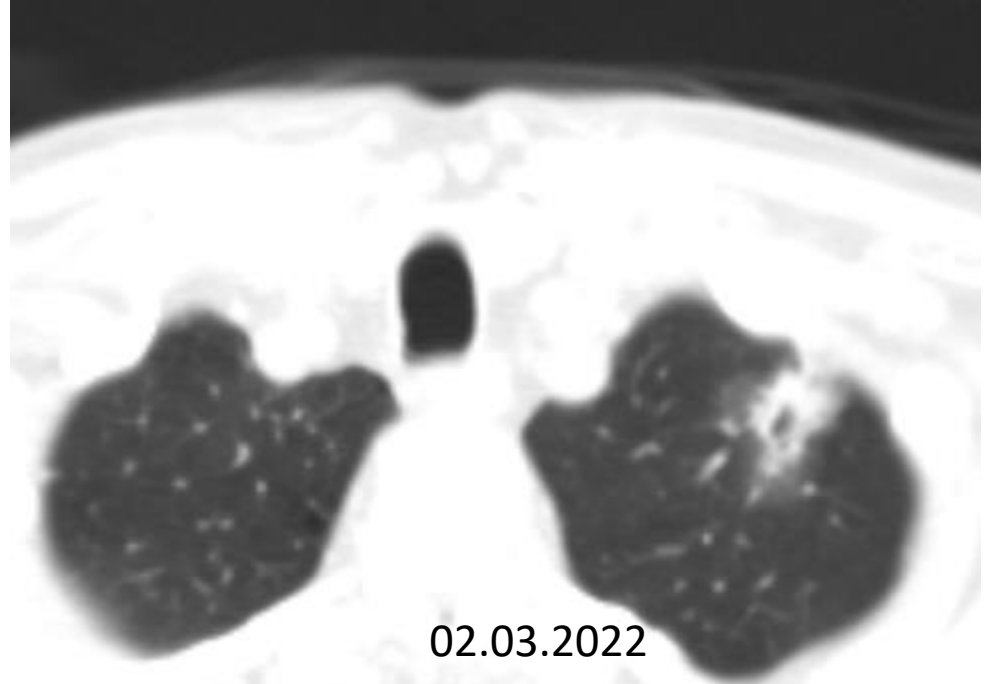
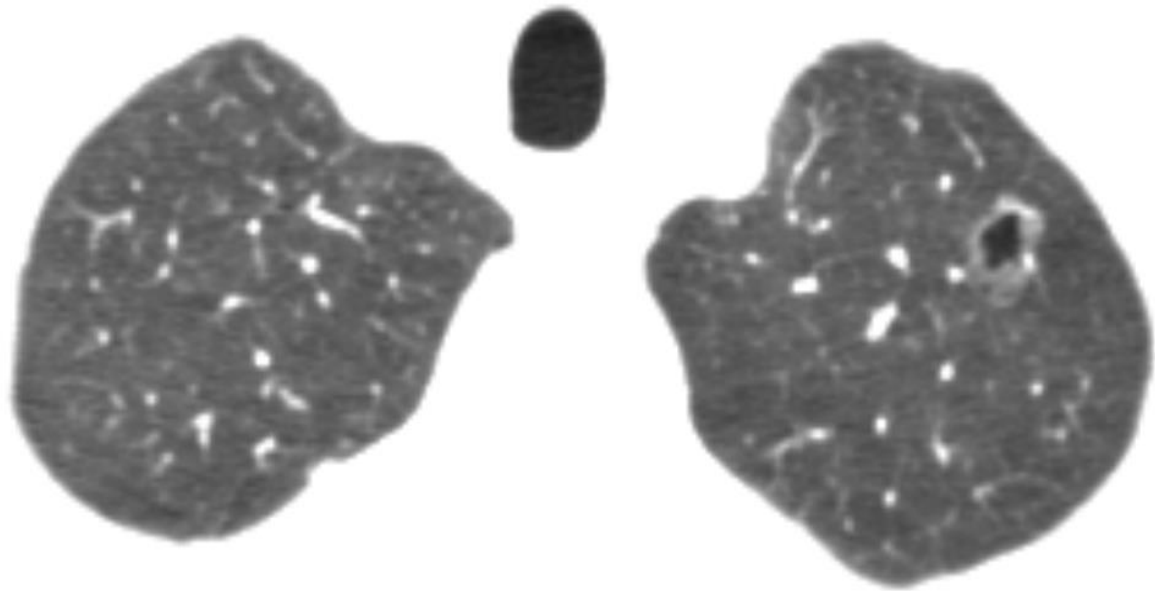




17.12.2009



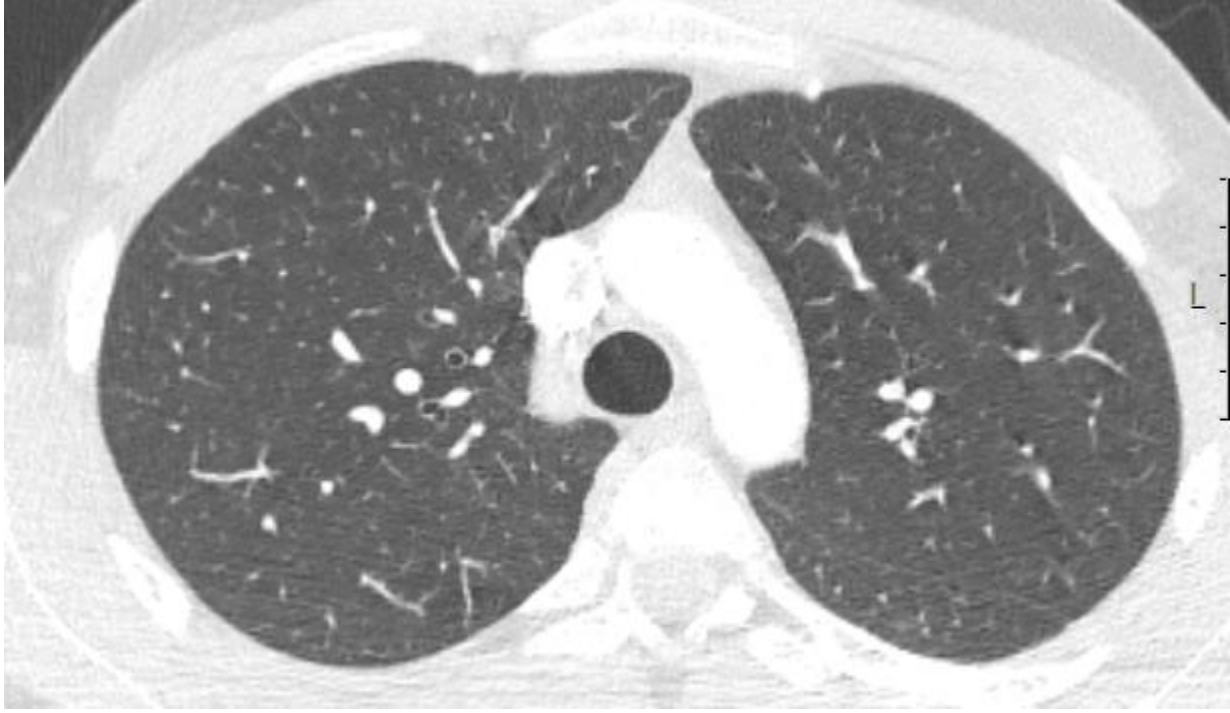02.03.2022



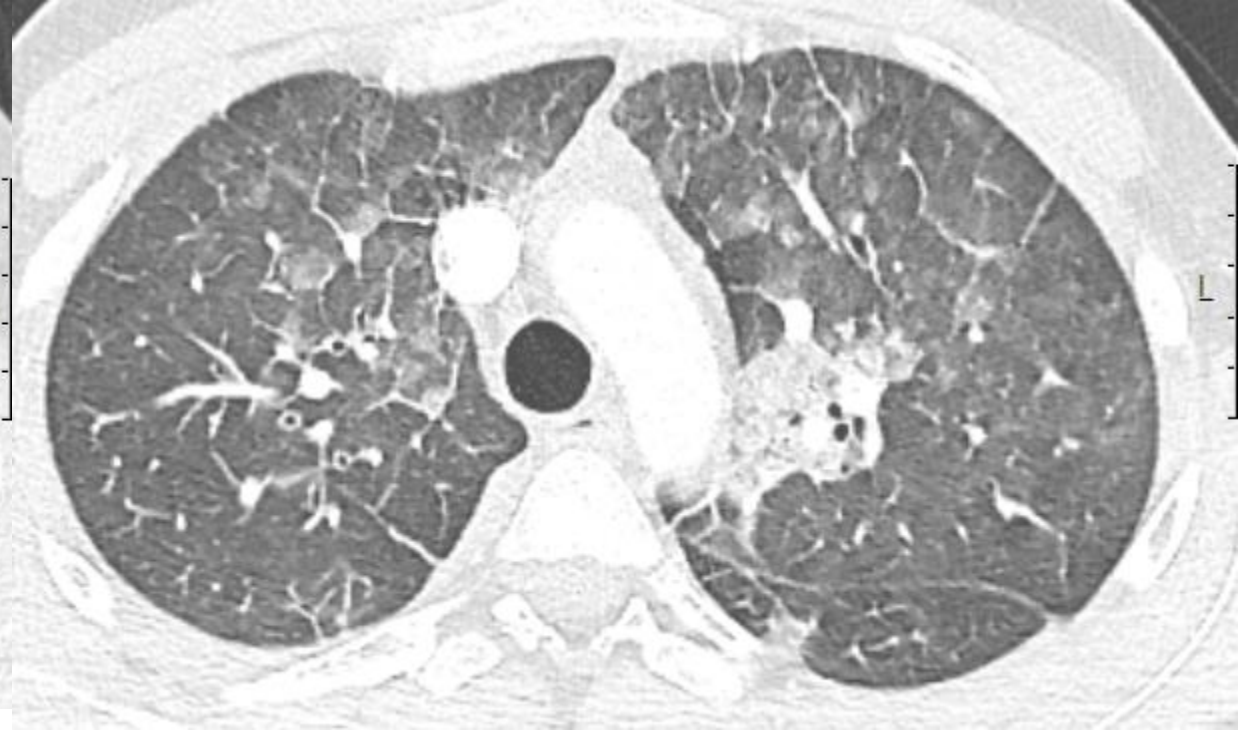
TEŞEKKÜRLER

18 Y E, AML hastası

Dispne başlamış. Fungal pnömoni? PE?)



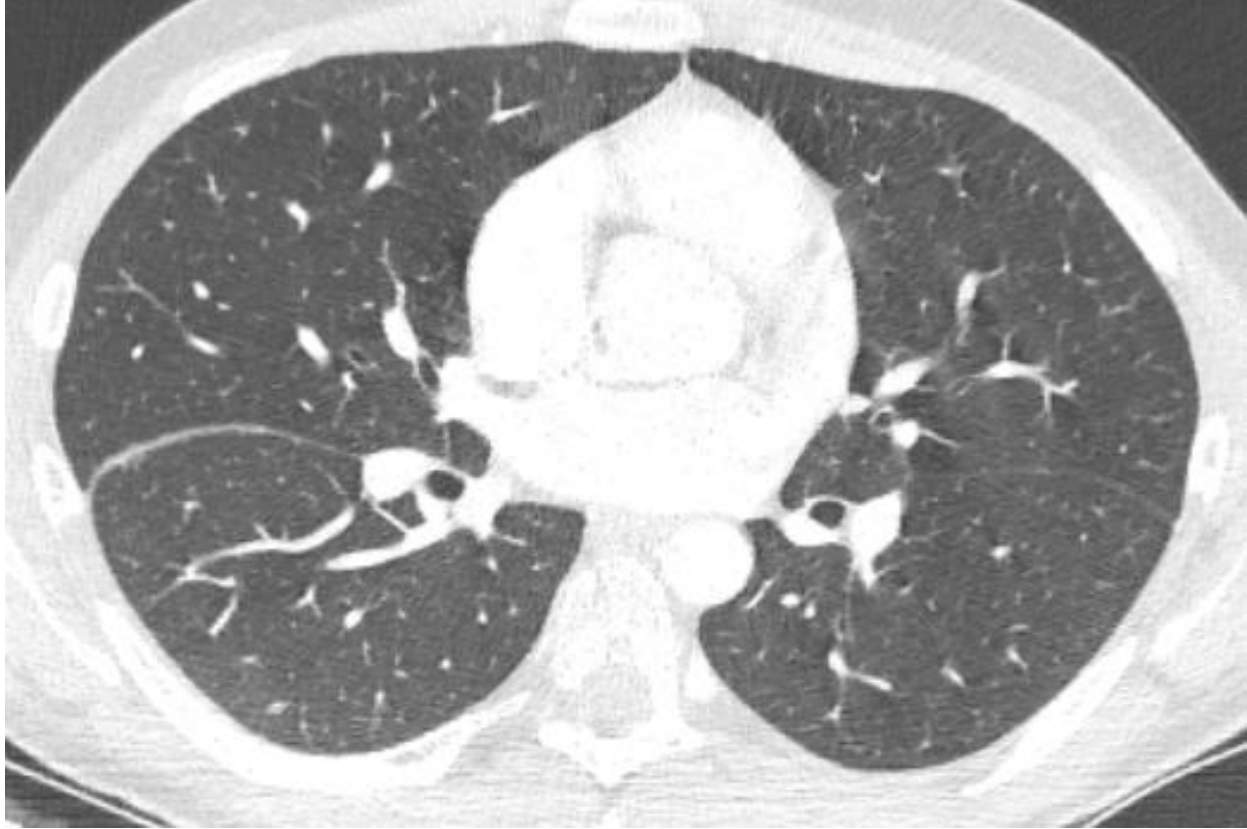10.09.2021



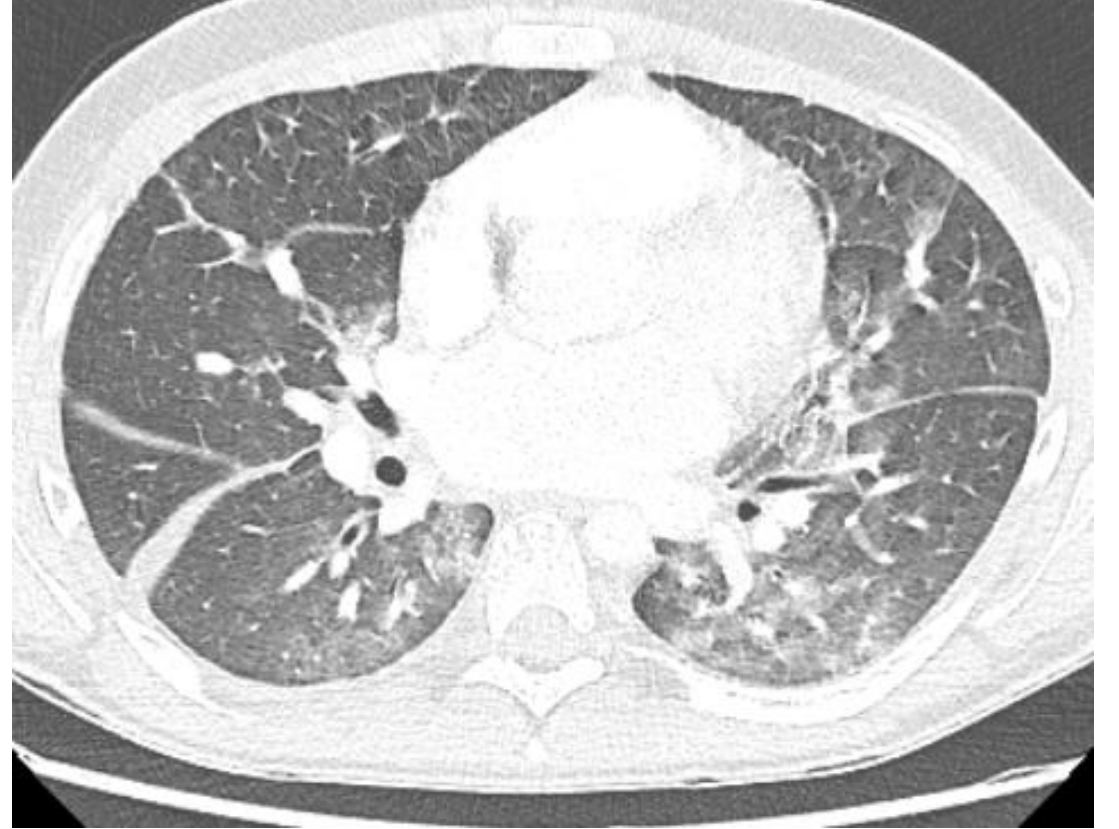17.09.2021

18 Y E, AML hastası

Dispne başlamış. Fungal pnömoni? PE?)



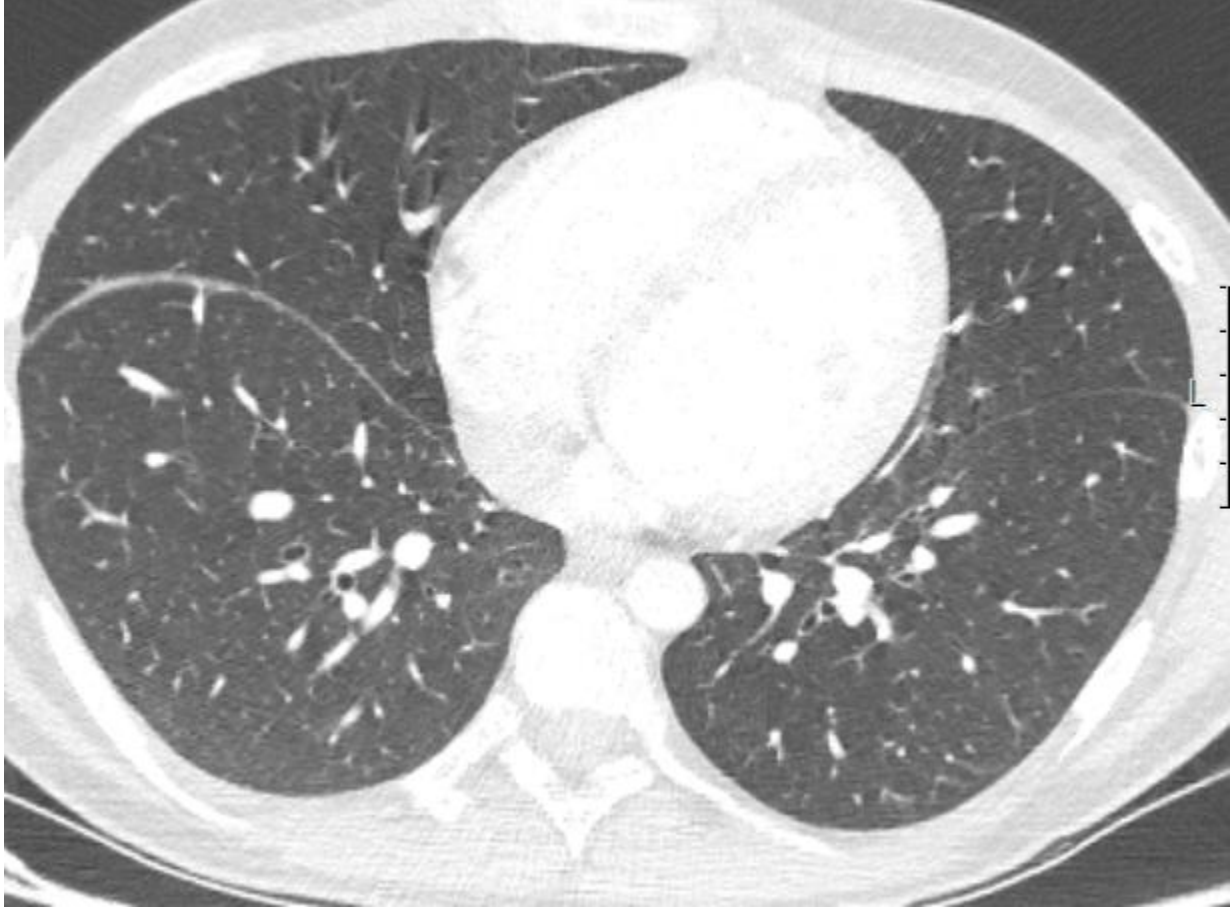
10.09.2021



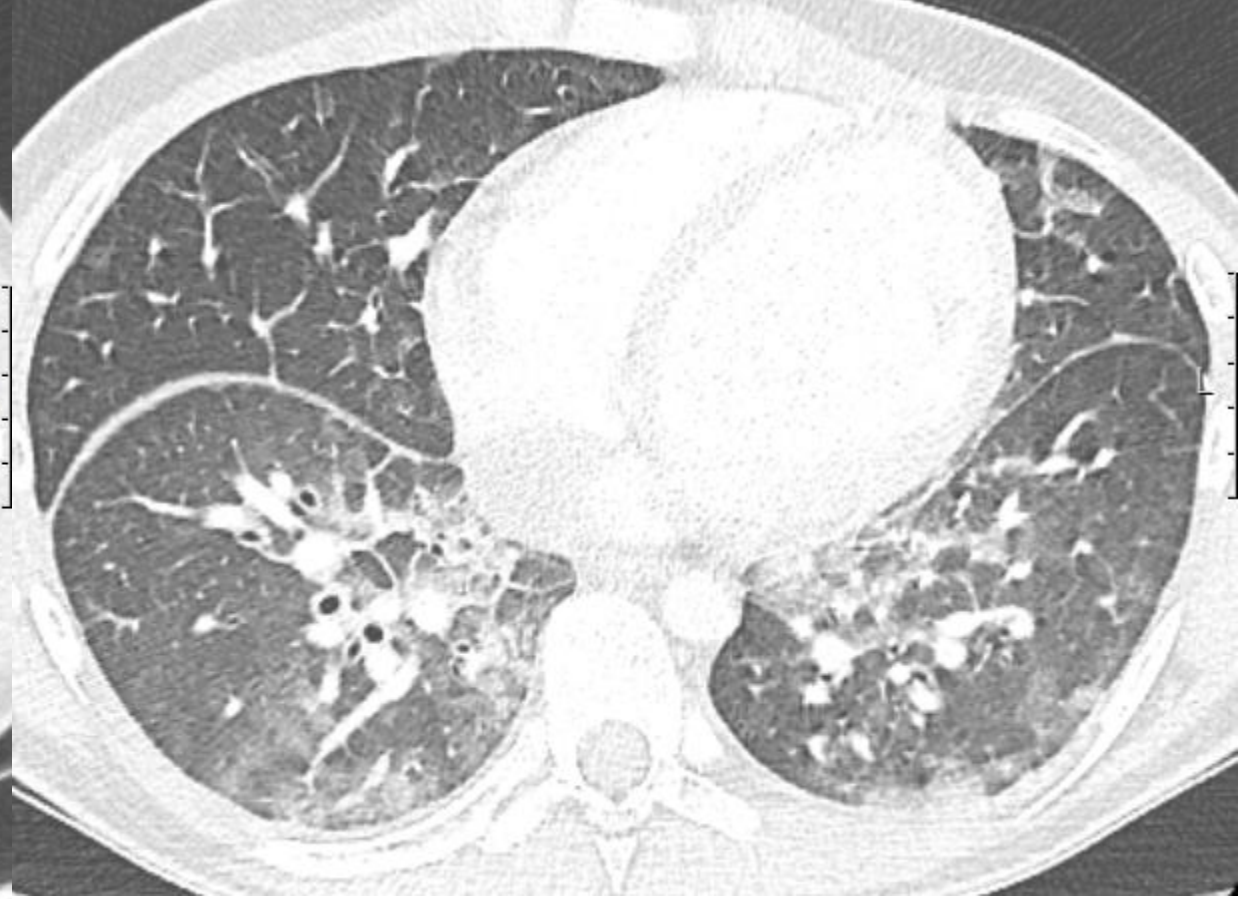17.09.2021

18 Y E, AML hastası

Dispne başlamış. Fungal pnömoni? PE?)



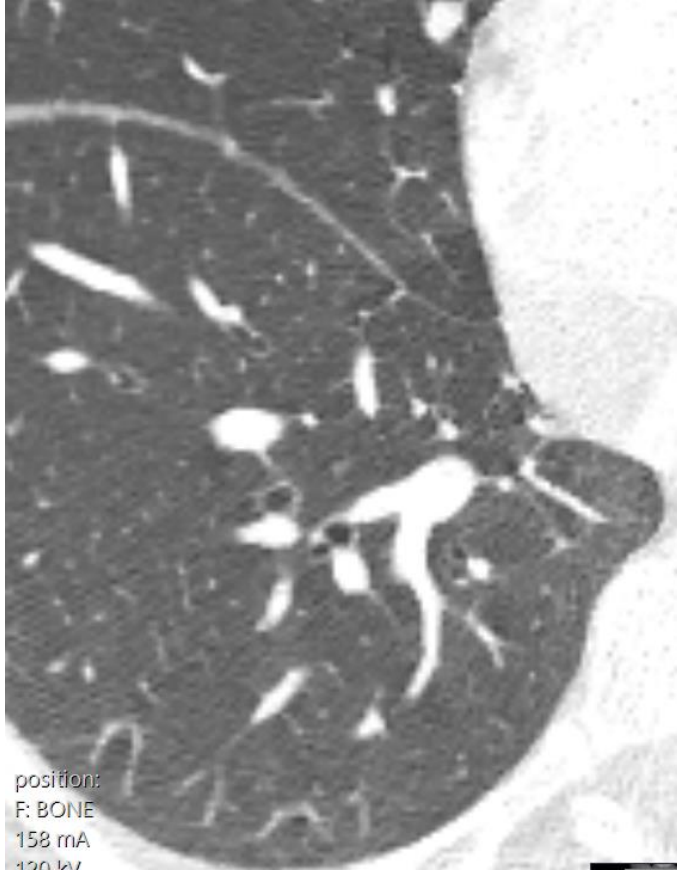
10.09.2021



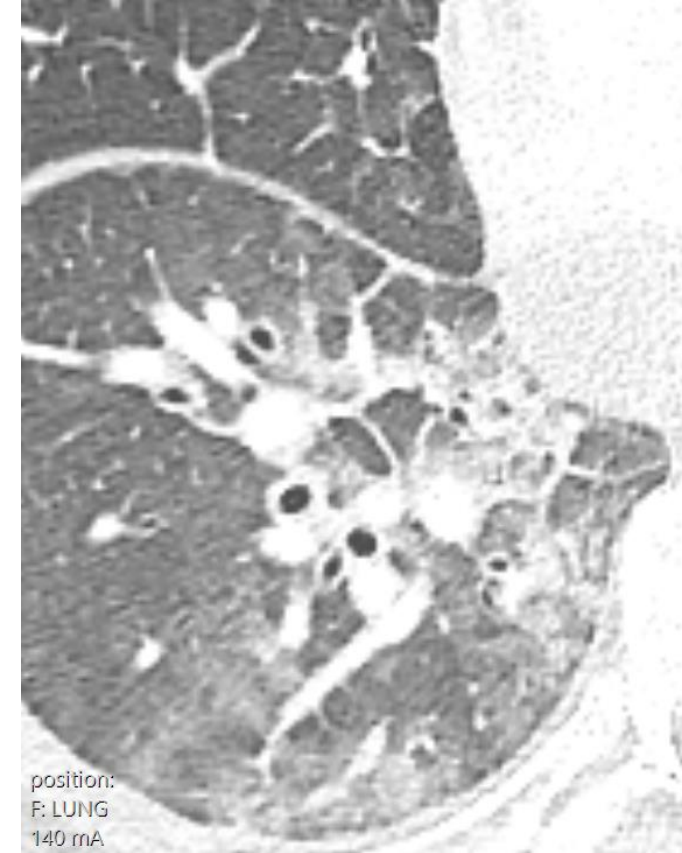
17.09.2021

18 Y E, AML hastası

Dispne başlamış. Fungal pnömoni? PE?)



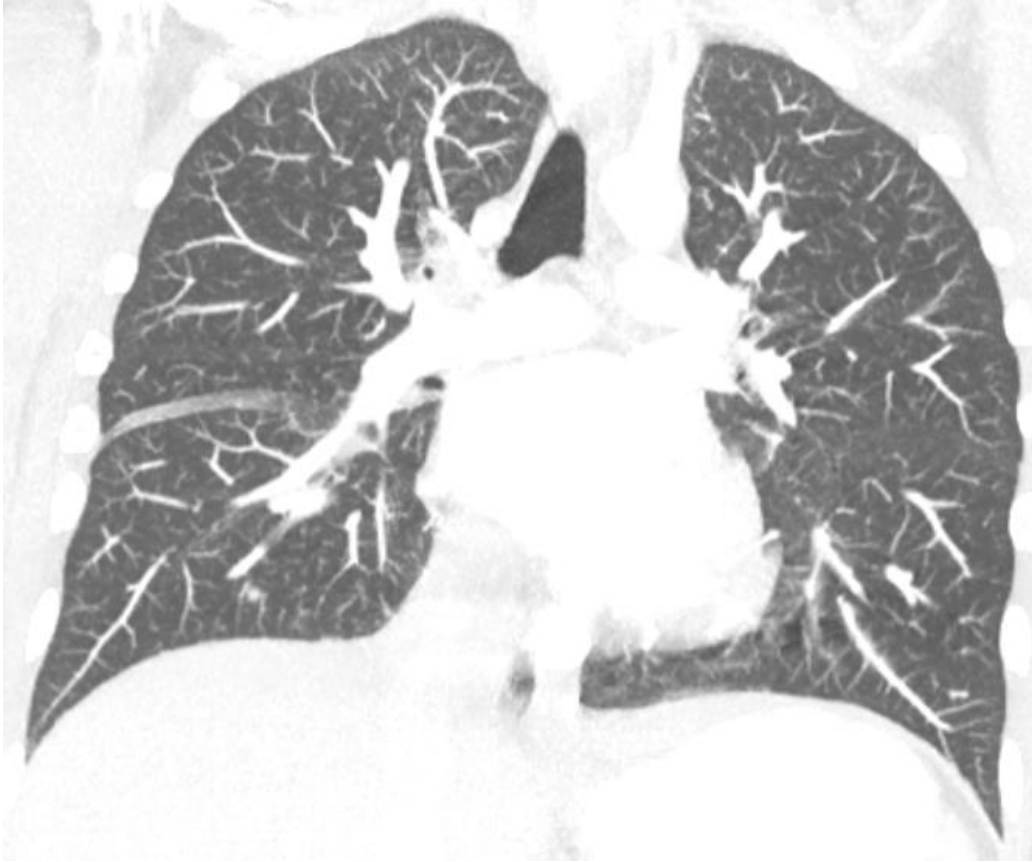10.09.2021



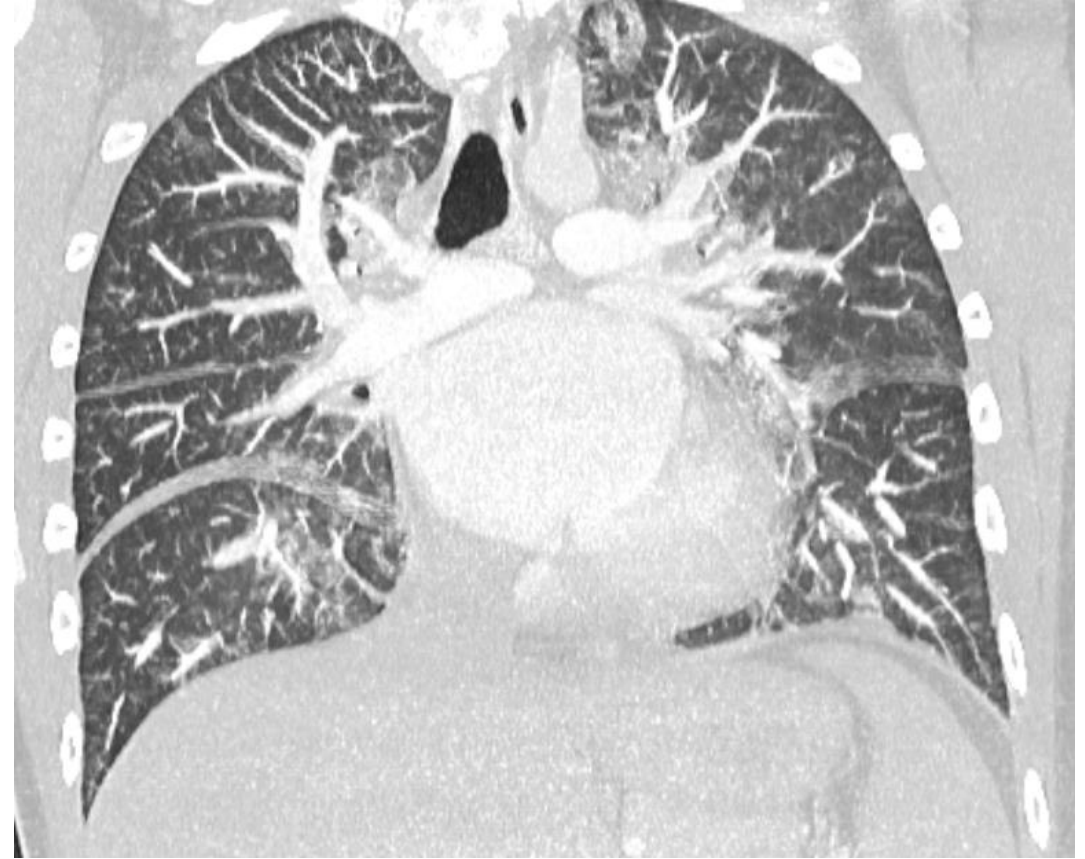
17.09.2021

18 Y E, AML hastası

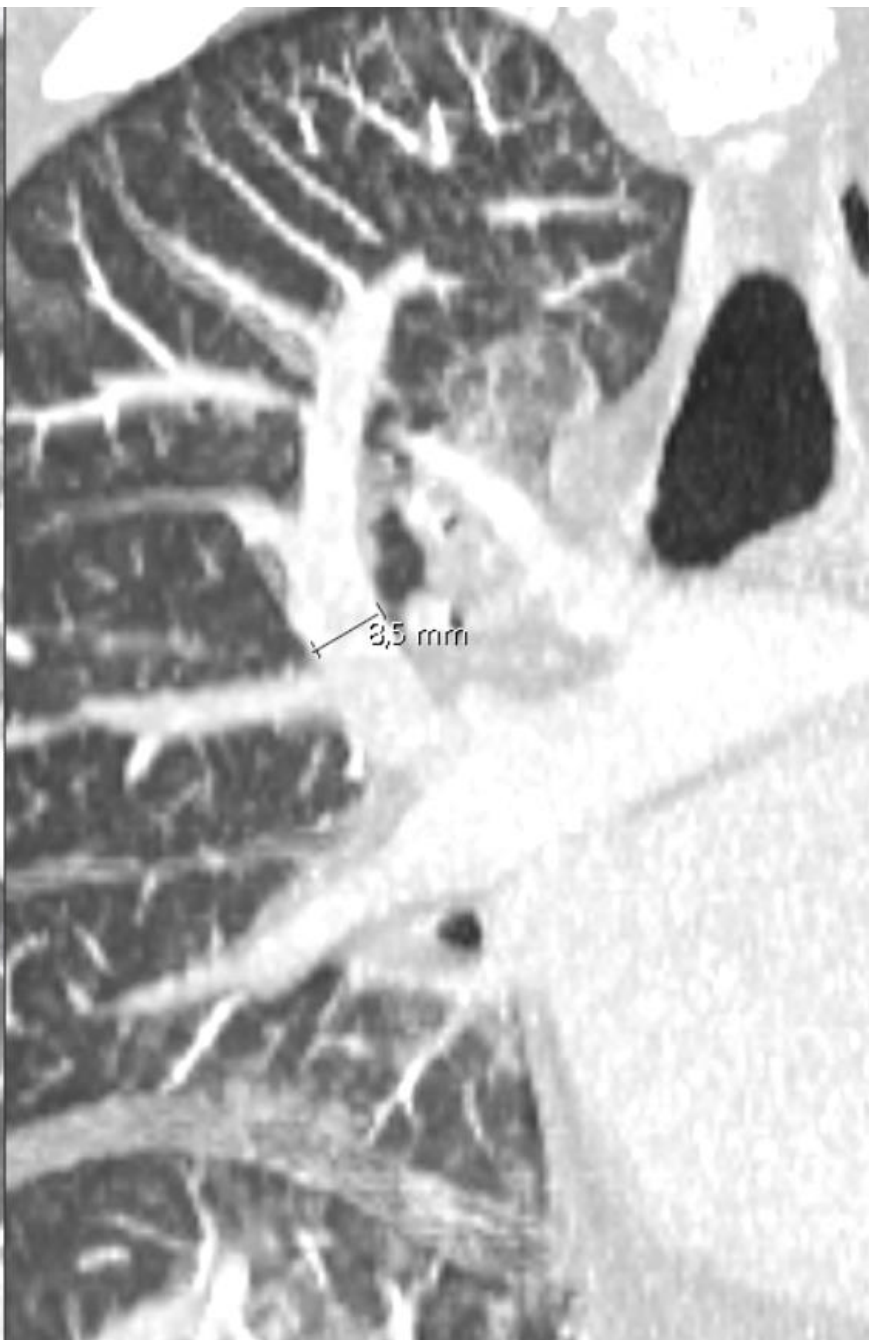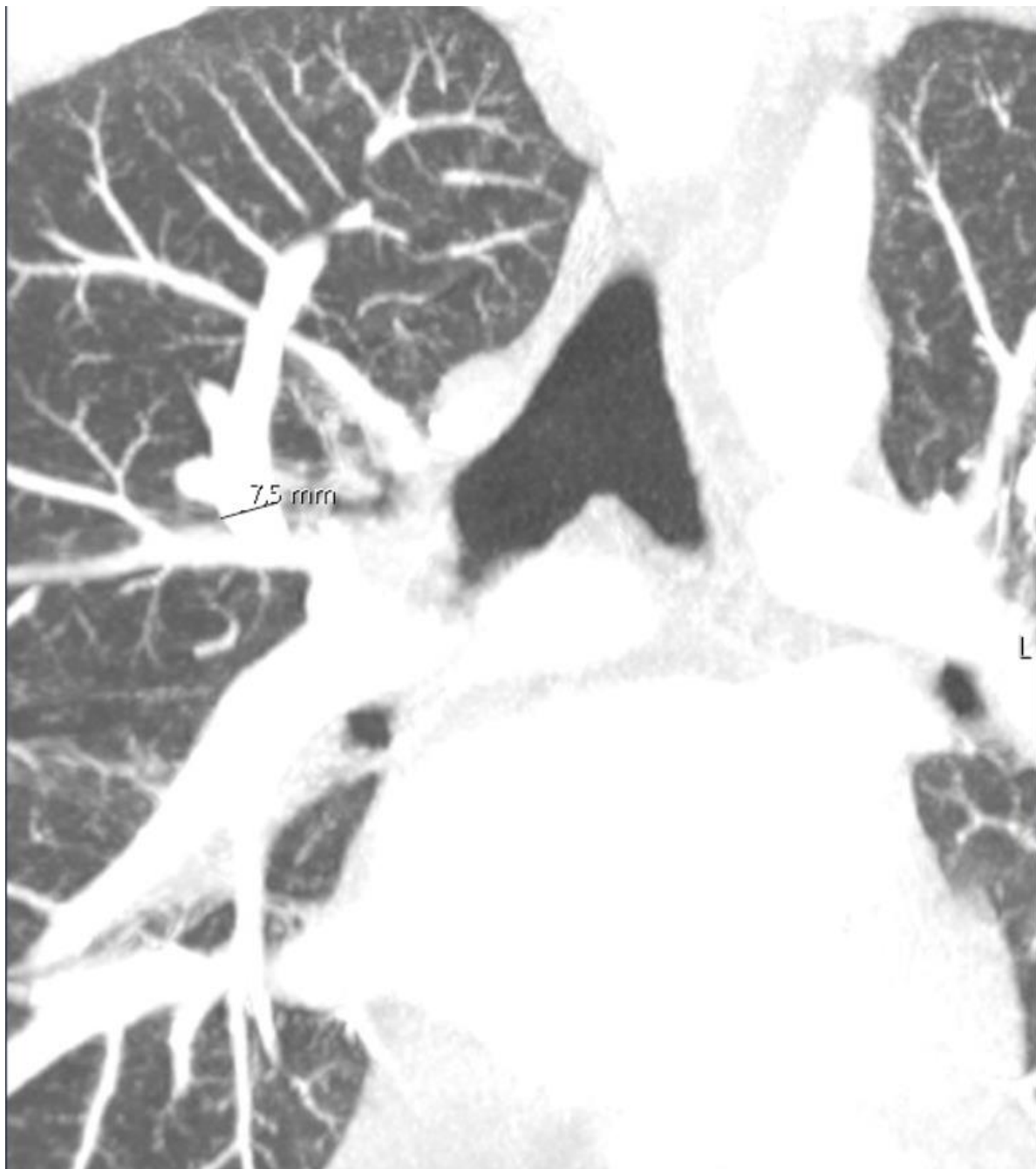
Dispne başlamış. Fungal pnömoni? PE?)

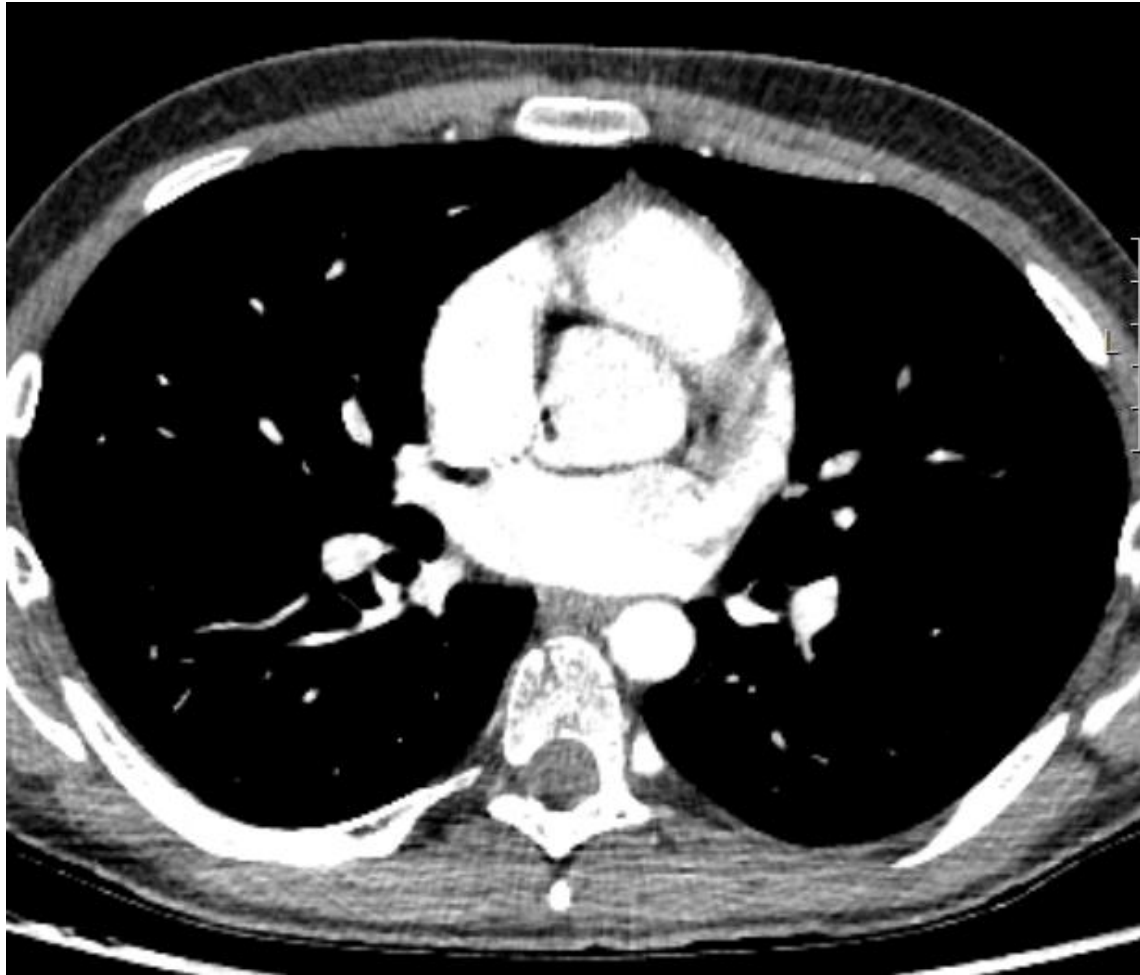


10.09.2021

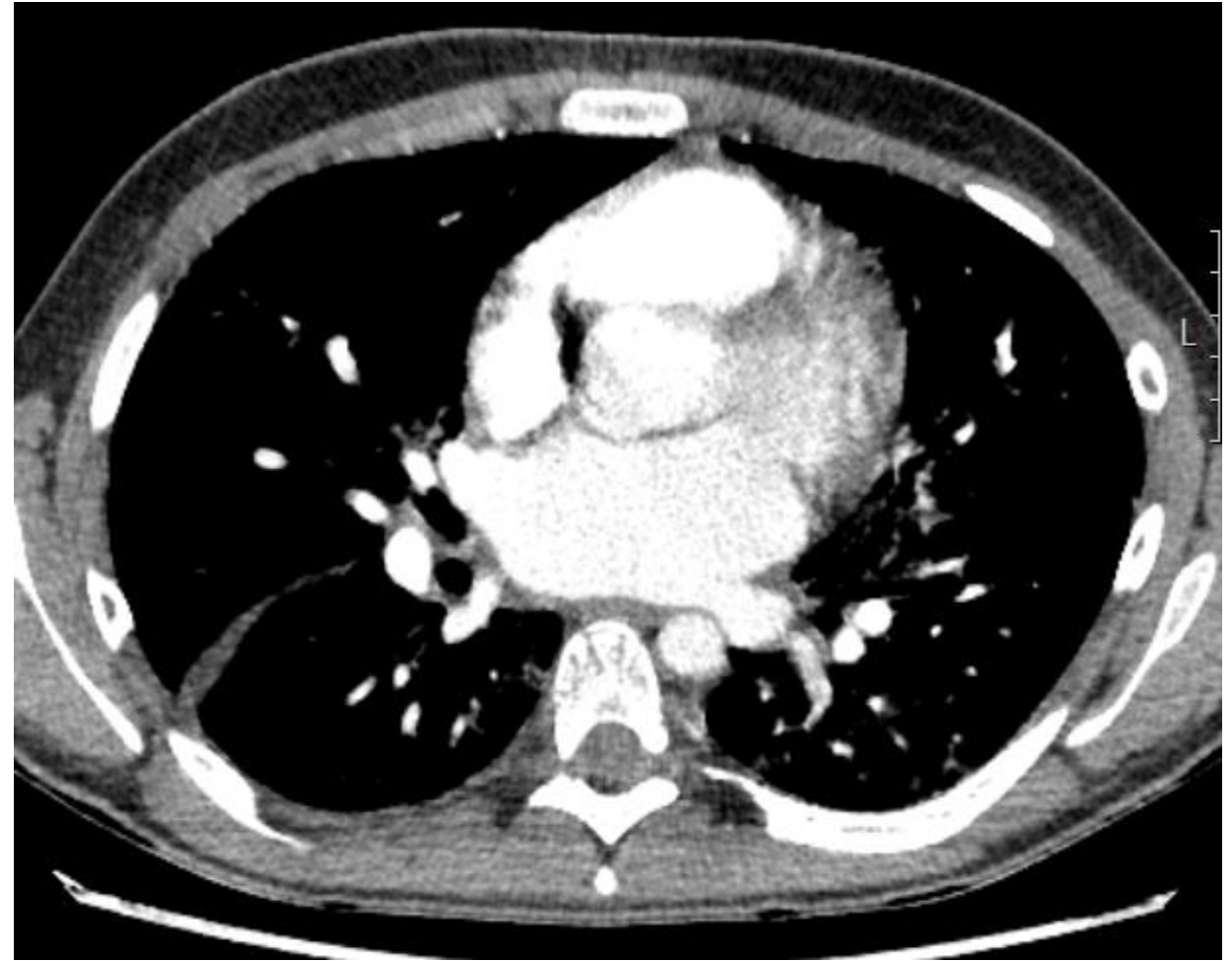


17.09.2021





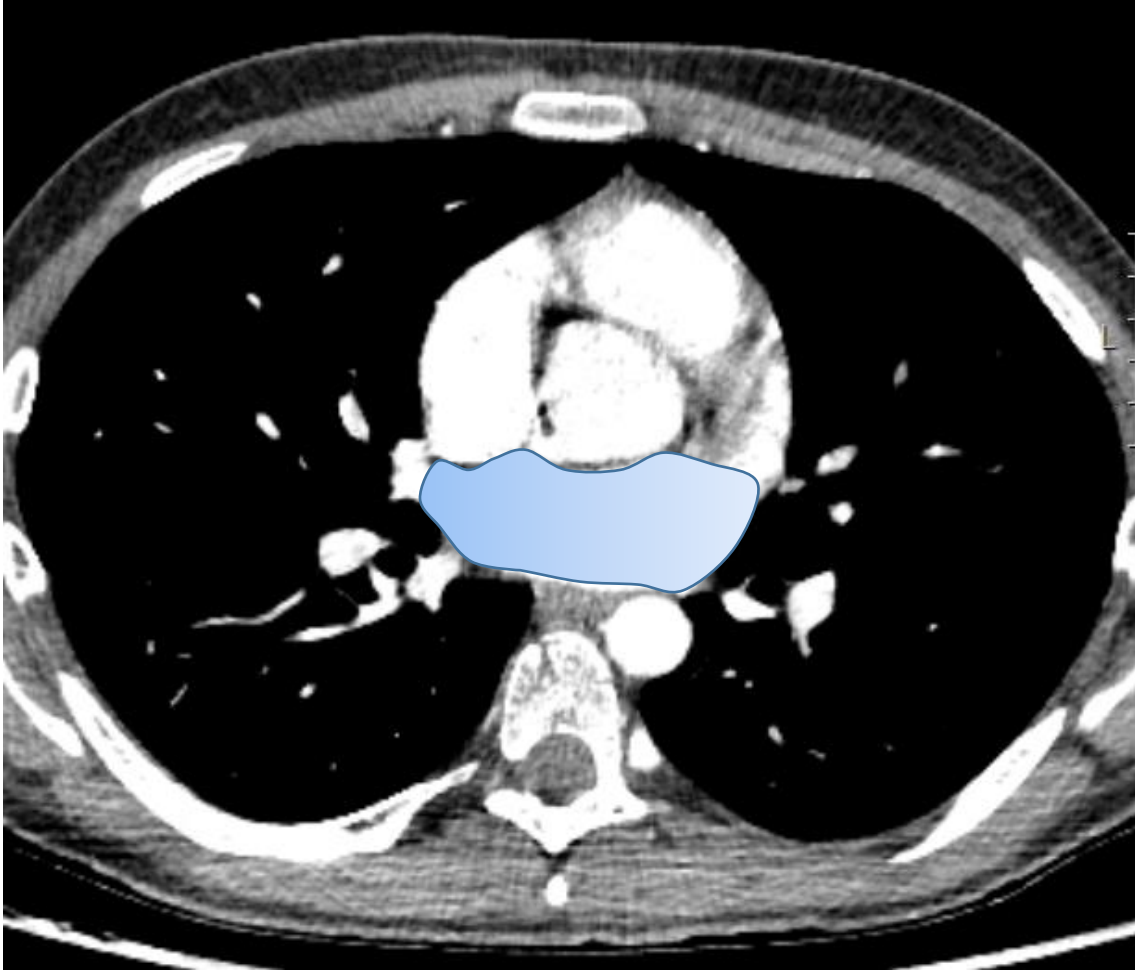
10.09.2021



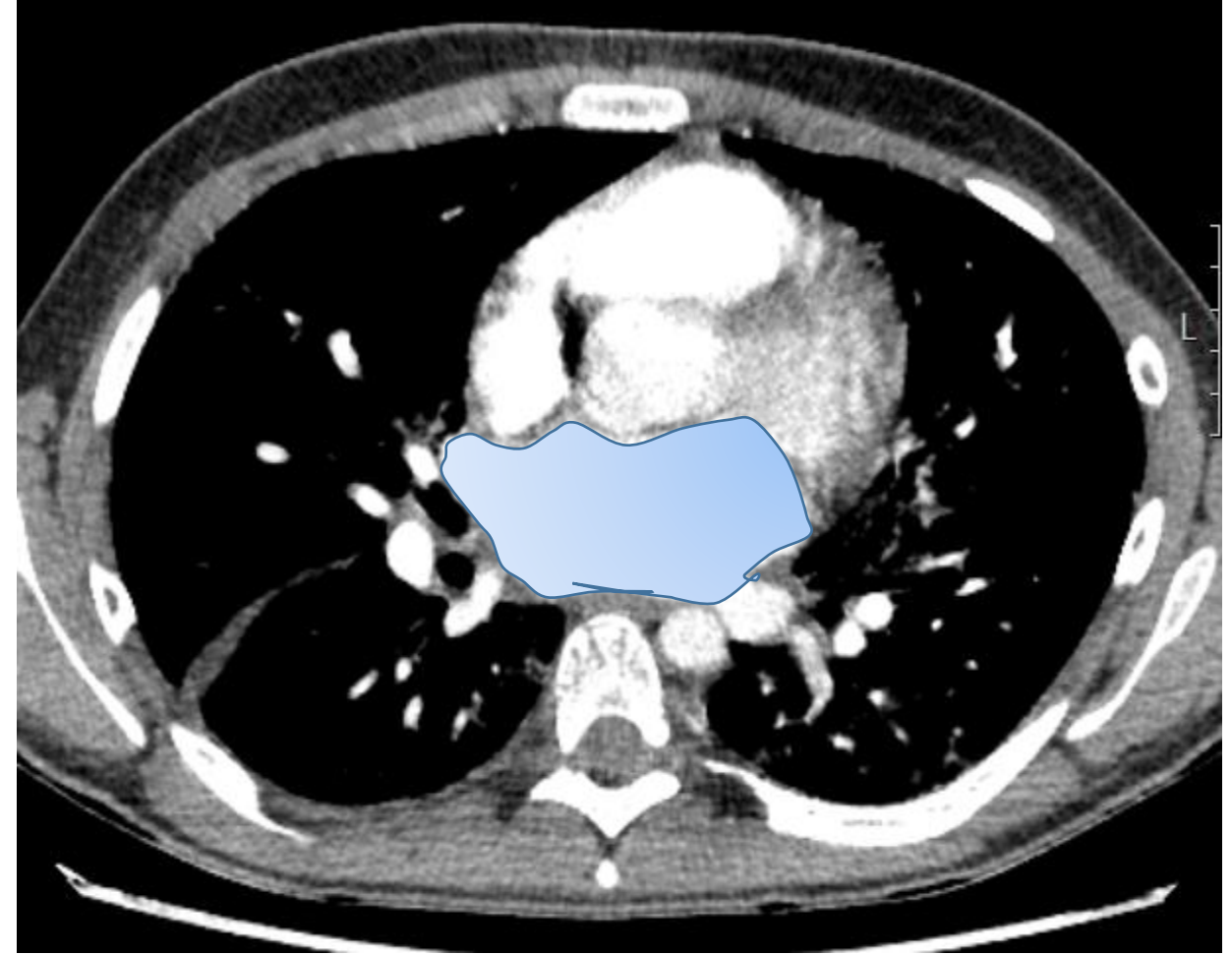
17.09.2021

Antrasiklin ilişkili akut kalp yetmezliği

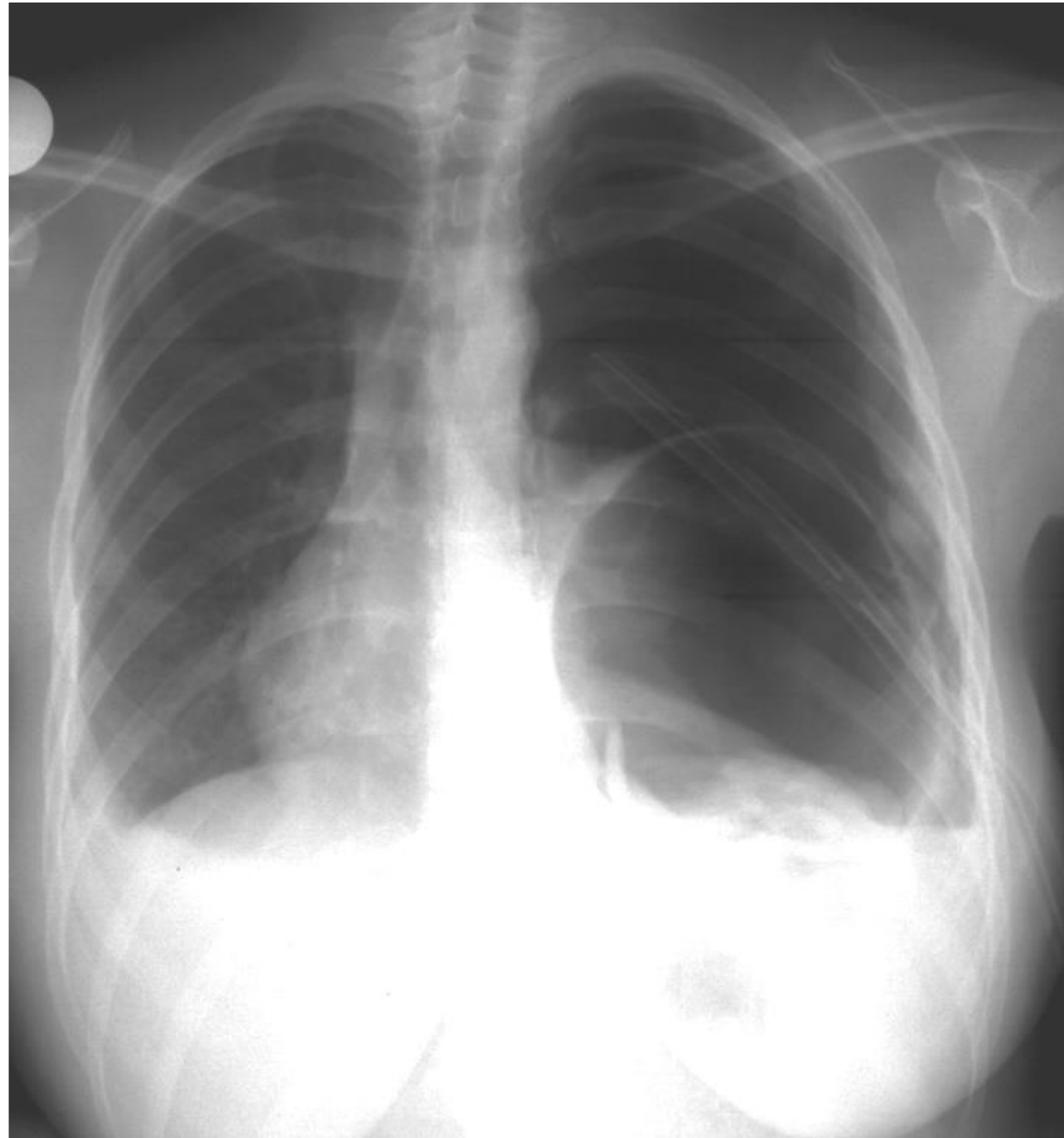
EF: % 25

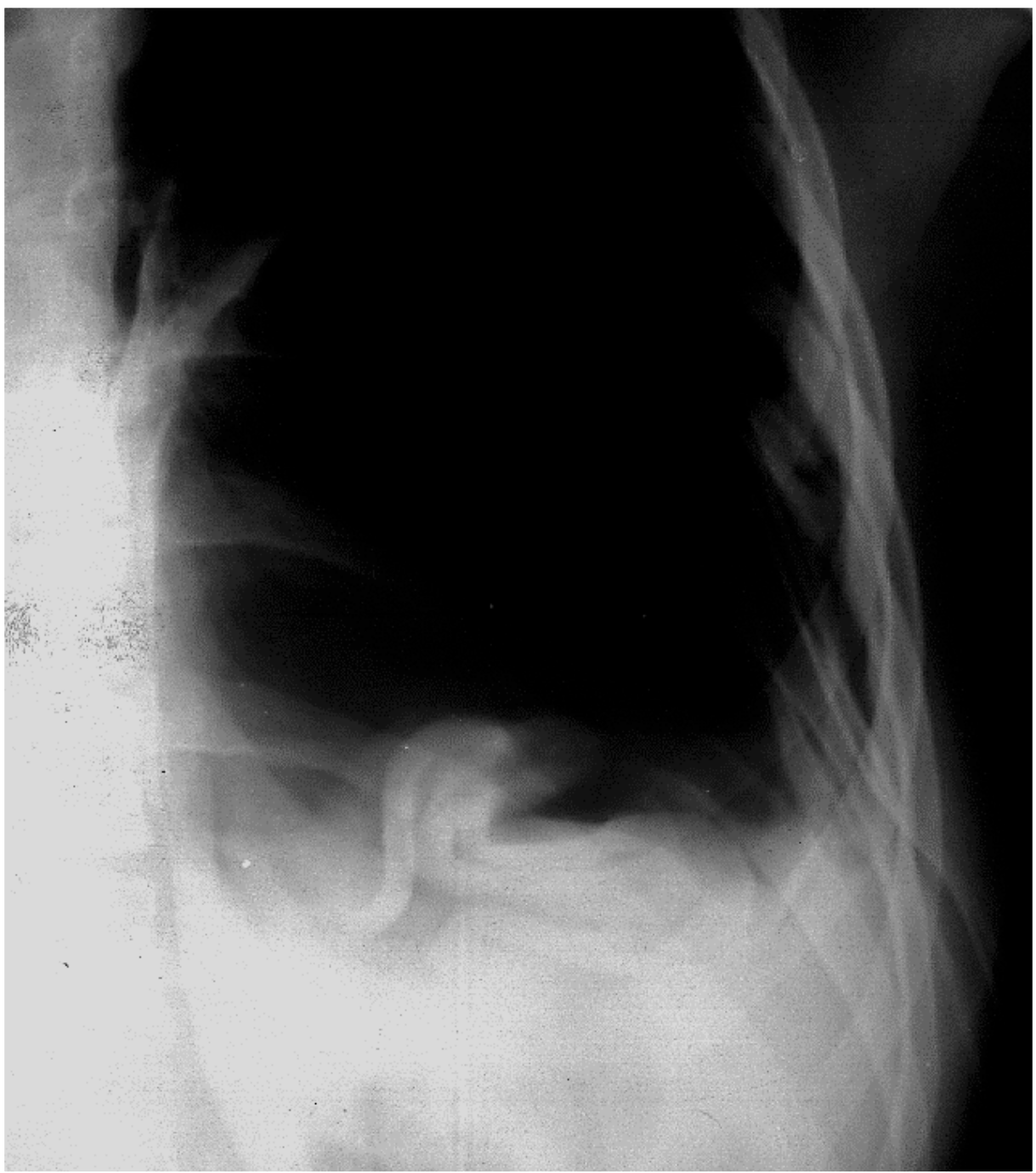


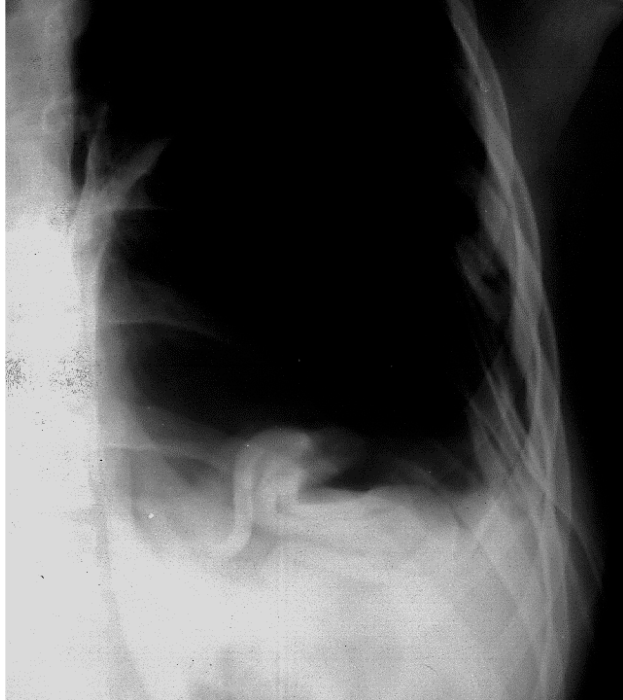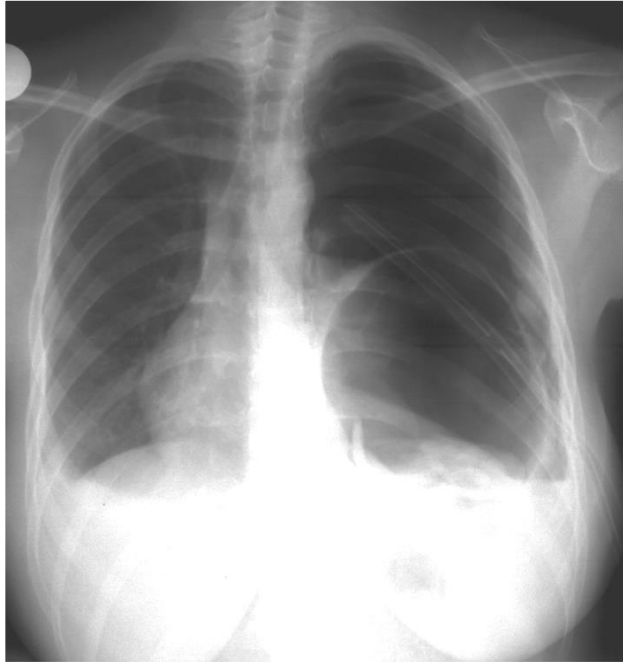
10.09.2021



17.09.2021

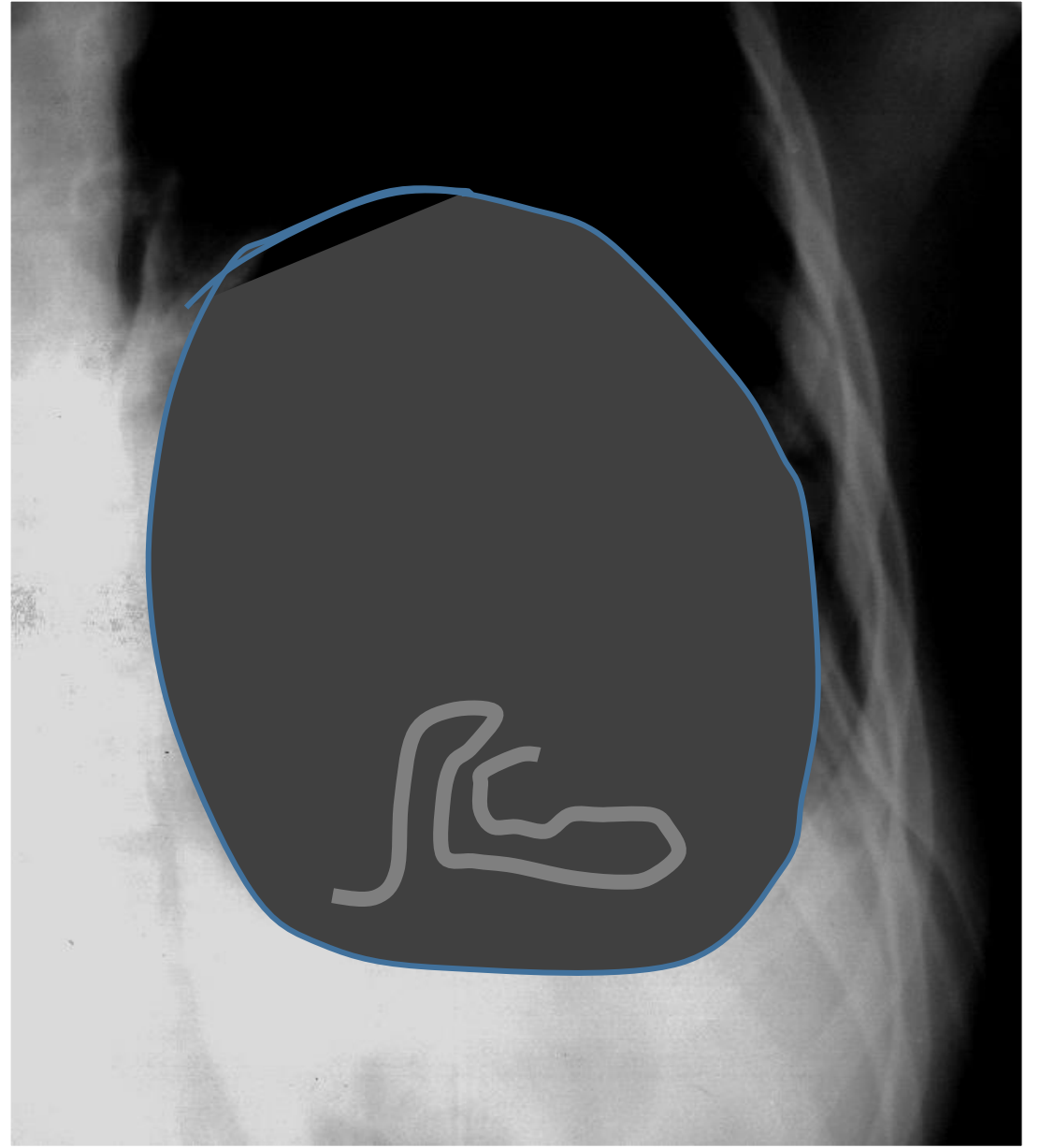
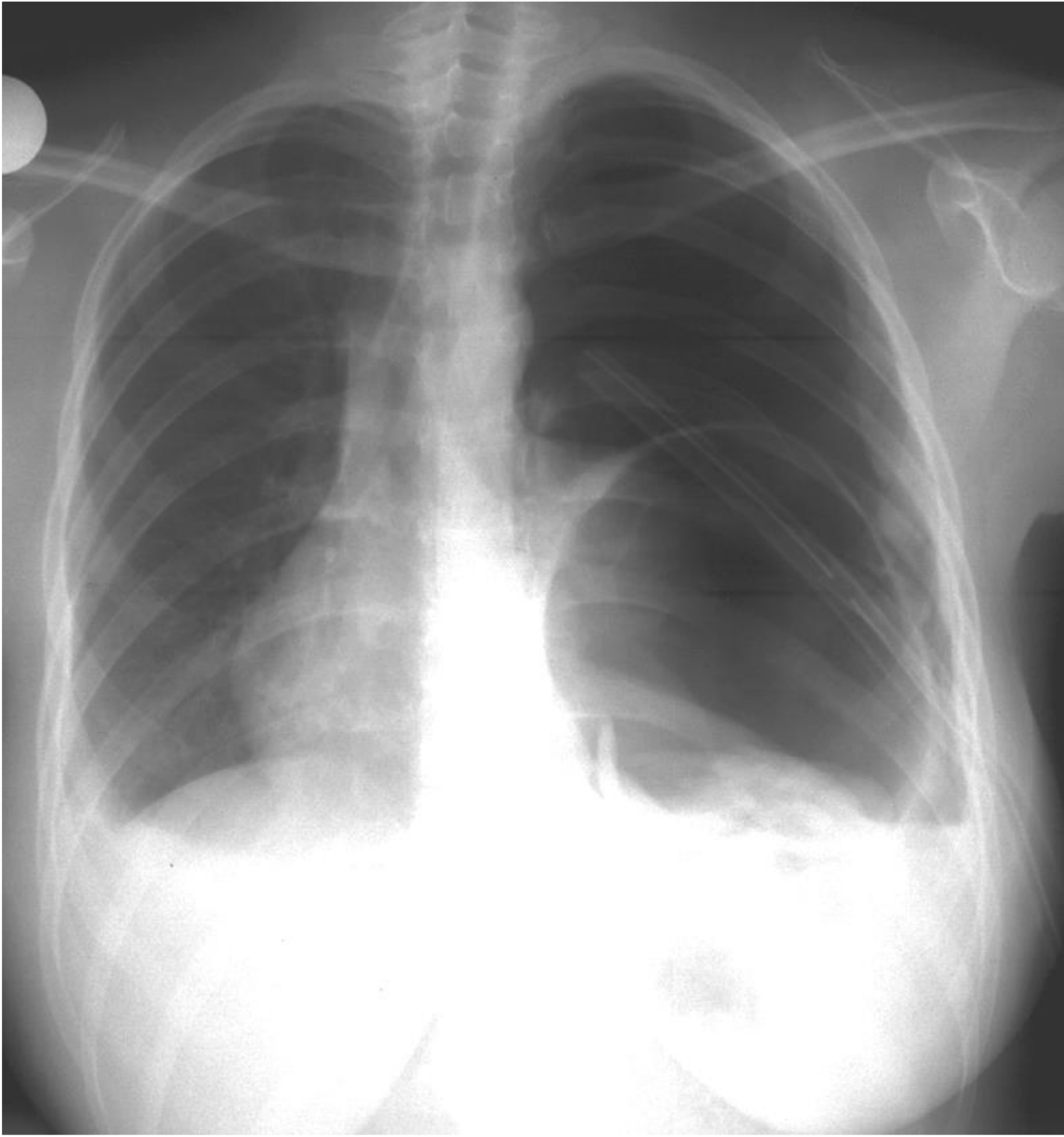




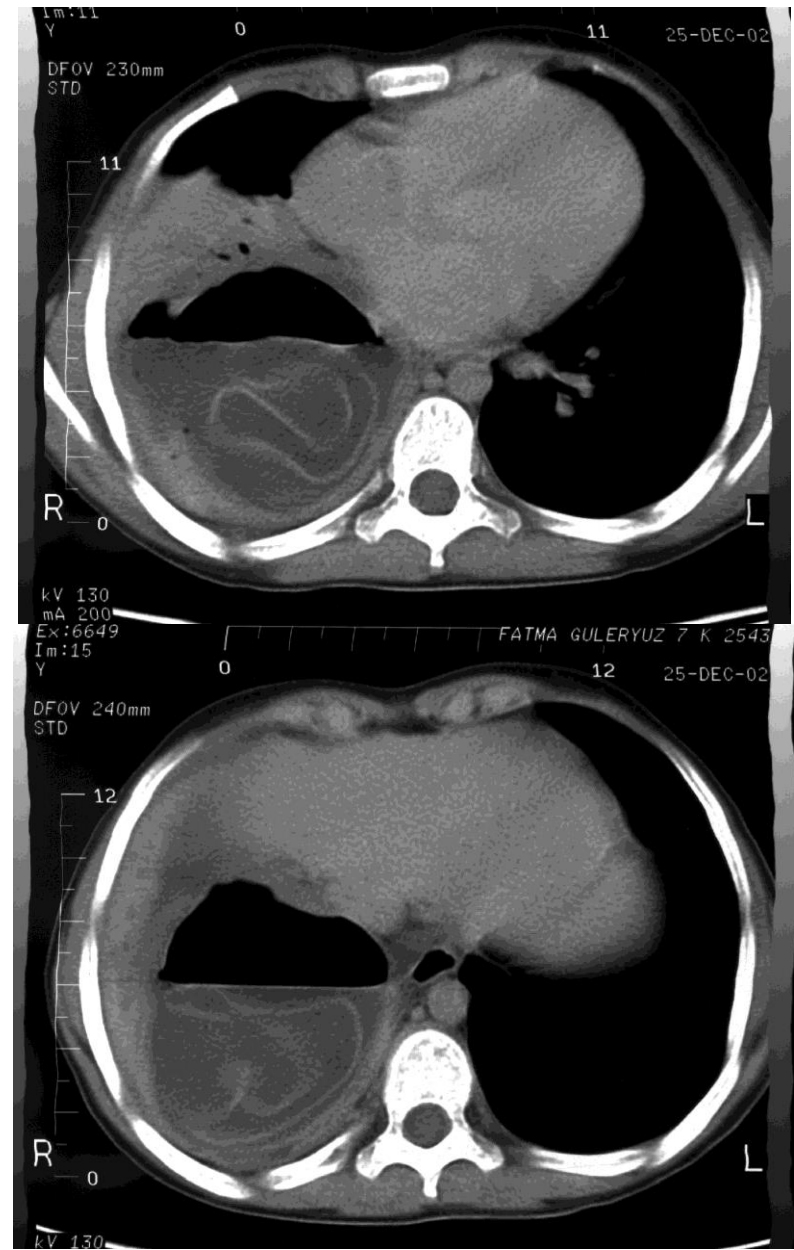
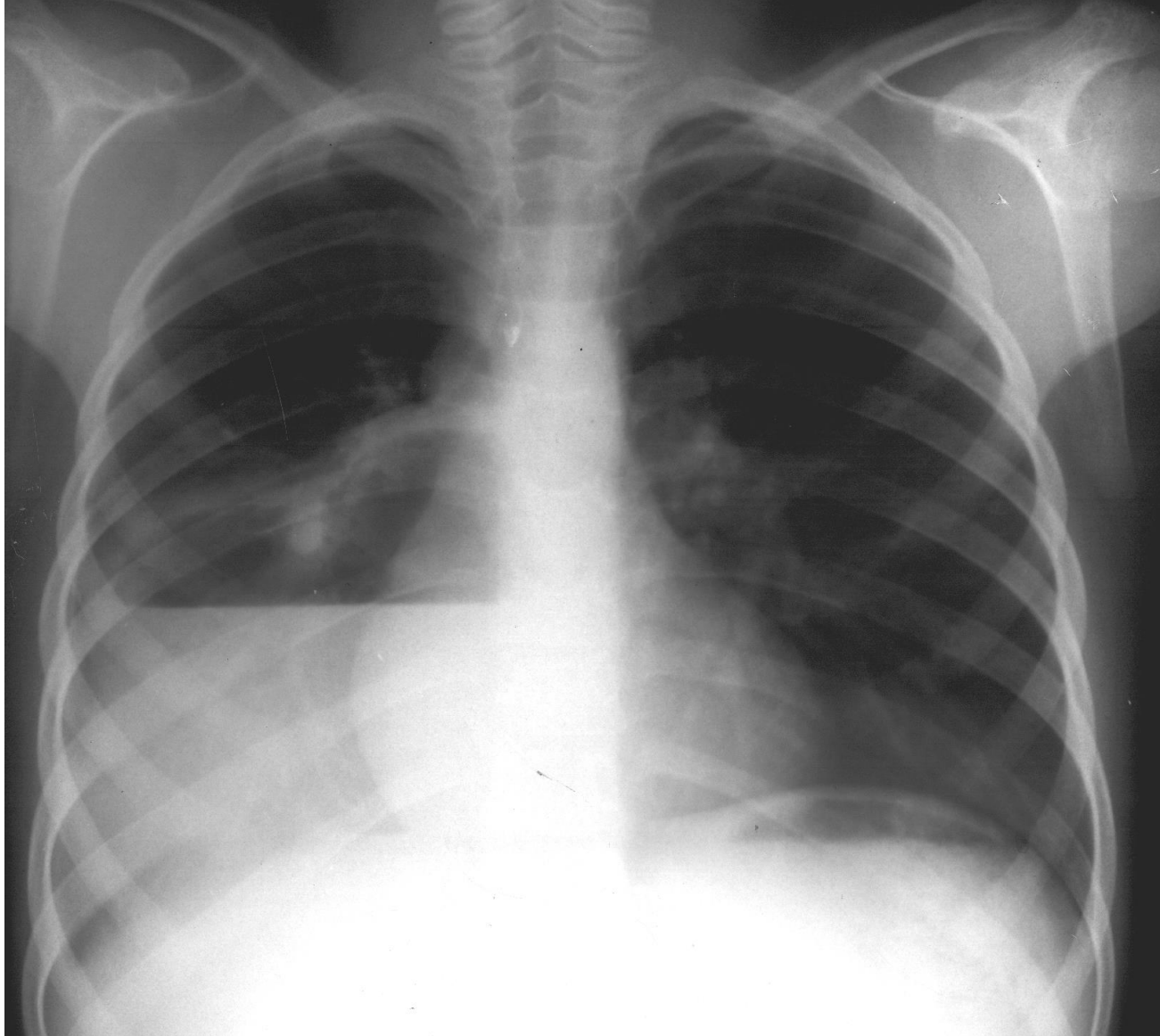

21 yaşında solunum sıkıntısı nedeniyle acil servise başvuran olguda PA grafide pnömotoraks sebebi ne olabilir?

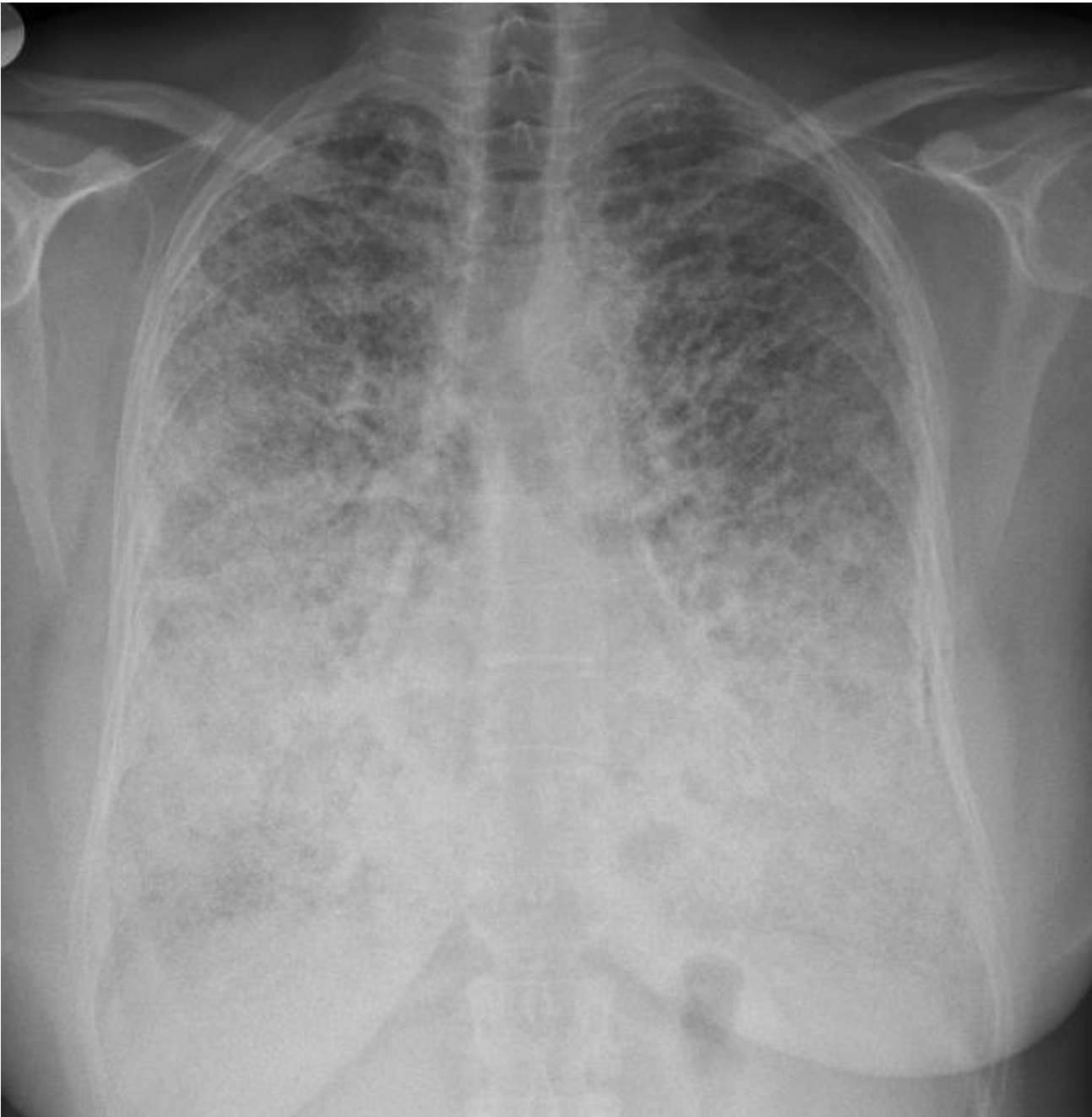- a) Diyafragma rüptürü
- b) Bül
- c) Kist hidatik
- d) Bronkojenik kist
- e) Akciğer absesi



PERFORE KİST HİDATİK

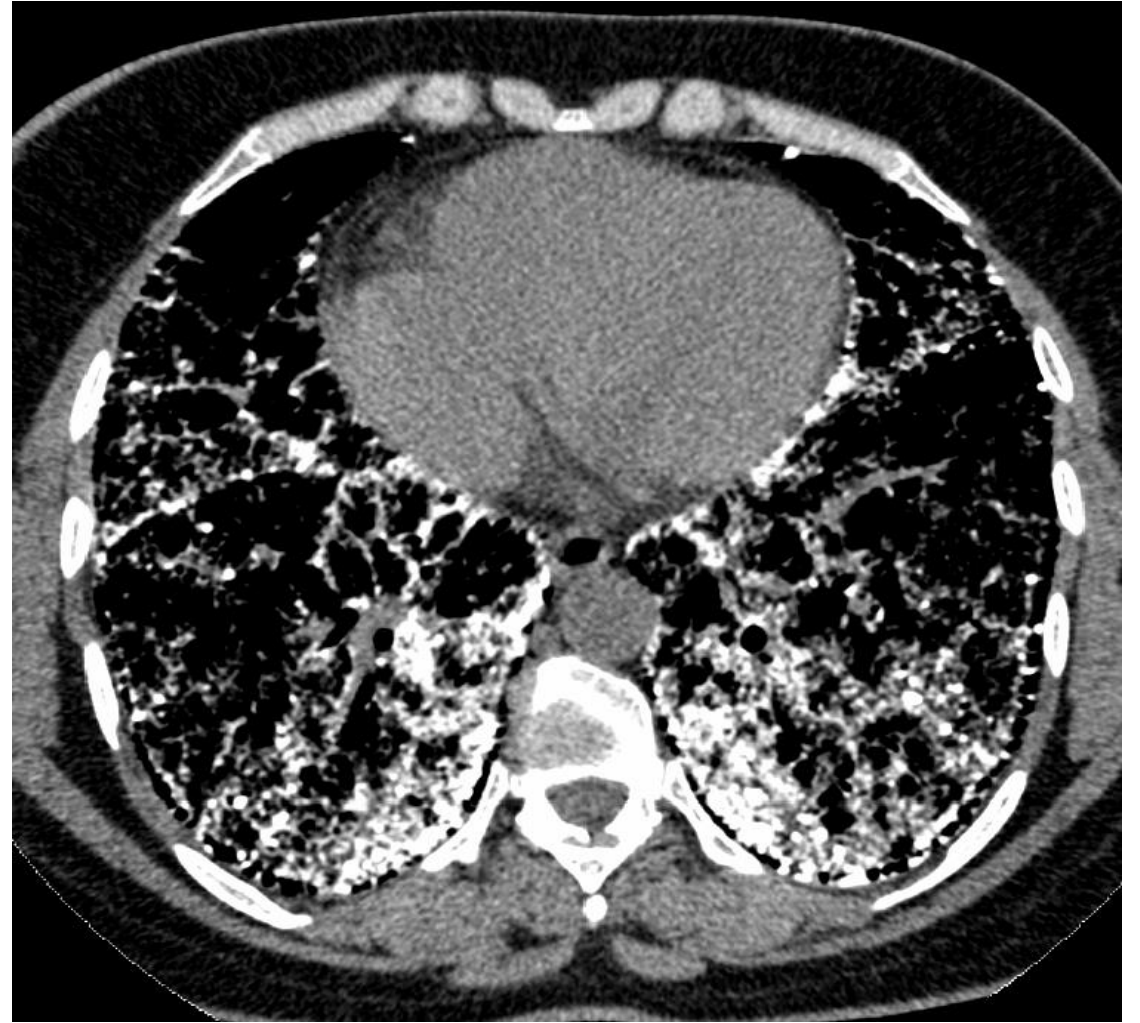
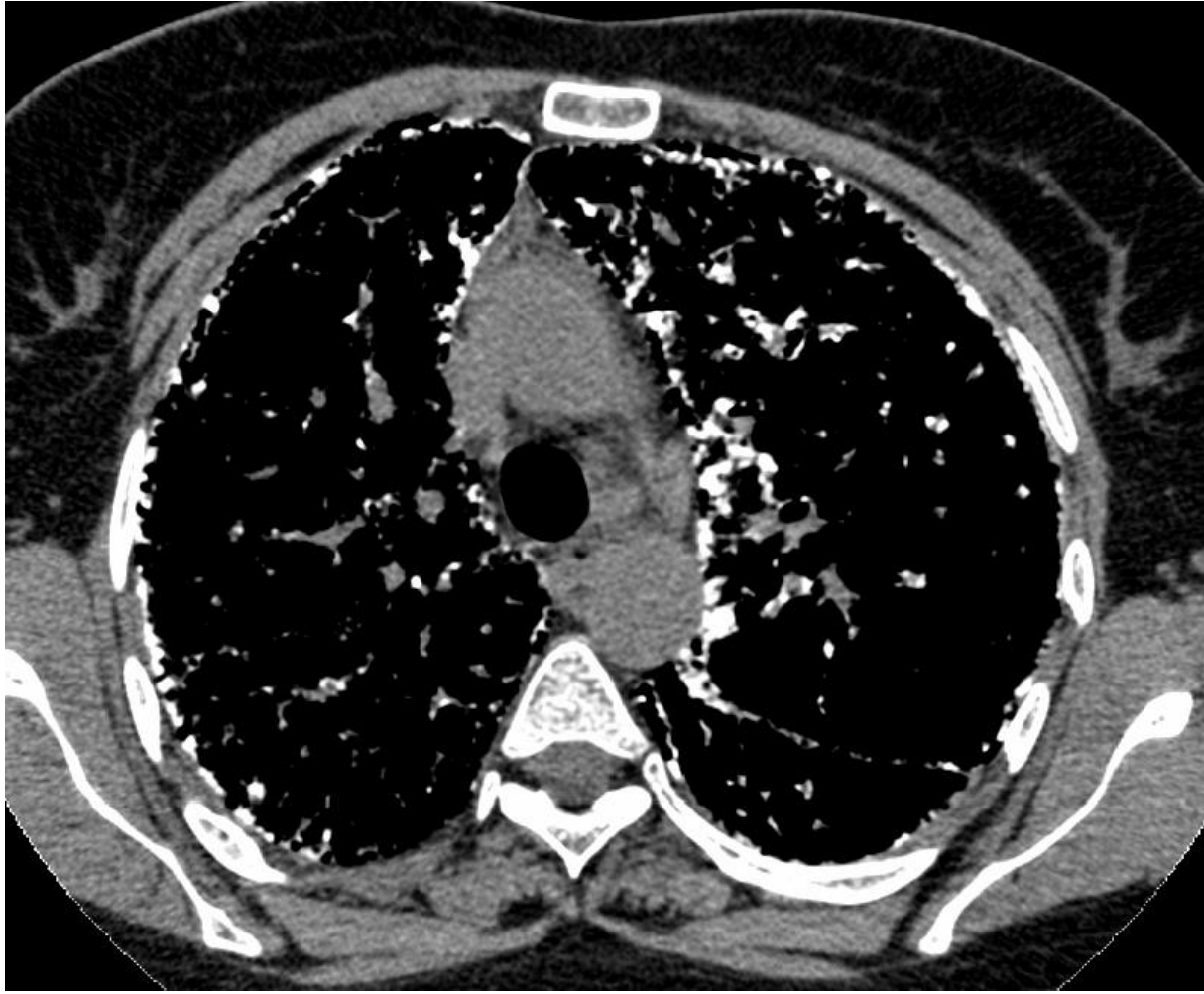

PERFORE KİST HİDATİK

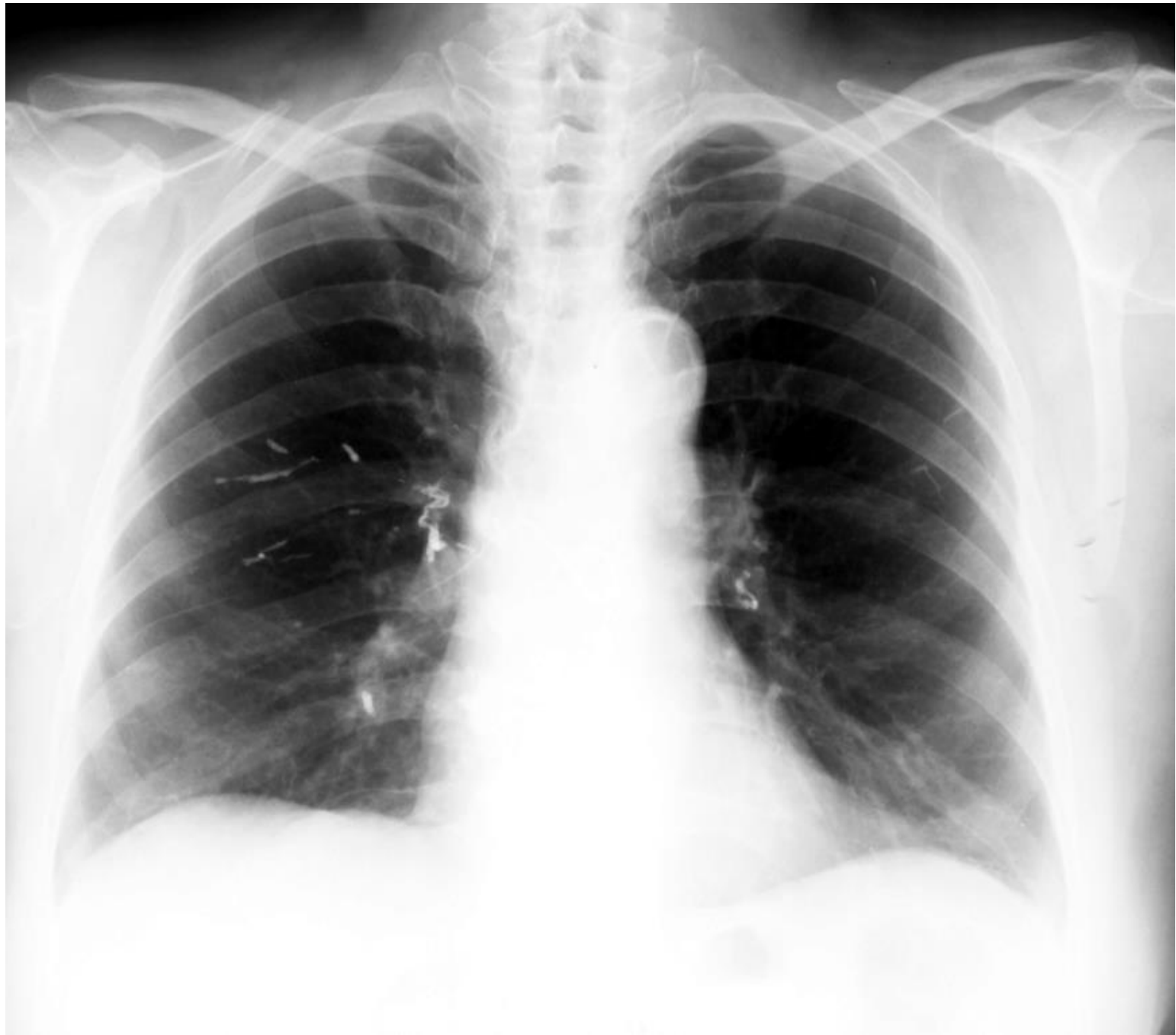

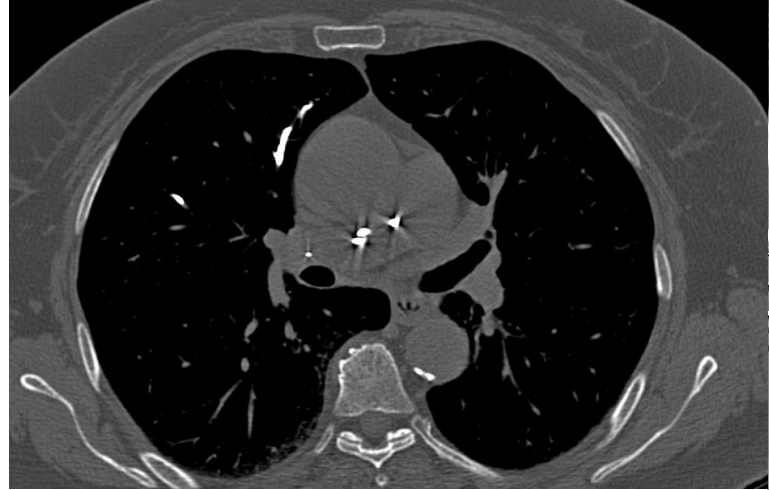
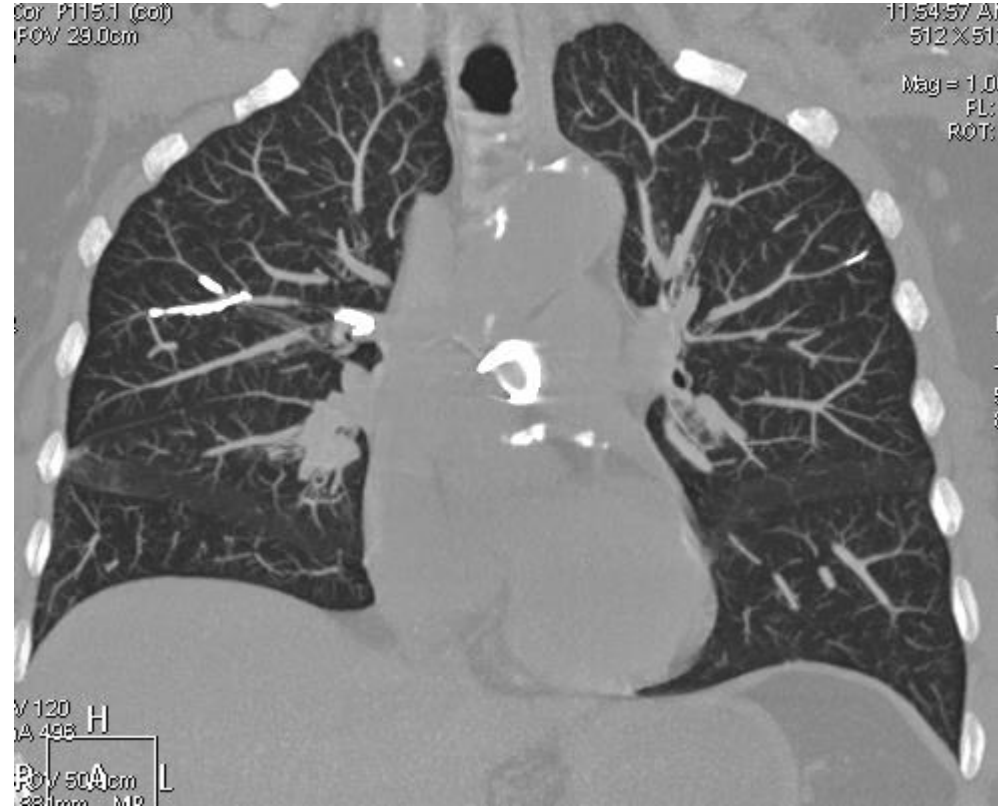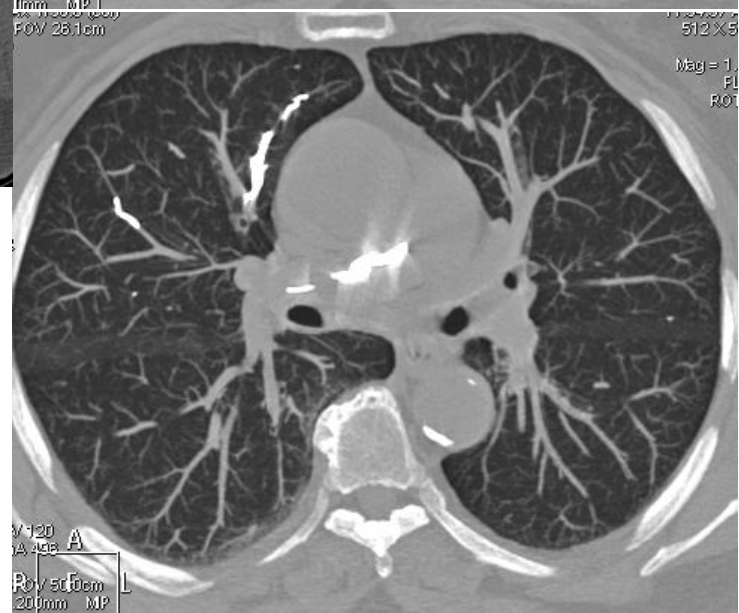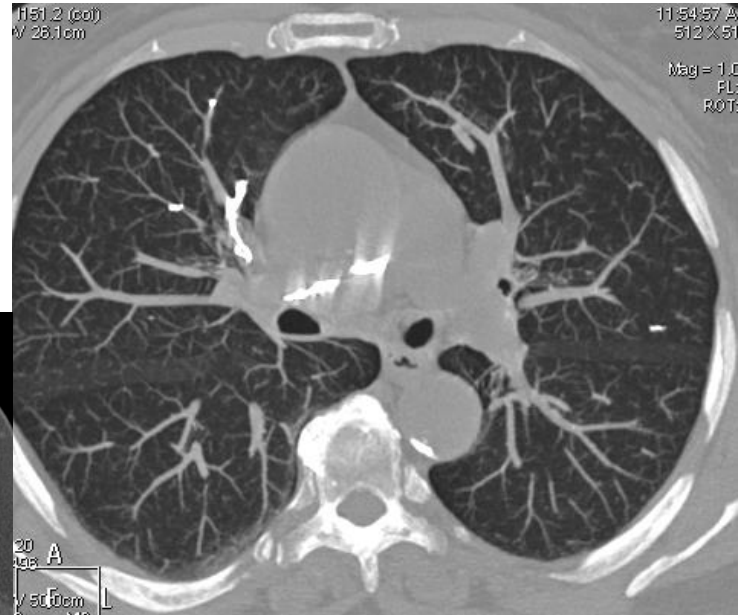
25 yaşında erkek,
solunum sıkıntısı.
Tanıda ne düşünürsünüz?

- a) ARDS
- b) Akciğer ödemi
- c) PCP
- d) Alveoler mikrolitiazis
- e) Familyal İPF

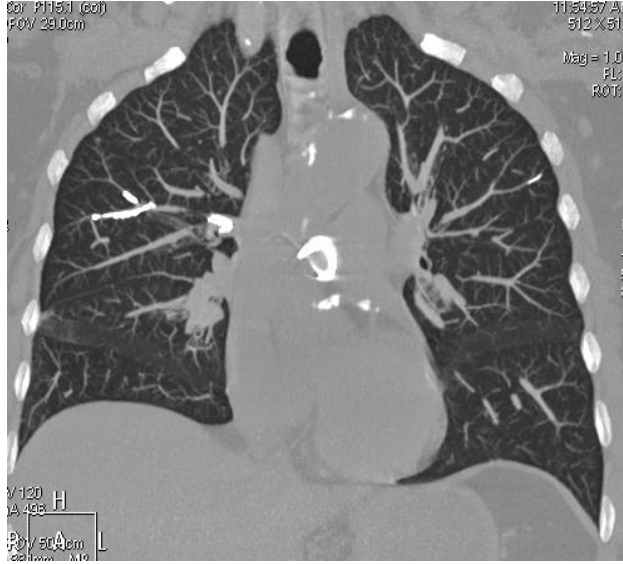


ALVEOLER MİKROLİTİAZİS

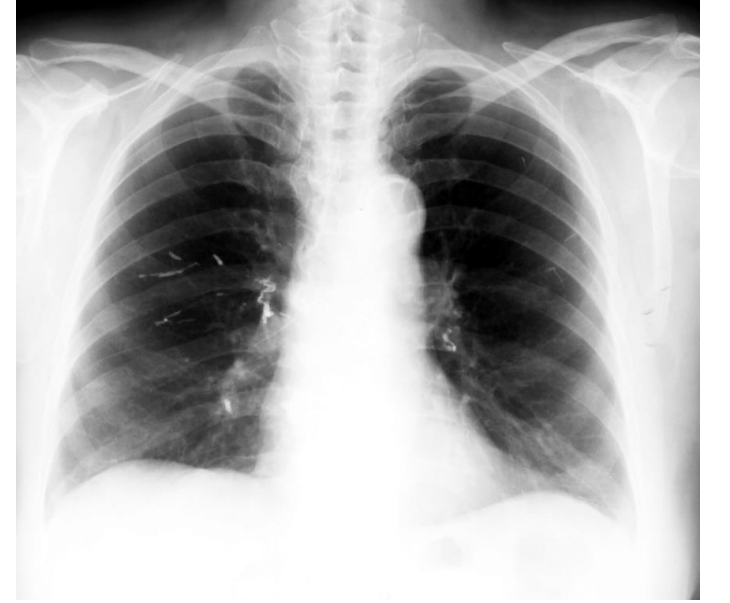

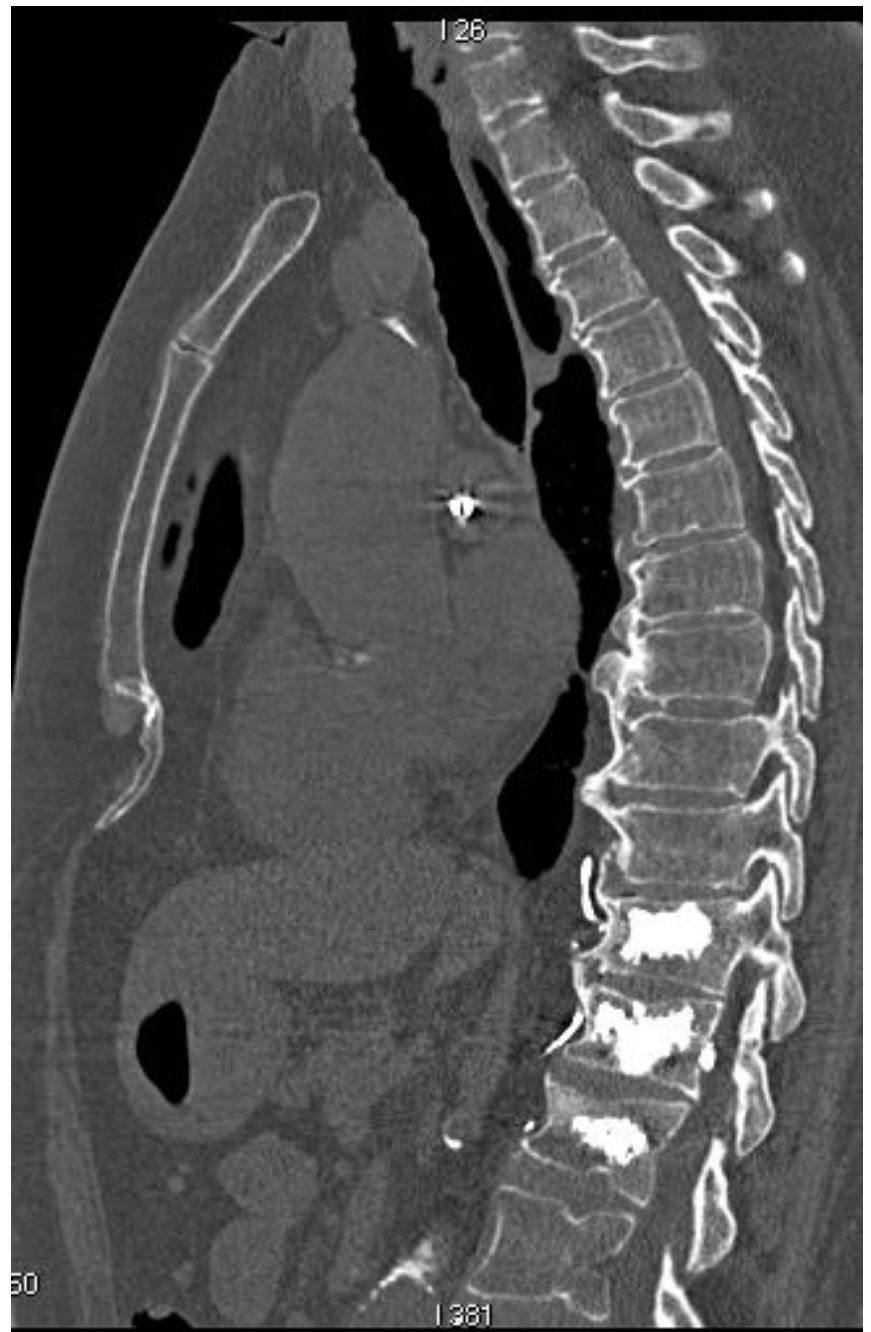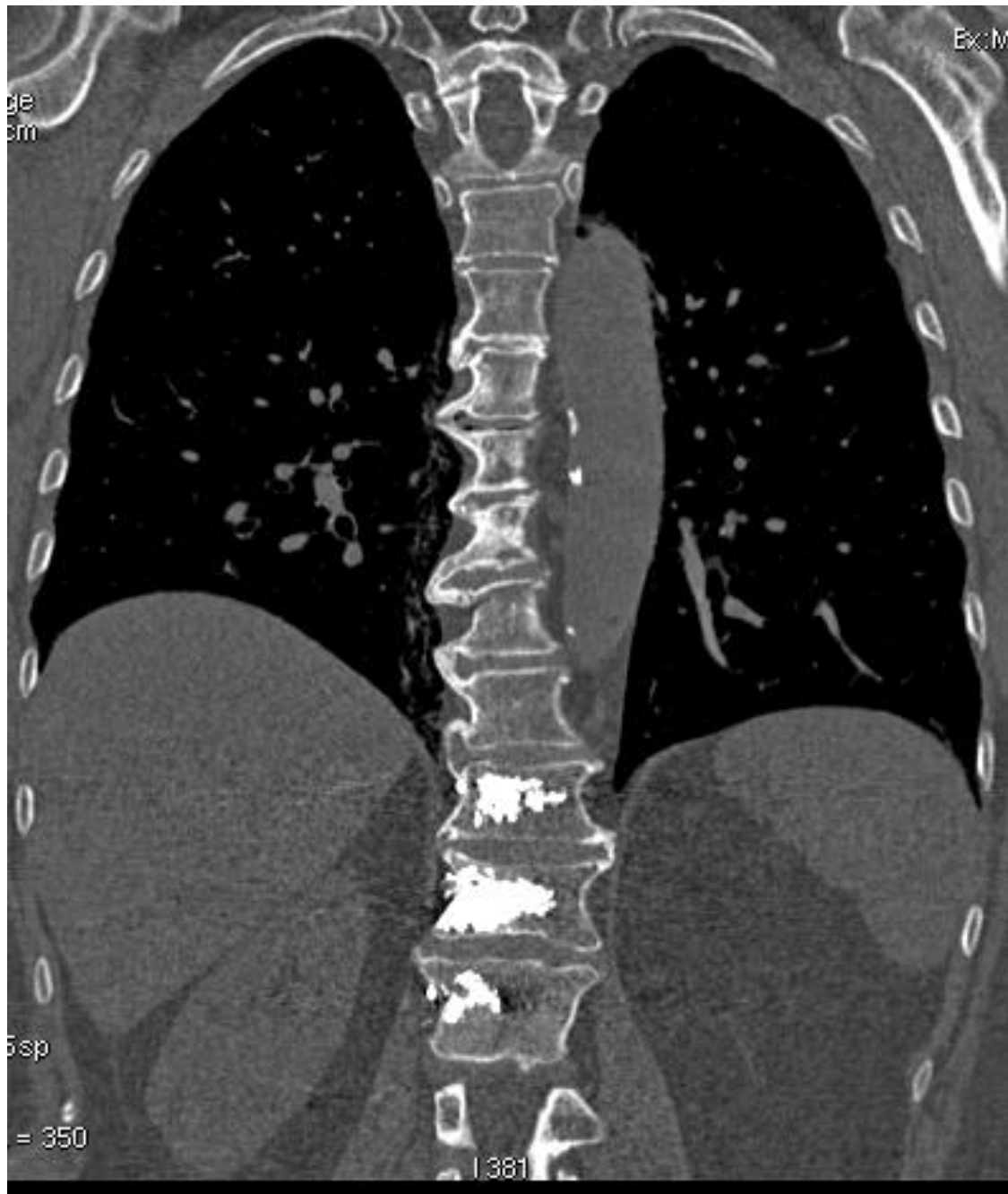


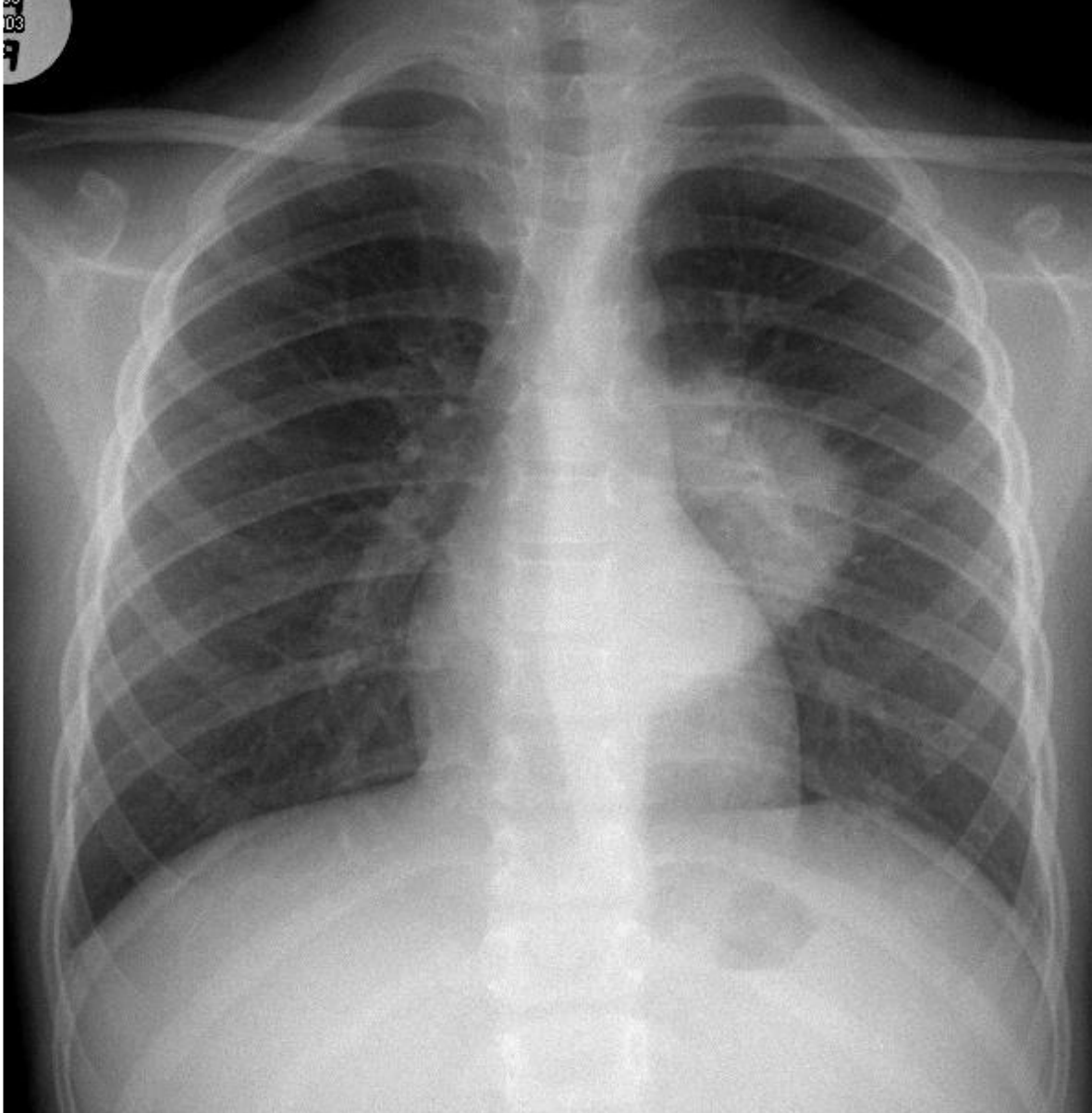
Tanı için ne düşünürdünüz?



- a) Bronkolithiazis
- b) Su çiçeği pnömonisi
- c) Tüberküloz sekeli
- d) Sement embolisi
- e) Kalsifik mukus tıkaçları

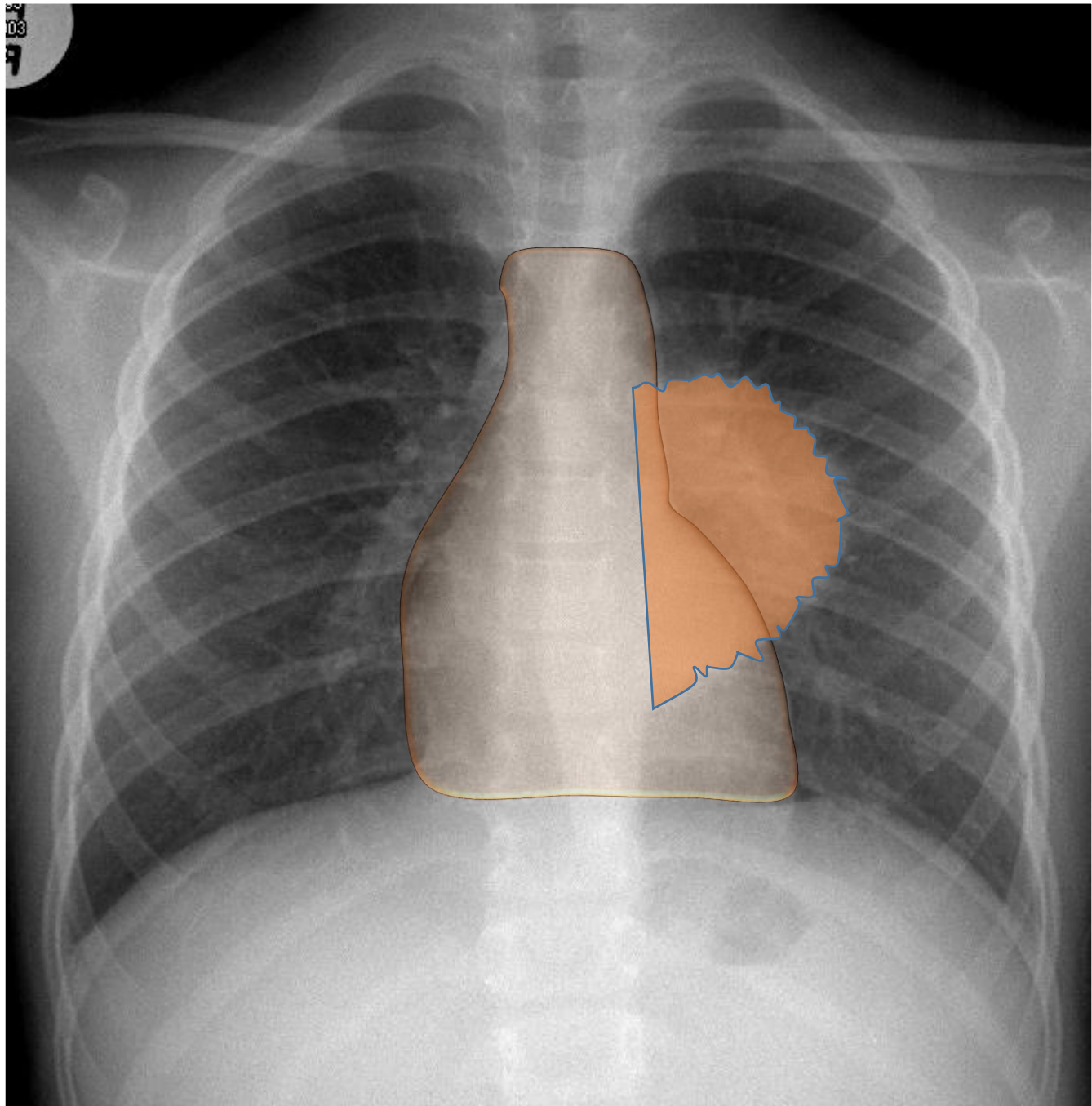


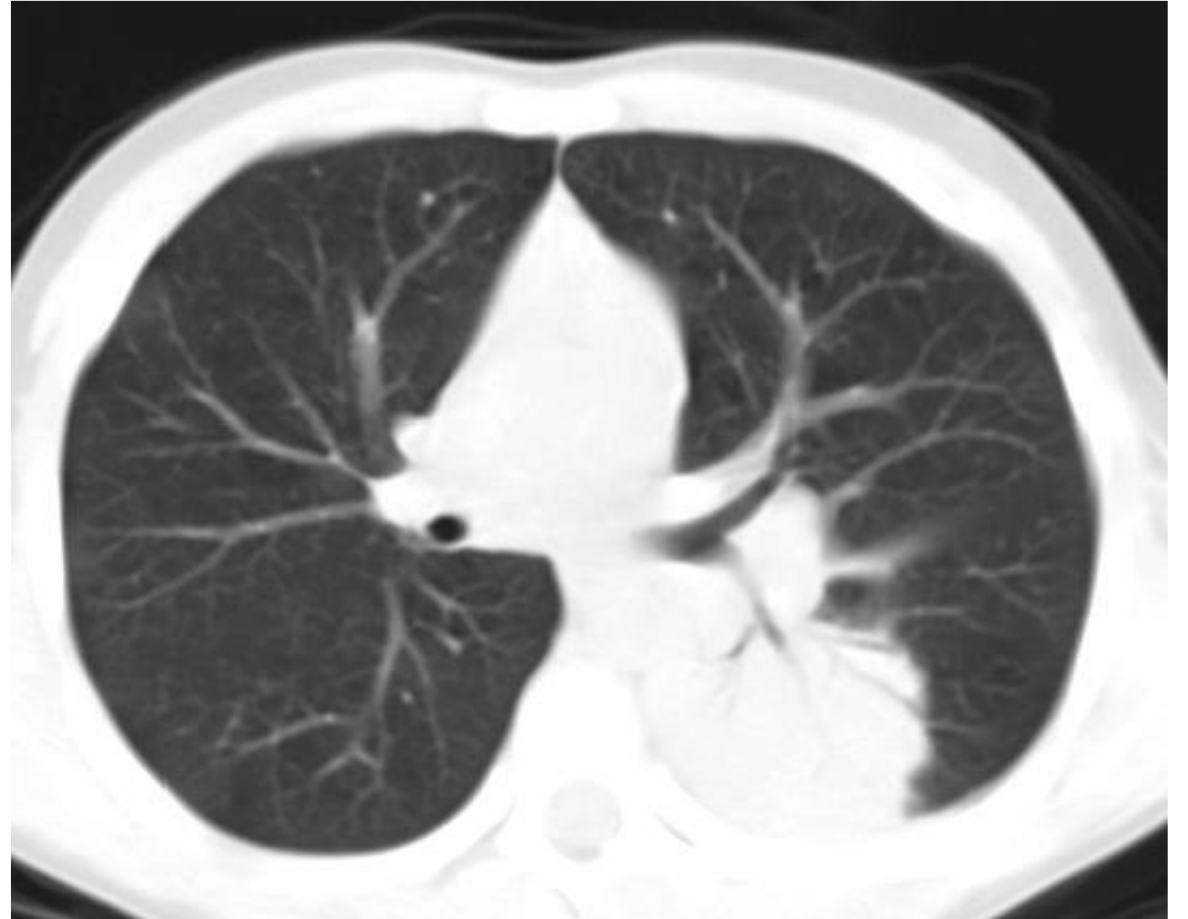
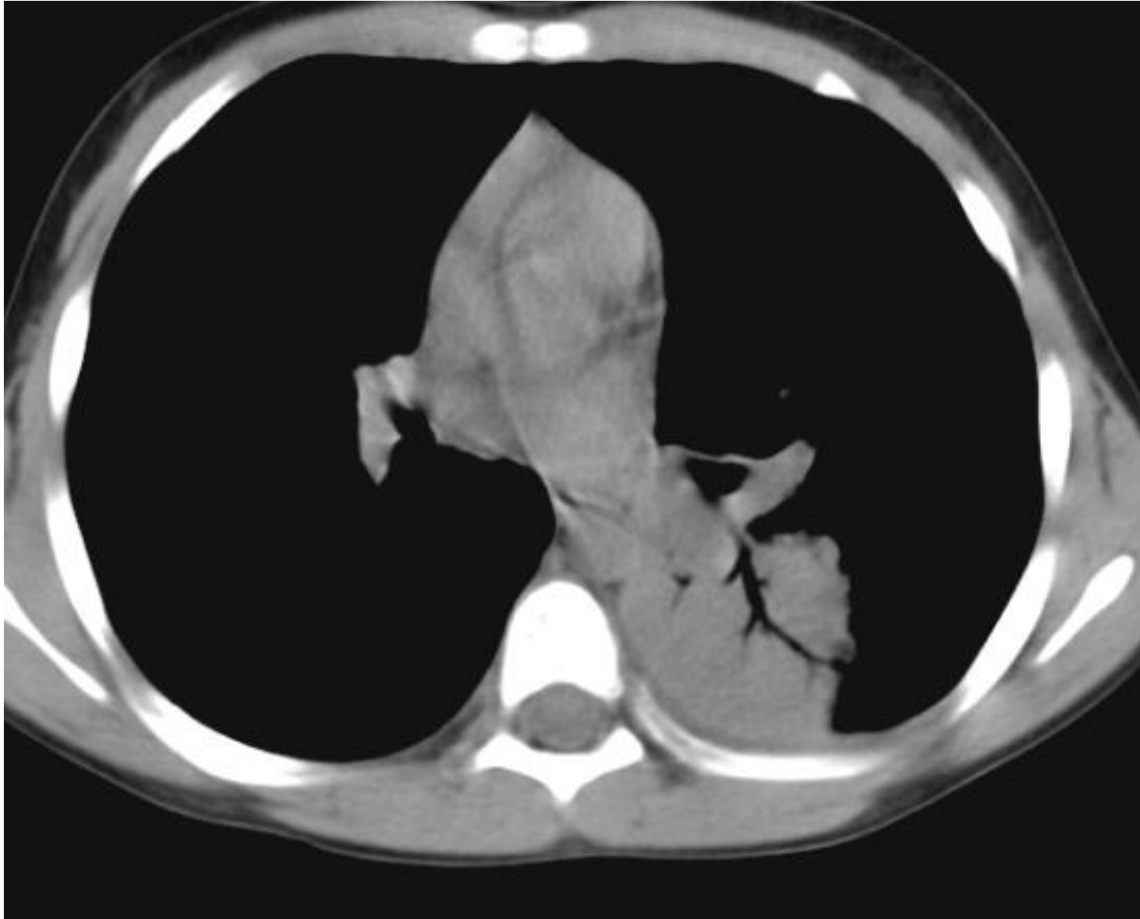


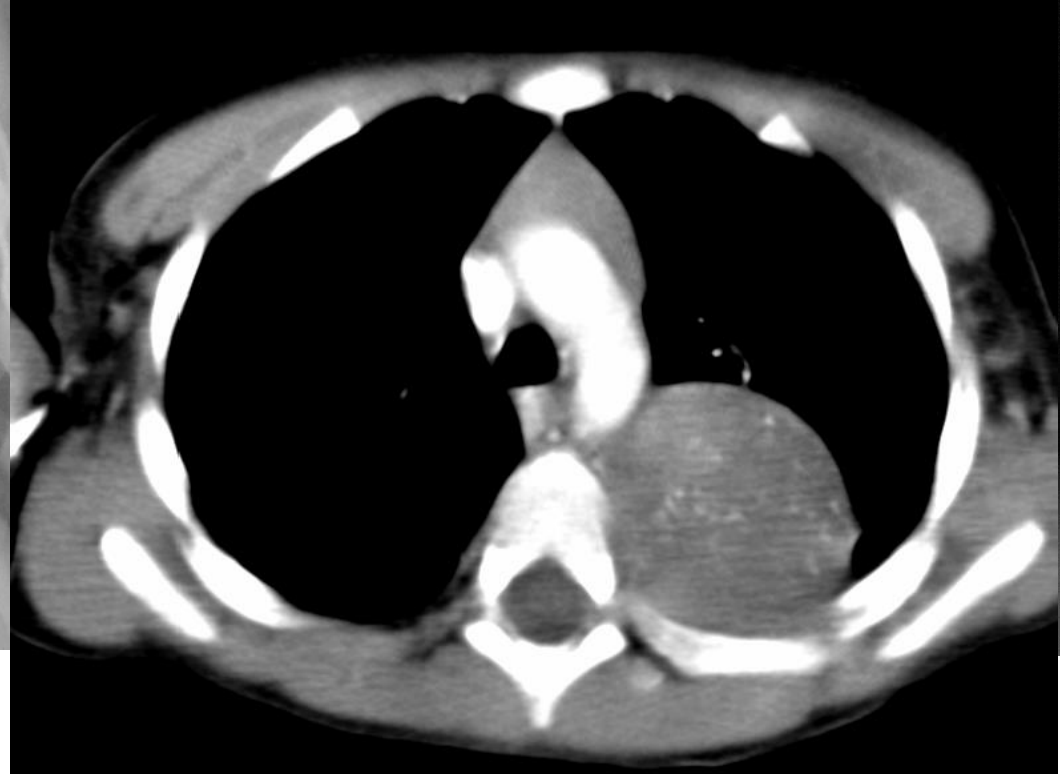
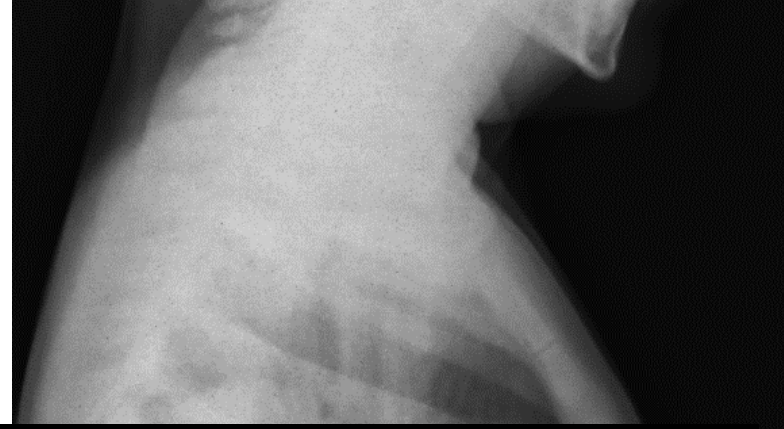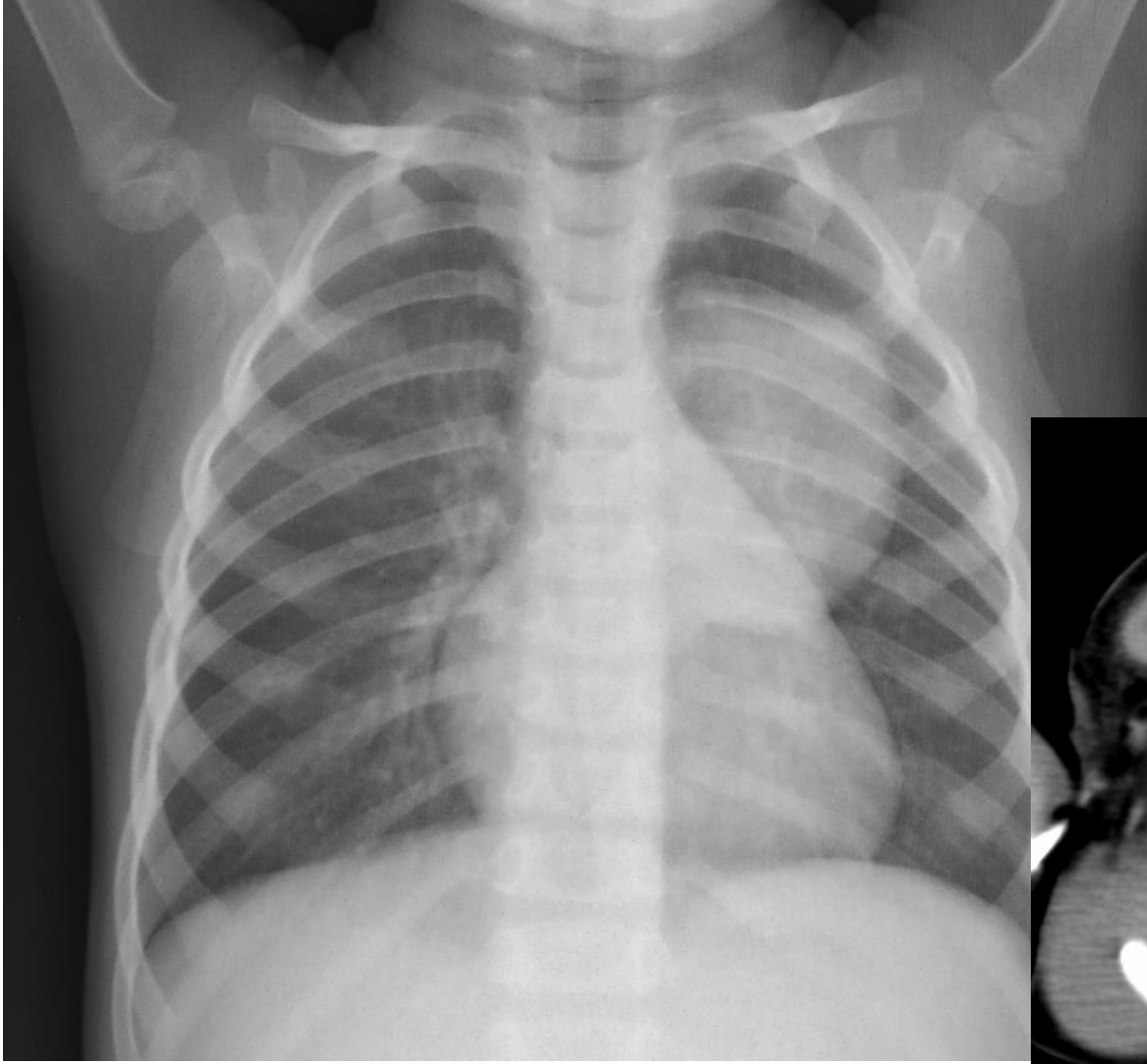
10 yaşında çocuk olgu
PA grafideki lezyon için

- a) Mediastinal kitle
- b) Pnömoni
- c) Hiler kitle
- d) Sekestrasyon
- e) Göğüs duvarı lezyonu

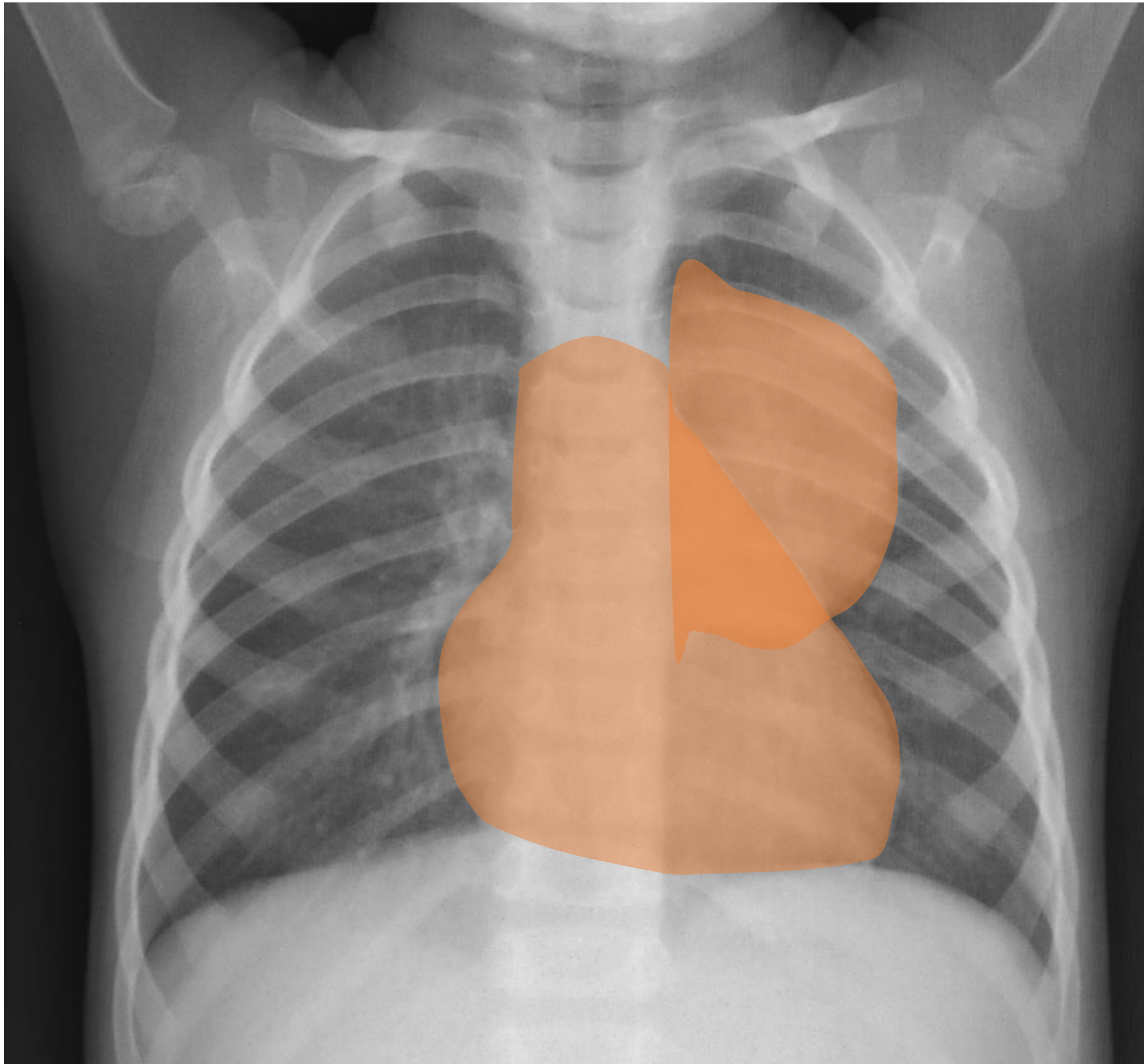


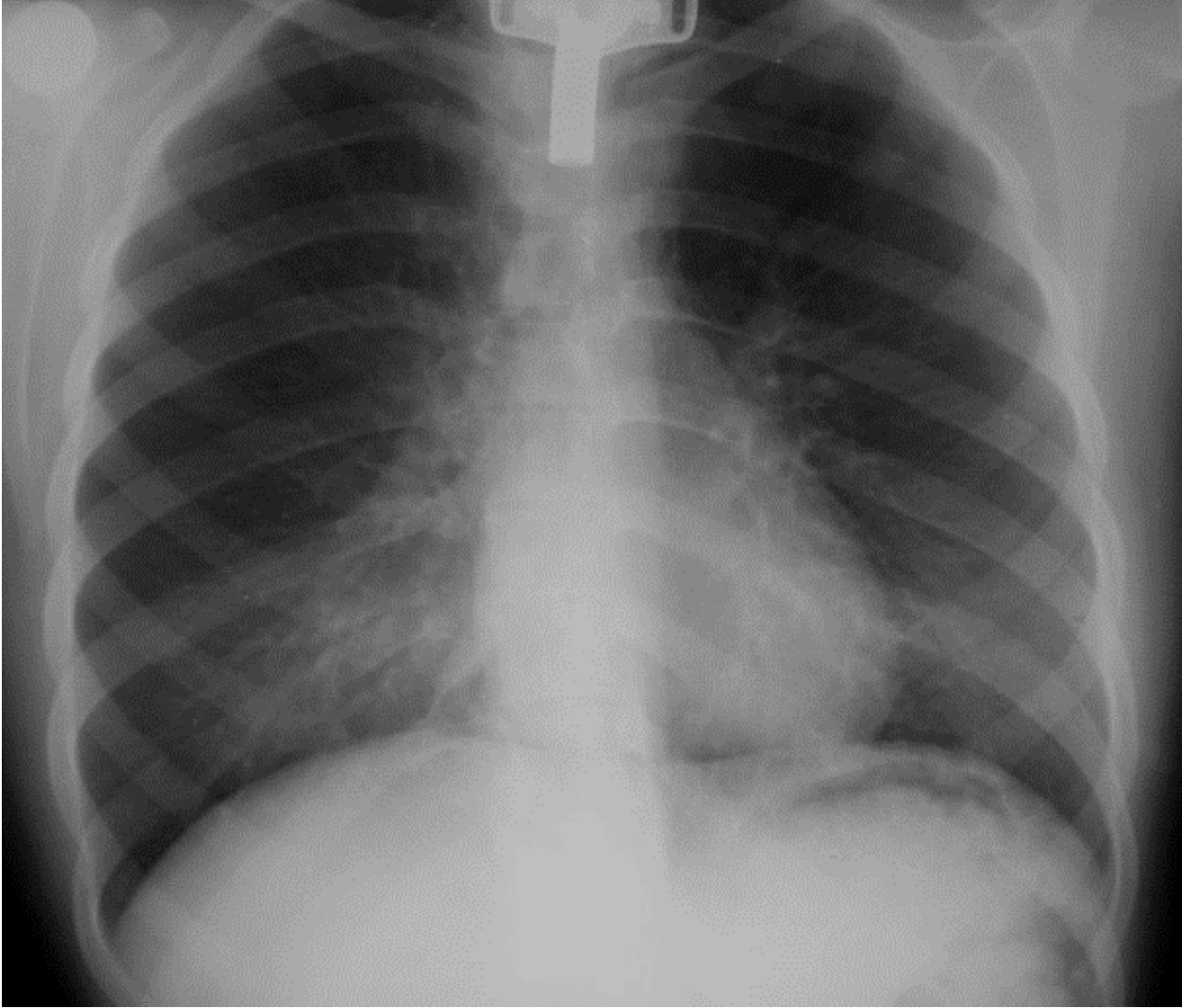


SOL ALT LOBDA PNÖMONİ



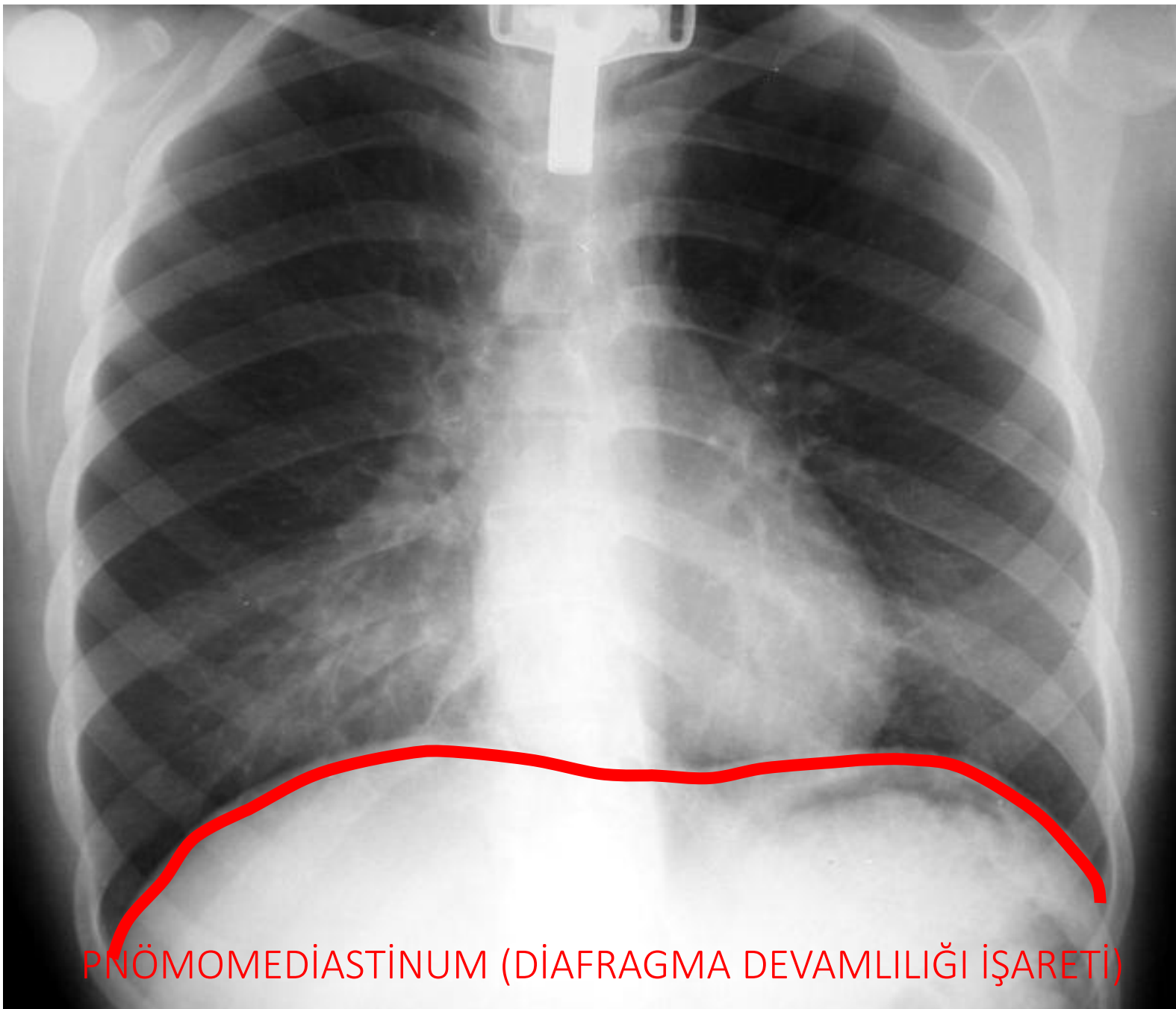
NÖROJENİK KİTLE



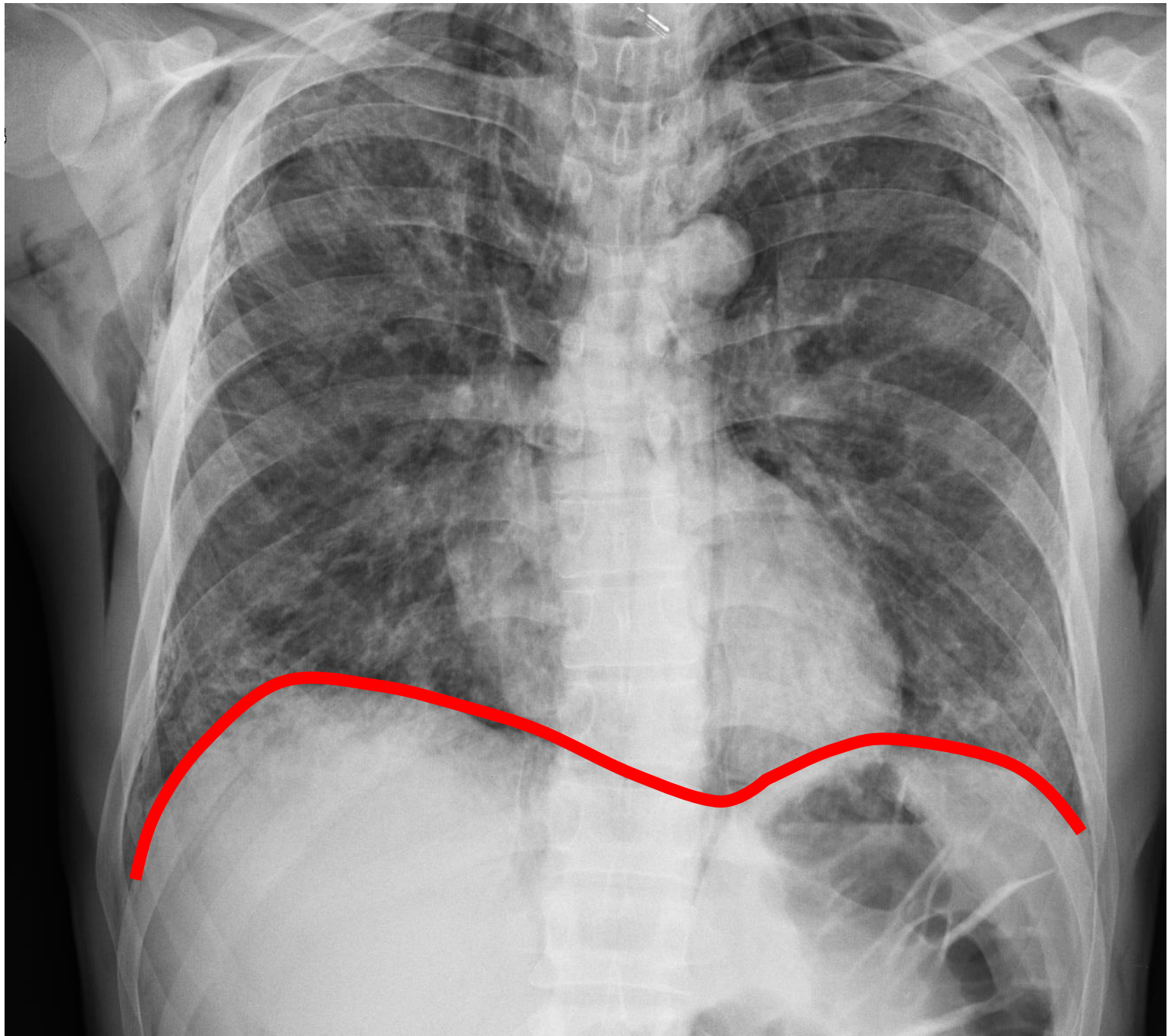


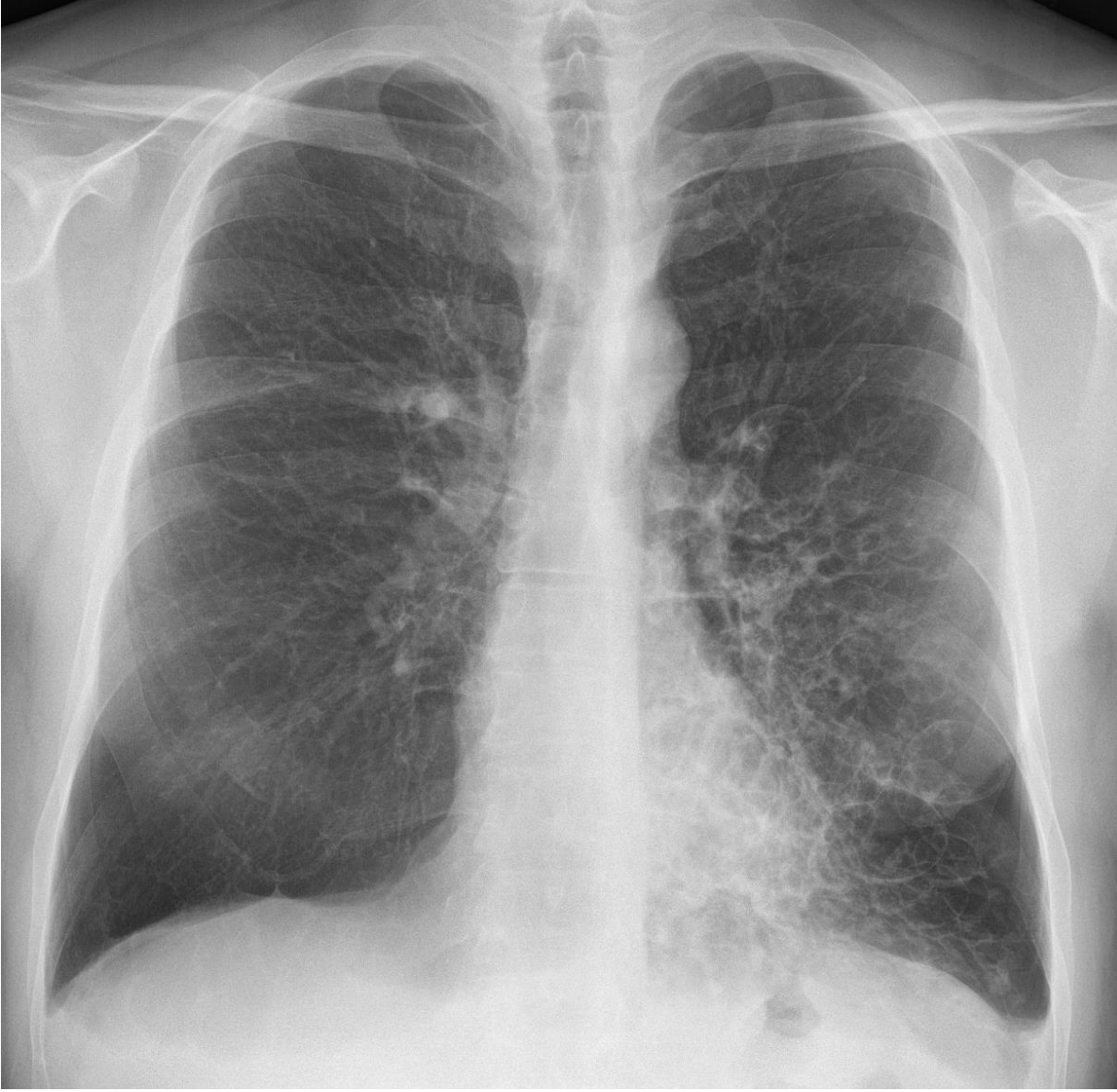16 yaşında Down sendromu olgu
Trakeostomi açılmış
PA grafide görülen bulgu nedir?

- a) Derin sulkus işareti
- b) Çift diyafragma işareti
- c) Düşmüş akciğer işareti
- d) Diyafram devamlılığı işareti
- e) Tam olmayan kenar işareti



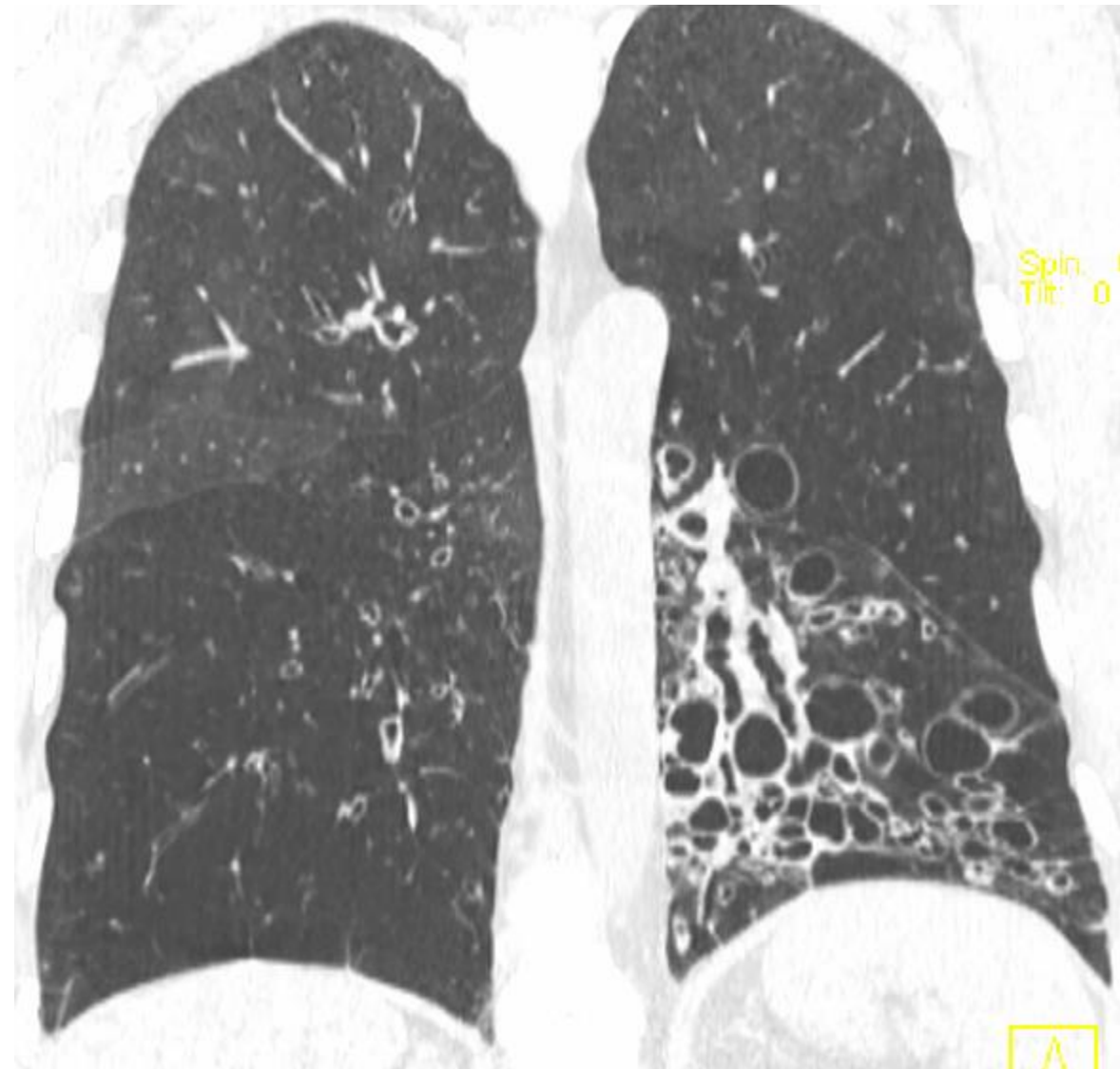
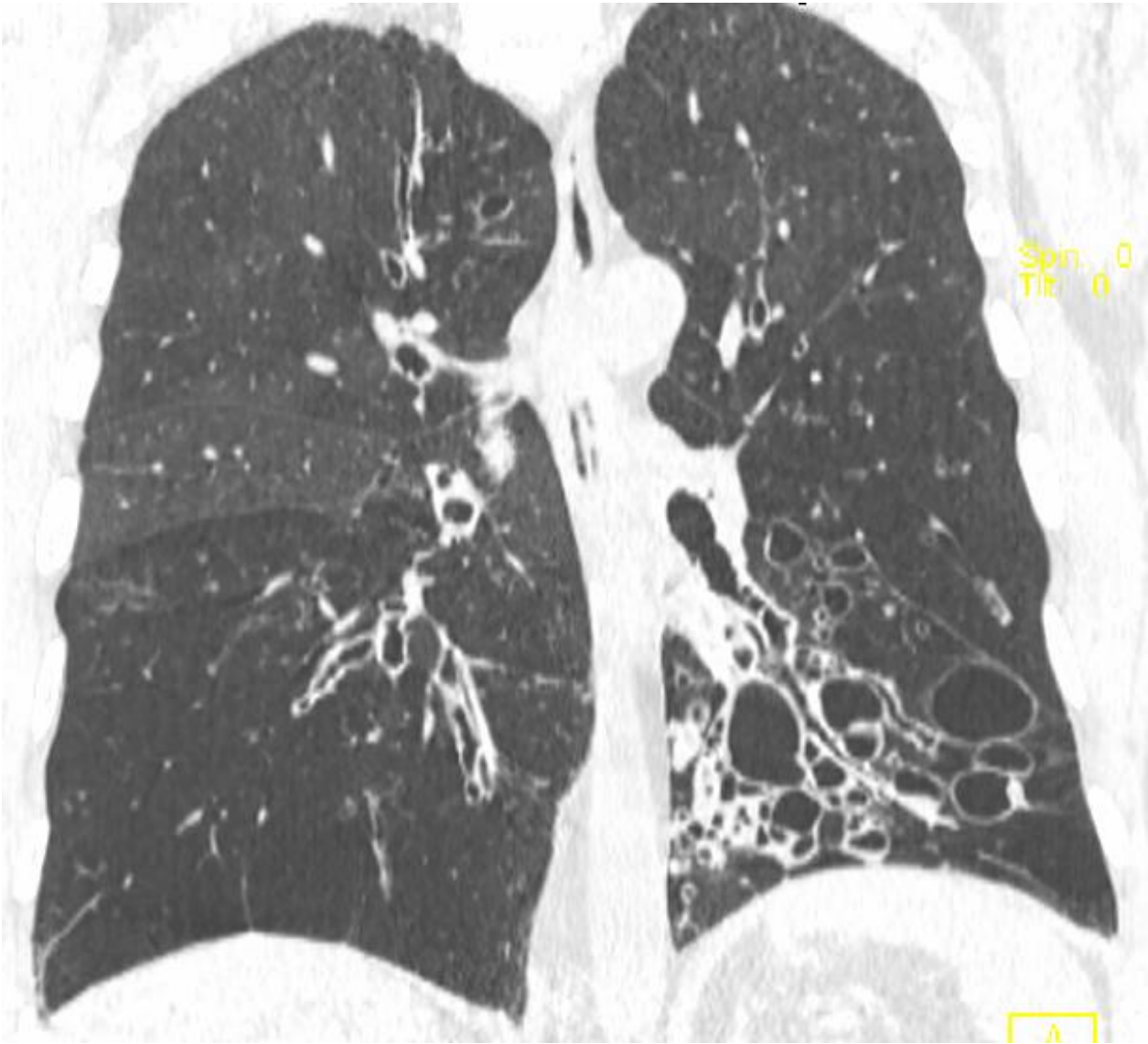
PNÖMOMEDIASTINUM (DİAFRAGMA DEVAMLILIĞI İŞARETİ)





52 yaşında erkek olgu
Öksürük, balgam şikayeti mevcut
Grafı için tanınız nedir ?

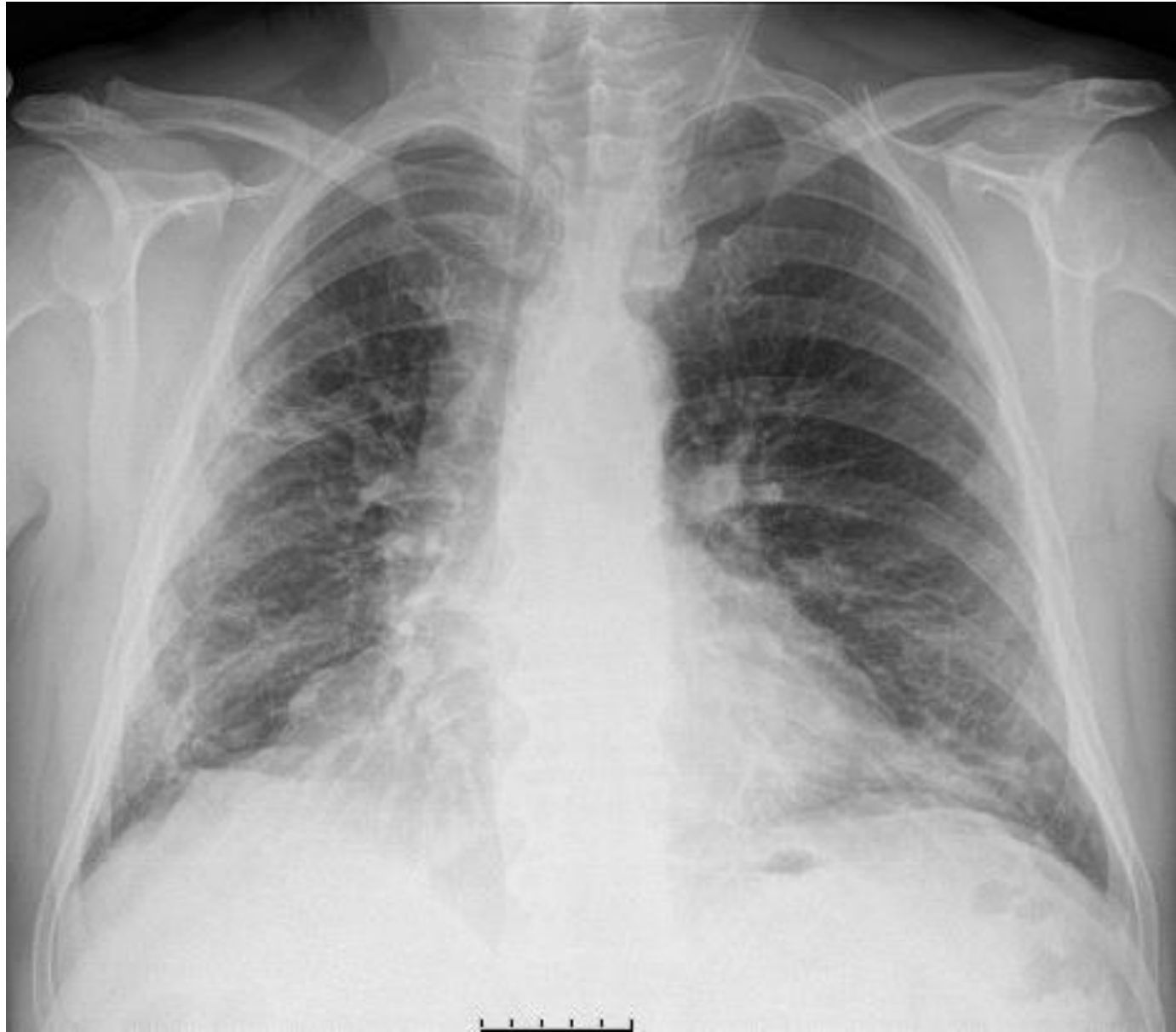
- a) Kist hidatik
- b) ABPA
- c) Bronşektazi
- d) Pulmoner ödem
- e) LİP



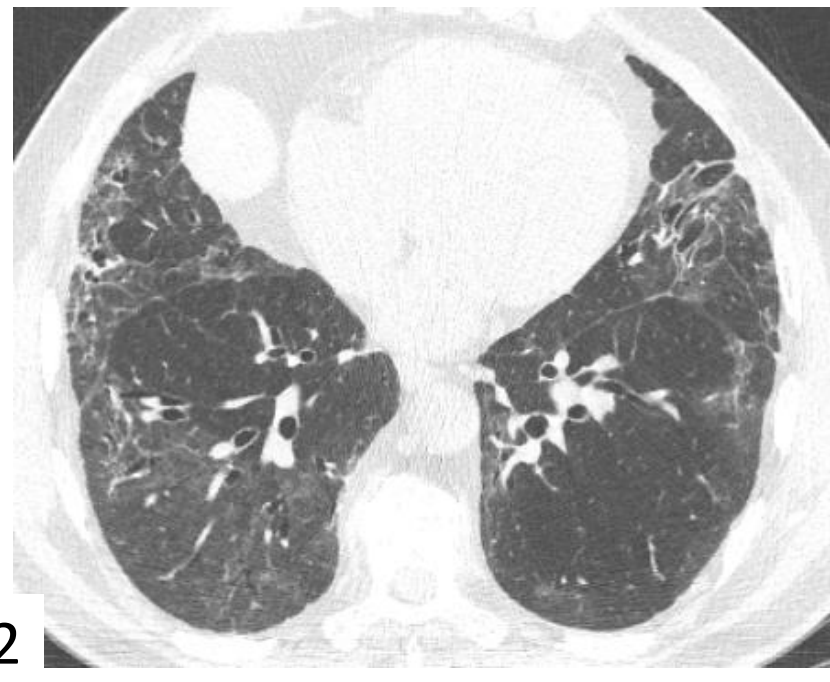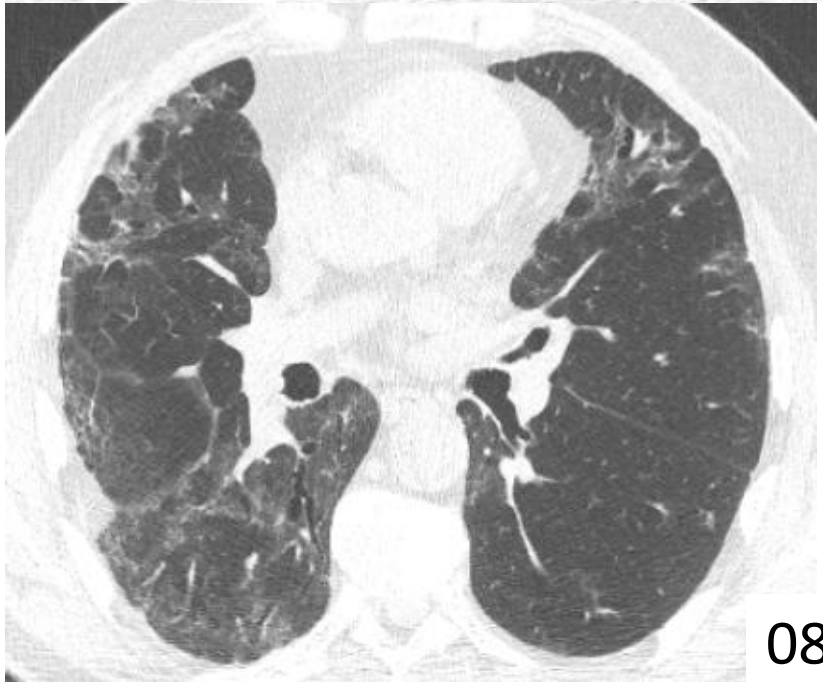
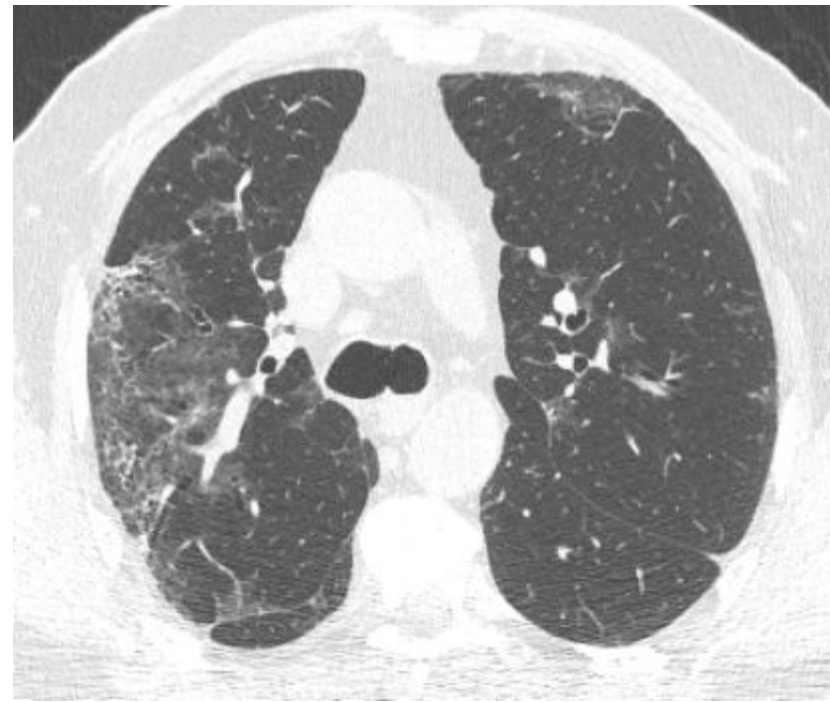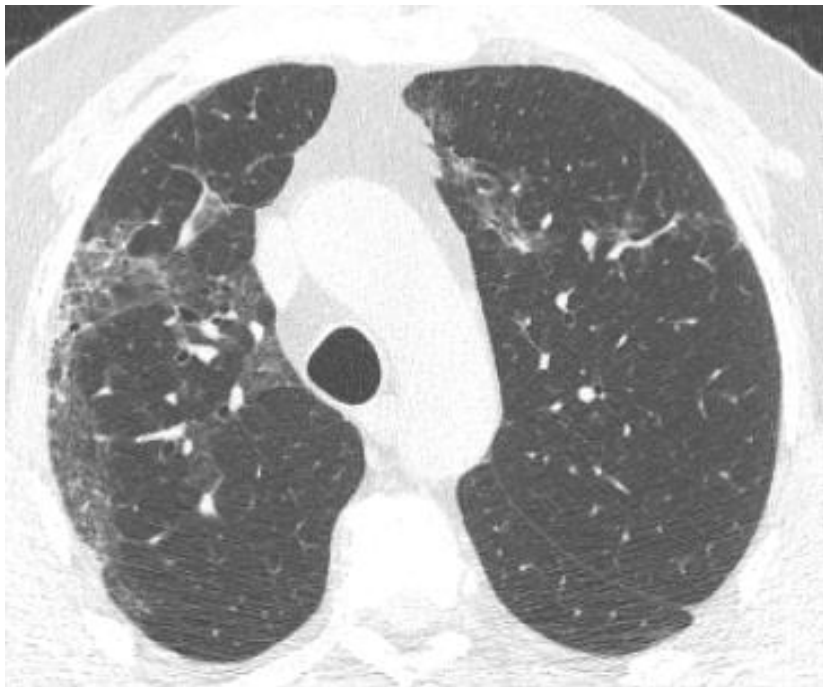
BRONŞEKTAZİ

OLGU

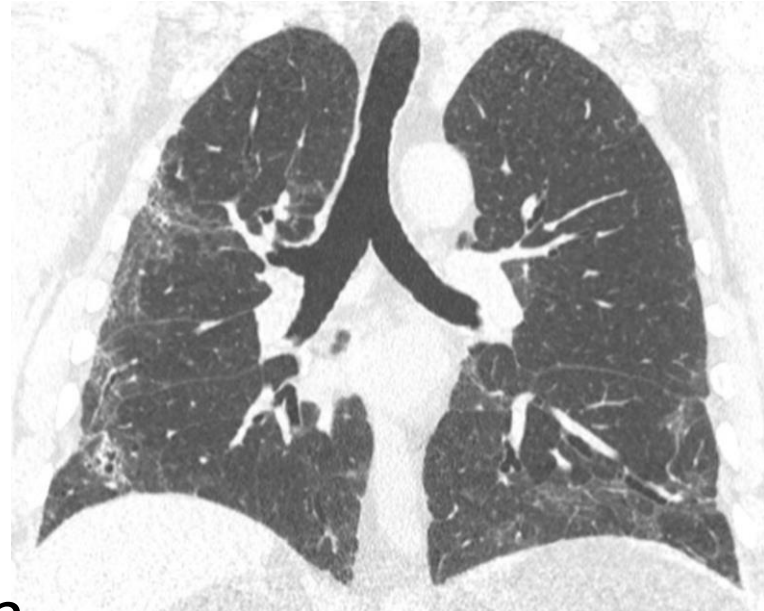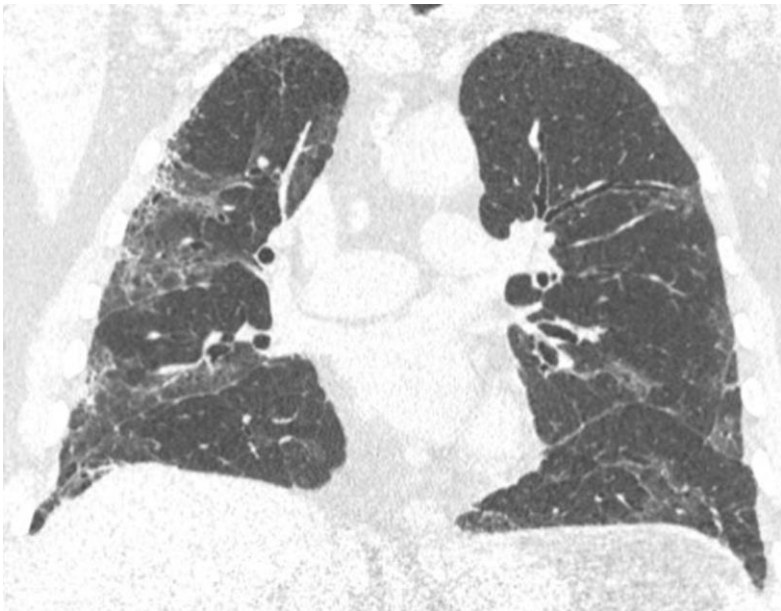
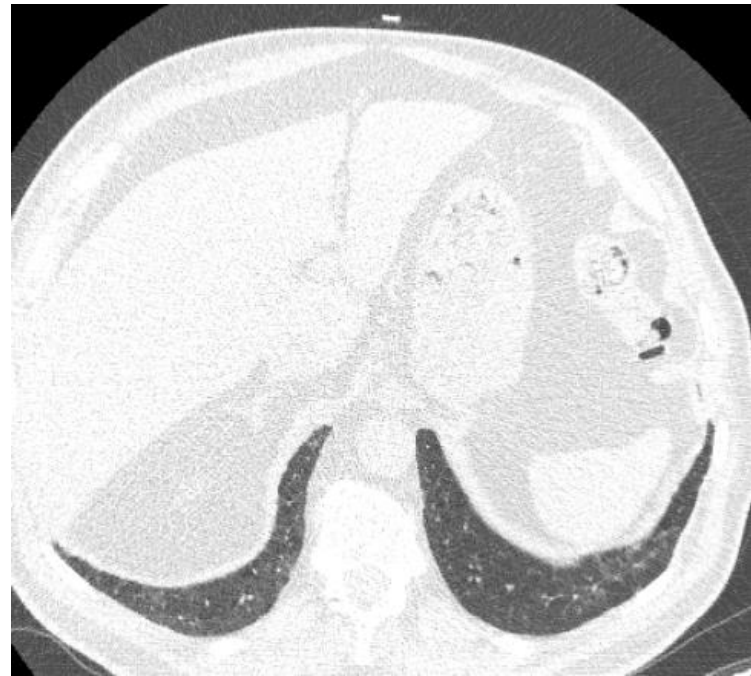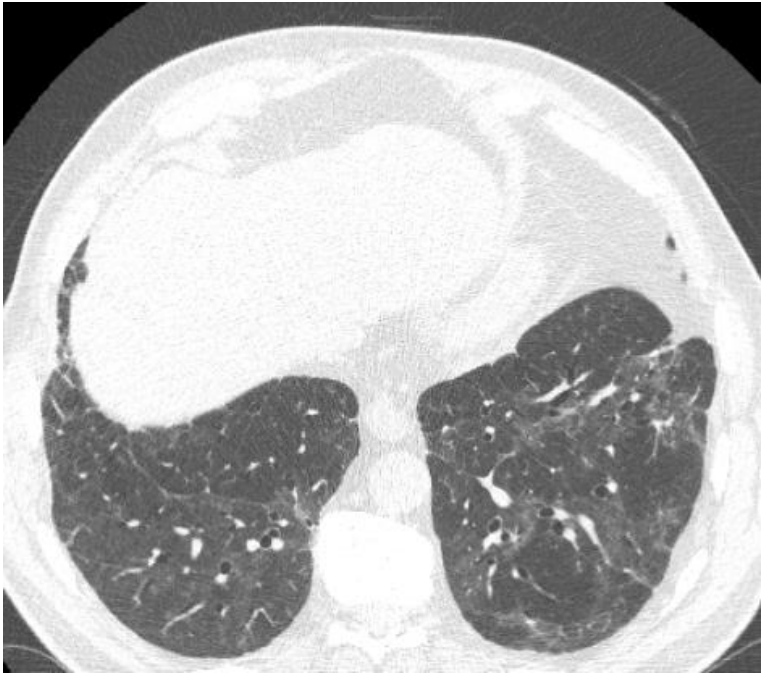
- 59 yaşında erkek
- Diabetes Mellitus (+),
- **3-4 aydır geçmeyen solunum sıkıntısı** nedeniyle PA akciğer grafisi ve YRBT çekiliyor.



08.03.2022



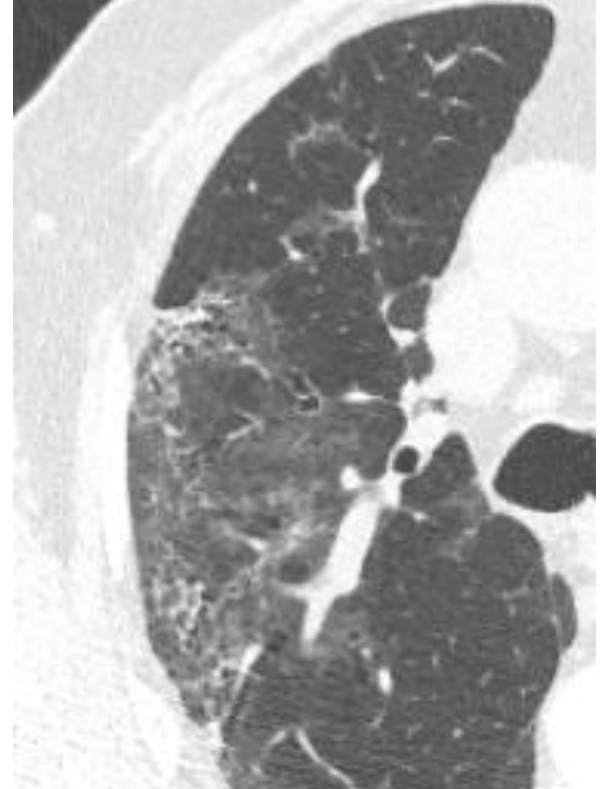
08.03.2022



08.03.2022

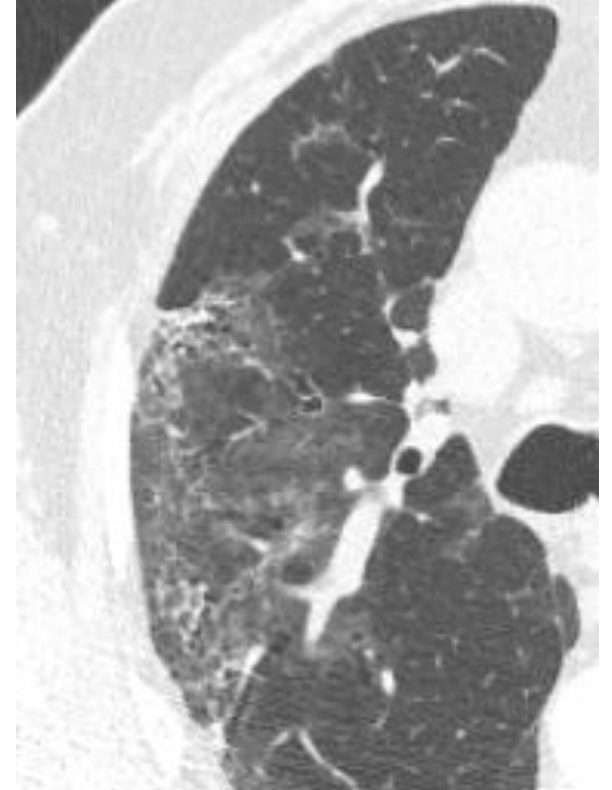
Radyolojik bulguları için en doğru yanıt hangisidir?

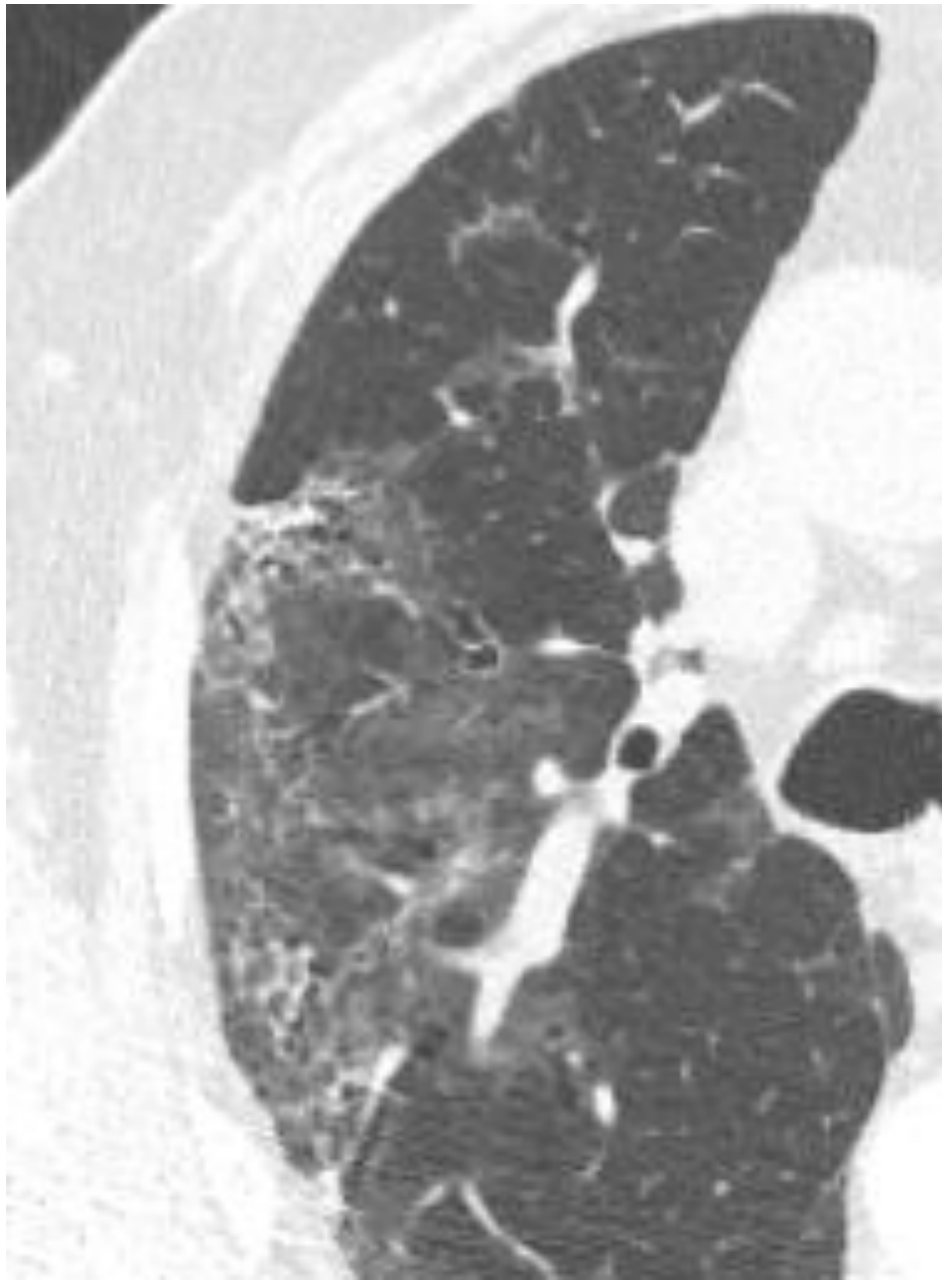
- a) Buzlu cam ve atelektazi
- b) Traksiyon bronşektazisi ve buzlu cam
- c) Headcheese sign
- d) Amfizem, buzlu cam ve mozaik patern
- e) Hava kistleri ve fibrotik bantlar



Radyolojik bulguları için en doğru yanıt hangisidir?

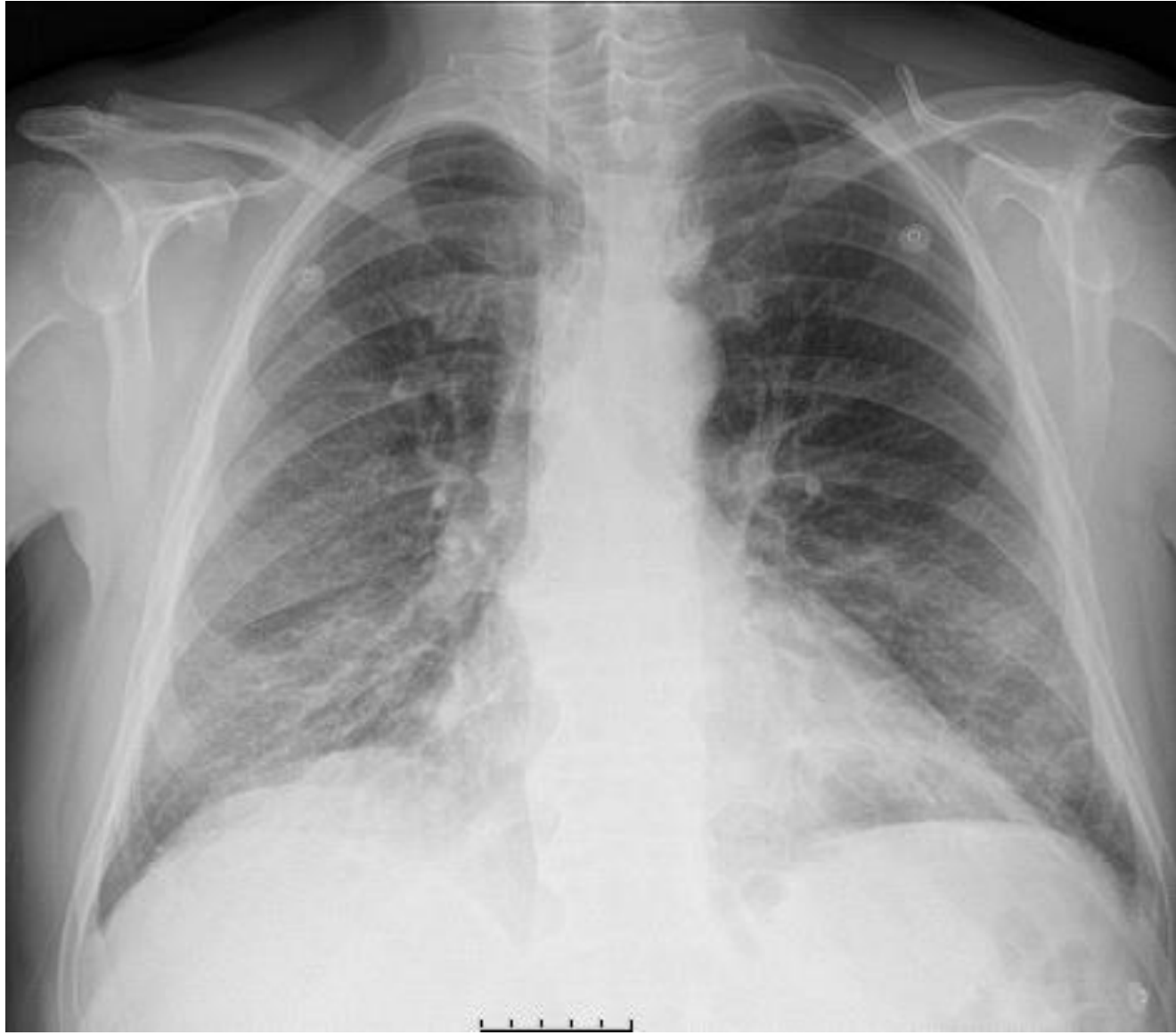- a) Buzlu cam ve atelektazi
- b) Traksiyon bronşektazisi ve buzlu cam**
- c) Headcheese sign-
- d) Amfizem, buzlu cam ve mozaik patern
- e) Hava kistleri ve fibrotik bantlar



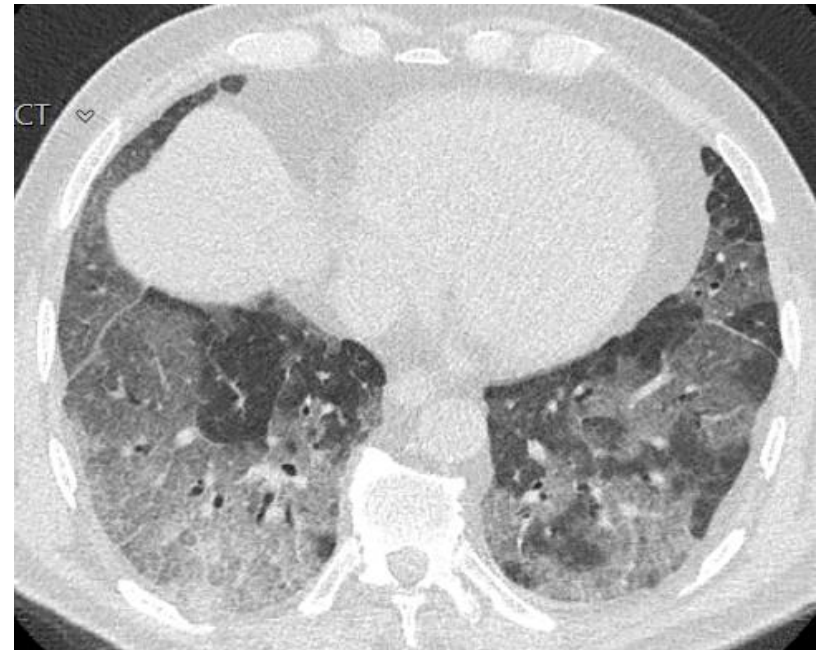
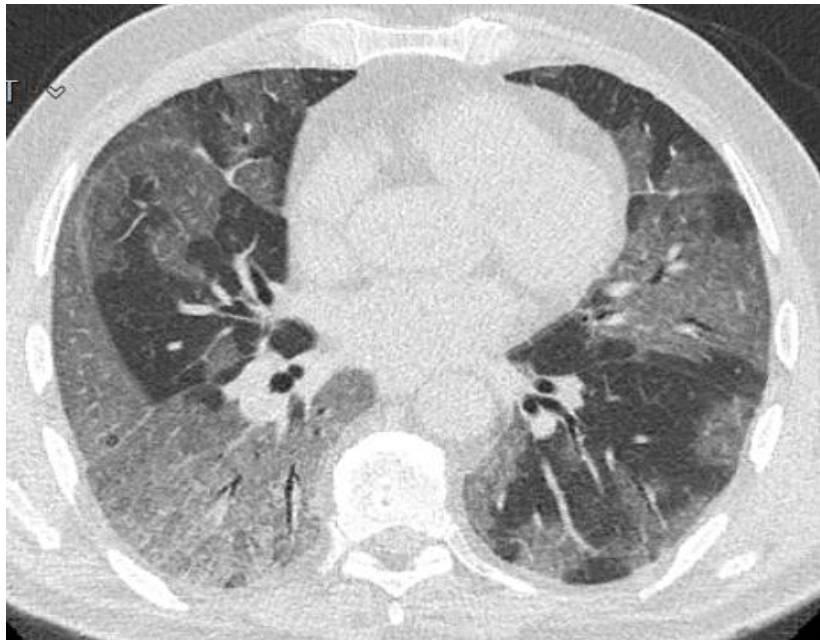
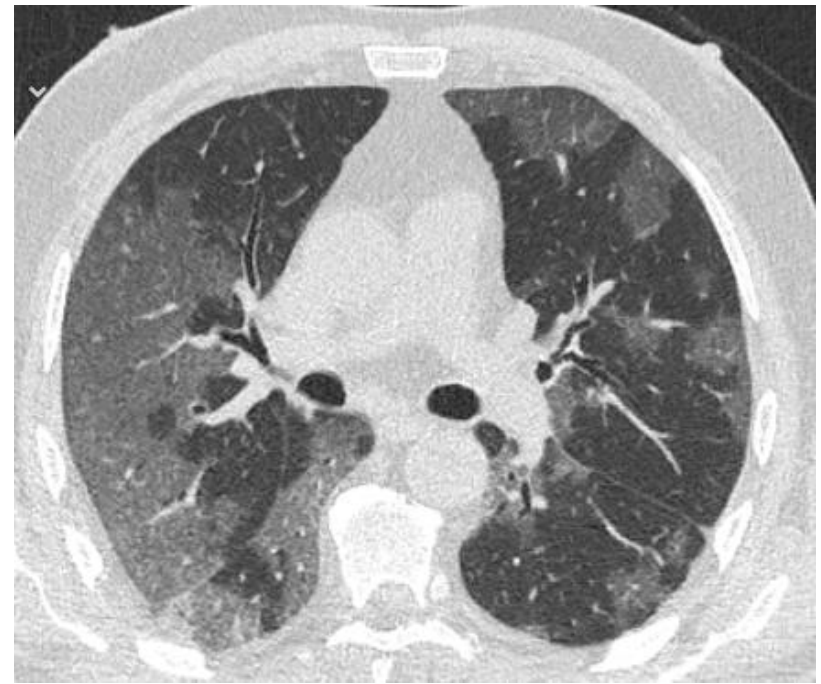
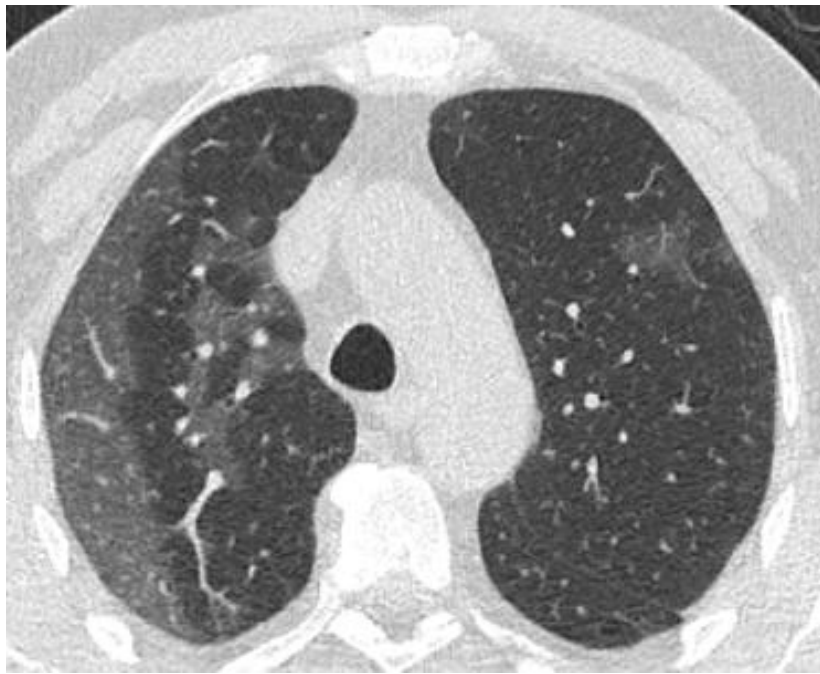

En olası tanı sizce ne olabilir?

- a) İlaç reaksiyonu
- b) Kronik eozinofilik pnömoni
- c) Bağ dokusu hastalığı
- d) Olası UIP
- e) Postenfeksiyöz süreç



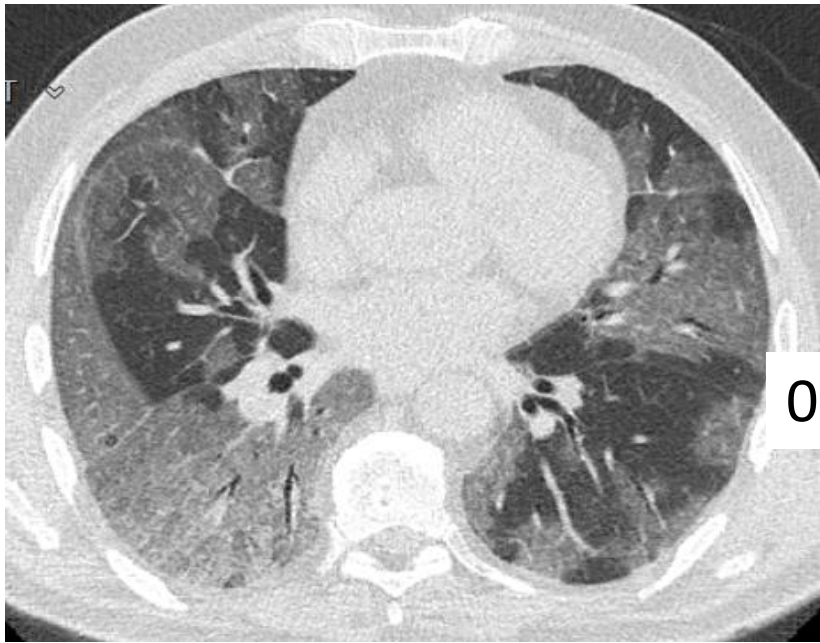
05.11.2021



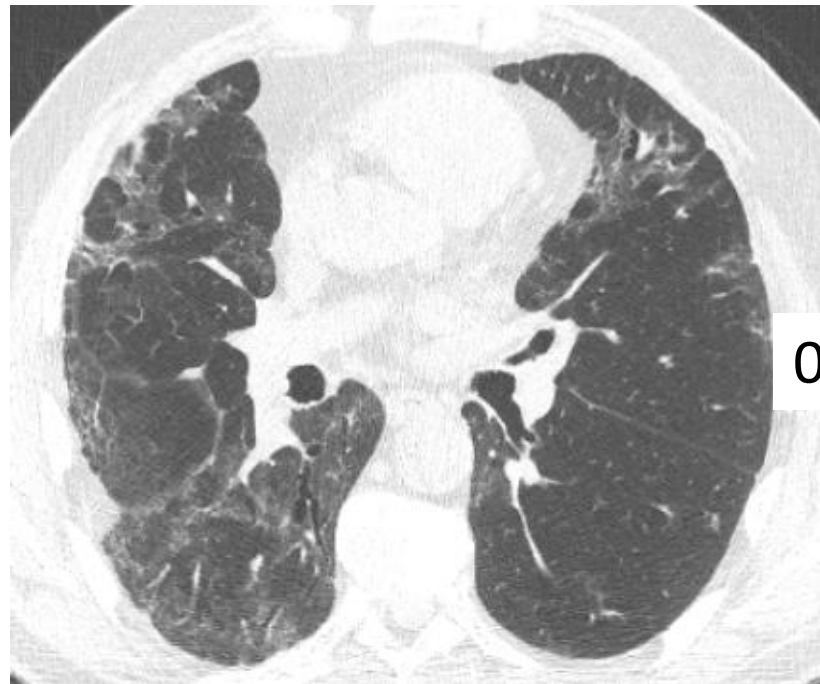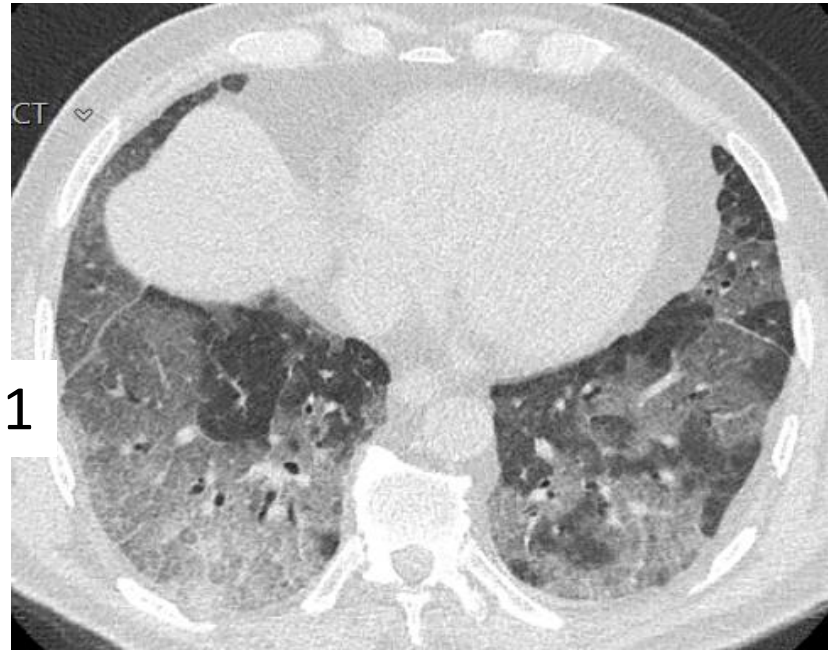
05.11.2021

3 ay önceki BT için tanınız ne olurdu?

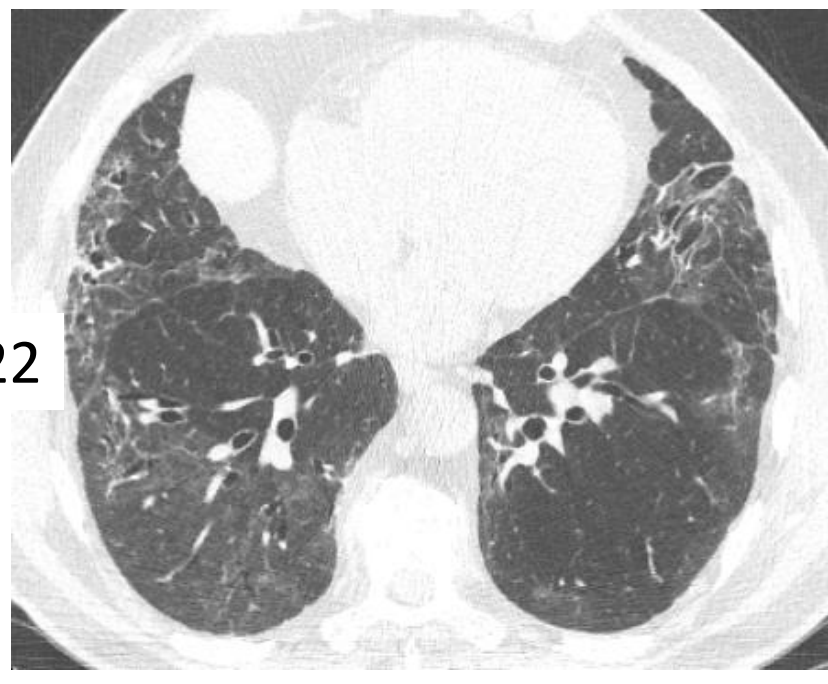- a) Covid 19 enfeksiyonu
- b) Alveoler proteinozis
- c) Kronik eozinofilik pnömoni
- d) İlaç reaksiyonu
- e) SLE-Bağ dokusu hastalığı



05.11.2021



08.03.2022



Şimdi son kararınız ne olur?

- a) Covid 19 enfeksiyonu
- b) Alveoler proteinozis
- c) Kronik eozinofilik pnömoni
- d) İlaç reaksiyonu
- e) SLE-Bağ dokusu hastalığı

Şimdi son kararınız ne olur?

- a) Covid 19 enfeksiyonu
- b) Alveoler proteinozis
- c) Kronik eozinofilik pnömoni
- d) İlaç reaksiyonu
- e) SLE-Bağ dokusu hastalığı

UZUN DÖNEM AKCİĞER BT BULGULARI

- Tamamen iyileşebilir,
 - Septal kalınlaşmalar, kaba retiküler patern,
 - Fibröz bant ve irregüler arayüz bulguları kalıcı olabilir,
 - Bronşial dilatasyon,
 - Mozaik atenüasyon,**
 - Volüm kaybı gelişebilir.
 - En son olarak traksiyon bronşektazisi ve **nadiren bal peteği**
- Bulgular, her iki akciğer alt loblarında en belirgin.**

PULMONER FİBROZİS İÇİN RİSK FAKTÖRLERİ

İnfeksiyon öncesi risk faktörleri

- Erkek cinsiyet
- İleri yaş
- Aktif sigara içiciliği
- Diabet
- Kronik akciğer hastalıkları
- Kardiyovasküler hastalıklar
- Diğer komorbid hastalıklar

İnfeksiyon sonrası risk faktörleri

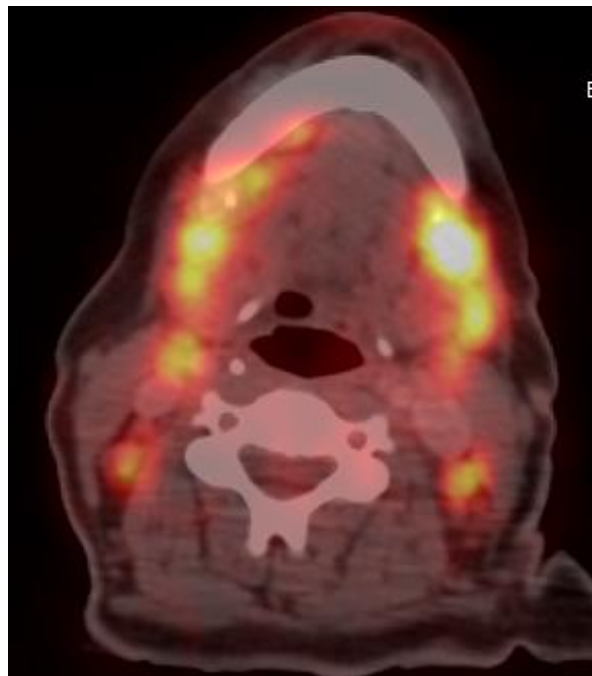
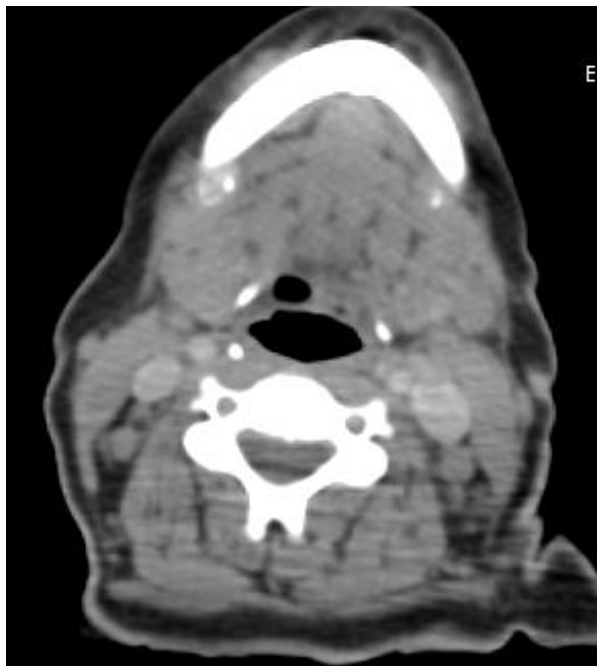
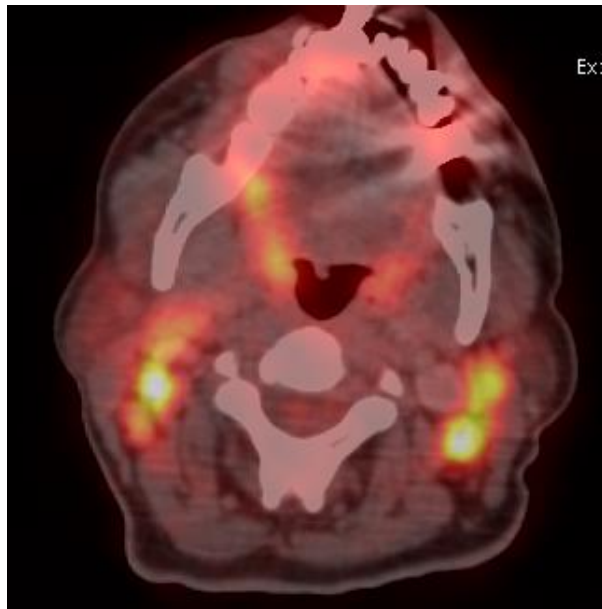
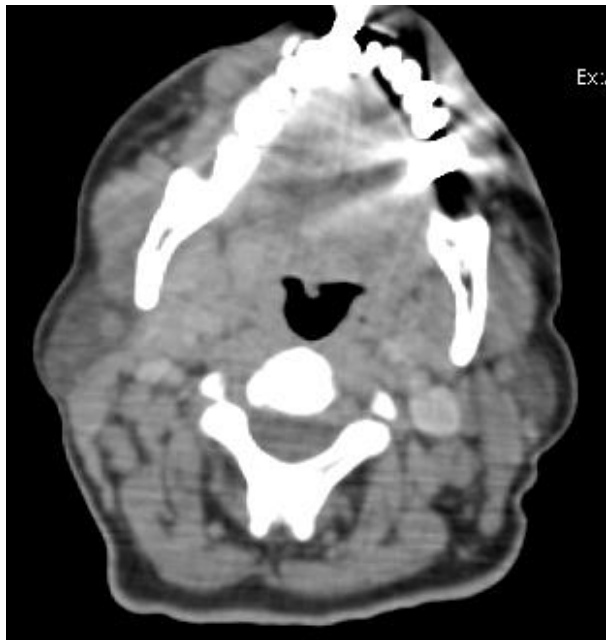- Mekanik ventilator kullanımı
- Yüksek akımlı oksijen gerekliliği
- Akut infeksiyonun ağır seyretmesi (YB ve hastanede uzun kalış)
- ARDS den iyileşmiş olma
- Persistan dispne
- Akciğer BT'de yaygın konsolidasyon ve kaldırım taşı görünümü varlığı
- Sistemik inflamasyon (CRP, IL-6, LDH, D-Dimer seviyelerinde artış, lenfosit sayısında ve interferon- γ seviyesinde azalma)

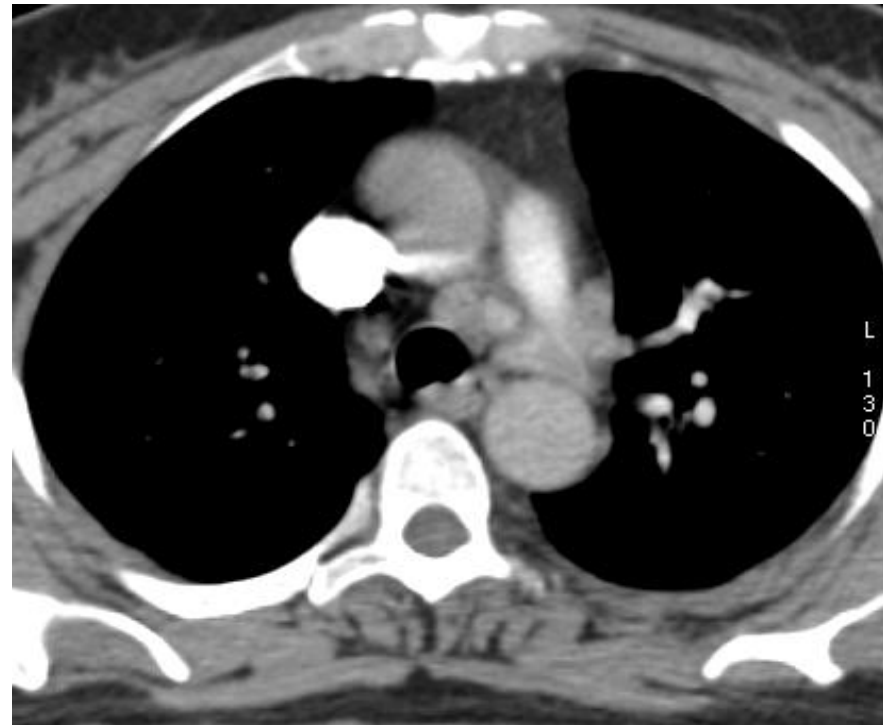
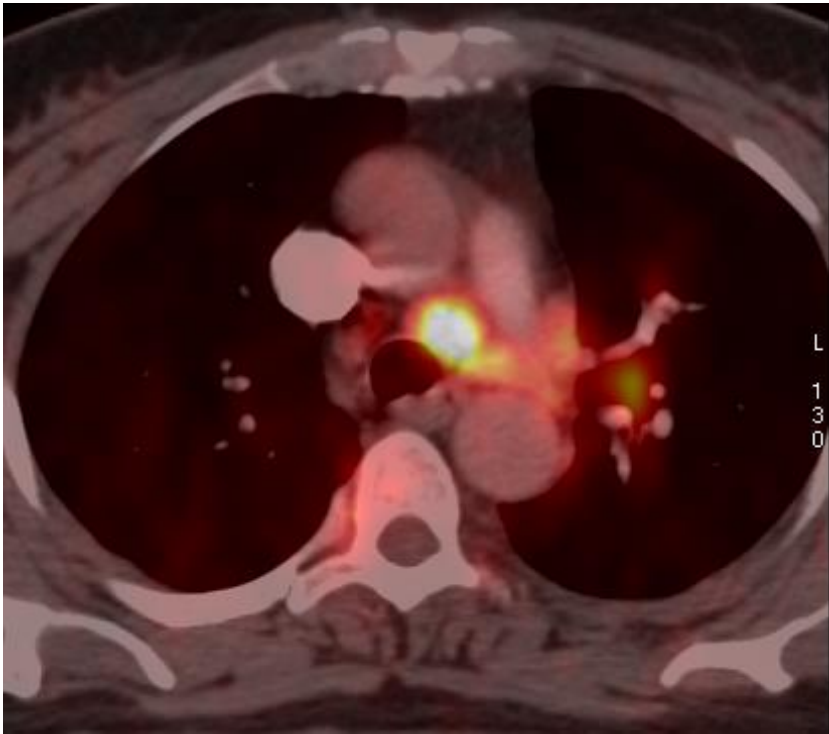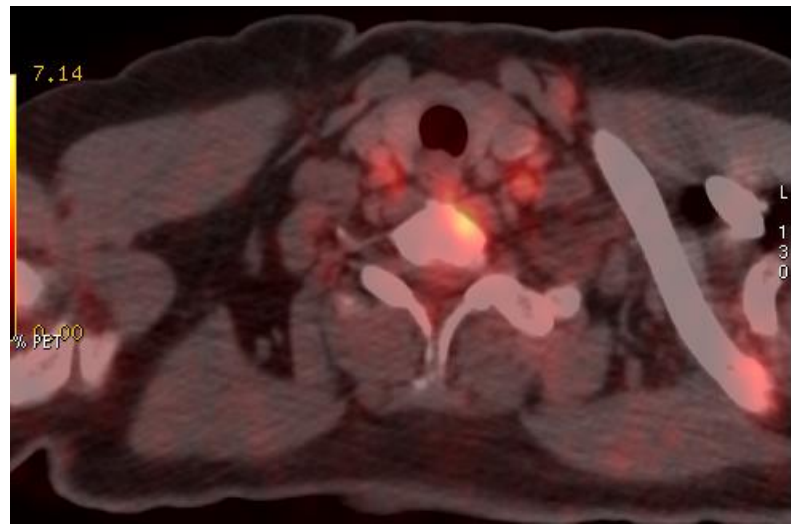
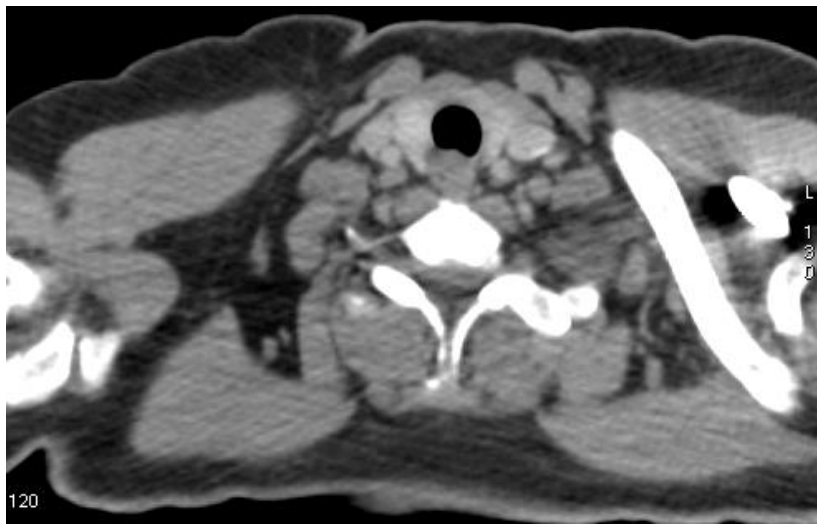
COVID VE FİBROZİS ÖZELLİKLERİ

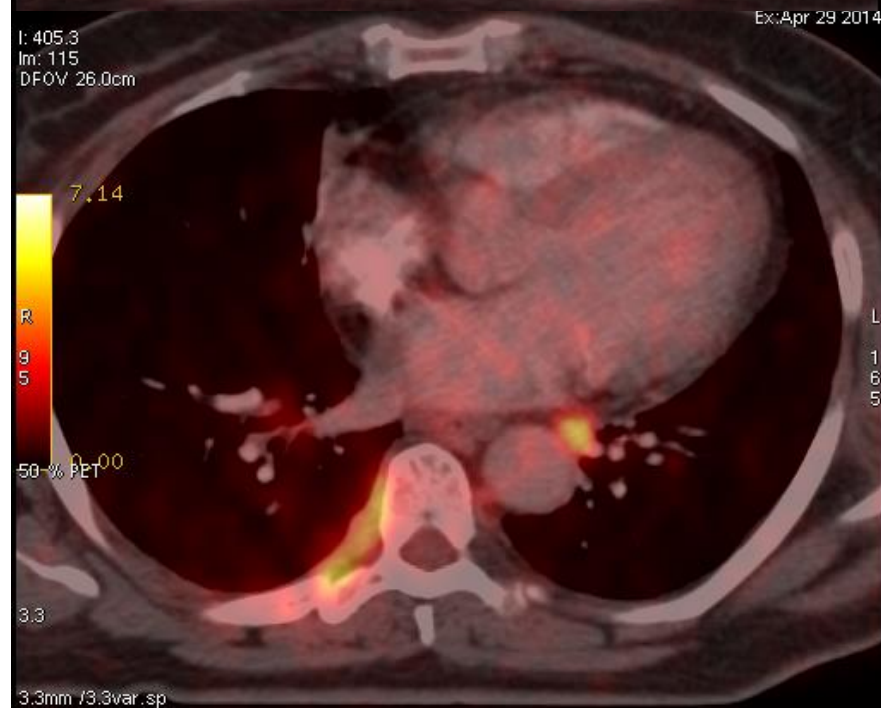
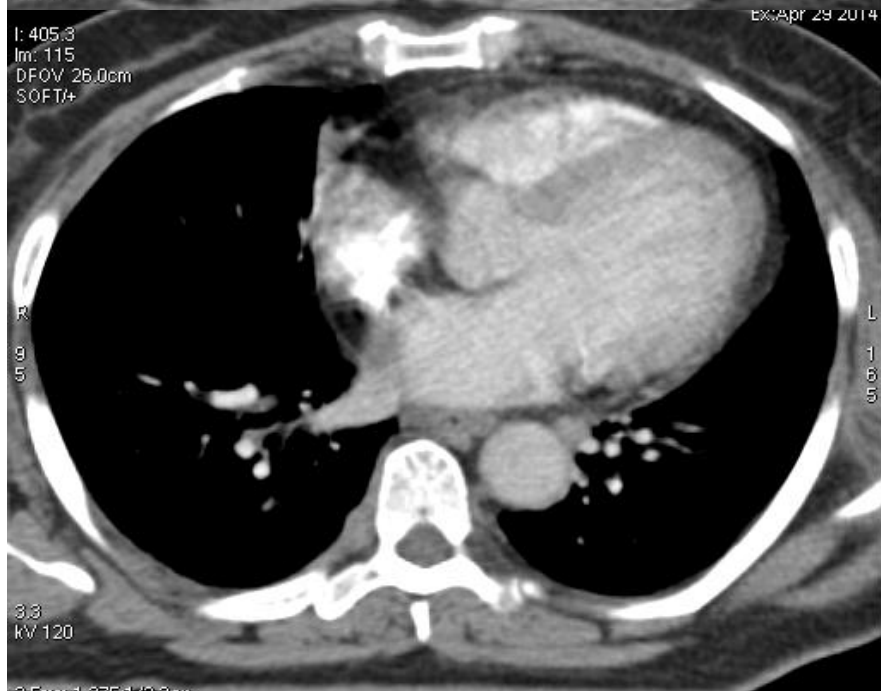
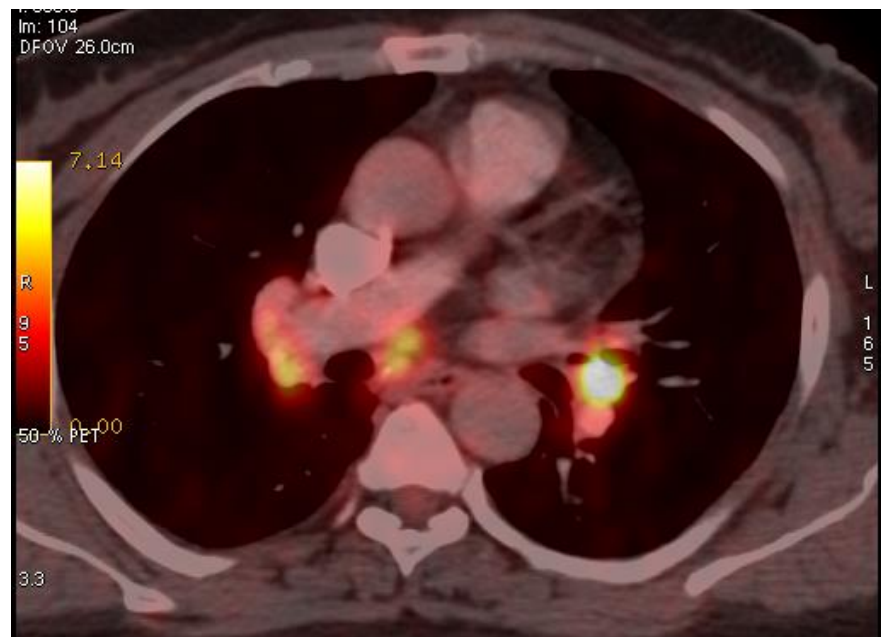
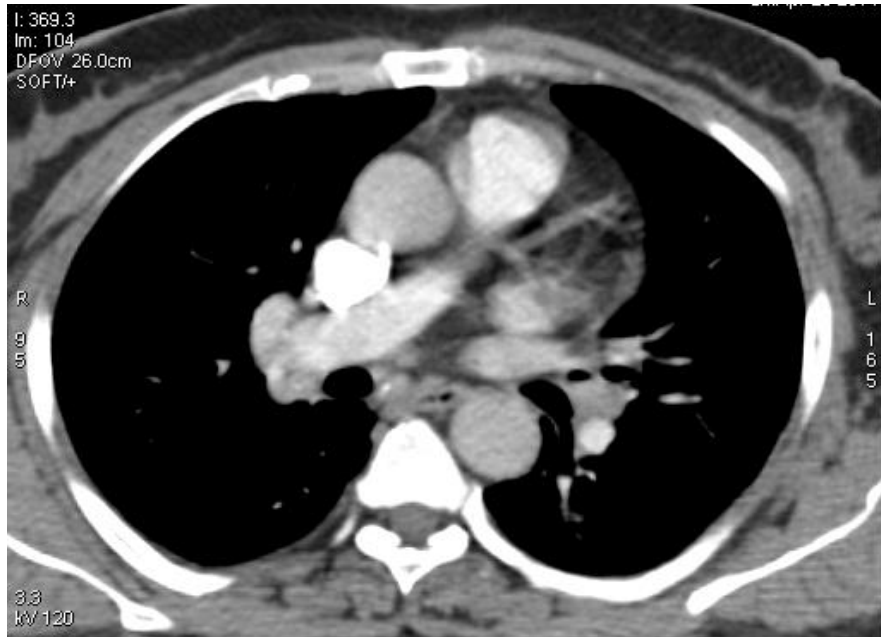- Covid 19 da meydana gelen fibrozis akciğer bazallerinde ve periferik alanda
- **Bal peteđi görünümü ya hiç yok ya da çok az**
- COVID-19 kaynaklı fibrozis **daha çok parankimal bantlar, traksiyon bronşektazisi, hacim kaybı ve parankim yapısında bozulma ile retiküler opasiteler ile karakterizedir.**

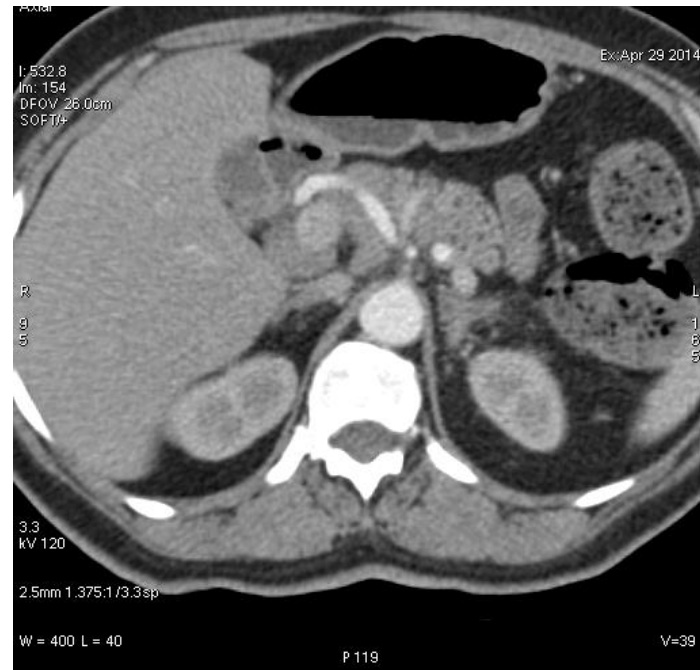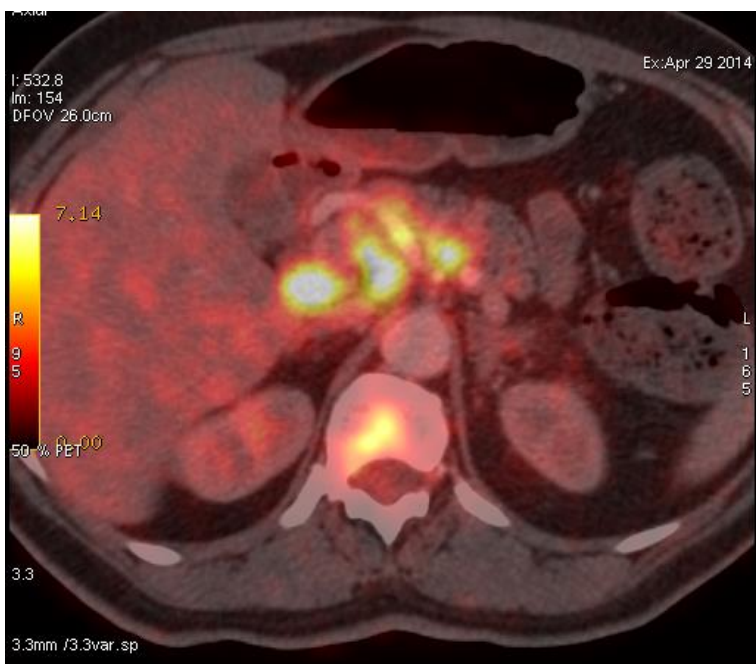
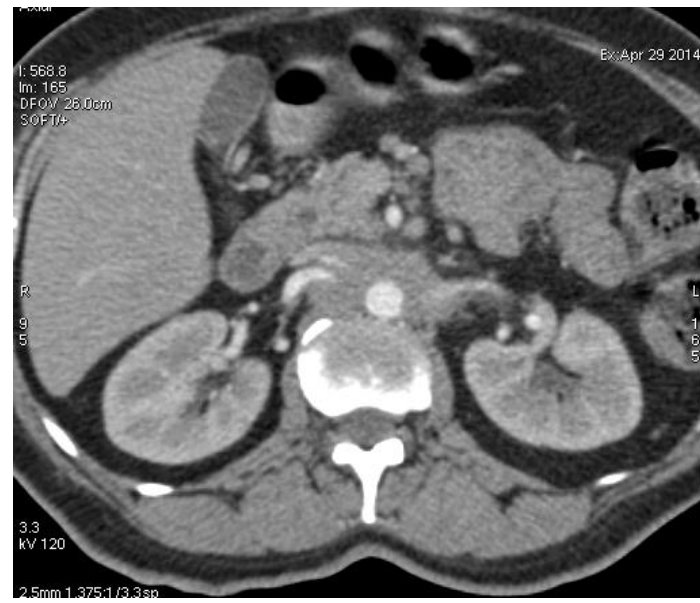
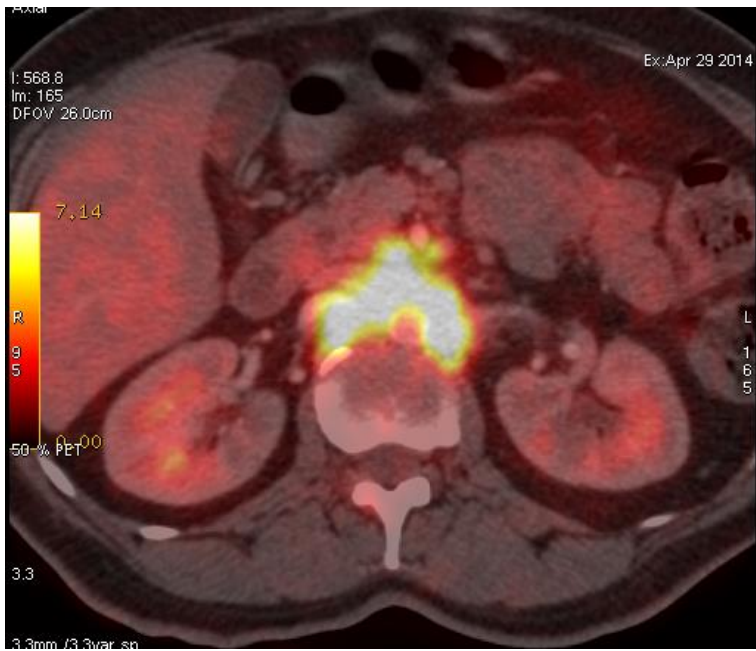
OLGU

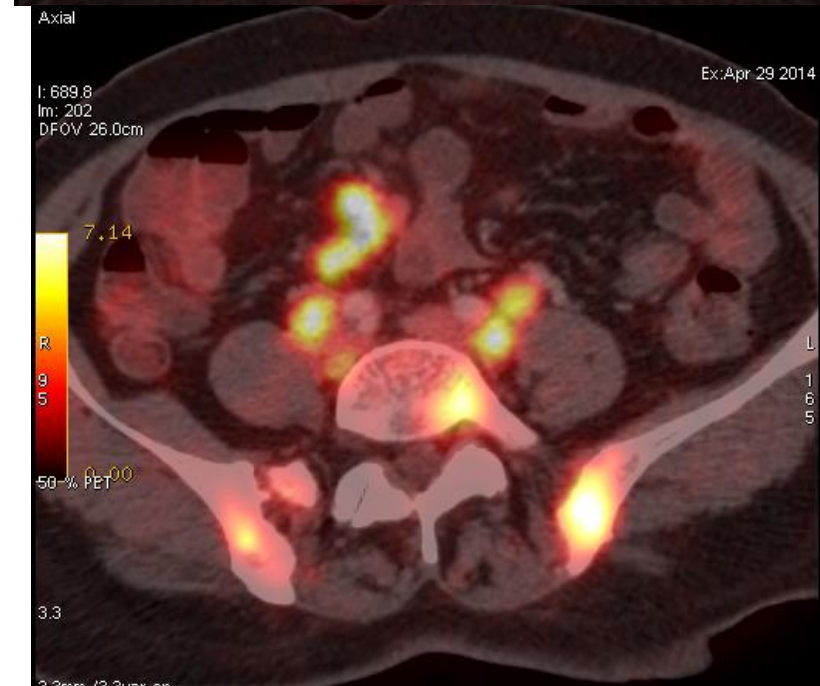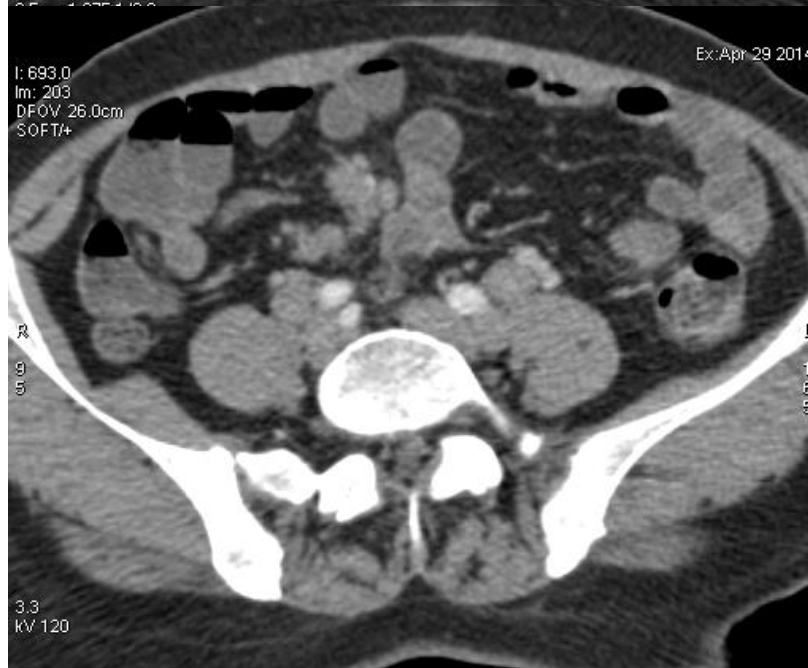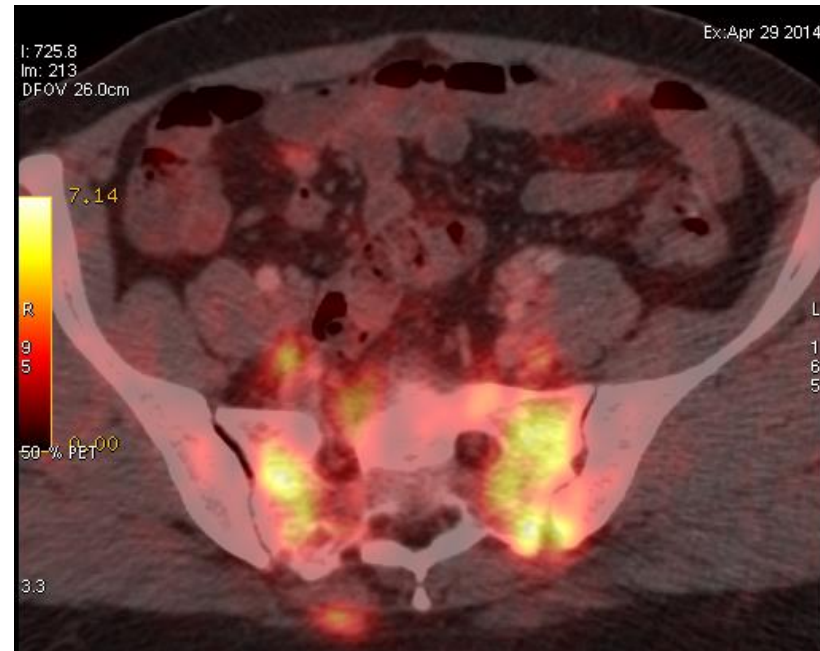
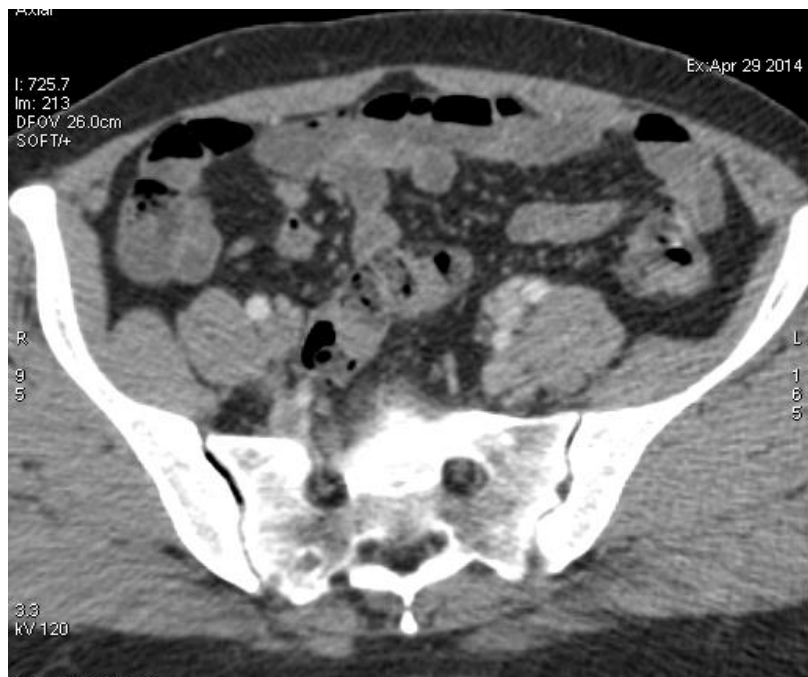- 38 yaşında kadın
- Anemi, kilo kaybı, öksürük şikayetleri var
- Mediastinal LAP tetkik amaçlı PET/BT çekiliyor

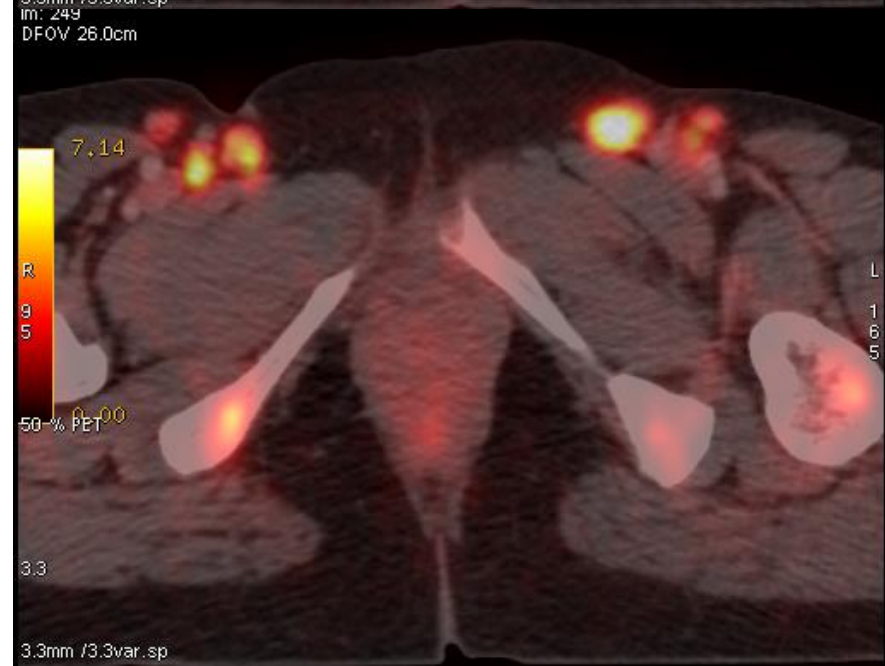
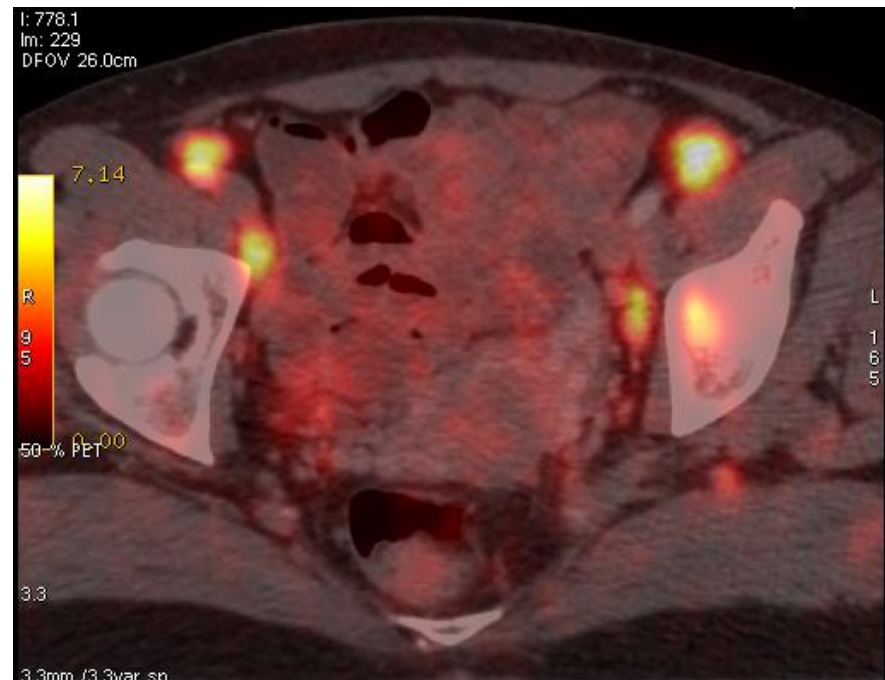
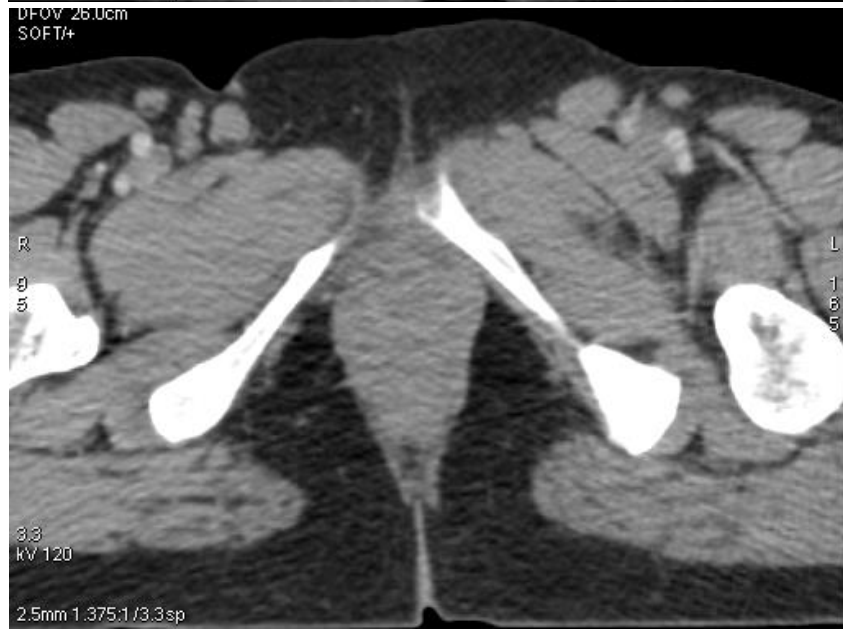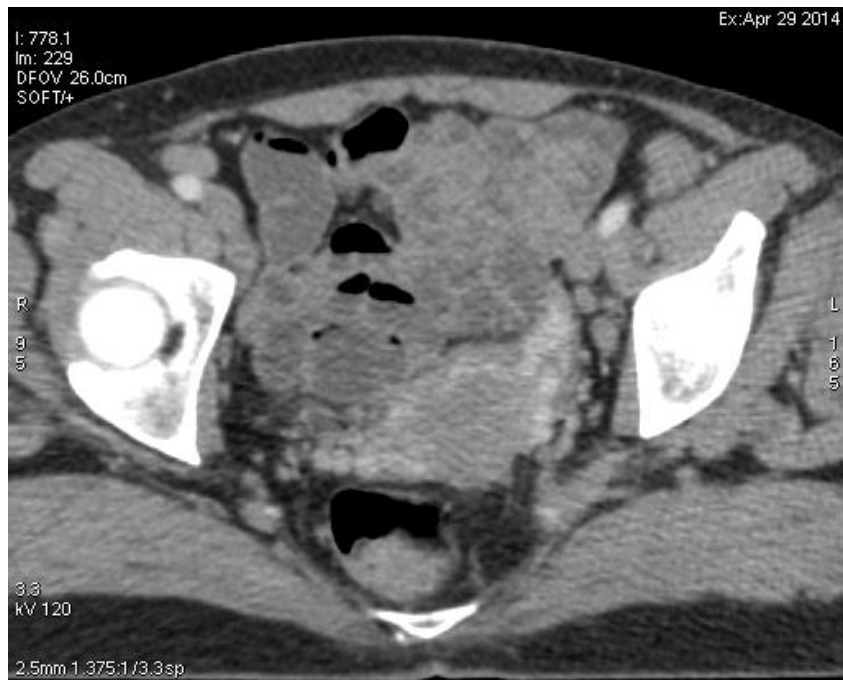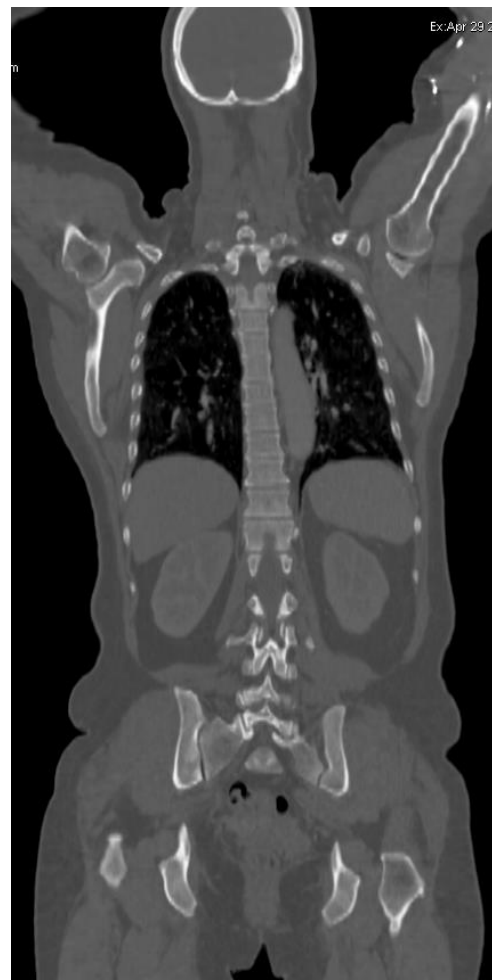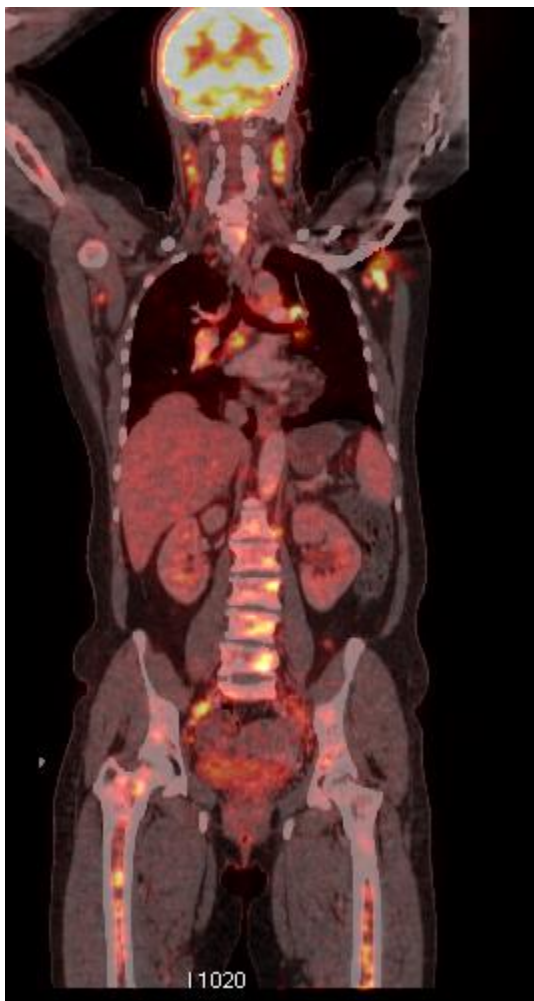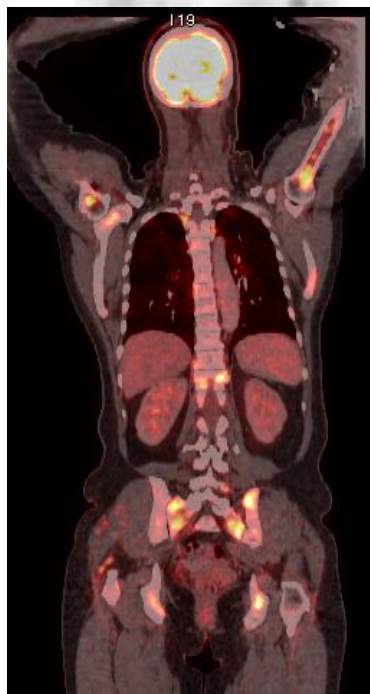


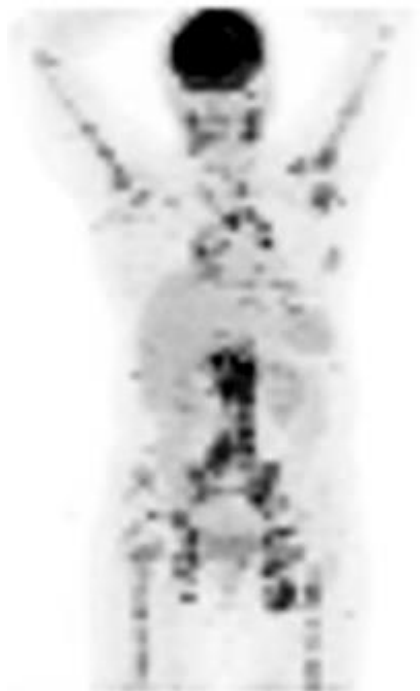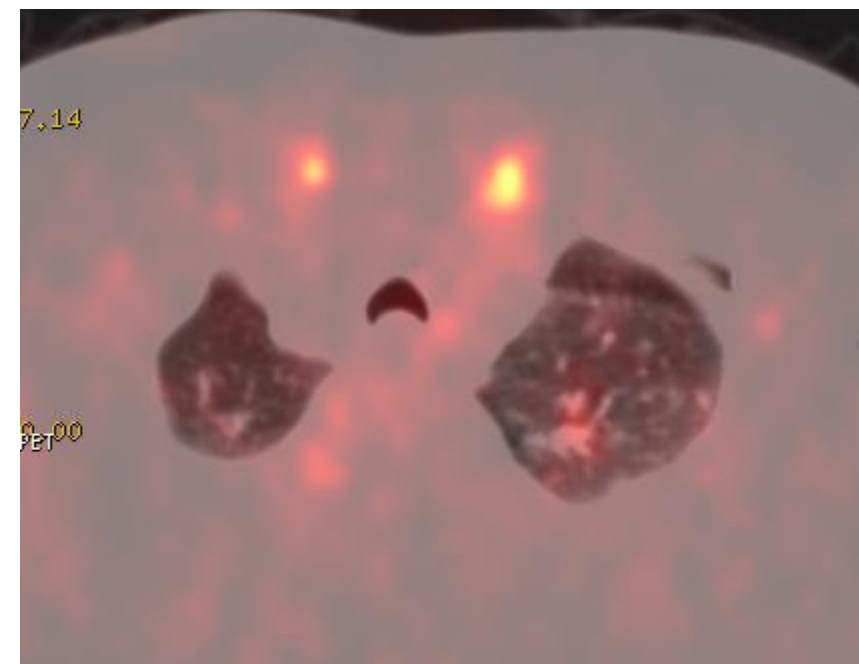
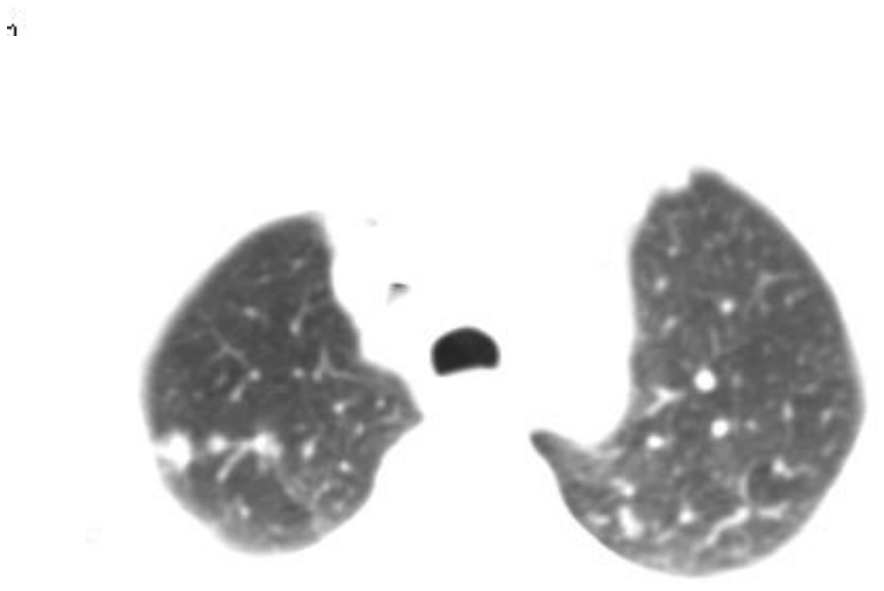

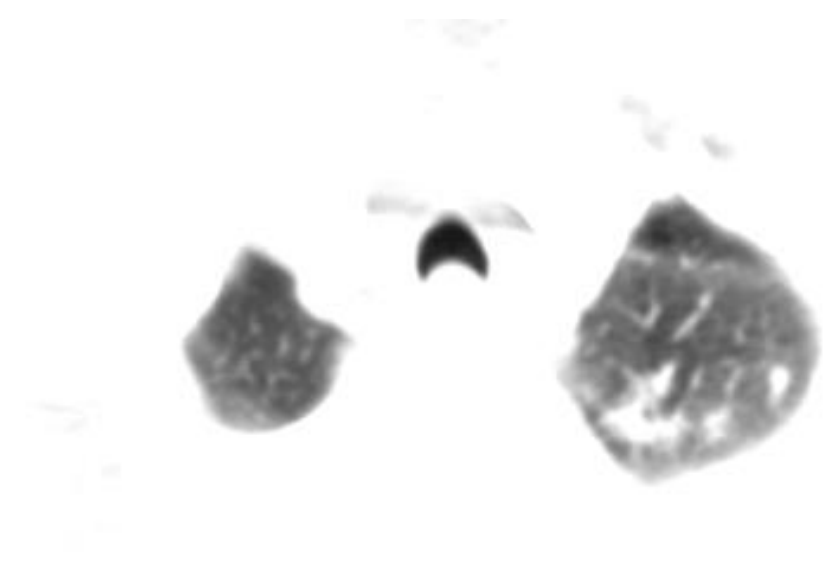




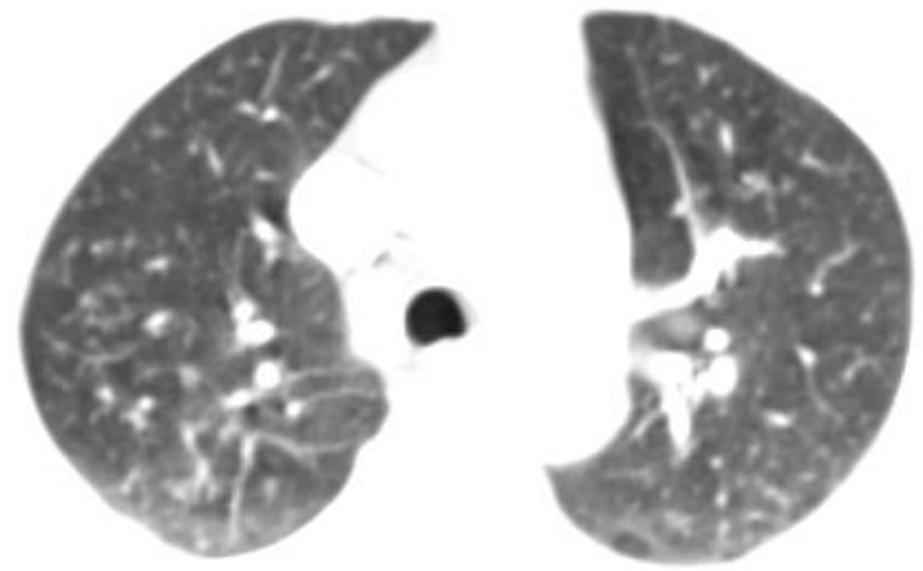
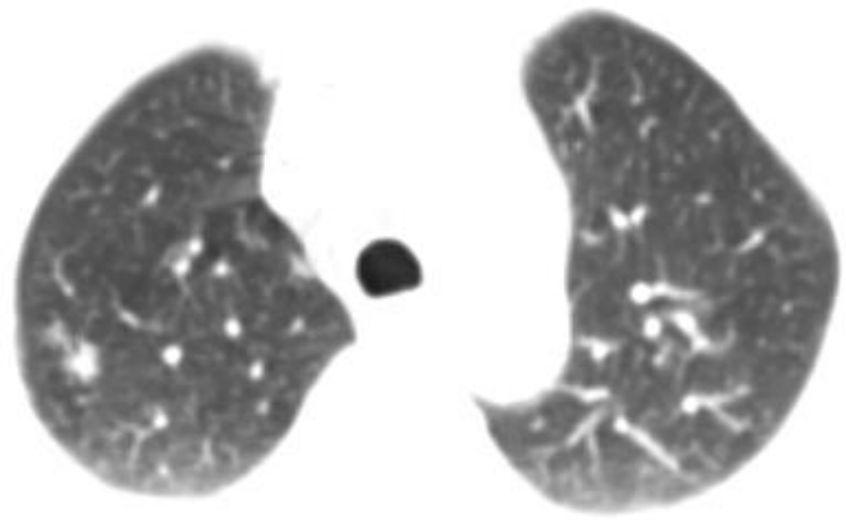




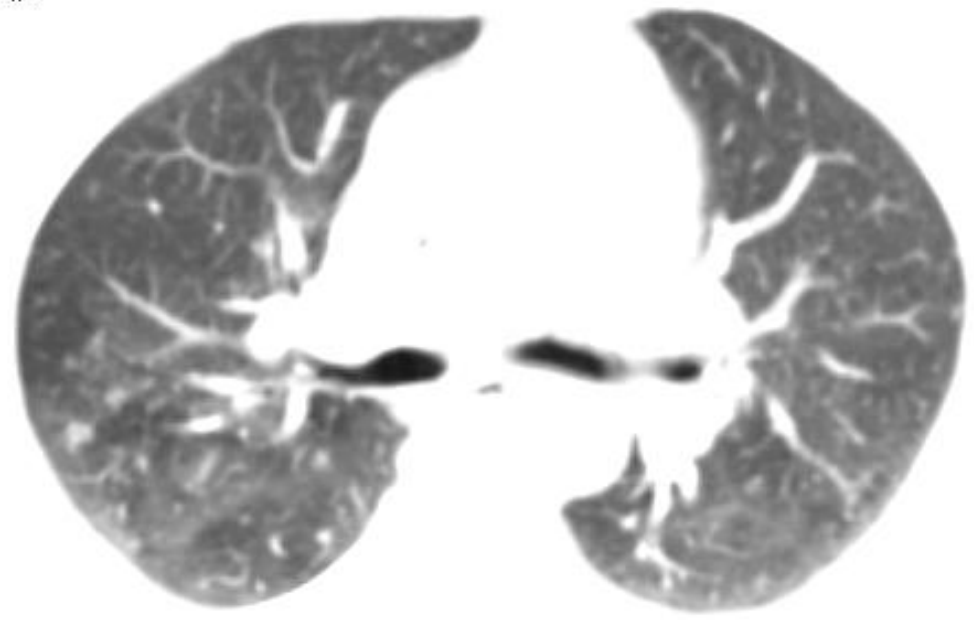




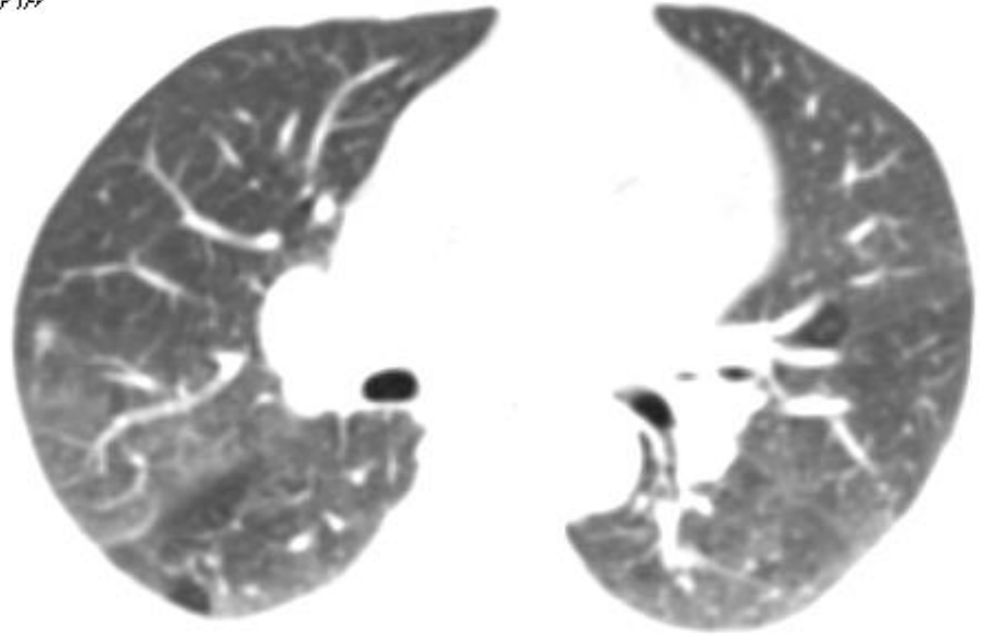
12.117

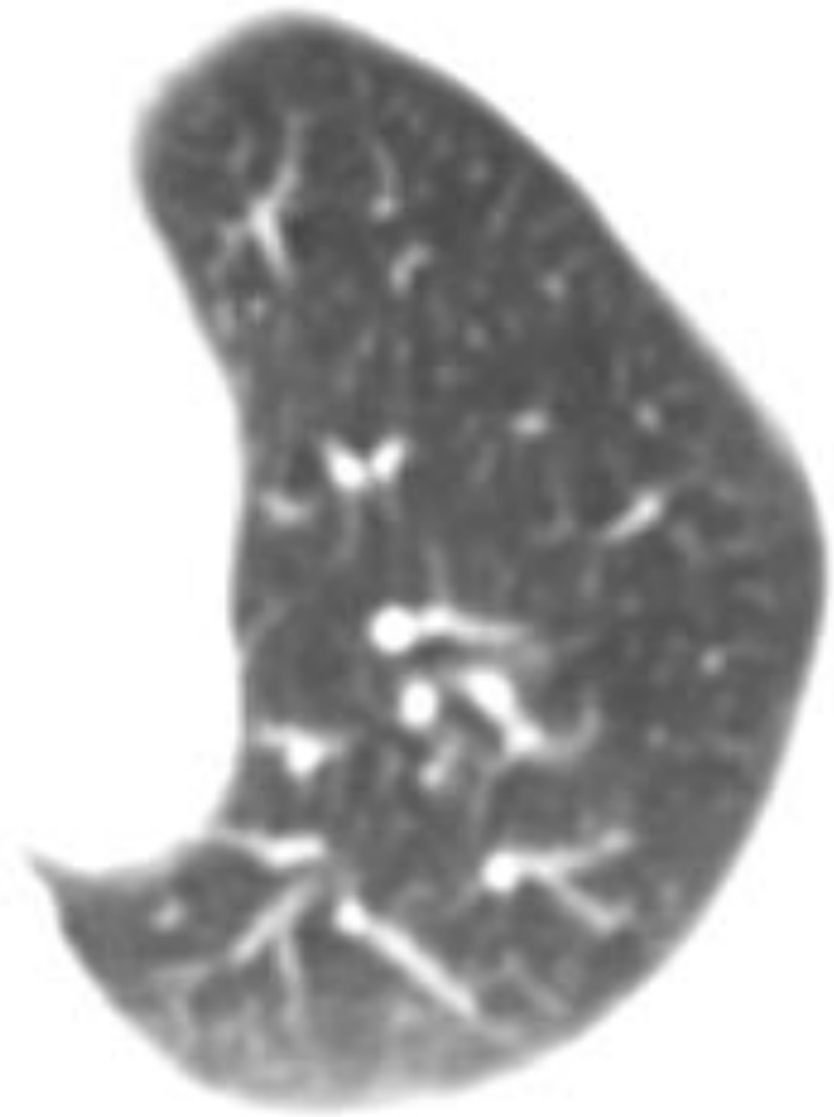
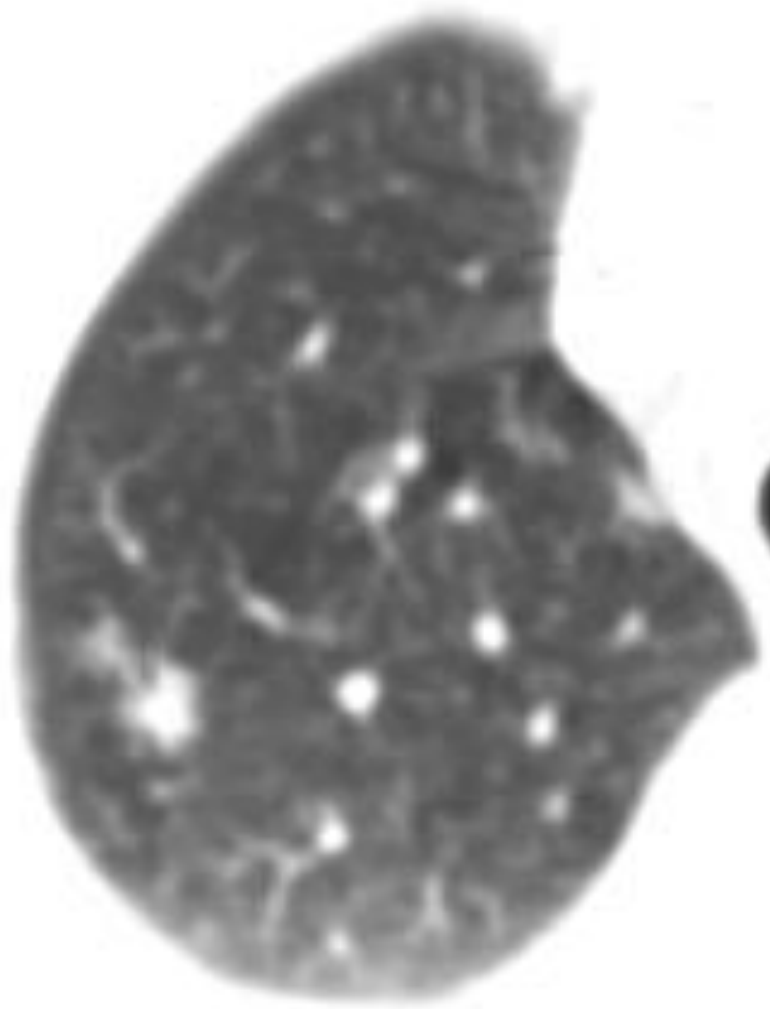


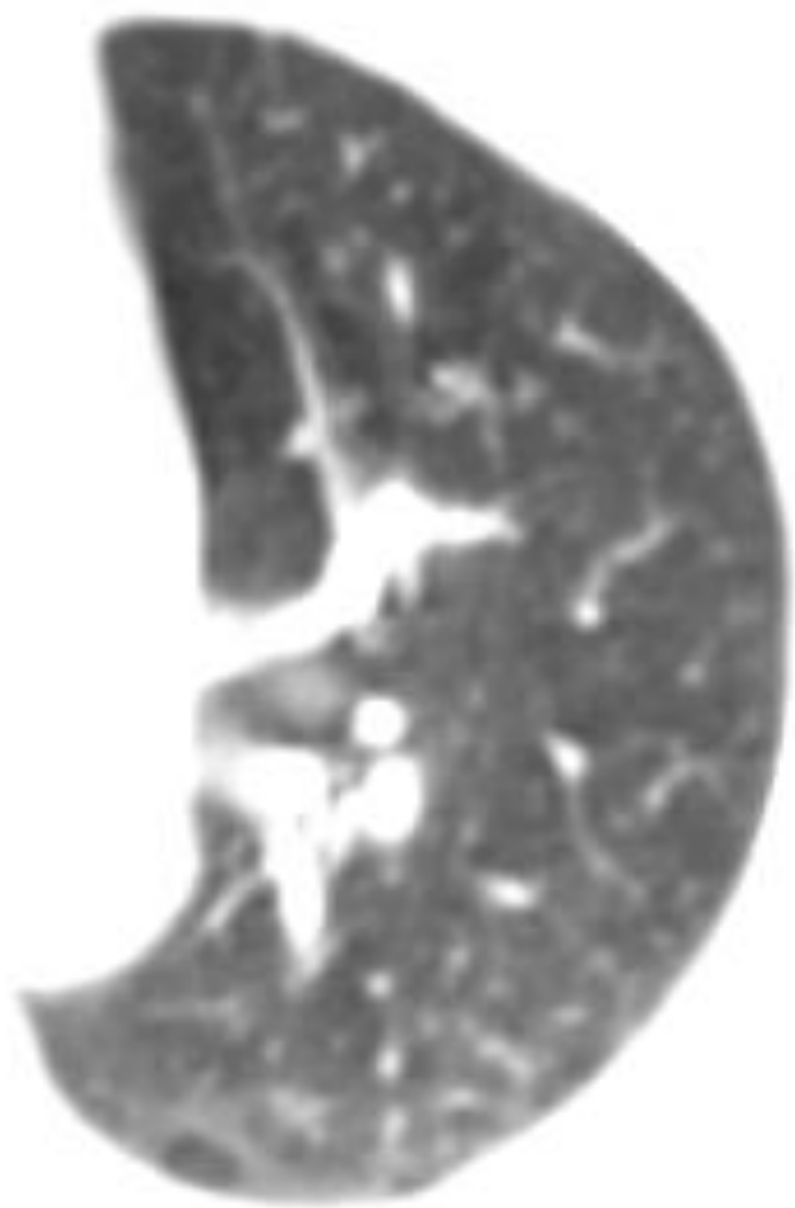
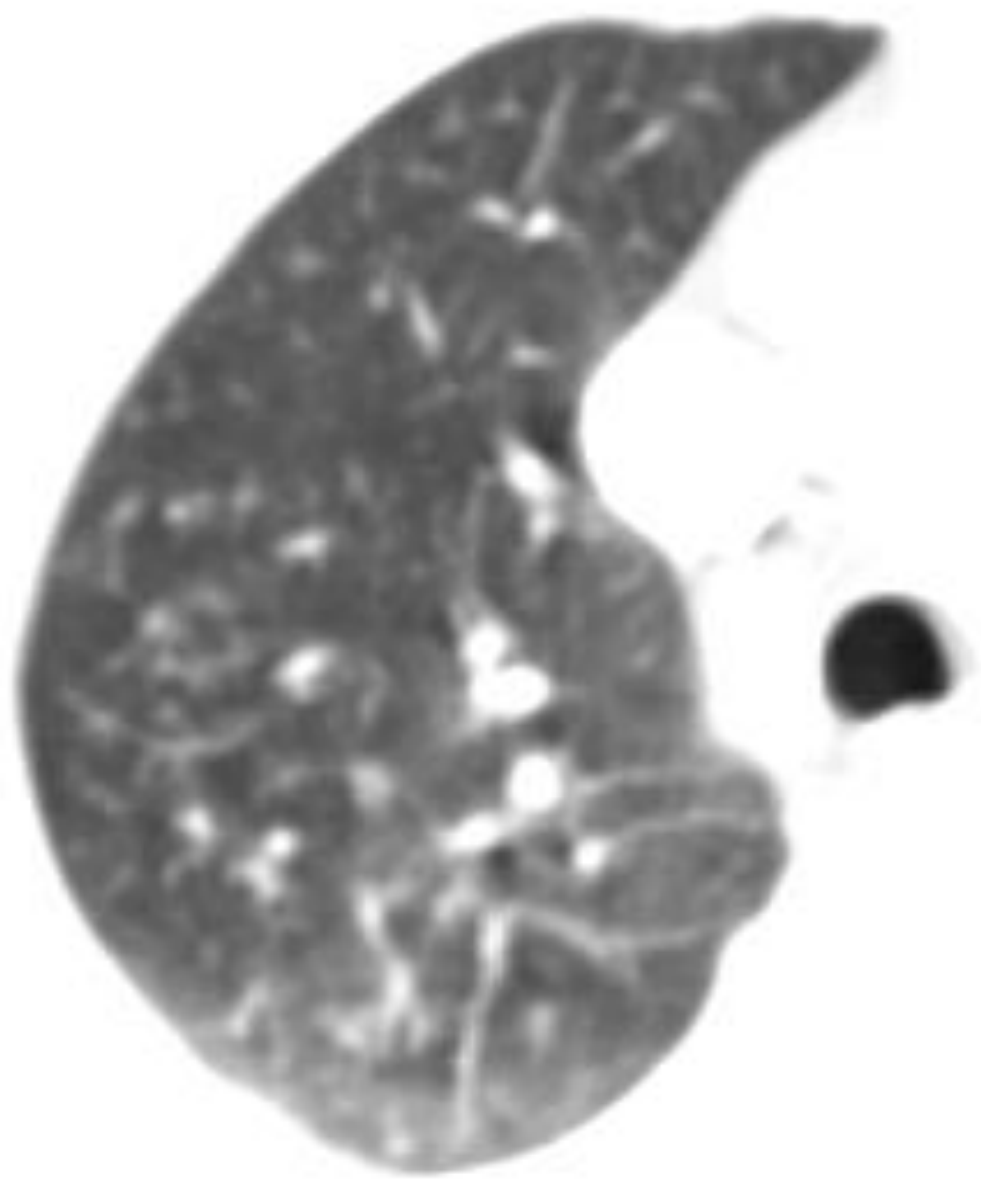
0v 28.Dcm
{FTA}

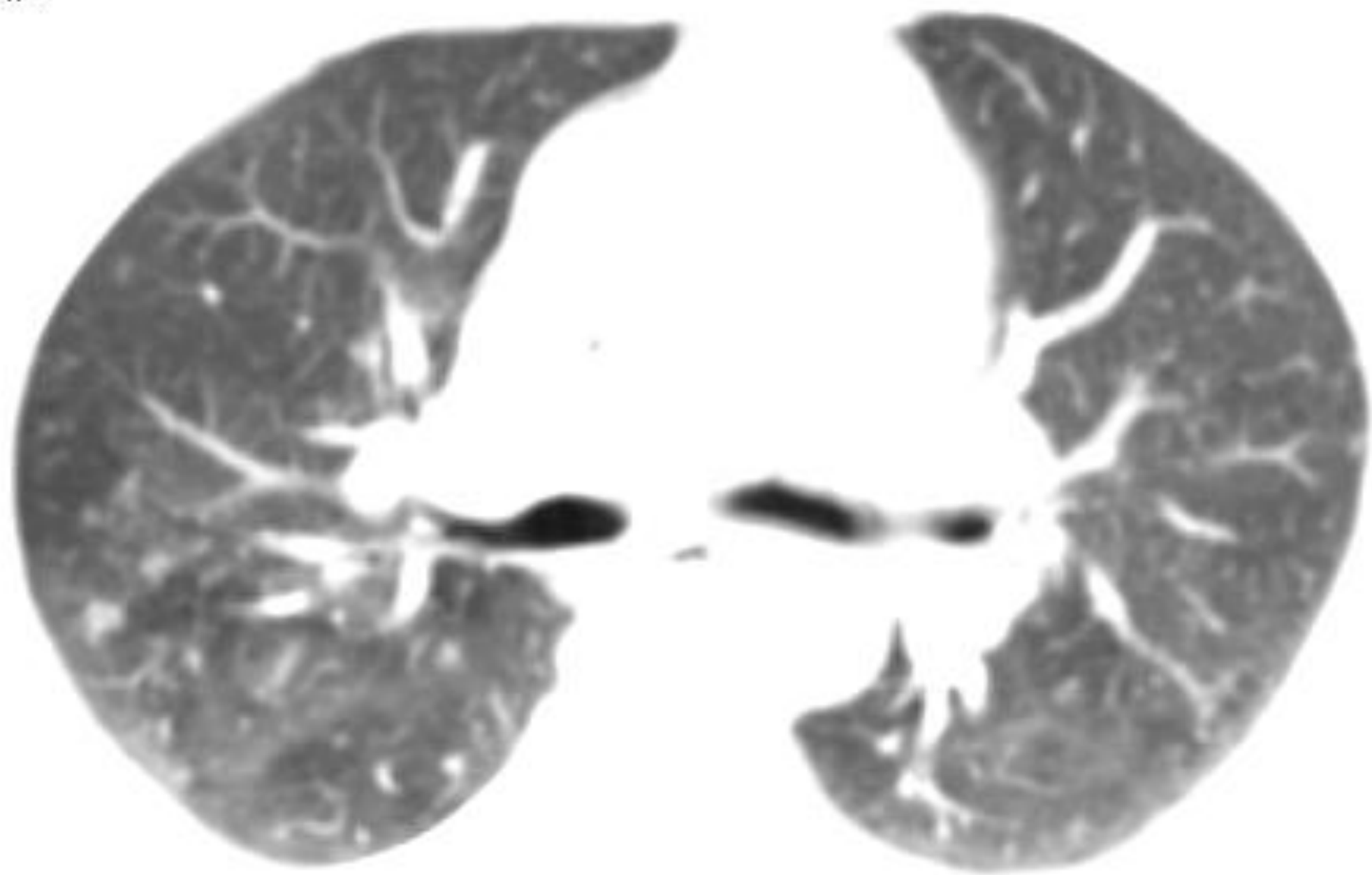


0v 28.Dcm
{OFTA}

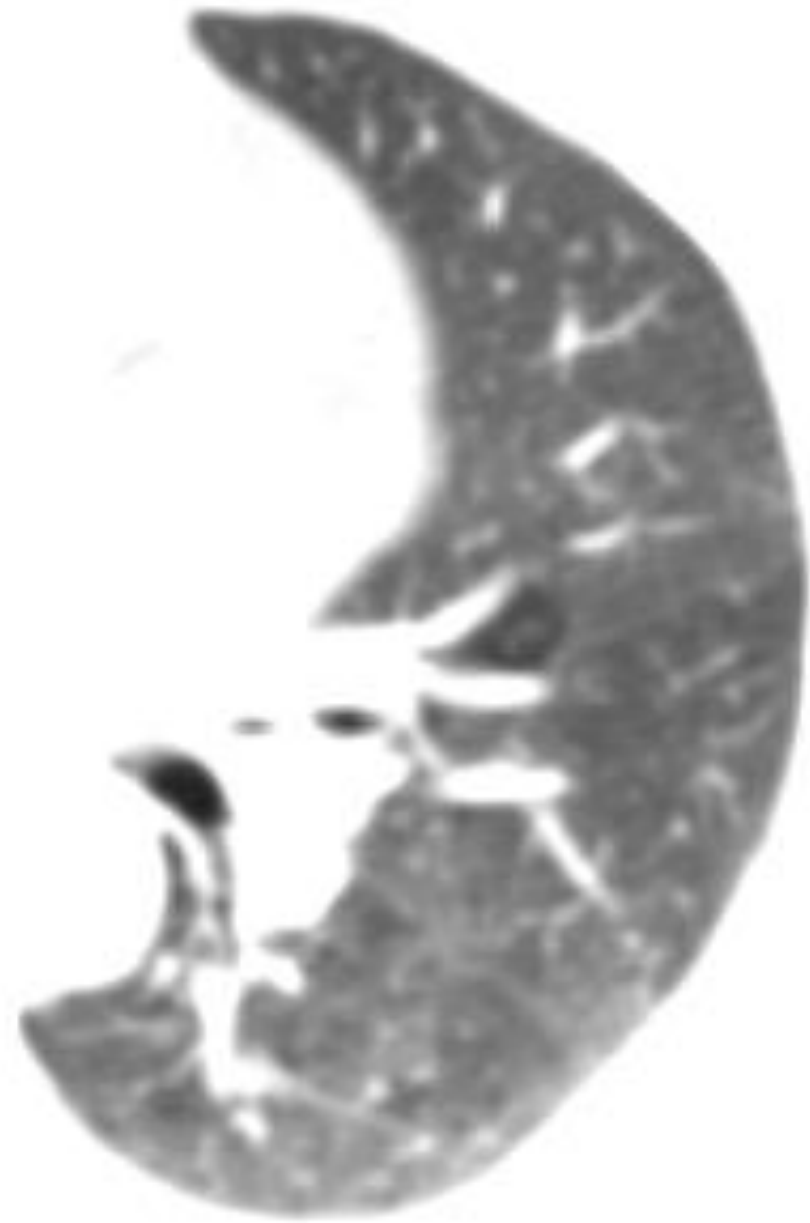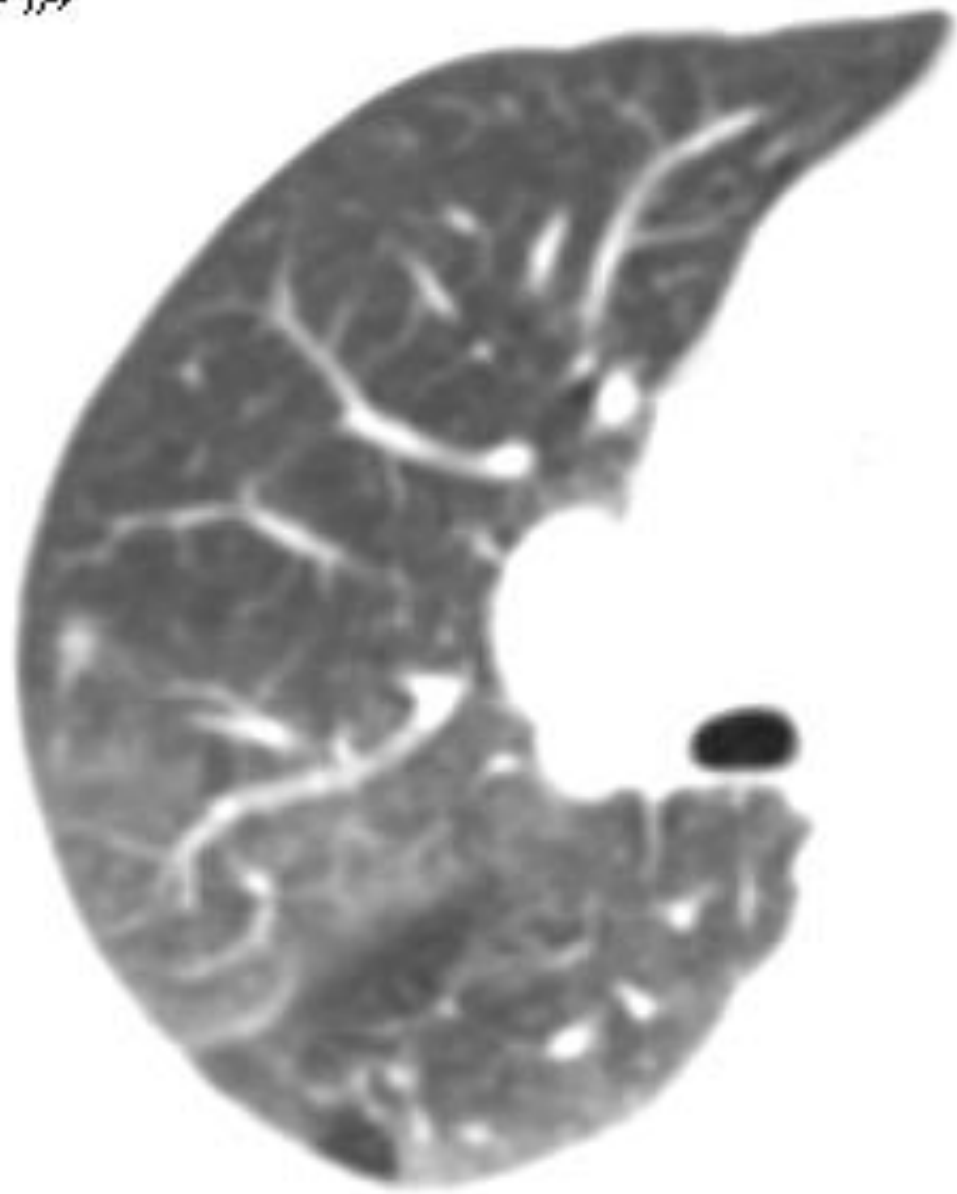








1004
FOV 23.Dcm
30F14



BULGULAR

- Boyundan inguinal bölgeye kadar supraklavikuler ve aksiller bölge dahil hipermetabolik LAP (SUV: 5-13)
- Akciğerde nodüller
- Plevrada kalınlaşma ve FDG tutulumu
- Yaygın kemiklerde hipermetabolik tutulum

Ne düşünürdünüz?

- a) Tüberküloz
- b) Lenfoma
- c) Primeri bilinmeyen metastatik hastalık
- d) IgG4 ile ilişkili hastalık
- e) Sarkoidoz

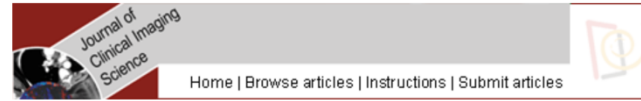Ne düşünürdünüz?

- a) Tüberküloz
- b) Lenfoma
- c) Primeri bilinmeyen metastatik hastalık
- d) IgG4 ile ilişkili hastalık
- e) **Sarkoidoz**

Önce Aksiller lenf bezi ve sonra kemik biyopsisi

- PATOLOJİK TANI: **SARKOİDOZ**
- Tüberküloz ve diğer enfeksiyonlar lehine hiç bir bulgu yok.

Journal List > J Clin Imaging Sci > v.5; 2015 > PMC4541162



J Clin Imaging Sci. 2015; 5: 40.

Published online 2015 Jul 31. doi: [10.4103/2156-7514.161850](https://doi.org/10.4103/2156-7514.161850)

PMCID: PMC4541162

PMID: [26312138](https://pubmed.ncbi.nlm.nih.gov/26312138/)

Corticosteroid Responsive Sarcoidosis with Multisystemic Involvement Years after Initial Diagnosis: A Lymphoma Mimicker on 18-FDG PET/CT

[Turker Acar](#), [Recep Savas](#),¹ [Kenan Kocacelebi](#),² and [Eyup Sabri Ucan](#)³

• [Author information](#) • [Article notes](#) • [Copyright and License information](#) [Disclaimer](#)

This article has been [cited by](#) other articles in PMC.

Abstract

Go to:

Sarcoidosis is a chronic multisystemic inflammatory disease characterized by noncaseating epithelioid cell granulomas. 18-Fluorodeoxyglucose positron-emission tomography/computer tomography (FDG-PET/CT) is increasingly used in routine clinical practice to assess active sarcoidosis because it can detect active

Formats:

[Article](#) | [PubReader](#) | [ePub \(beta\)](#) | [Printer Friendly](#) | [Citation](#)

Share

[Facebook](#) [Twitter](#) [Google+](#)

Save items

[Add to Favorites](#)

Similar articles in PubMed

Splenic and lymph nodal involvement in sarcoidosis mimicking lymphoma on fluorine-18 fluorodeoxyglu [Indian J Nucl Med. 2015]

Sarcoidosis mimicking lymphoma on FDG-PET imaging. [Radiol Case Rep. 2011]

An atypical sarcoidosis involvement in FDG PET/CT: A case report. [Medicine (Baltimore). 2016]

PET/CT in the Diagnosis and Workup of Sarcoidosis: Focus on Atypical Manifestations. [Radiographics. 2018]

Functional imaging in extrapulmonary sarcoidosis: FDG-PET/CT

SARKOİDOZ

- Plevral sarkoidozis tüm sarkoidozis olgularının yaklaşık % 3 'ünde
- Ancak yeni yöntemlerle daha yüksek oranda olduğu ortaya çıkmakta

SARKOİDOZ

- Plevral nodül veya kalınlaşma şeklinde görülmekte
- Pnömotoraks, şilotoraks veya hemotoraks şeklinde de karşımıza çıkabilir.

SARKOİDOZ

- Kemik tutulumu nadir ve insidansı % 1-12 arası değişmekte
- Sıklıkla tutulan kemikler el ve ayağın kısa tübüler kemikleri ama vertebra, sternum, pelvis, kostalar, nazal kemikler, tibia ve femur da tutulabilir.

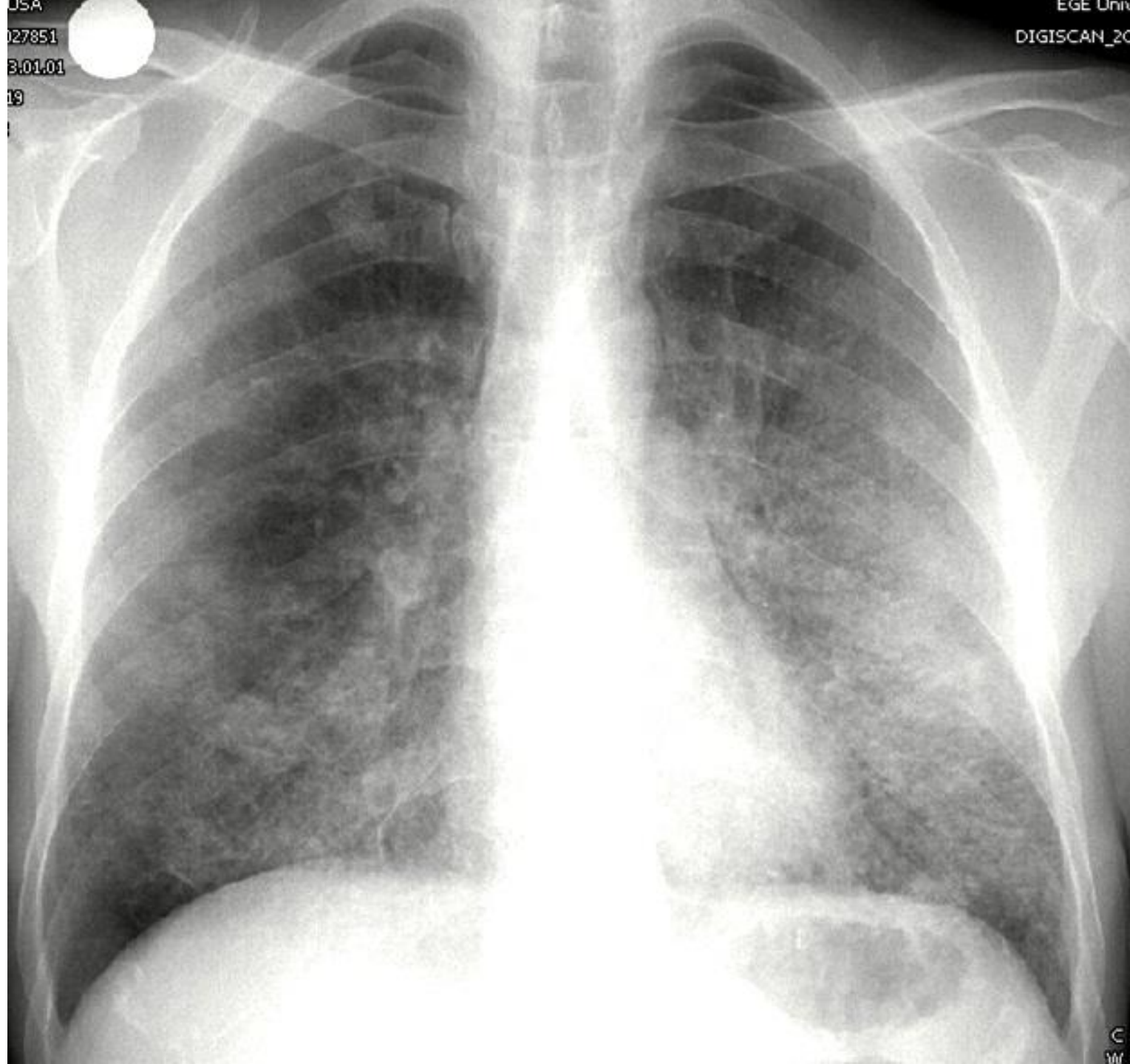
SARKOİDOZ

- Genelde kemik tutulumu asemptomatik ama bazen ağrı eşlik edebilir. Litik veya sklerotik olabilir.
- Ayırıcı tanıda metastaz, lenfoma, myelom, tüberküloz düşünülebilir. Biyopsi diğer lezyonların ekartasyonu için gereklidir.

- 42 y erkek hasta
- Yakınmaları
 - Nefes darlığı
 - Öksürük
 - Balgam çıkarma
- Öz ve Soy geçmişinde özellik yok

USA
027851
3:01.01
19

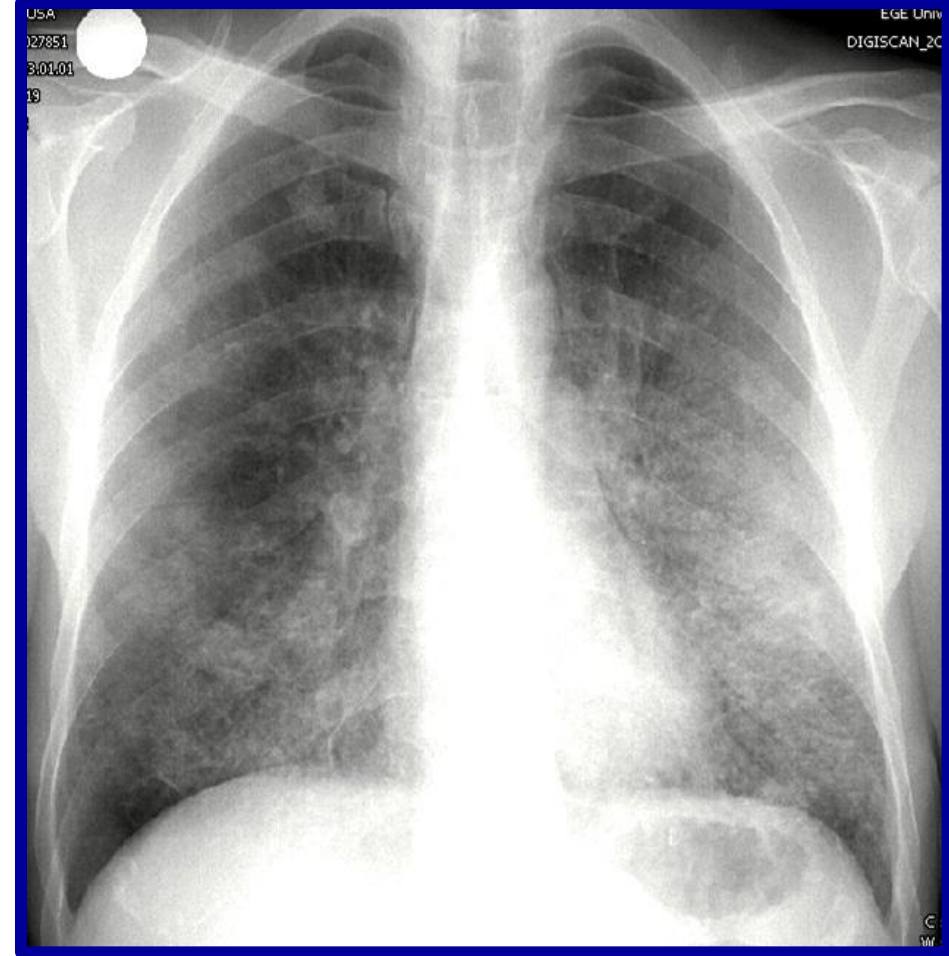
EGE Univ
DIGISCAN_20



C
W

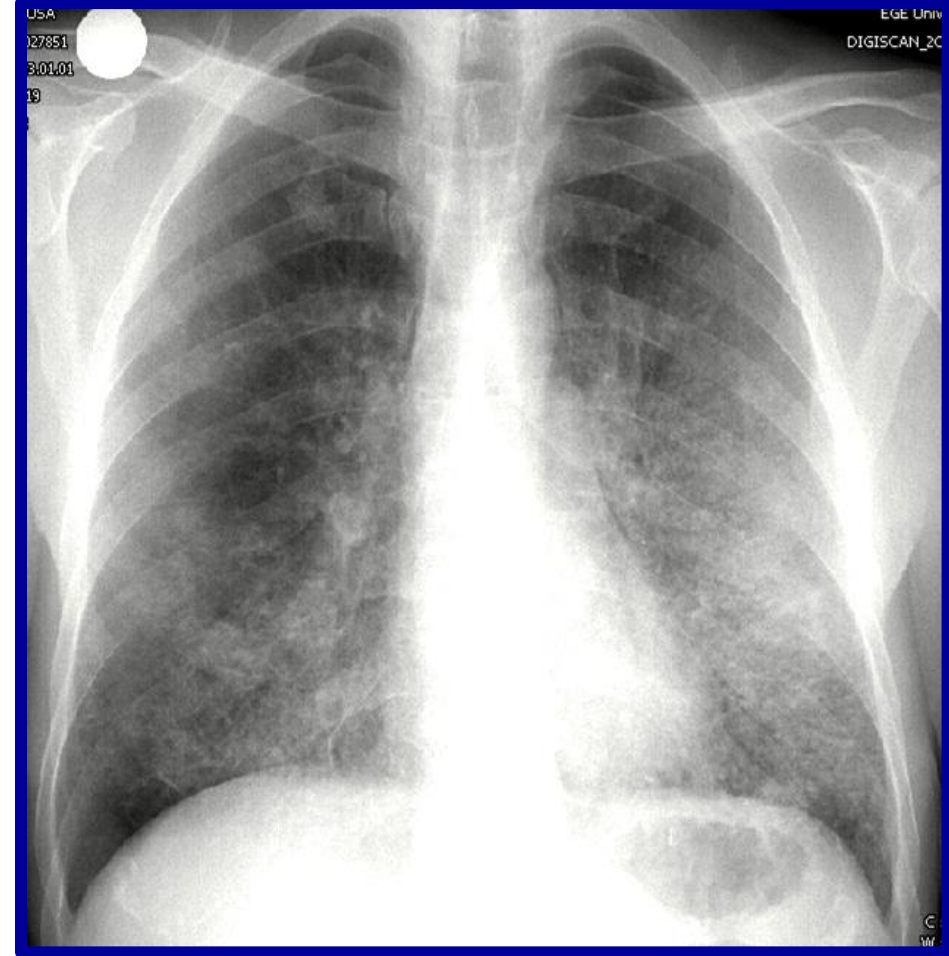
Hangisi olabilir?

- a) İnterstisyel fibrozis
- b) ARDS
- c) Pulmoner ödem
- d) Sarkoidozis
- e) Hiçbiri



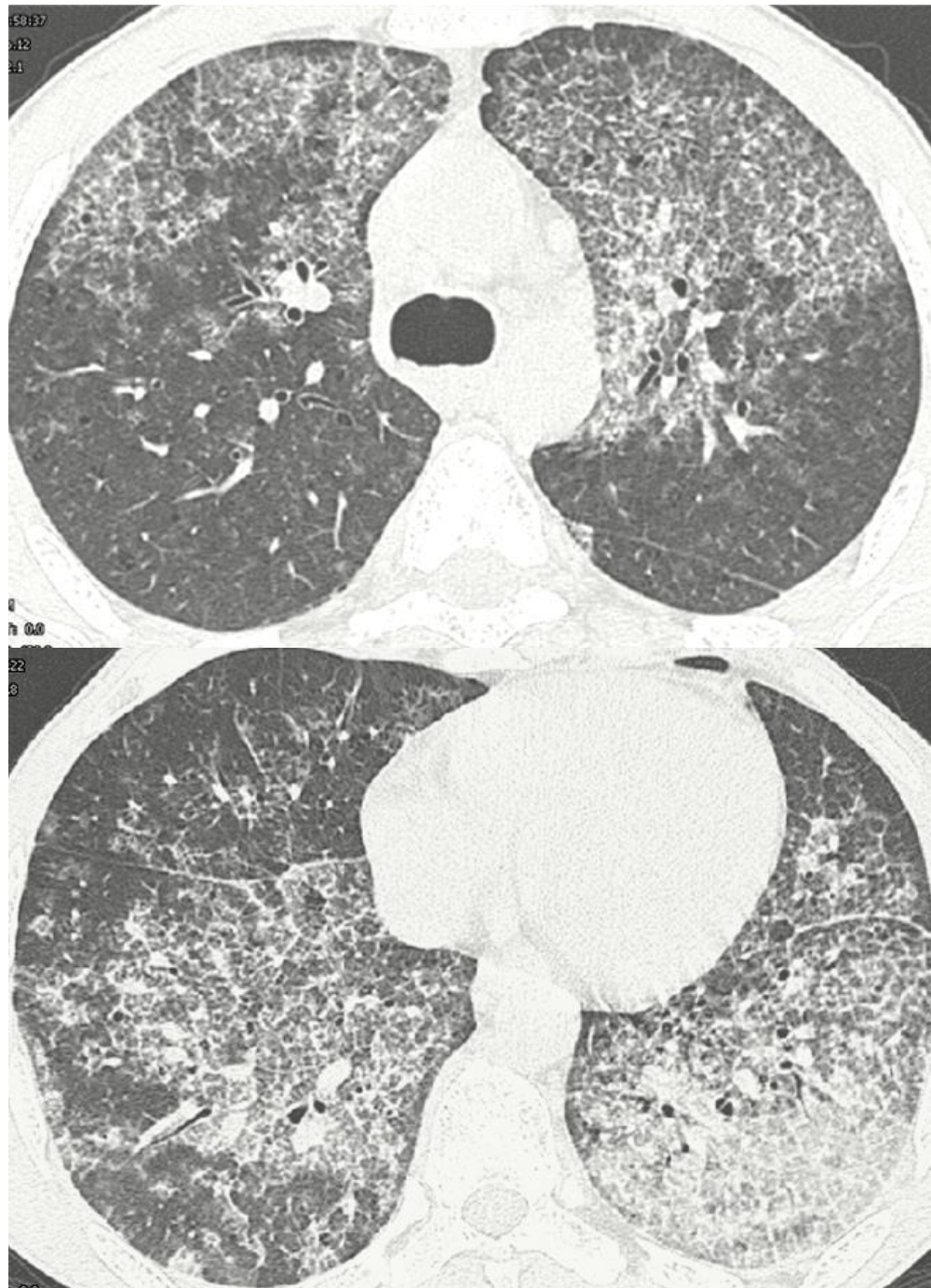
Hangisi olabilir?

- a) İnterstisyel fibrozis
- b) ARDS
- c) Pulmoner ödem
- d) Sarkoidozis
- e) Hiçbiri



Radyografik Bulgular

- Bilateral, simetrik alveolar opasiteler
- Buzlu cam → konsolidasyon
- Perihiler ve bazal yerleşim
- Müphem nodüler ve/veya retiküler örnek
- Buzlu cam zemininde interstisyel kalınlaşmalar (kaldırım taşı örneği)



YRBT Bulguları

- Buzlu cam görünümü
(konsolidasyon-özellikle dorsalde)
- İnterlobüler ve intralobüler septal kalınlaşmalar (kaldırım taşı)
- Keskin ve düzgün sınırlanmalar
(coğrafik özellikte)

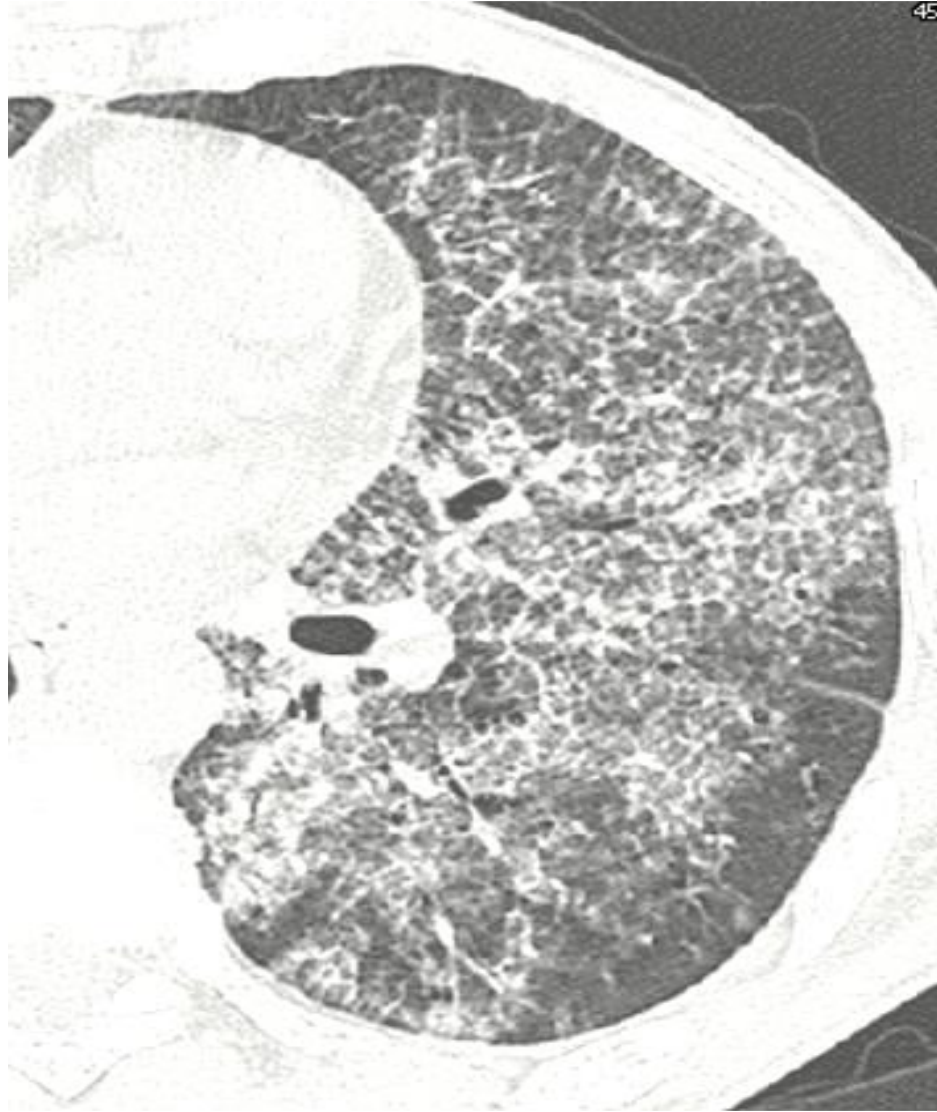Kaldırım taşı (crazy paving) görünümü yapan nedenler

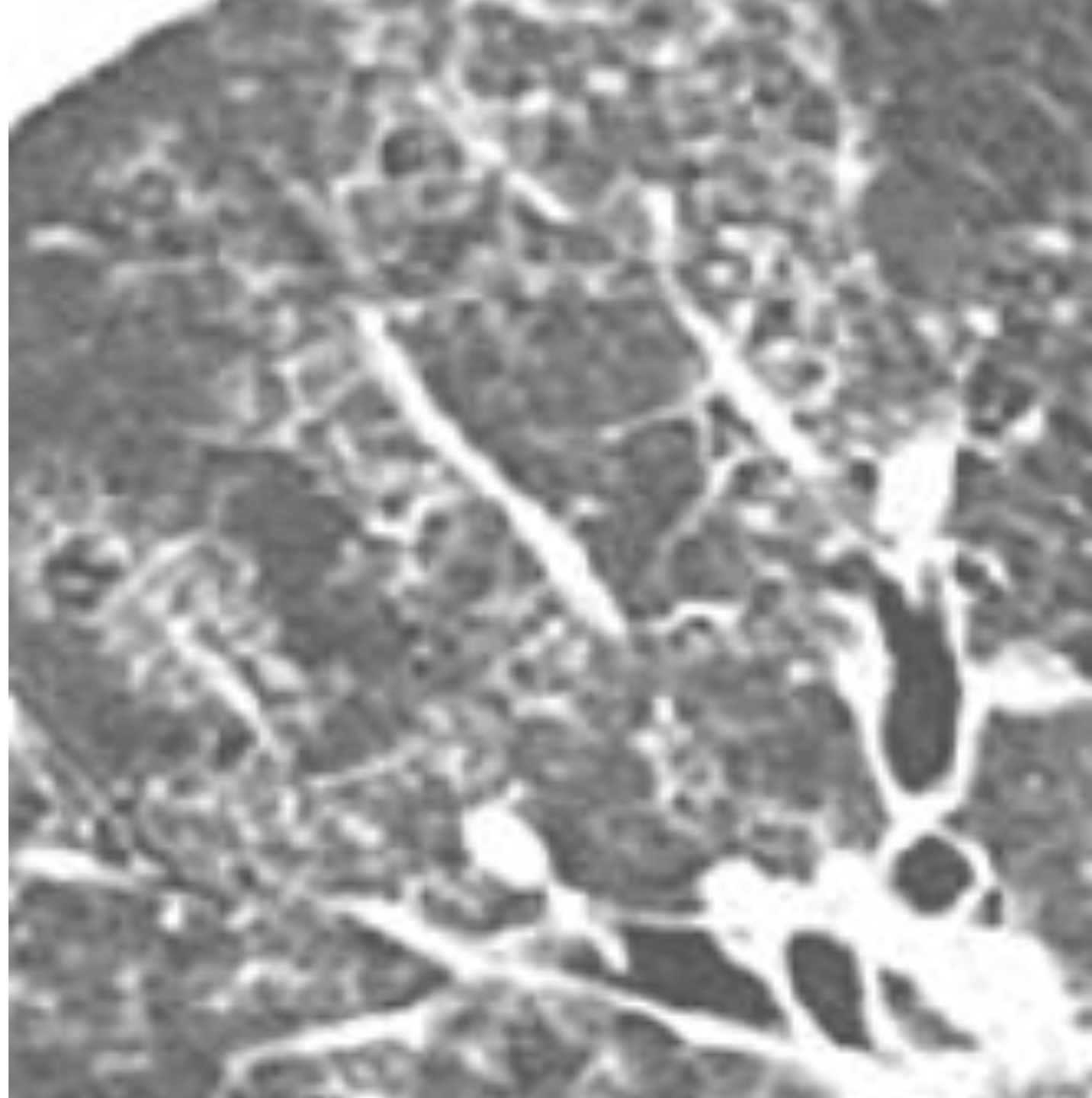
En sık nedenler

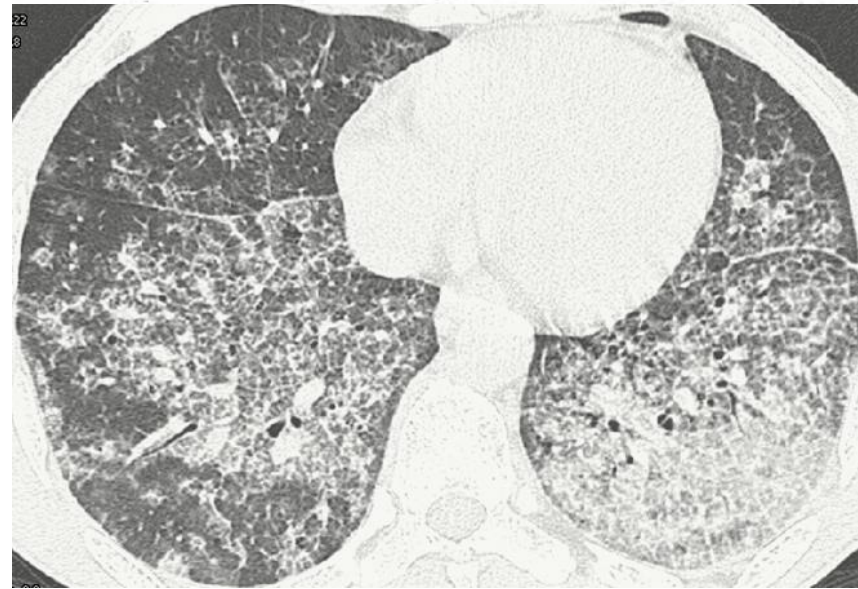
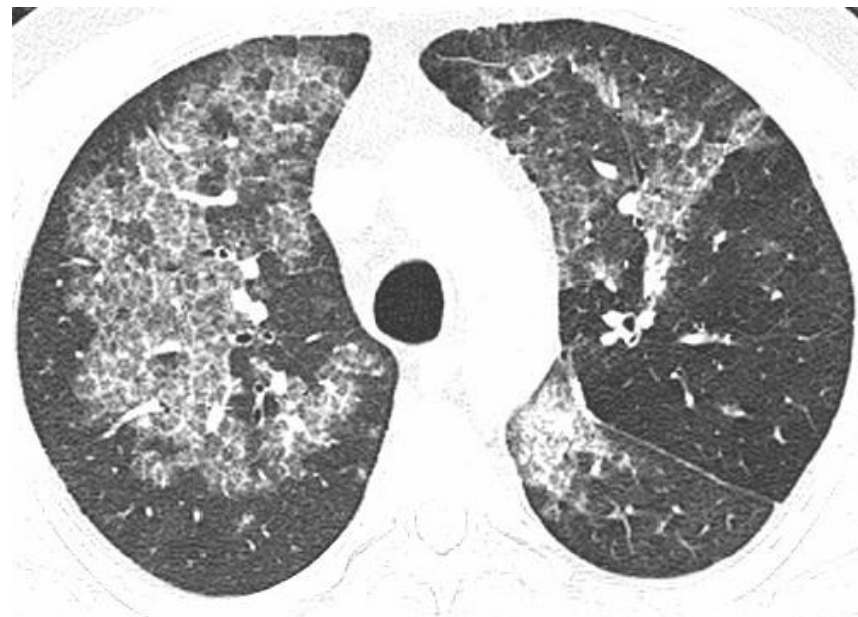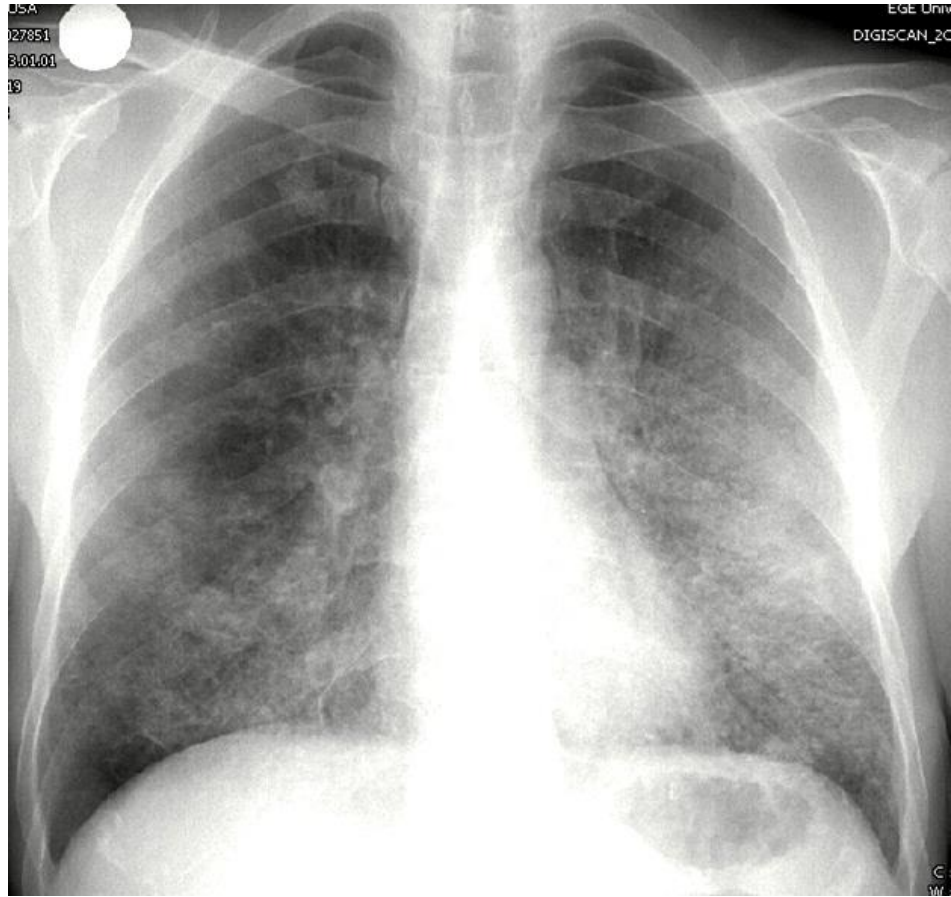
- Pulmoner ödem
- ARDS
- Bakteriyel pnömoni
- Akut interstisyel pnömoni
- pulmoner alveolar proteinosis (PAP)

Daha nadir nedenler

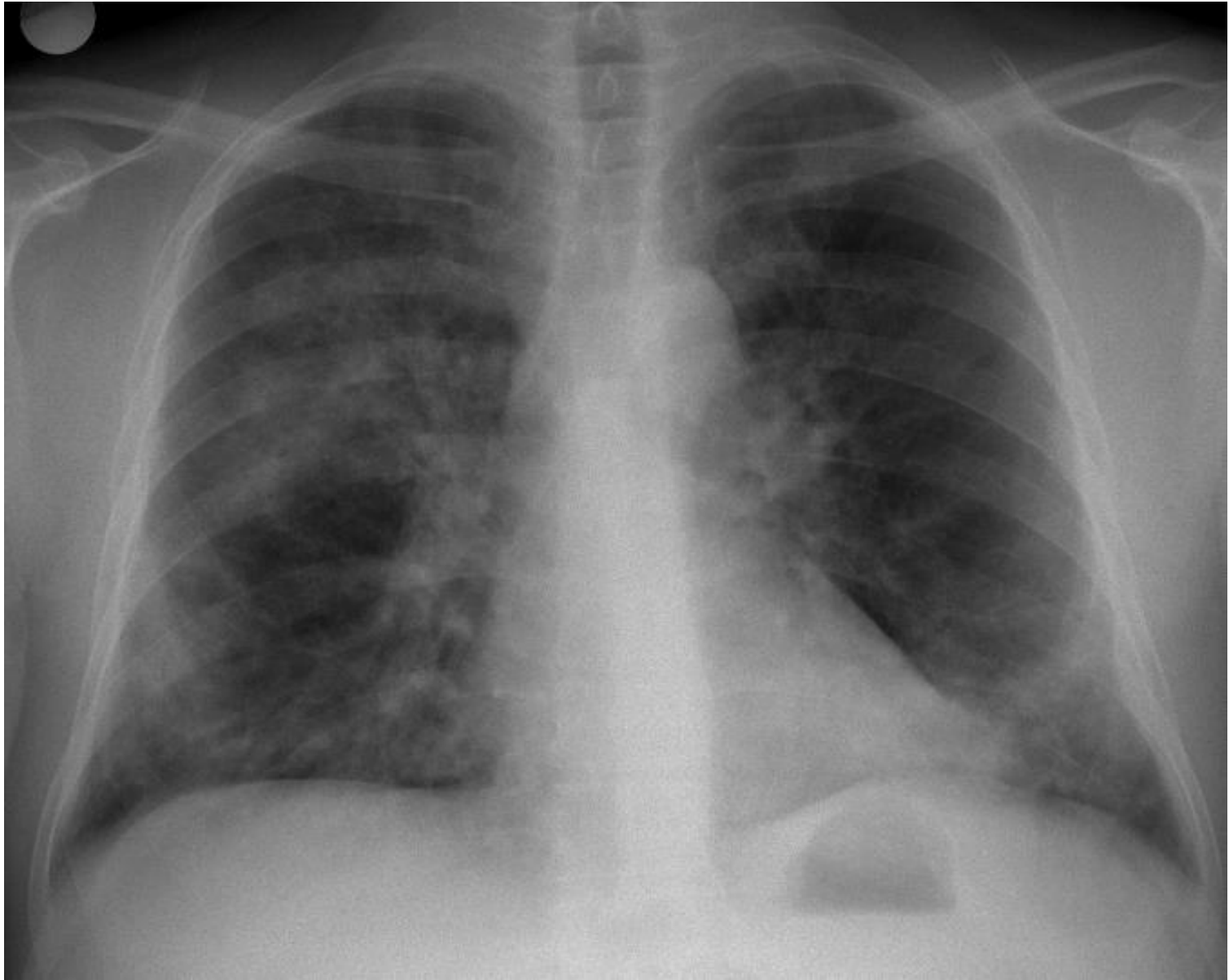
- İlaçla ilişkili pnömoni
- Radyasyon pnömonisi
- Pulmoner hemoraji
- Kronik eozinofilik pnömoni
- Pulmoner enfeksiyonlar
 - Mikoplazma pnömonisi
 - Tüberkülozis
 - PCP
- Organize pnömoni
- Müsinöz bronkoalveoler karsinom (eski adıyla)
- Sarkoidozis
- Lipoid pnömonisi
- Pulmoner veno-okluziv hastalık

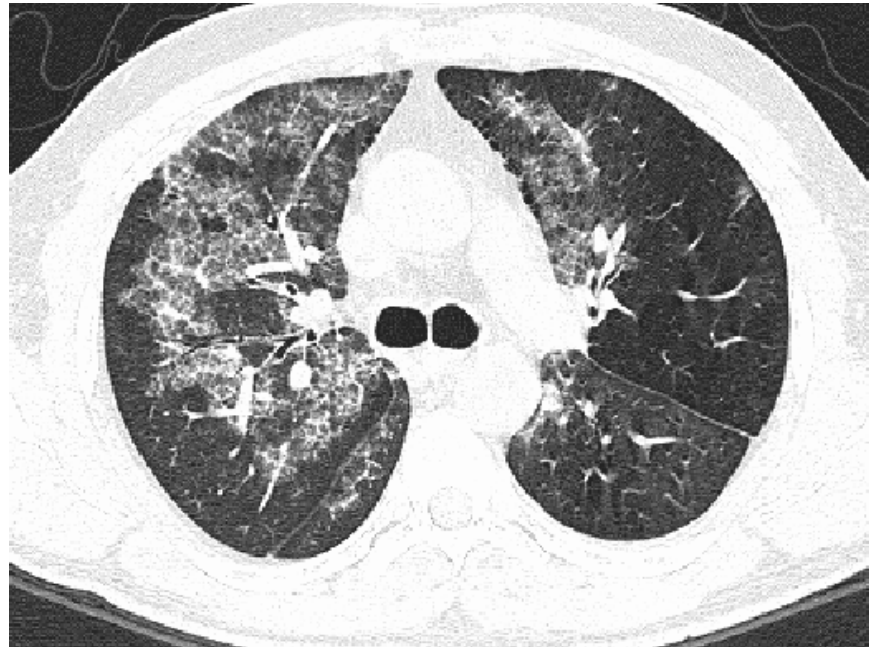
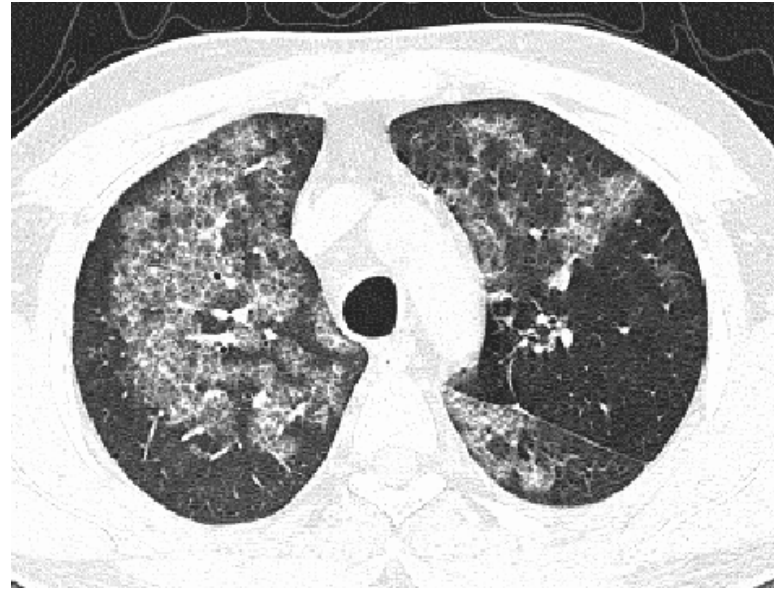
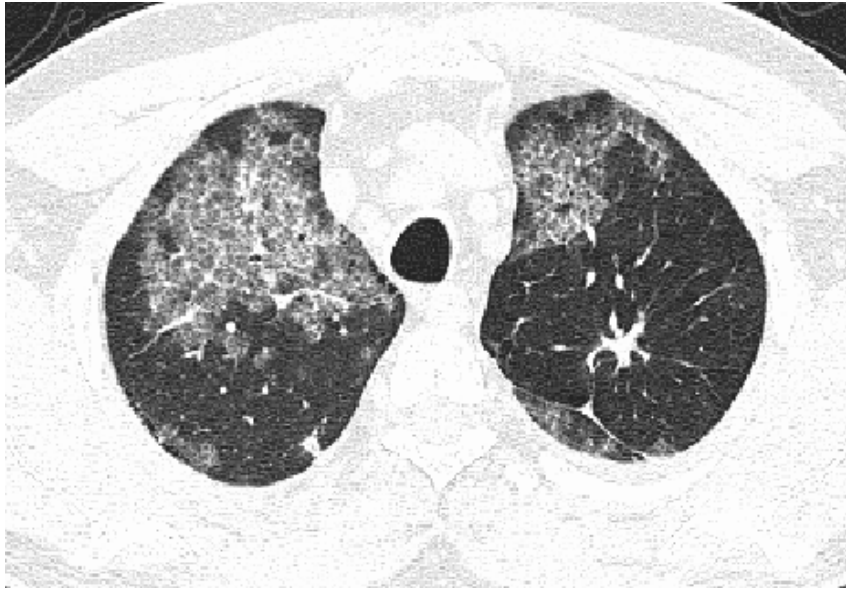


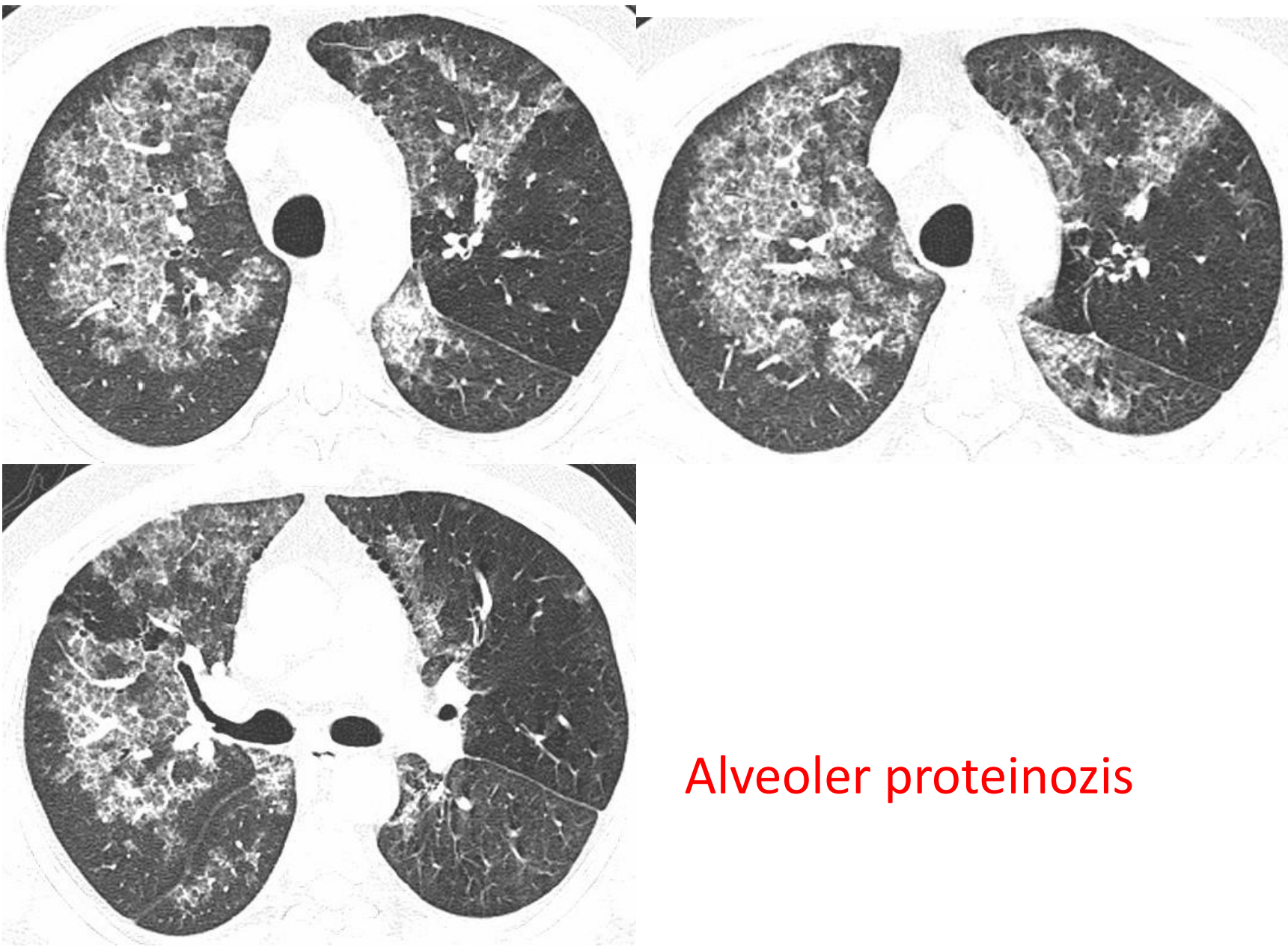




Alveolar proteinosis







Alveoler proteinozis

