



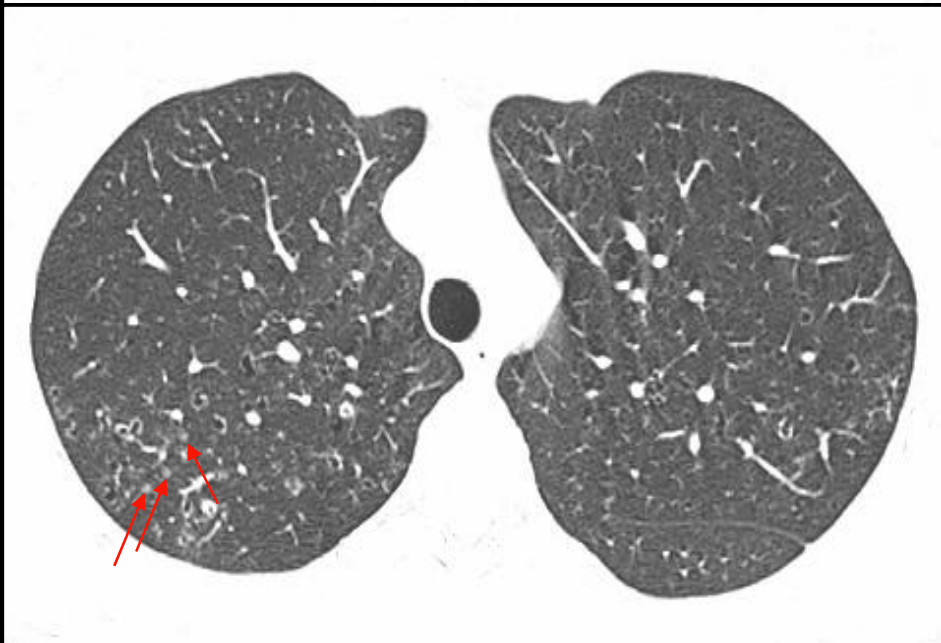
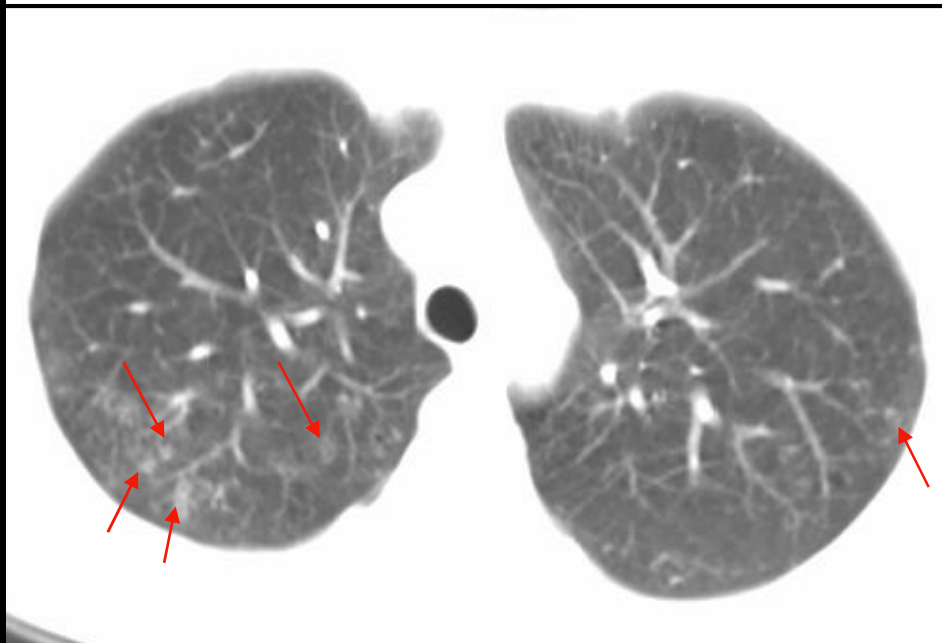
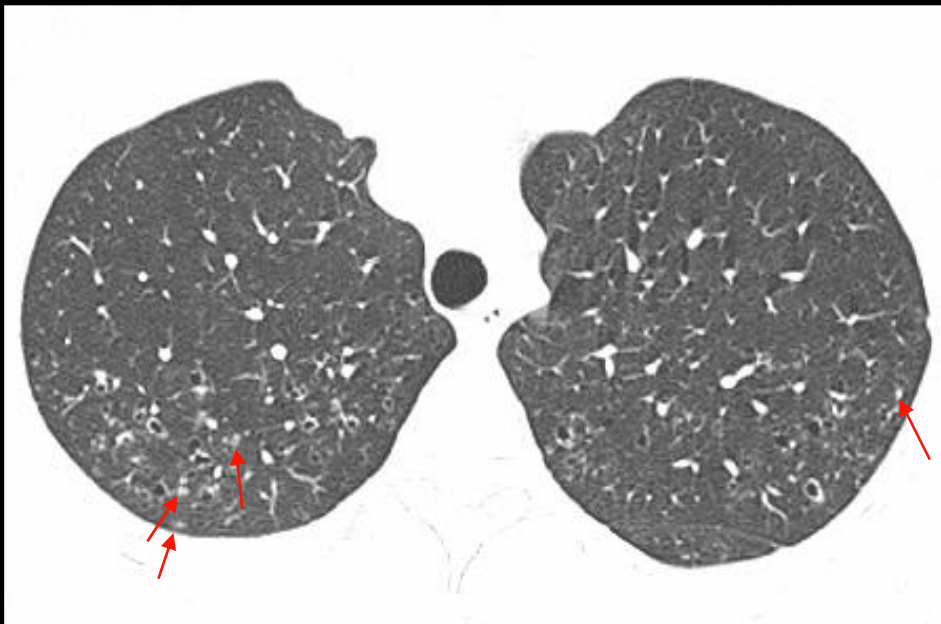
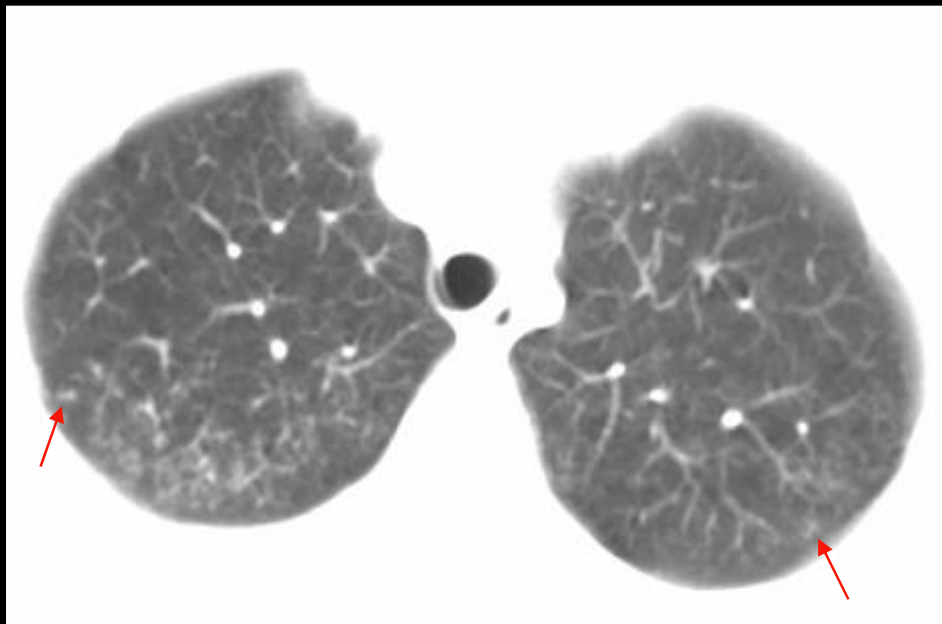
İNTERTİŞYEL AKCİĞER HASTALIĞI TANISINDA TORAKS BT

Dr.Selen Bayraktarođlu

Ege Üniversitesi Tıp Fakültesi

Radyoloji AD/İZMİR





İTERSTİSYEL AKCİĞER HASTALIĞI

Sebebi
bilinen grup

Bağ doku hastalıkları
İlaçlar
Radyasyon
Meslek hastalıkları

İdiopatik
interstisyel
pnömoniler

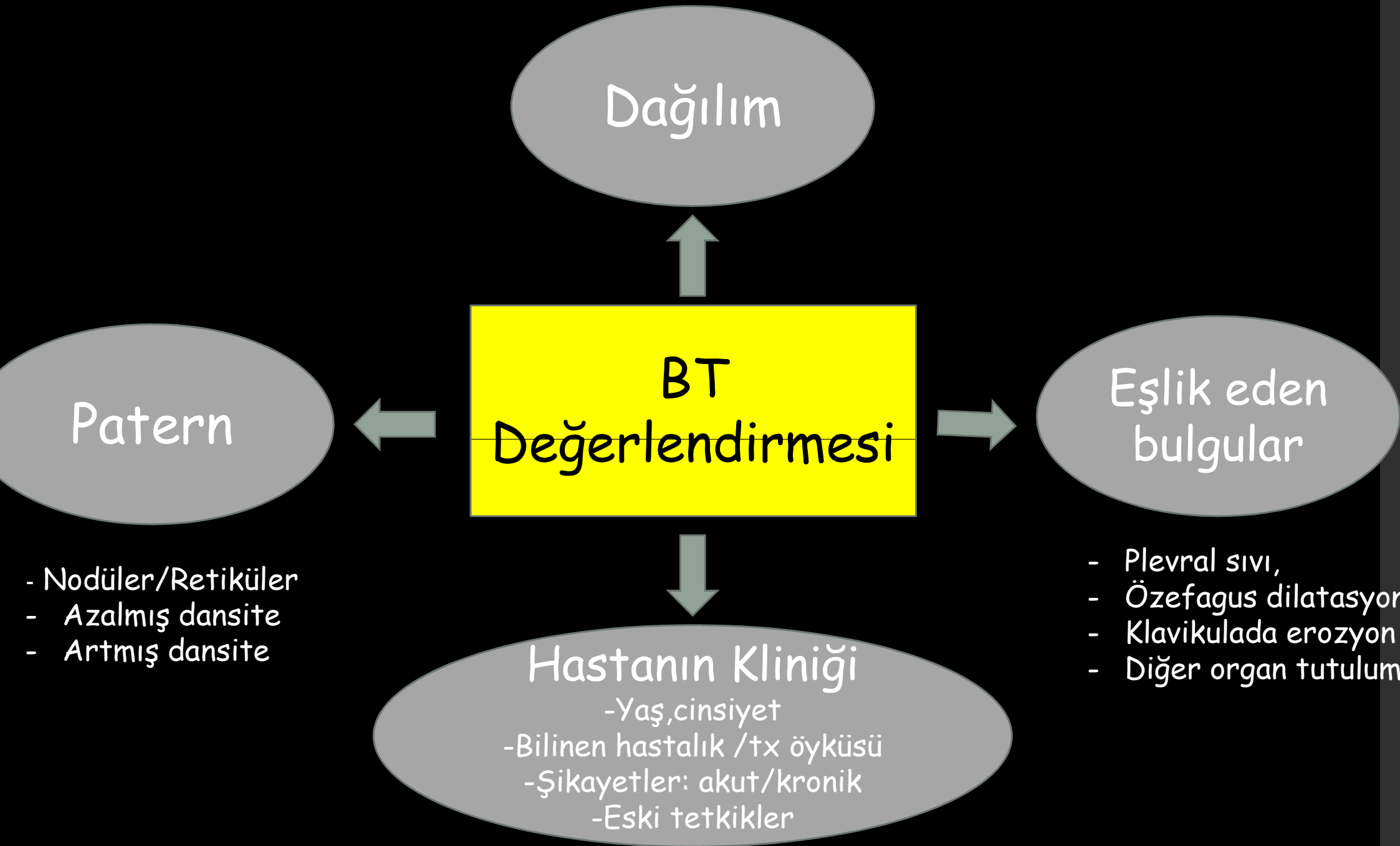
- Majör İİP
- Nadir İİP

Granülomatöz
hastalıklar

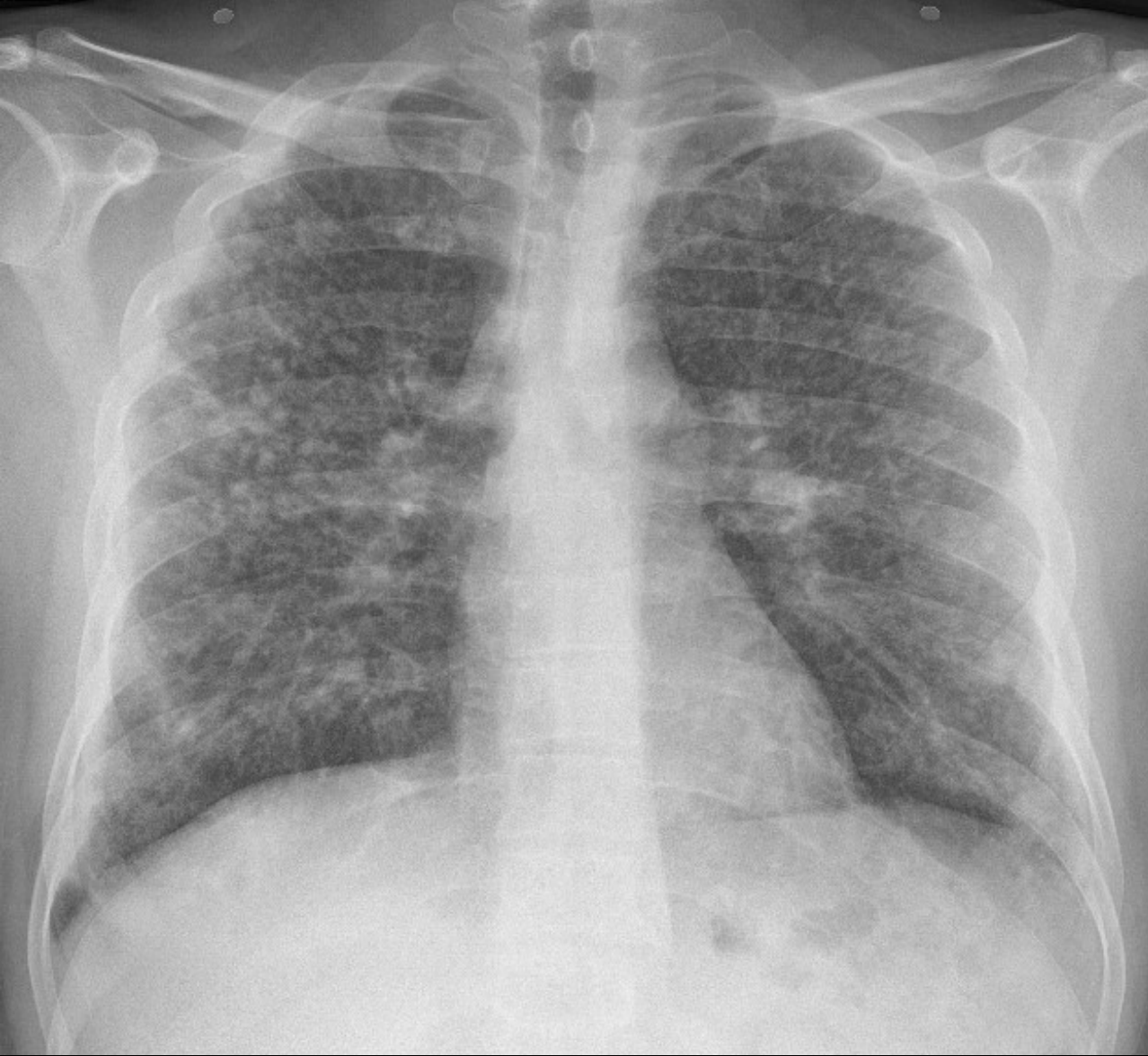
- Sarkoidoz
- Hipersensitivite
Pnömonisi

Diğer
sebepler

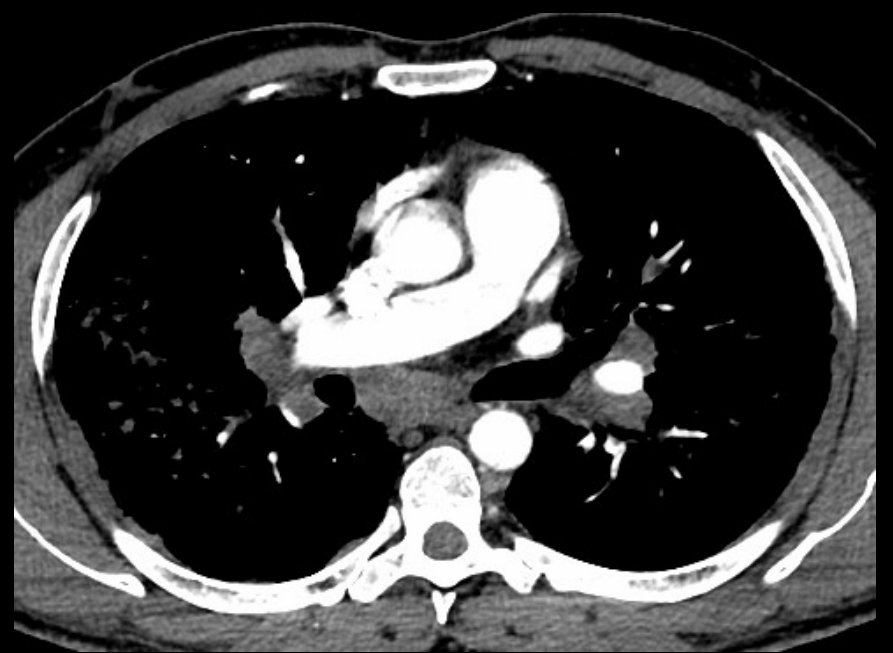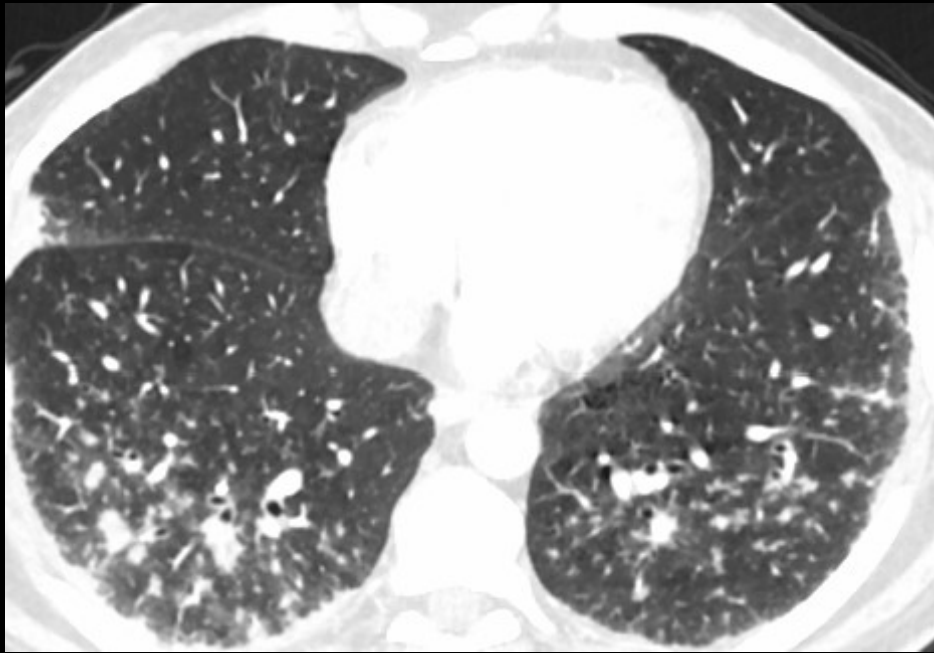
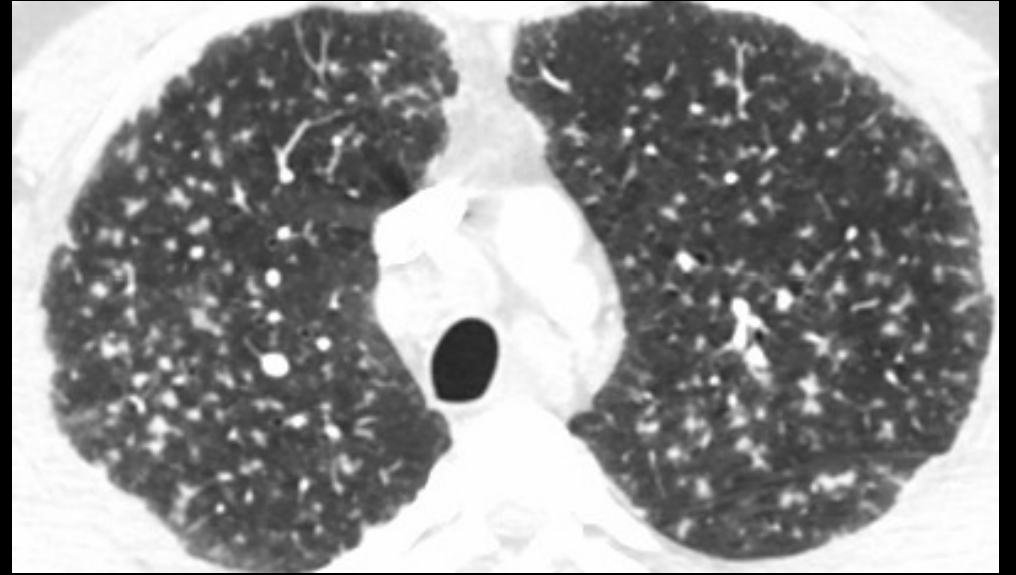
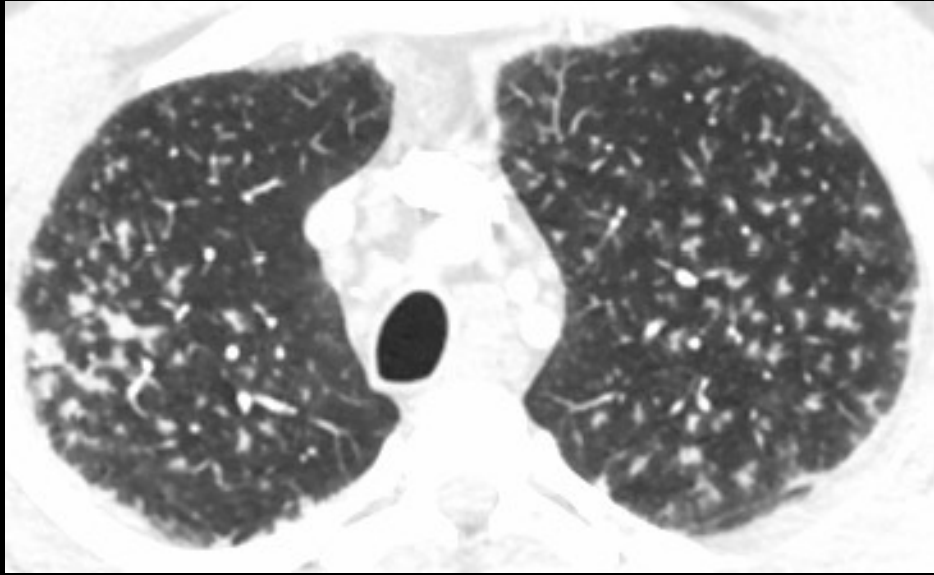
- LAM
- LHH
- Genetik sendrom
- Eozinofilik
Pnömoniler

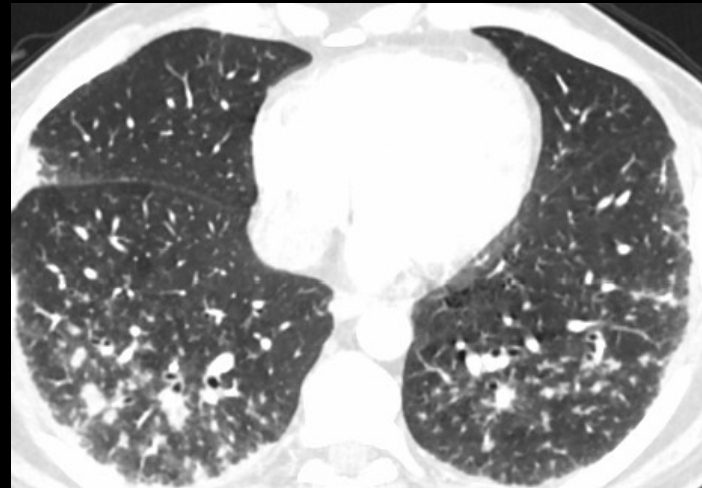
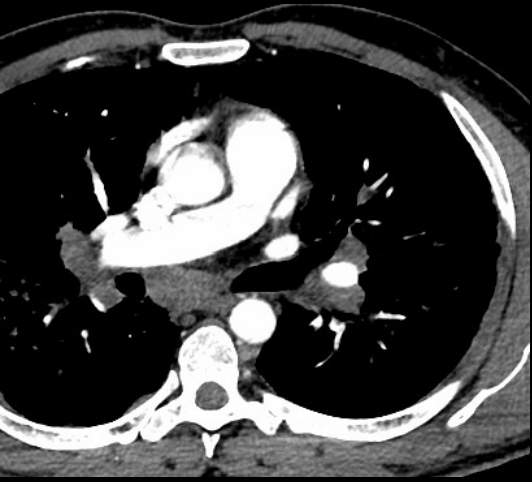
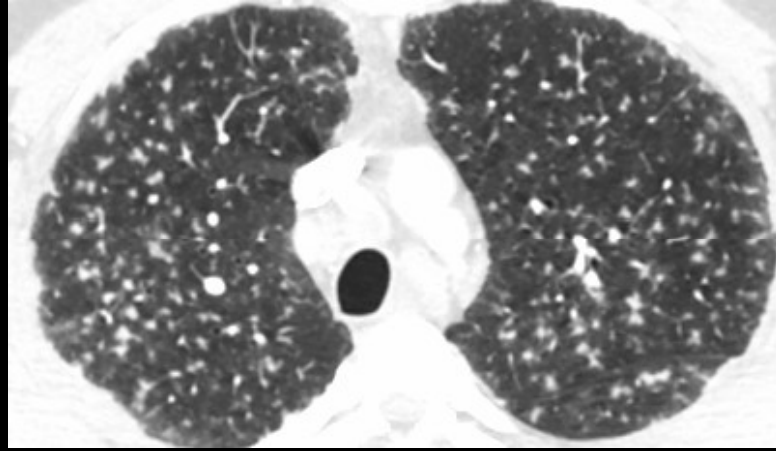
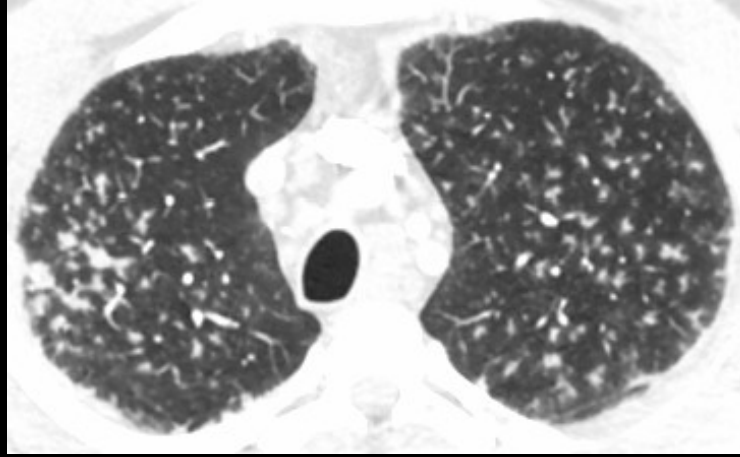
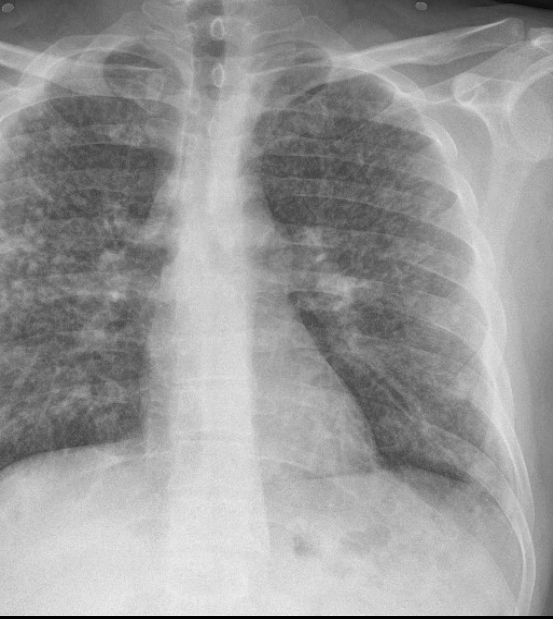


OLGU 1:



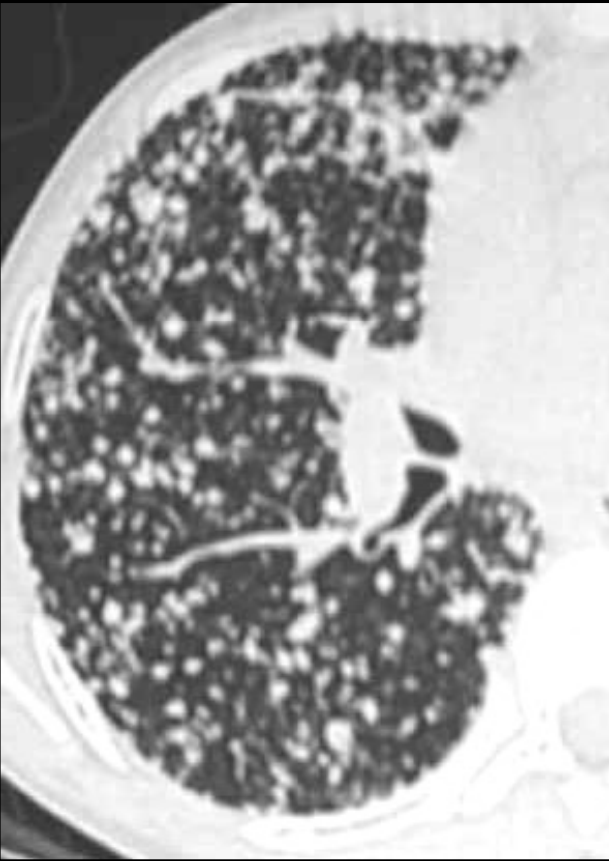
36 y, erkek
İş başvurusu
esnasında çekilen graf



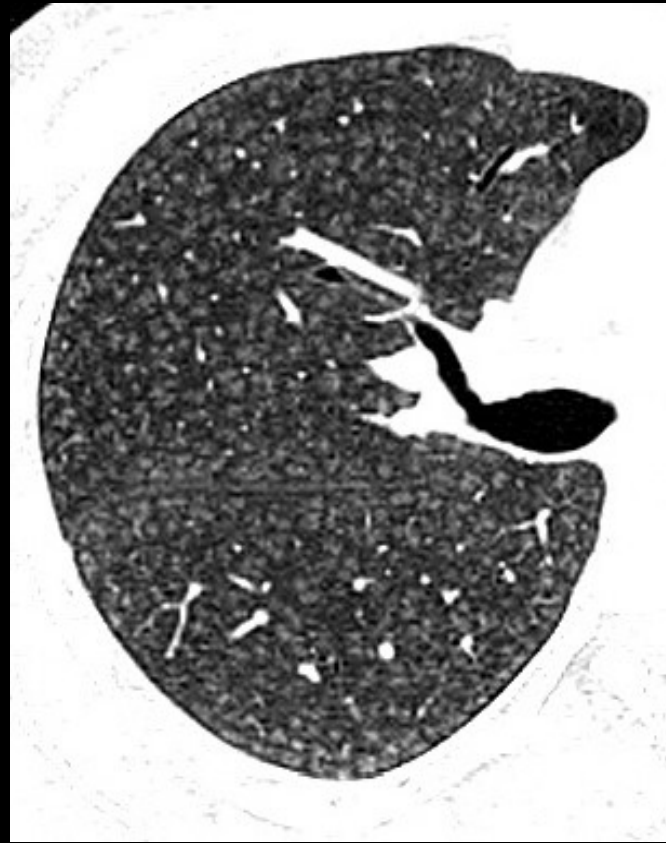


- 1.Hastaya ait bilgiler: genç erkek, belirgin şikayet yok
- 2.Dominanat patern :Nodüll
- 3.Zonal tutulumu? Üst zon
- 4.Eşlik eden bulgular: Hilar

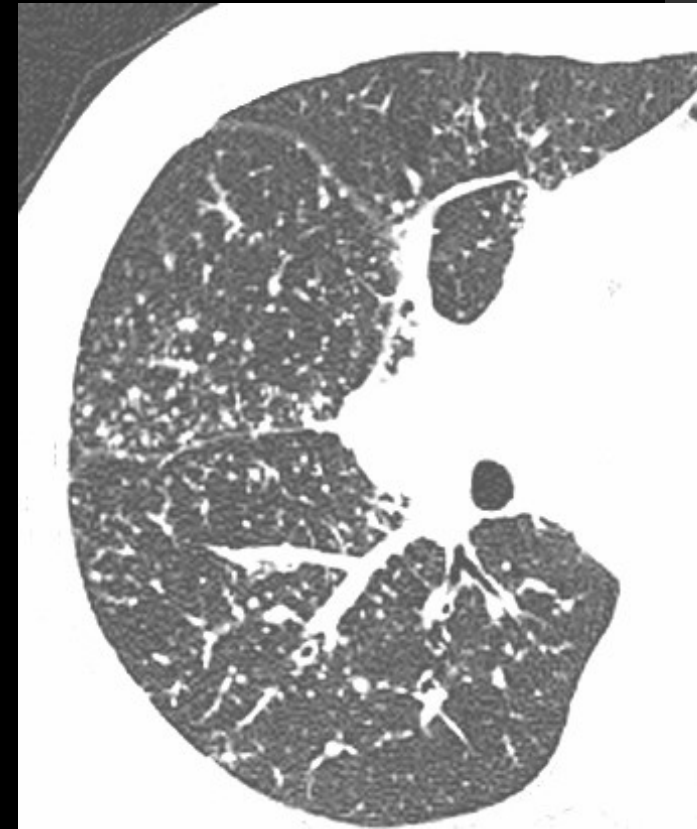
Nodüllerin dağılımı nasıl ?



1

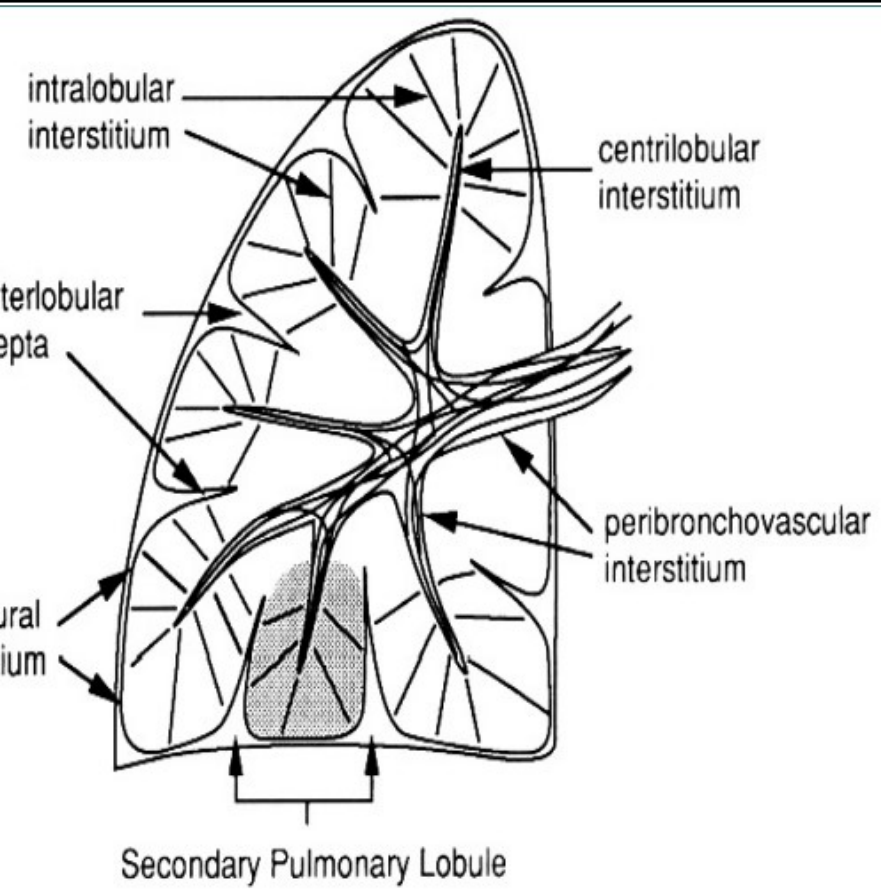


2

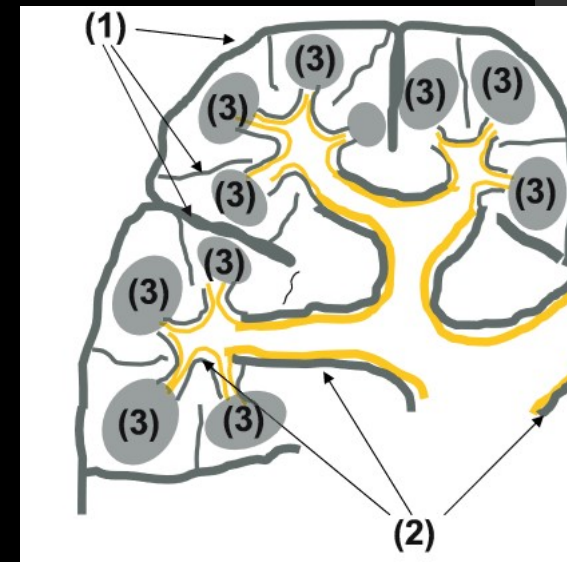
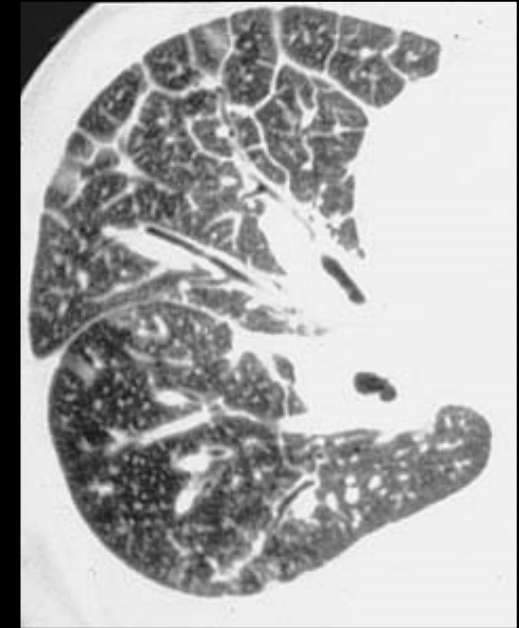
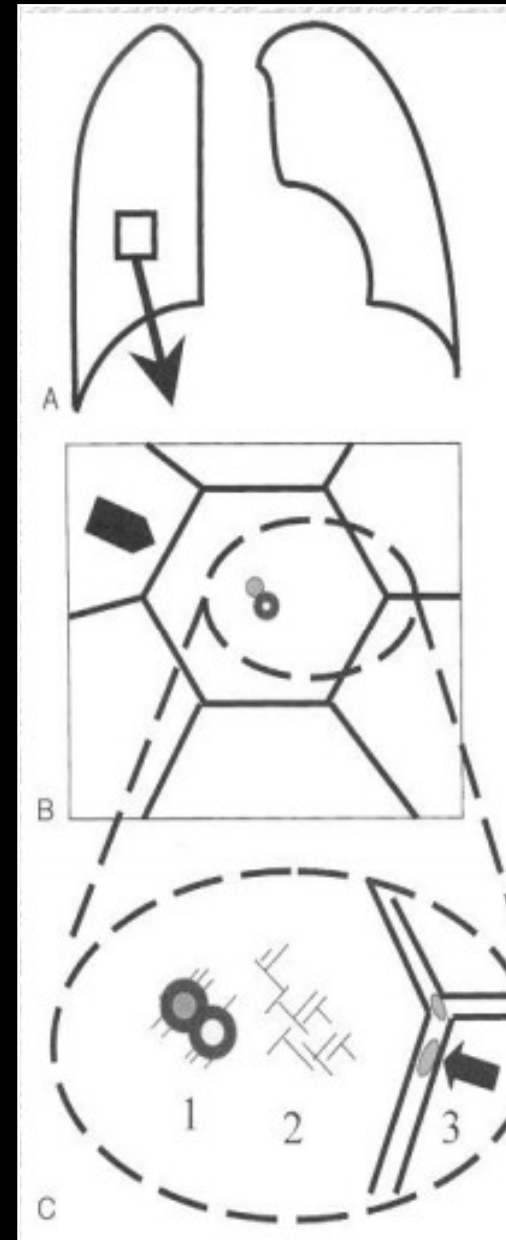


3

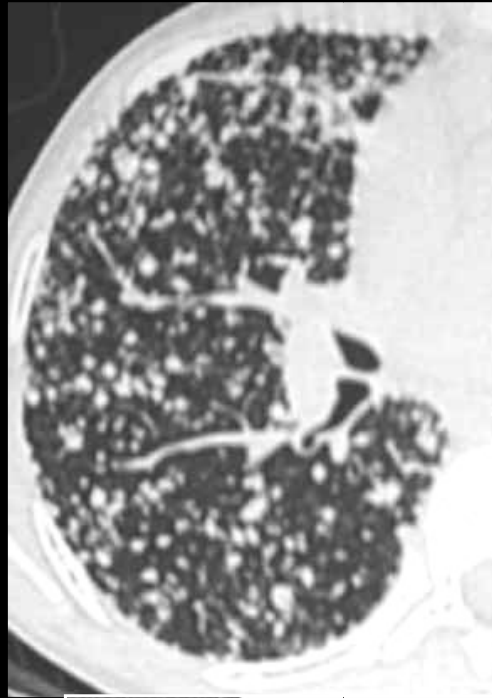
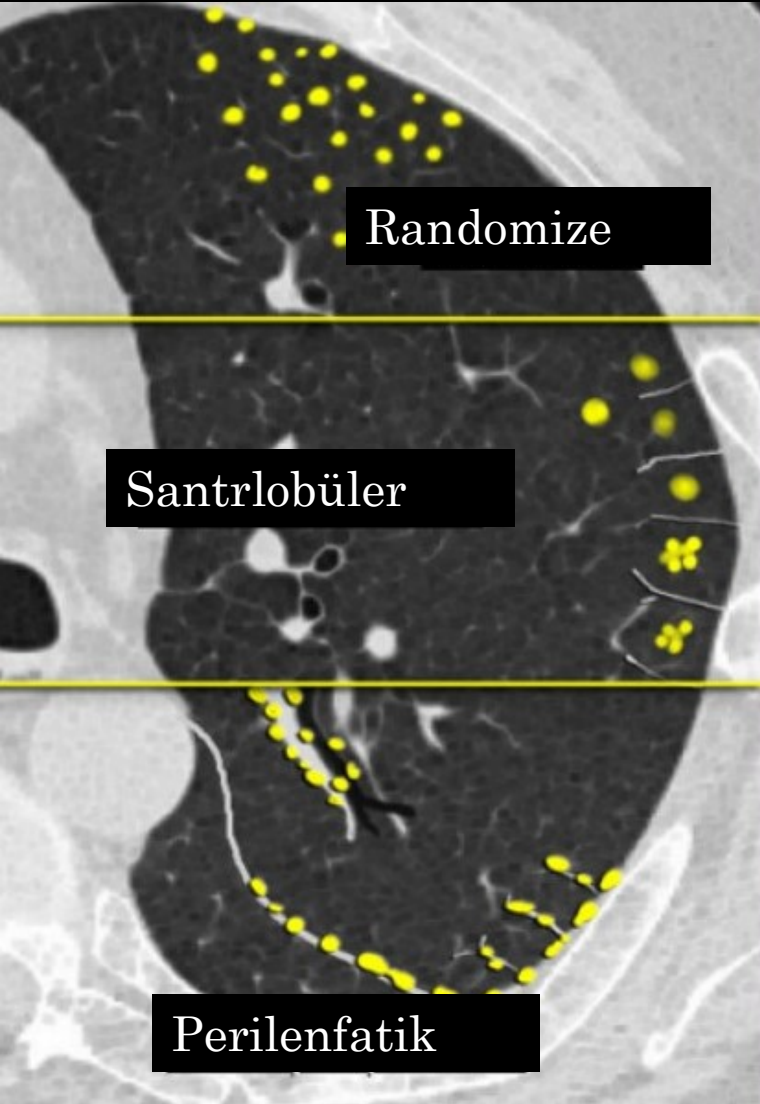
Intertisyum



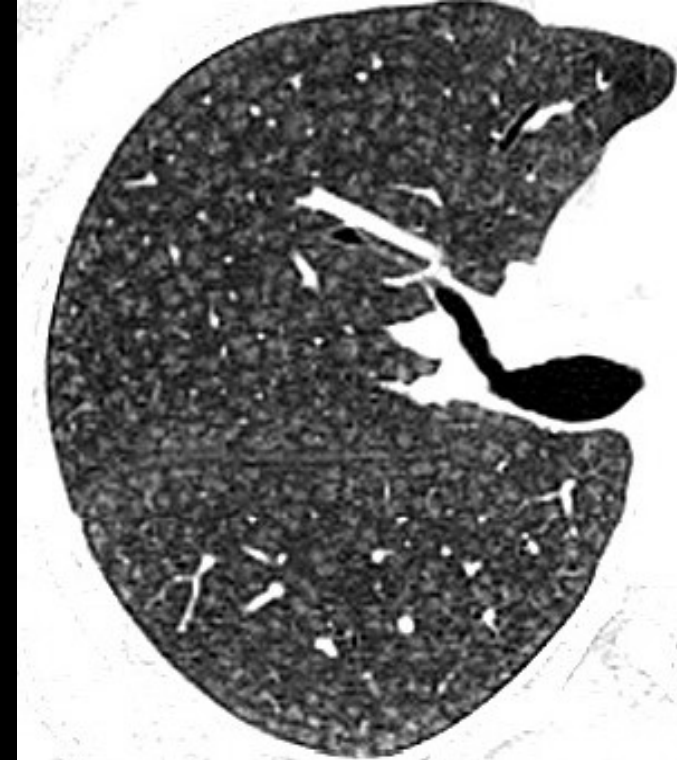
- Peribronkovasküler (aksiyal)
- Subplevral (periferik)
- İntralobuler (alveoler)



Nodüler Patern



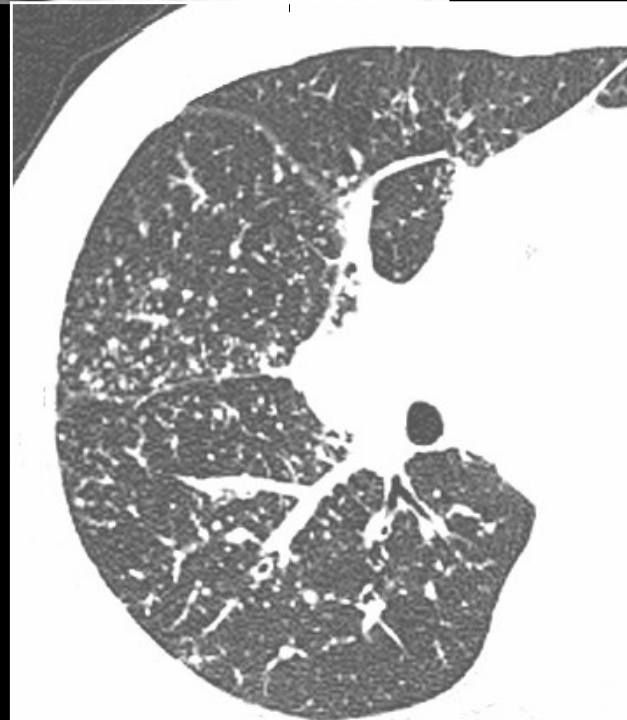1. Randomize (metastaz,
hematojen yayımlı enfeksiyonlar)

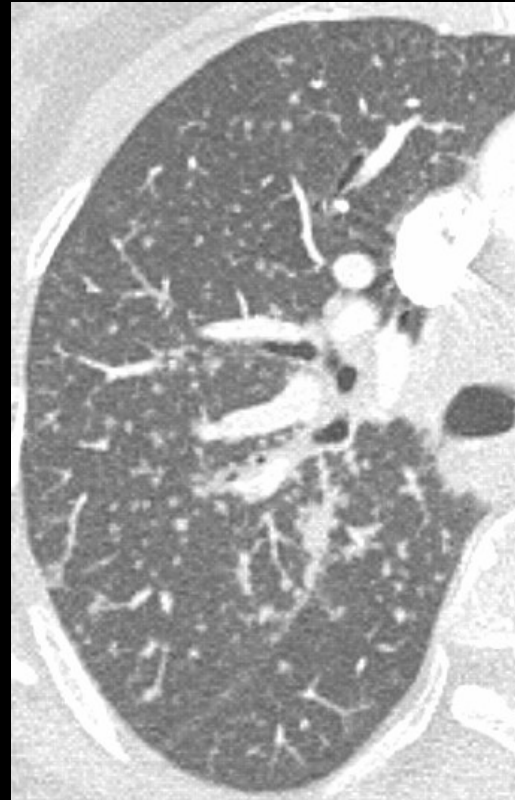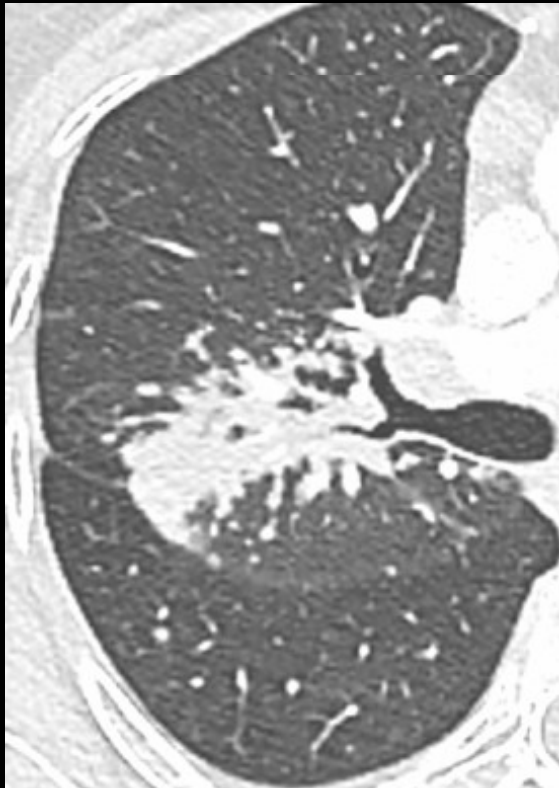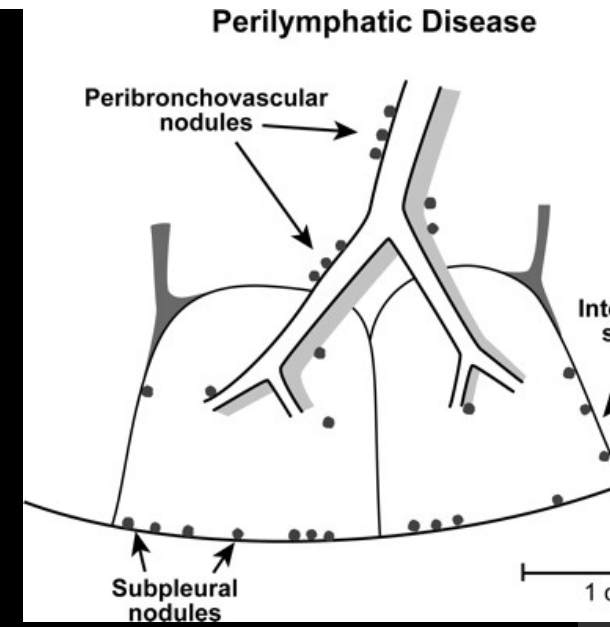
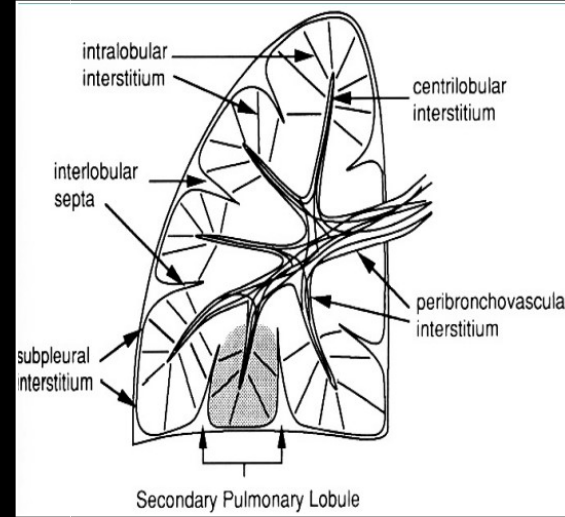
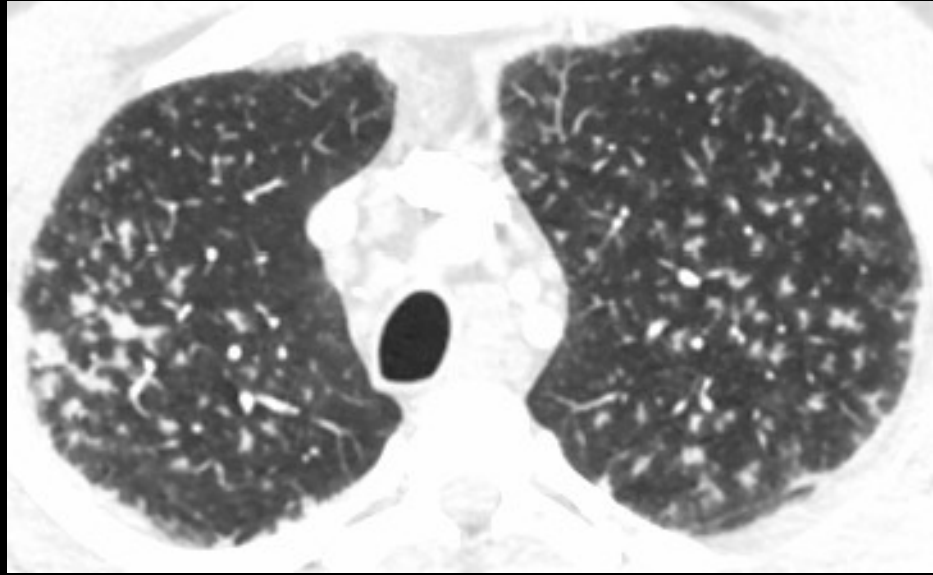


2. Santrlobüler
(HP, RB, LHH)

3. Perilenfatik

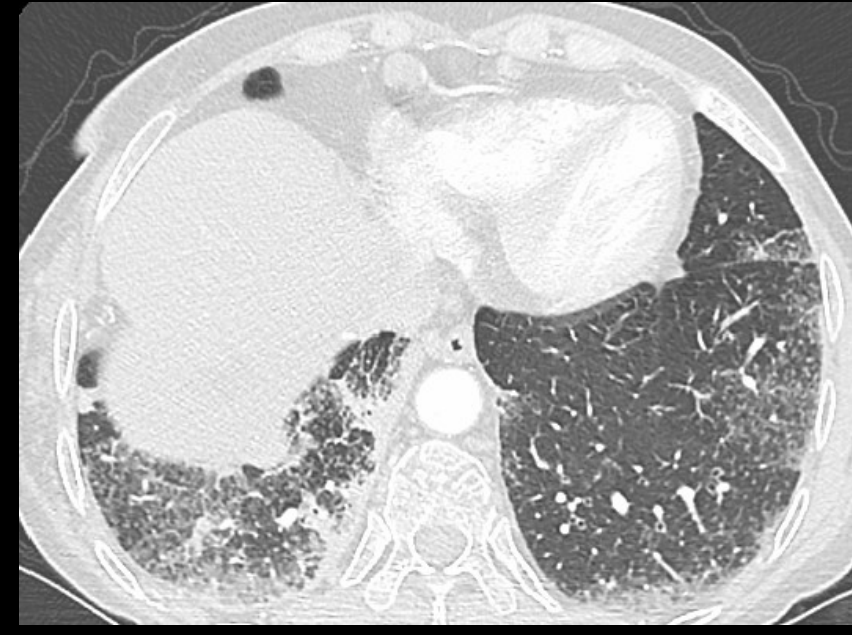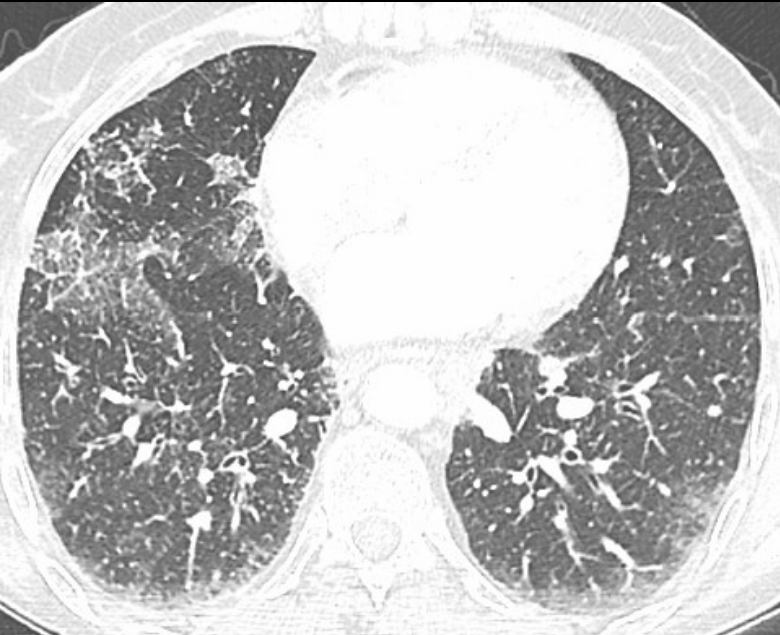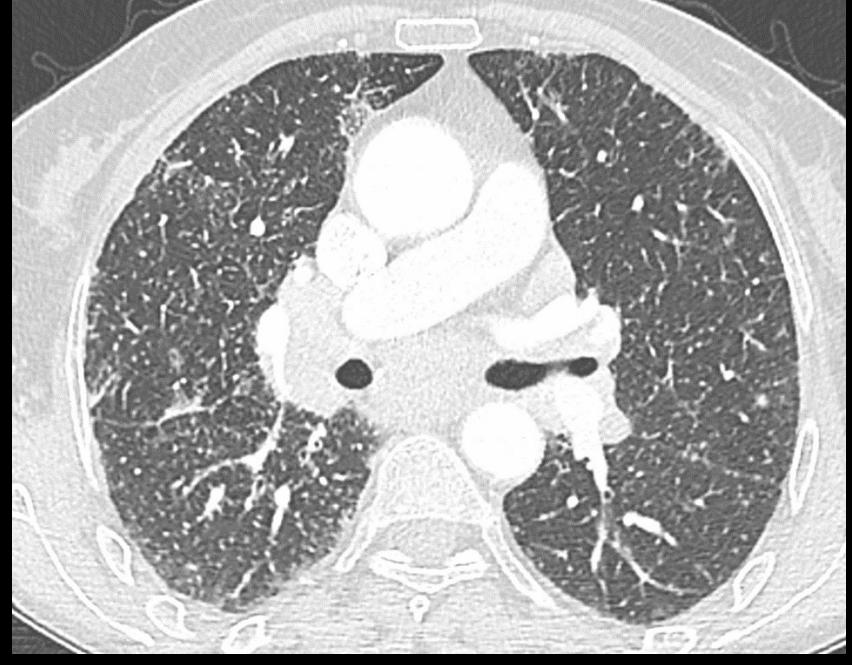
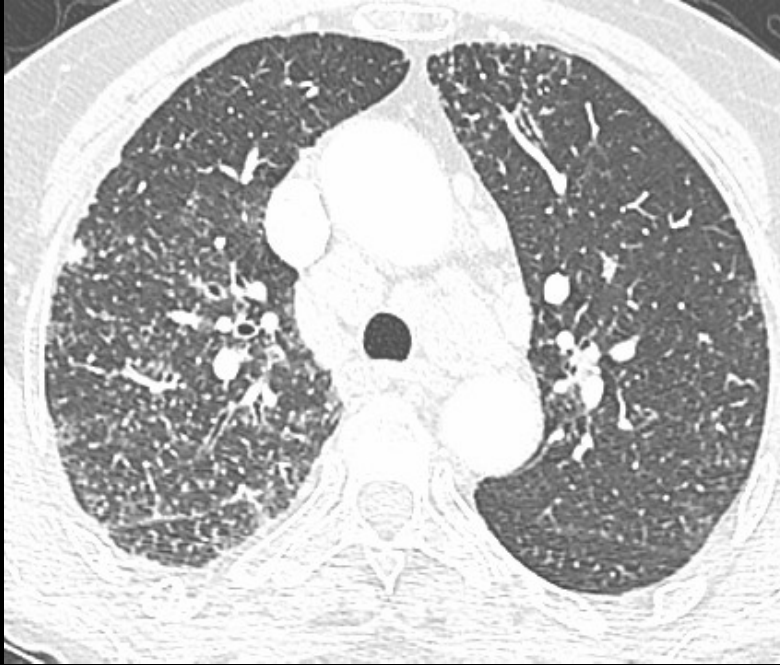(Sarkoidoz, Silikozis,
Lenfanjitik Metastaz)



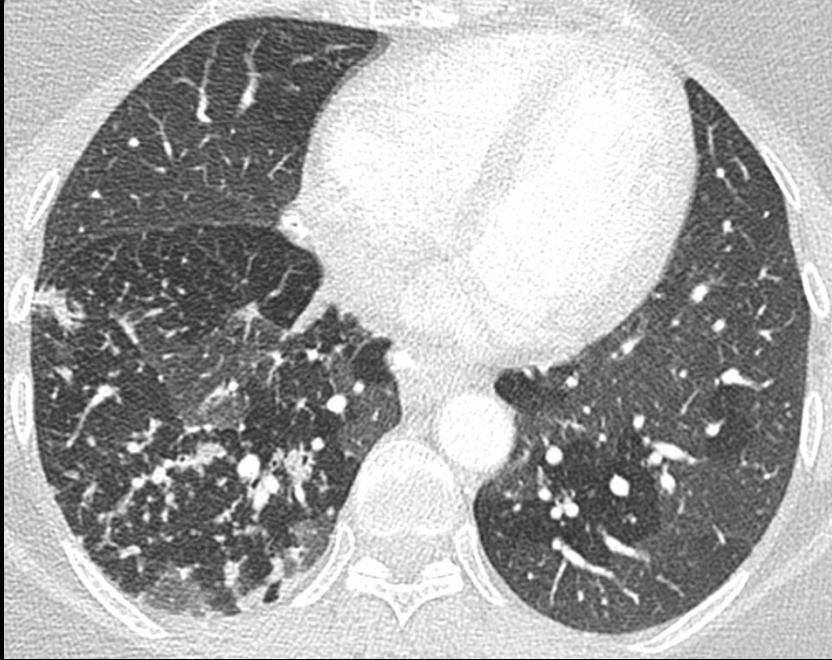
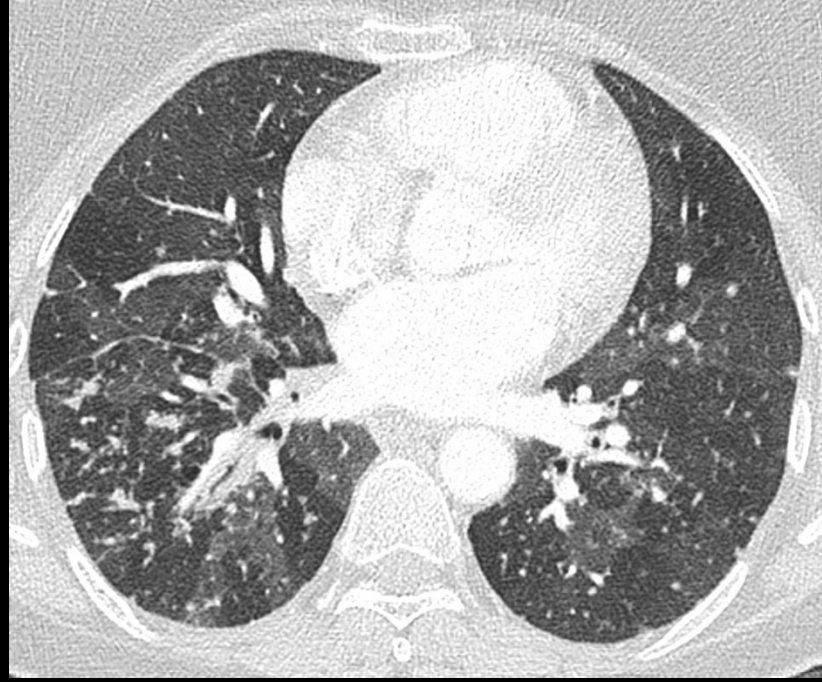
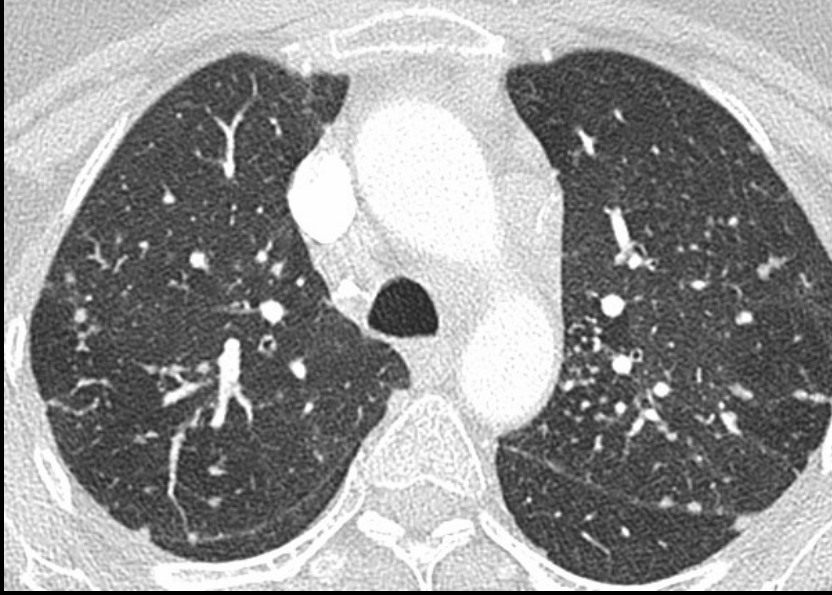

Sarkoidozda Nodüller

- ✓ Peribronkovasküler alanda
- ✓ İnterlobüler septalarda
- ✓ Fissürlerde
- ✓ Plevral yüzde
- ✓ Santrlobüler alanda



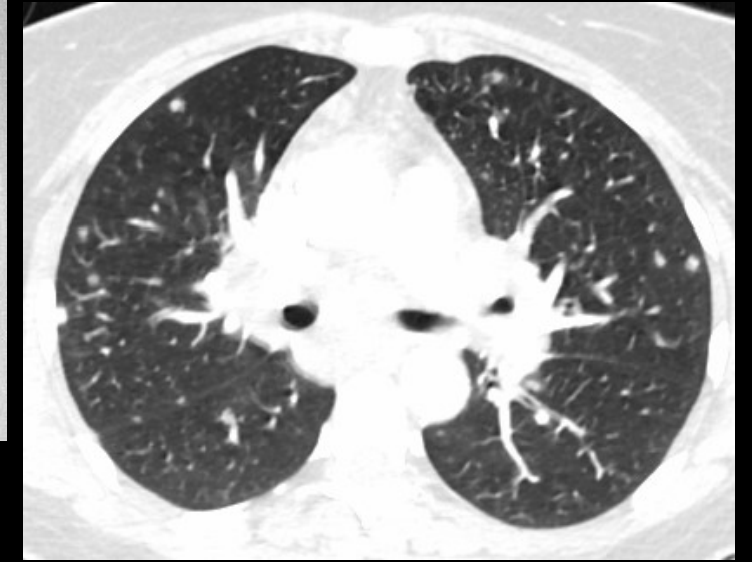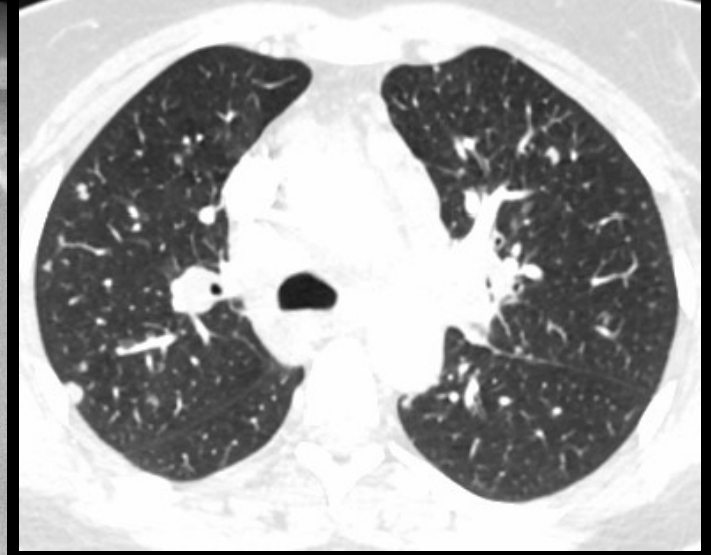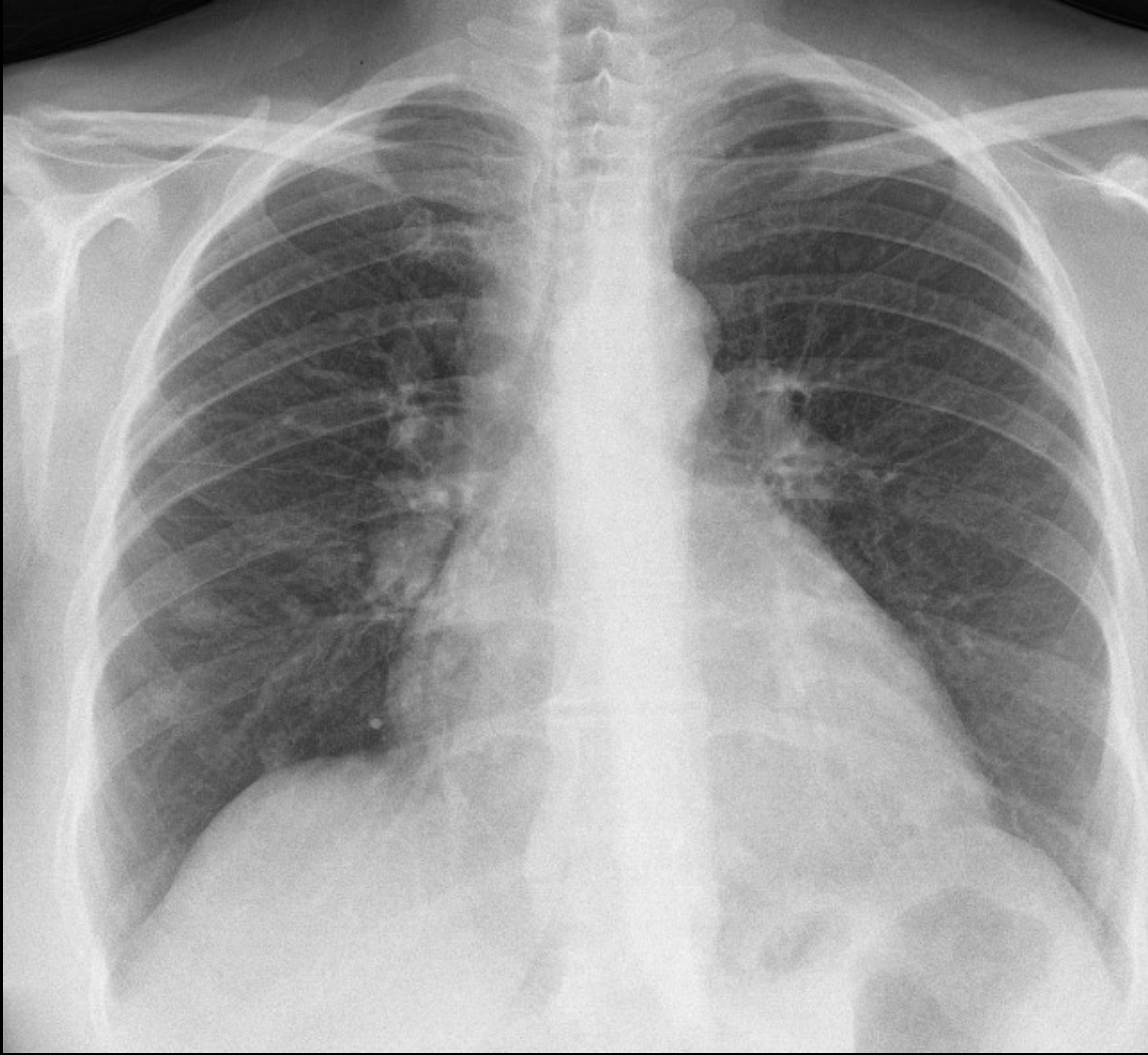
Buzlu cam alanları



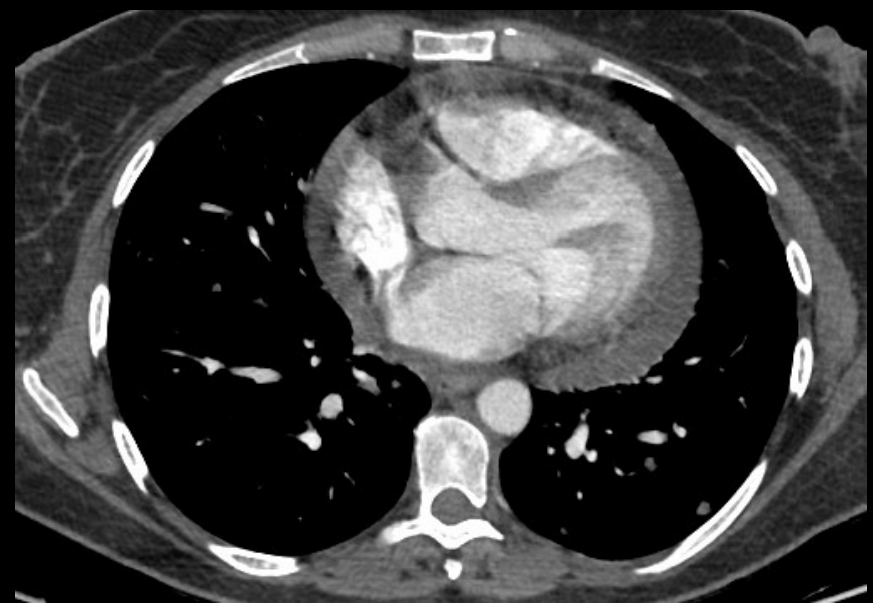
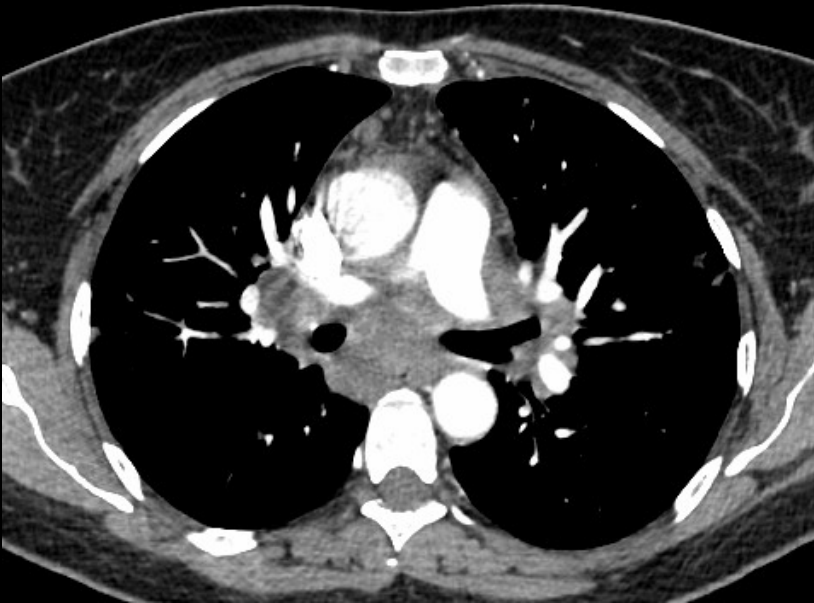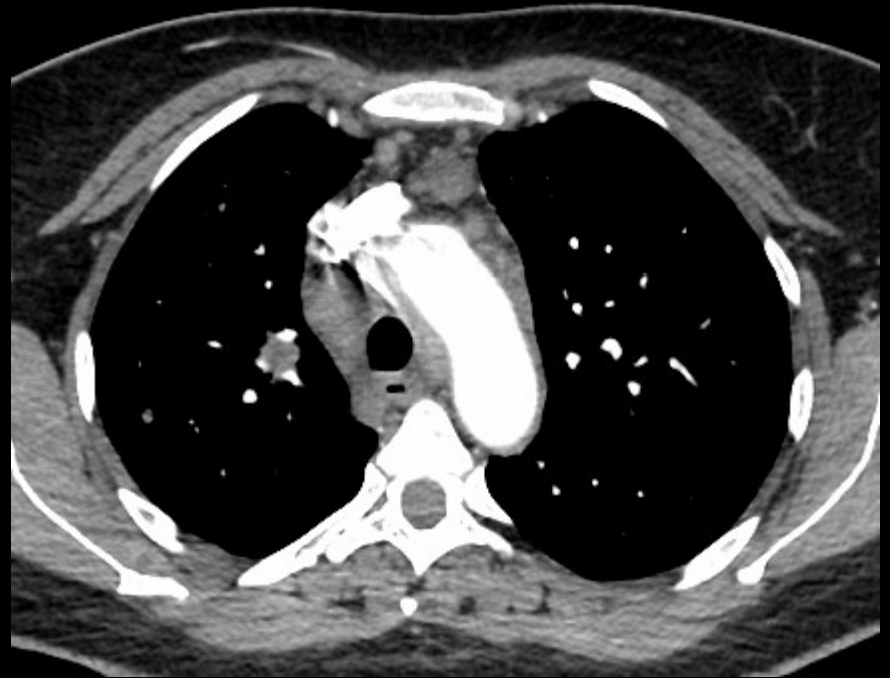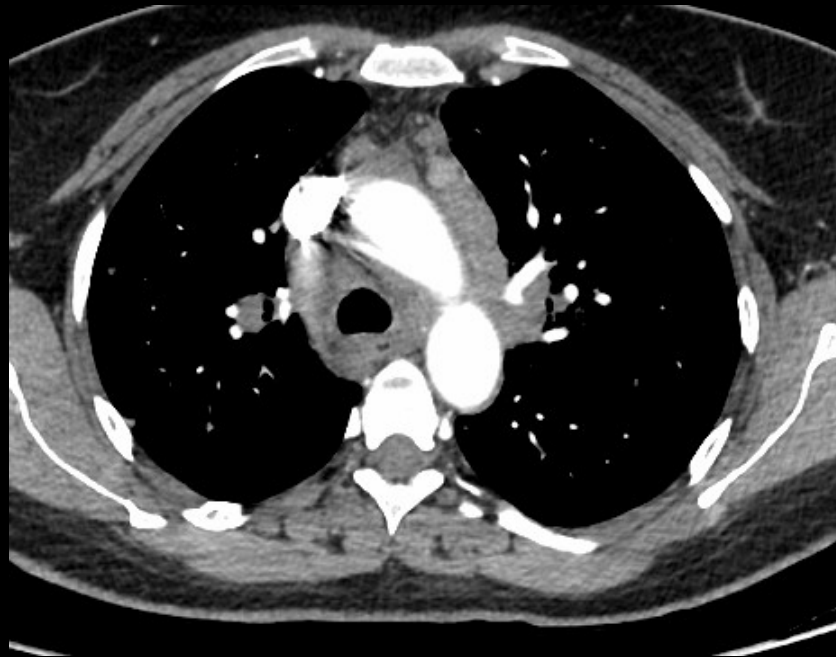Sarkoidozda Hava Yolu Hastalığı

- ✓ Trakeal/Bronşiyal Granülomlar
- ✓ Bronşiyal Stenoz/Distorsiyon
- ✓ KHYH bulguları
(Mozaik atenüasyon)

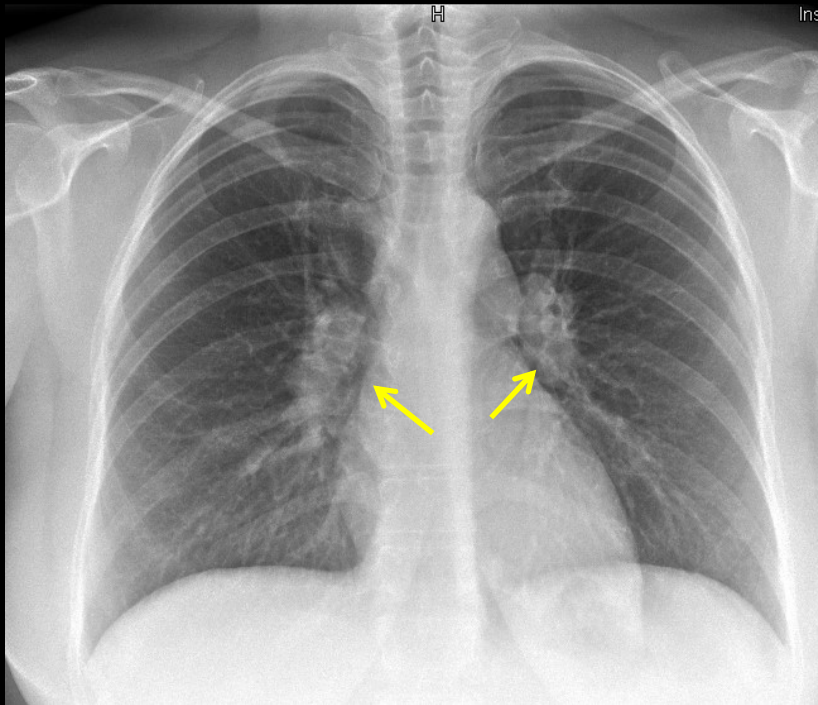
Mozaik Atenüasyon alanları



43 y, kadın hasta , sarkoidoz ön tanısı
ile göğüs hastalıklarına sevk ediliyor

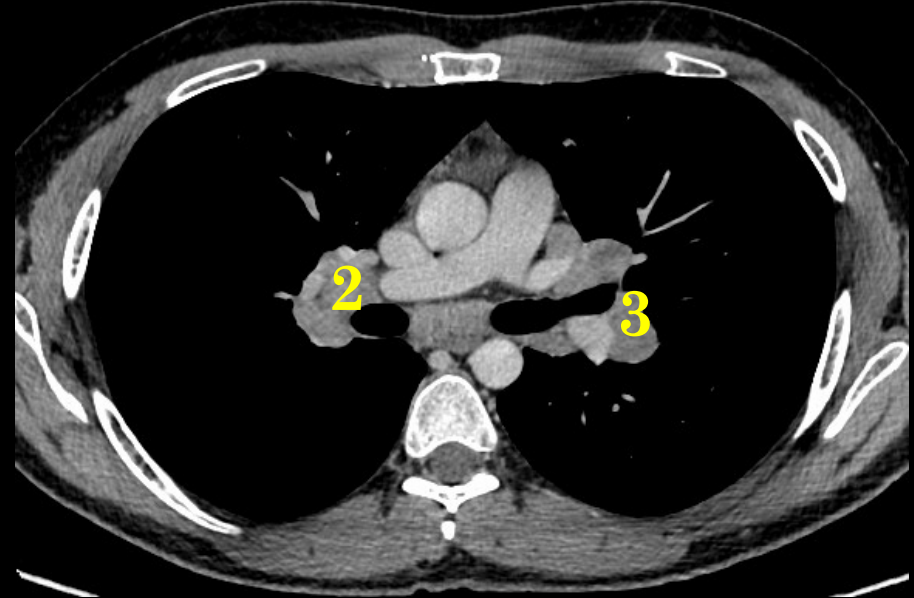
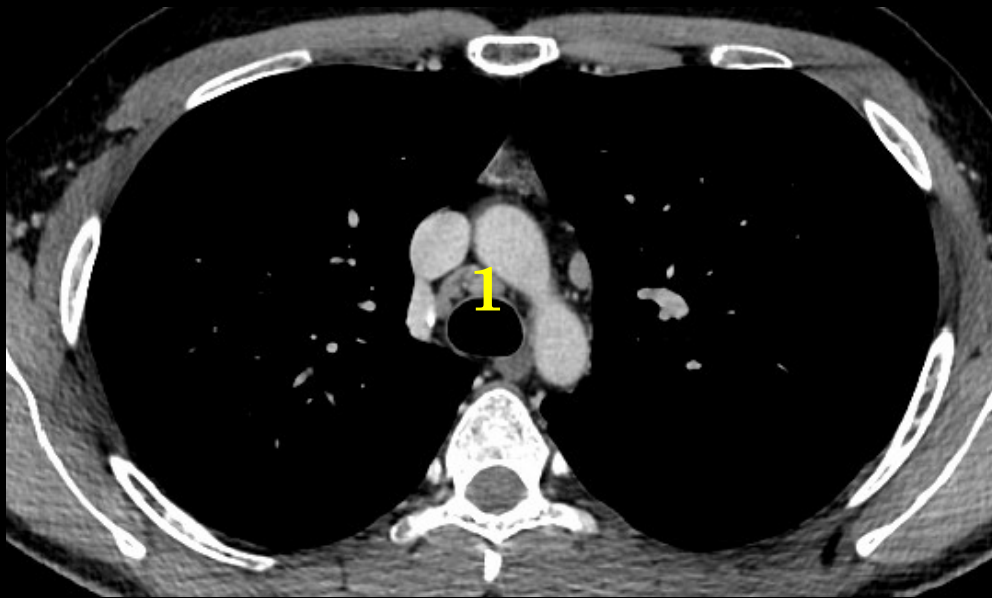


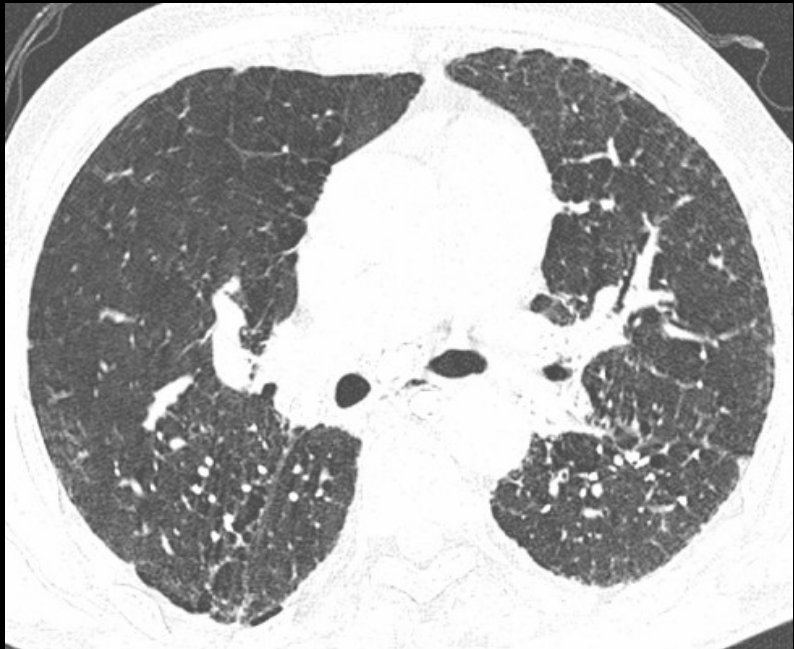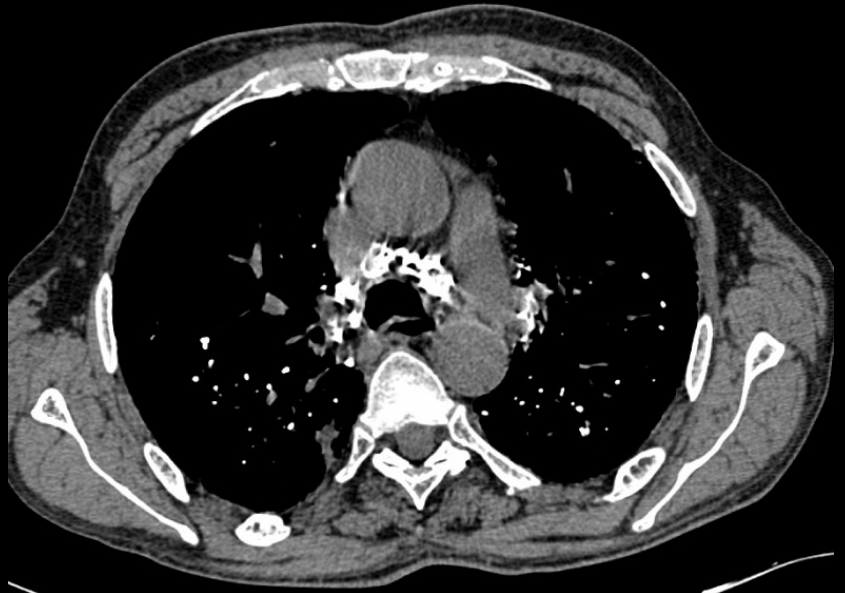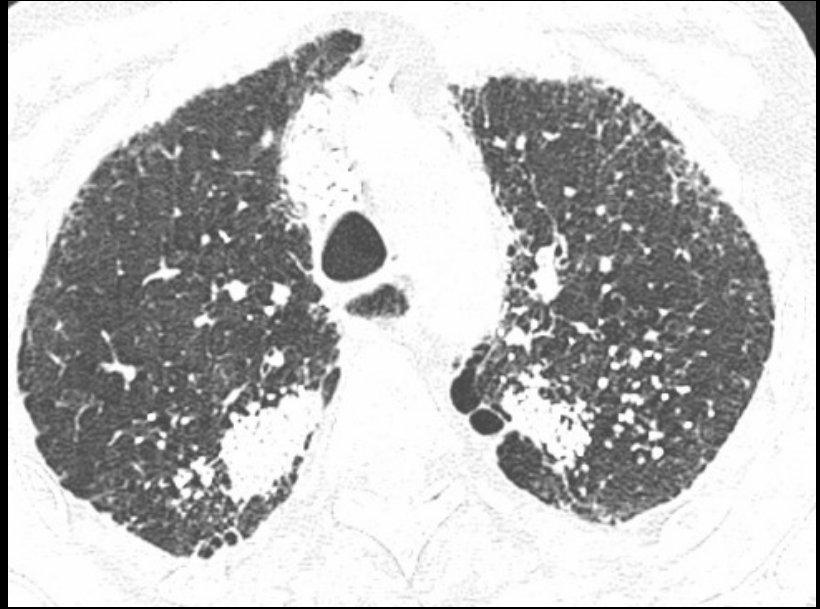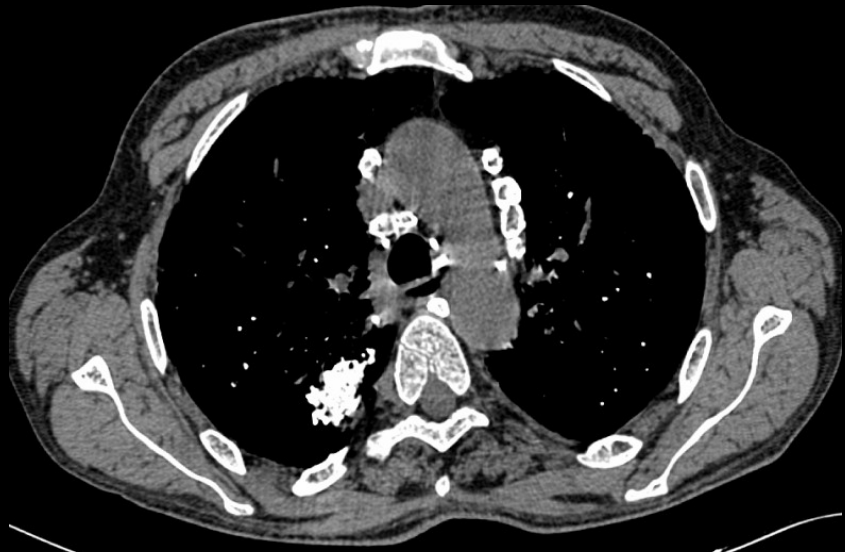Lenfoma



Sarkoidozda Adenopati

- ✓ Bilateral Hilar
 - ✓ Sağ paratrakeal
 - ✓ Subkarinal
 - ✓ AP pencere
- Daha Nadiren:
- ✓ Ön/Arka Mediasten
 - ✓ Parakardiyak
 - ✓ Retrokrural

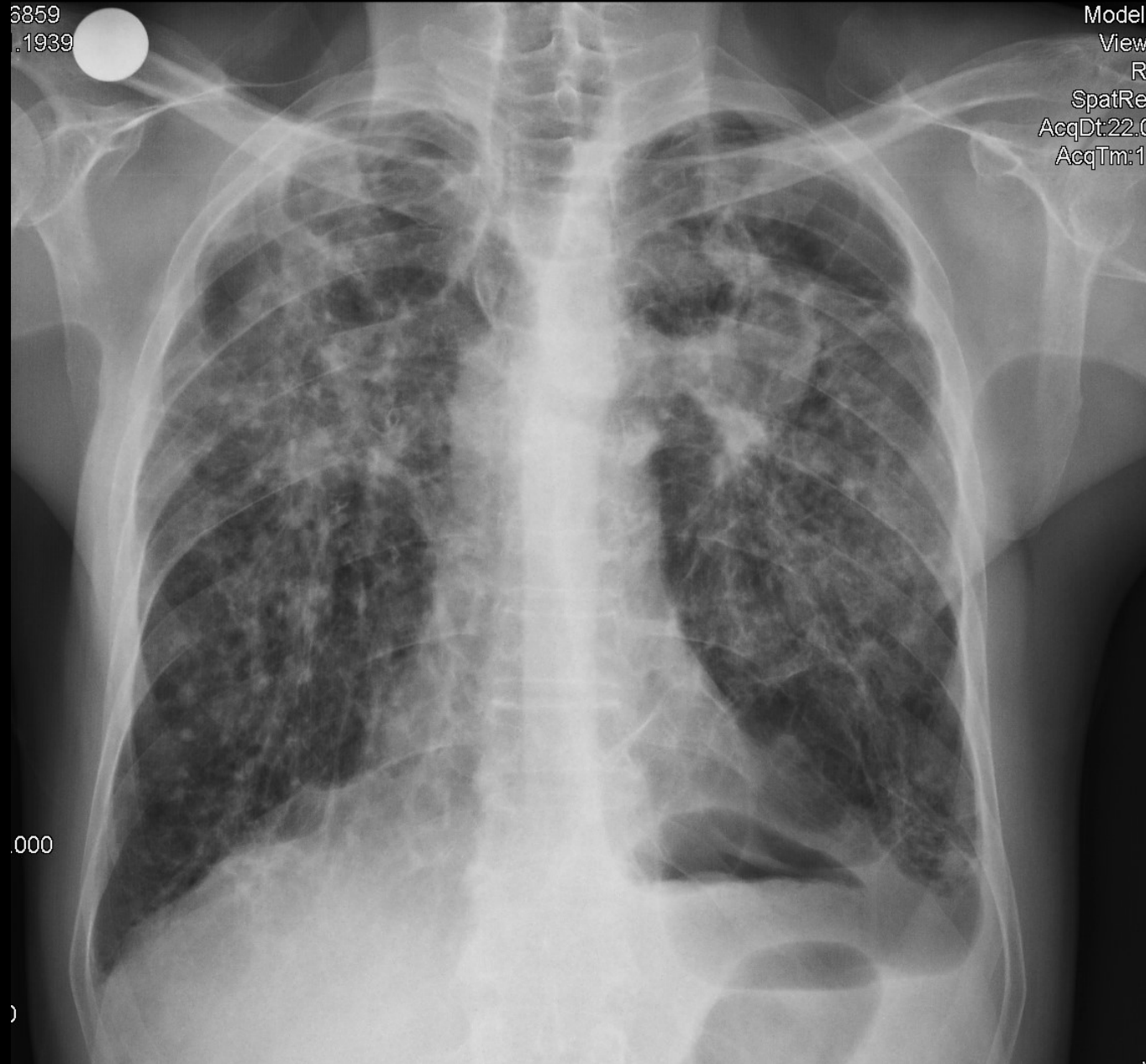



6859
.1939

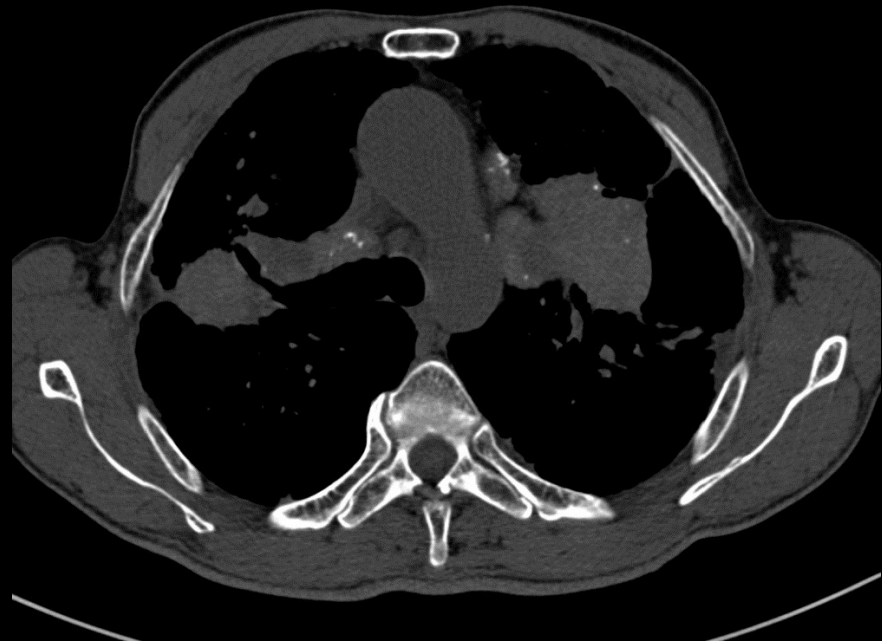
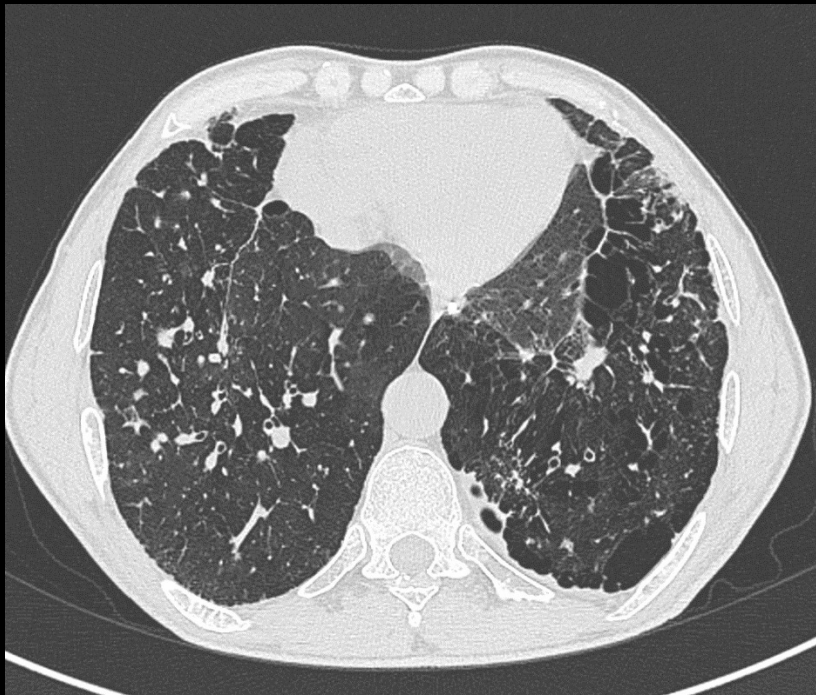
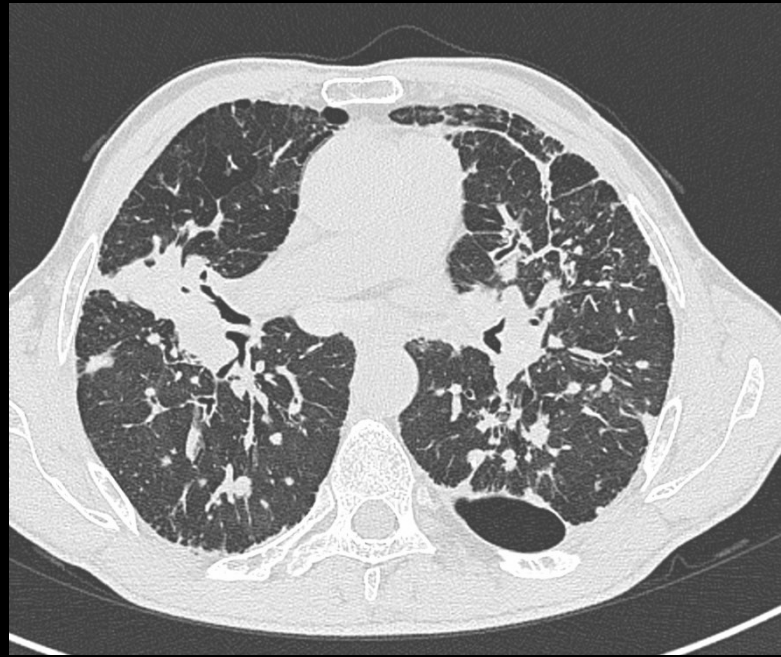
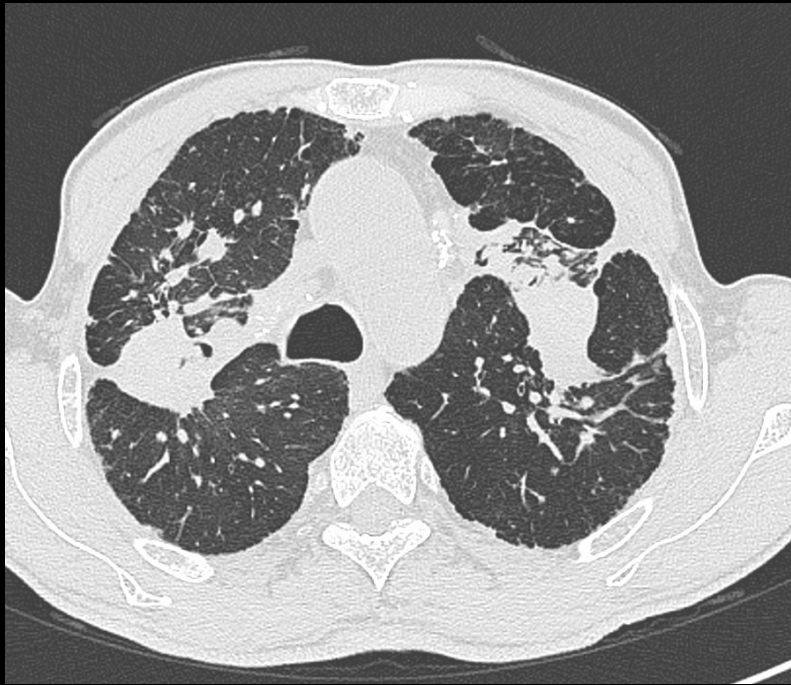


Model:
View:
Re:
SpatRes:
AcqDt:22.0
AcqTm:14



.000

)



OLGU 2:

45 yaşında, erkek,
sigara kullanıcısı, nefes darlığı

Diagnozunuz Nedir?

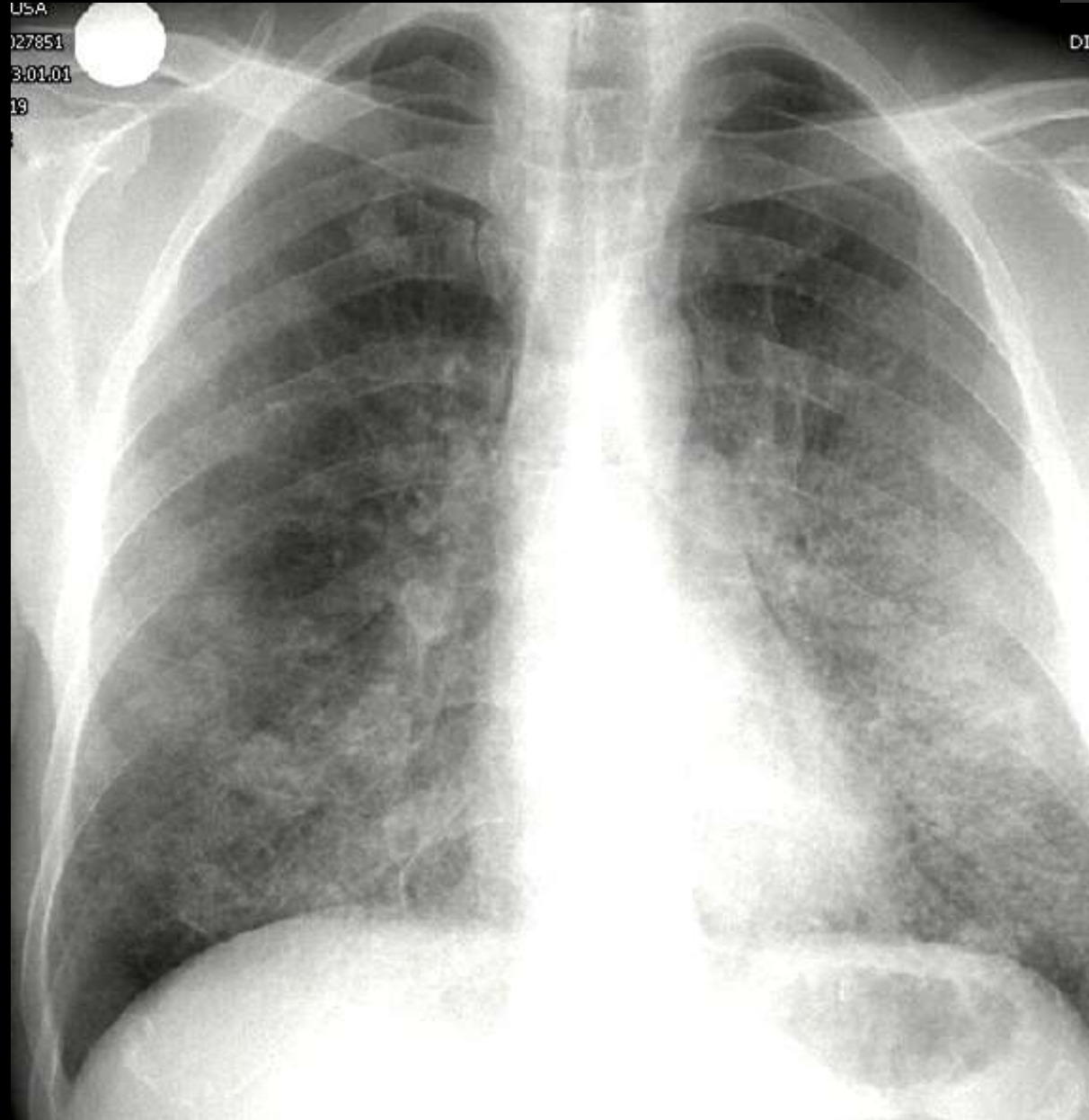
Kronik Hipersensitivite Pnömonisi

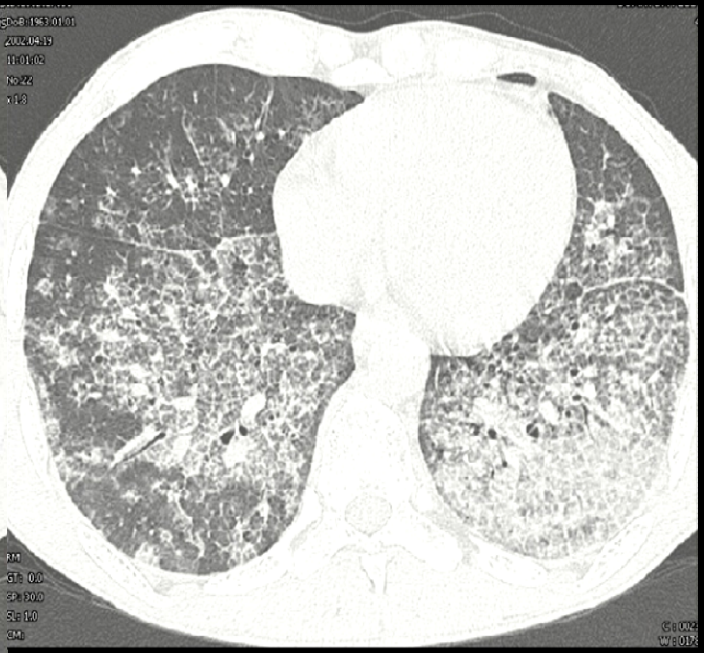
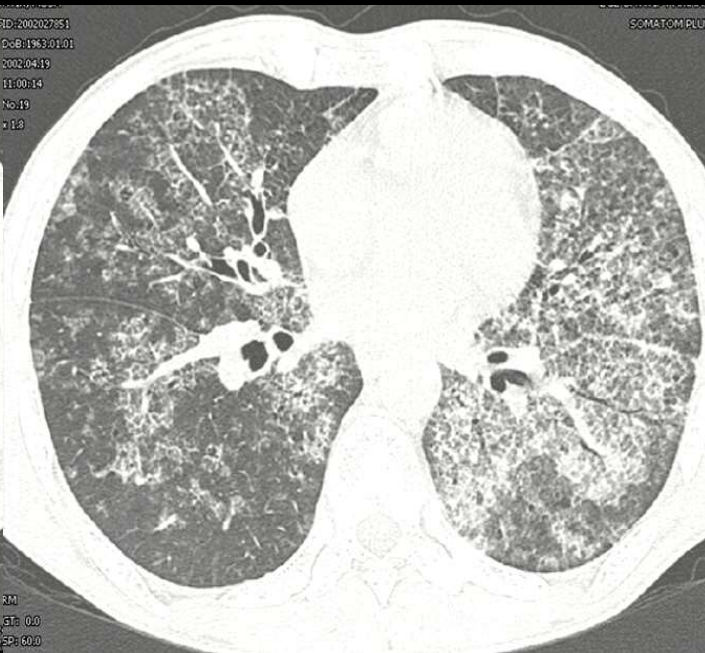
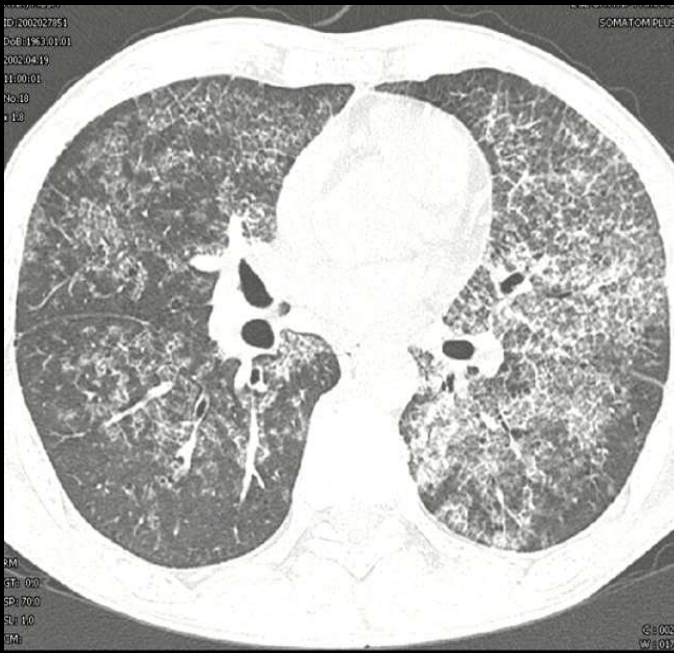
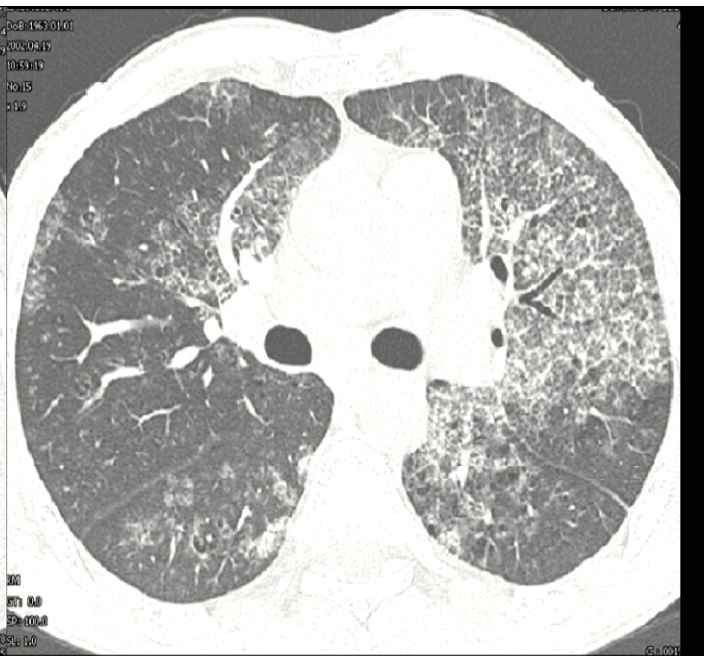
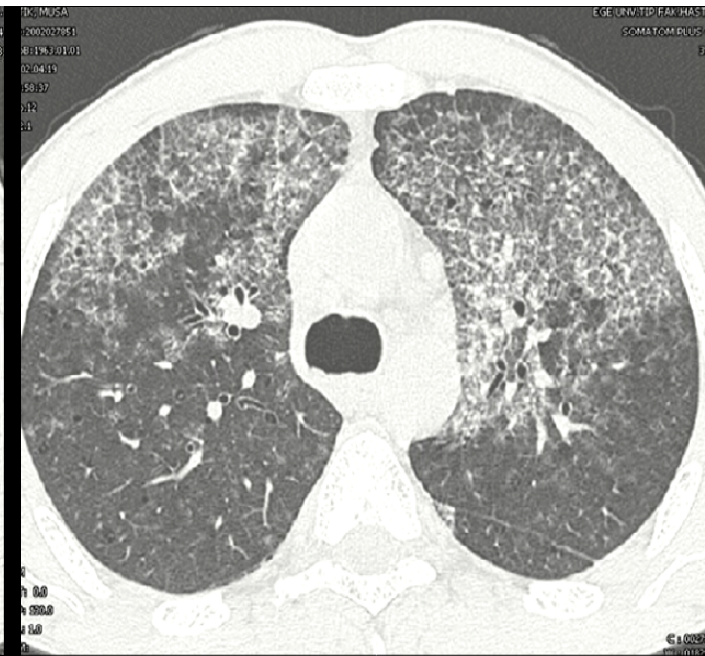
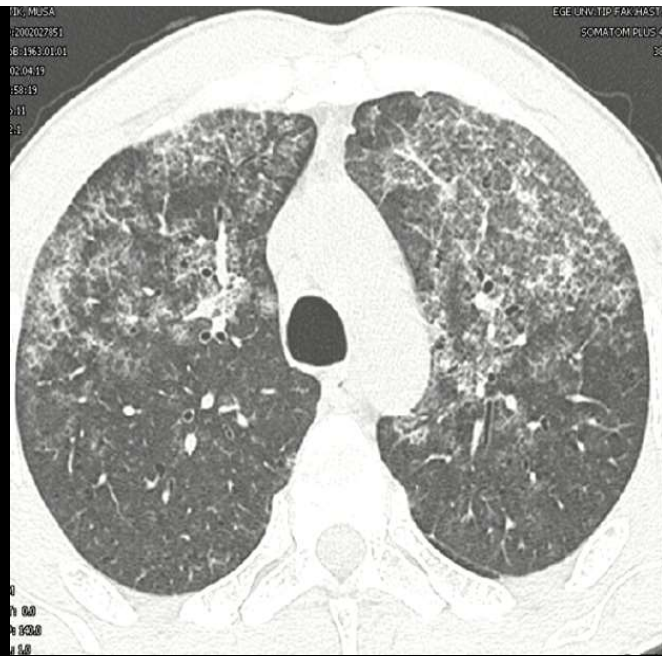
Pulmoner Alveoler Proteinozis

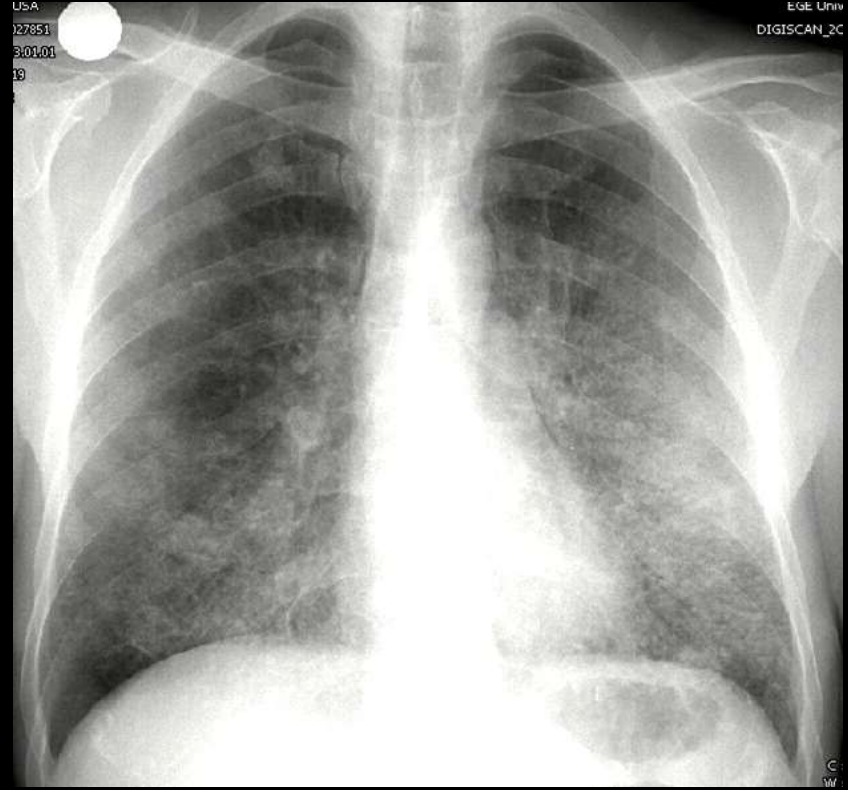
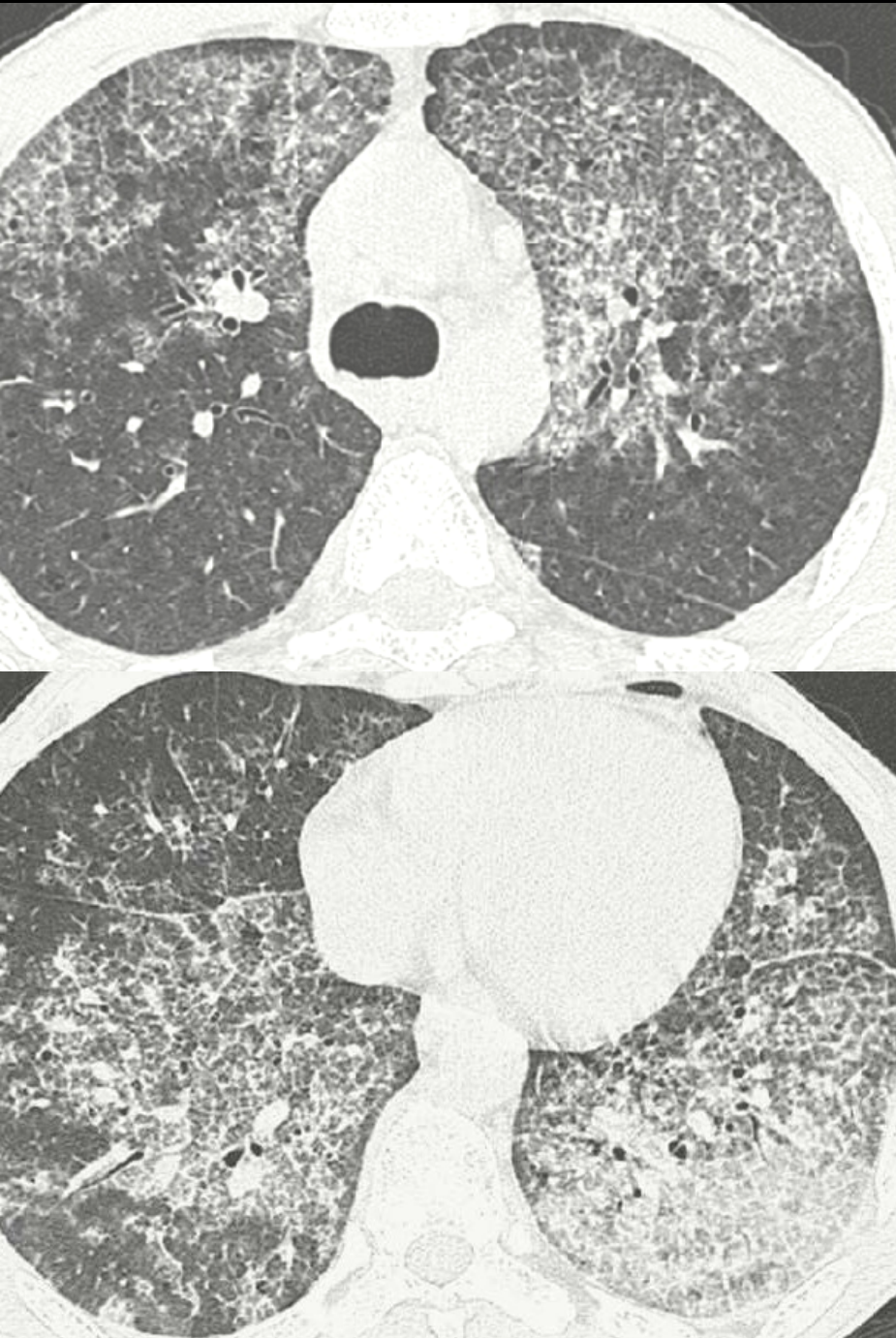
Pulmoner Ödem

Pnömosistis Jerovici Pnömonisi

YIP







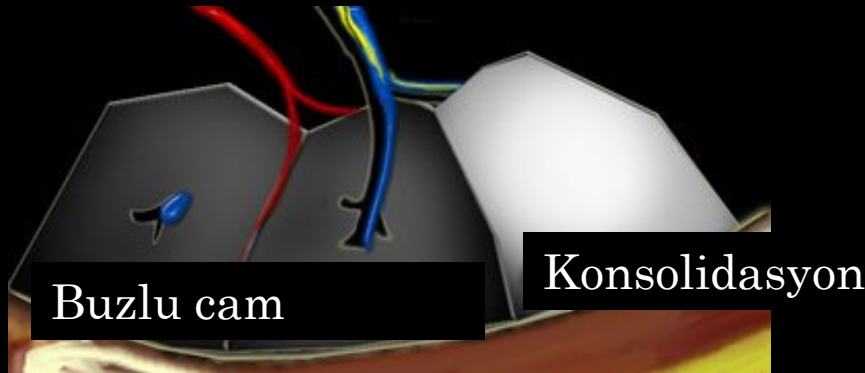
- 1.Hastaya ait bilgiler: genç ,erkek,
- 2.Dominanat patern :Buzlu cam ve retiküler işaretler
- 3.Tutulum şekli? : apikal kesim, kostofrenik sinüsler korunmuş, santral akciğerde simetrik tutulum
- 4.Eşlik eden bulgular: yok

Dansite

Artmış Dansite

Azalmış Dansite

- Konsolidasyon
- Buzlu Cam



Buzlu Cam Alanları

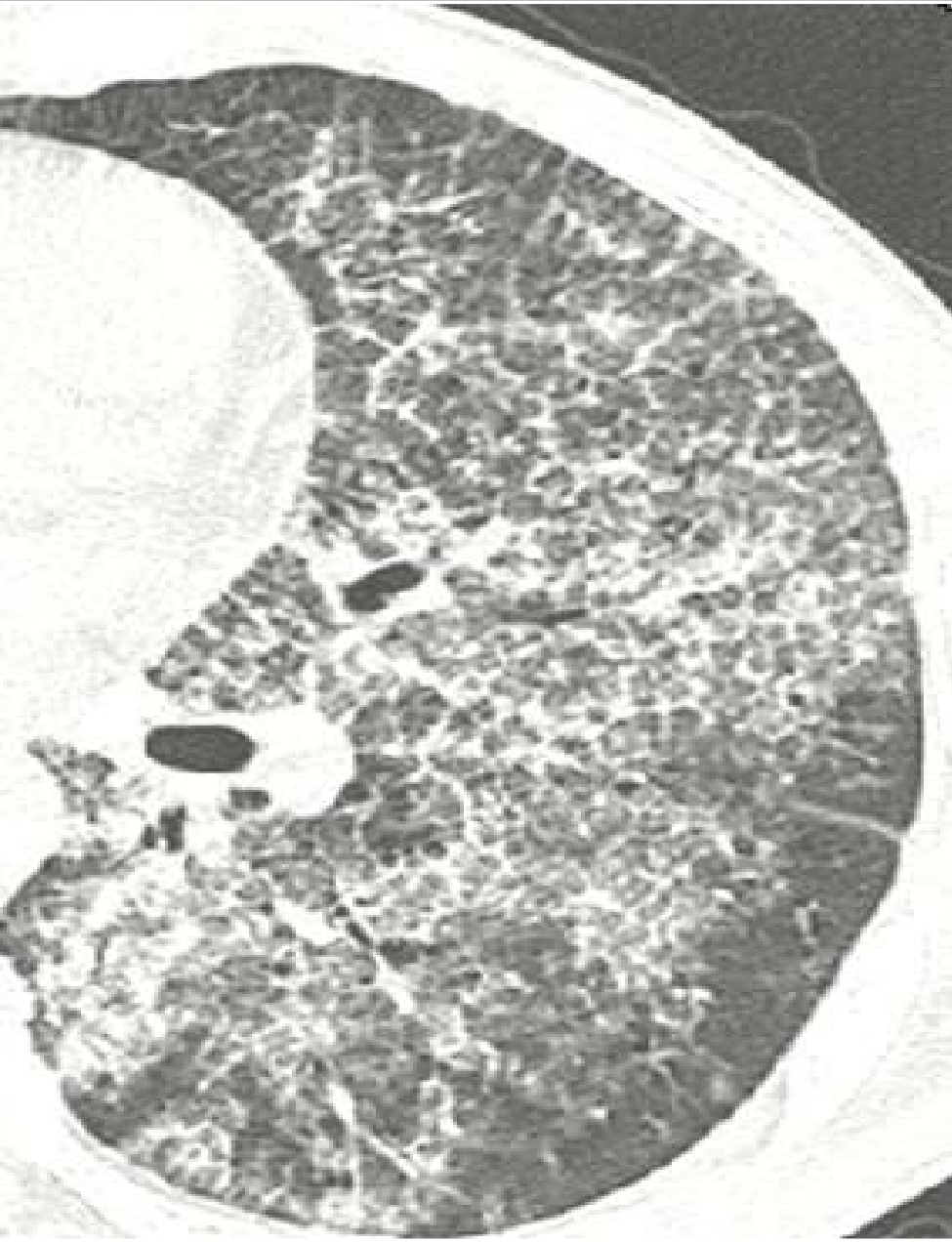
AKUT

- Pulmoner Ödem
- Enfeksiyonlar
- Alveoler Hemoraji
- Akut Hipersensitivite Pnömonisi

SUBAKUT/KRONİK

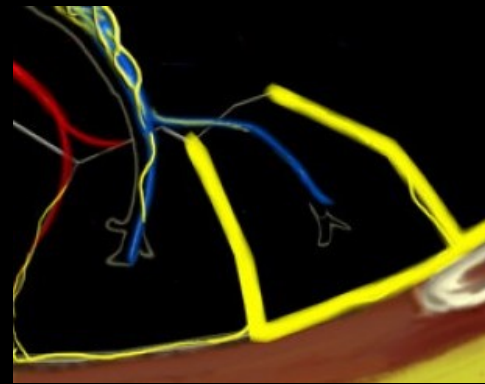
- NSIP
- DIP
- PAP
- Kronik HP
- Organize Pnömoni
- Adenokanser

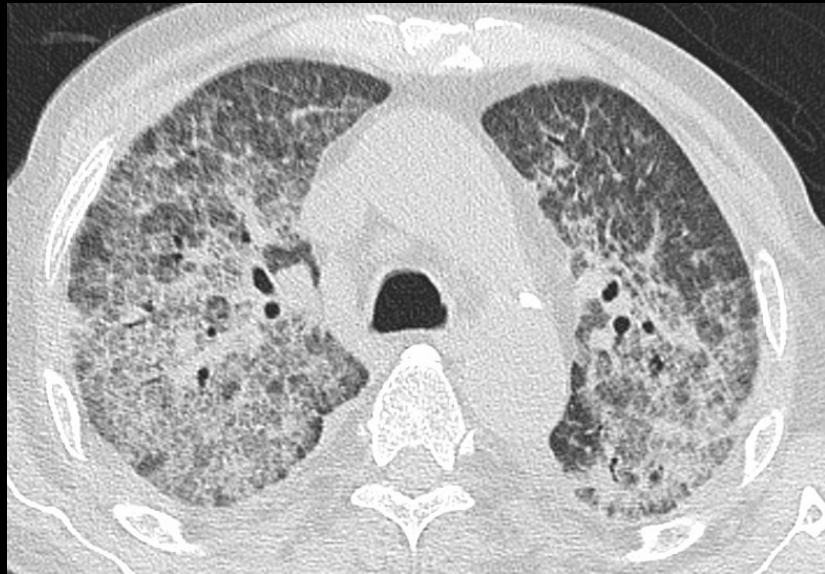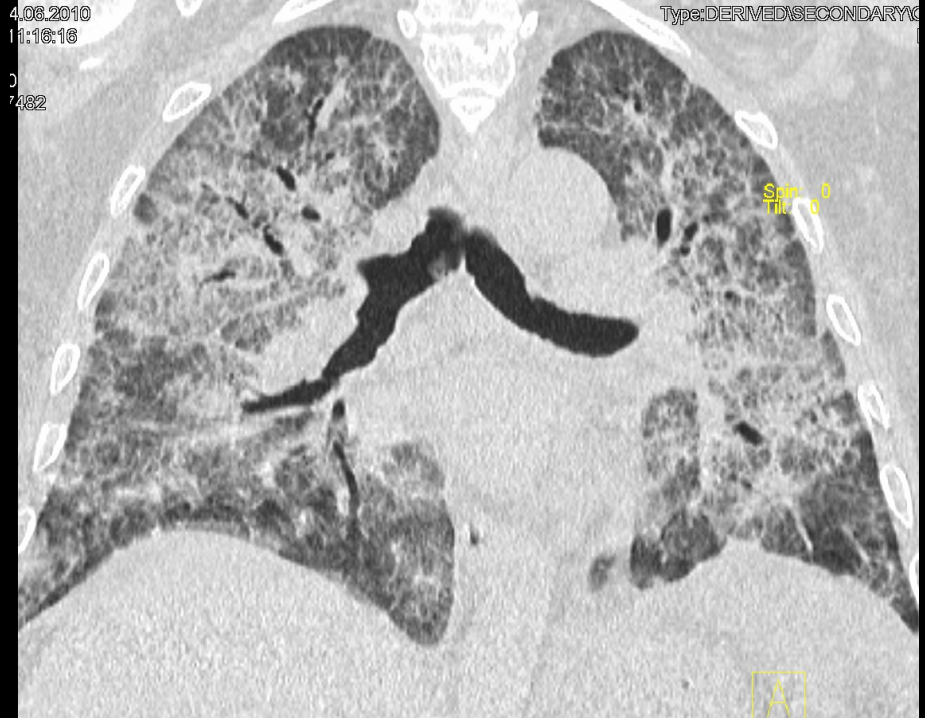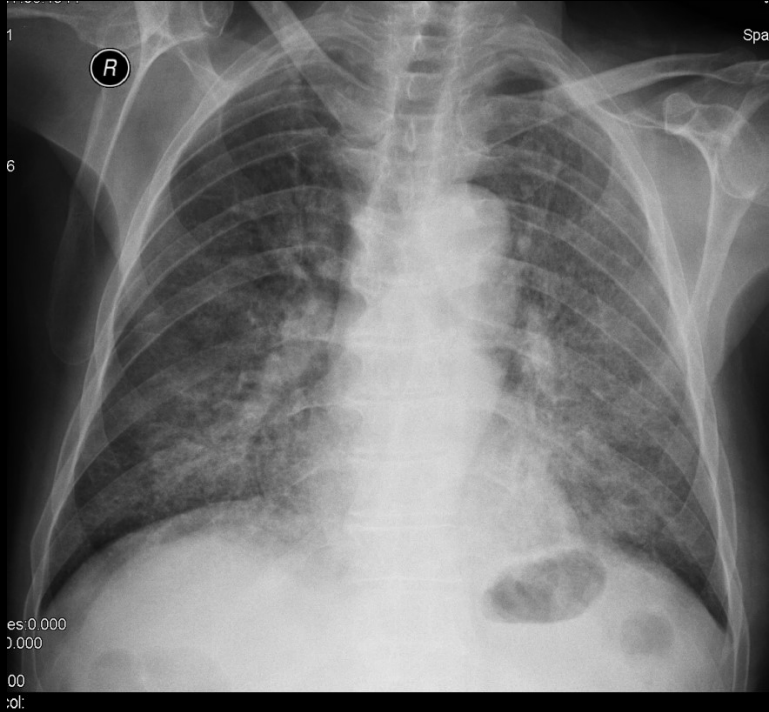
Farklı Paternlerin Kombinasyonu



KALDIRIM TAŞI MANZARASI

- İnterlobüler septa
- İntرالobüler septa
- Buzlu cam





45 yaşında erkek hasta ,
Renal tx öyküsü ve
ateş yükeklği , öksürük

Pneumocystis jiroveci
pnömonisi

aldırım taşı (crazy paving) görünümü pan nedenler

sık nedenler

Pulmoner Ödem

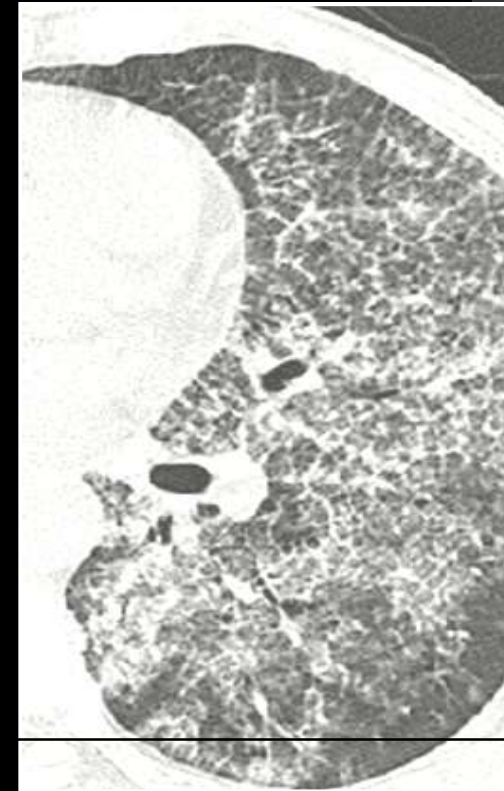
ARDS

İnfeksiyonlar

Akut interstisyel pnömoni

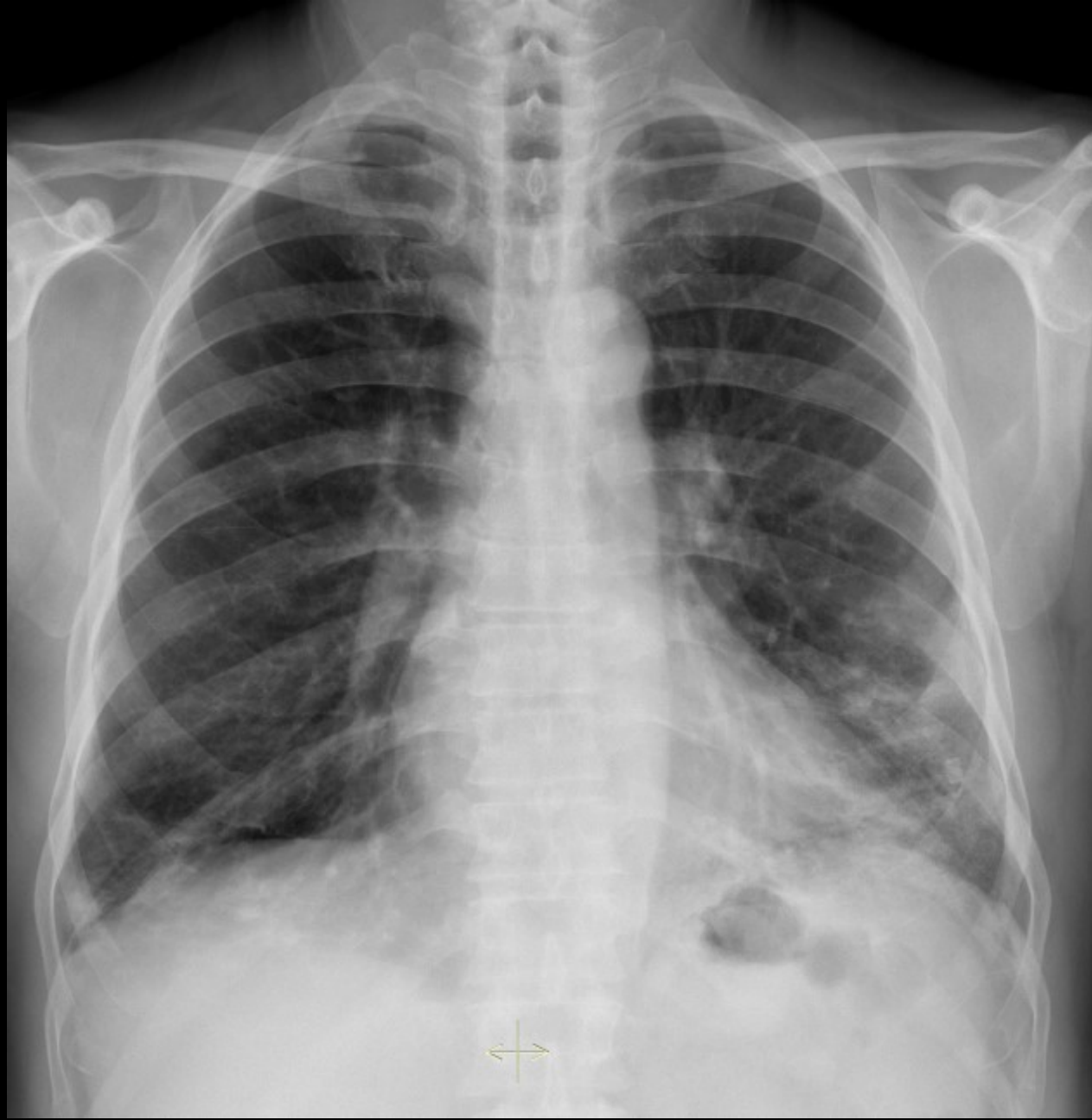Pulmoner alveolar
proteinosis (PAP)

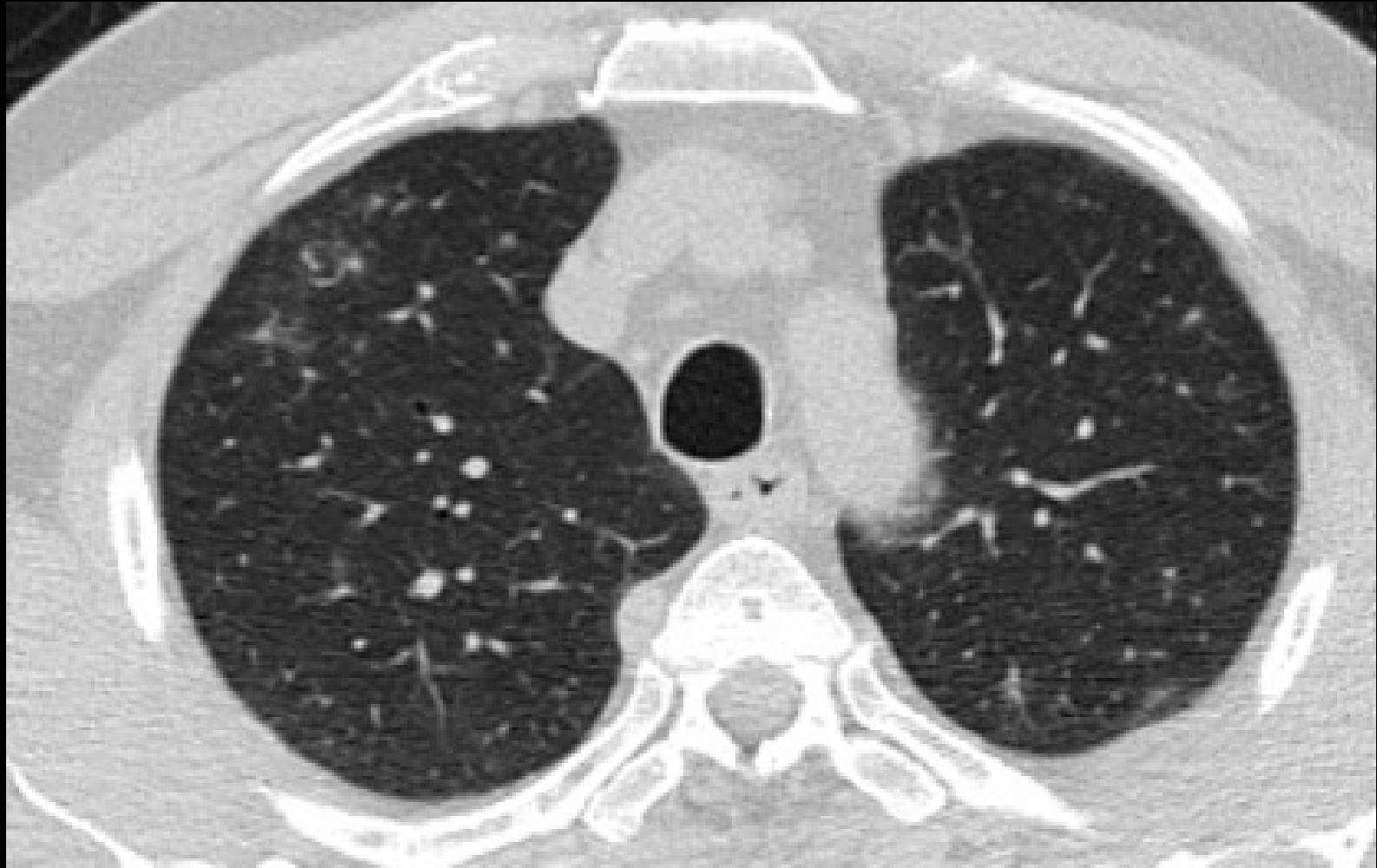
- UIP;DIP
- İlaçla ilişkili pnömoni
- Radyasyon pnömonisi
- Pulmoner hemoraji
- Kronik eozinofilik pnömoni
- Organize pnömoni
- Adenokanser
- Sarkoidozis
- Lipoid pnömonisi

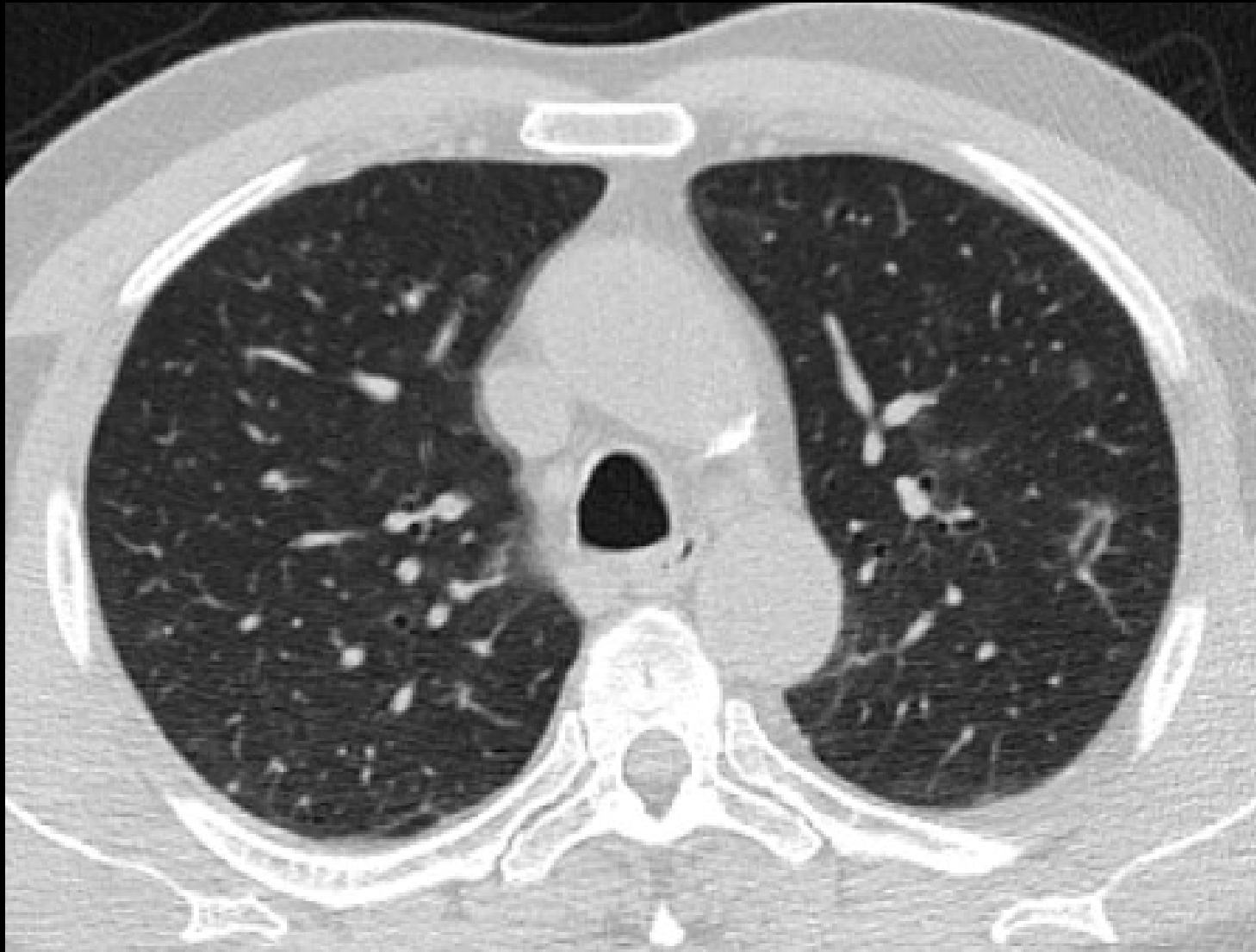


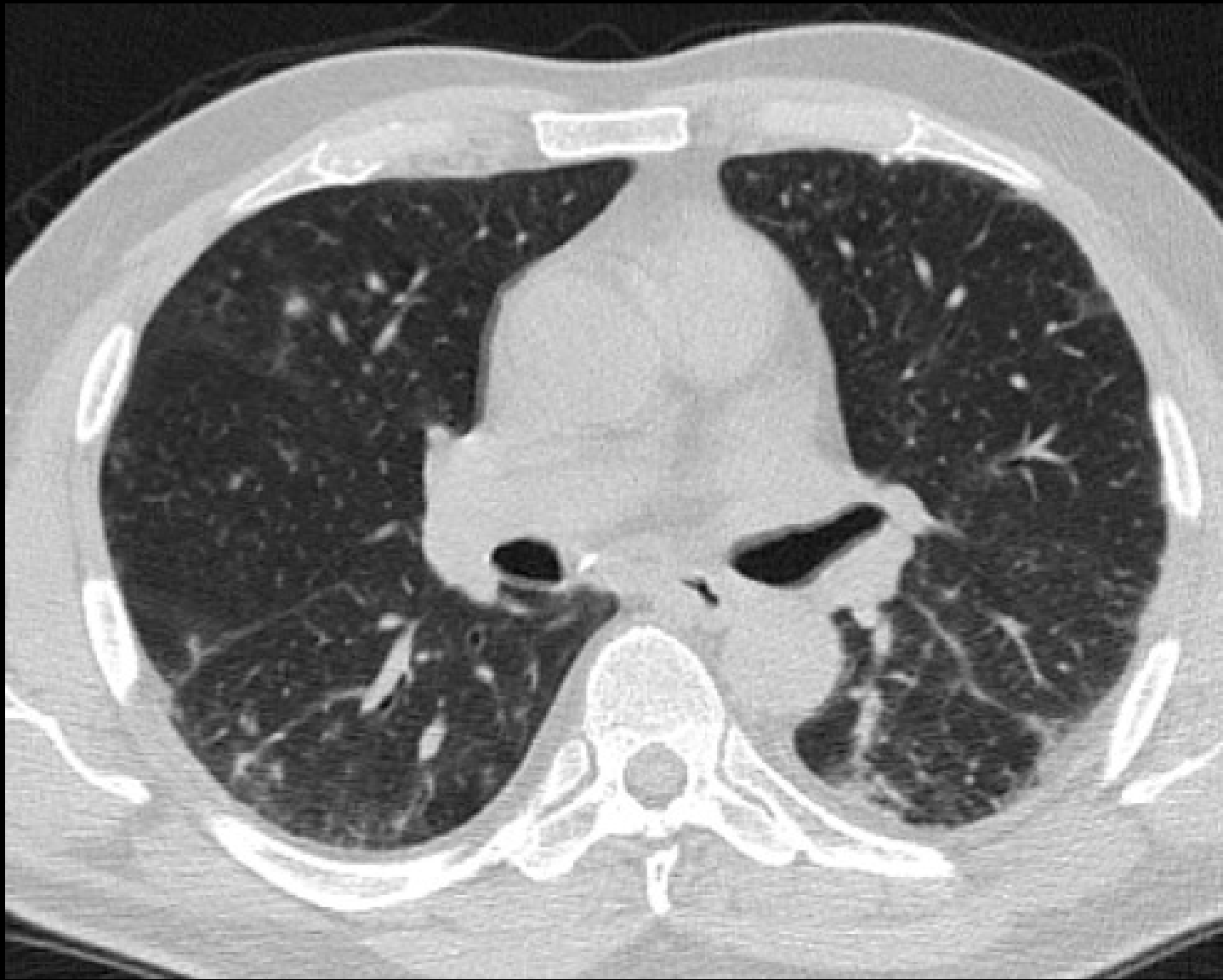
OLGU 3:

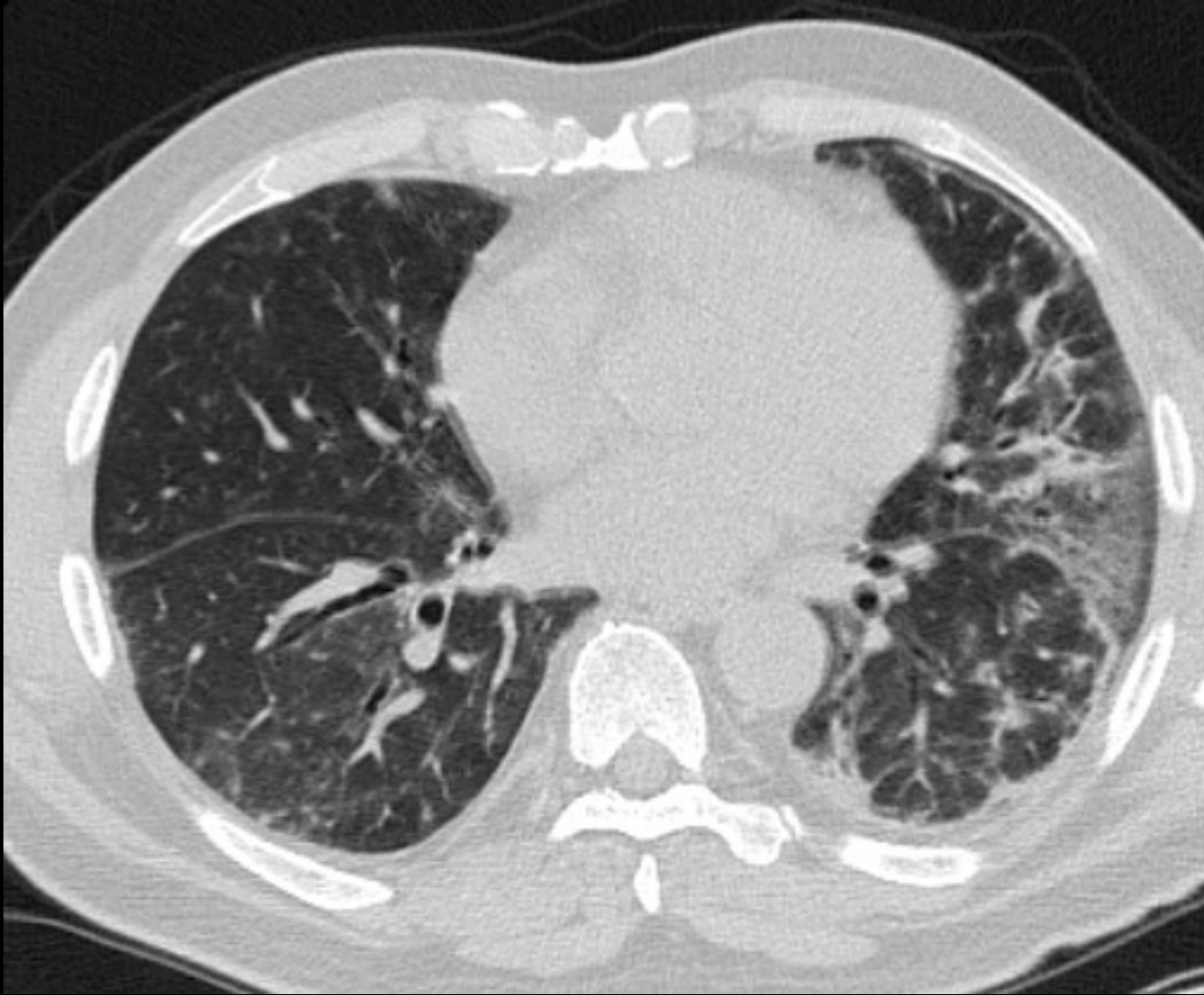. y, erkek
ksürük, balgam,
efes darlığı,
nömoni tedavisi
miş

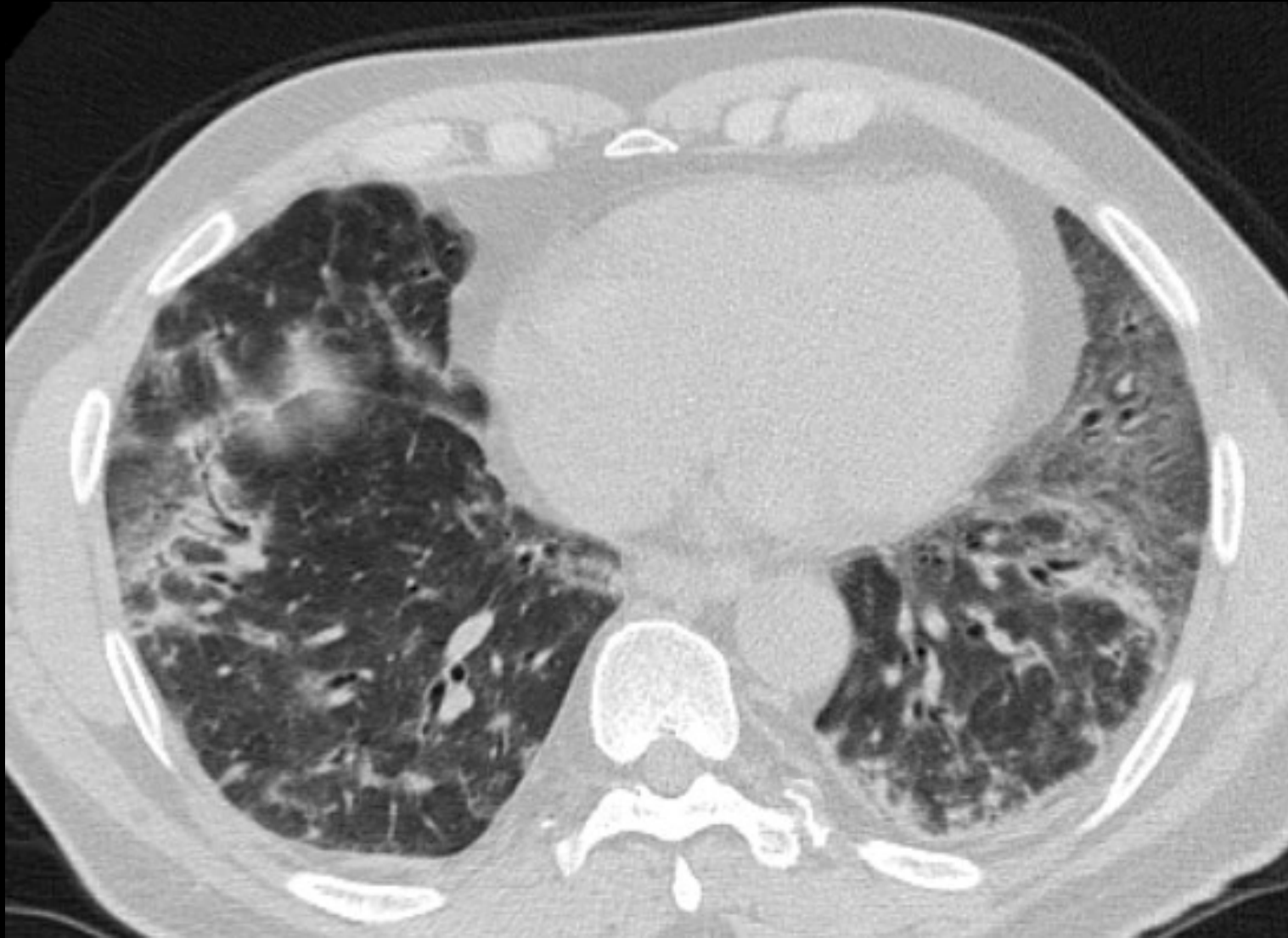


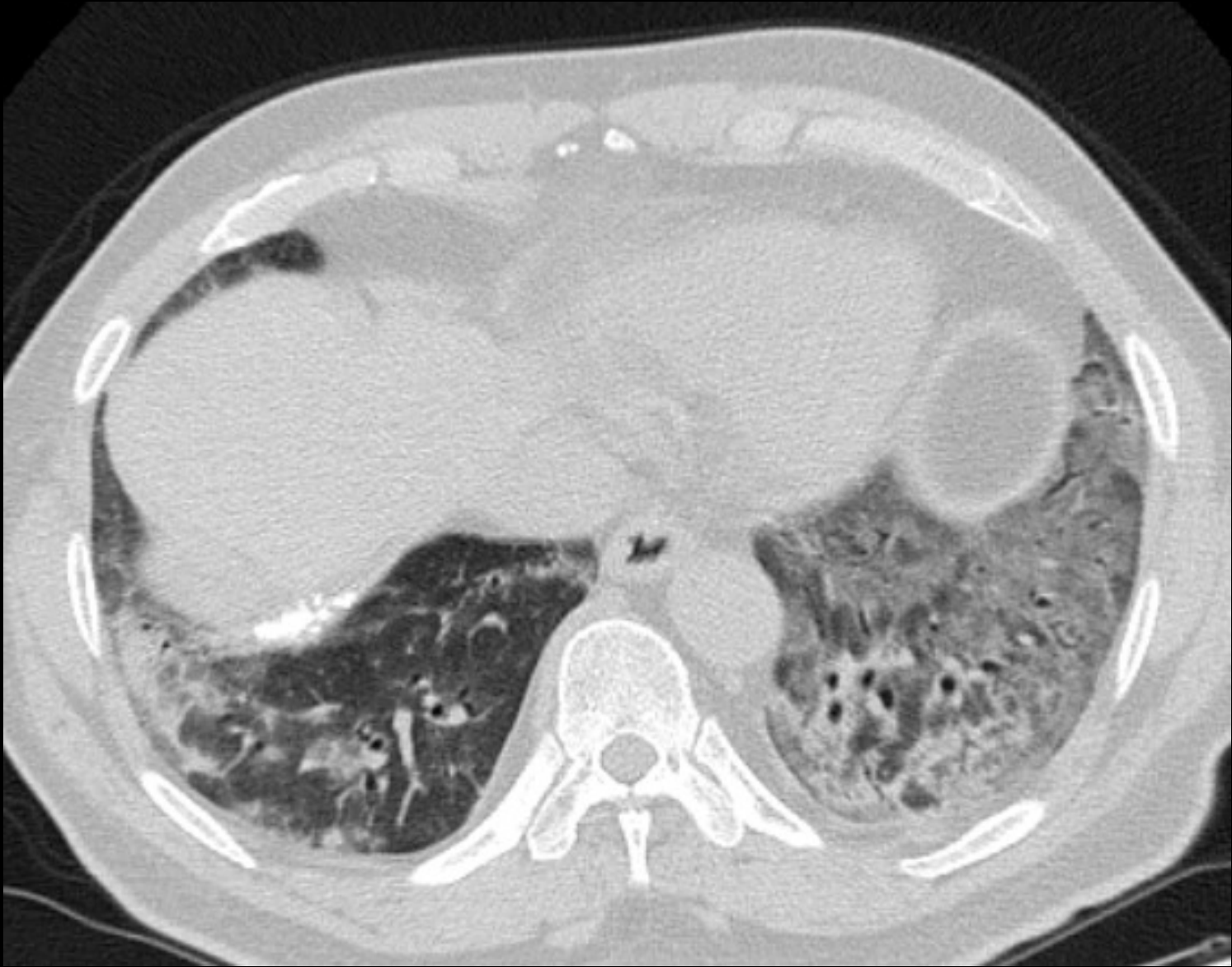


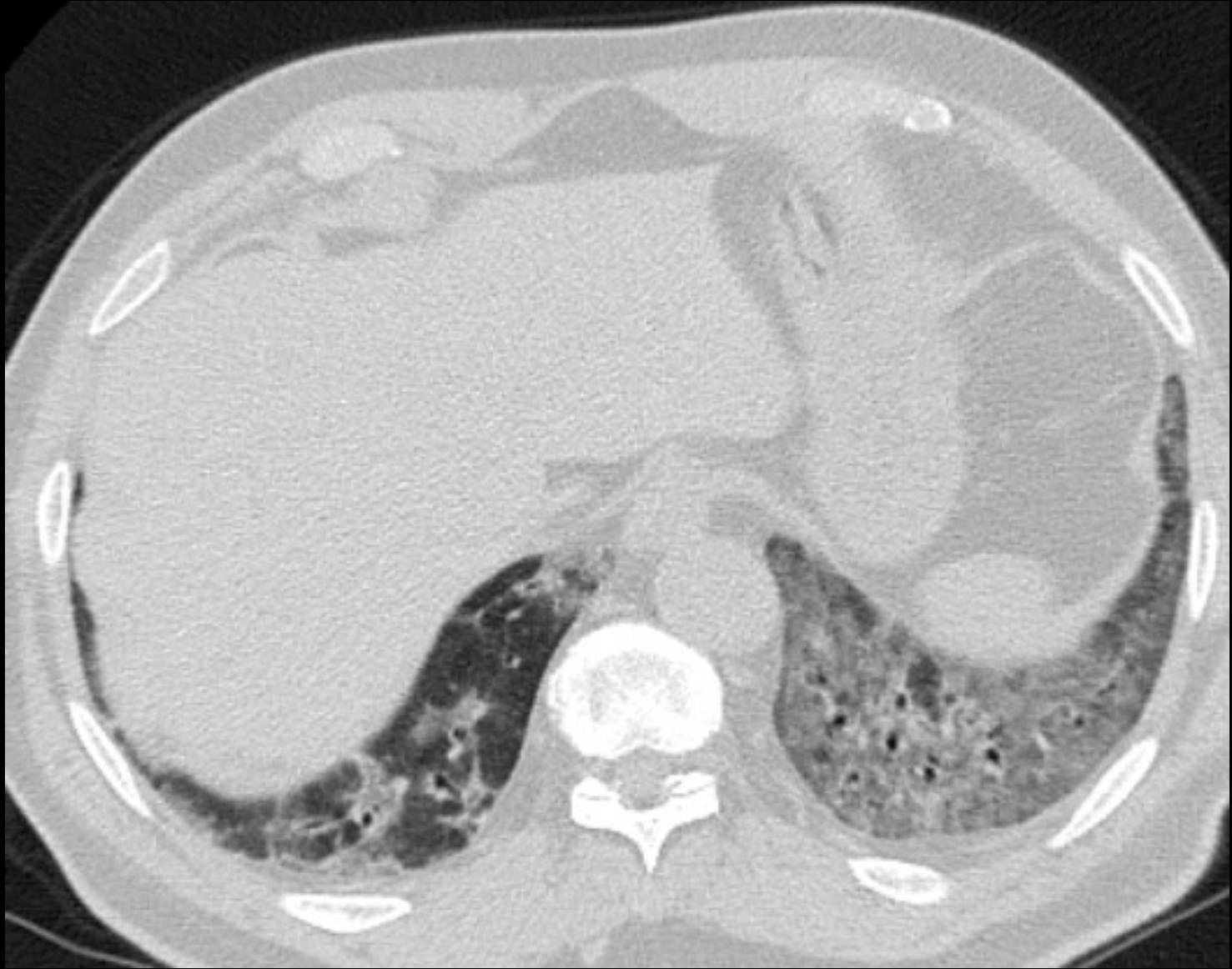


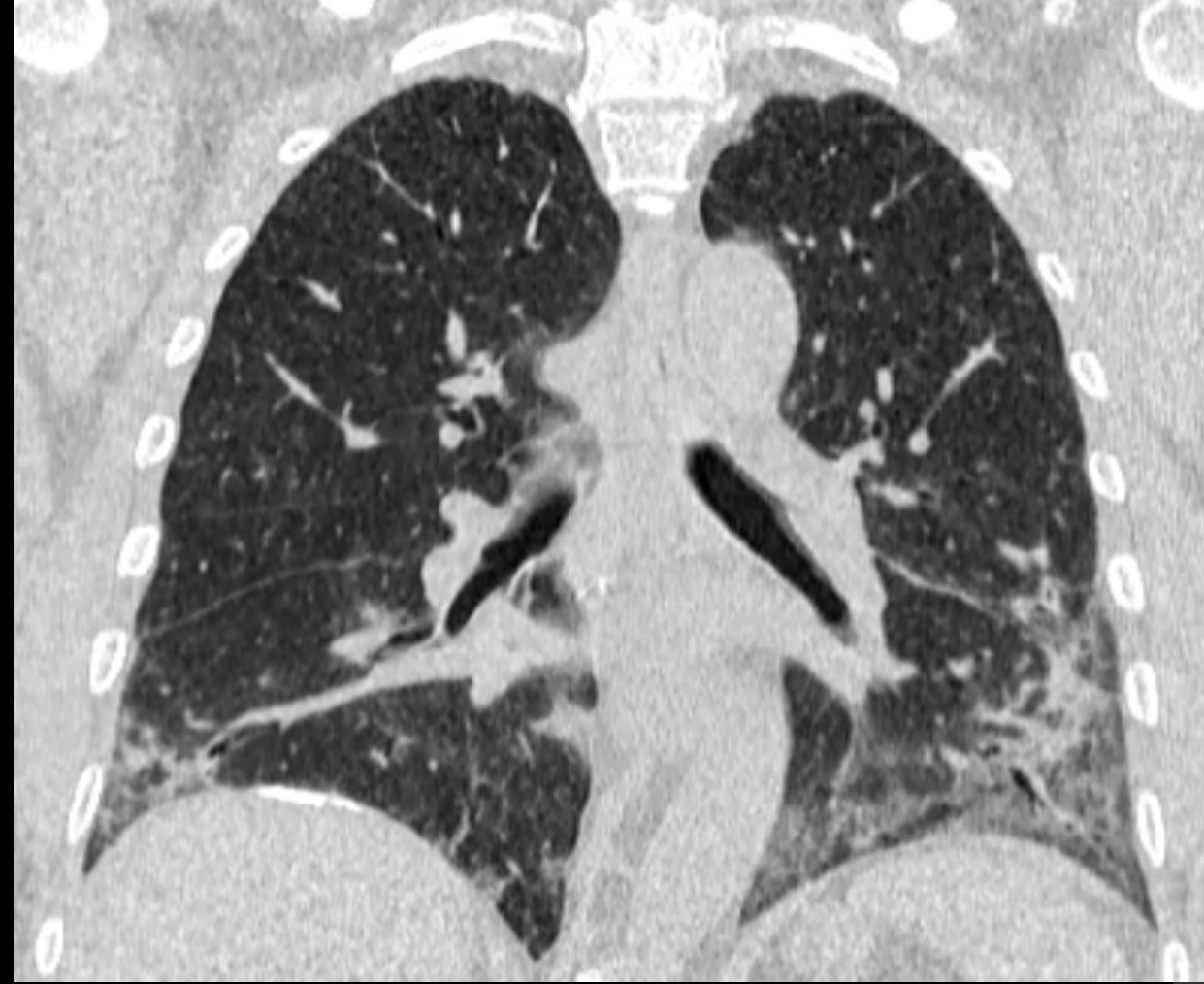
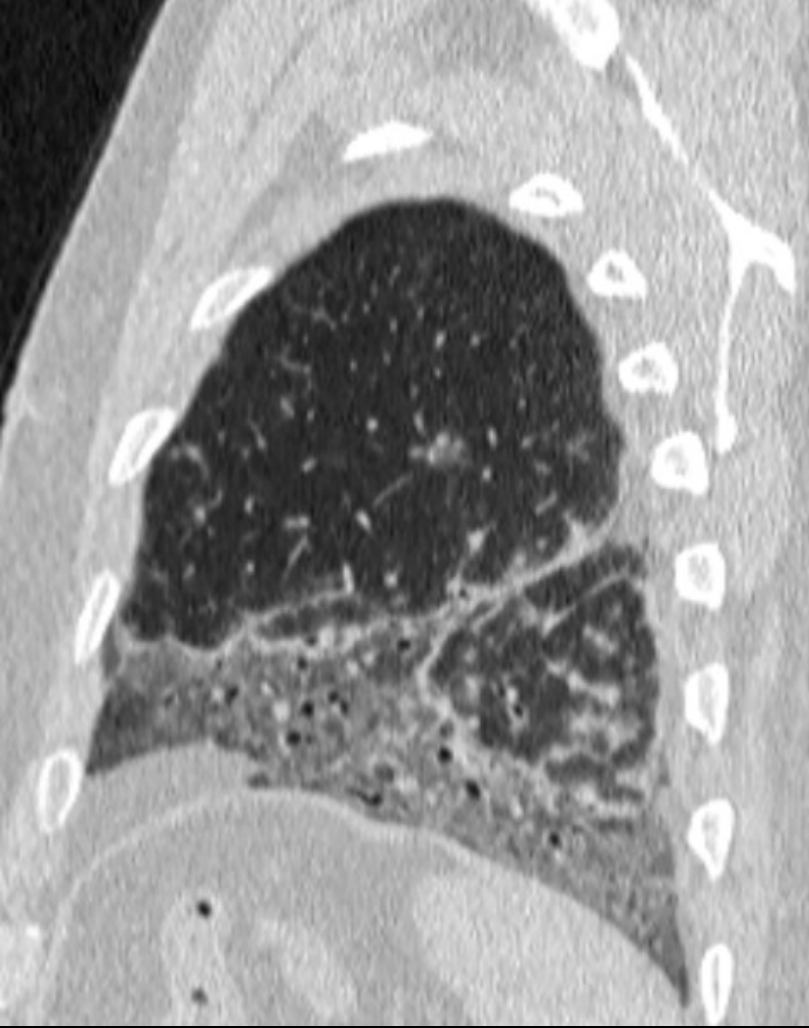









Tanınız Nedir?

NSİP /SELLÜLER TİP

İDİOPATİK İNTERSTİSYEL PNÖMONİLER

Major
İİP

Nadir
İİP

Sınıflandırılama

İdiopatik
pulmoner
fibrozis
(İPF)

Nonspesifik
interstisyel
pnömoni
(NSIP)

Orga
nize
pnöm
oni

Deskuamatif
interstisyel
pnömoni
(DIP)

Respiratuar
bronşiolit-
interstisyel
akciğer
hastalığı

Akut
interstisyel
pnömoni

İDİOPATİK İNTERSTİSYEL PNÖMONİLER

Nadir İİP

Lenfositik
interstisyel
pnömoni

Major
İİP

Plevroparankimal
fibroelastoz

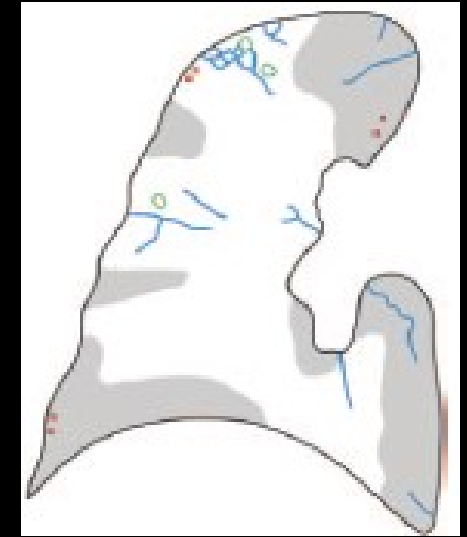
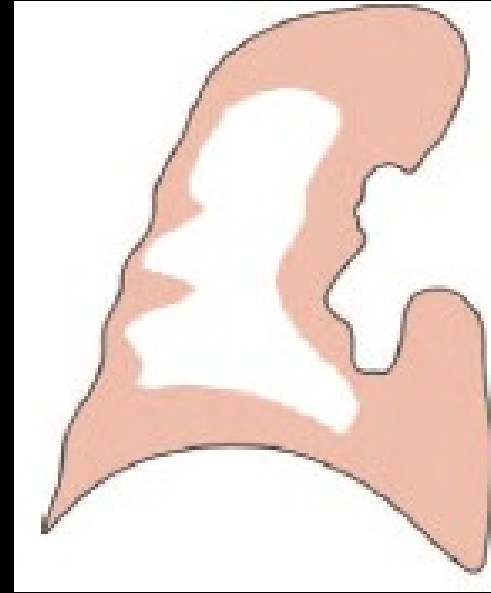
Sınıflandırılmayanlar

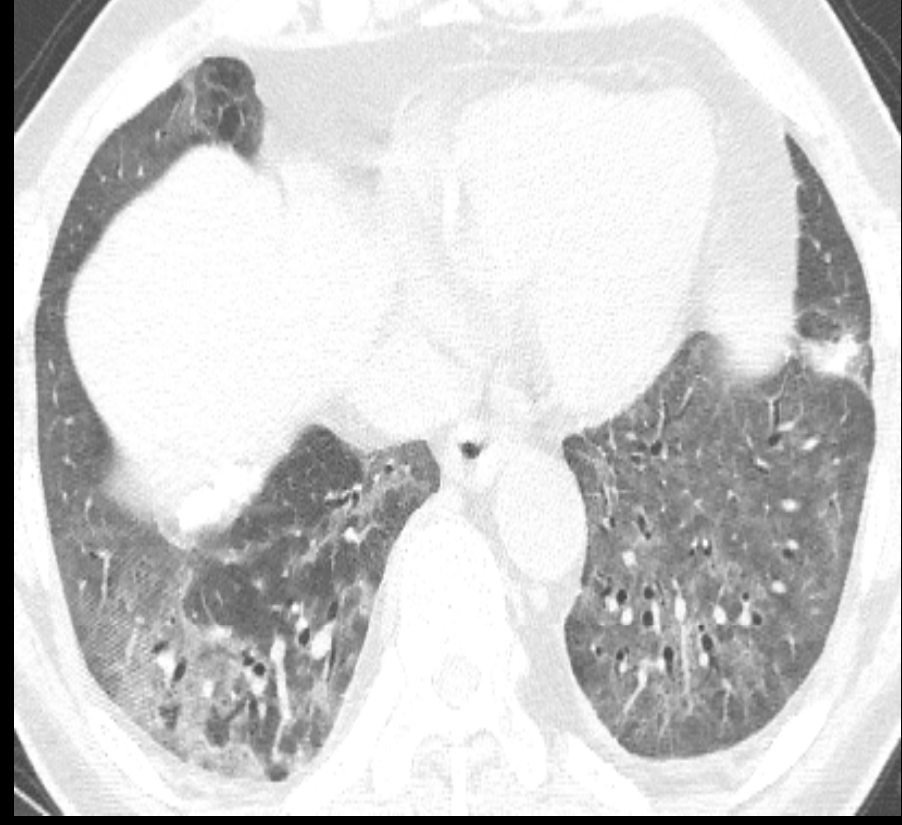
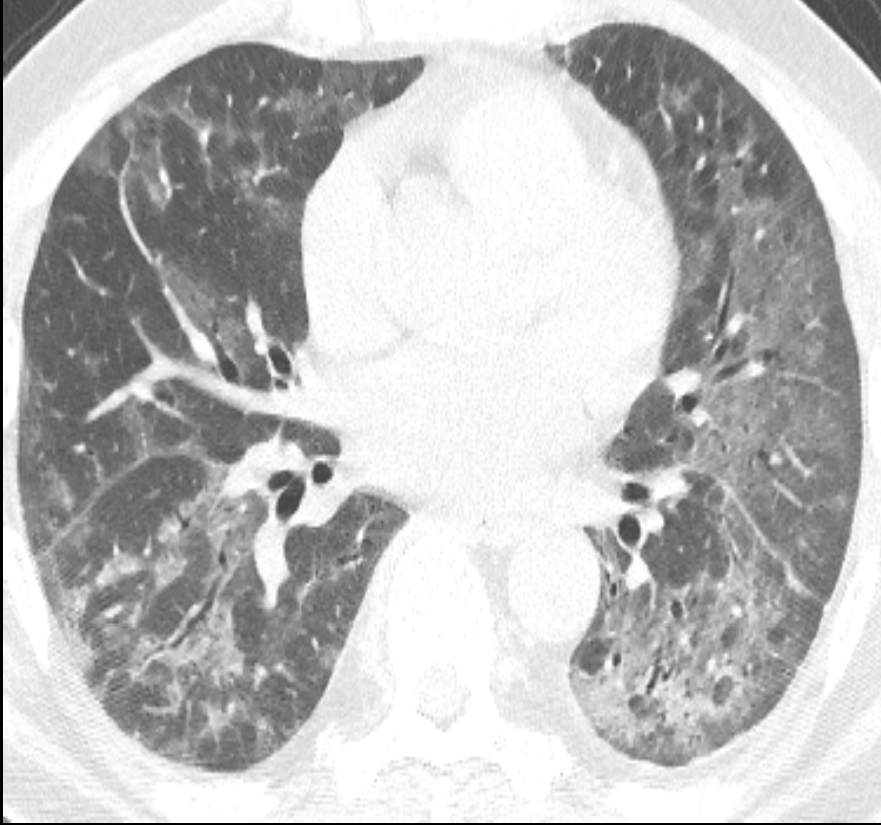
Nonspesifik İntertisyel Pnömoni(NSIP)

➤ İki tip:Selüler/Fibrotik

HRCT paterni

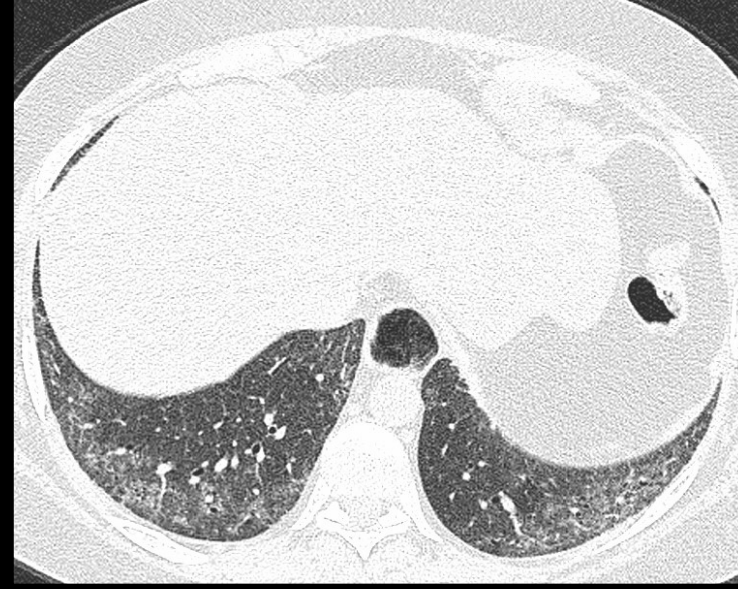
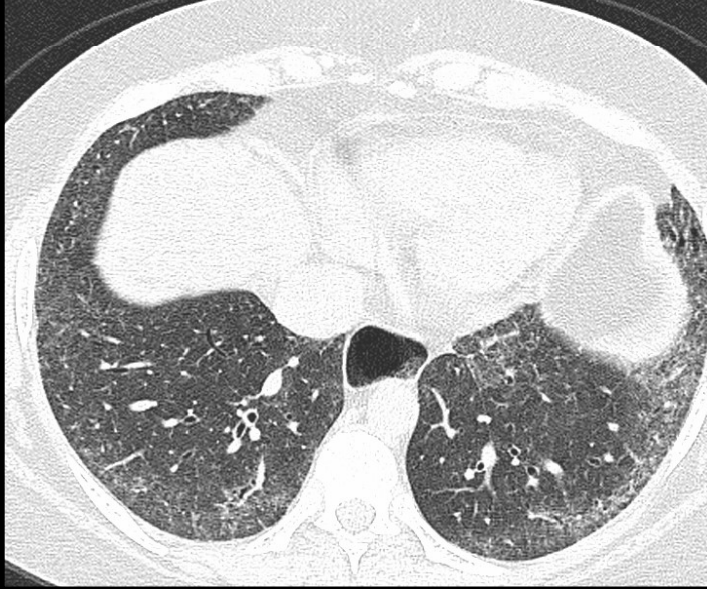
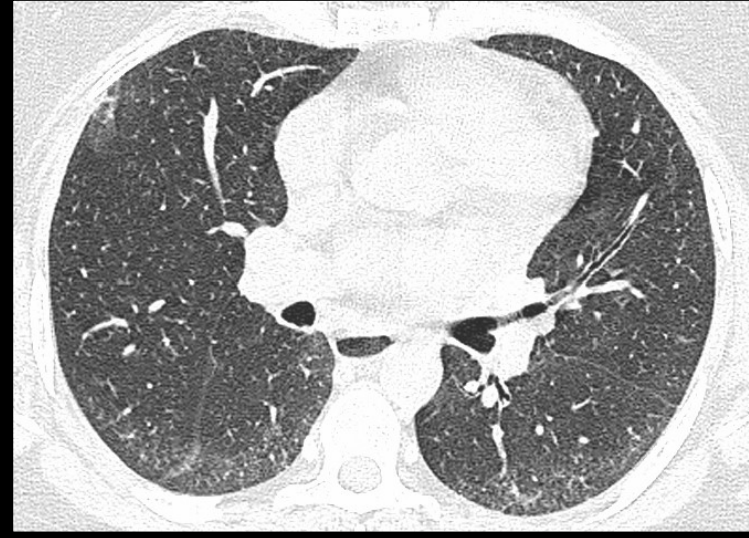
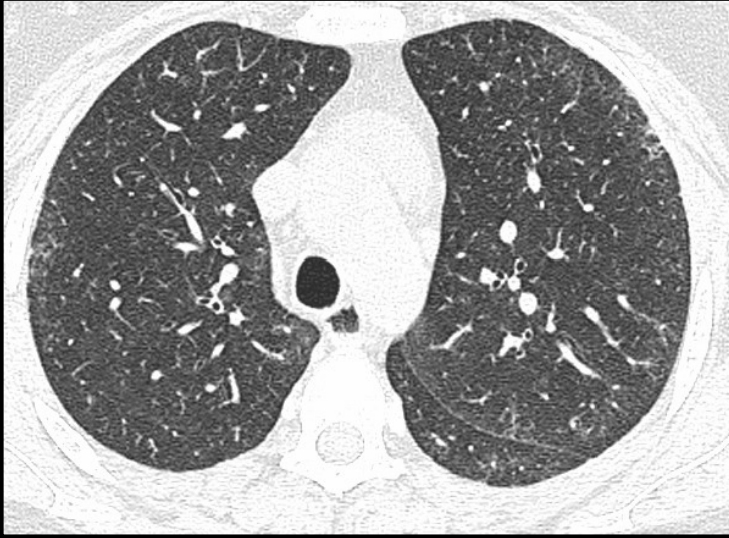
- Bilateral homojen , **buzlu cam alanları**
- Retikülasyonlar
- Traksiyon bronşektazileri ve Bronşiolektazileri
- Mikronodülarite
- Subplevral alanın korunması
- **Balpeteği az ya da yok**



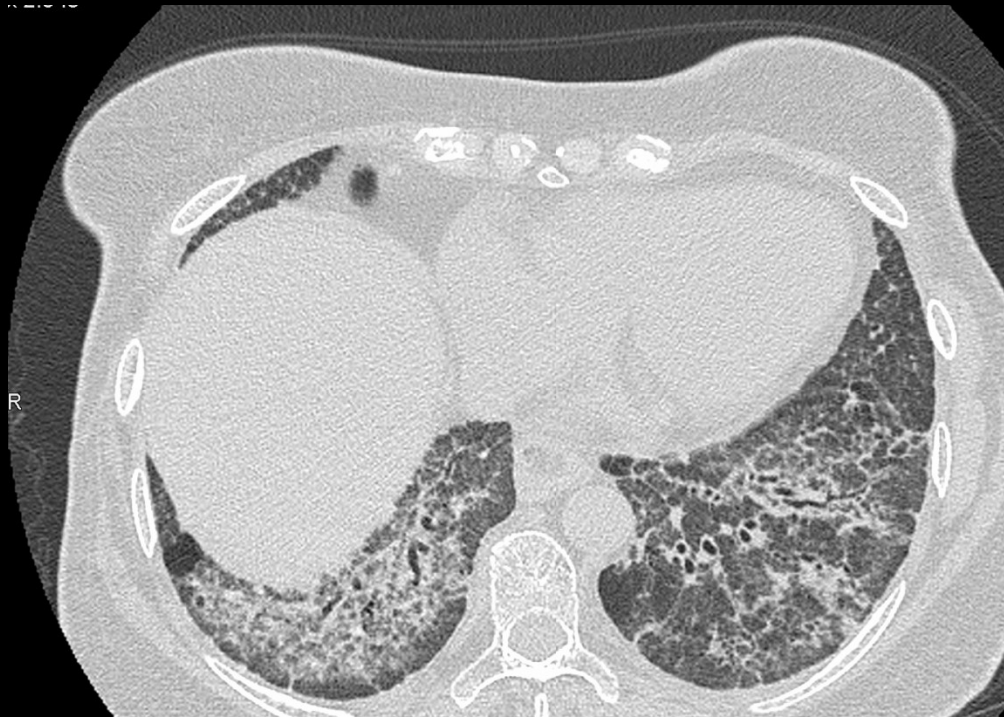
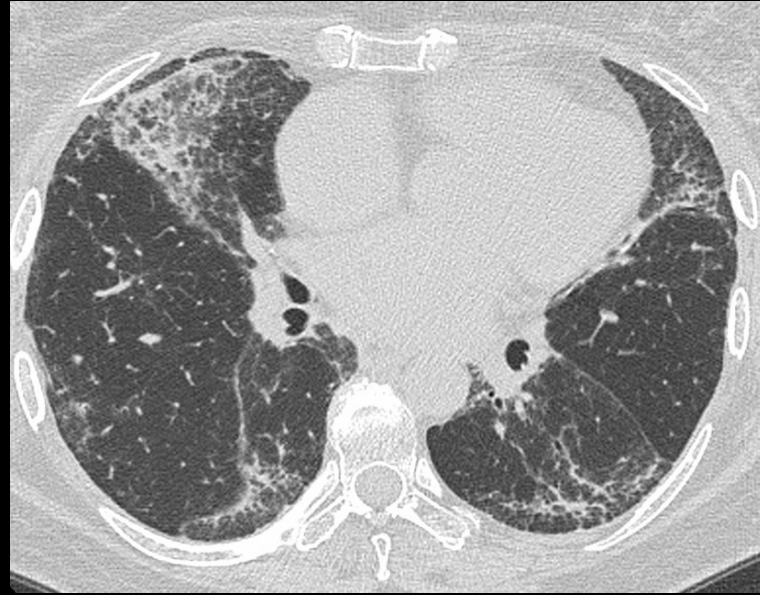
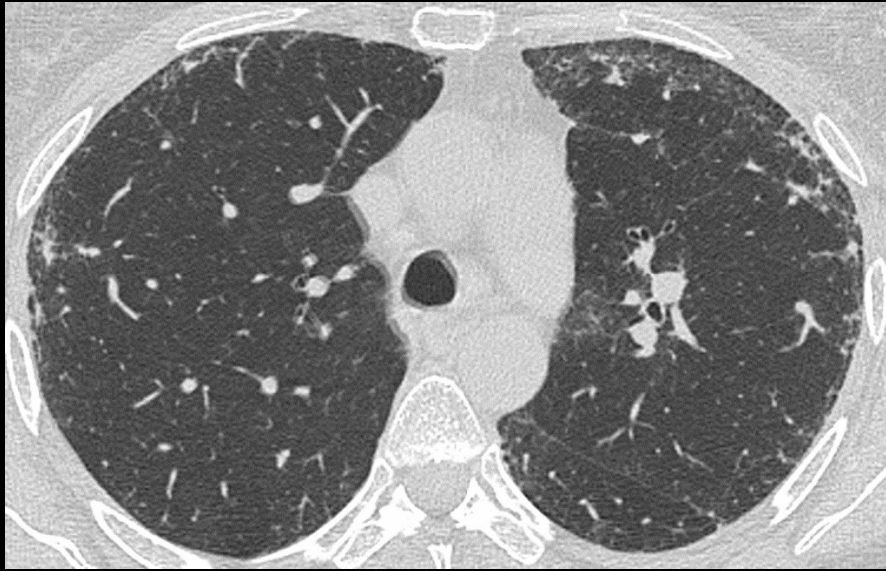


NSIP (sellüler form)

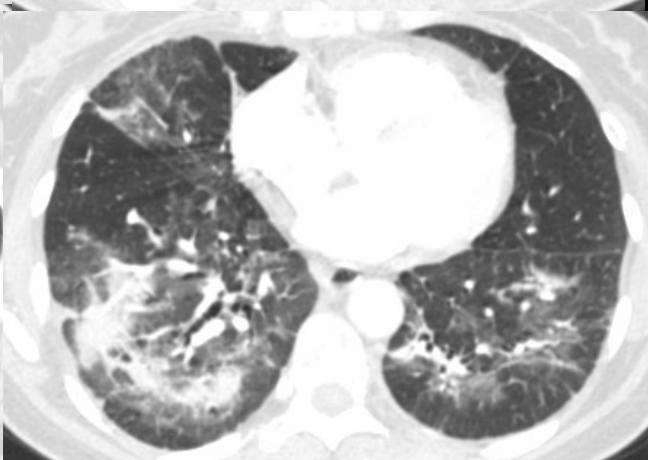
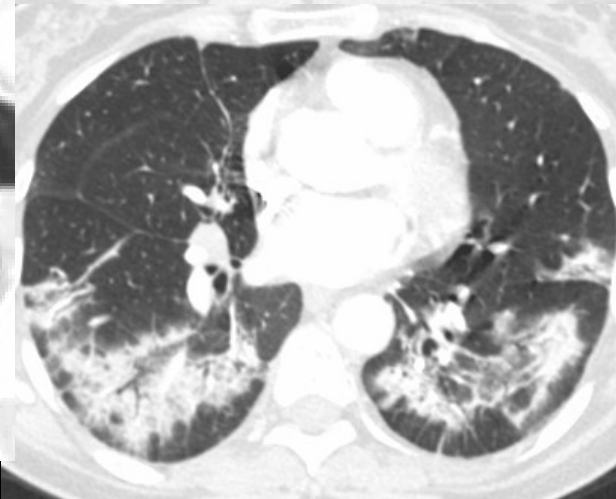
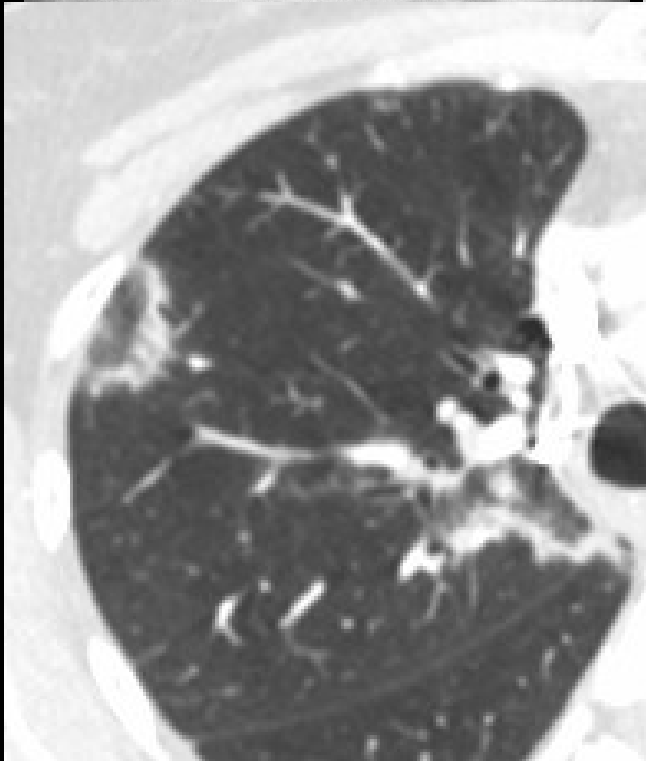
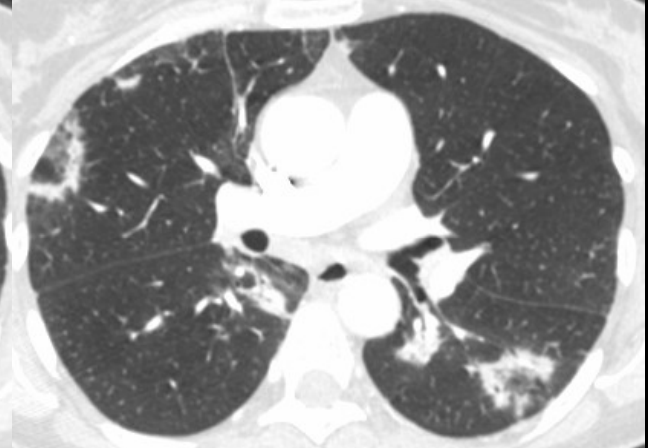
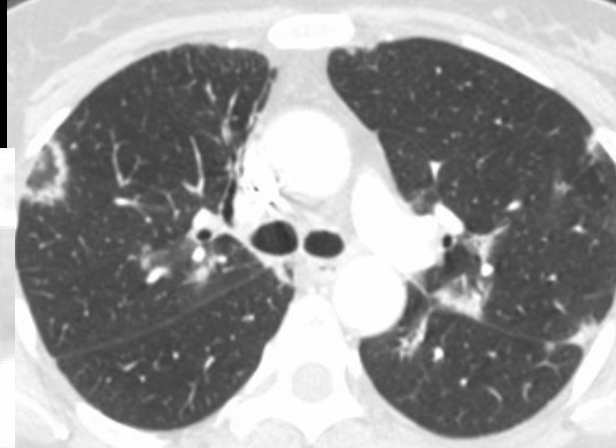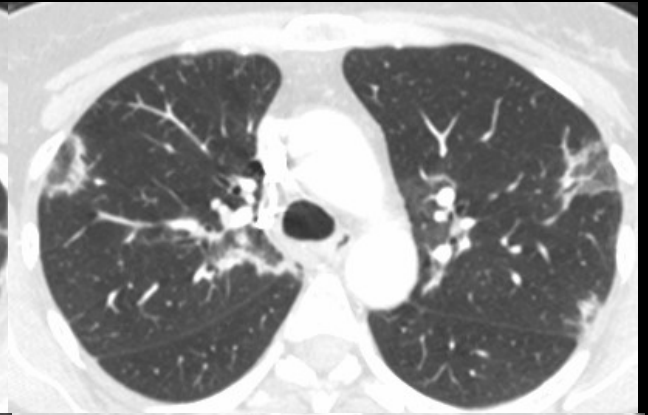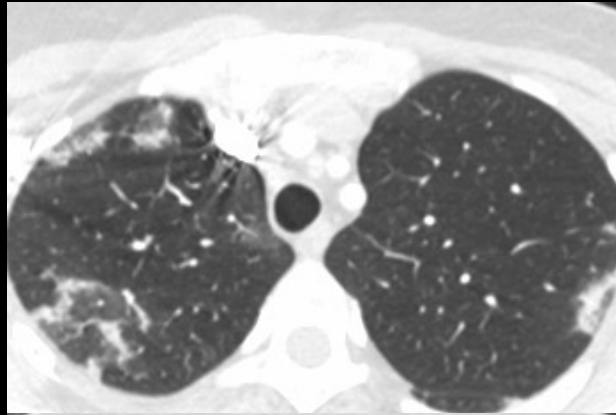
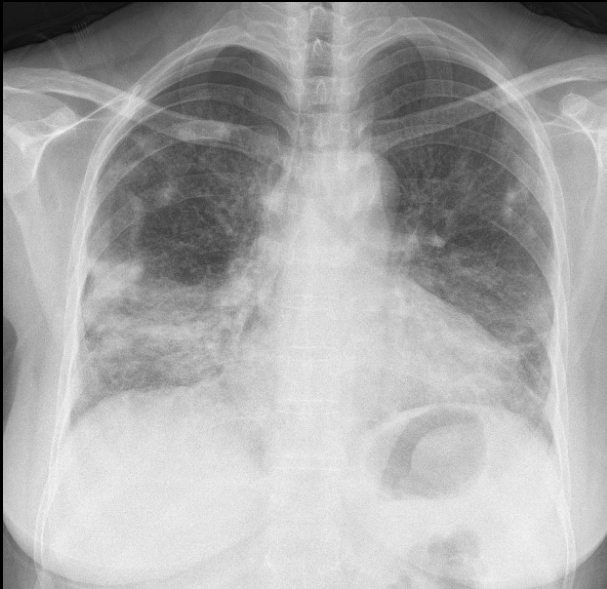
NSIP yaygın peribronkovasküler dağılıma uyan buzlu cam alanları ile karakterizedir

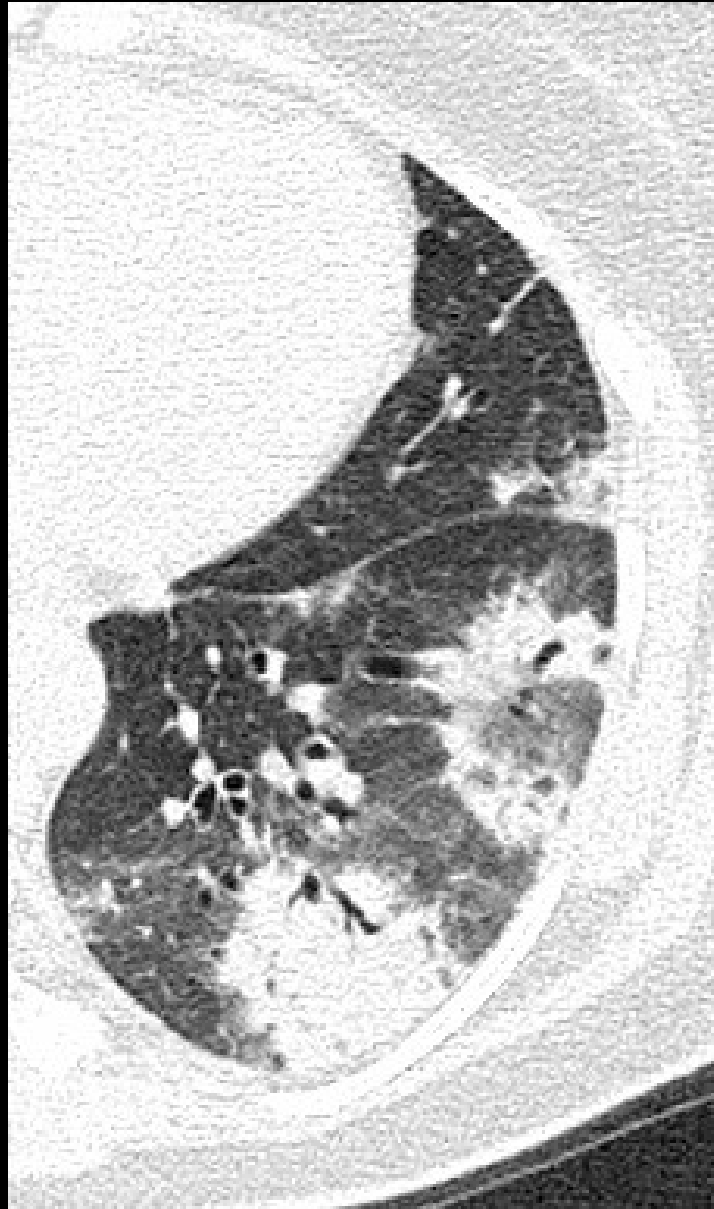
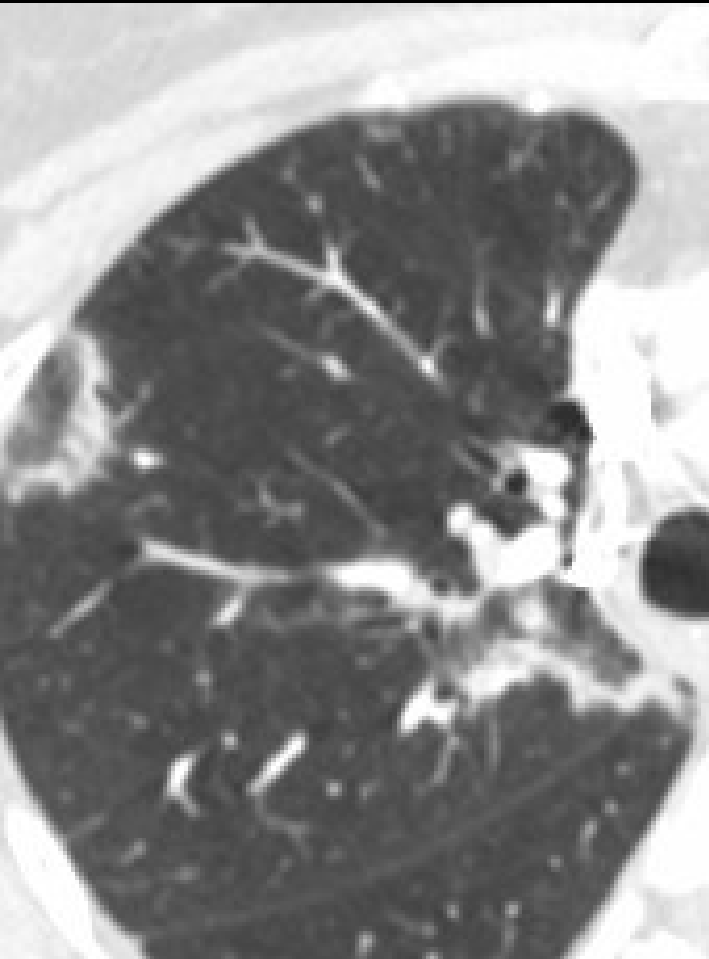


Skleroderma ve Nonspesifik İntertisyel Pnömoni (NSIP)



48 y, Kadın





Ters Halo
işareti/
Atol işareti

Bağ doku hastalıkları ile ilişkili intertisyel akciğer hastalıkları

Frequency of Pulmonary Manifestations of Collagen Vascular Diseases

Type of Collagen Vascular Disease	UIP	NSIP	COP	LIP	DAD	Hemorrhage	Airway Disease
Rheumatoid arthritis	+++	++	++	+	+	-	+++
Progressive systemic sclerosis	+	+++	+	-	+	-	-
Dermatomyositis/polymyositis	+	+++	+++	-	++	-	-
Sjögren syndrome	+	++	-	++	+	-	+
Mixed connective tissue disease	+	++	+	-	-	-	-
Systemic lupus erythematosus	+	++	+	+	++	+++	-

Note.—Symbols in columns indicate the frequency with which a feature or pattern of features occurs, with “+” indicating the lowest and “+++” the highest frequency, and with “-” indicating absence of the feature or pattern. COP = cryptogenic organizing pneumonia, DAD = diffuse alveolar damage.

** En sık patern NSIP (RA hariç)

RadioGraphics 2012; 32:33-50

Histolojik Patern	Klinikopatolojik Tanı	Hastalığın İkincil Sebepleri
Olağan İntertisyel Pnömoni (Usual Intertisial Pneumonia)	İdiopatik Pulmoner Fibrozis	Asbestozis, Kollajen Doku Hastalıkları, Kronik Hipersensitivite Pnömonisi, İlaç Reaksiyonu, Sarkoidoz
Nonspesifik İntertisyel Pnömoni	Nonspesifik İntertisyel Pnömoni	Kollajen Doku Hastalıkları, Hipersensitivite Pnömonisi, İlaç reaksiyonu, Enfeksiyon

Özellikler	UIP	NSIP
Yaş	60-65 y	40-50 y
Şlangıç	sinsi, yavaş seyirli	Subakut, sinsi
Mortalite	%68	%11
BT	Periferal, subplevral, bazal Retiküler değişiklikler, balpeteği, TBE	Periferik, subplevral, bazal Buzlu cam, konsolidasyon
Histoloji	Yamalı, subplevral, paraseptal , yoğun fibrozis, balpeteği, fibroblastik odaklar, heterojen	Homojen Uniform intertisyel fibrozis, Hafif-orta intertisyel inflamasyon

AMERICAN THORACIC SOCIETY DOCUMENTS

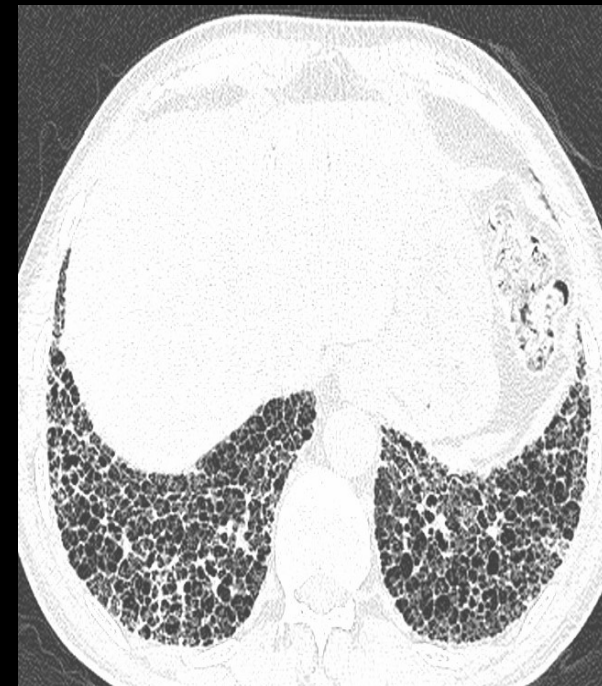
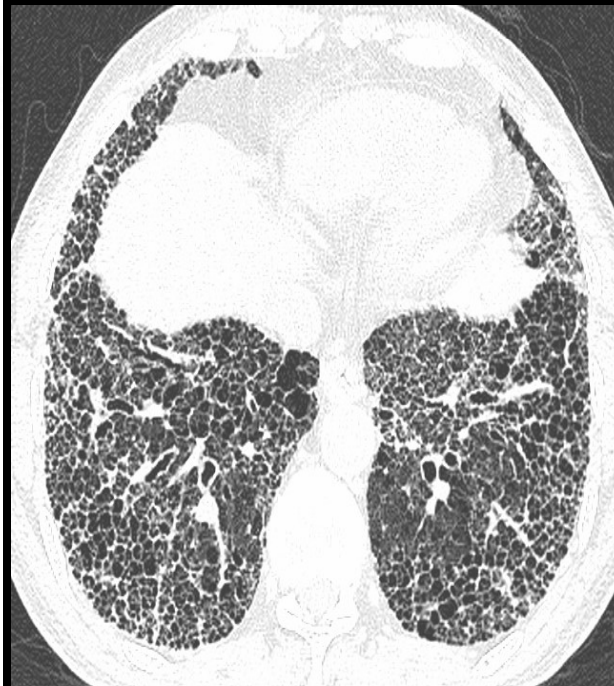
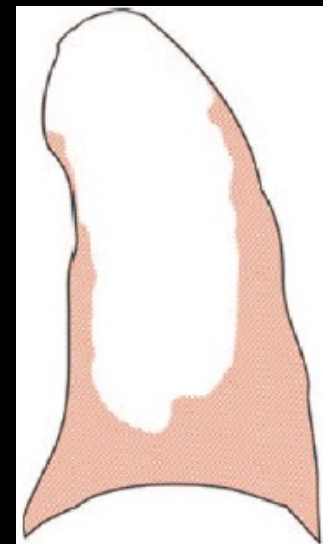
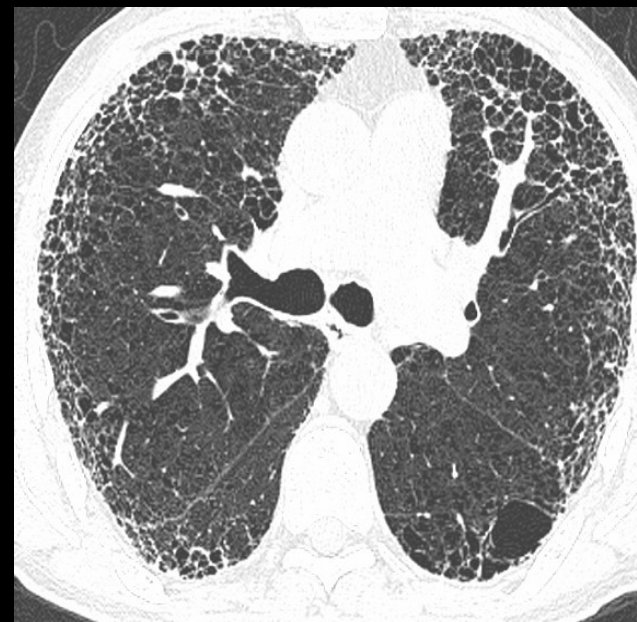
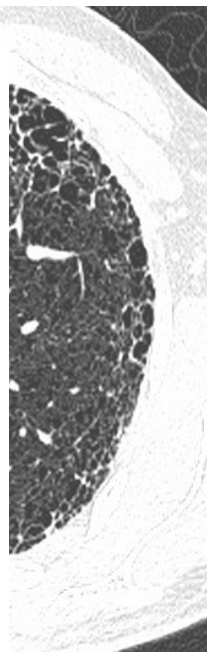
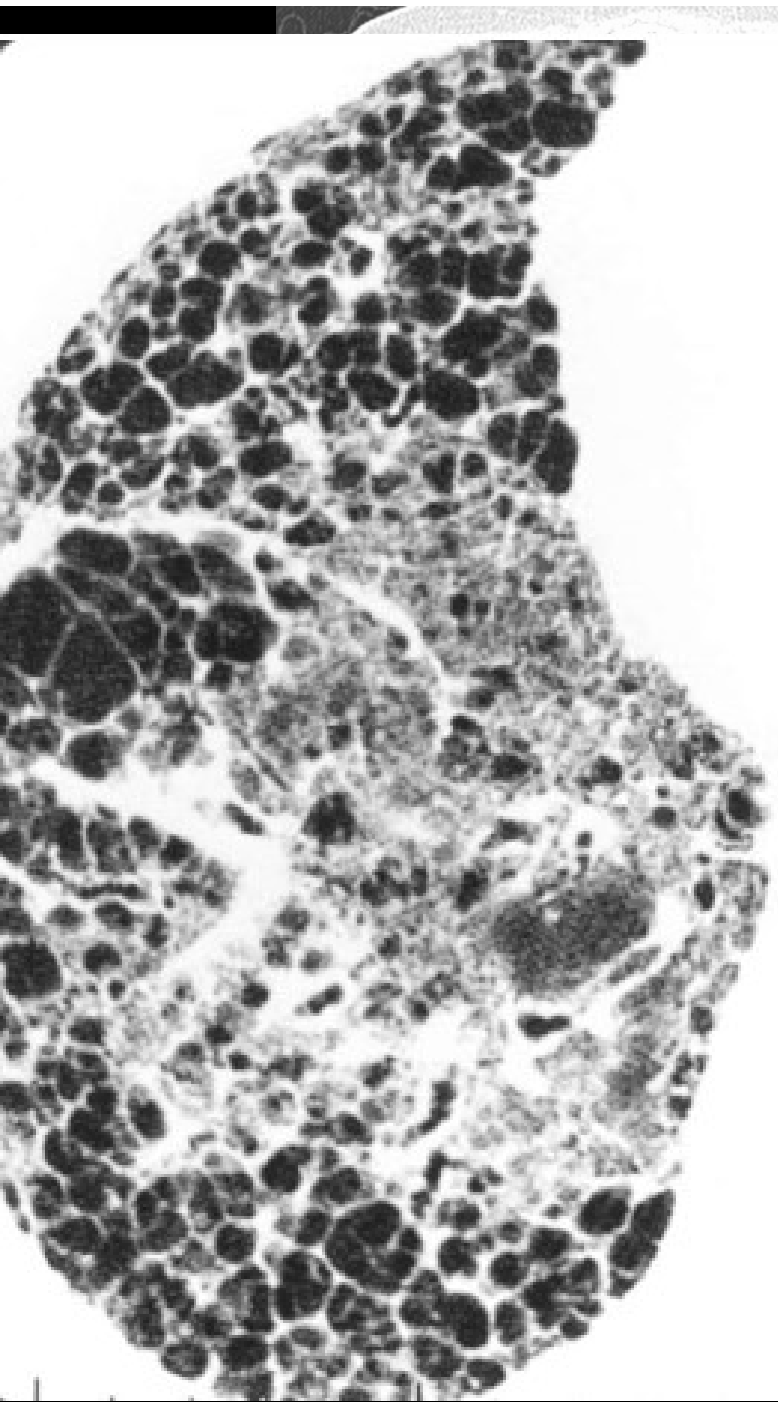
Diagnosis of Idiopathic Pulmonary Fibrosis

An Official ATS/ERS/JRS/ALAT Clinical Practice Guideline

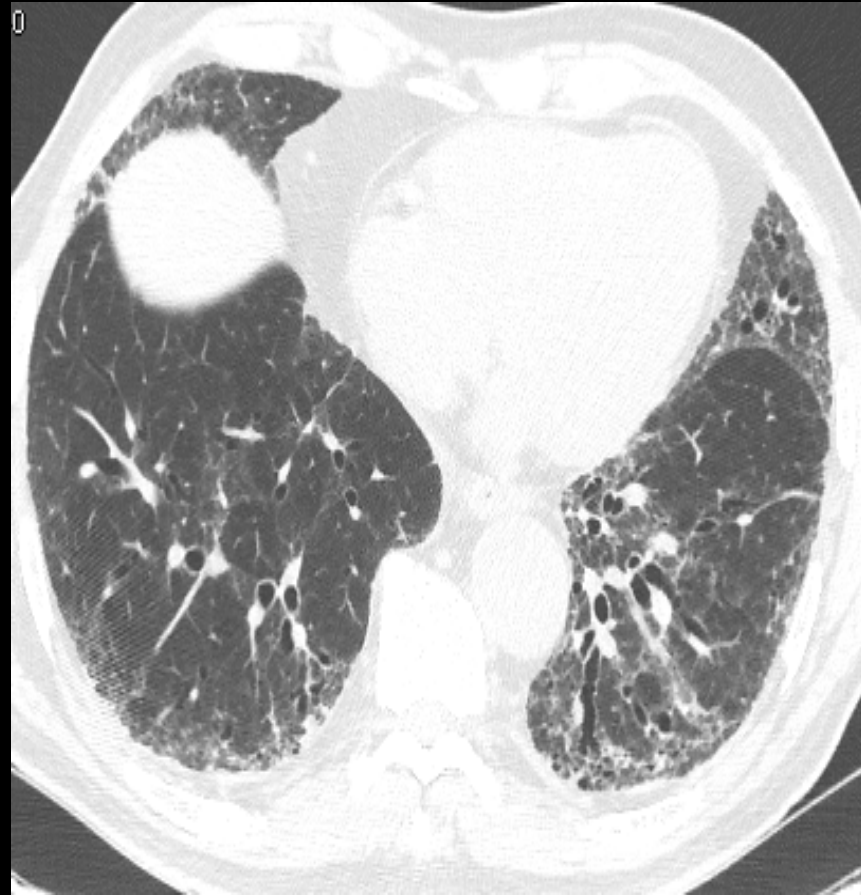
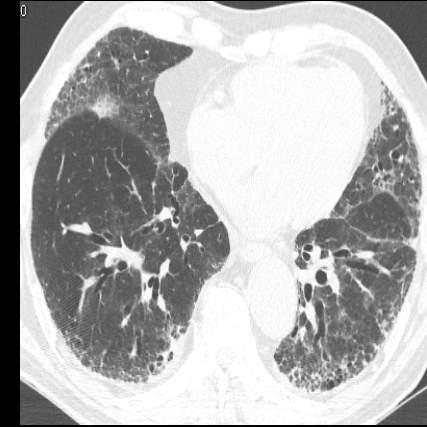
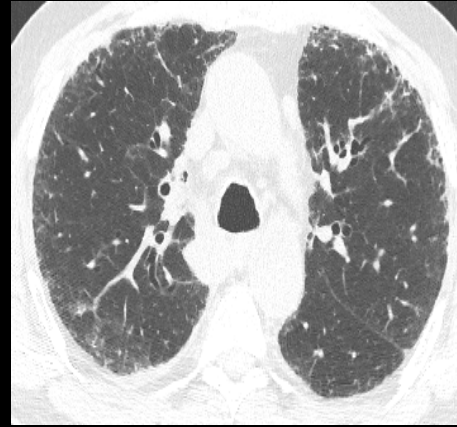
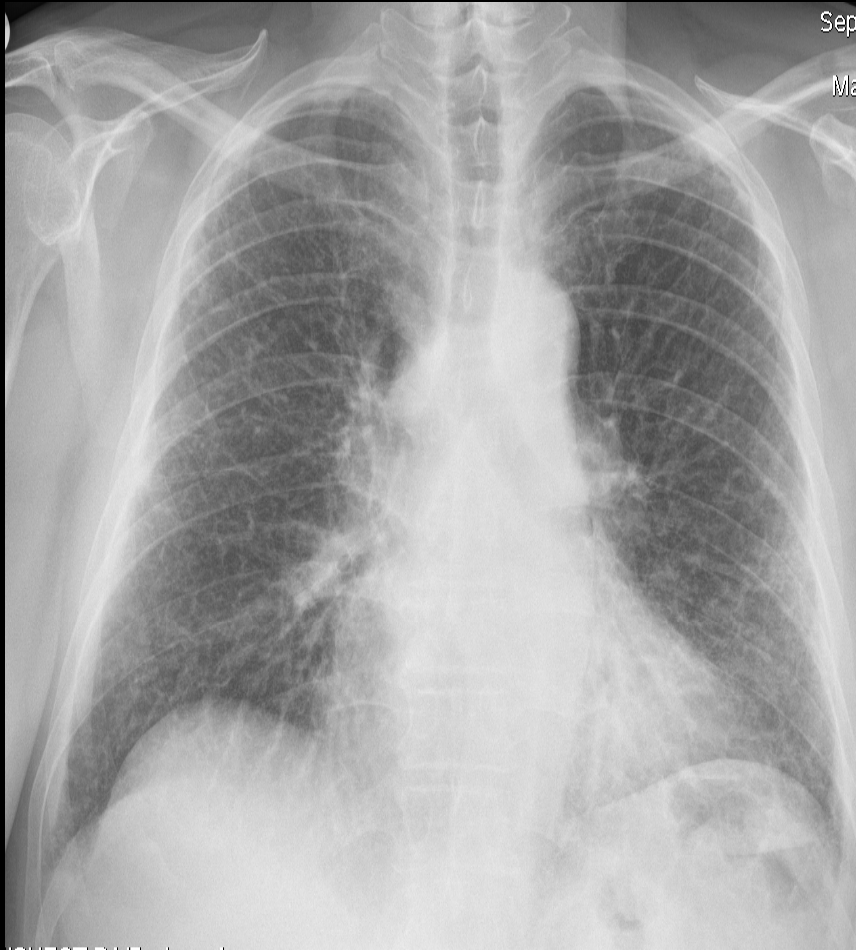Ganesh Raghu, Martine Remy-Jardin, Jeffrey L. Myers, Luca Richeldi, Christopher J. Ryerson, David J. Lederer, Juergen Behr, Vincent Cottin, Sonye K. Danoff, Ferran Morell, Kevin R. Flaherty, Athol Wells, Fernando J. Martinez, Arata Azuma, Thomas J. Bice, Demosthenes Bouros, Kevin K. Brown, Harold R. Collard, Abhijit Duggal, Liam Galvin, Yoshikazu Inoue, R. Gisli Jenkins, Takeshi Johkoh, Ella A. Kazerooni, Masanori Kitaichi, Shandra L. Knight, George Mansour, Andrew G. Nicholson, Sudhakar N. J. Pipavath, Ivette Buendía-Roldán, Moisés Selman, William D. Travis, Simon Walsh, and Kevin C. Wilson; on behalf of the American Thoracic Society, European Respiratory Society, Japanese Respiratory Society, and Latin American Thoracic Society

Table 4. High-Resolution Computed Tomography Scanning Patterns

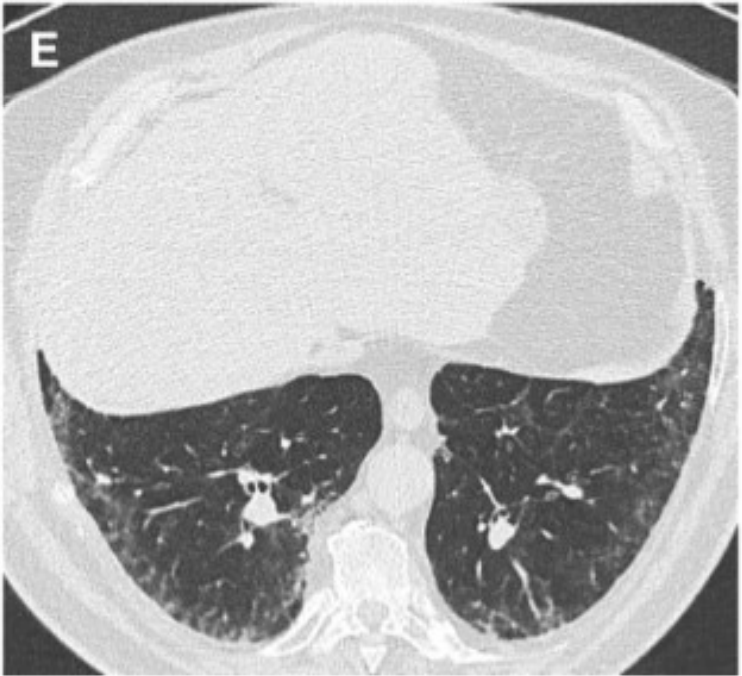
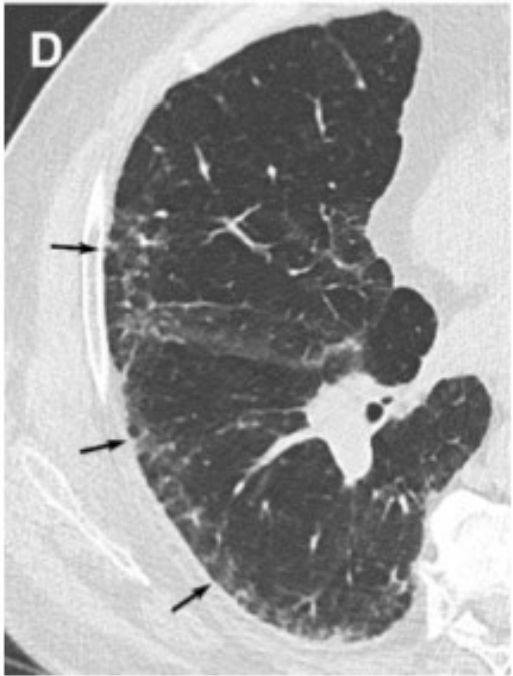
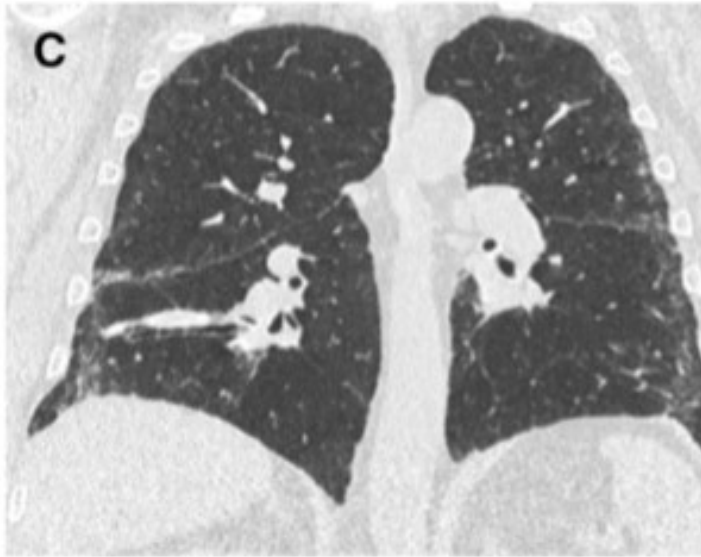
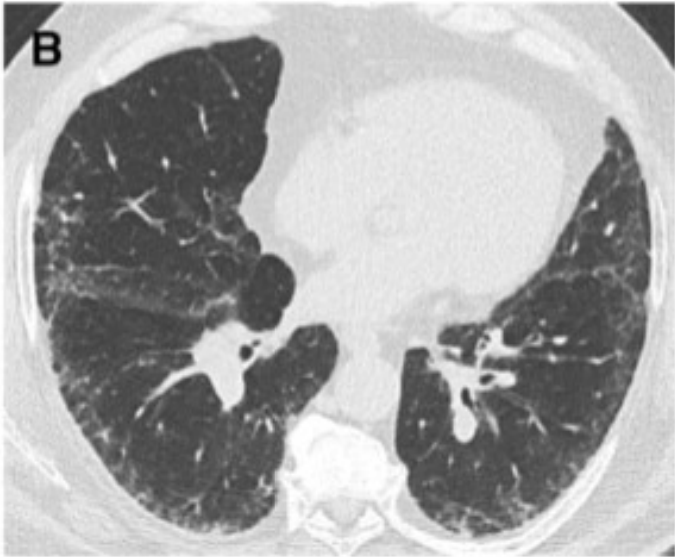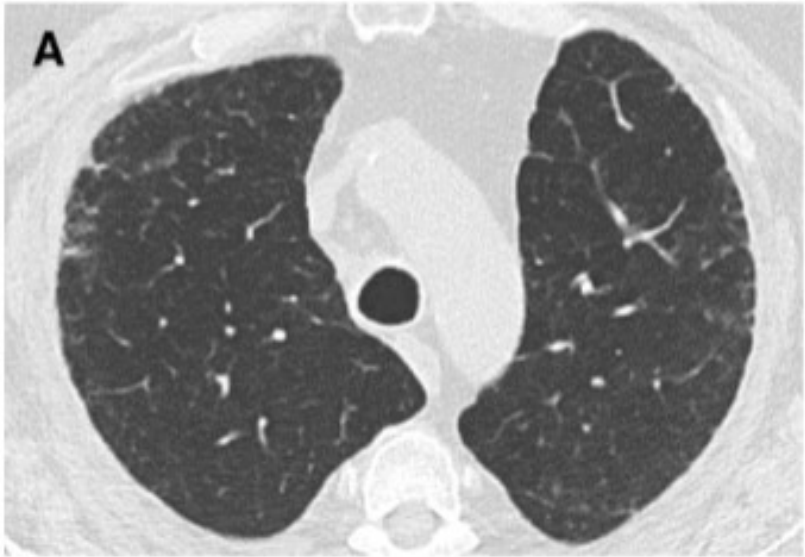
UIP	Probable UIP	Indeterminate for UIP	Alternative Diagnosis
<p>Subpleural and basal predominant; distribution is often heterogeneous*</p> <p>Honeycombing with or without peripheral traction bronchiectasis or bronchiolectasis[†]</p>	<p>Subpleural and basal predominant; distribution is often heterogeneous</p> <p>Reticular pattern with peripheral traction bronchiectasis or bronchiolectasis</p> <p>May have mild GGO</p>	<p>Subpleural and basal predominant</p> <p>Subtle reticulation; may have mild GGO or distortion (“early UIP pattern”)</p> <p>CT features and/or distribution of lung fibrosis that do not suggest any specific etiology (“truly indeterminate”)</p>	<p>Findings suggestive of another diagnosis, including:</p> <ul style="list-style-type: none"> • CT features: <ul style="list-style-type: none"> ◦ Cysts ◦ Marked mosaic attenuation ◦ Predominant GGO ◦ Profuse micronodules ◦ Centrilobular nodules ◦ Nodules ◦ Consolidation • Predominant distribution: <ul style="list-style-type: none"> ◦ Peribronchovascular ◦ Perilymphatic ◦ Upper or mid-lung • Other: <ul style="list-style-type: none"> ◦ Pleural plaques (consider asbestosis) ◦ Dilated esophagus (consider CTD) ◦ Distal clavicular erosions (consider RA) ◦ Extensive lymph node enlargement (consider other etiologies) ◦ Pleural effusions, pleural thickening (consider CTD/drugs)



KES
UI

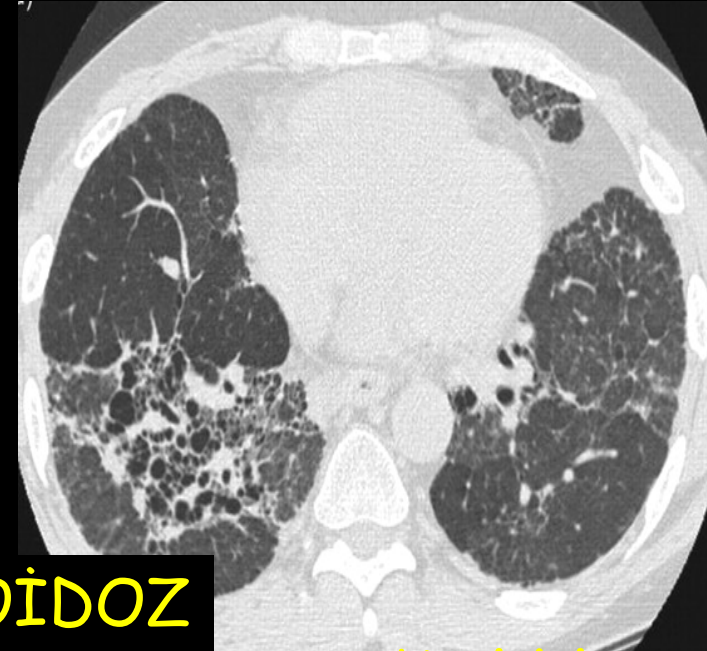
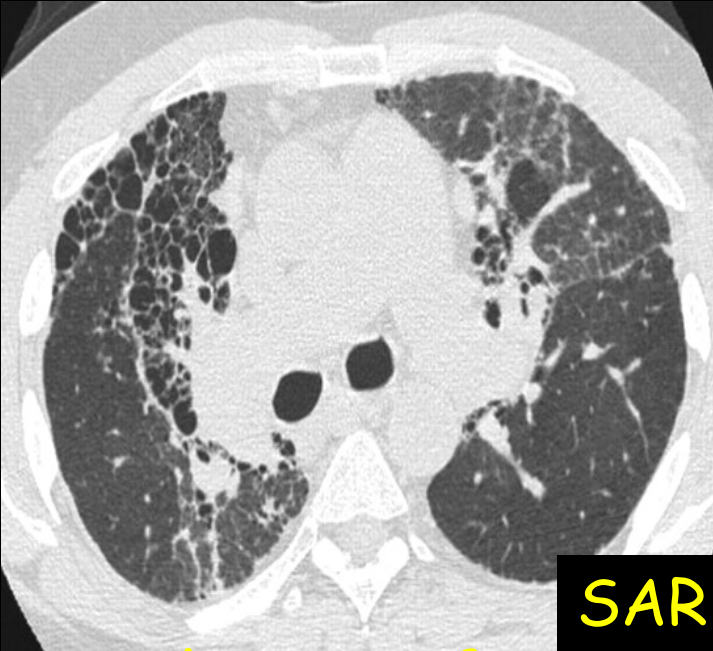
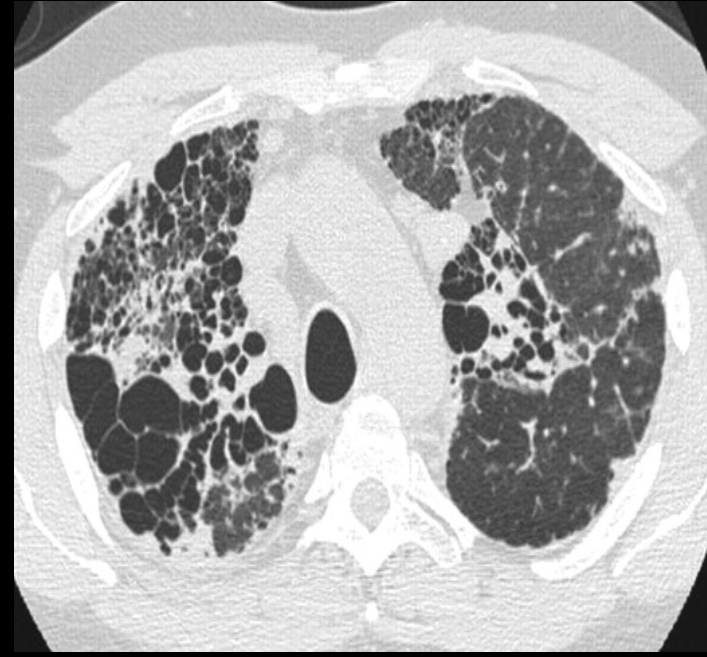
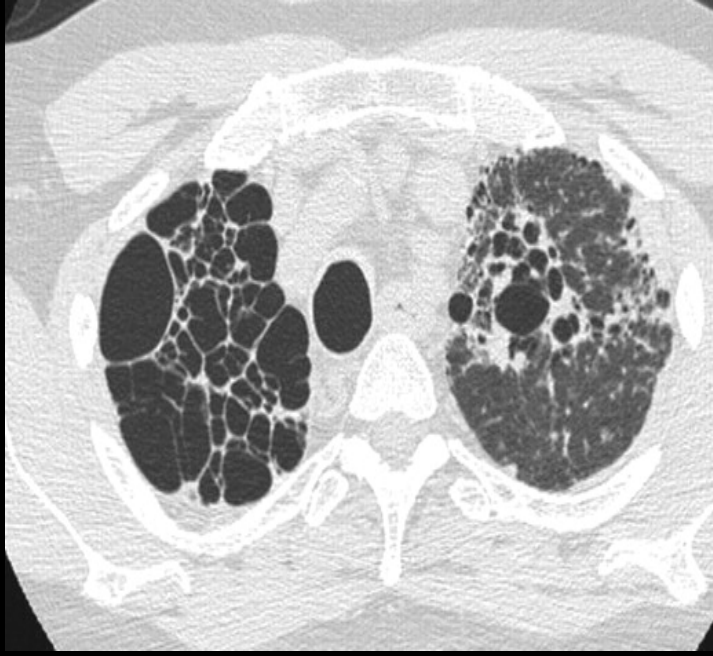


OLASI UIP



Am J Respir Crit Care Med
2018;198, e44–e68, Sep 1, 2018

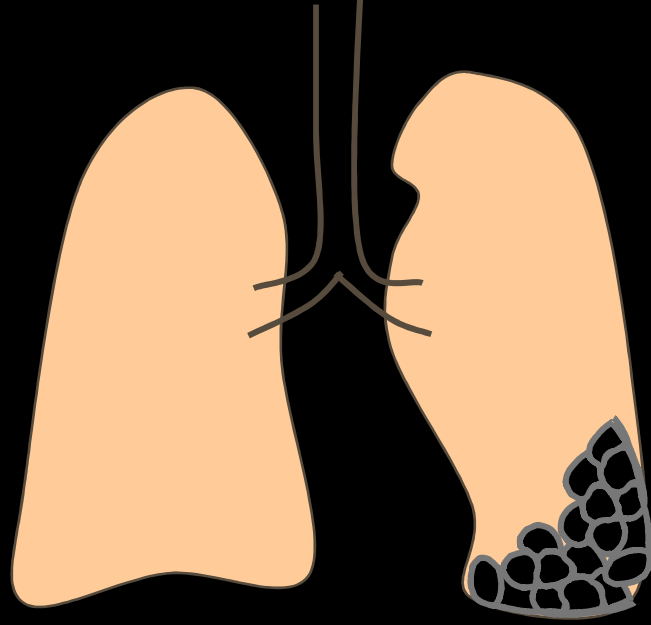
BELIRSIZ




SARKOİDOZ

Alternatif tanı- üst orta zon ağırlıklı tutulum


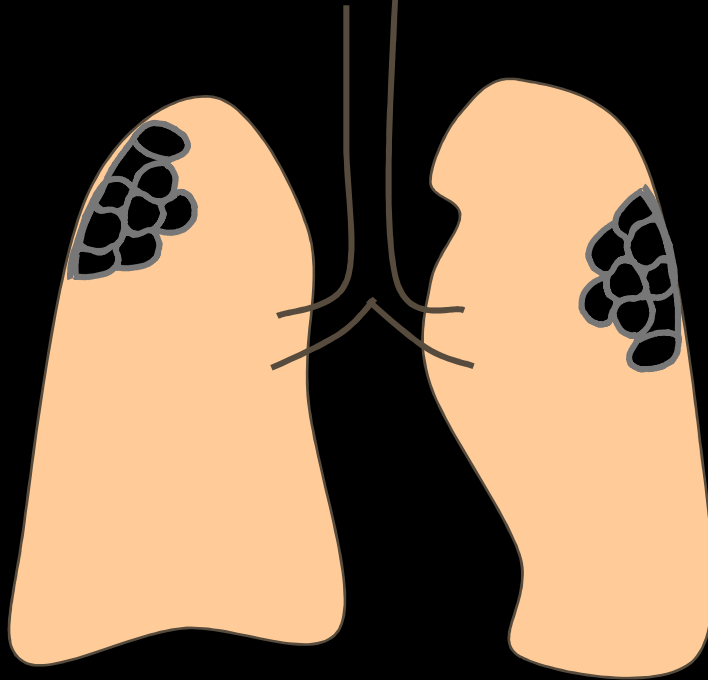
BALPETEĐİ DAĐILIMI



BAZAL



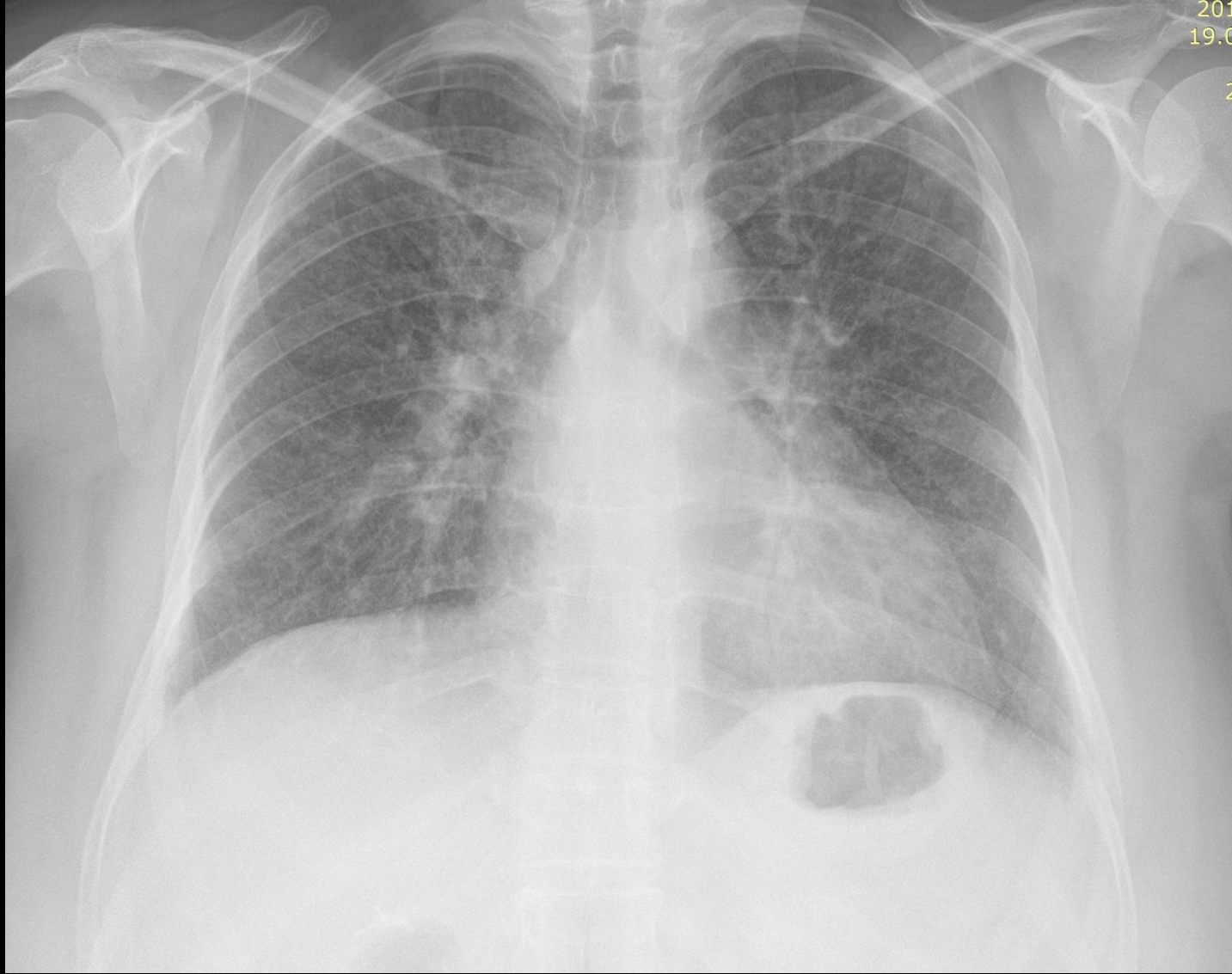- IPF
- Asbestozis
- Bađ doku hastalıĐı(RA)
- İlaçlar



ÜST / ORTA ZON

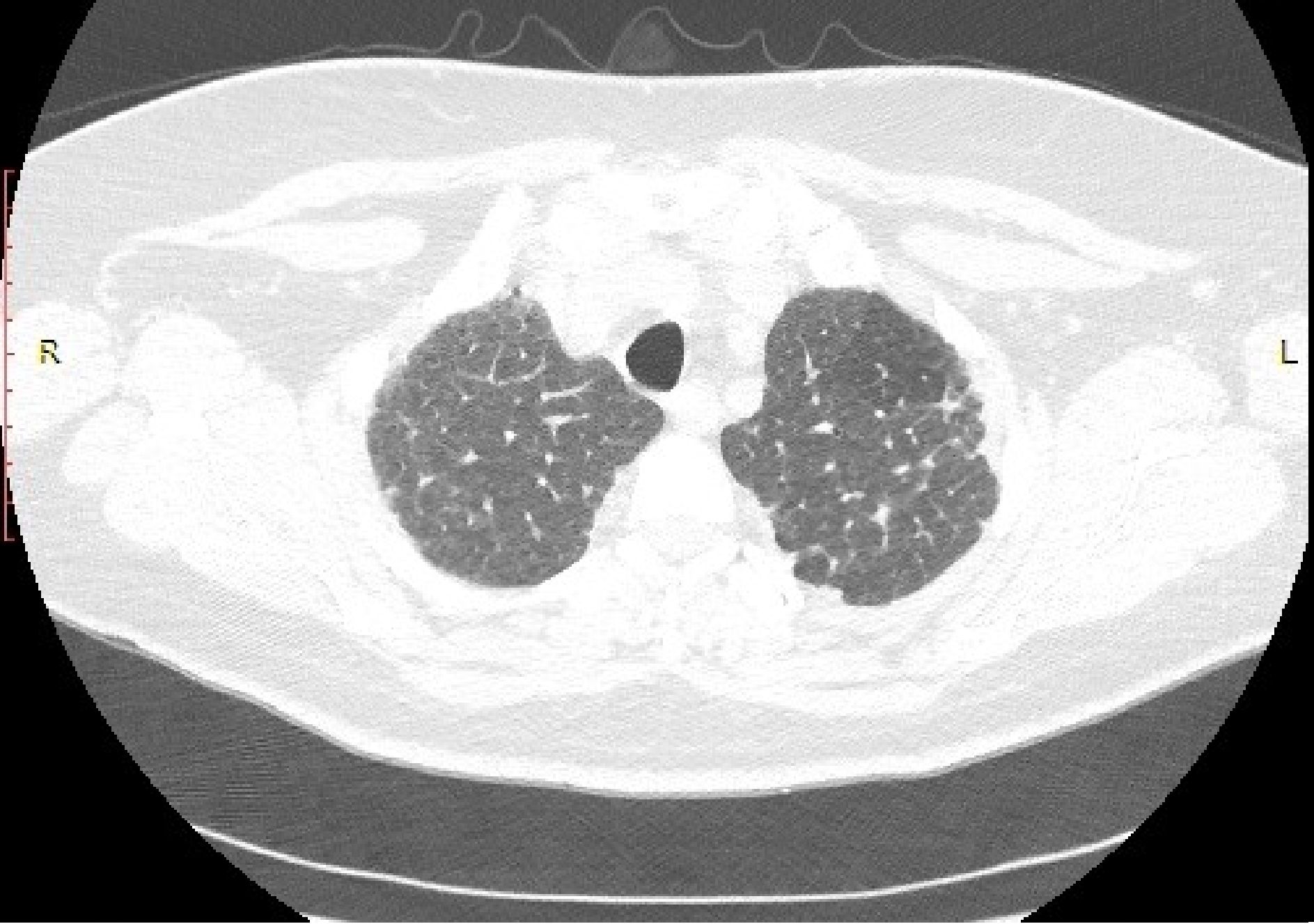
- Kronik HP
- Sarkoidoz

OLGU 4:

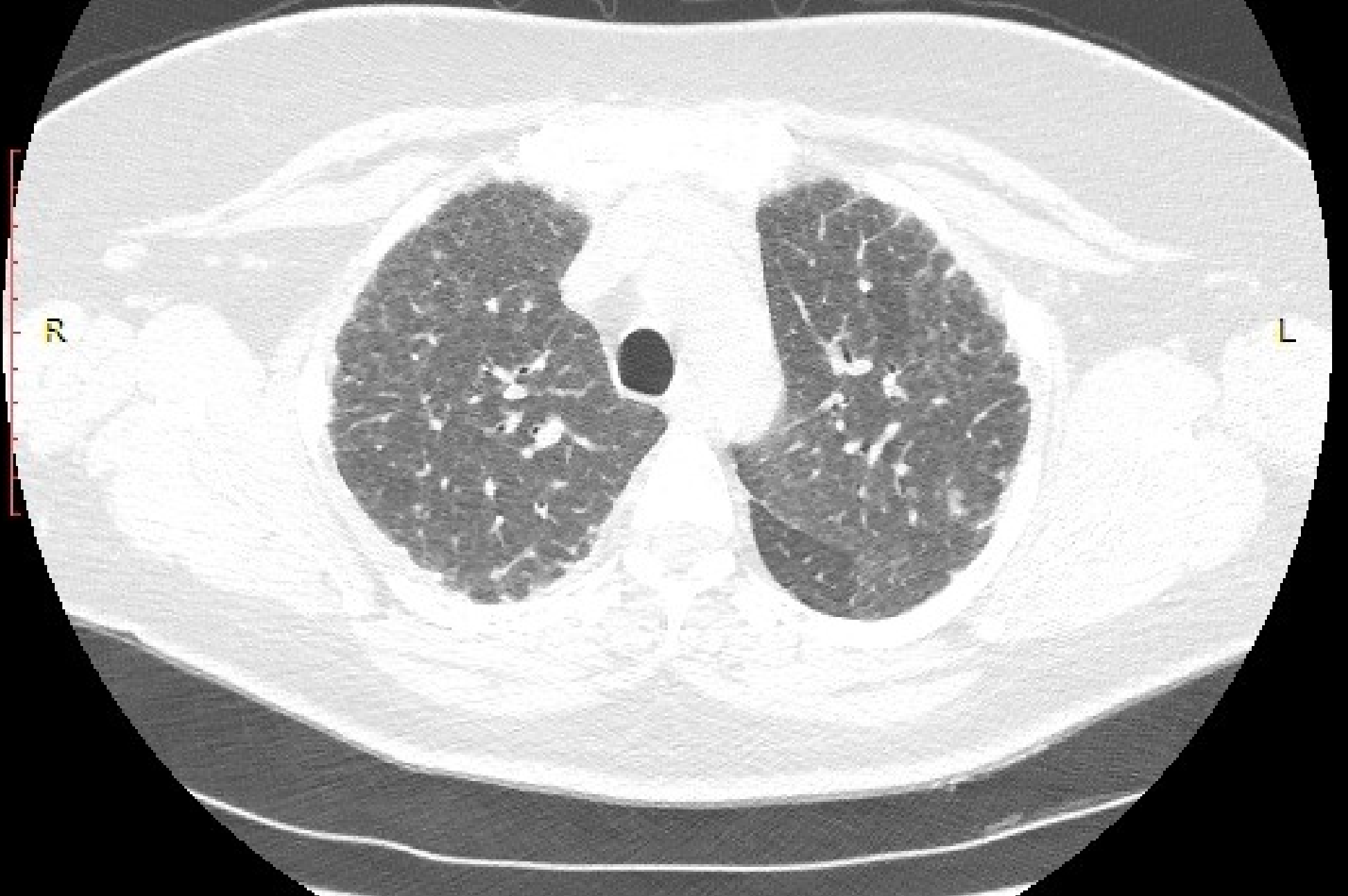


43 y, kadın,
Nefes darlığı, öksürük

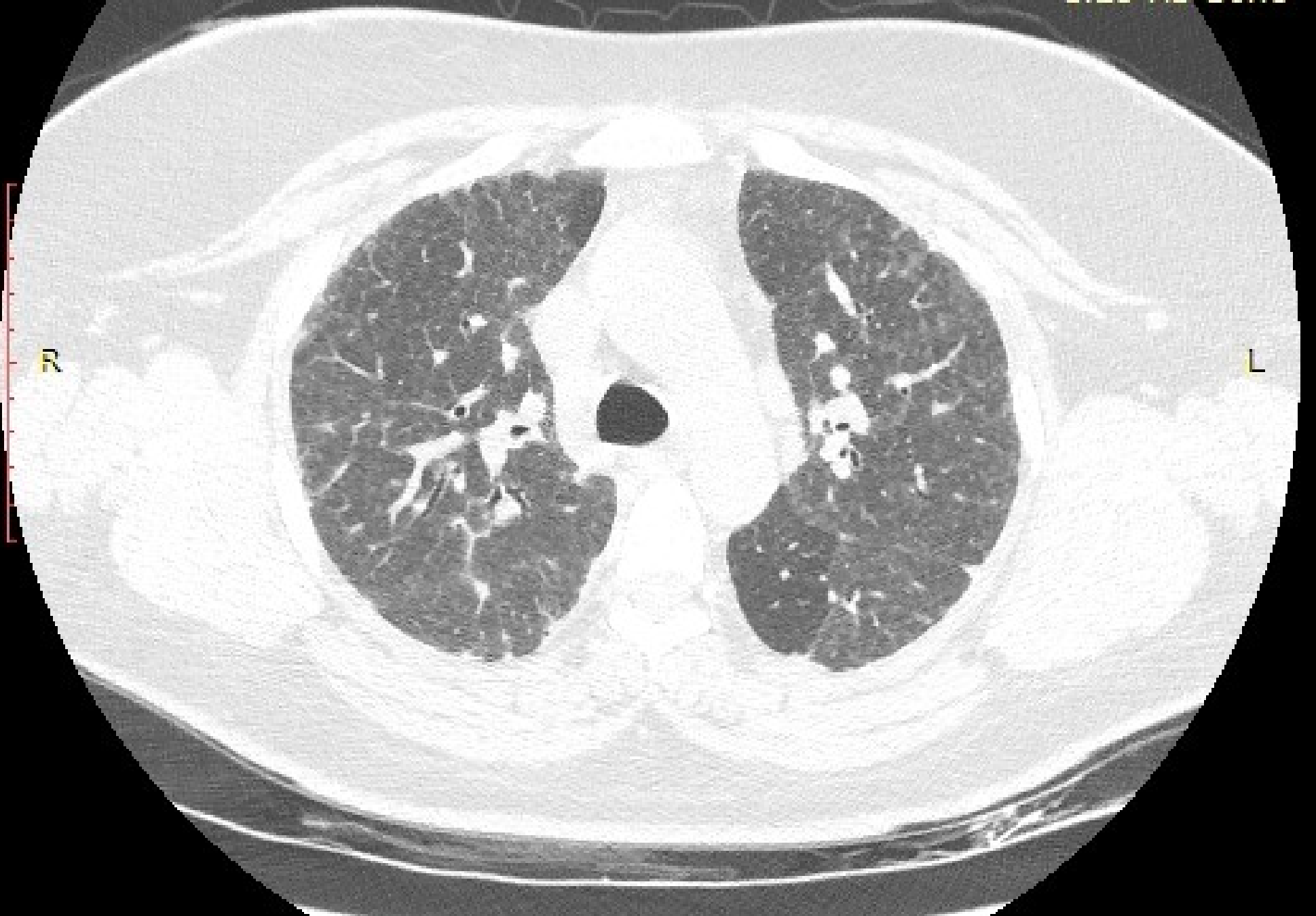
Yüksek Rezolüsyonlu AI
1.25 HD Bone



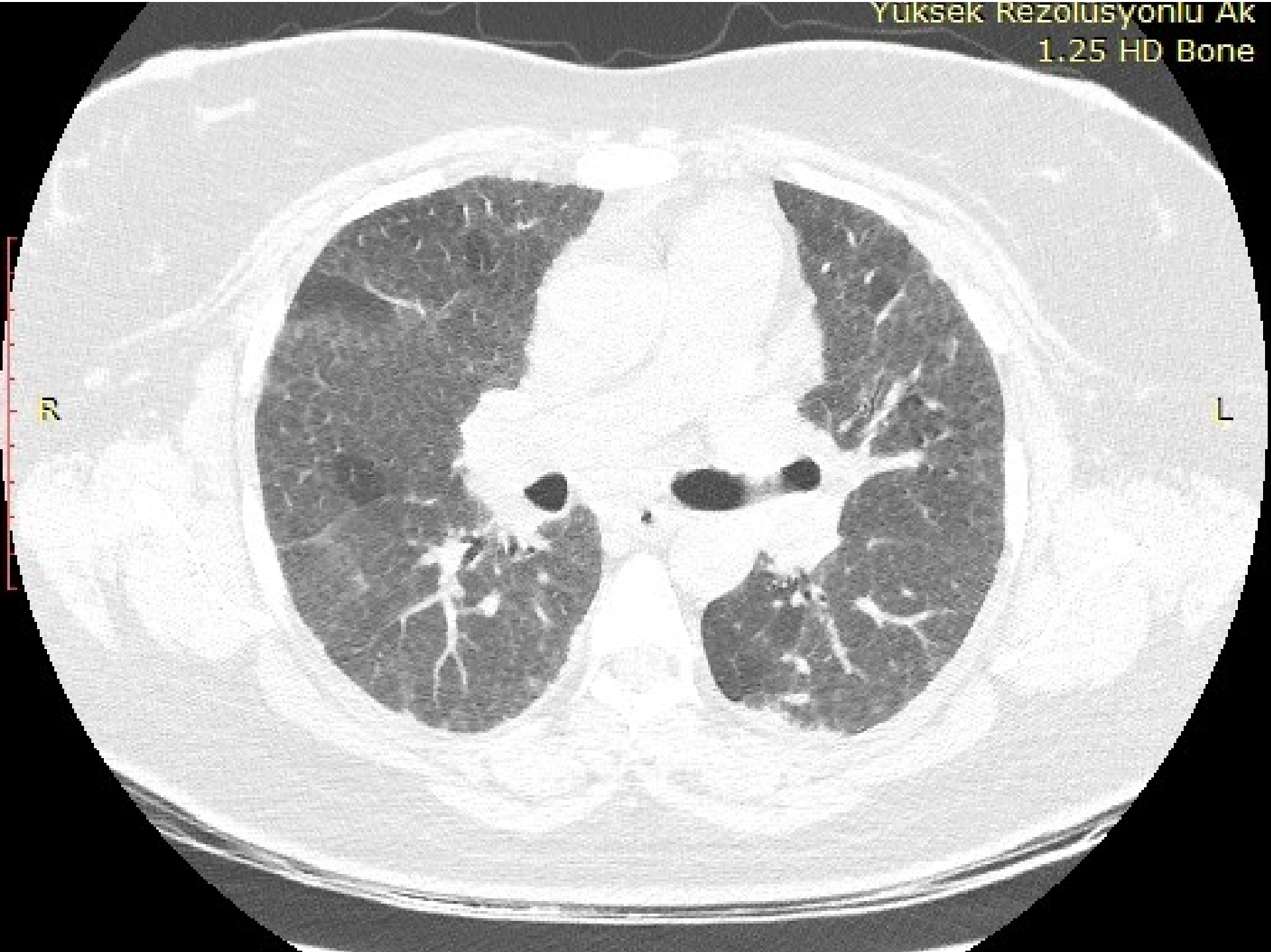
Yüksek Rezolüsyonlu Ak
1.25 HD Bone



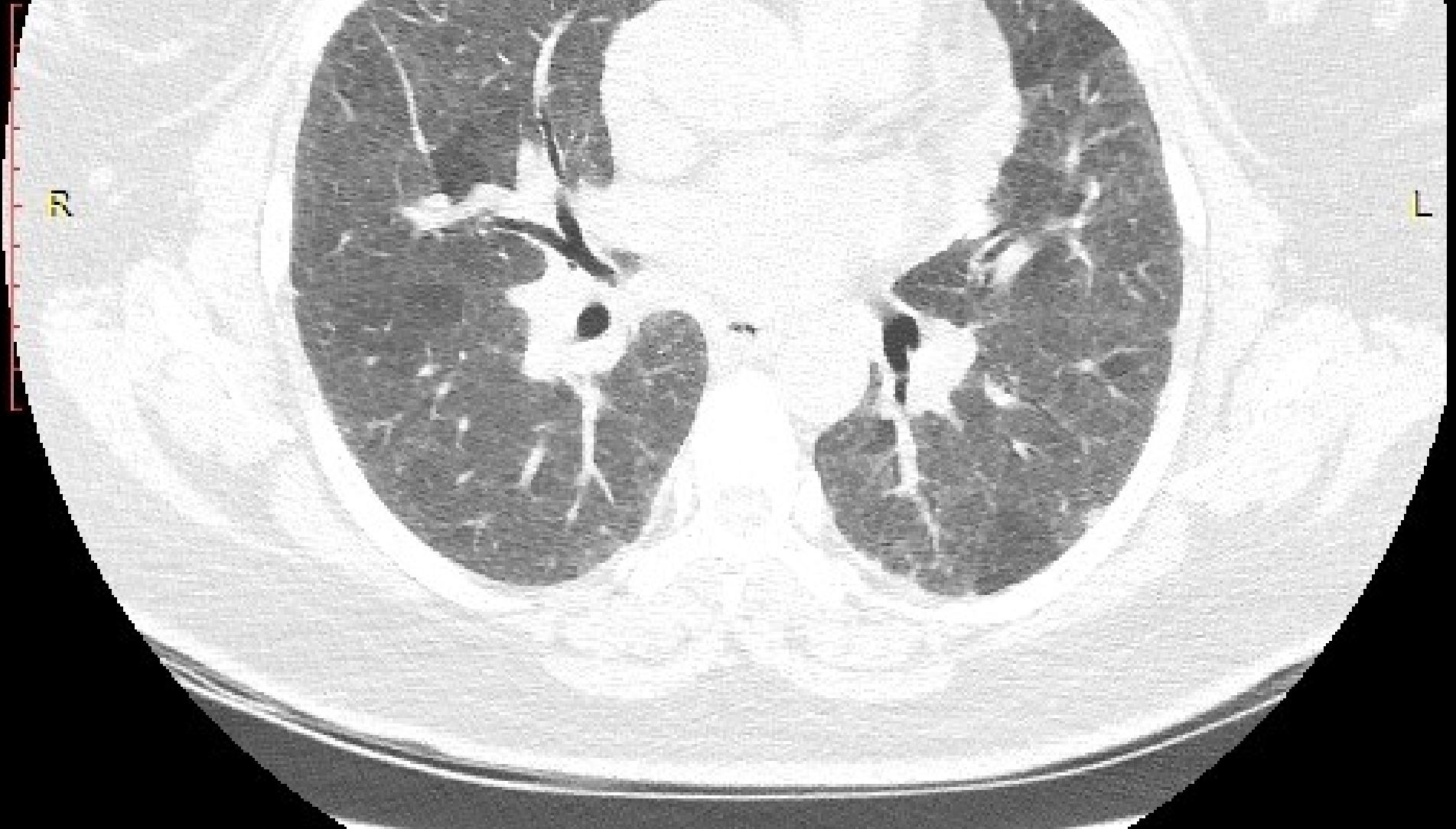
Yüksek Rezolüsyonlu Ak
1.25 HD Bone



Yuksek Rezolusyonlu Ak
1.25 HD Bone



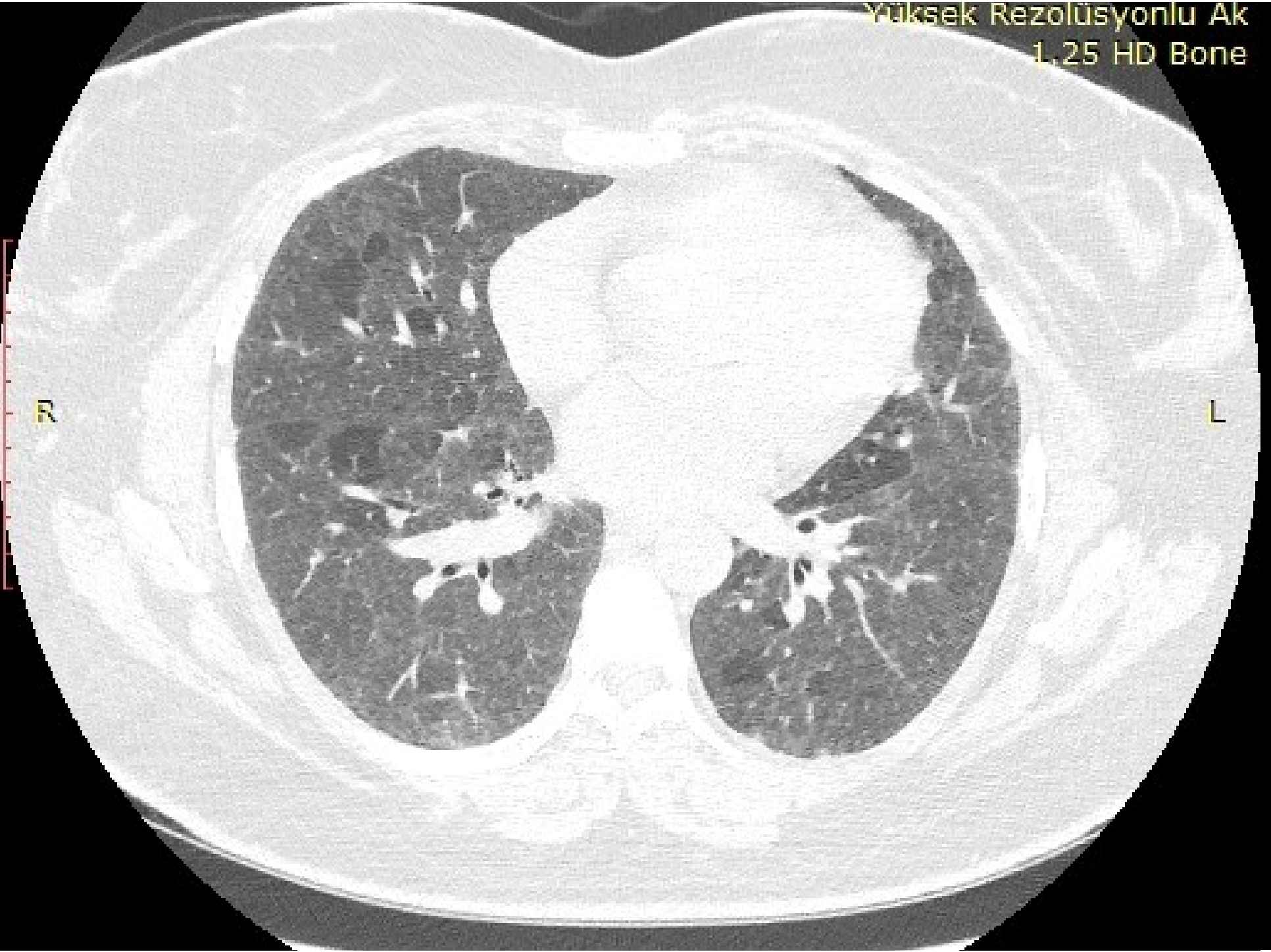
Yüksek Rezolüsyonlu AI
1.25 HD Bone



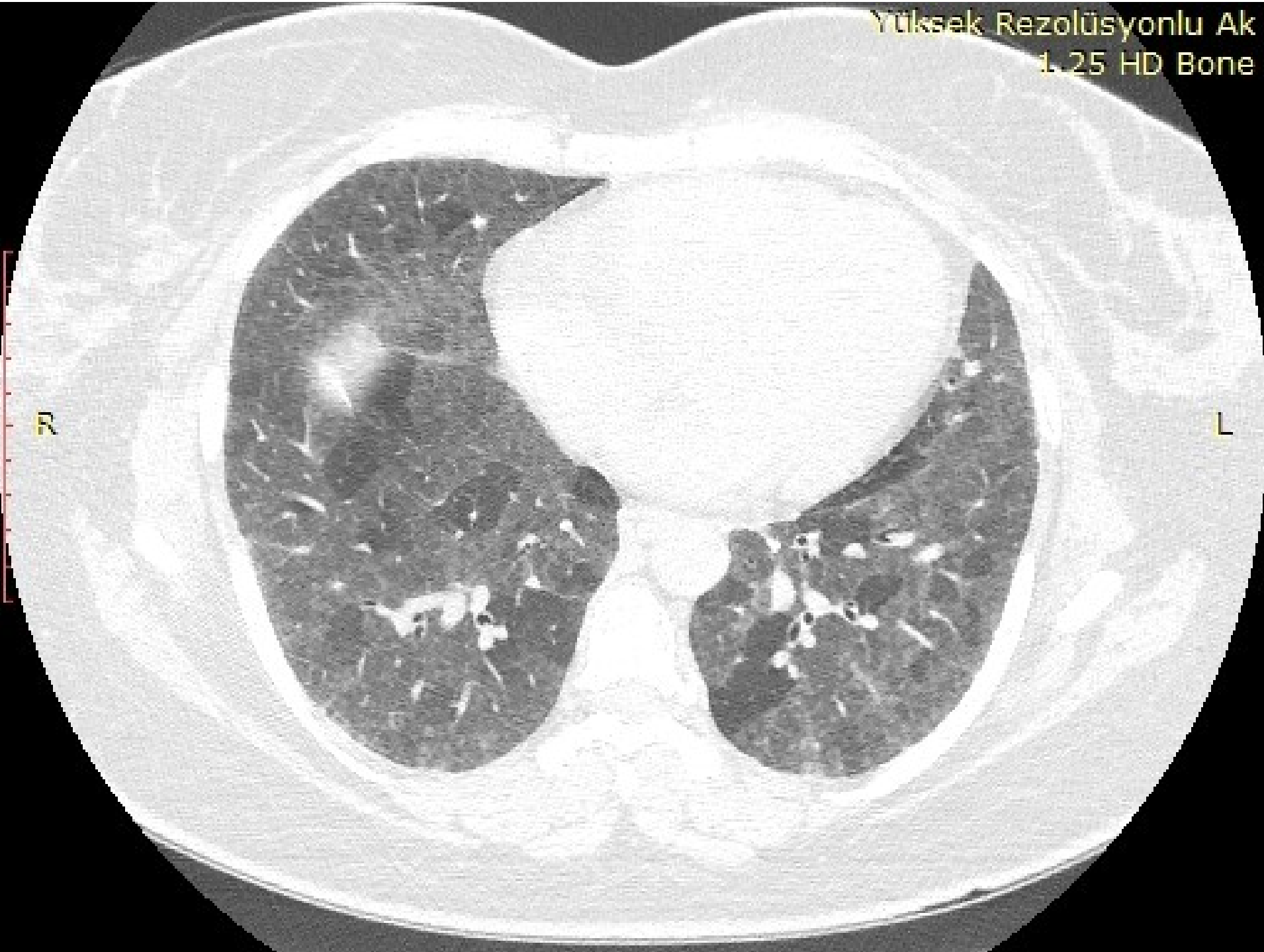
Yüksek Rezolüsyonlu Ak
1,25 HD Bone

R

L



Yüksek Rezolüsyonlu Ak
1.25 HD Bone



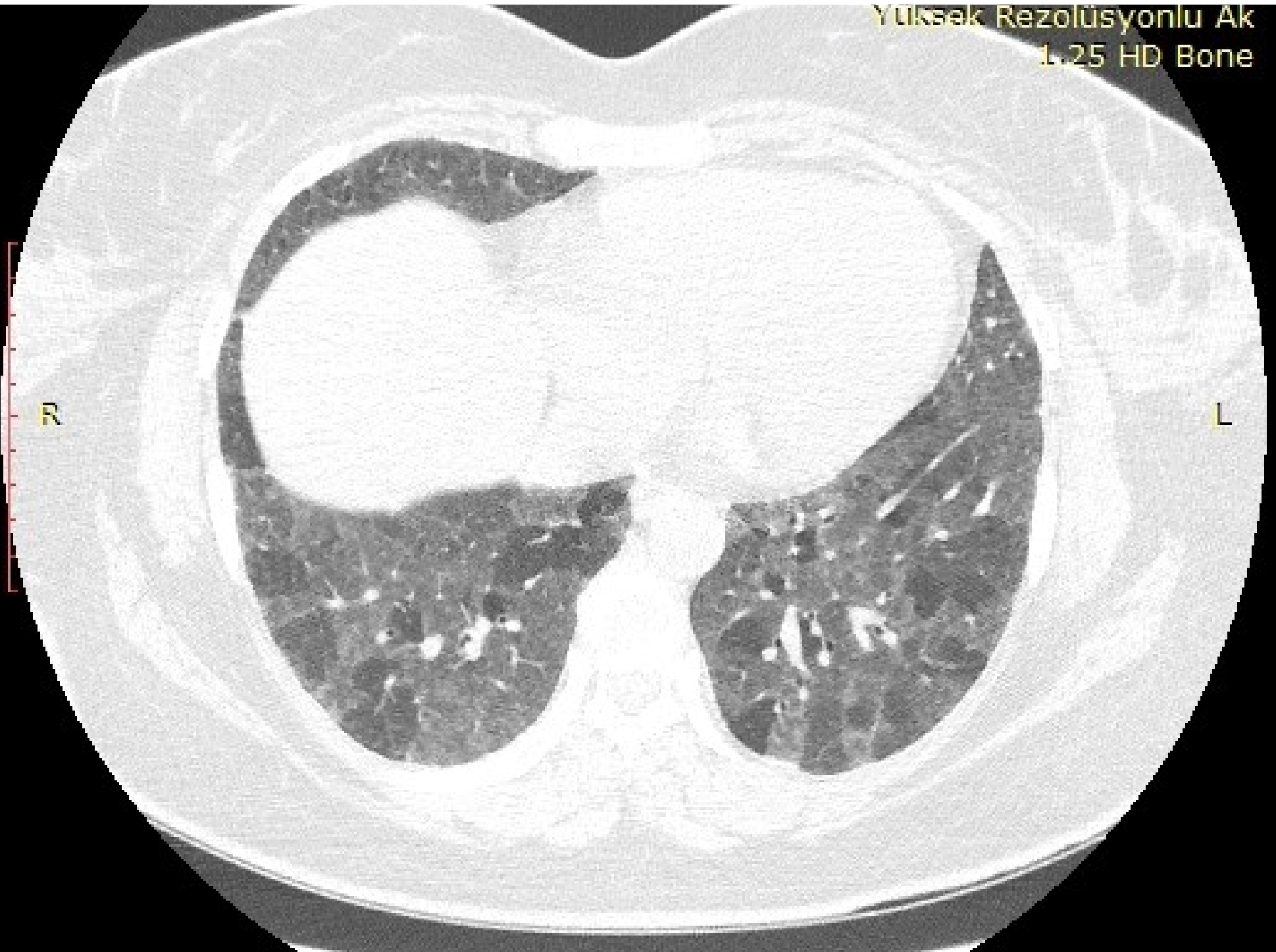
R

L

Yüksek Rezolüsyonlu Ak
1.25 HD Bone

R

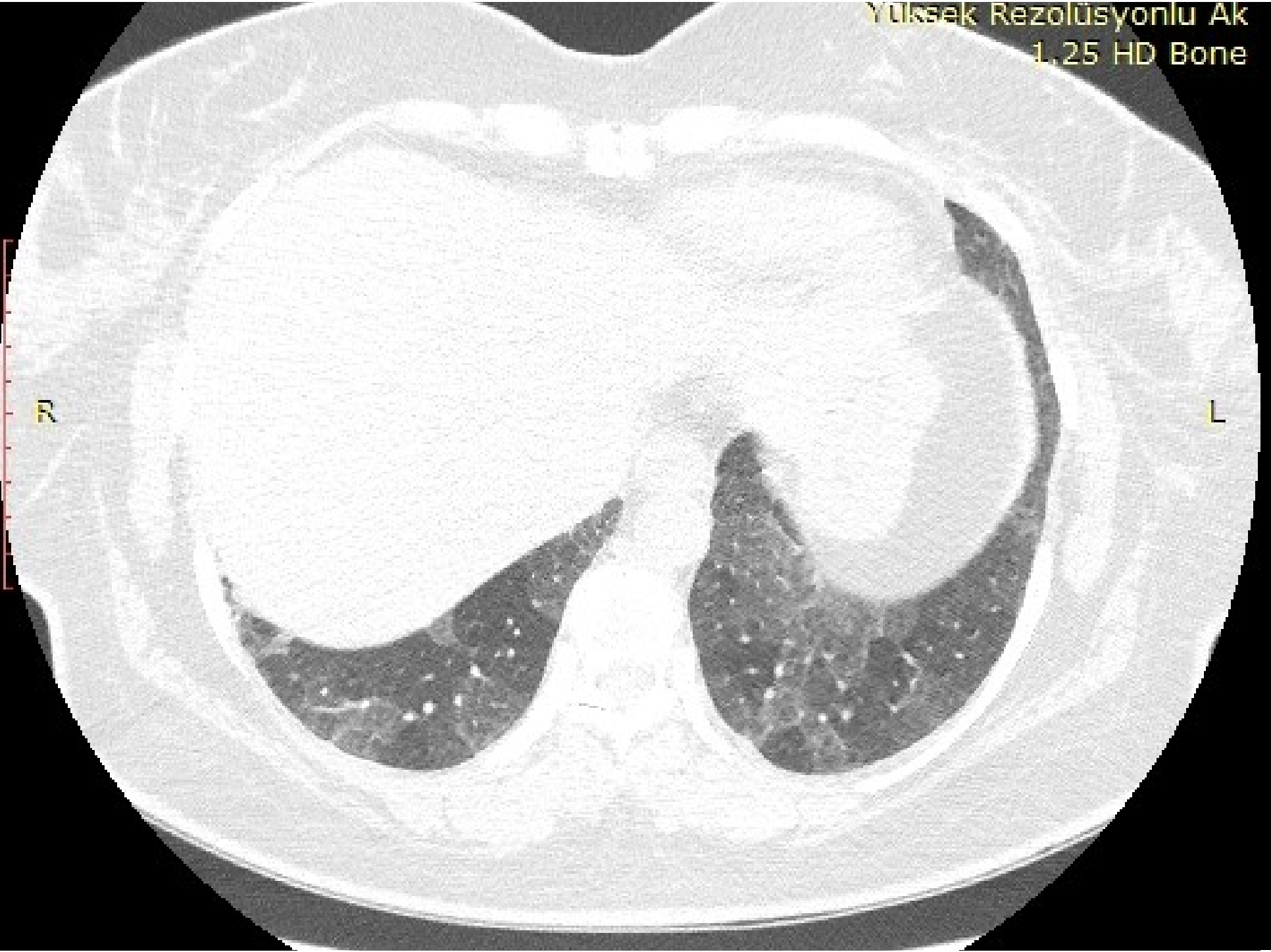
L

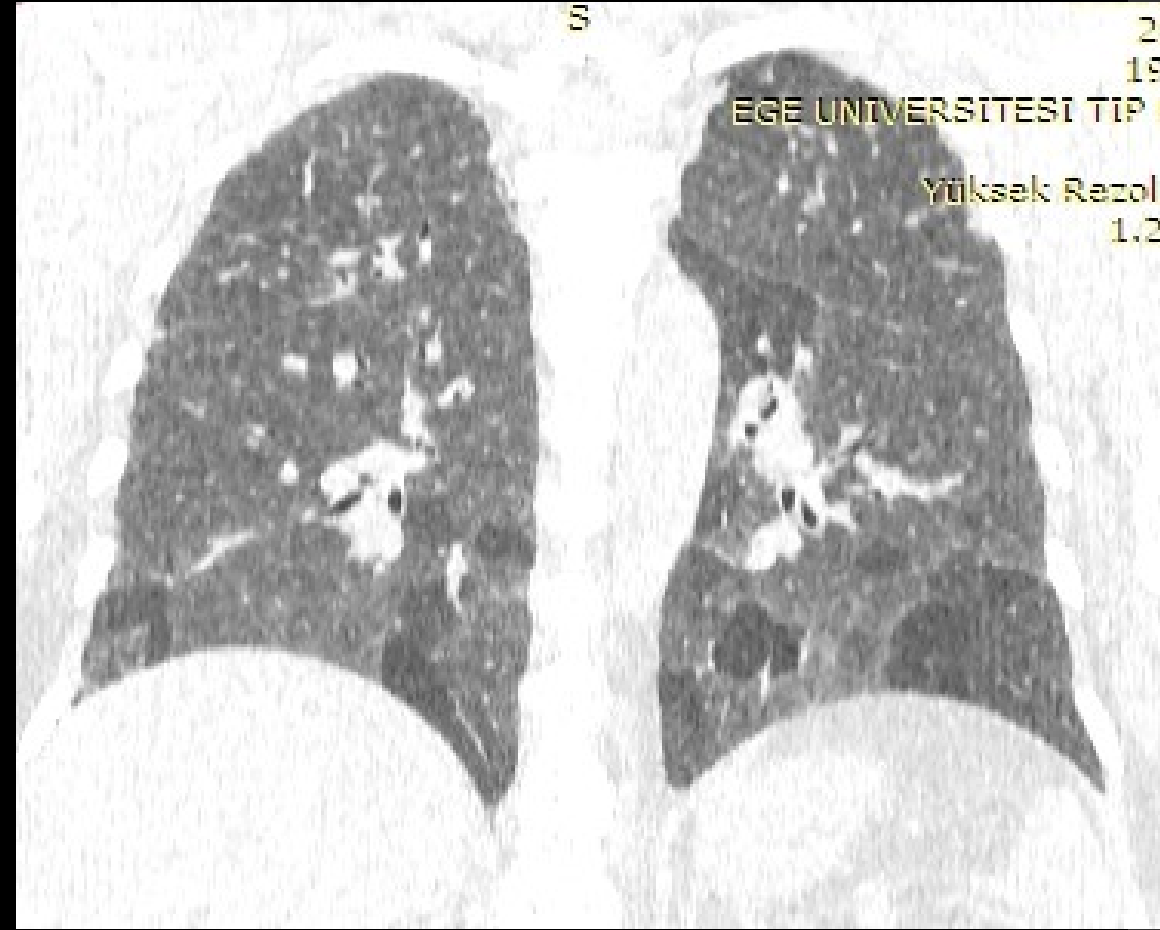
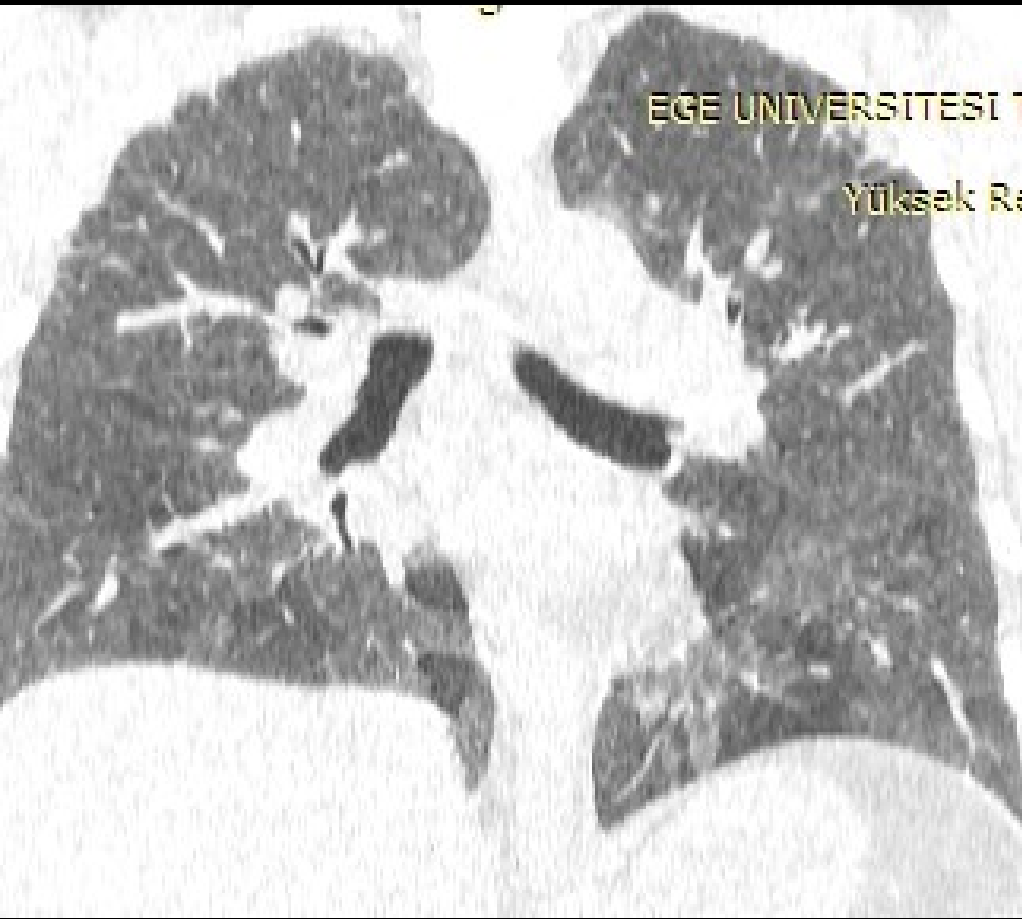


Yüksek Rezolüsyonlu Ak
1,25 HD Bone

R

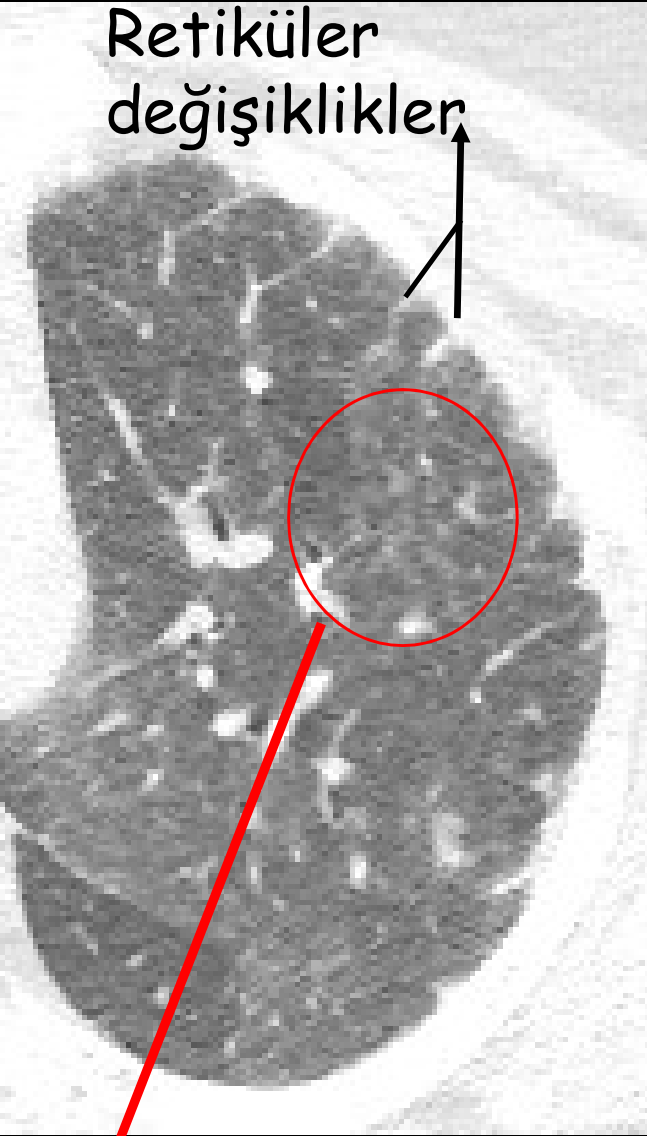
L



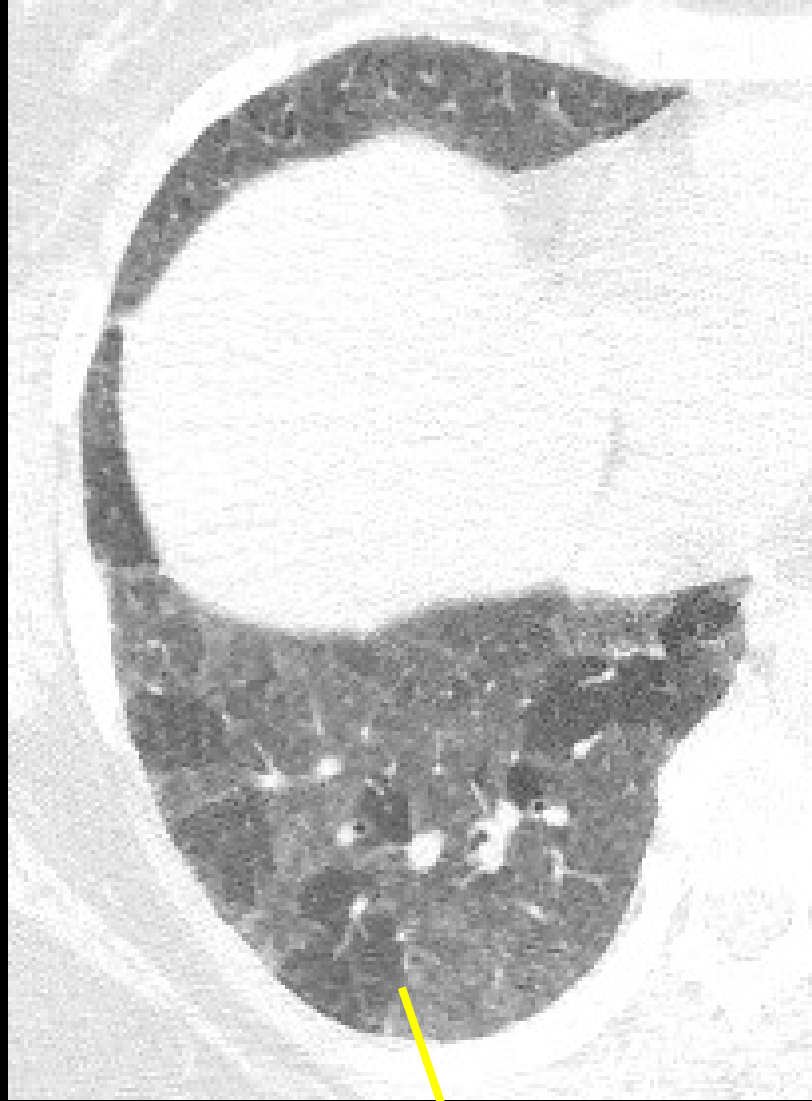

Tanınız Nedir?

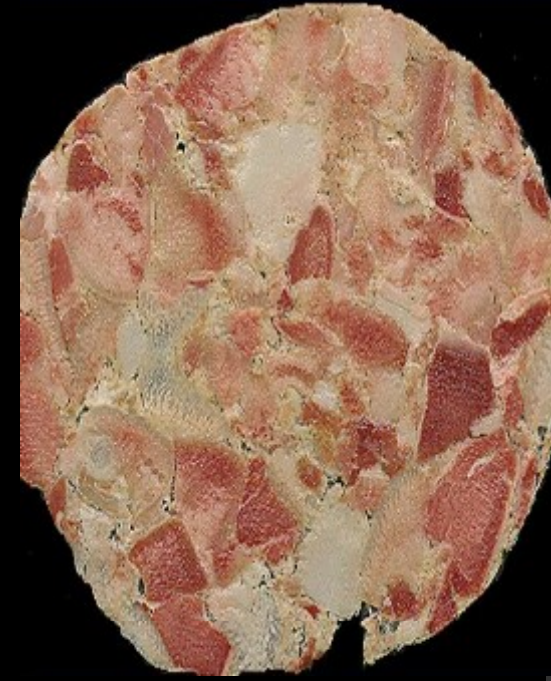Retiküler
değişiklikler



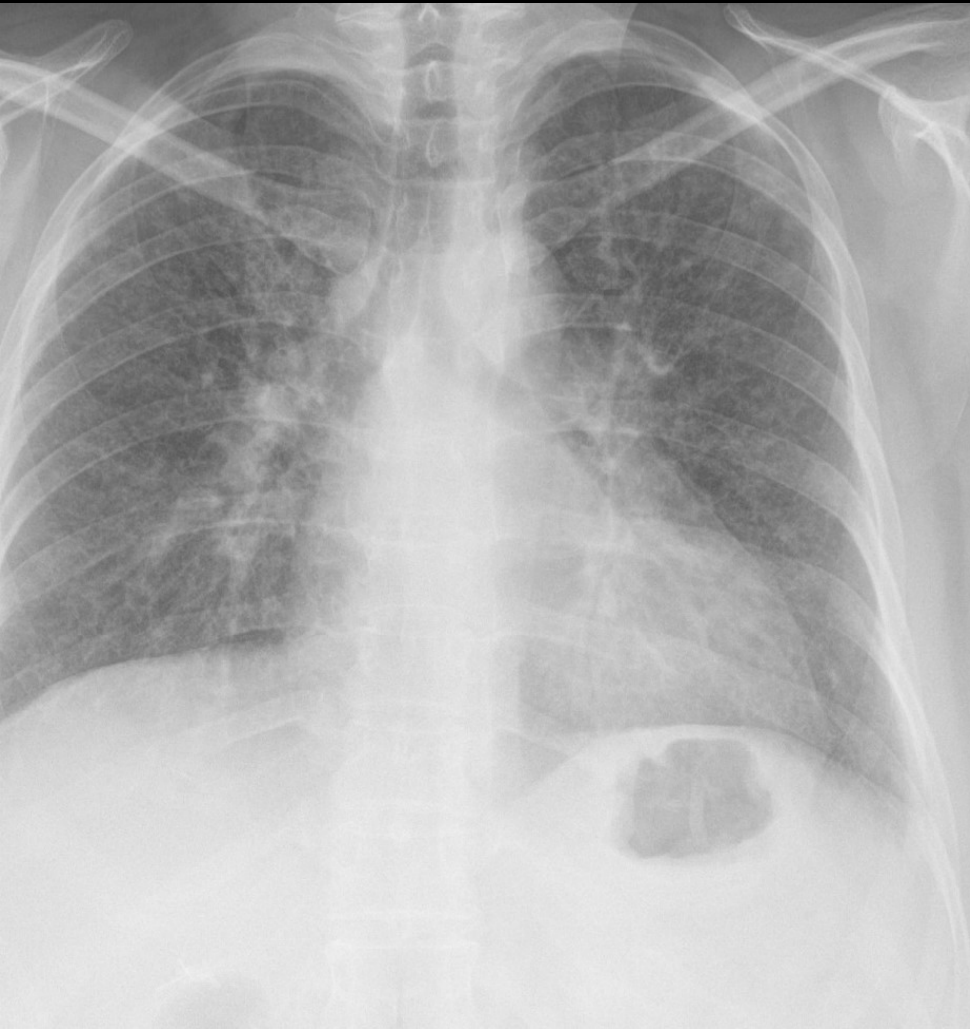
Santrlobüler
nodüller



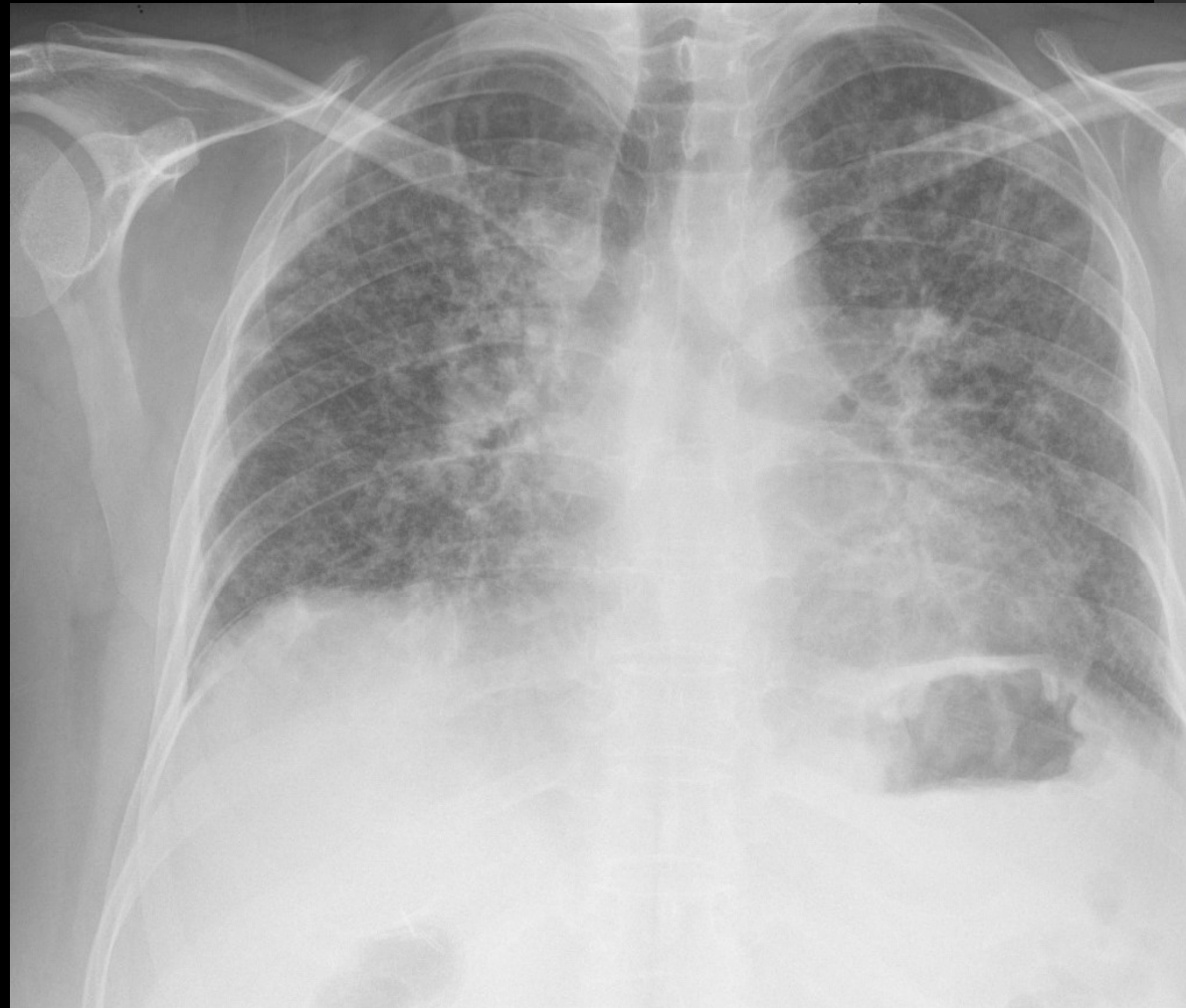
Hava Hapsi alanları



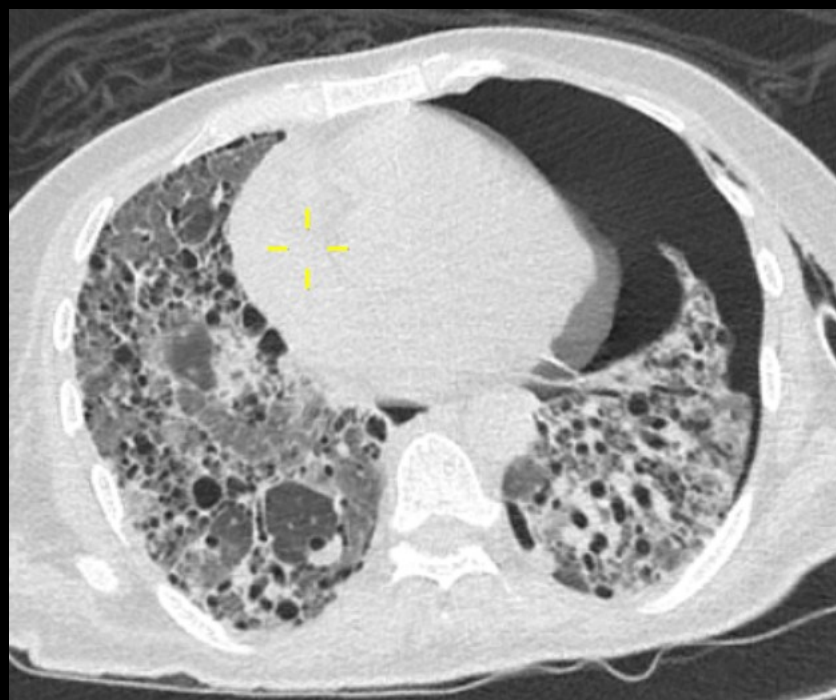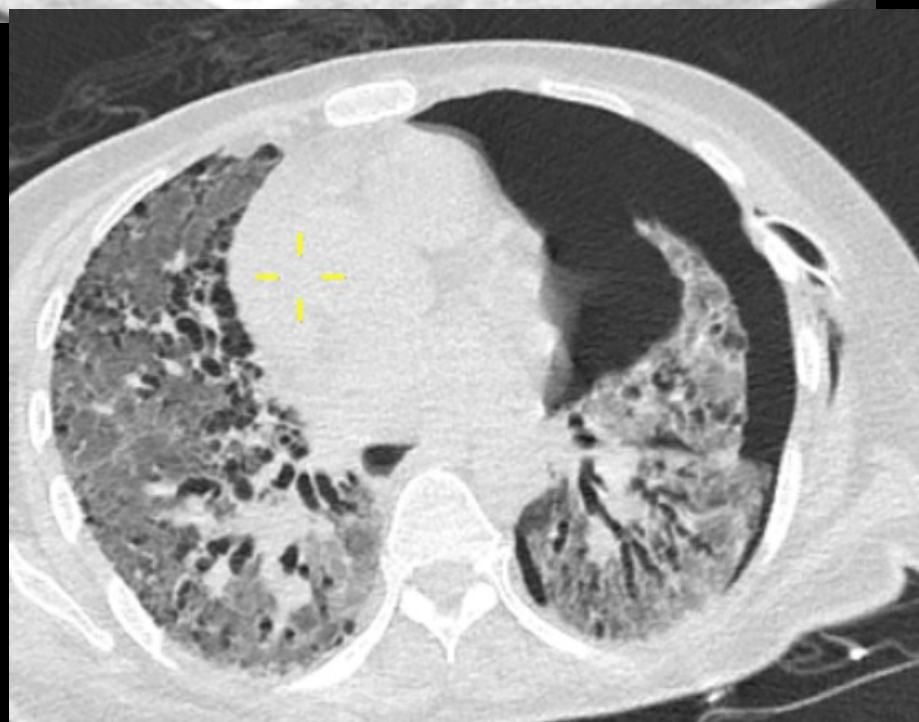
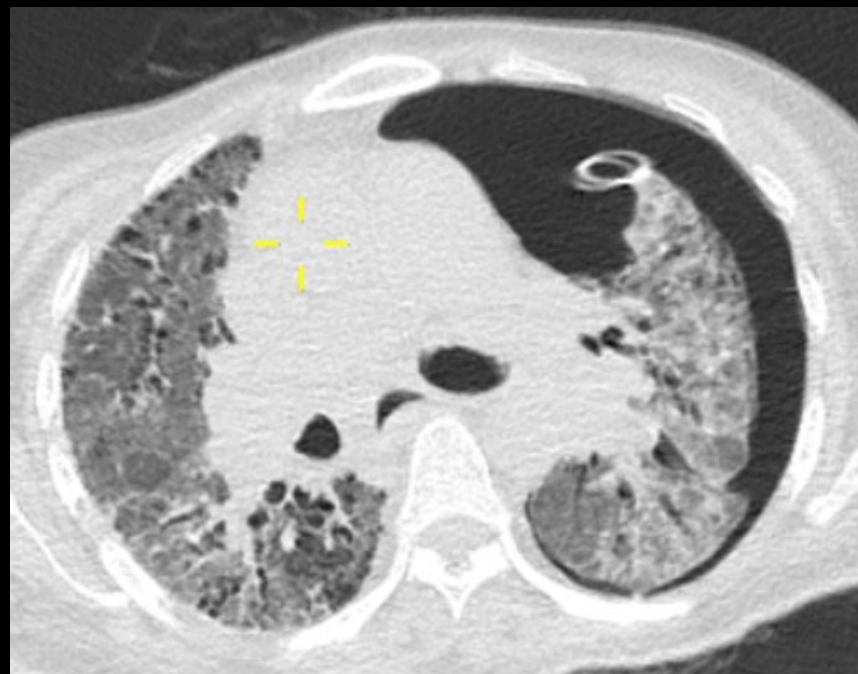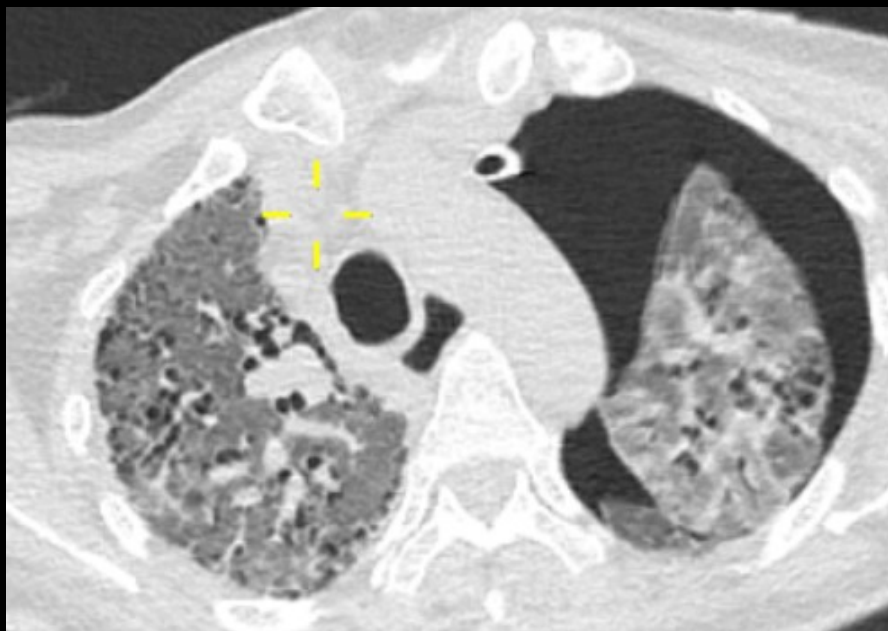
Kronik
Hipersensitivite
Pnömonisi
(Kuş besleme
öyküsü+)

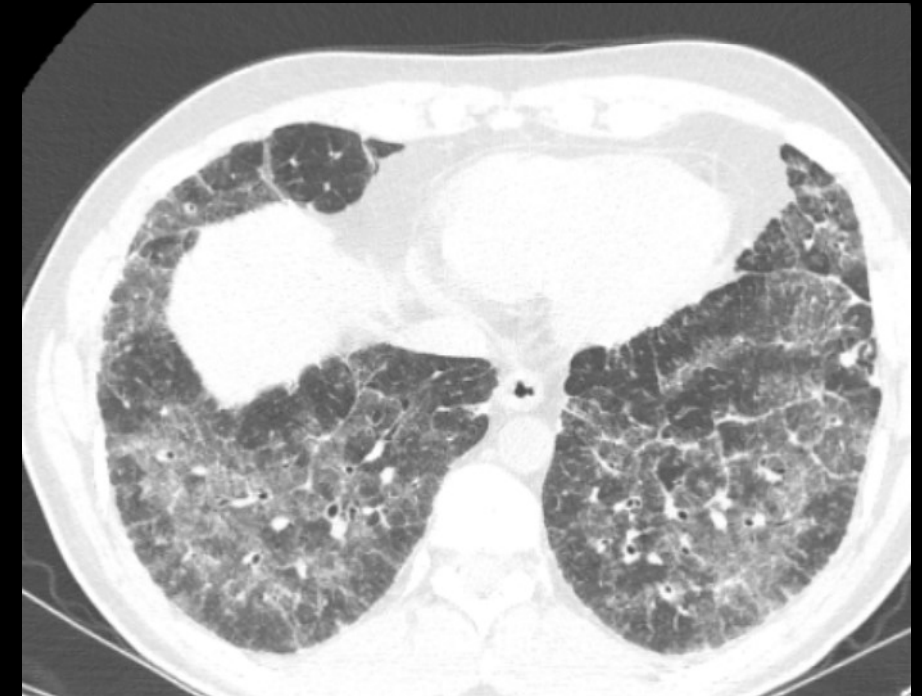
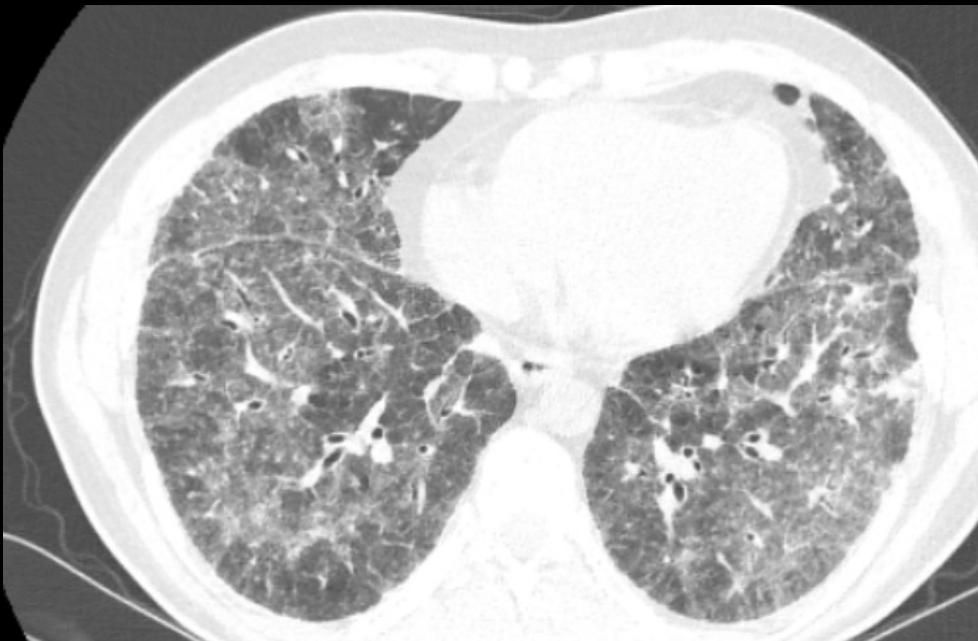
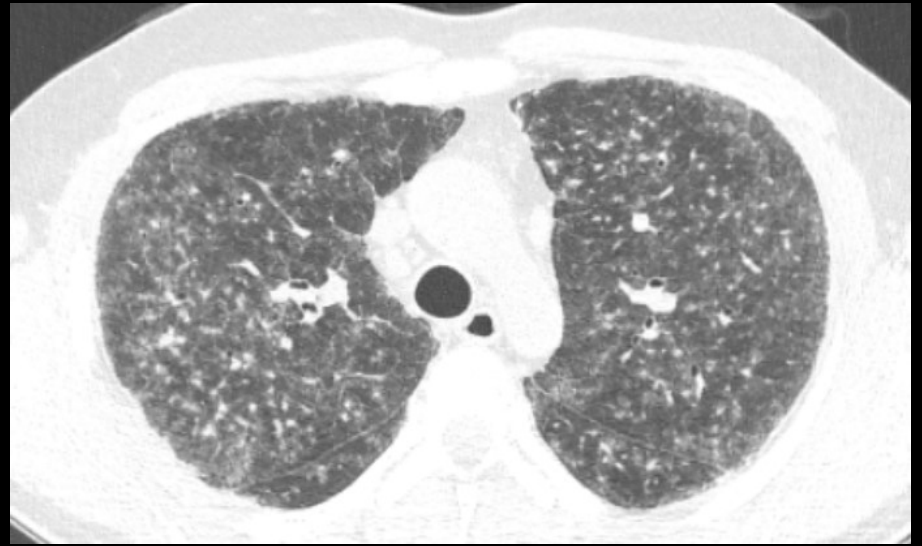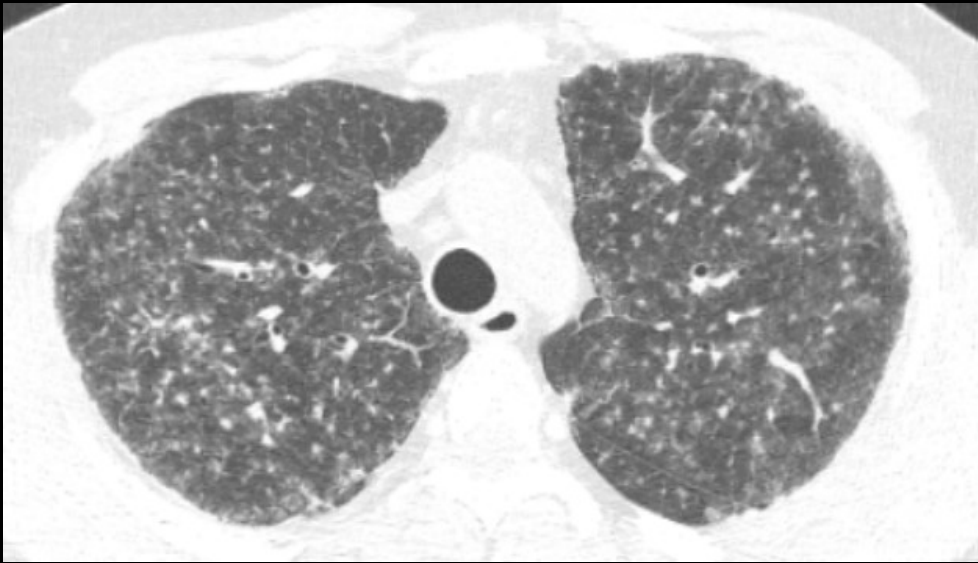11.10.2016



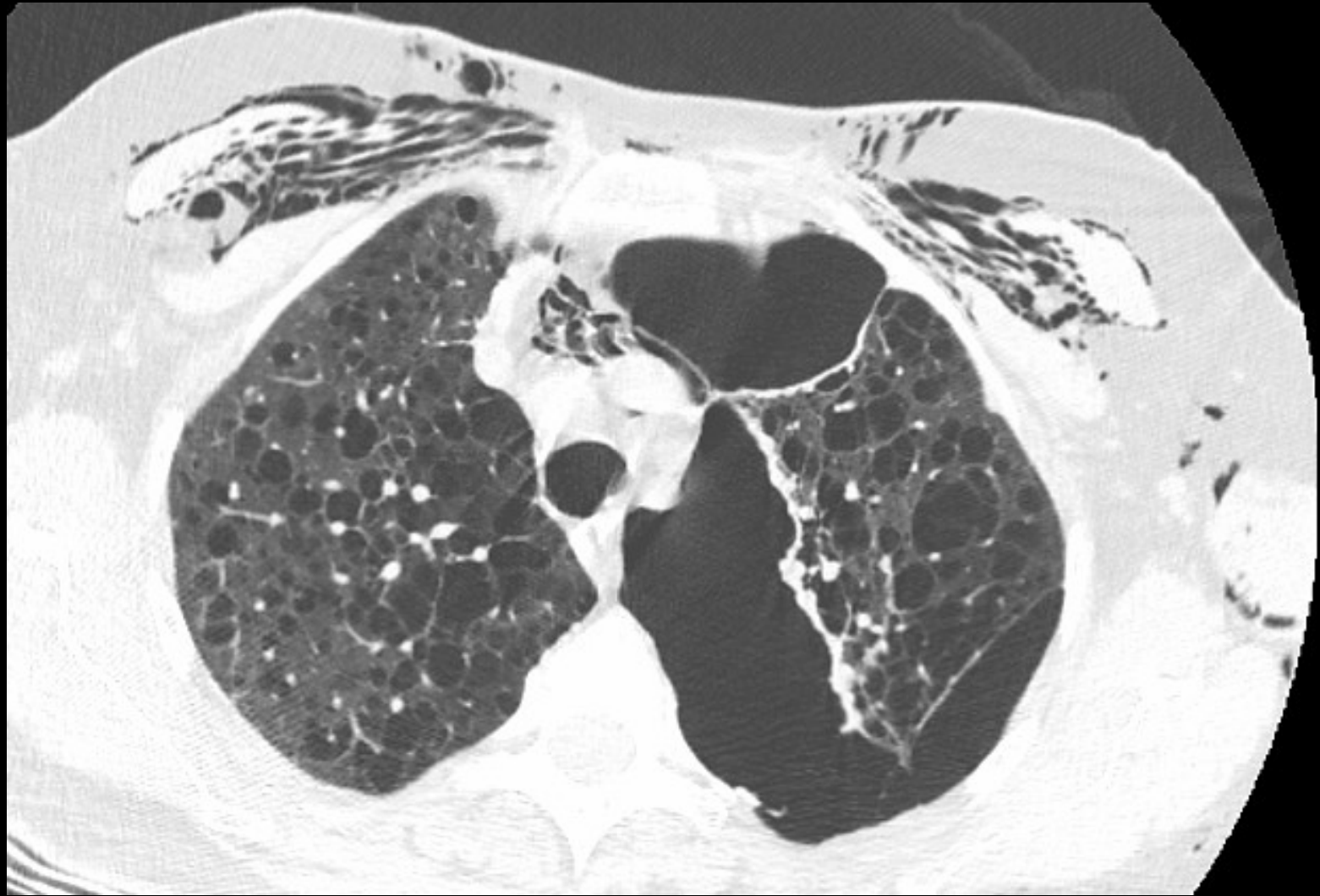17.01.2018



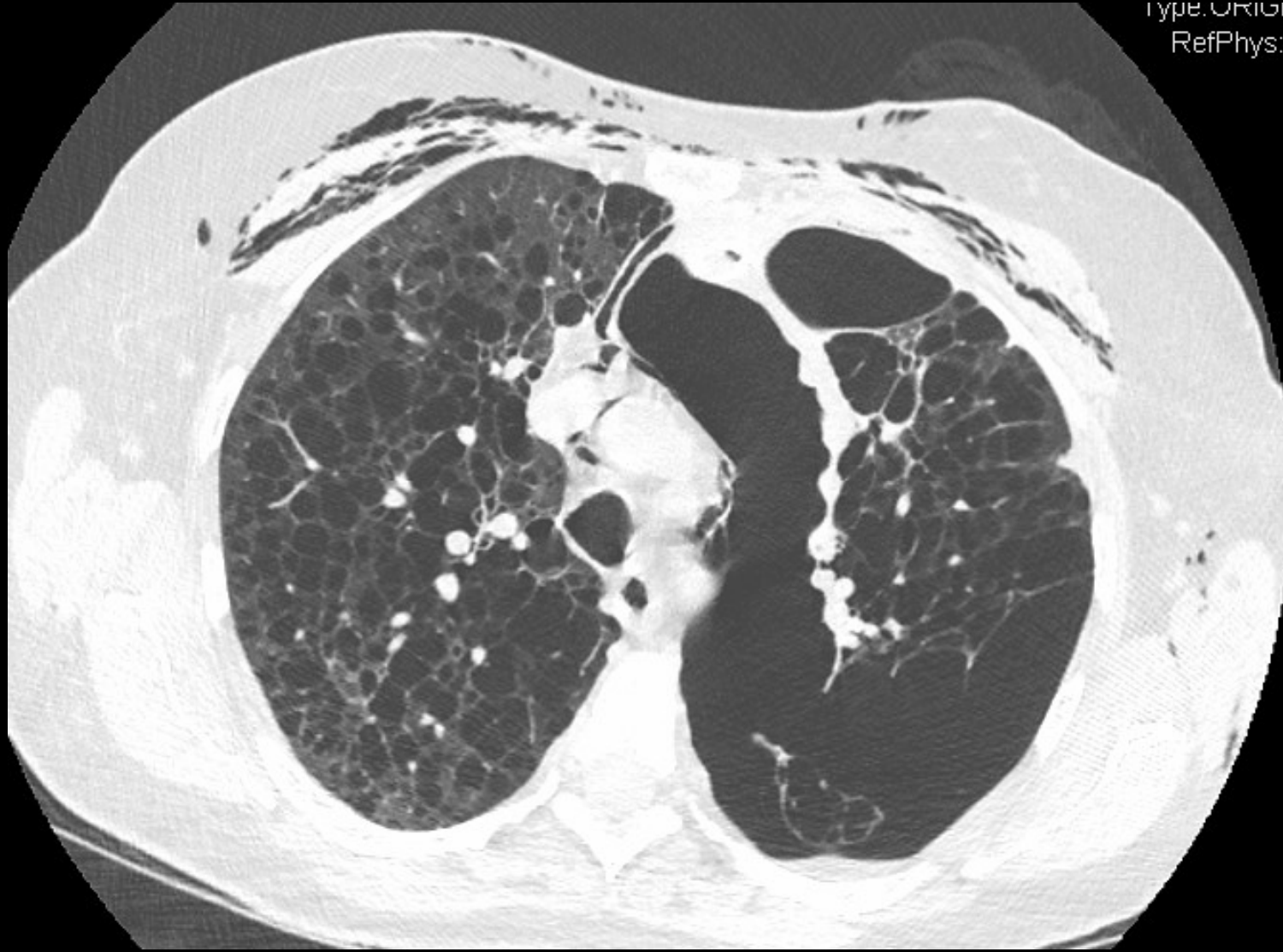


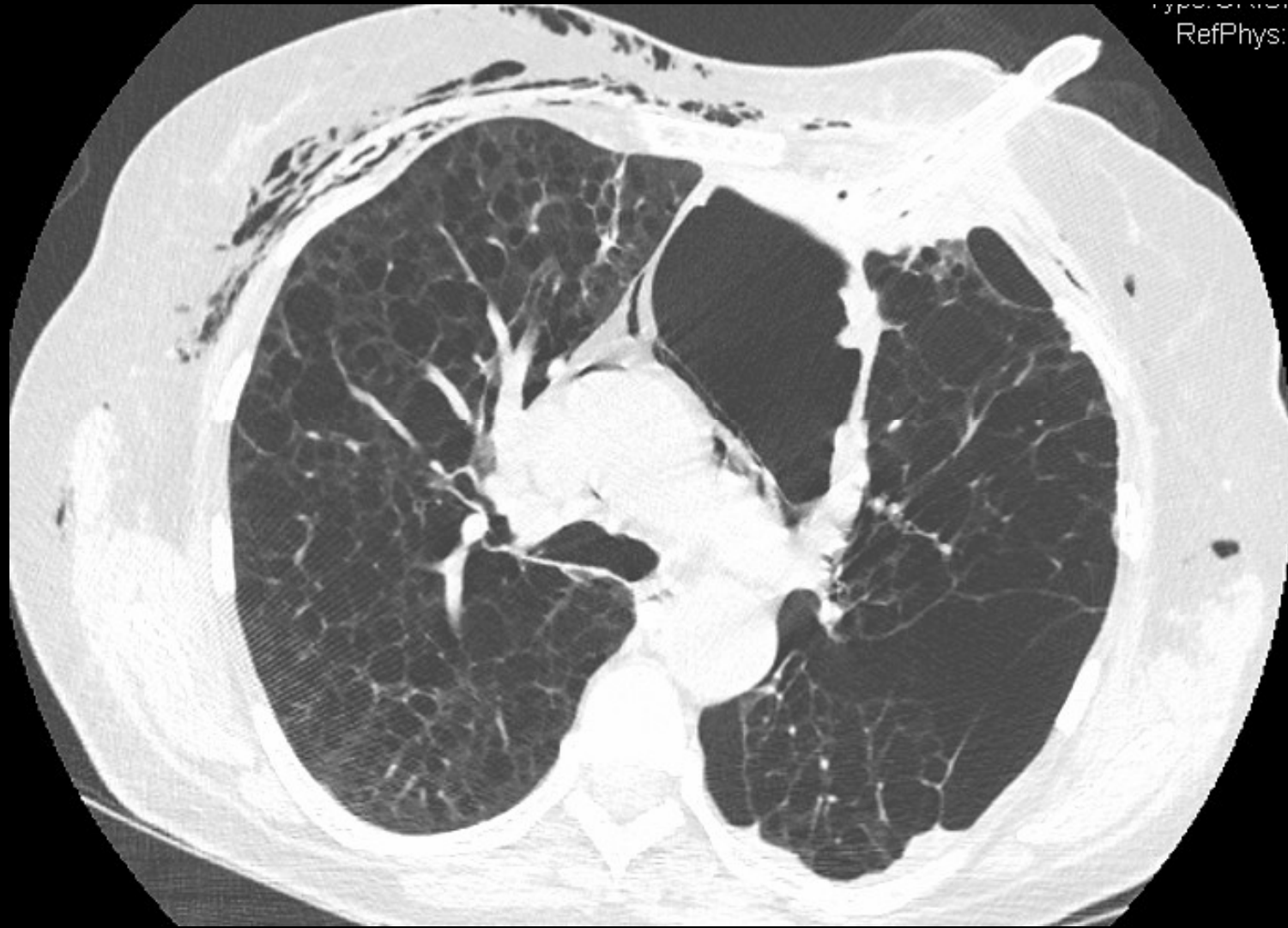
OLGU 5

- 58 yaş, kadın olgu
- Solunum sıkıntısı ile Acil Servise başvuruyor.

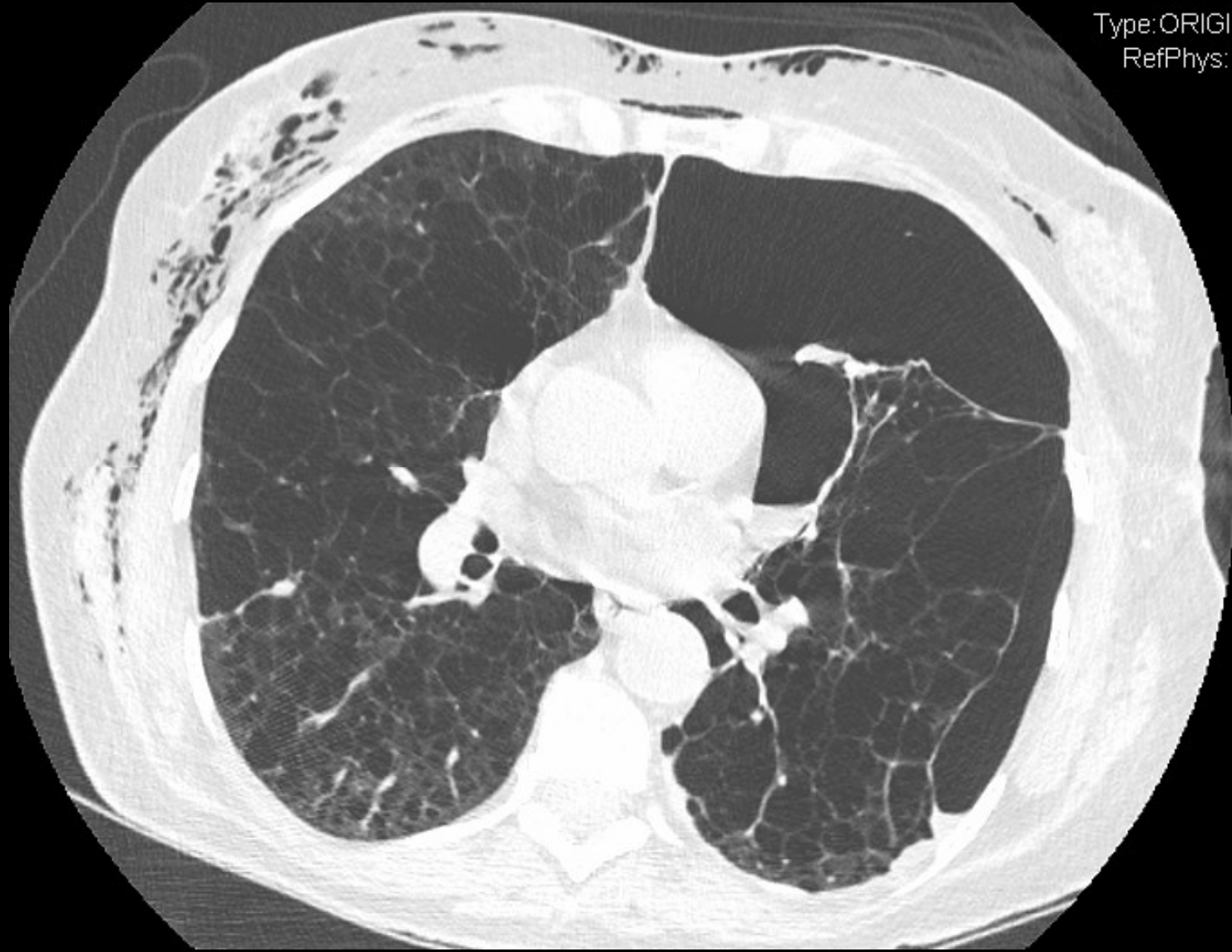


Type: ORIGINAL
RefPhys: Dr



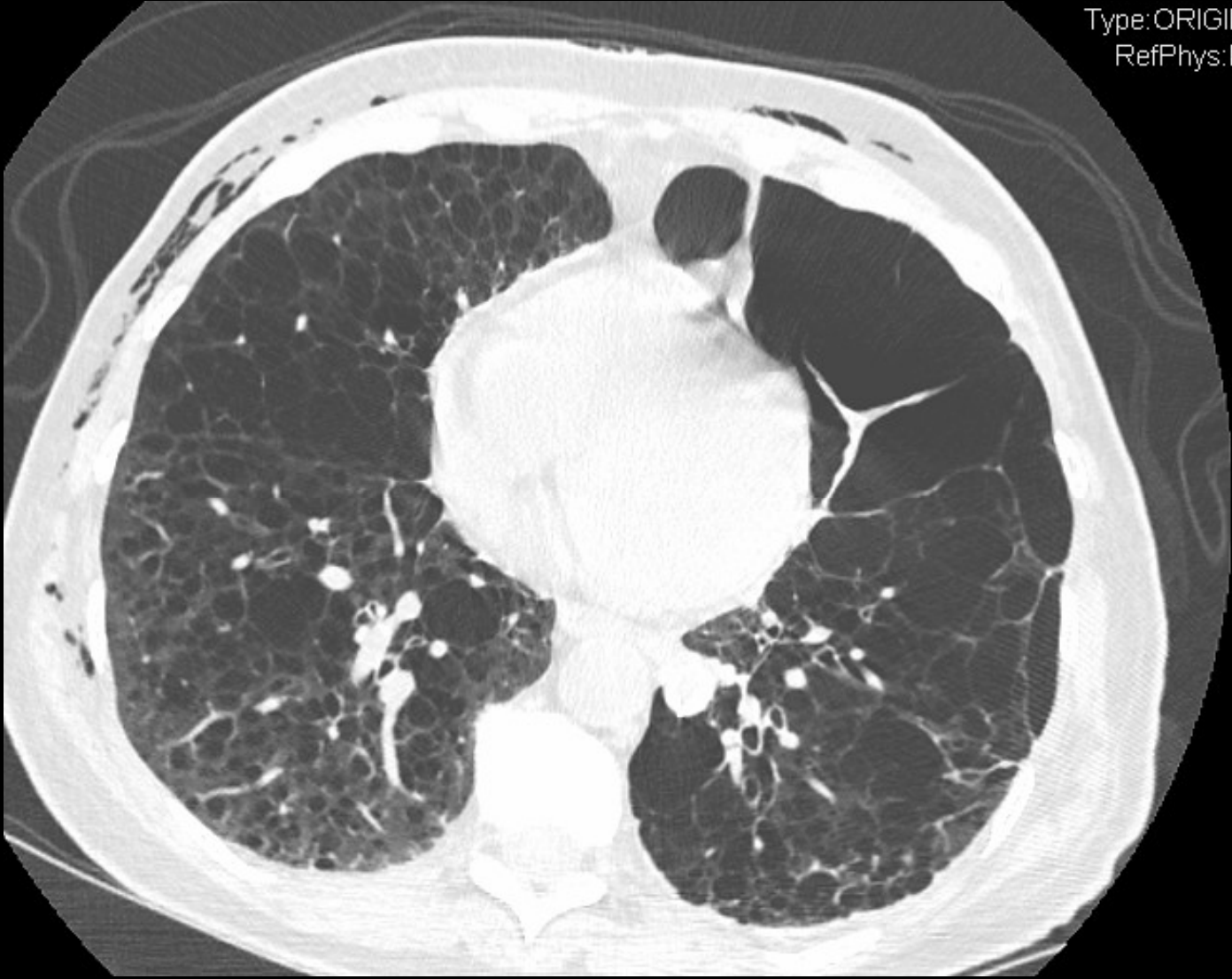

RefPhys:Dr.

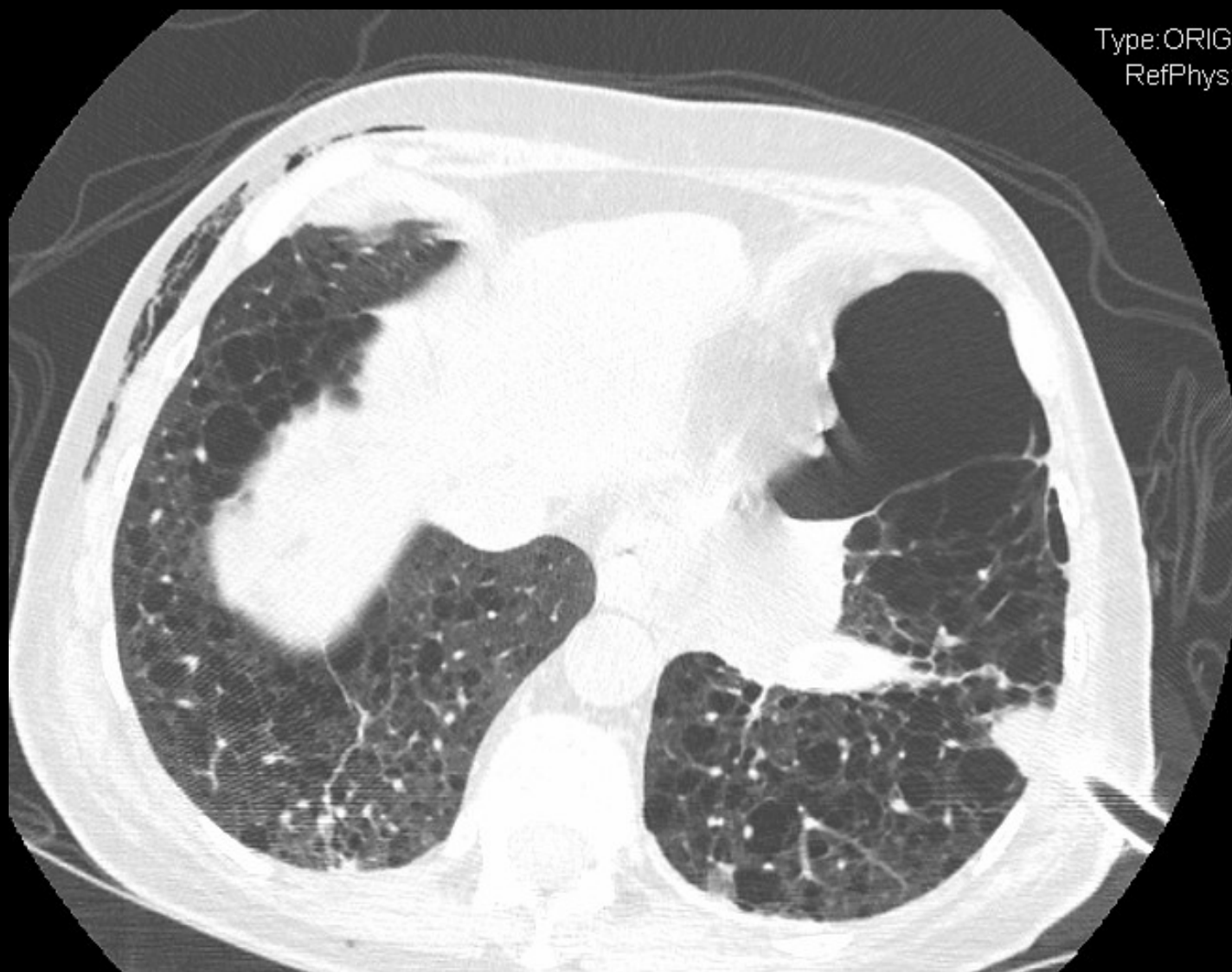


Type: ORIGINAL/
RefPhys: Dr. C

Type: ORIGIN.
RefPhys: D

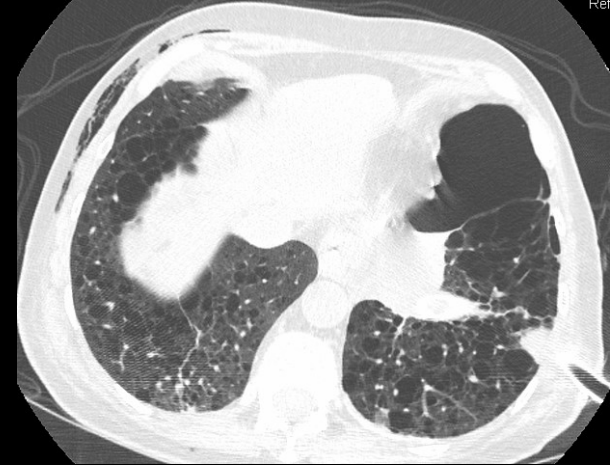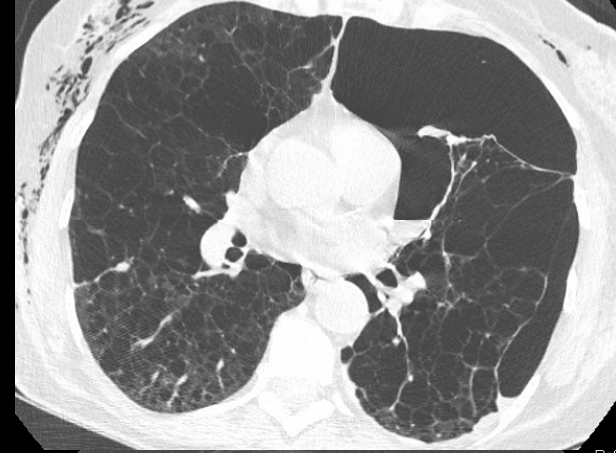

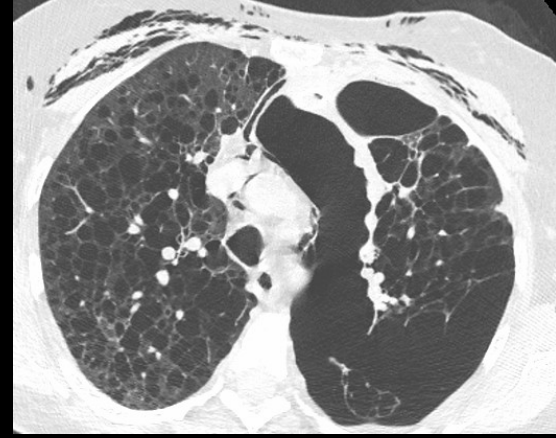
Type:ORIGIN/
RefPhys:Di

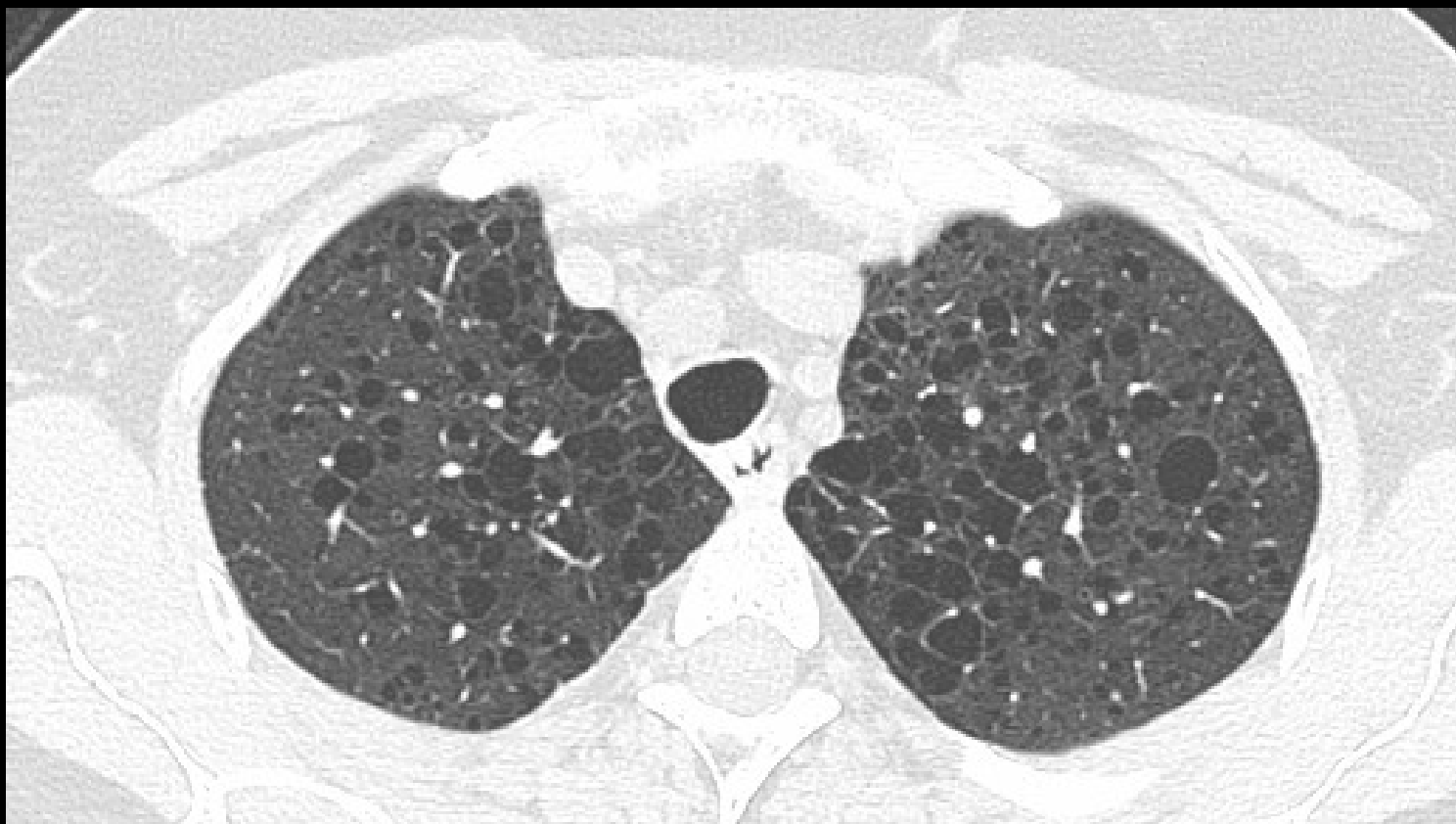


Tanınız Nedir?

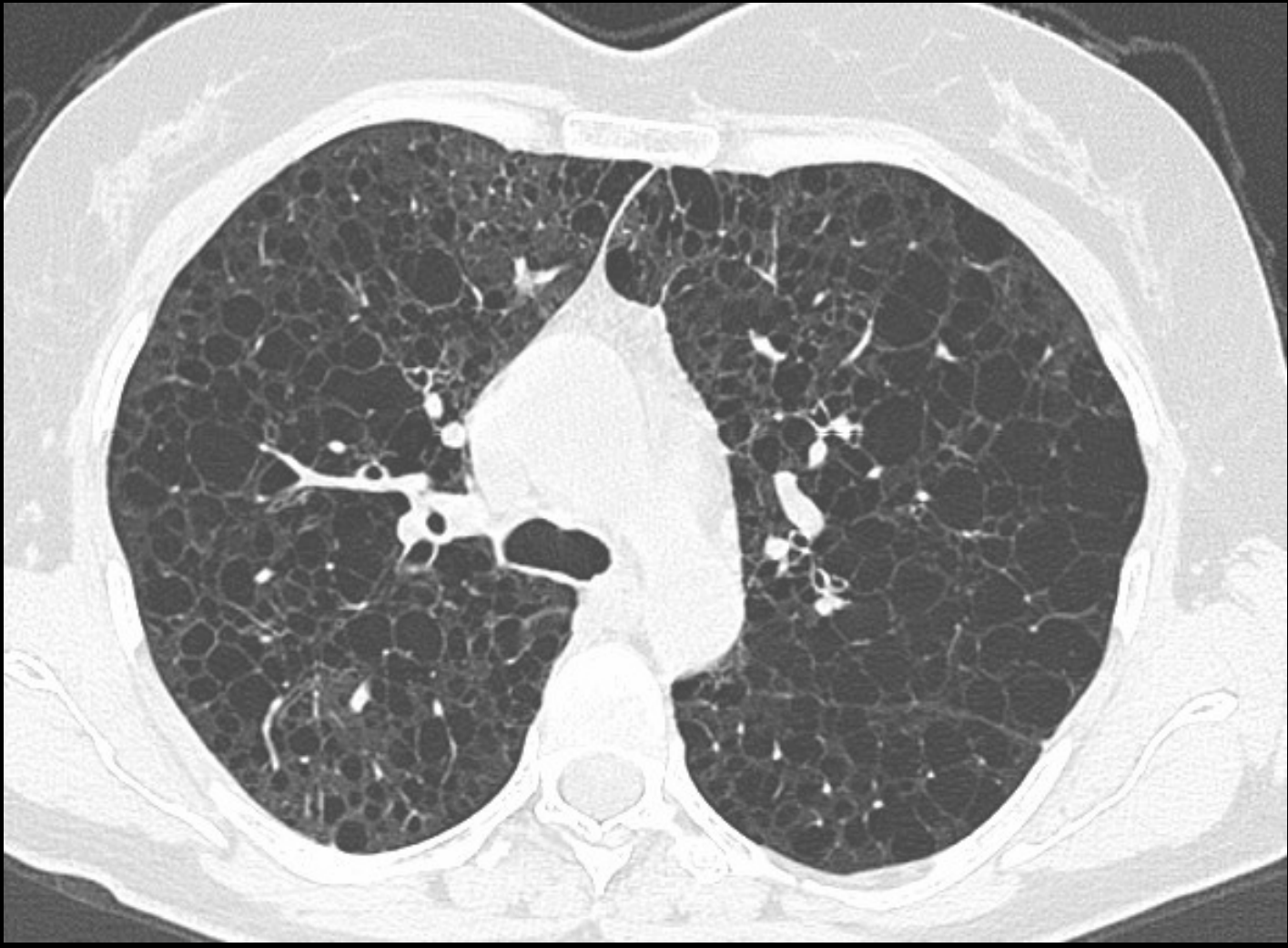
- A) Langerhans Hücreli Histiyoitozis
- B) Lenfanjiyoleyomiyomatozis
- C) Amfizem
- D) Diğer

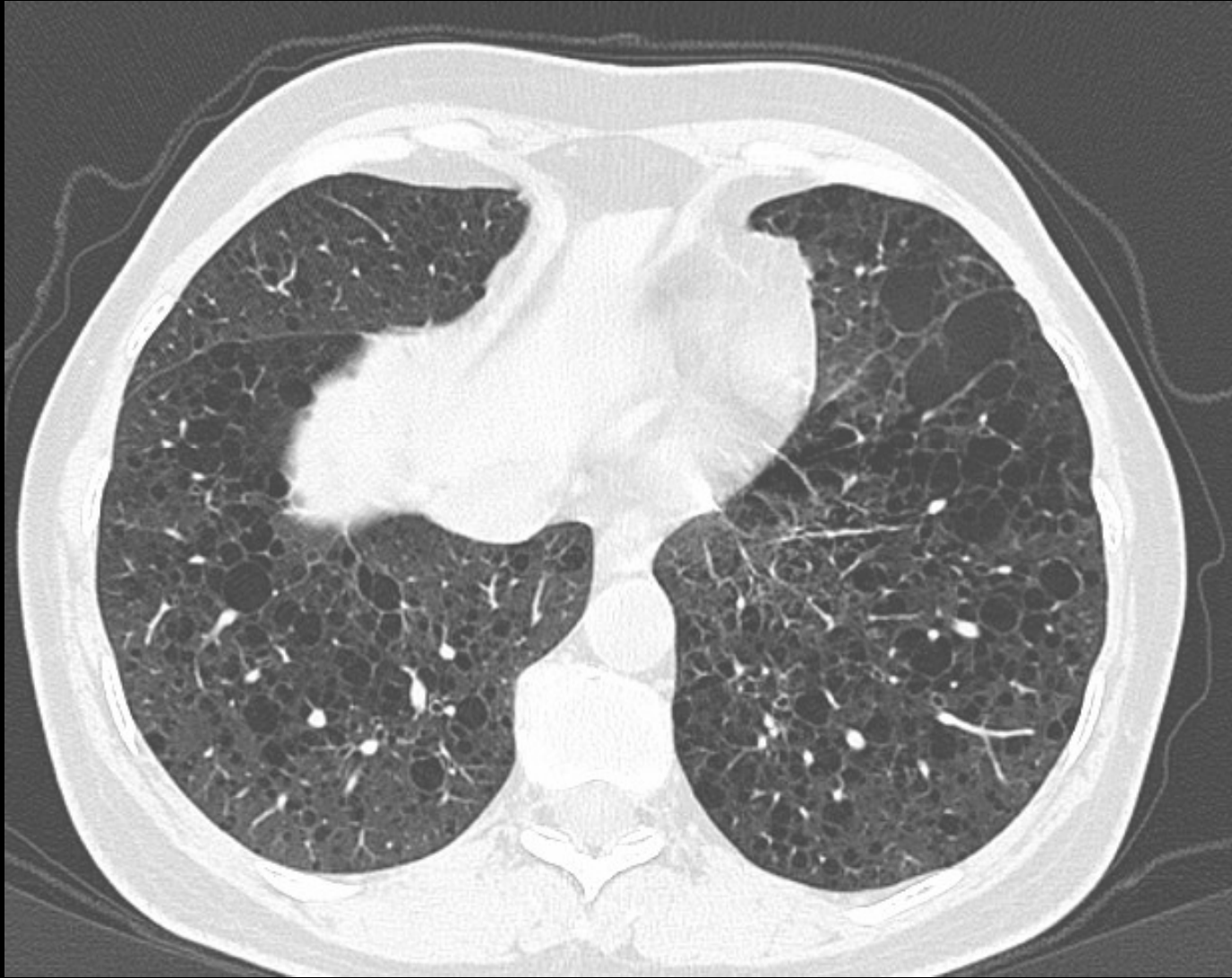


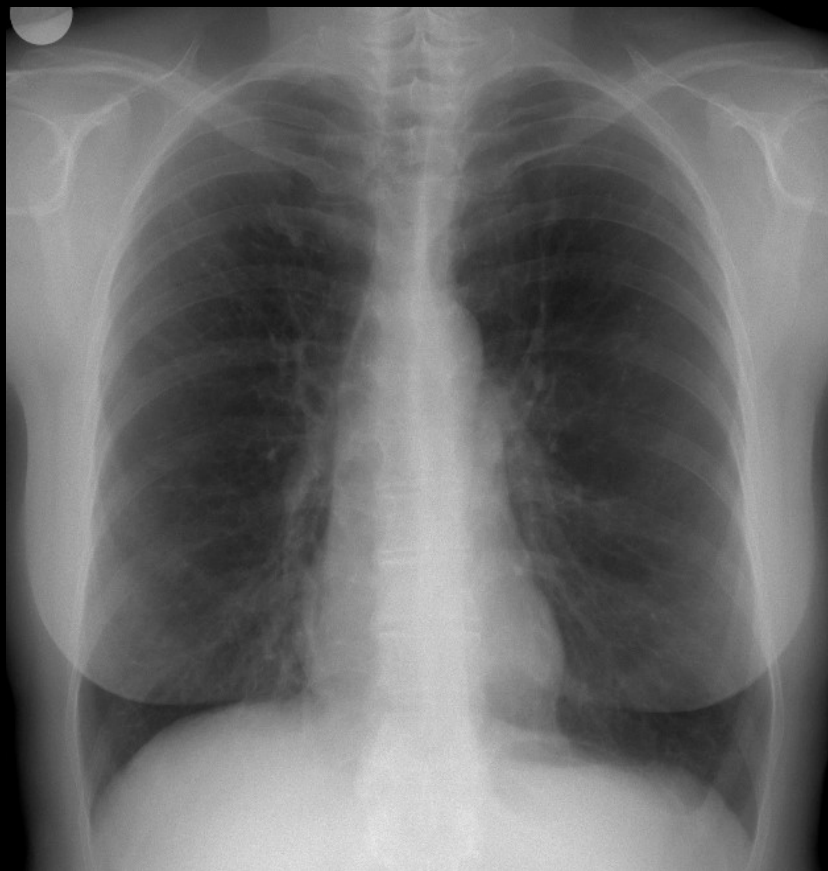
Ref



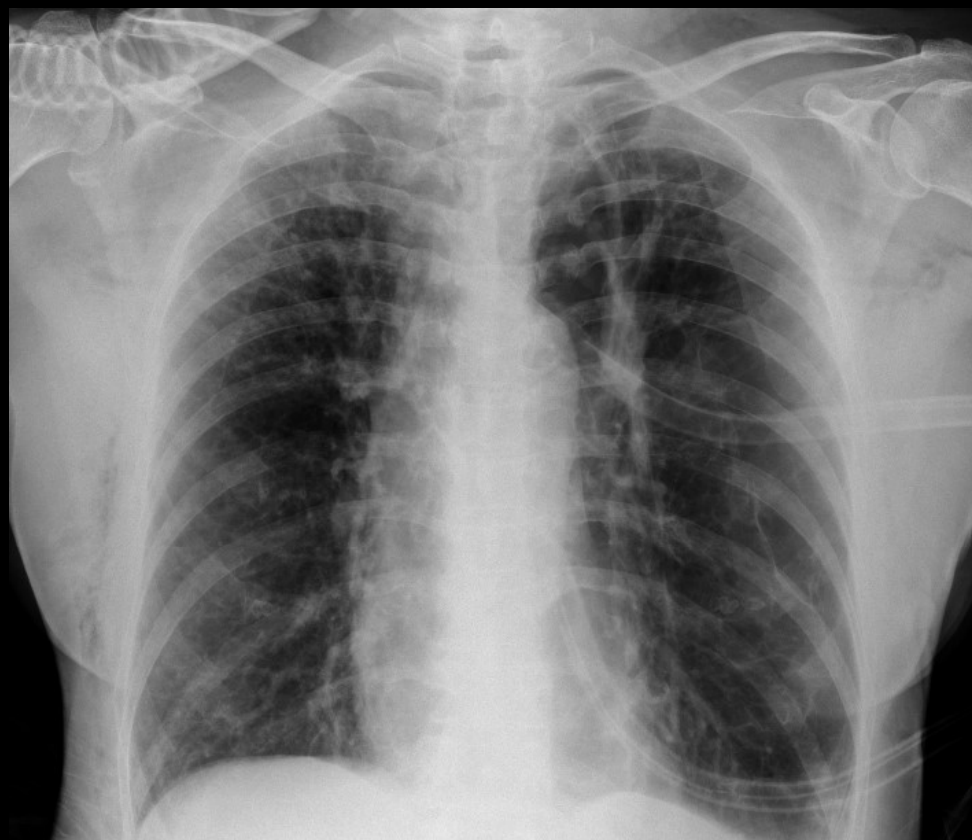
Eski BT / 2002







2002



2015

Lenfanjiyoleyomyomatosis

- Alveoler düz kas hücrelerinin proliferasyonu ve akciğer parankimindeki kistik değişiklikler ile karakterize nadir, multisistemik tutulumu neden olan hastalık
- Doğurganlık çağındaki kadınlar

- Akciğer:

- İnce duvarlı kistler
- Şilotoraks
- Pnömotoraks

- Pulmoner hemoraji

- Renal anjiyomyolipomlar

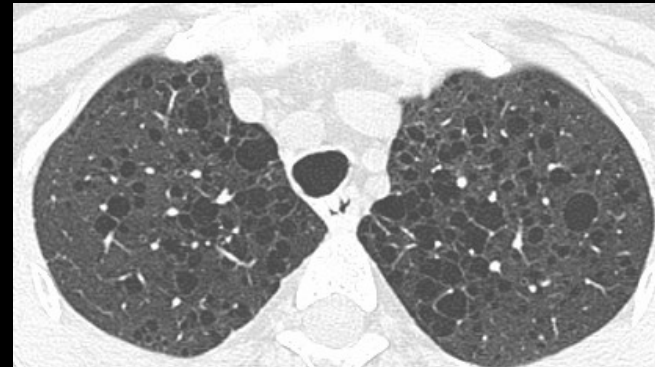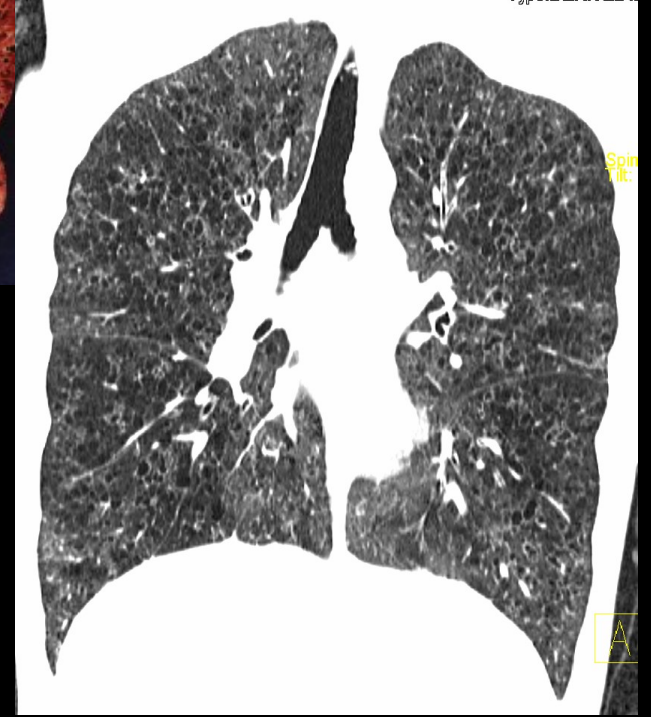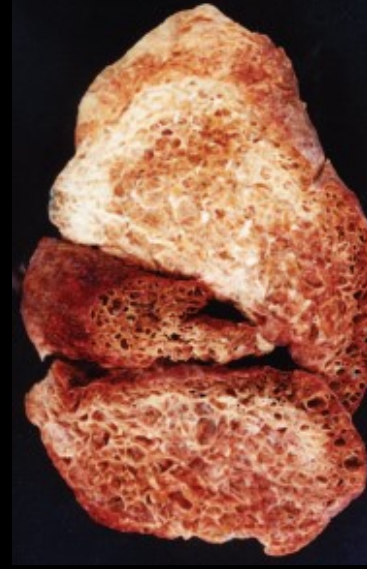
- Lenfanjiyoleyomiyomlar

- Abdominal LAP

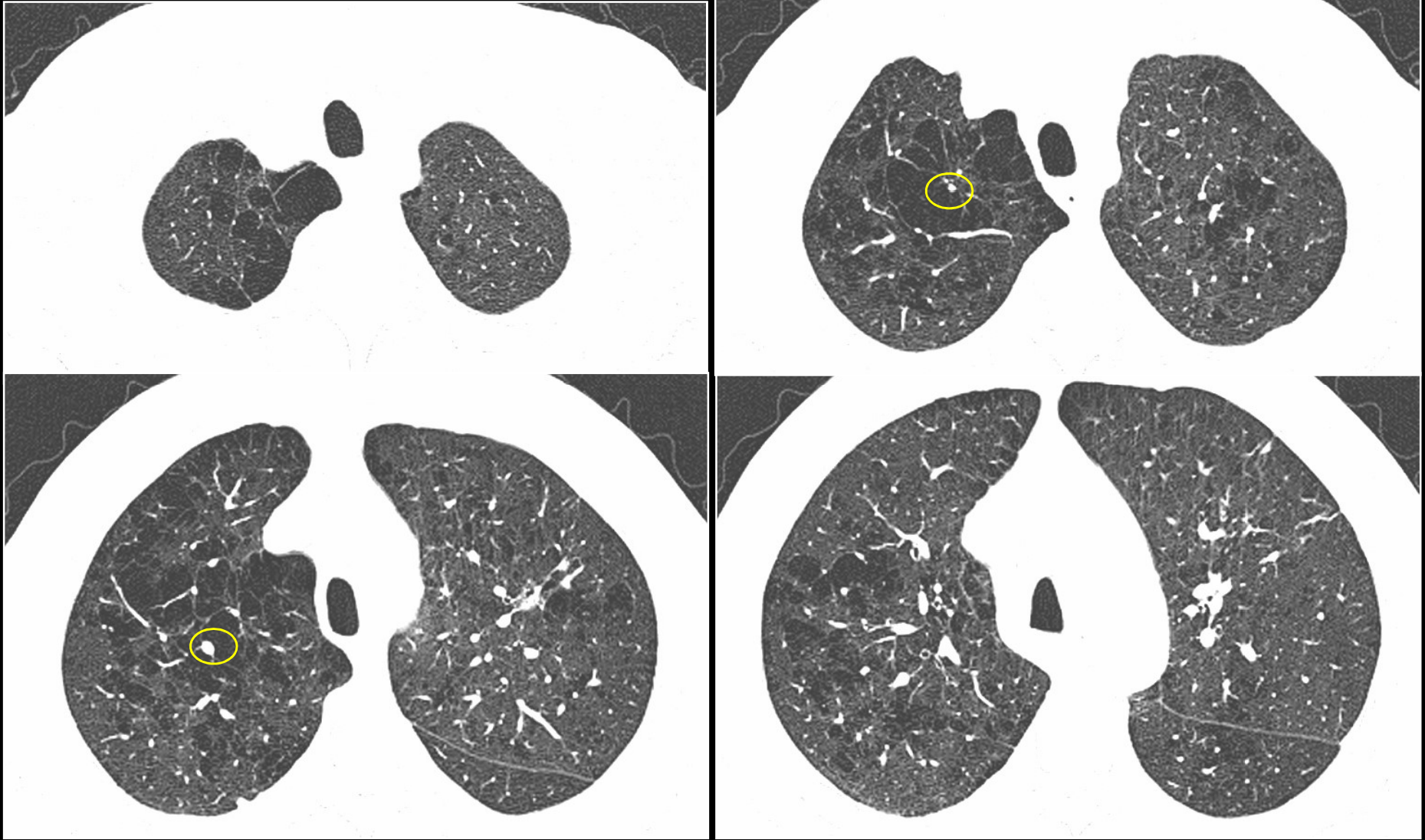
- Dalakta kistler

- Şiloz asit

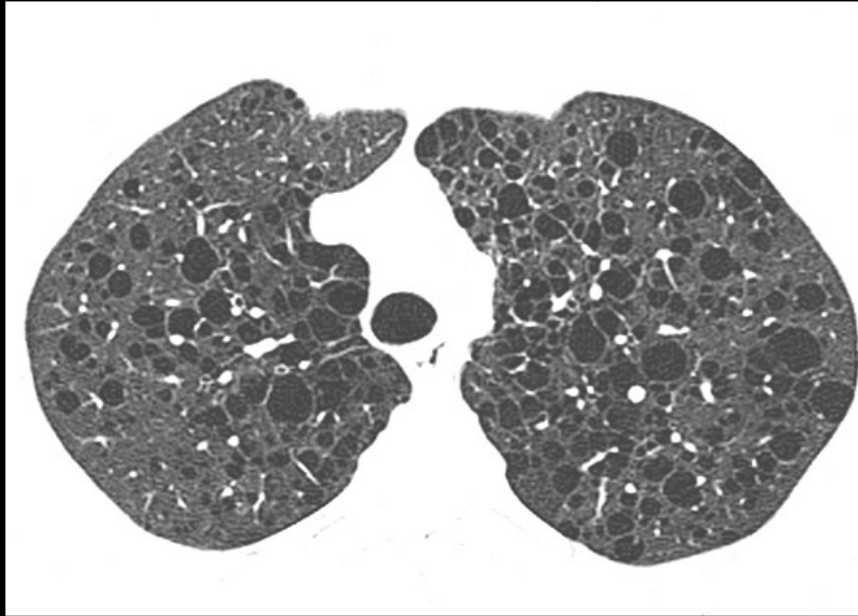
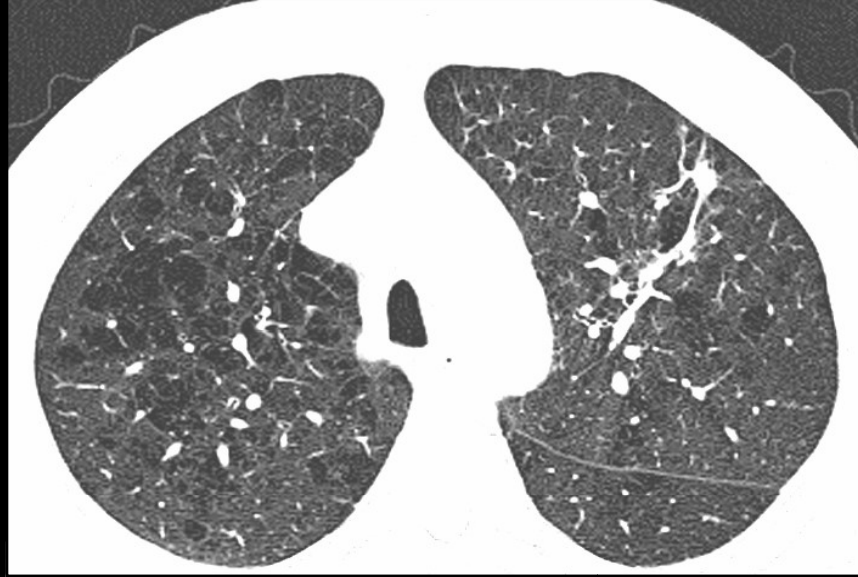
- Uterin myomlar



Ayırıcı Tanı 1: Amfizem



Amfizem / Hava kisti?

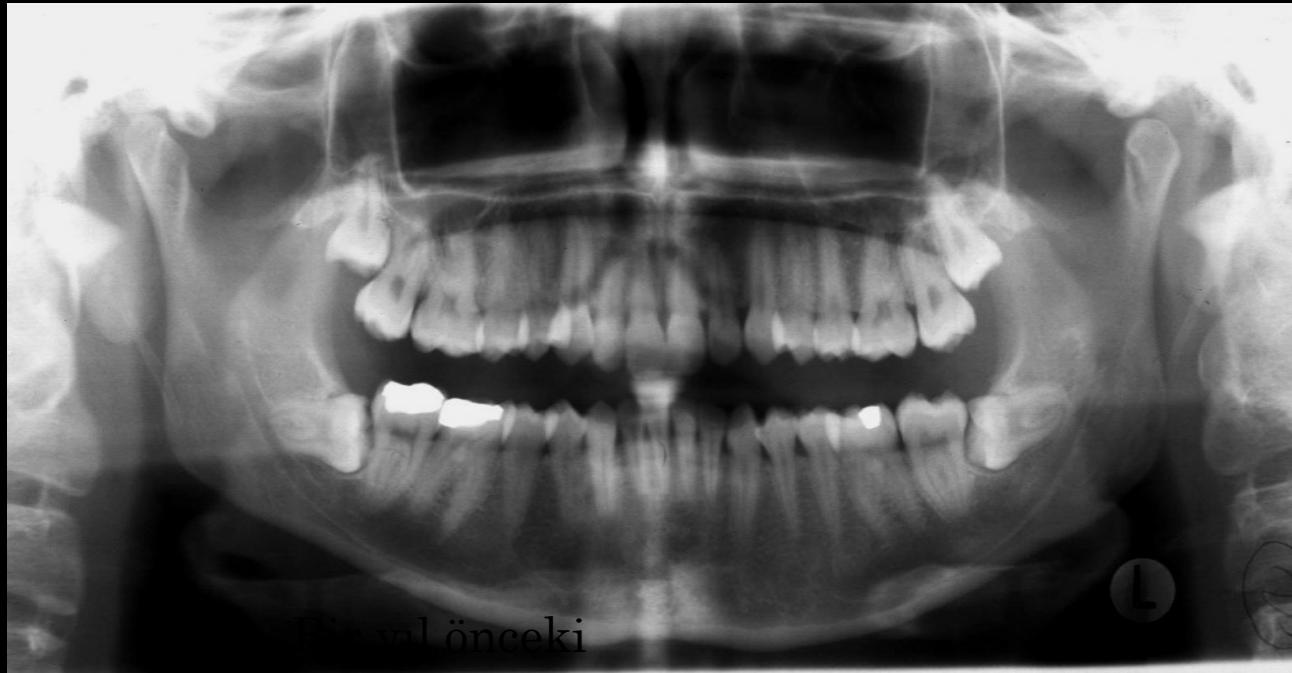

OLGU 6

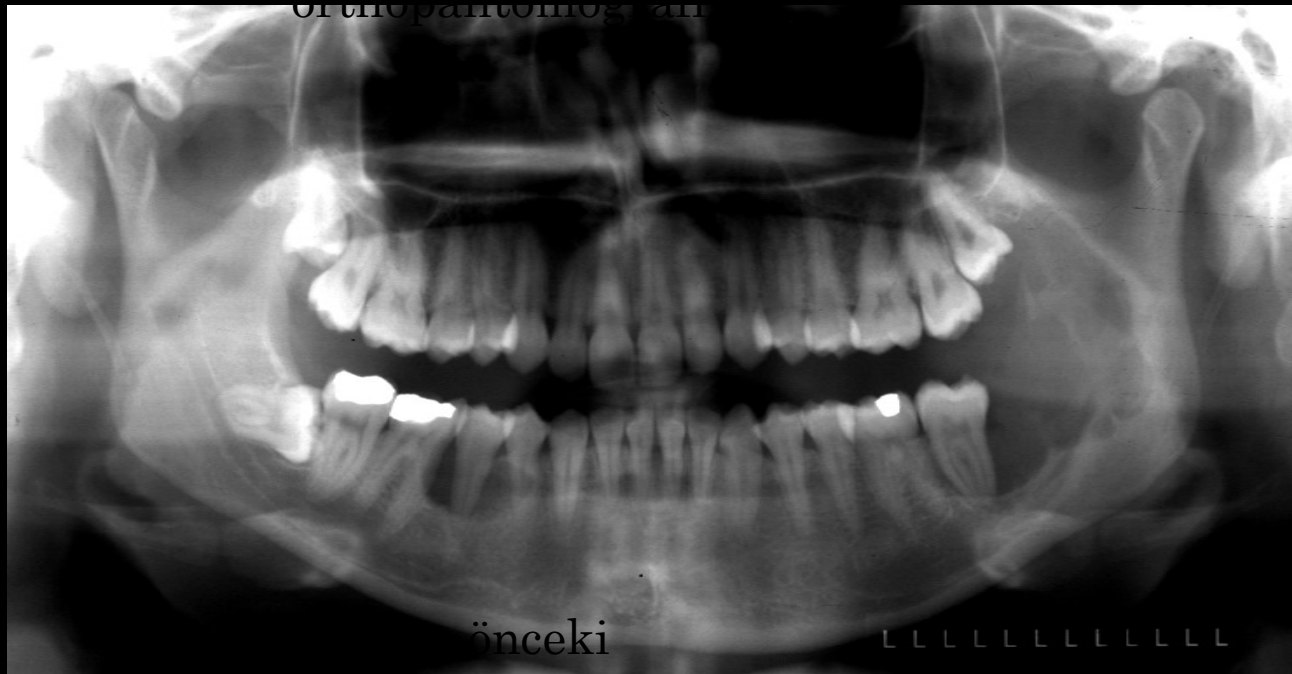21 yaşında kadın hasta

İki aydan beri devam eden, 20'lik diş çekiminden sonra ortaya çıkan abse ve

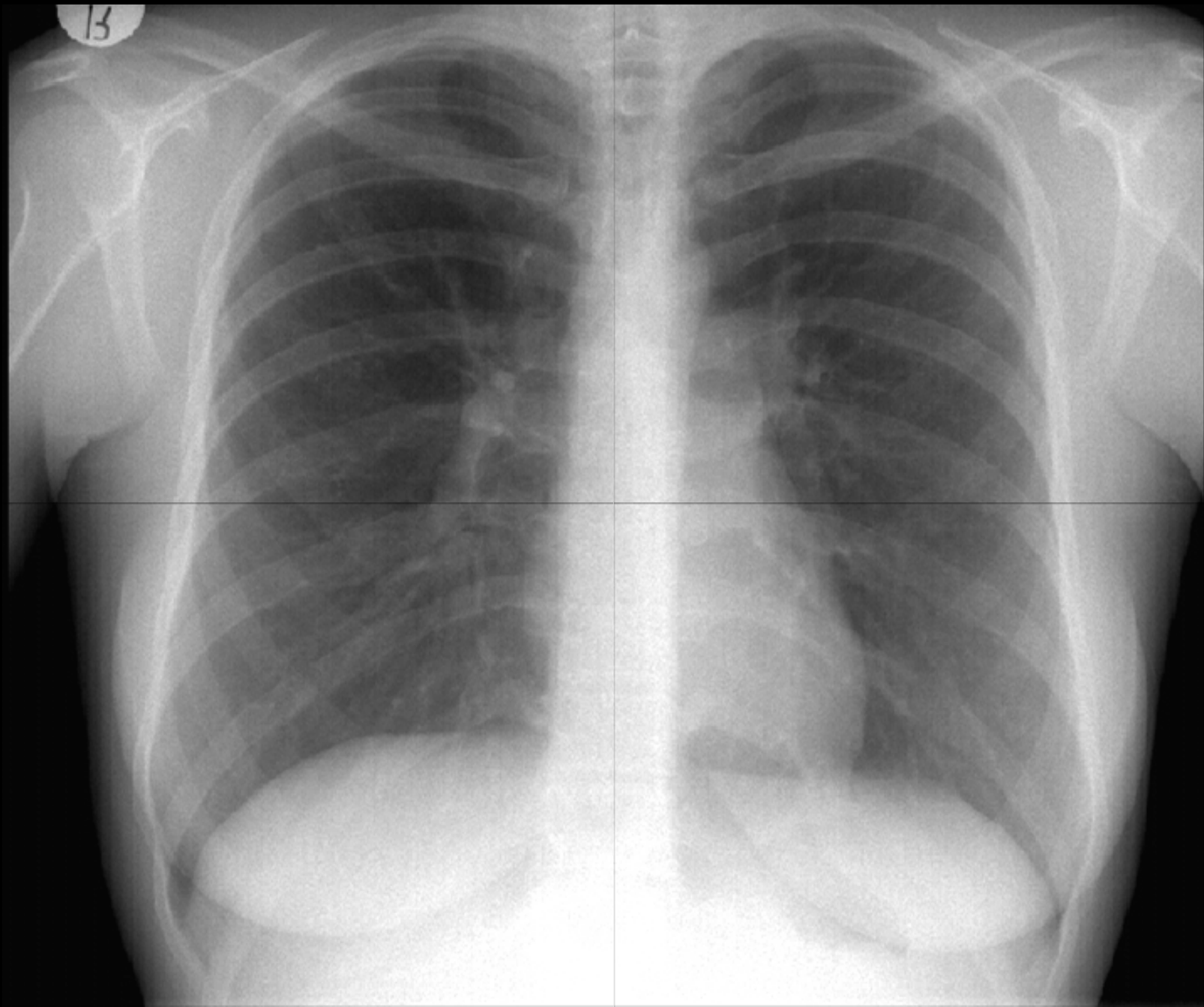
Nefes darlığı nedeniyle doktora başvuruyor

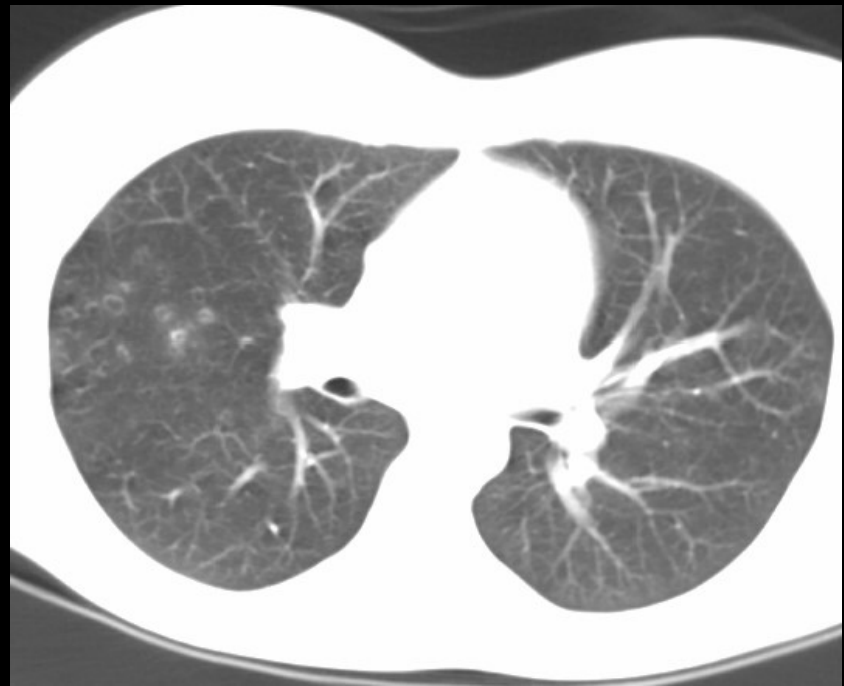
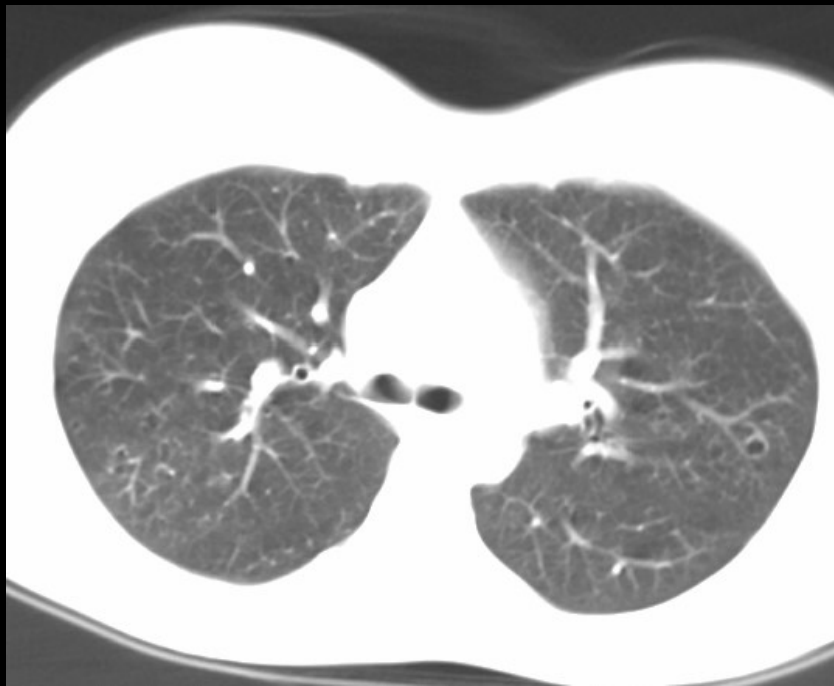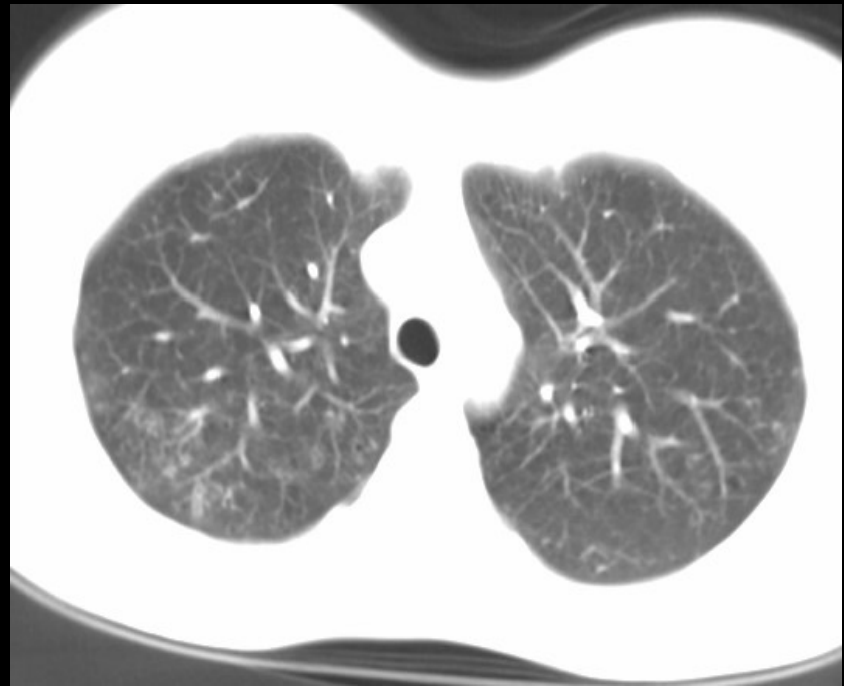
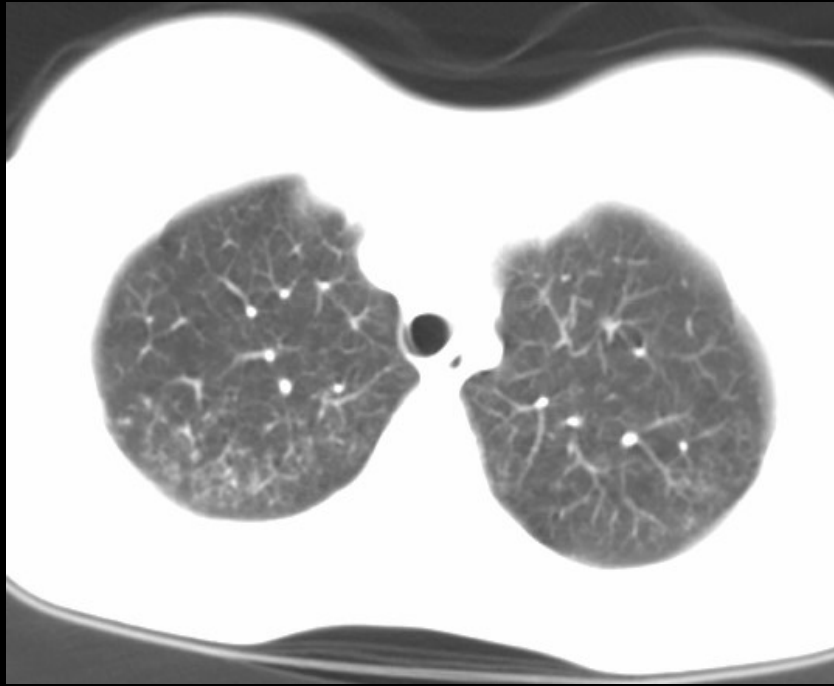


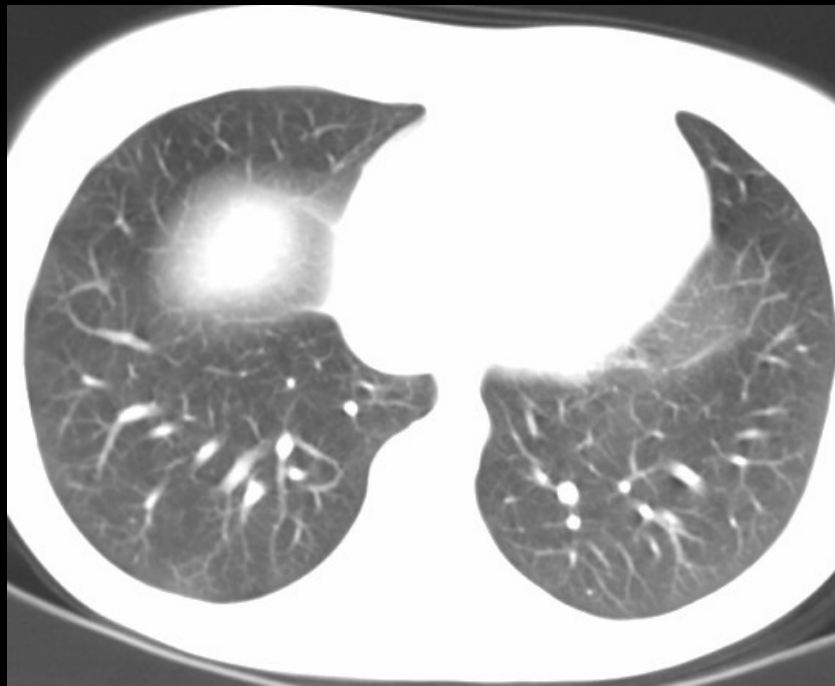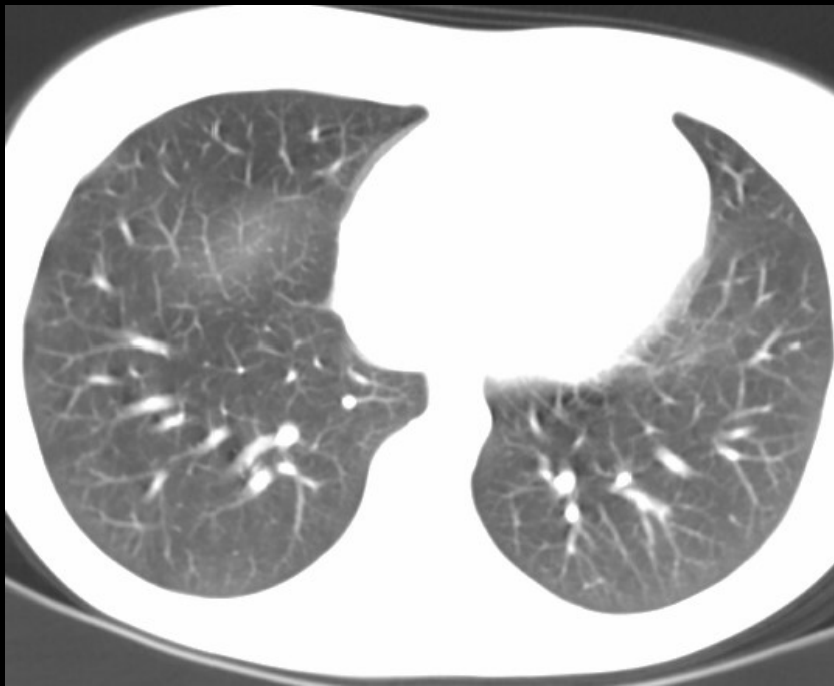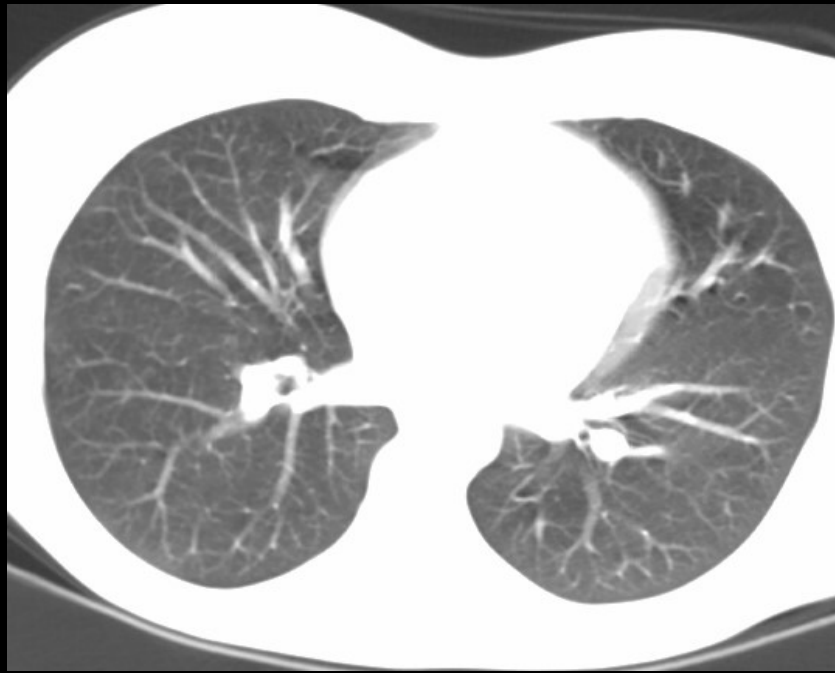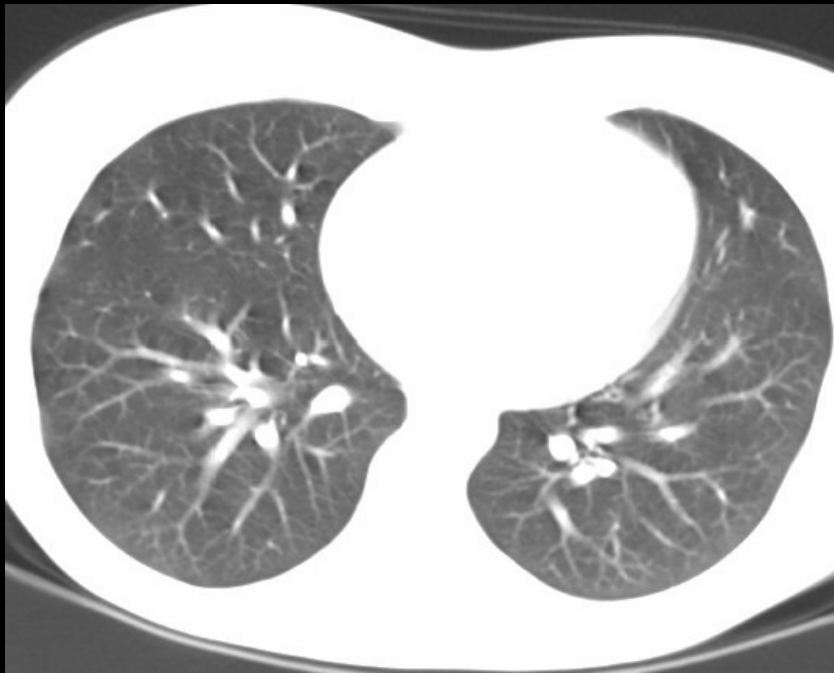Dişsiz önceki
Orthopantomogram

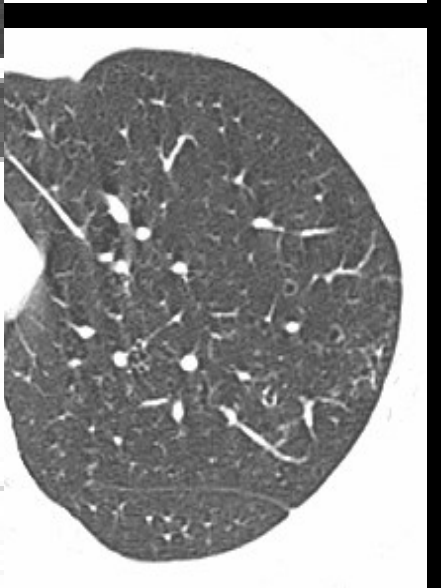
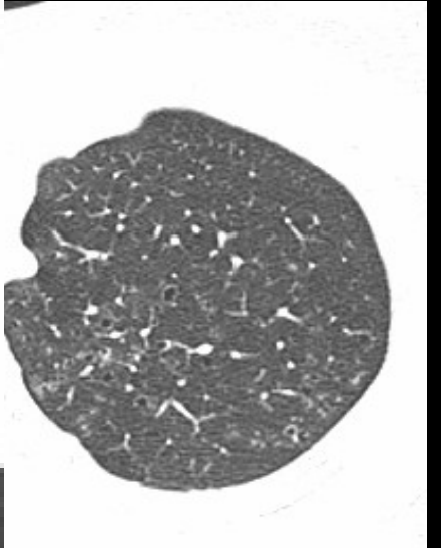
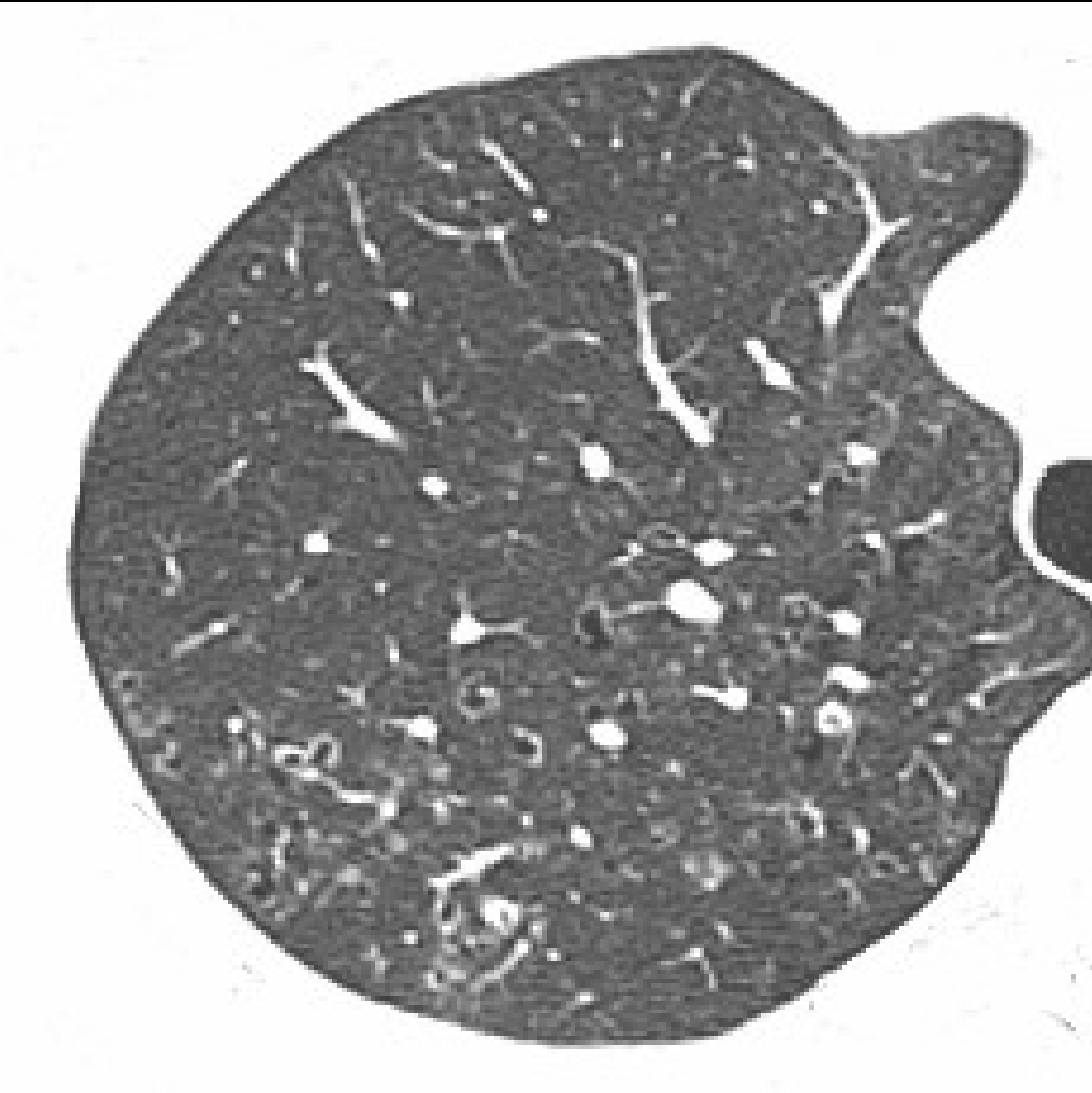
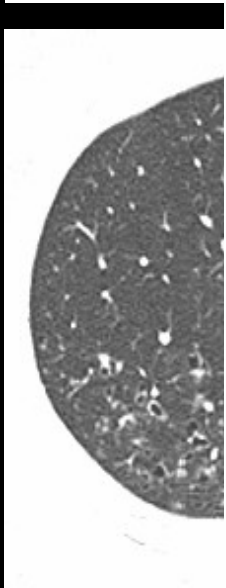
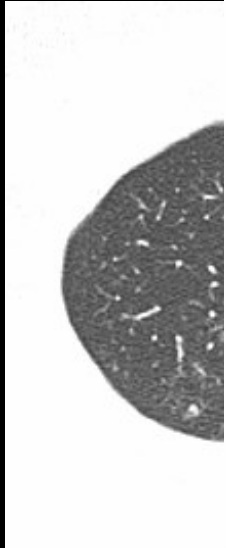

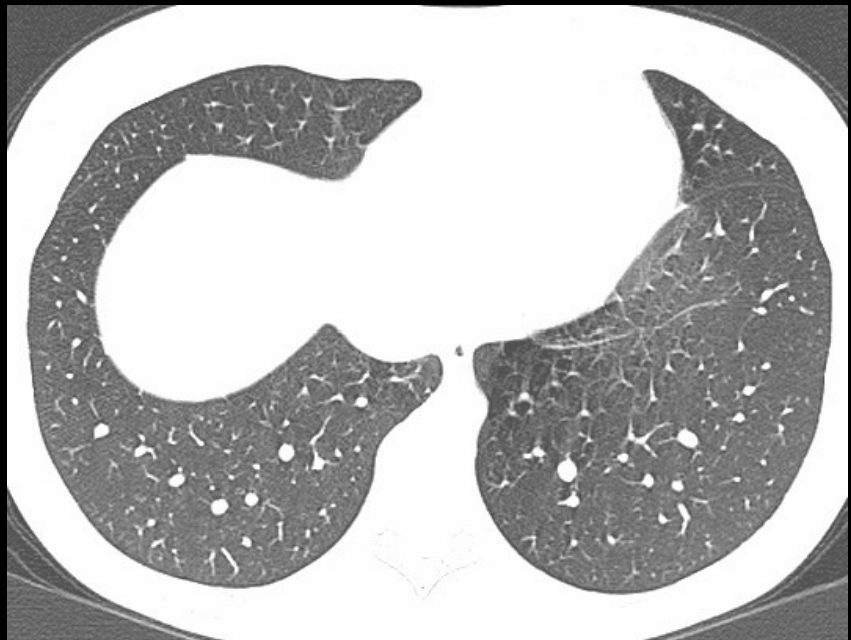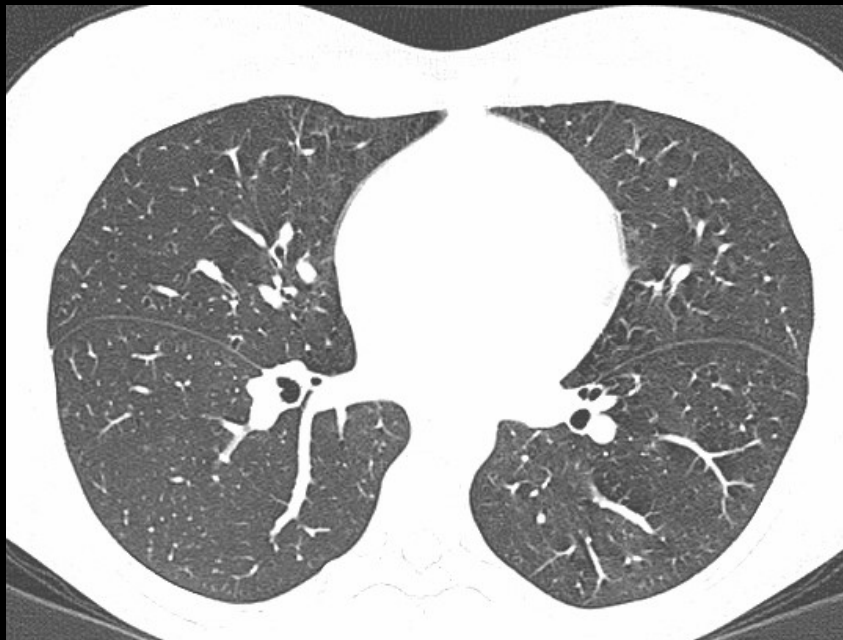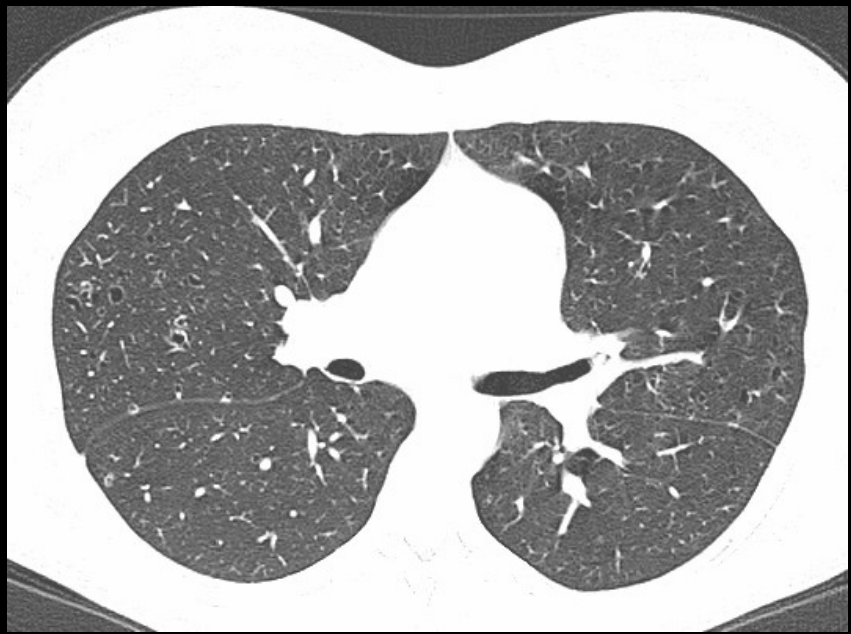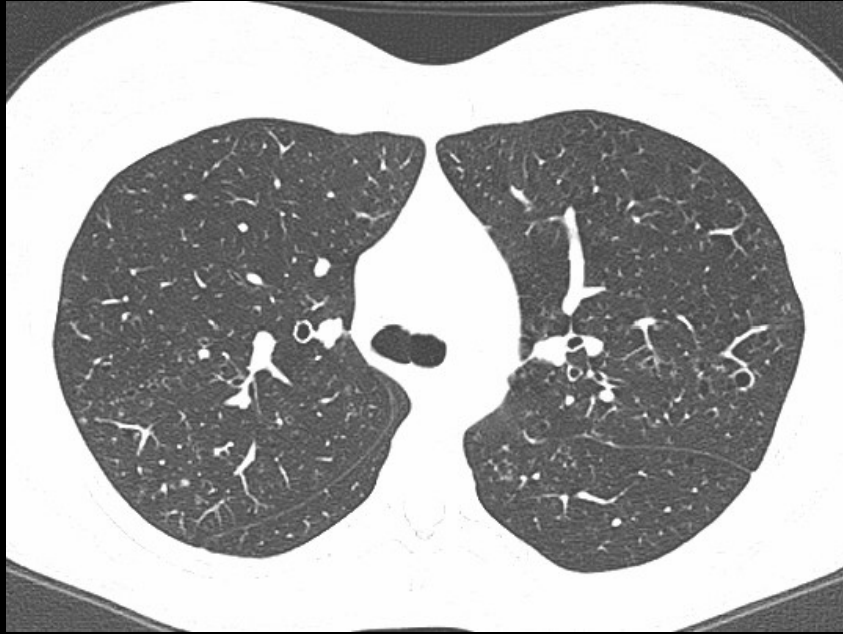önceki
LLLLLLLLLLLLLLLL











Langerhans Hücreli Histiyozyozis (LHH)

Erken dönemde → nodüler patern

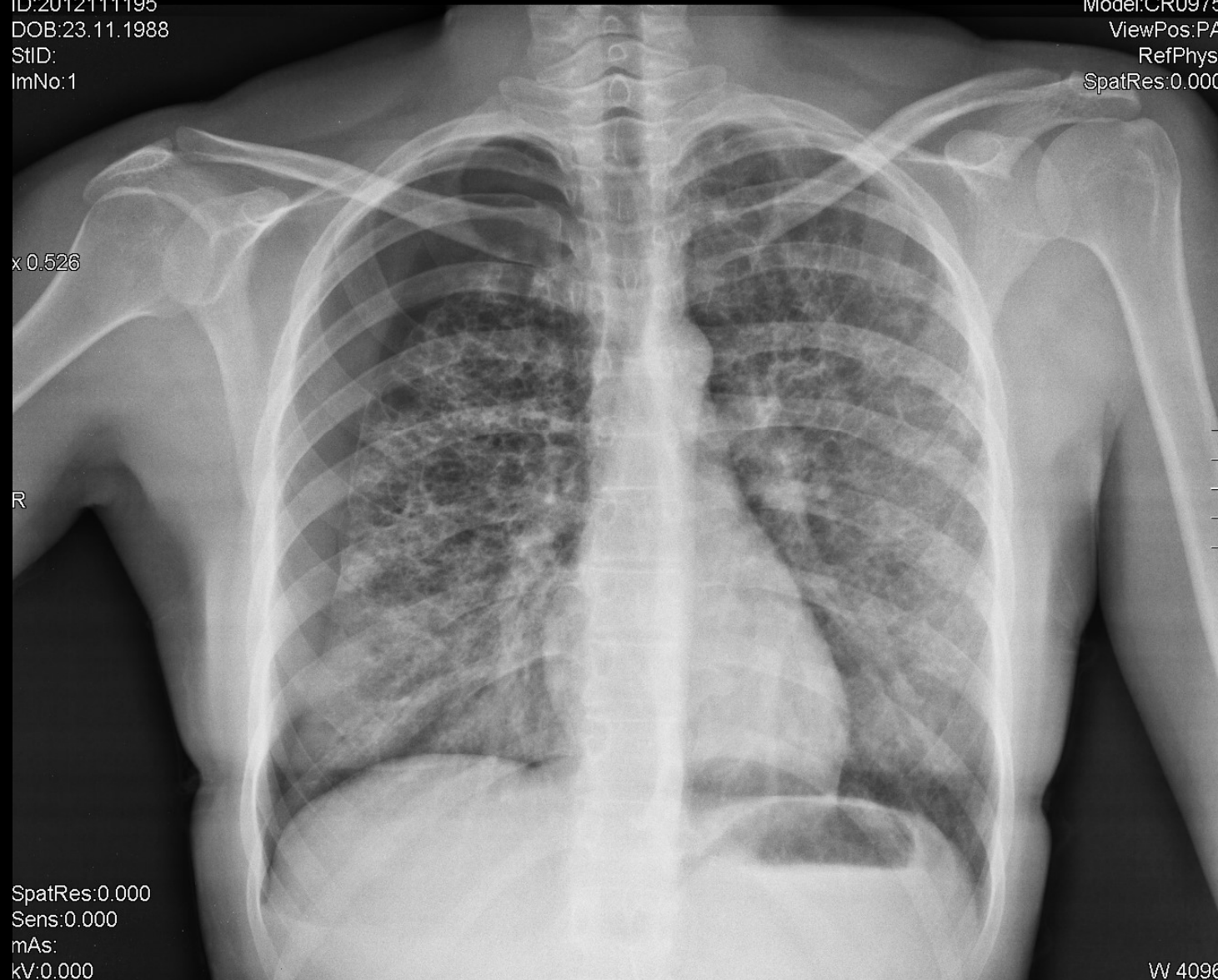İleri dönemde → retikülonodüler patern

BT'de ileri dönemde kistler → yuvarlak, oval veya şekilsiz. Balpeteği şeklinde kistik görünüm.

Kostofrenik açılar korunmuş ve üst - orta zonda daha yaygın.

ID:2012111195
DOB:23.11.1988
StID:
ImNo:1

Model:CR0975
ViewPos:PA
RefPhys:
SpatRes:0.000

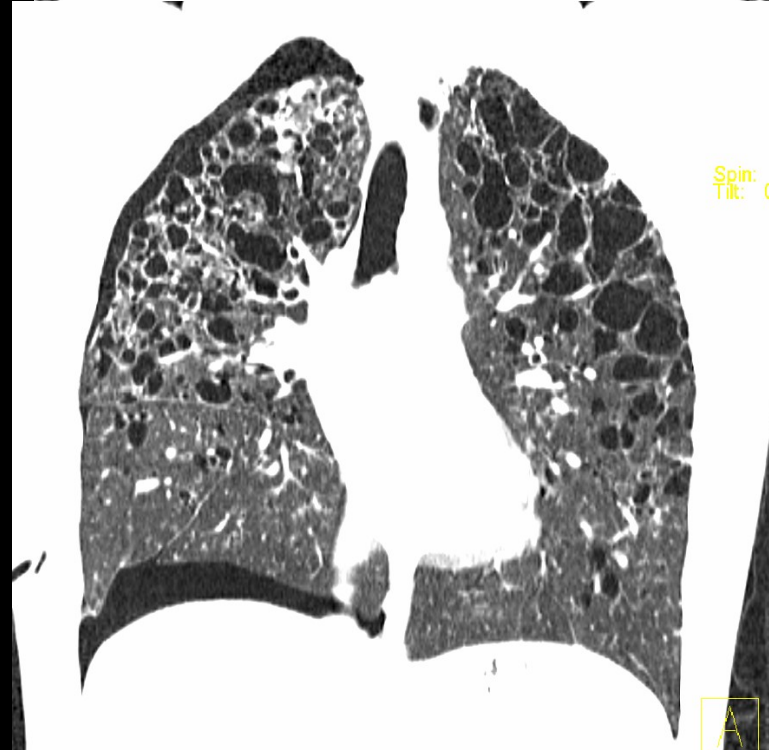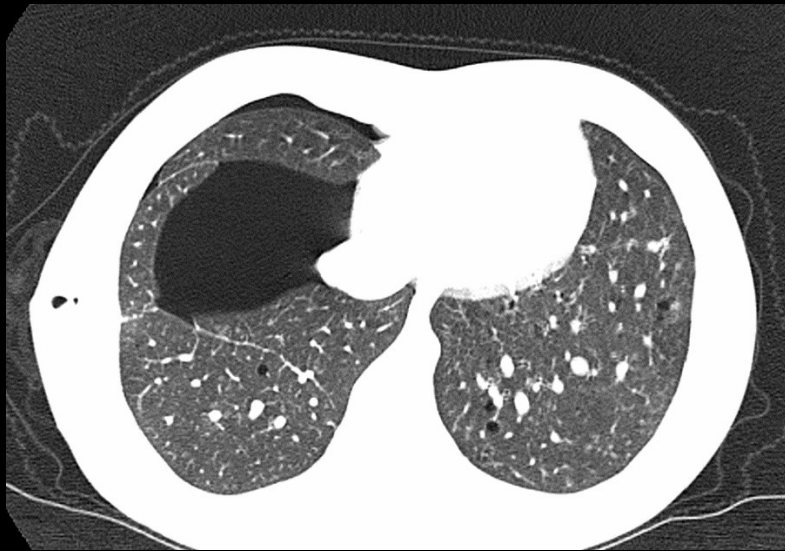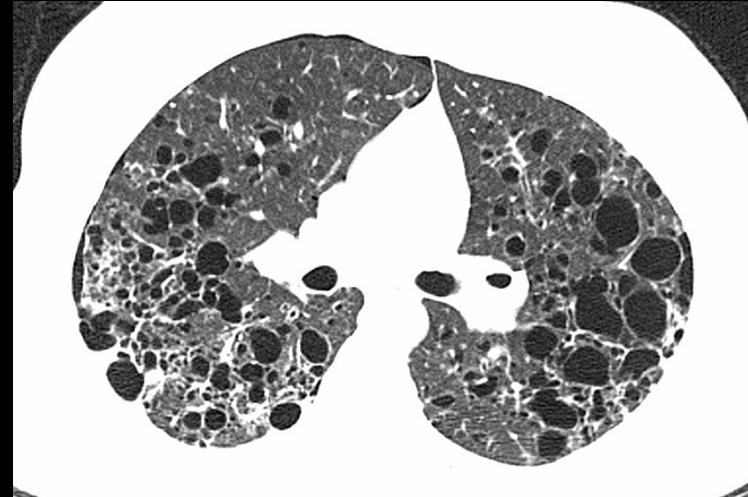
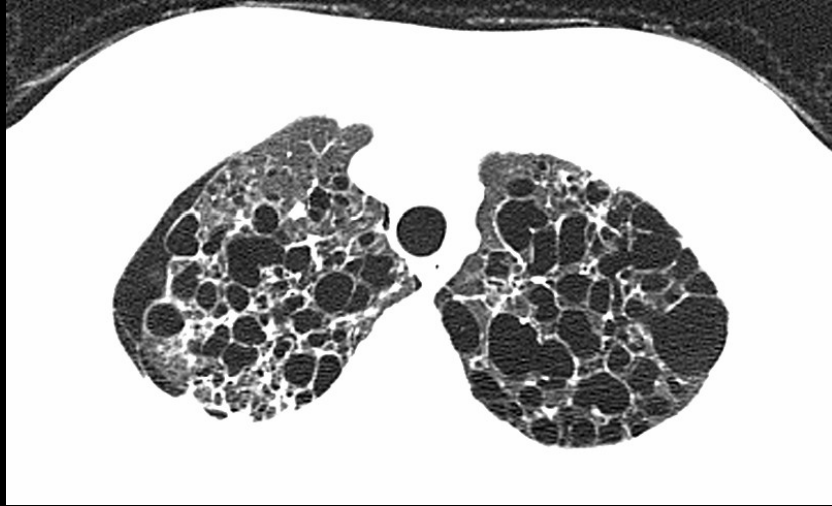


x 0.526

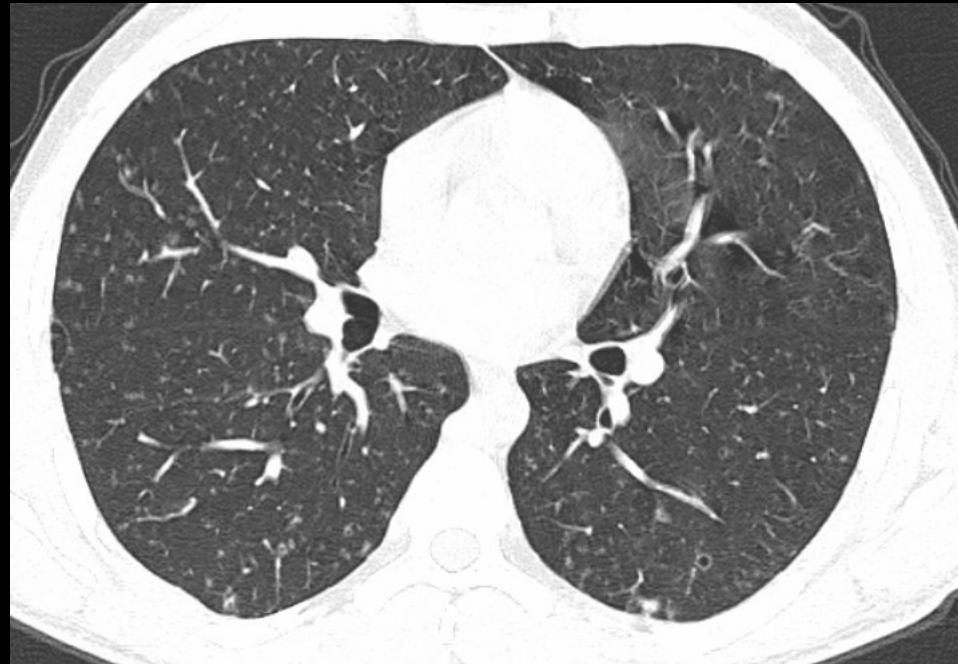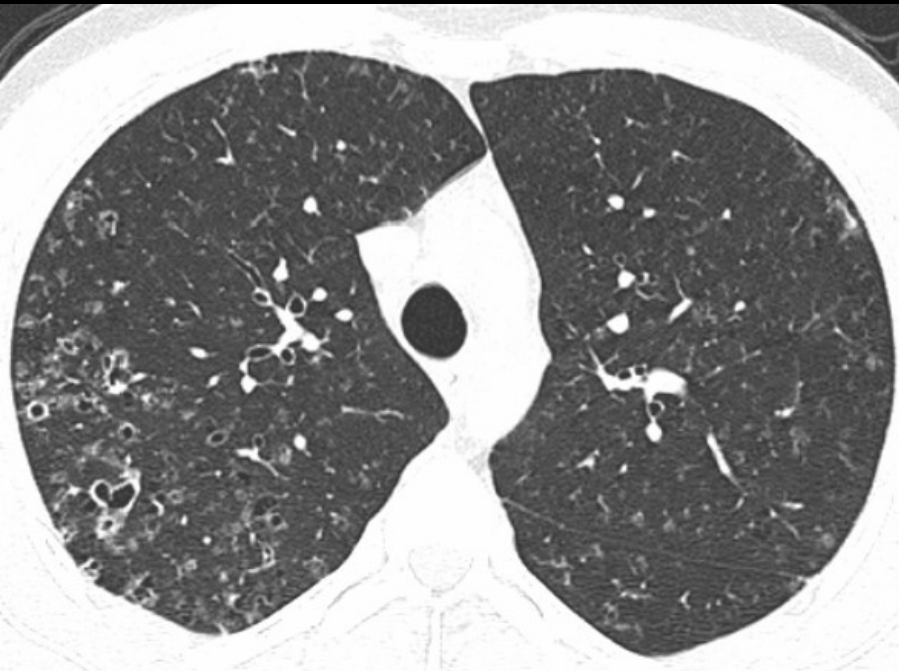
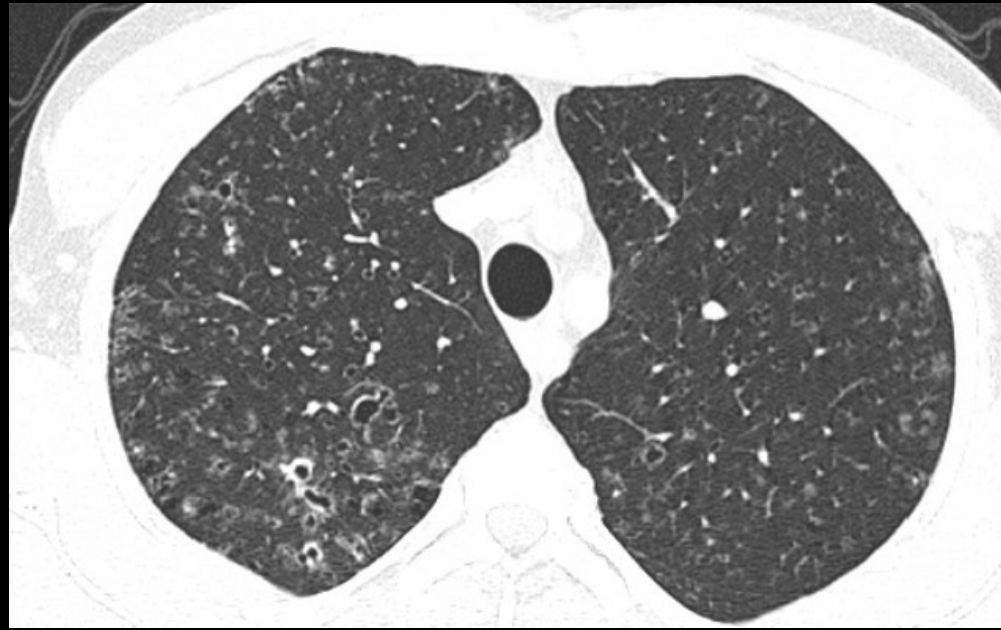
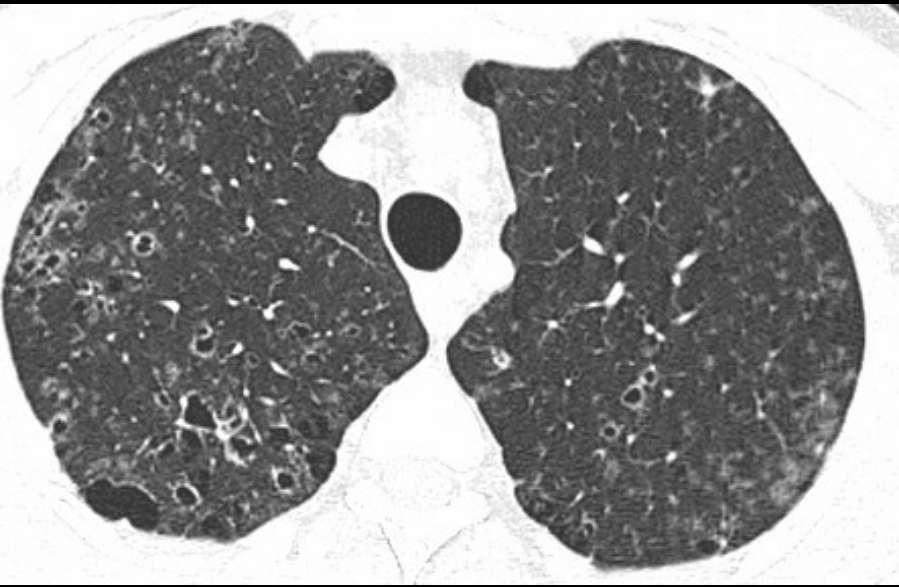
R

SpatRes:0.000
Sens:0.000
mAs:
kV:0.000
Protocol:

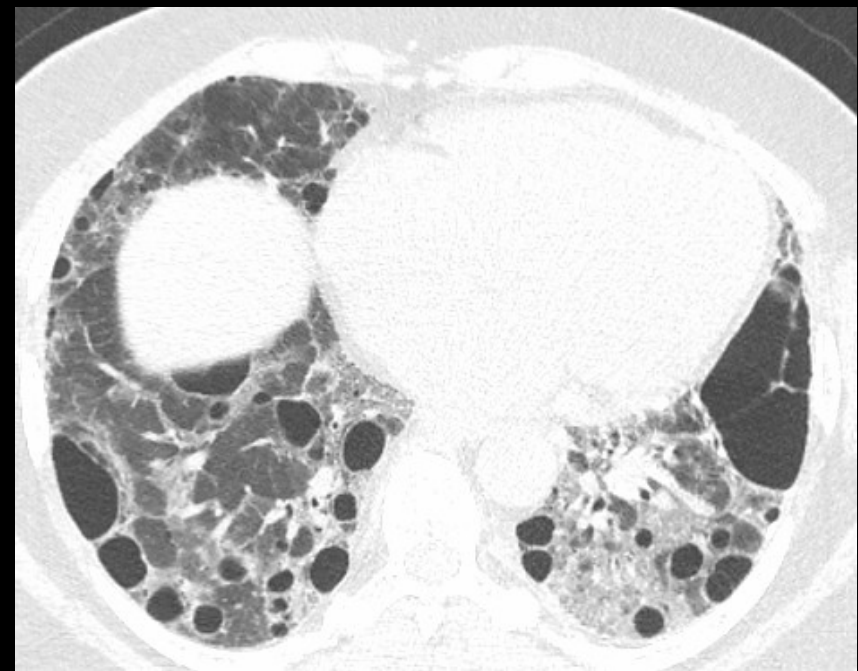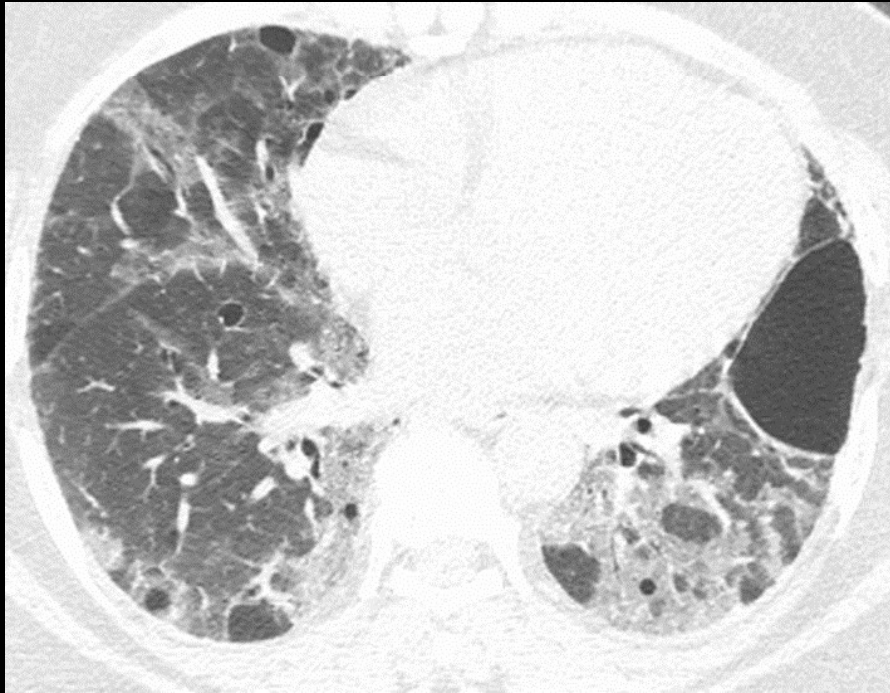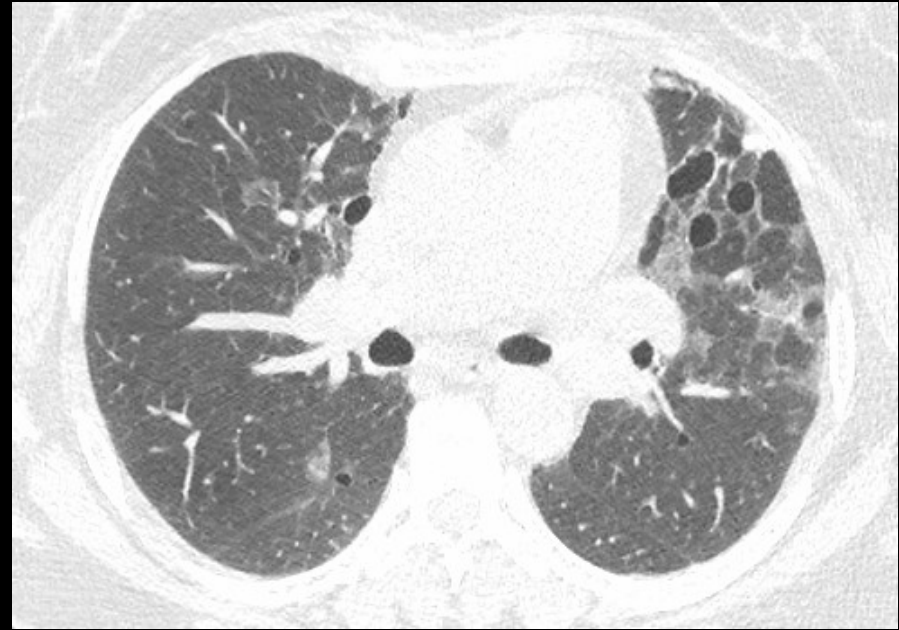
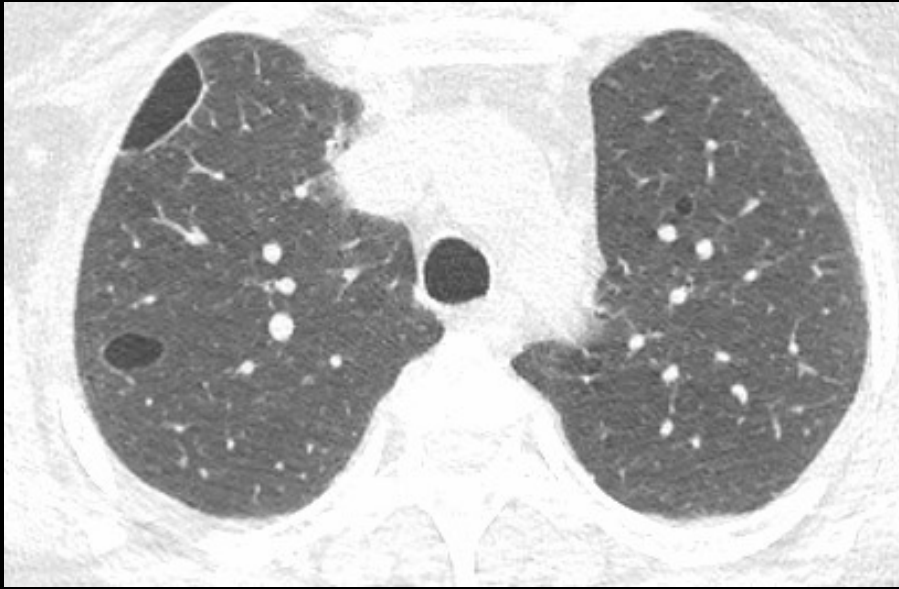W 4096
C 2048



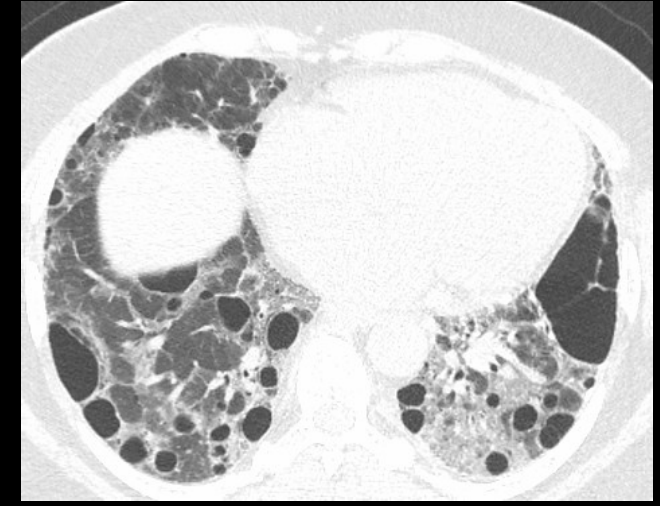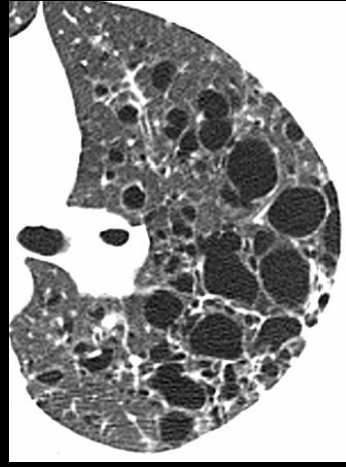
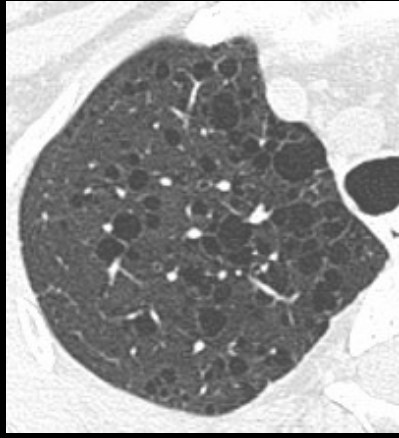
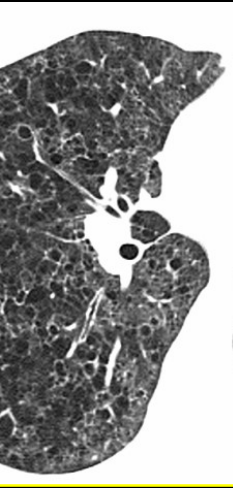
Langerhans Hücreli Histiyositozis



LHH



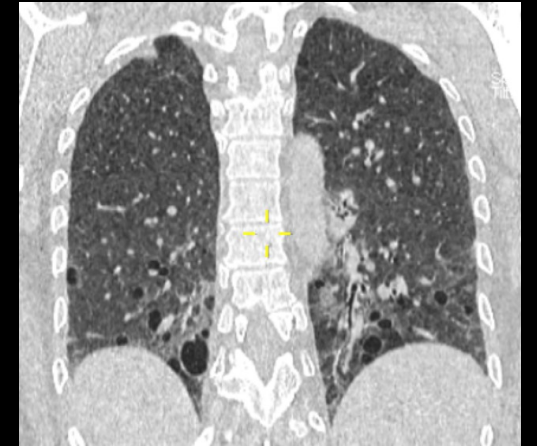
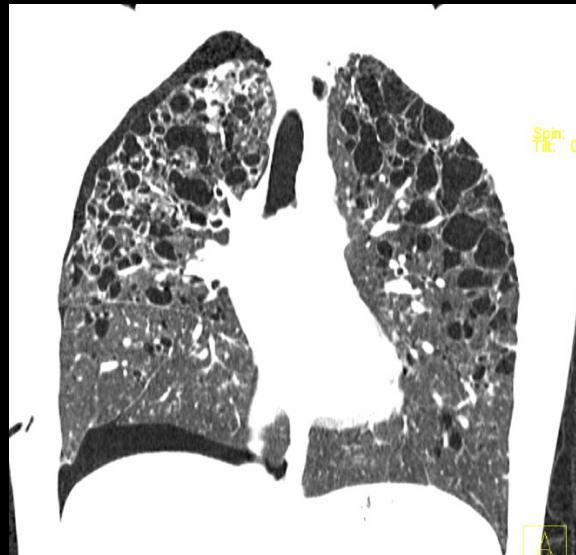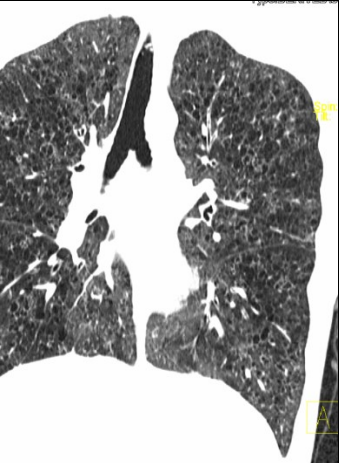
Lenfositik İntertisyel Pnömoni



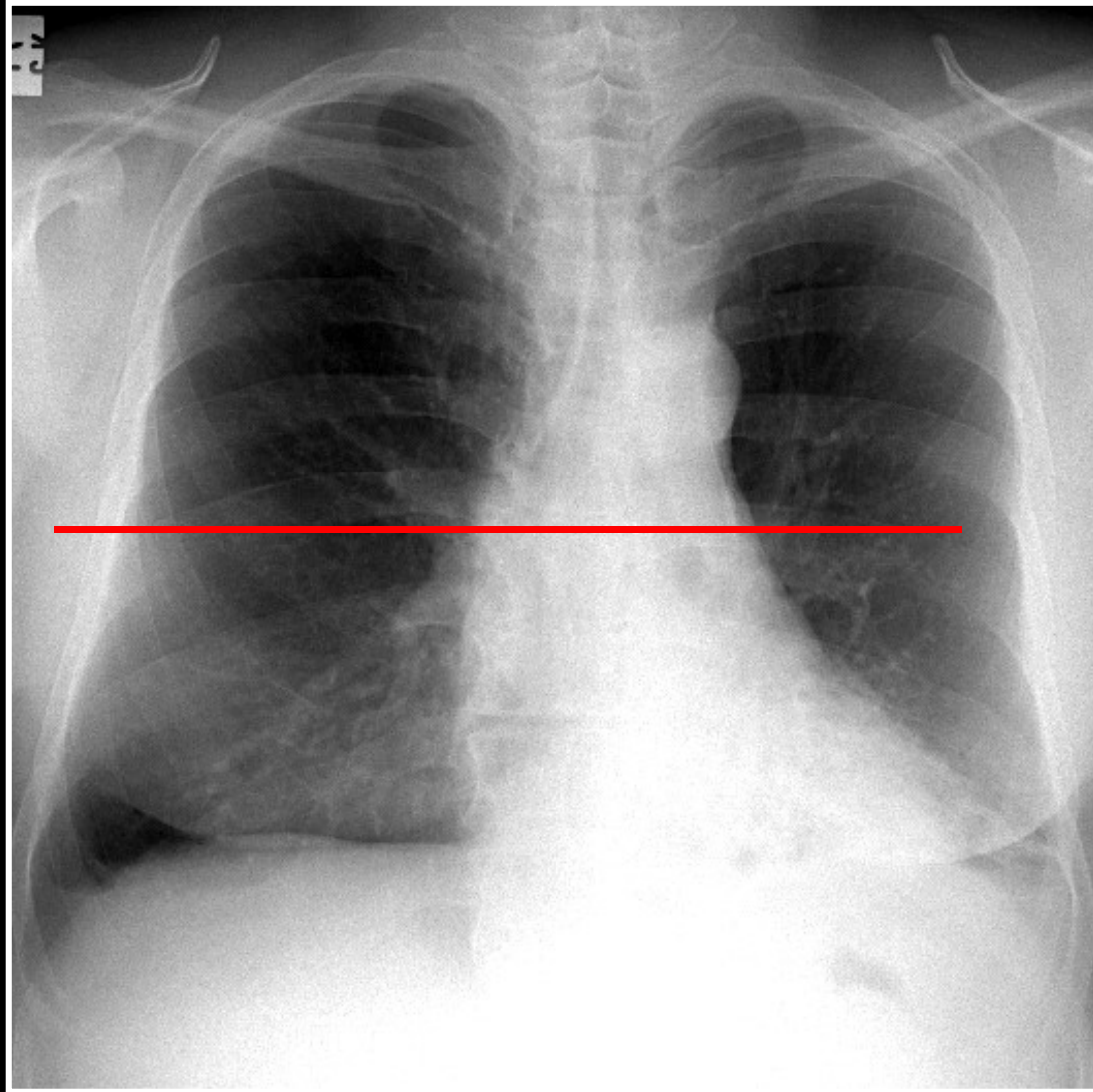
M
Doğurganlık çağında
din hasta
Uniform kistler
Kostofrenik sinüsler
zeyinde tutulum
Sigara öyküsü yok
Pnömotoraks gelişebilir.

LHH
• İrregüler şekilli , farklı boyutta
kistler
• Eşlik eden nodüller
• Sigara öyküsü, 20-40y
• Kostofrenik sinüsler korunur

LIP
• Orta yaş , kadın
• Bağ doku hastalığı öyküsü
• İnce duvarlı baziler,
perivasküler kistler
• Eşlik eden buzlu cam alanları



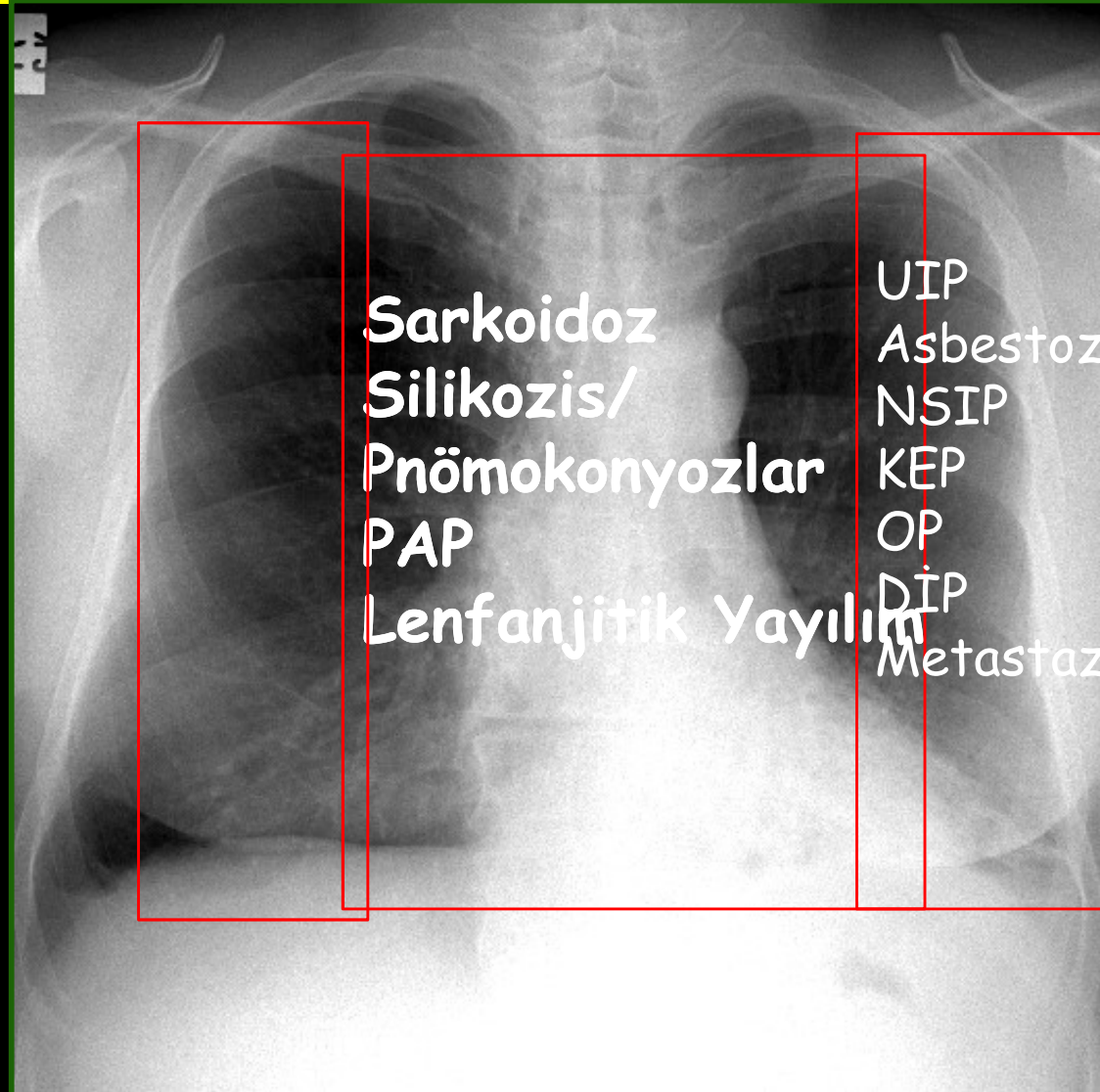
AKCİĞER ÜST VE ALT ZONLARINI TUTAN HASTALIKLAR



Silikozis, Sarkoido
LHH
Kronik hipersensit
pnömonisi
Respiratuar Bronşi
Santrlobüler Amfi
Ankilozan spondilit
PPFE

P,
bestozis
SIP, DIP, OP
nlobuler Amfizem

AKCIĐER SANTRALINI/PERİFERİNİ TUTAN HASTALIKLAR



Sarkoidoz
Silikozis/
Pnömkonyozlar
PAP
Lenfanjitik Yayılım

UIP
Asbestozis
NSIP
KEP
OP
DIP
Metastaz





TEŞEKKÜRLER