
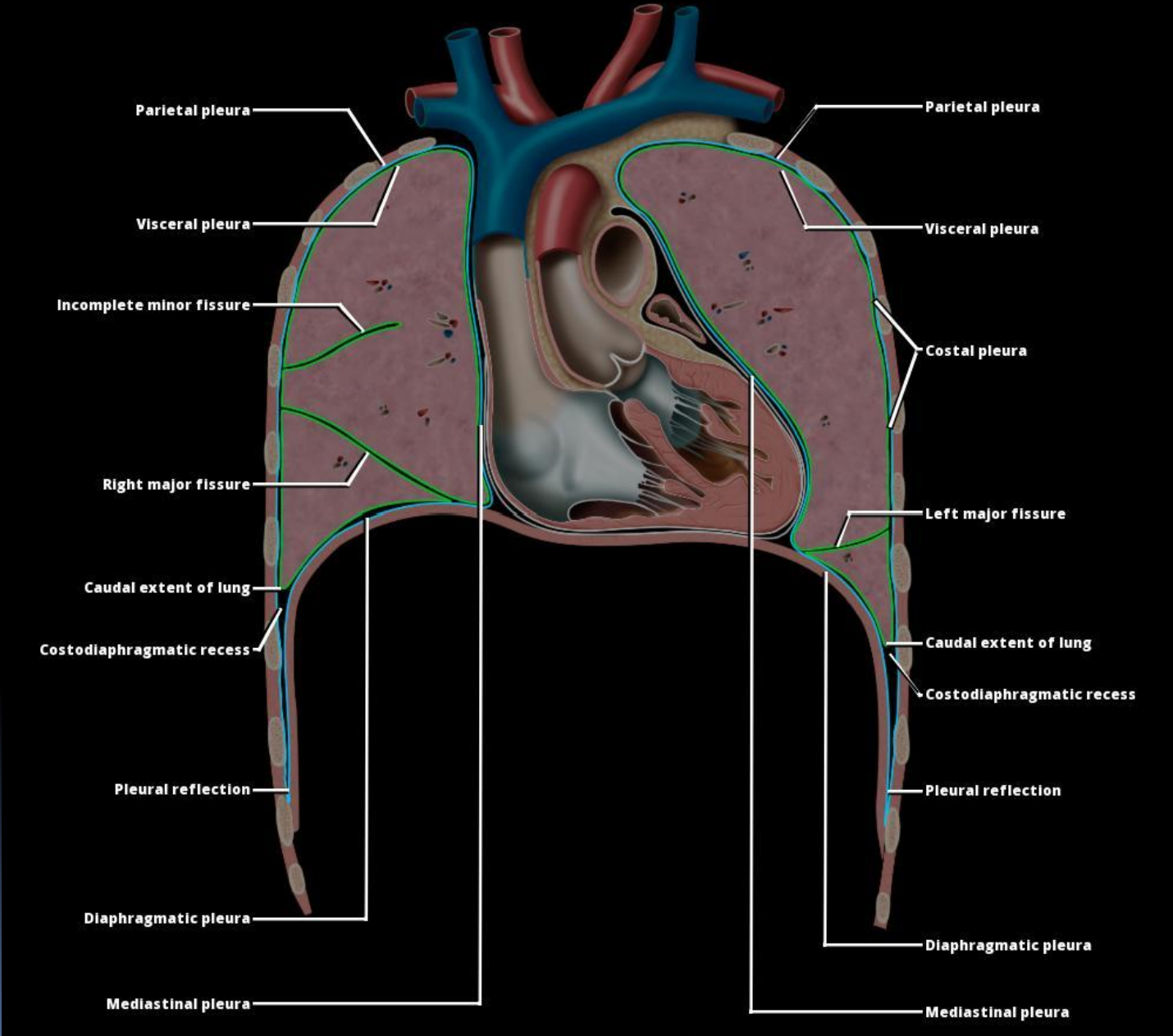


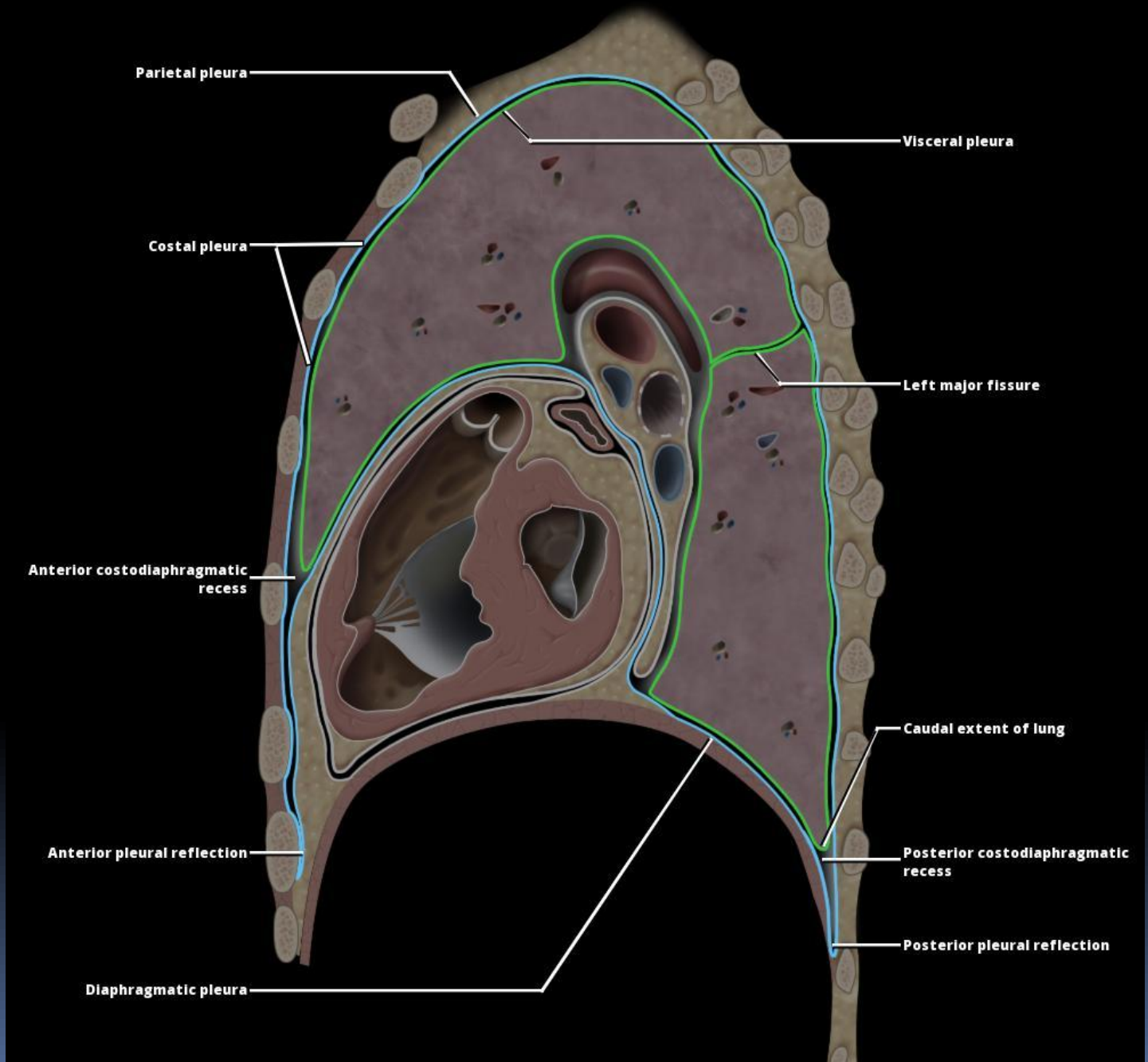
# PLEVRAL HASTALIKLARDA RADYOLOJİ



**Türk Toraks Radyolojisi Derneği**

DR. RAGIP ÖZKAN  
MEDİGÜNEŞ HASTANESİ SALİHLİ

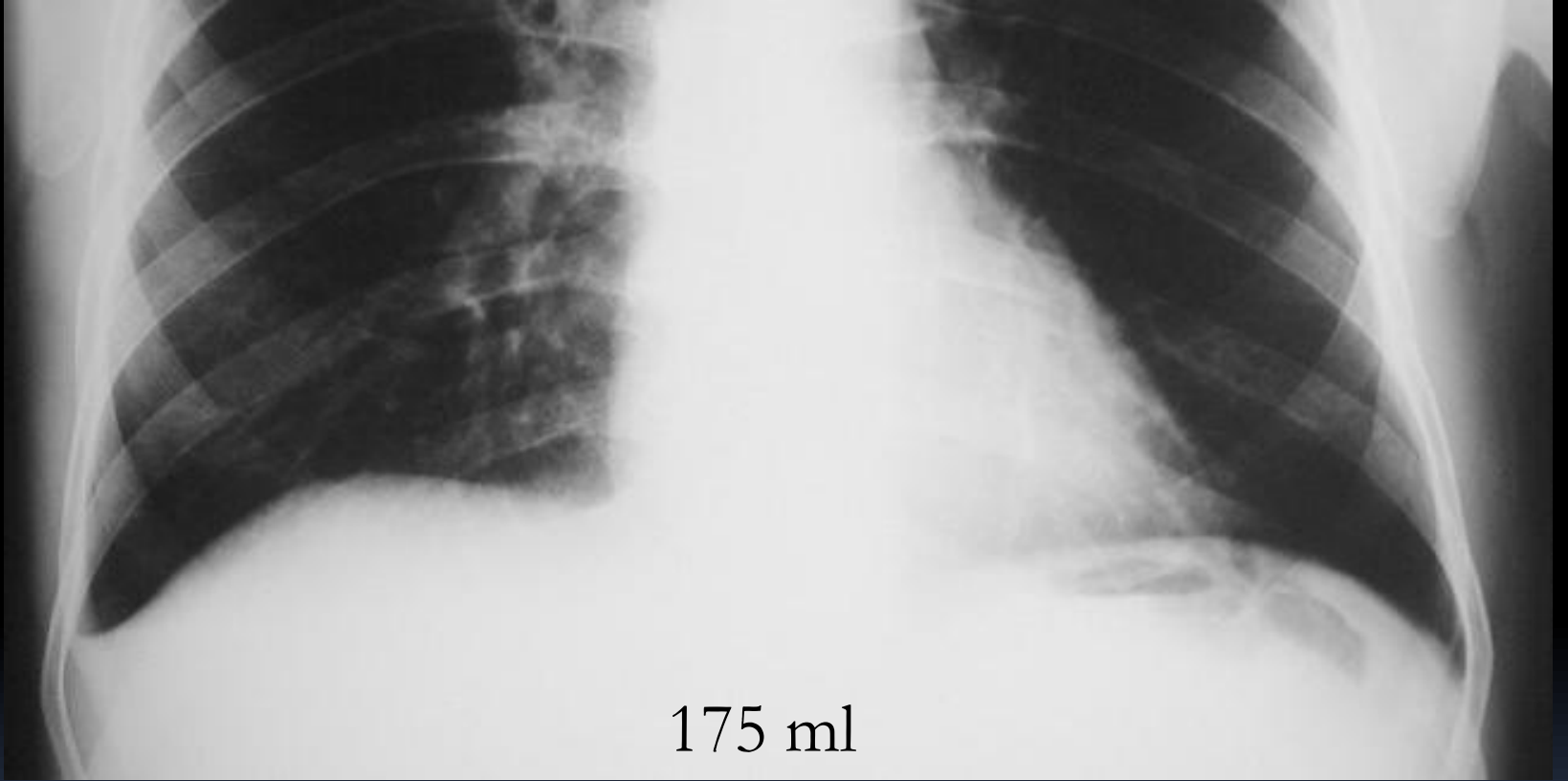




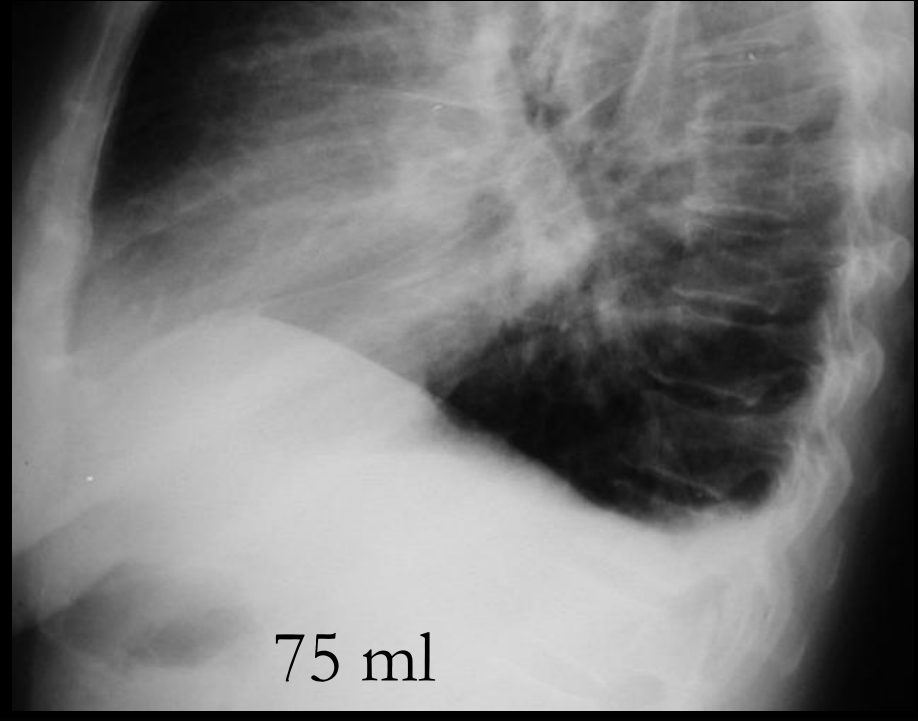
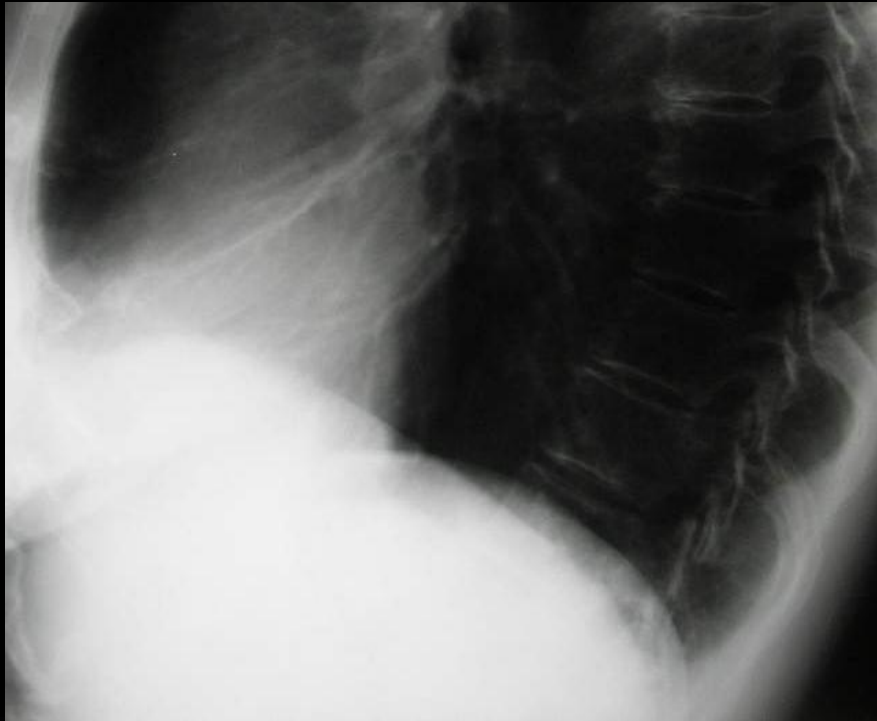# PLEVRAL HASTALIKLAR

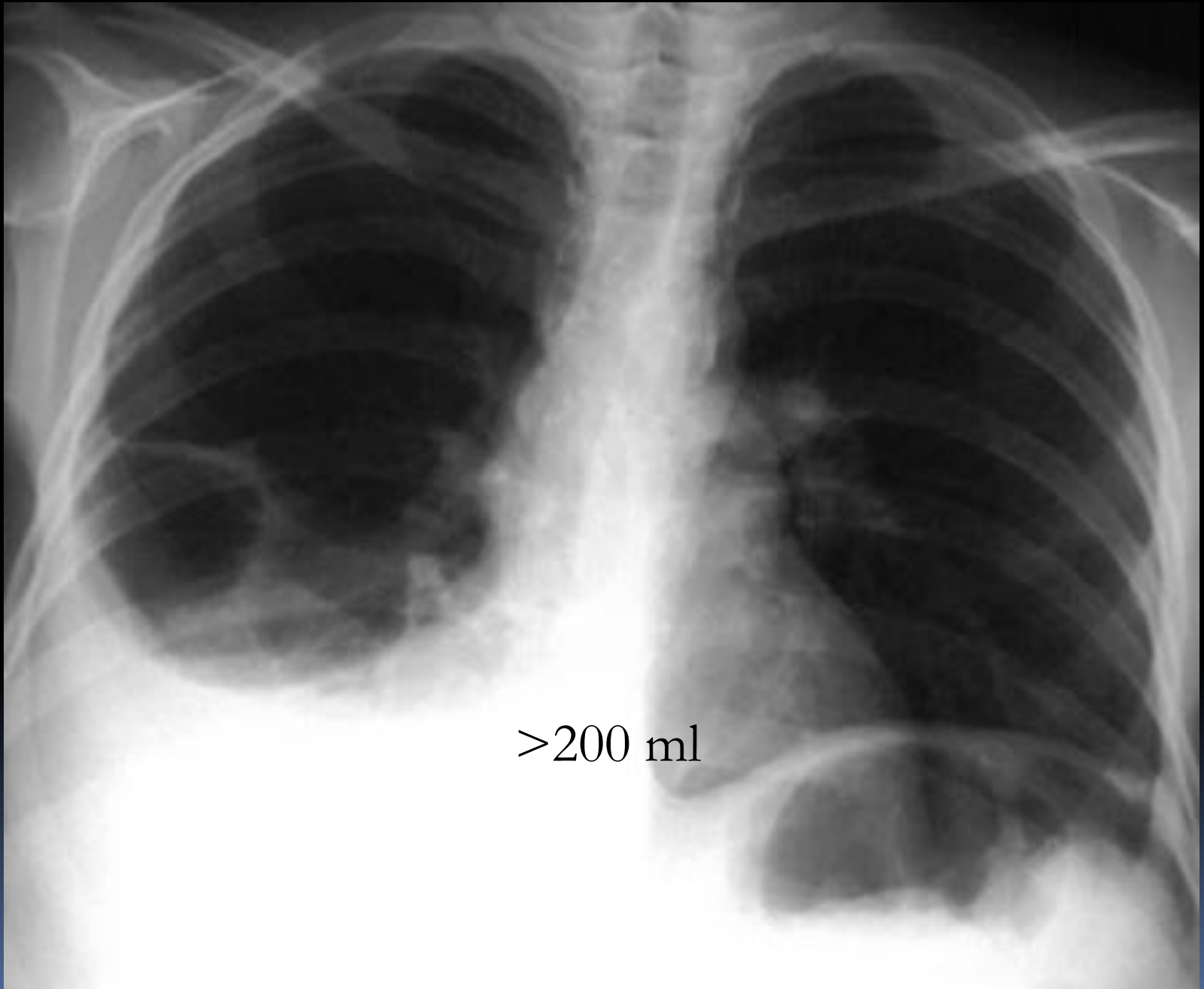
- Plevral sıvı
- Plevral kalınlaşma
- Neoplazi
- Pnömotoraks

PLEVRAL SIVI



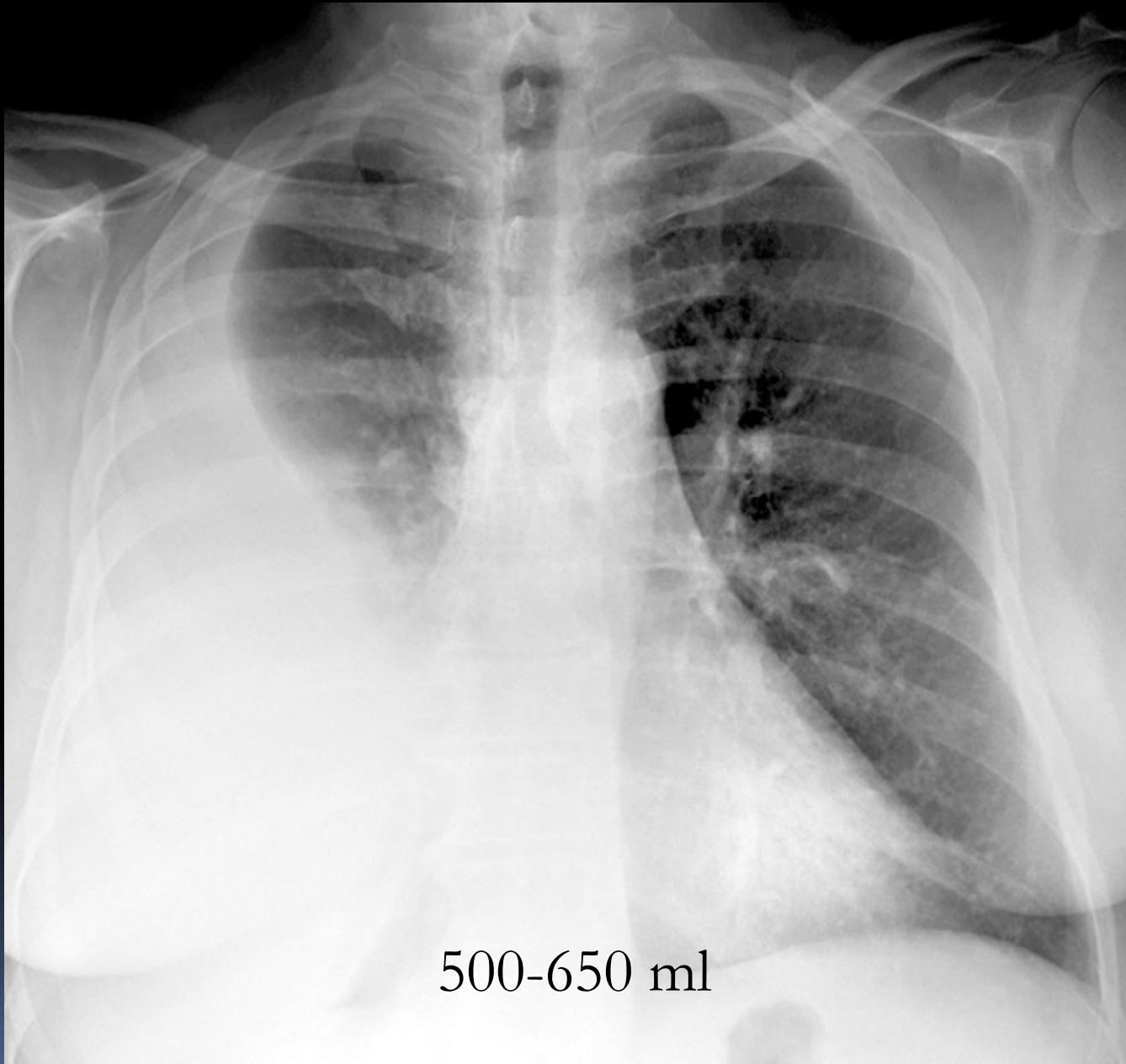
175 ml



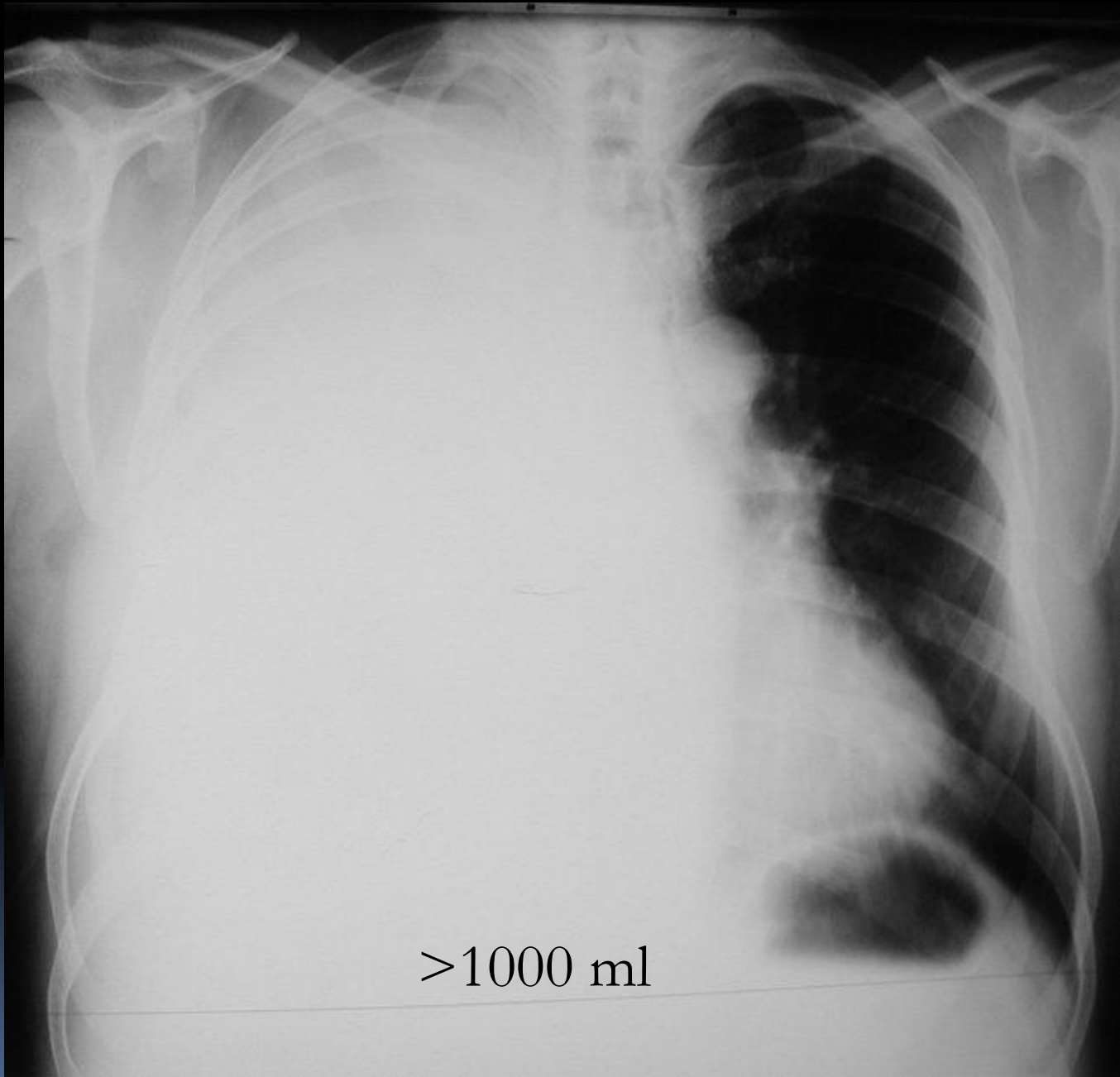


>200 ml





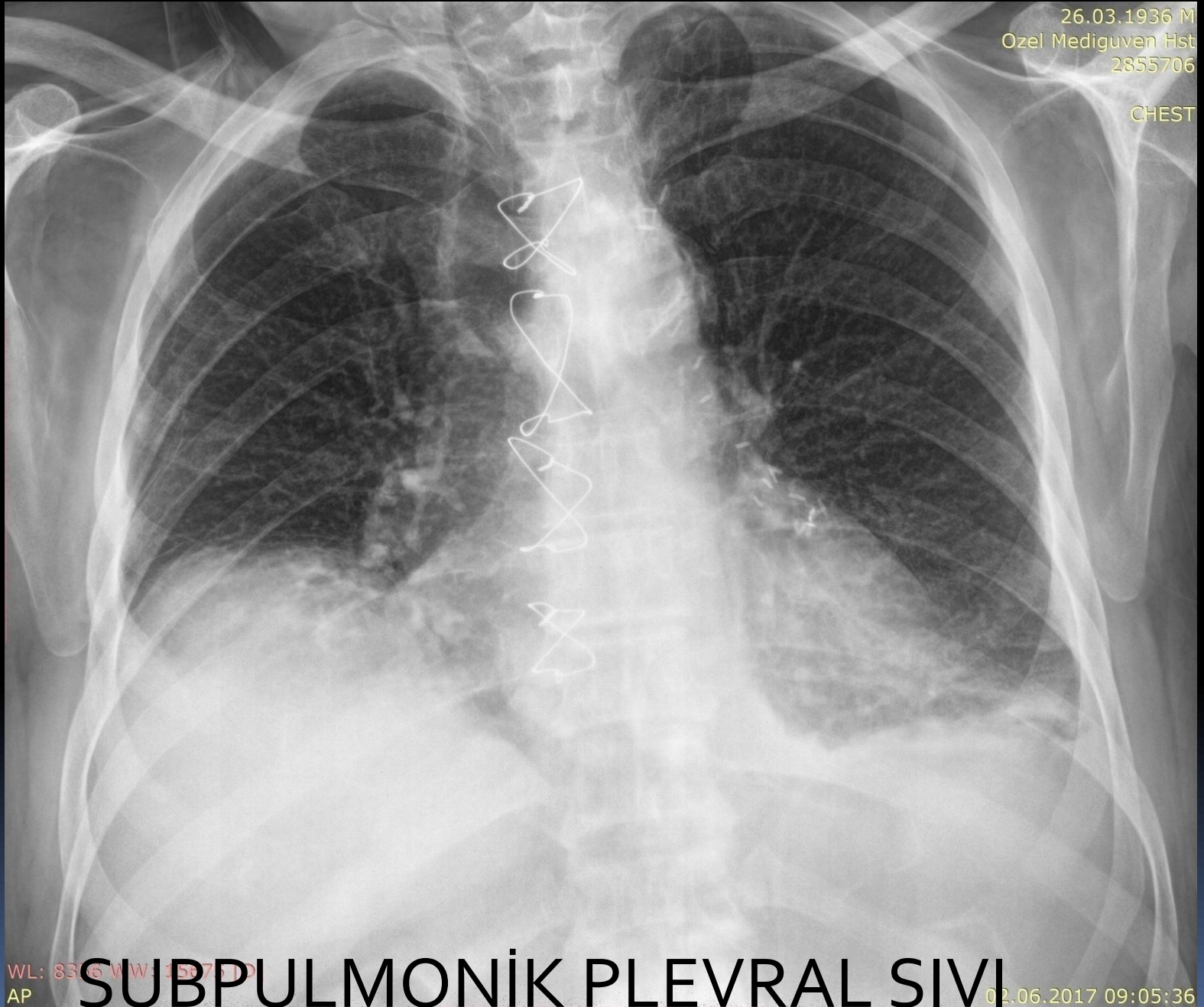
500-650 ml



>1000 ml

26.03.1936 M  
Ozel Mediguven Hist  
2855706

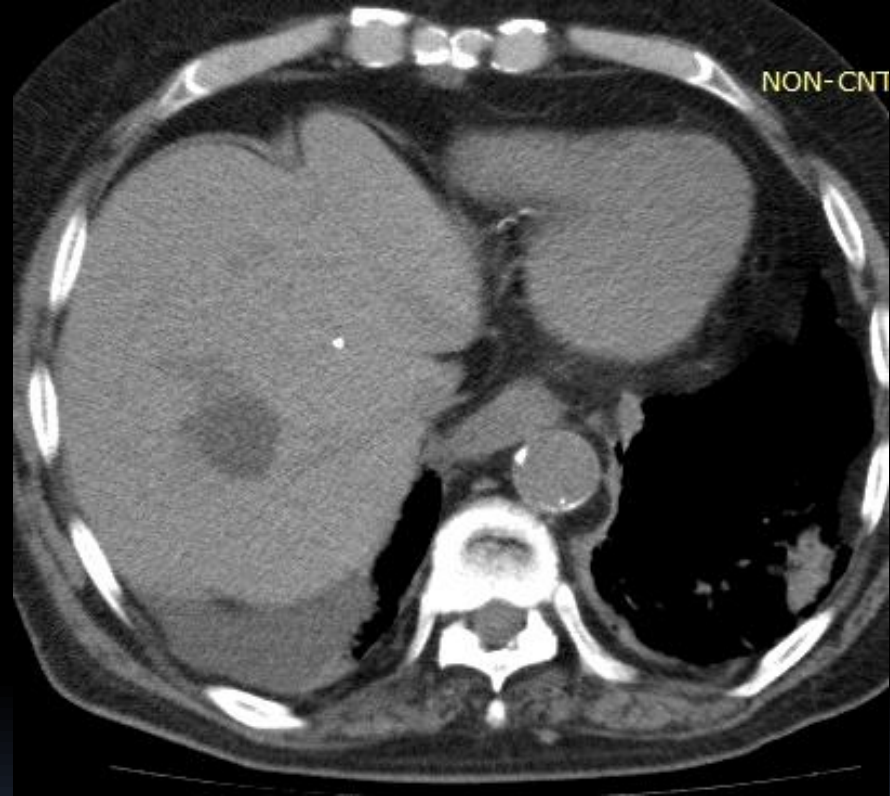
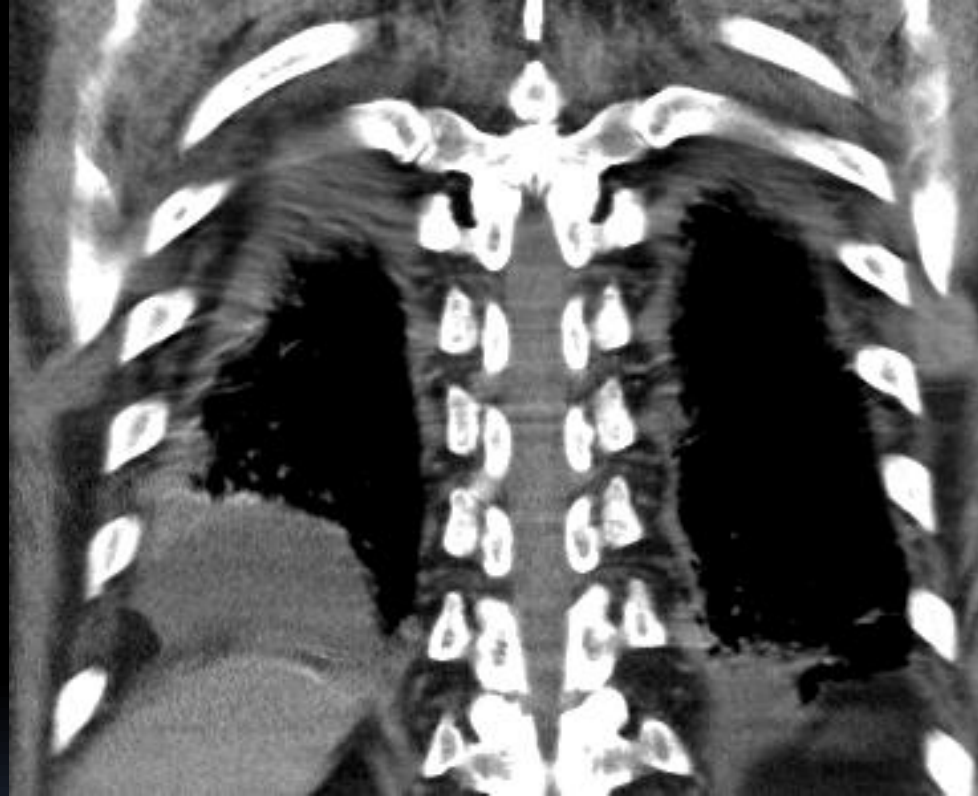CHEST



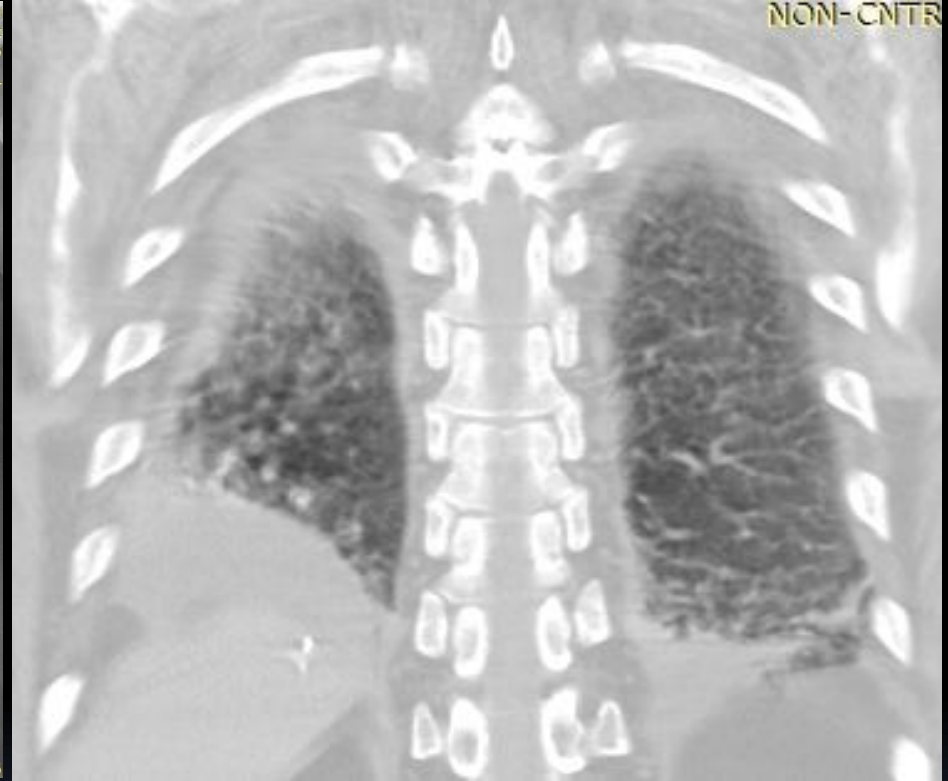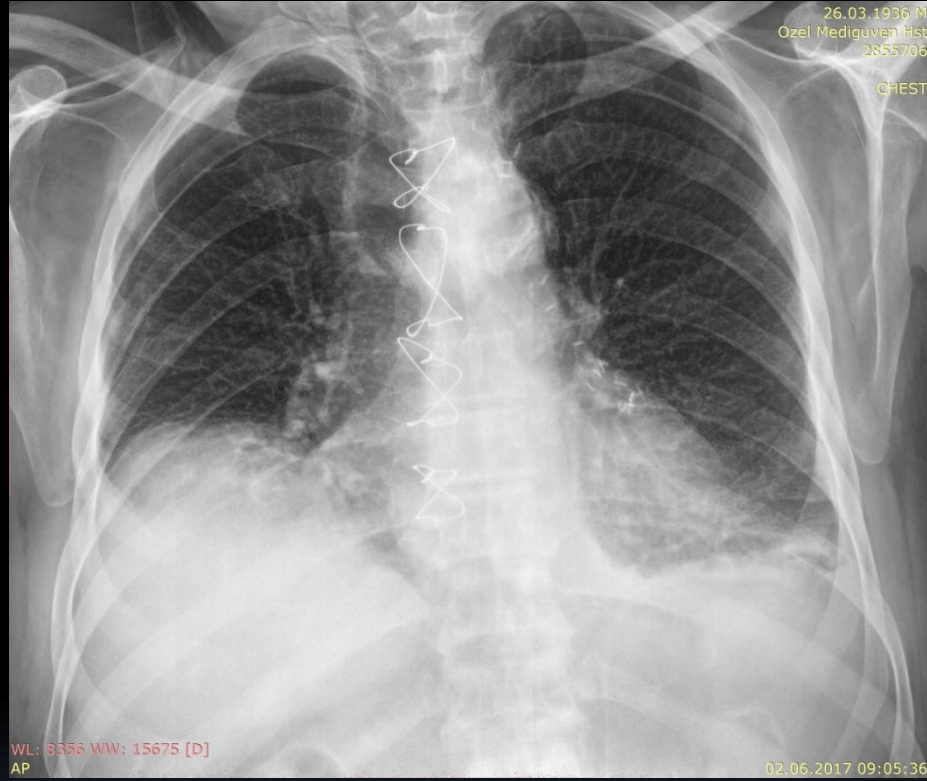
WL: 83.6 WW: 1507.0 D  
AP

**SUBPULMONİK PLEVRAL SIVI**

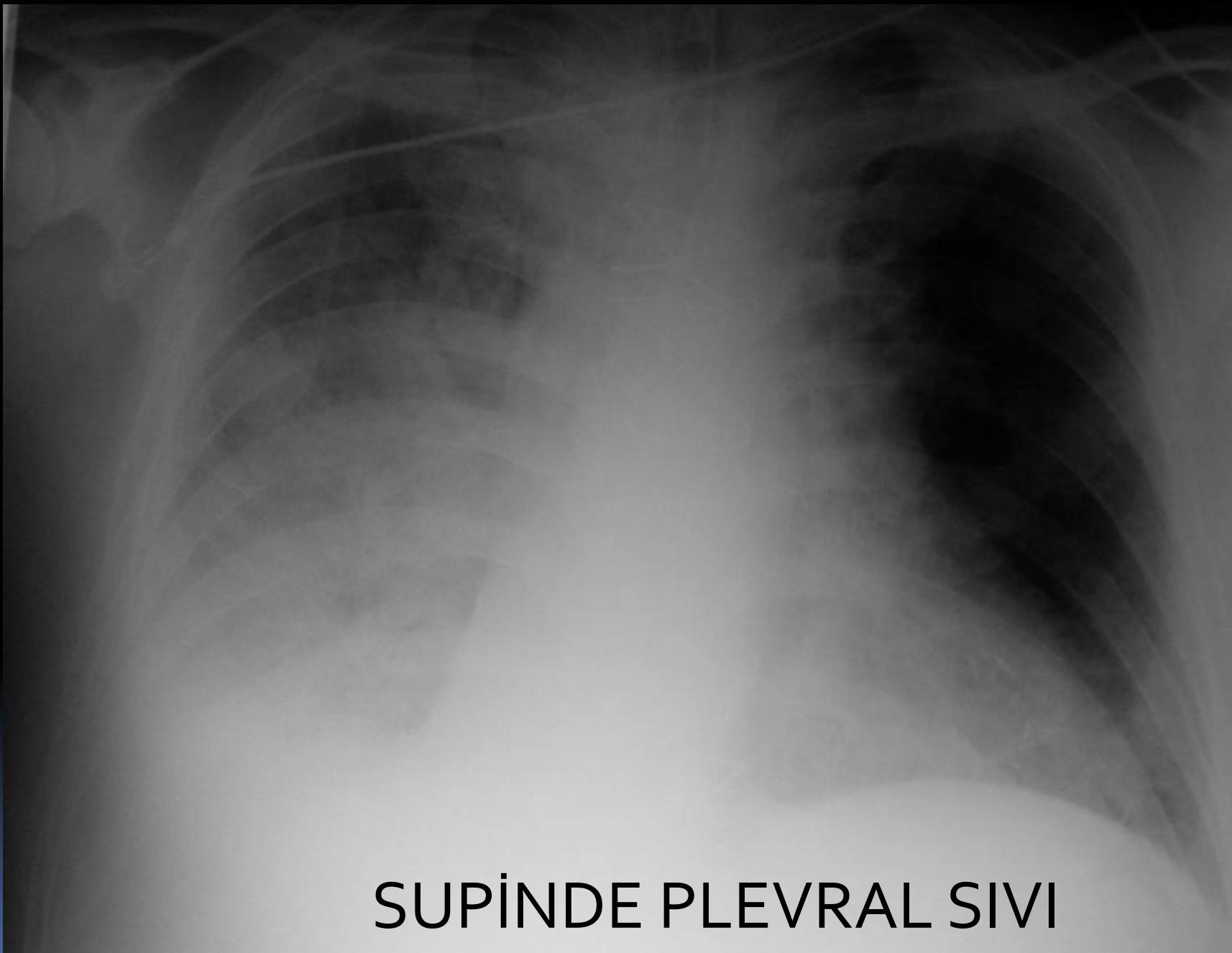
02.06.2017 09:05:36



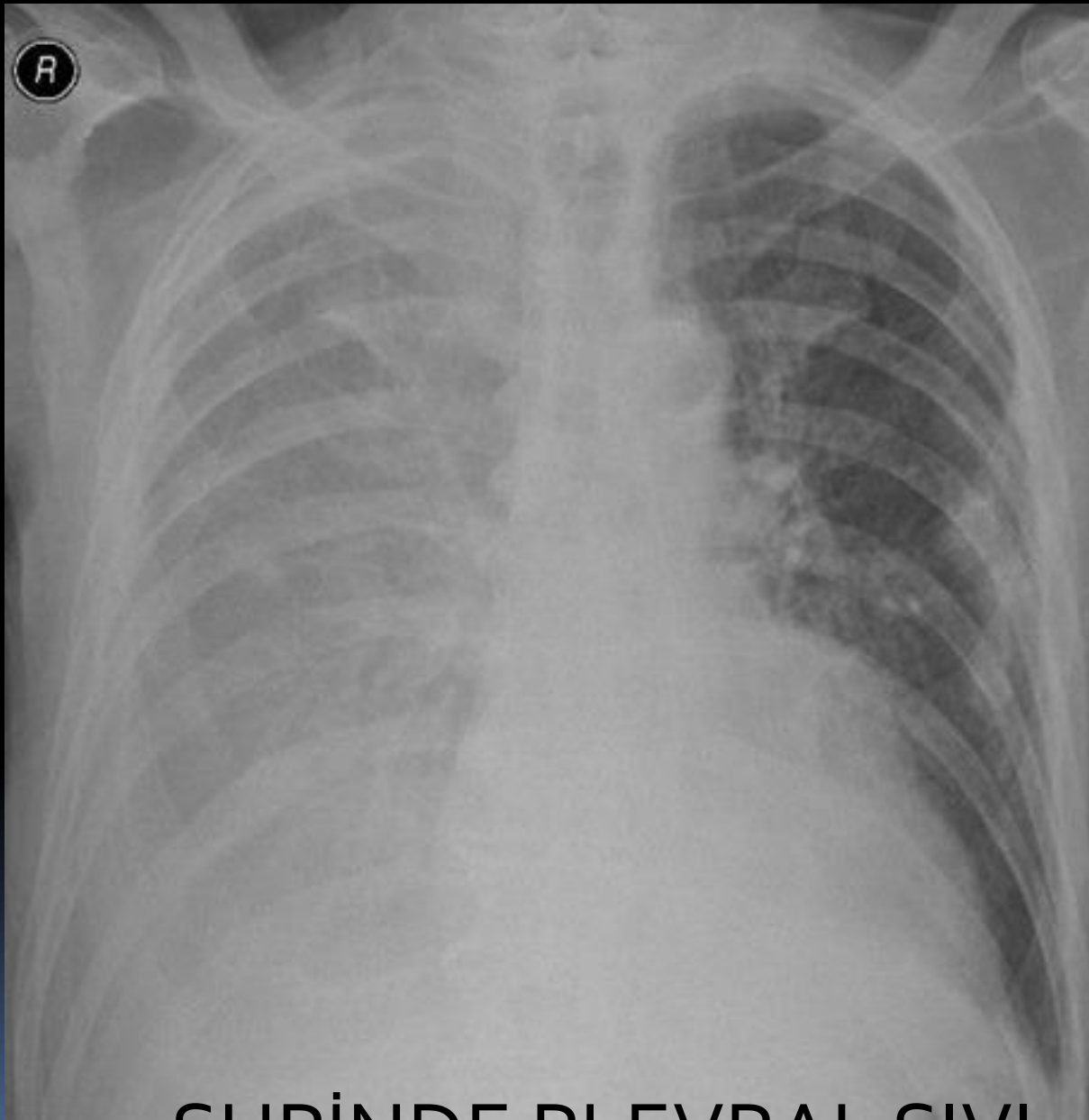
SUBPULMONİK PLEVRA SIVI



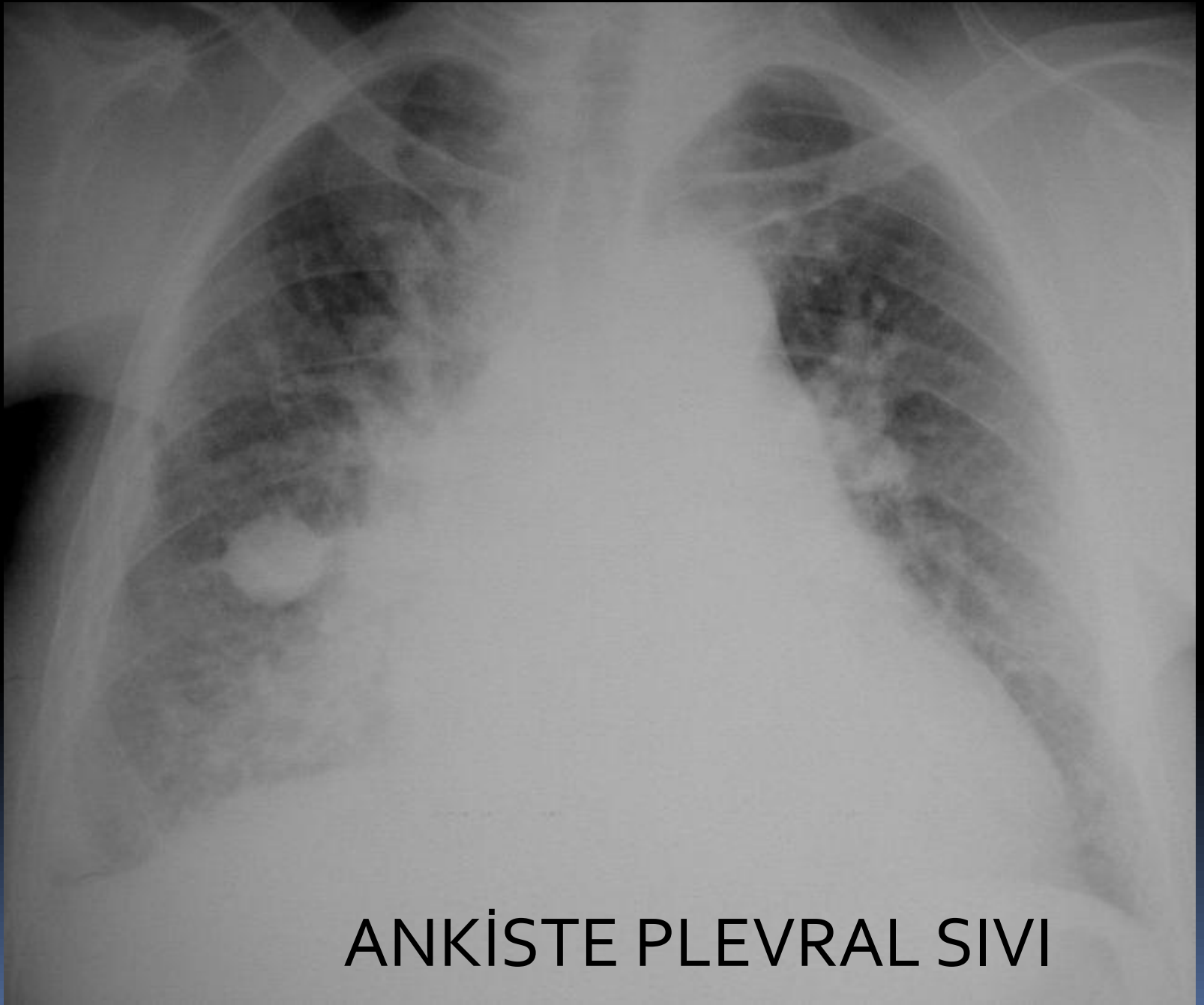
# SUBPULMONİK PLEVURAL SIVI



SUPINDE PLEVRA SIVI

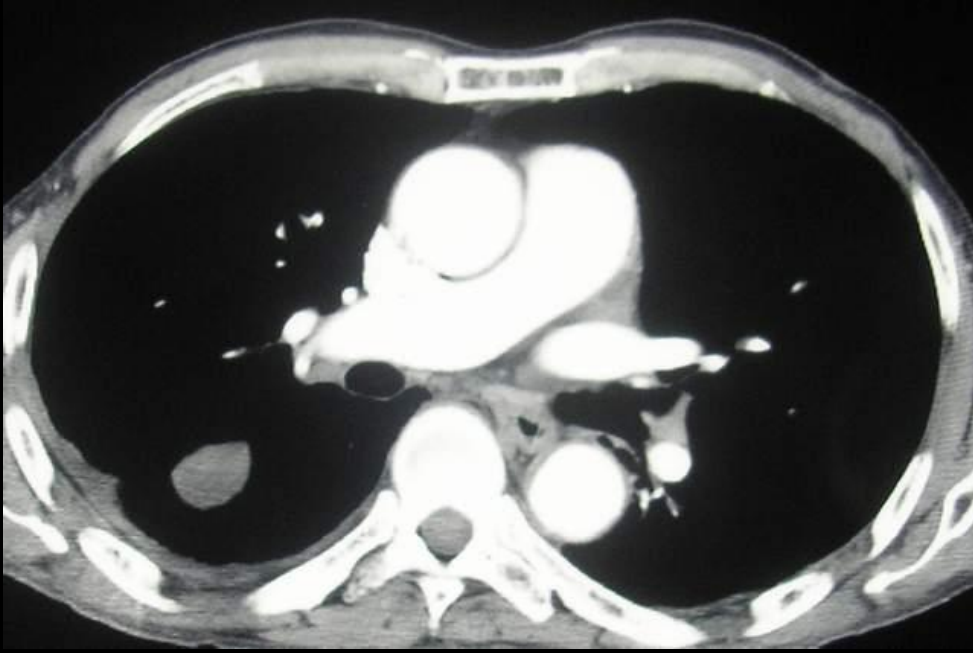


SUPINDE PLEVURAL SIVI

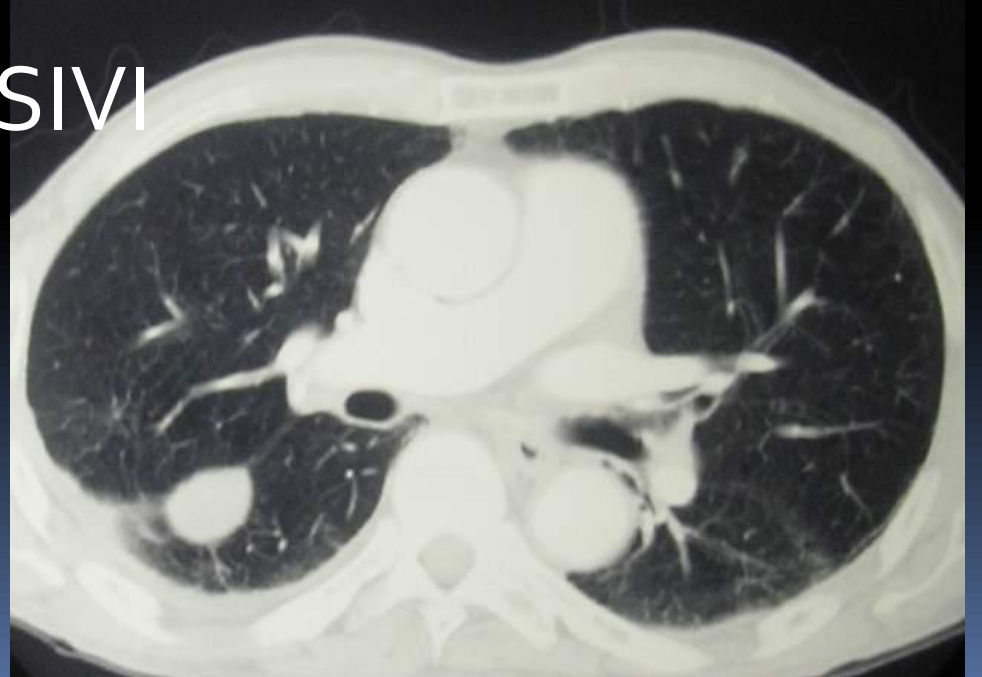


ANKİSTE PLEVURAL SIVI





ANKİSTE PLEVURAL SIVI



CEKIM TARİHİ: 04/2007 11:38  
H.HUSEYİN AKANSU,  
600779

**R**

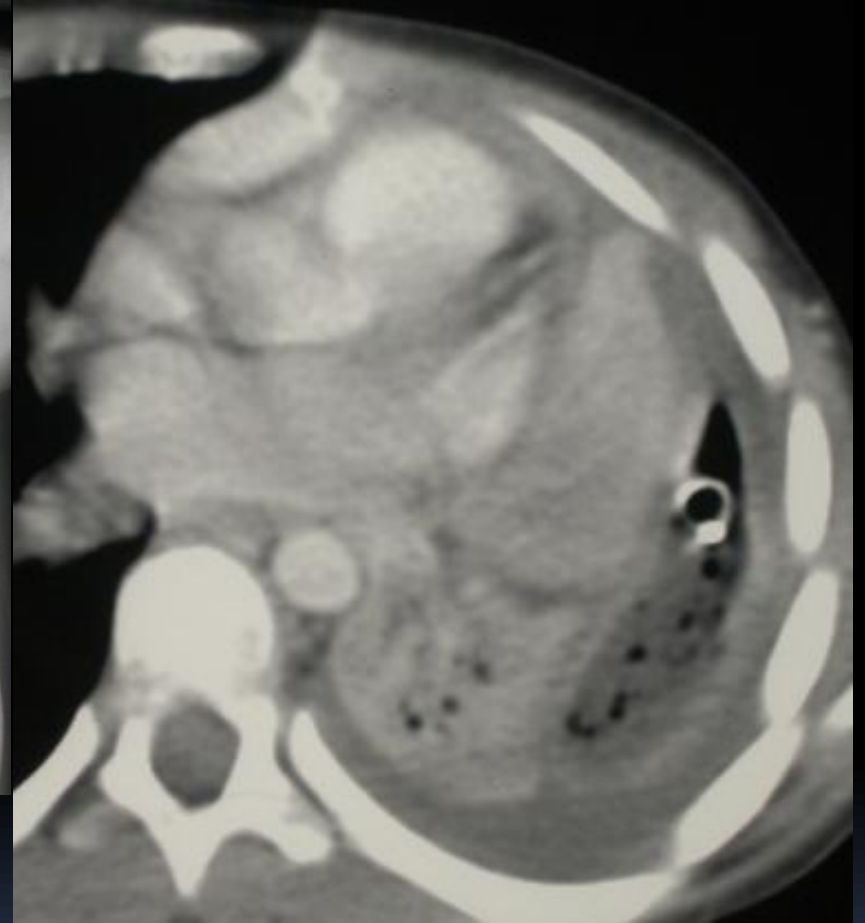
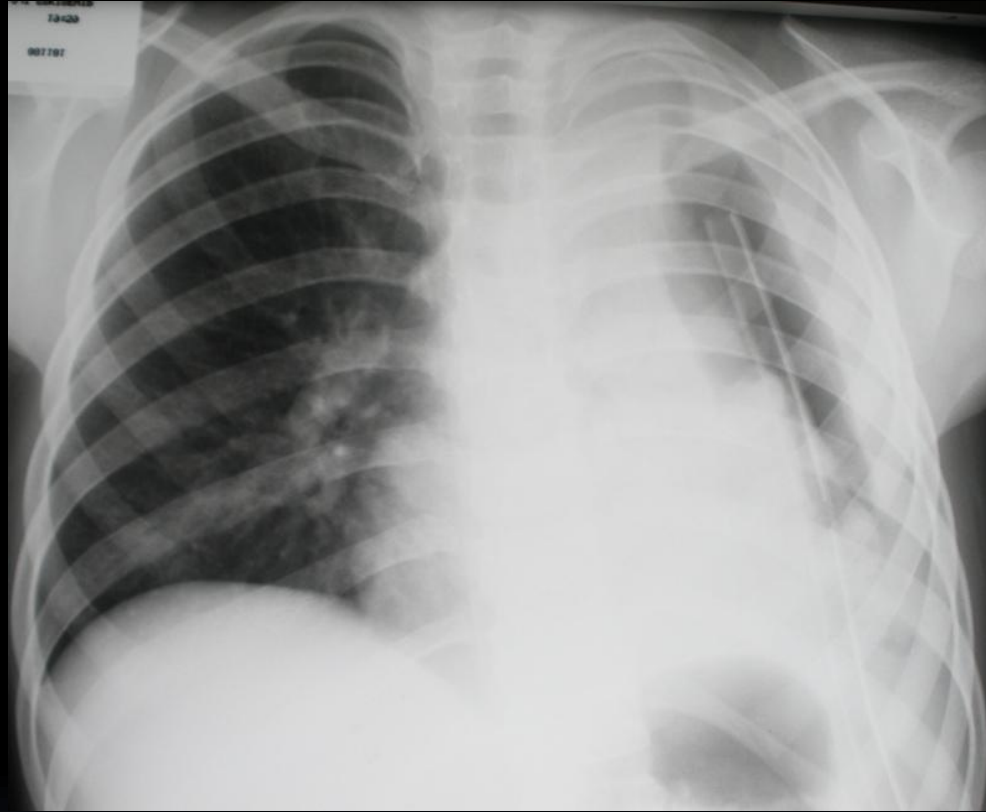
KV: 90  
MA: 20  
MAS: 8  
MS: 40

CEKIM TARİHİ: 04/2007 11:38  
H.HUSEYİN AKANSU,  
600779

KV: 9  
MA: 20  
MAS: 34  
MS: 17

**L**

ANKİSTE PLEVRA SIVI



LAMELLAR SIVI

# TRANSUDA PLEVRAL SIVI

- Konjestif kalp yetmezliđi
- Siroz
- Atelektazi
- Peritoneal dializ
- Hipoalbuminemi
- Nefrotik sendrom
- Ürinotoraks
- Postpartum
- Santral kataterin plevra içine girmesi
- Mikstödem

# TRANSUDA PLEVURAL SIVI

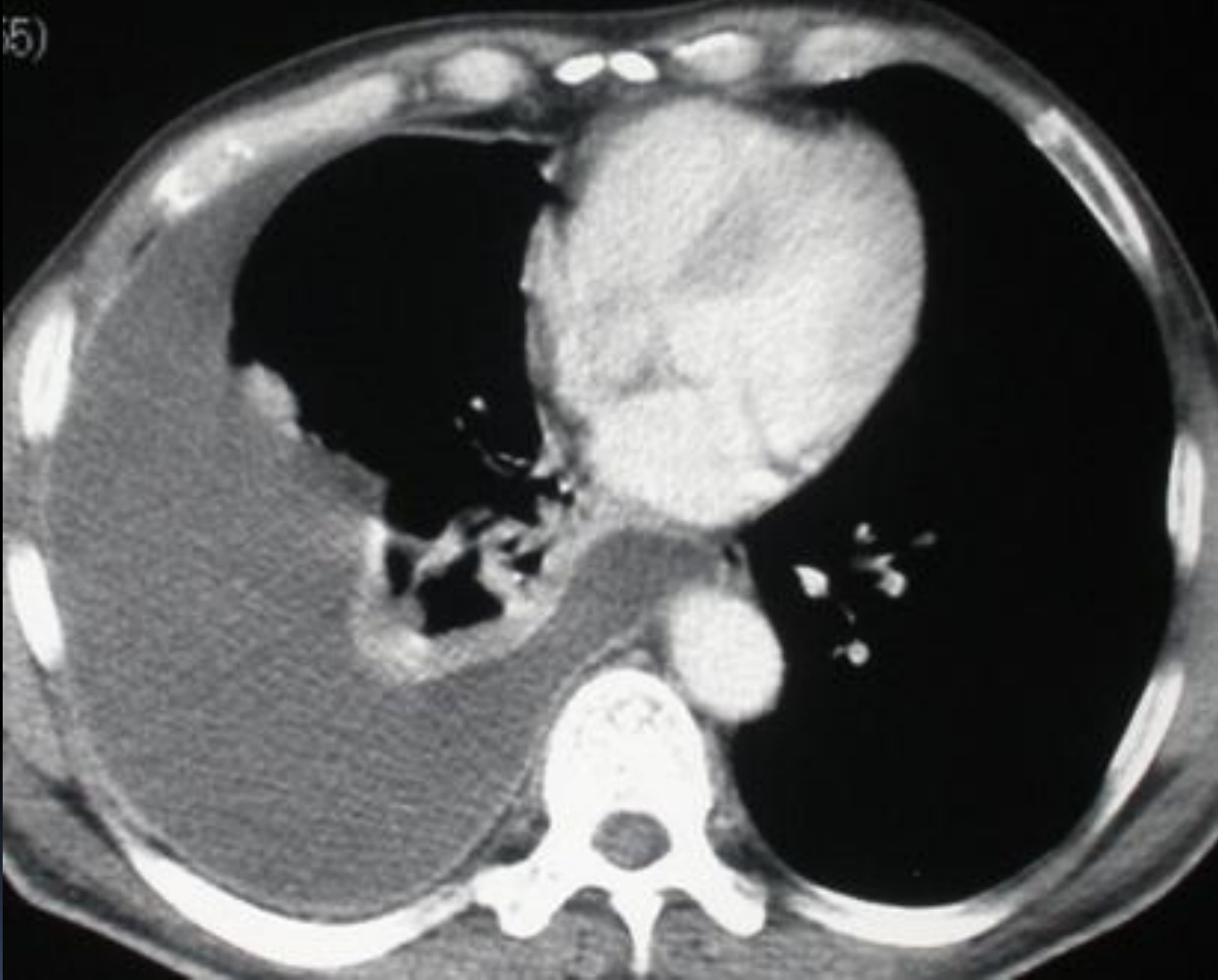
- Sol kalp yetmezliđi
  - Plevral sıvı oluřumu iin pulmoner venöz hipertansiyon temel faktördür
  - Subplevral alanda interstisyel basın artar
  - Ödem sıvısı viseral plevradan sızar
- İzole sađ kalp yetmezliđinde plevral sıvı beklenen bir durum deđildir

# TRANSÜDA-EKSÜDA SIVI AYIRIMI

- BT ile sıvı yoğunluk ölçümleri güvenilir şekilde transüda-eksüda-hematom-şilöz sıvı ayırımını yapamamakta
- Çoğu sıvılar nedeni ne olursa olsun 20-30 HU arasında değişmekte

# TRANSÜDA-EKSÜDA SIVI AYIRIMI

- Kontrastlı BT'de pariyetal plevranın boyanması plevranın kalınlaşmış olduğunu gösterir
- Kalınlaşmış pariyetal plevra ile birlikte izlenen plevral sıvı eksüdadır
- Bu bulgu eksüdatif sıvıların % 60'ında vardır. Doğruluk oranı yaklaşık % 100'dür
- Plevral kalınlaşma yoksa sıvı eksüda veya transüda olabilir

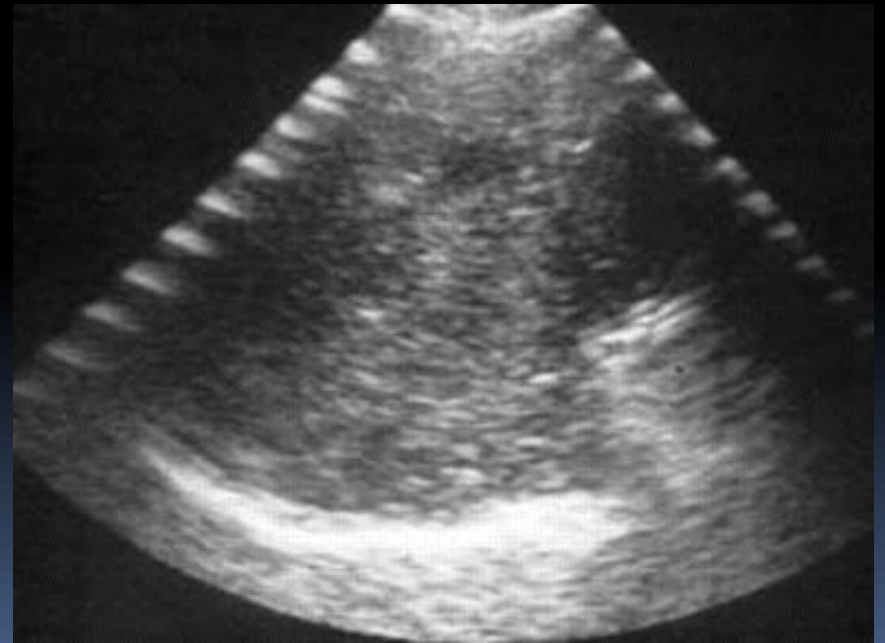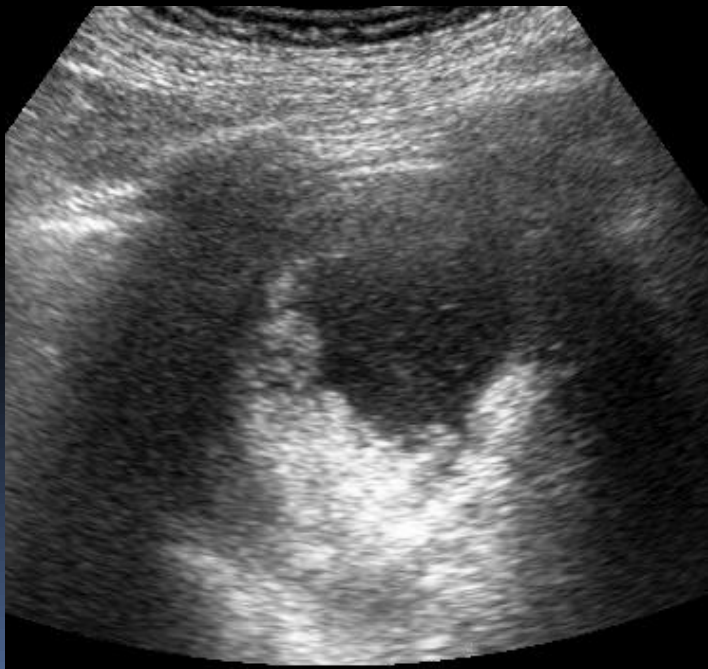

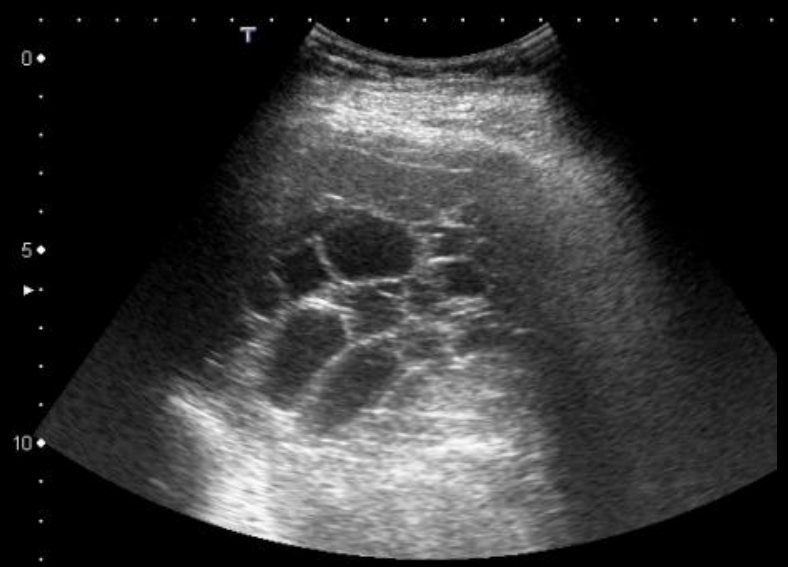
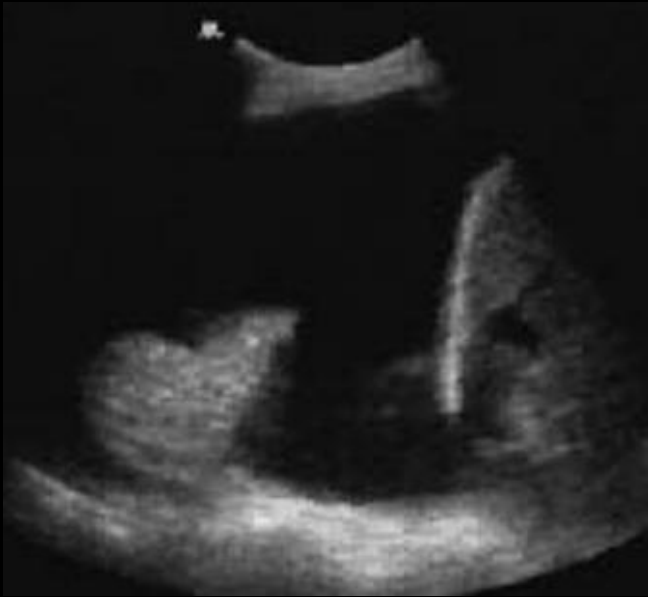BOYANMIŞ PARİYETAL PLEVRA

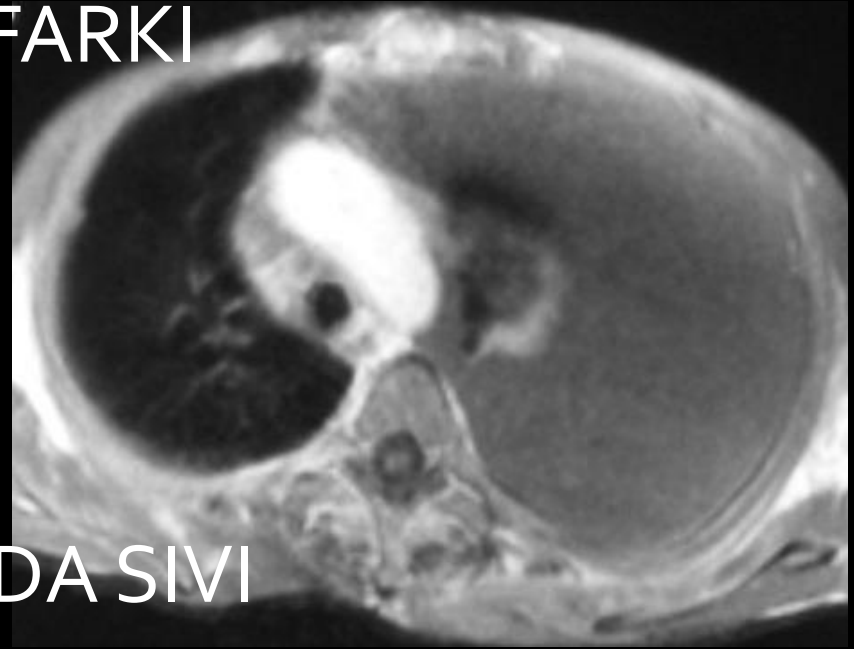
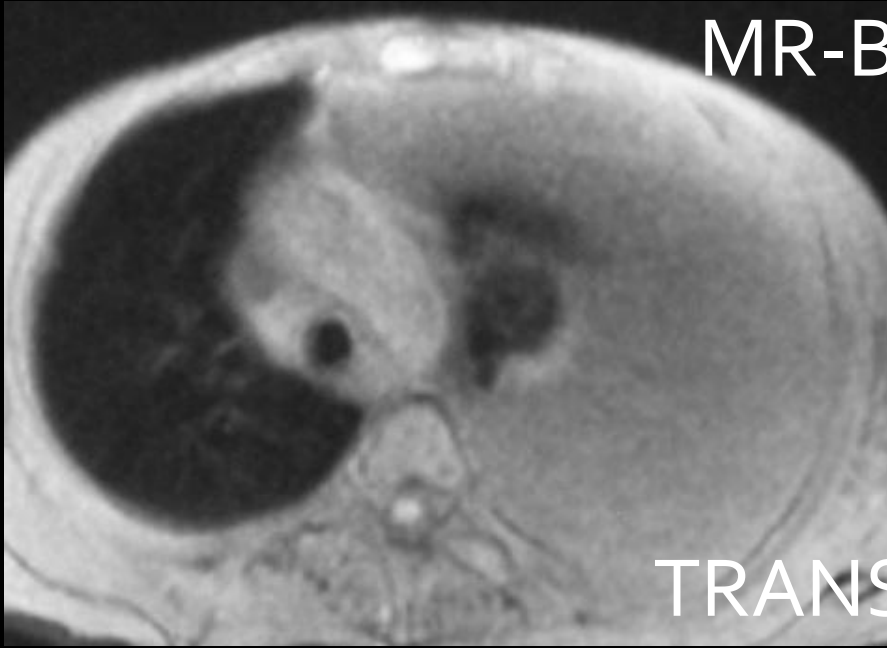


# TRANSÜDA-EKSÜDA SIVI AYIRIMI

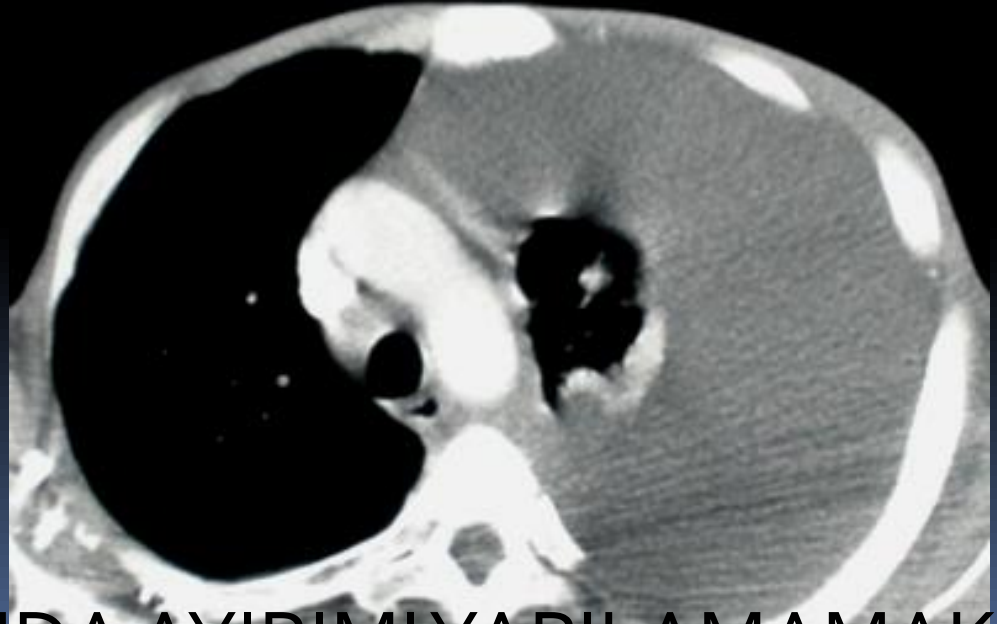
- US'de eksüda
  - Septasyonların olması
  - Kompleks olup septasyon içermemesi
  - Homojen ekojenite
  
- US'de eksüda/transüda
  - Anekoik



MR-BT FARKI



TRANSÜDA SIVI



TRANSÜDA -EKSÜDA AYIRIMI YAPILAMAMAKTA

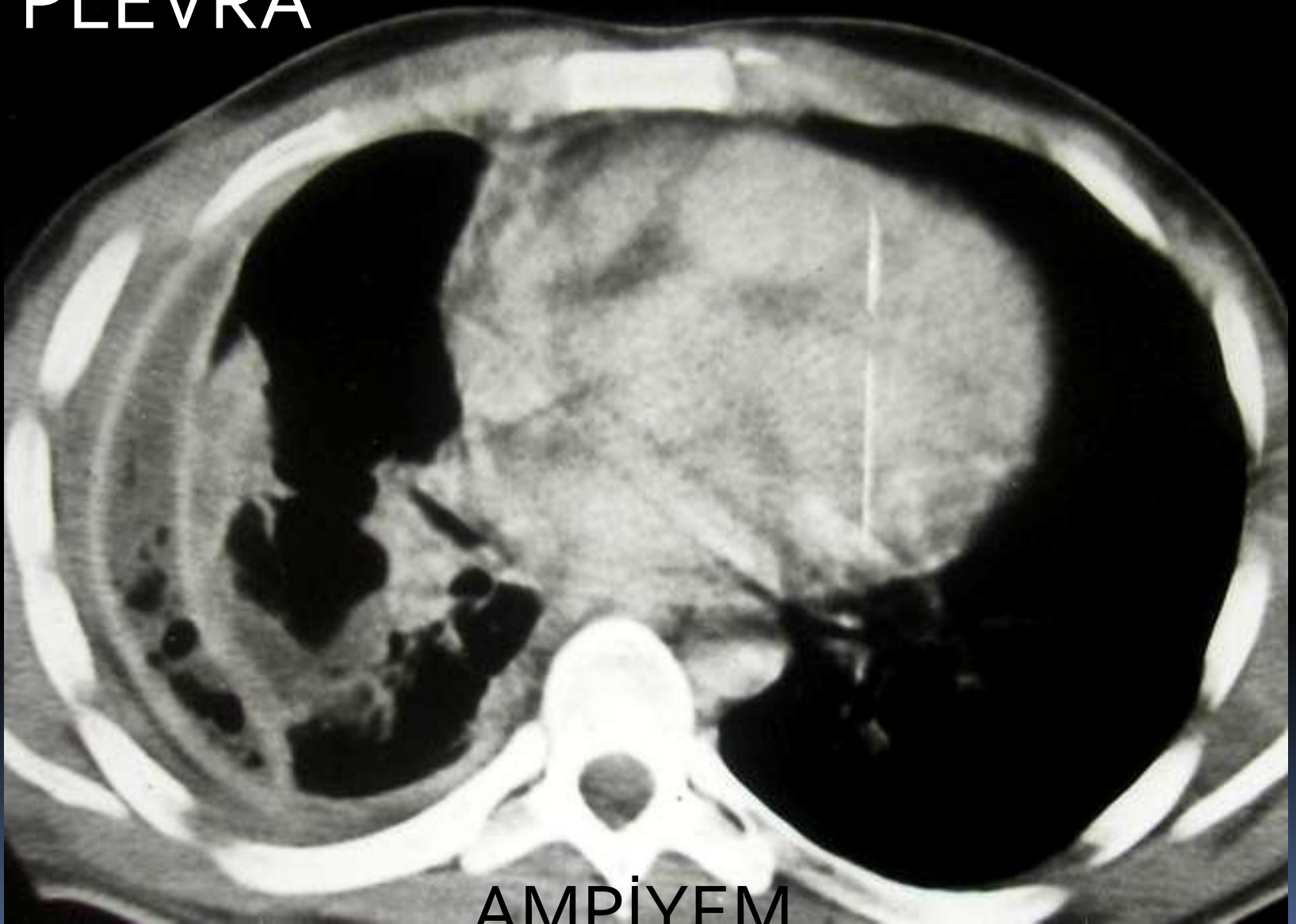
# EKSUDA PLEVRAL SIVI

- Pnömoni ve parapnömonik sıvı
- Ampiyem
- TB plöritis
- Neoplasm
- Pulmoner emboli
- SLE ve romatoid artrit gibi kollajen hastalıklar
- Abdominal hastalıklar (pankreatit, abse, cerrahi),
- Dressler sendromu
- Asbestoz teması
- Meig sendromu
- Üremi
- Endometriozis
- İlaç reaksiyonları
- Terapötik radyasyondur

# EKSÜDA SIVIDA İZLENECEK YOL

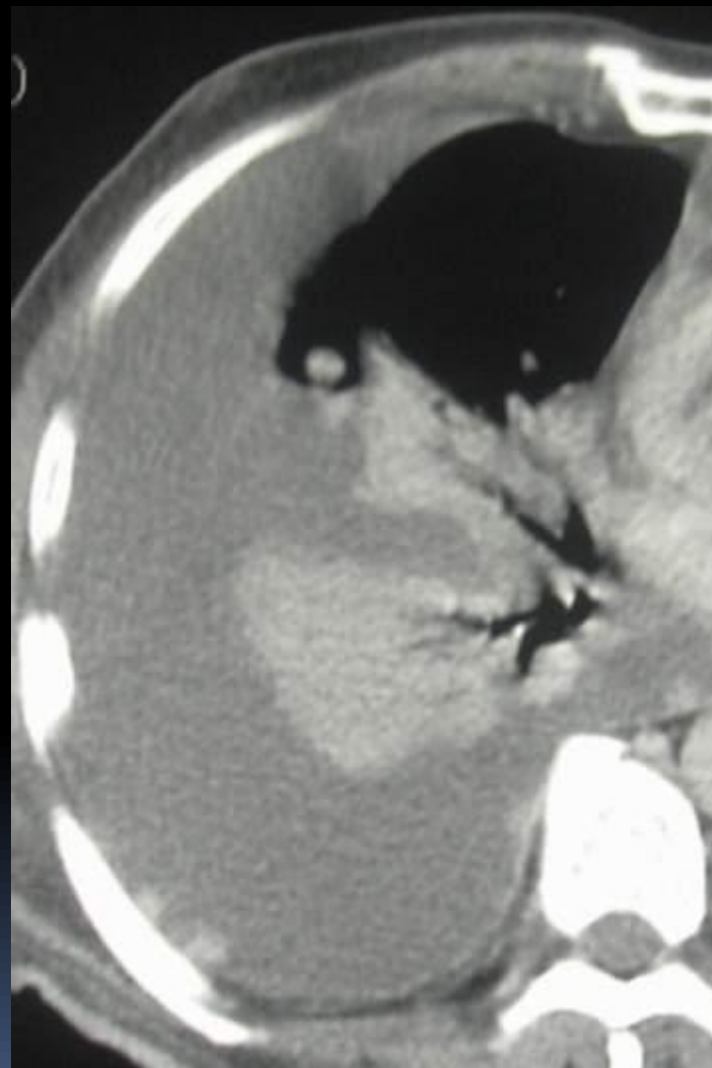
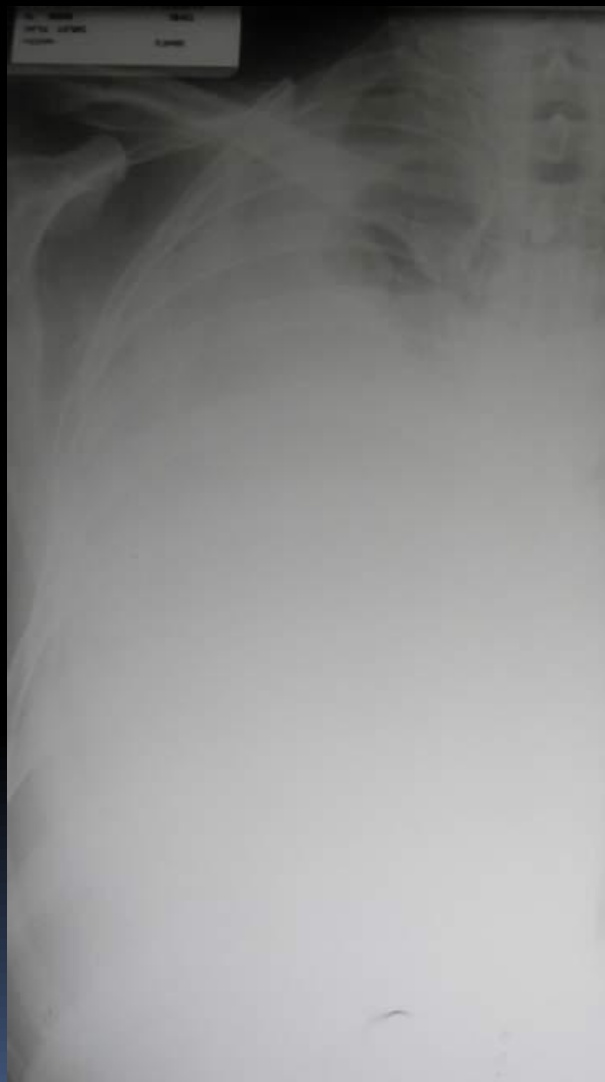- PLEVRA
- AKCİĞER PARANKİMİ
- EKSTRAPLEVRAL YAĞ
- MEDIASTİNUM
- GÖĞÜS DUVARI
- ABDOMEN

PLEVRA

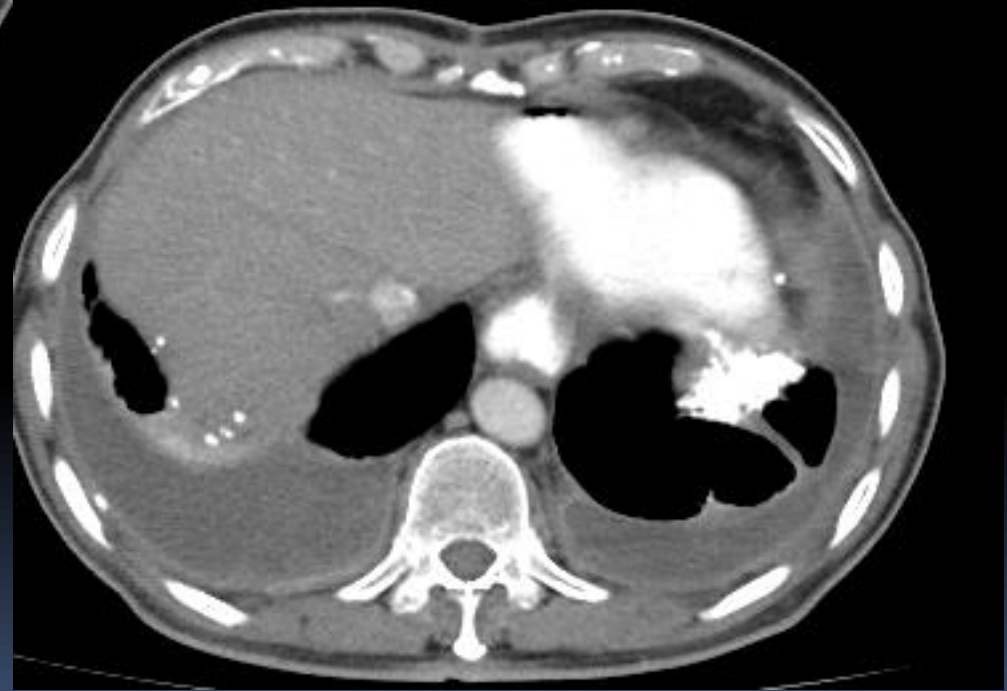
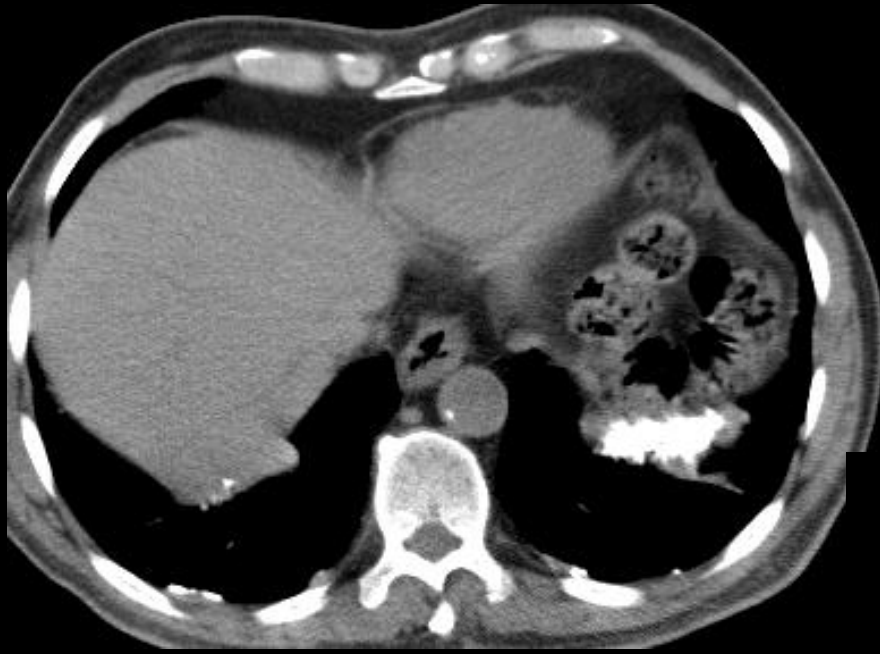


AMPIYEM

PLEVRA



MPM

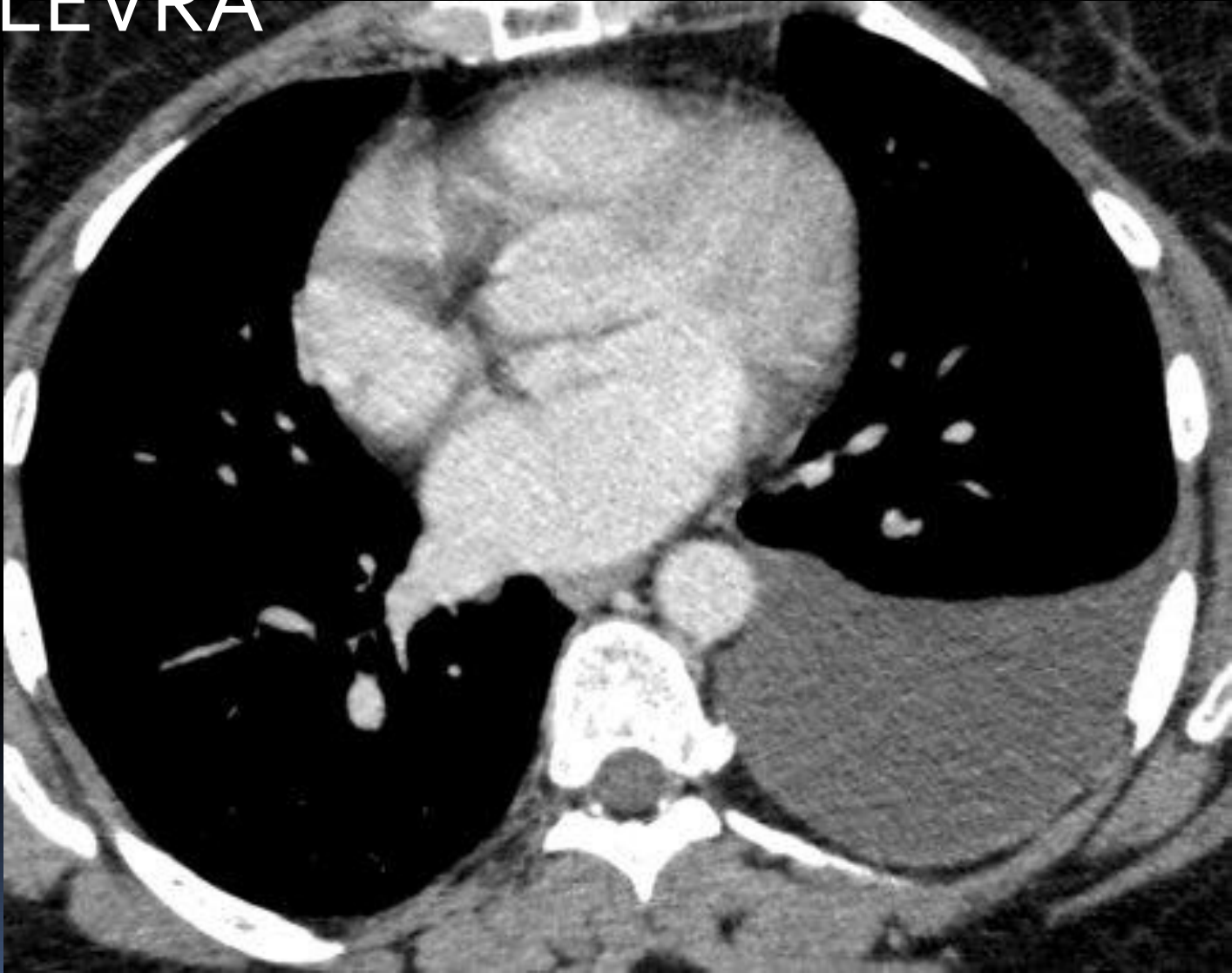


BENİGN ASBEST PLÖREZİSİ



PLEVRA BAZEN BİR ŐEY  
SÖYLEMEZ

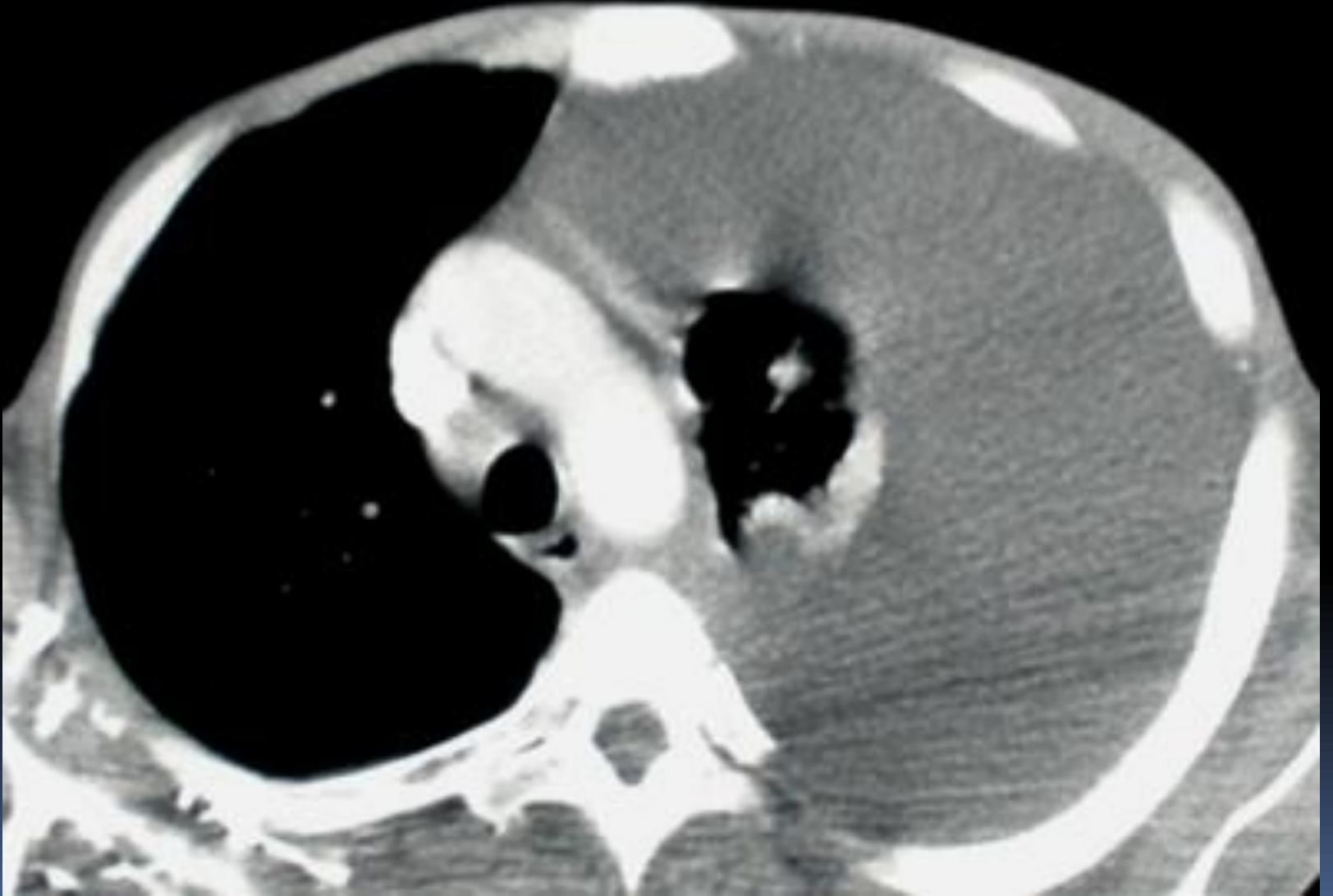
PLEVRA



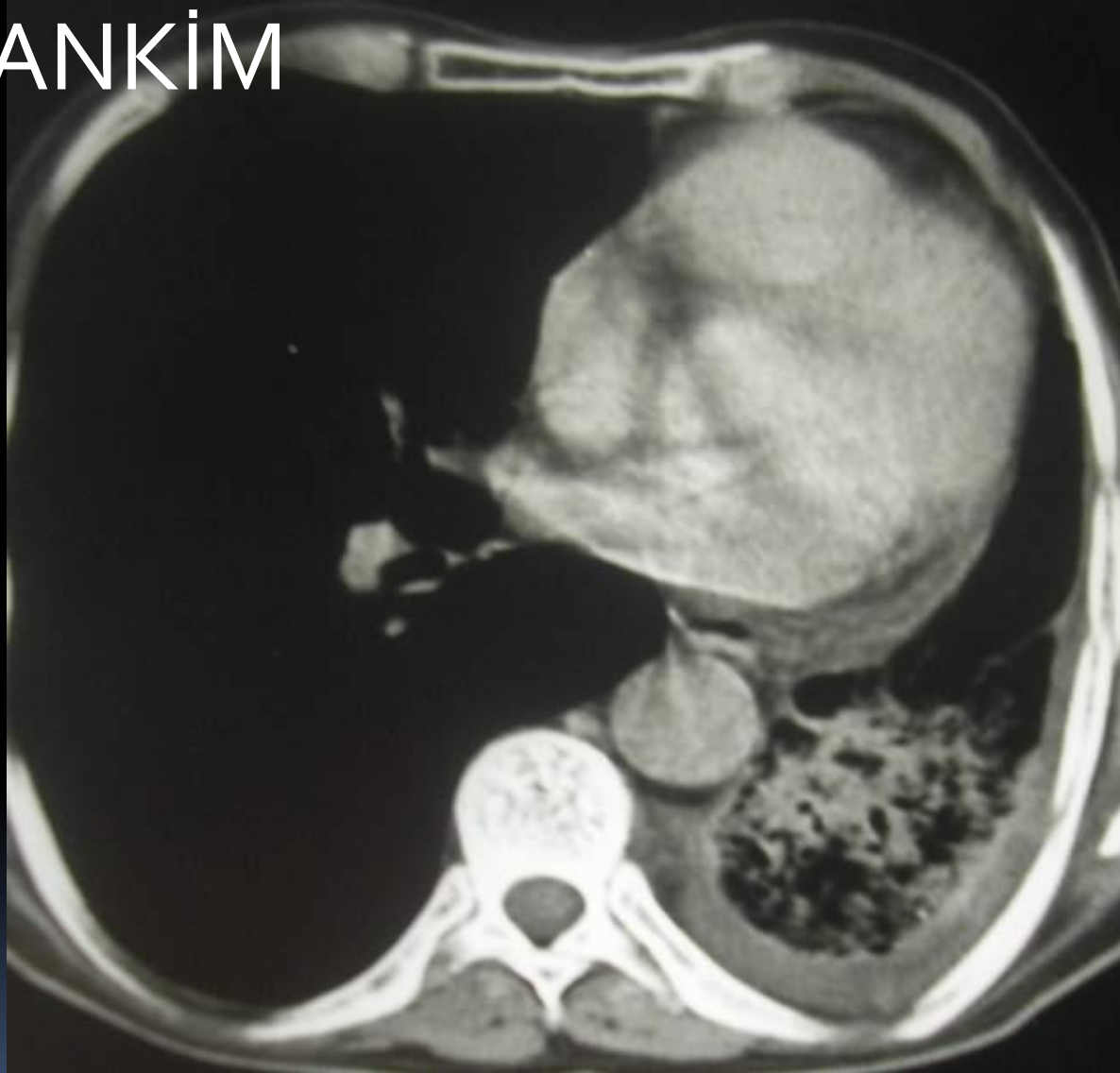
MPM

# PLEVRA

PLEVRA BAZEN BİR ŐEY  
SÖYLEMEZ

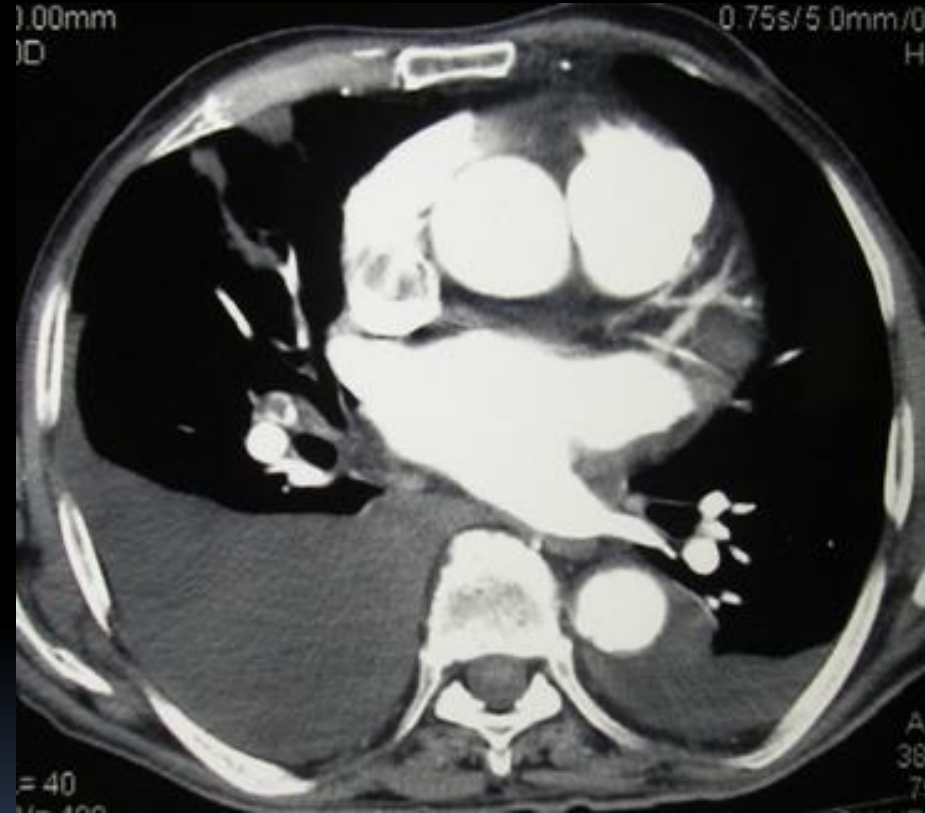
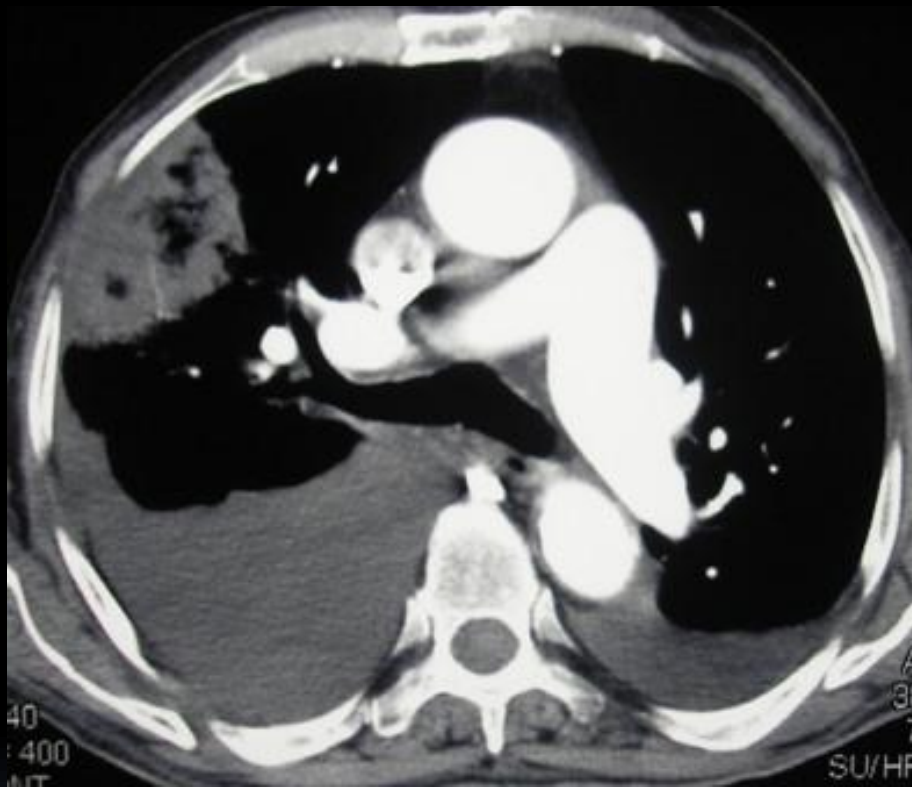


PARANKİM



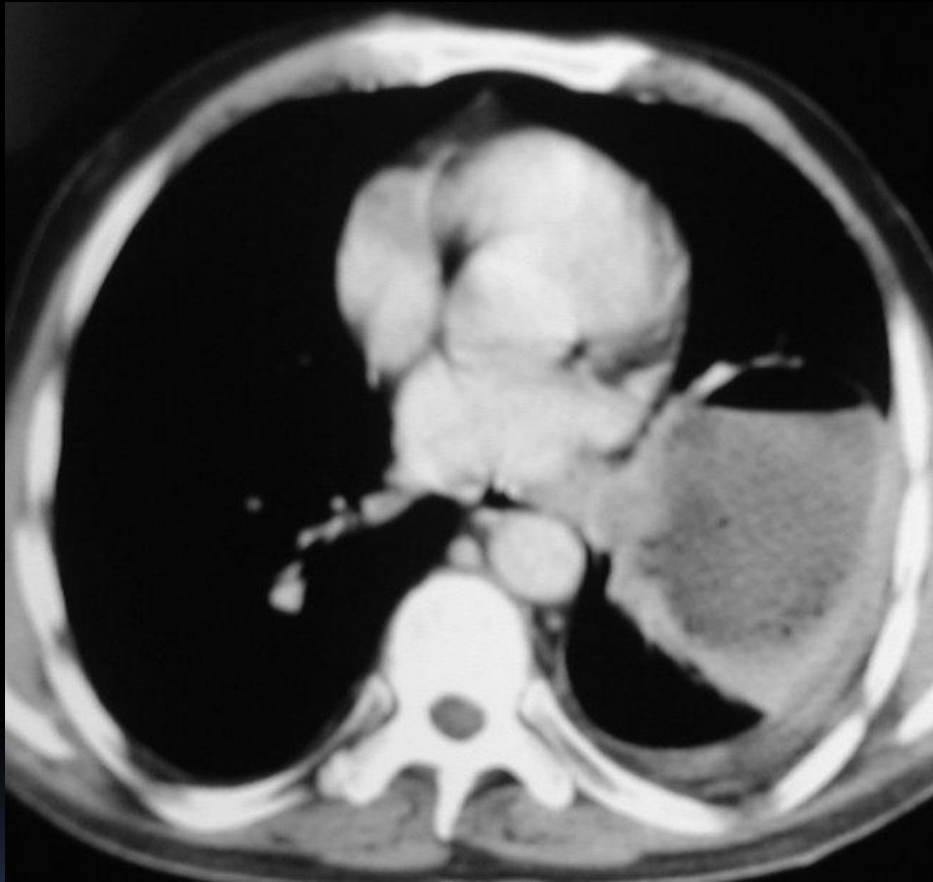
PARAPNÖMONİK PLÖREZİ

# PARANKİM

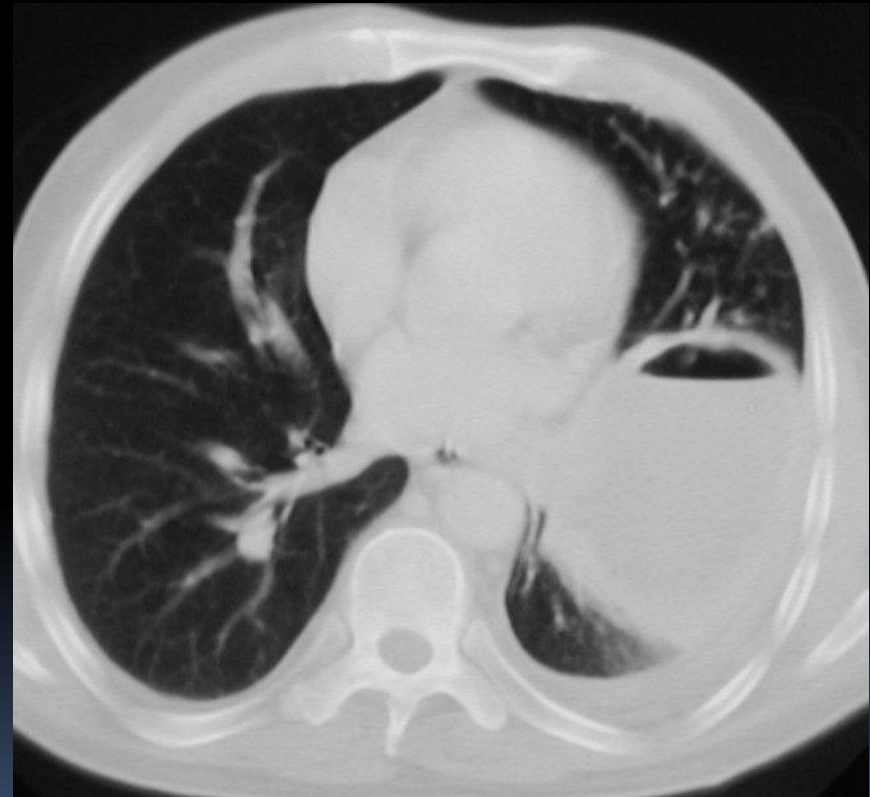


# PULMONER EMBOLİ

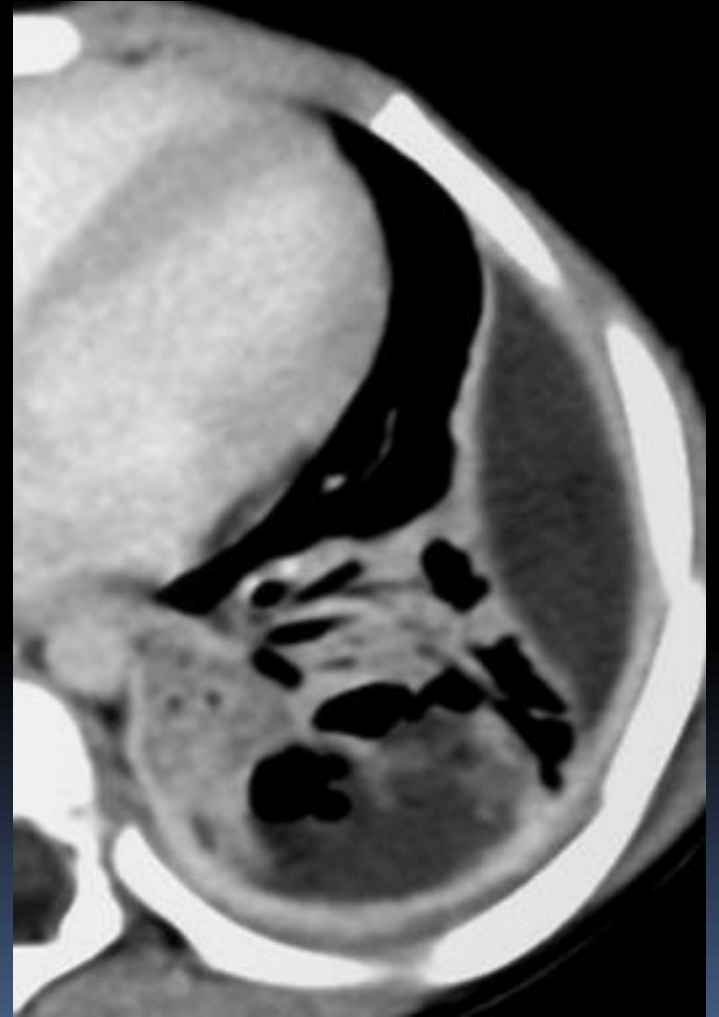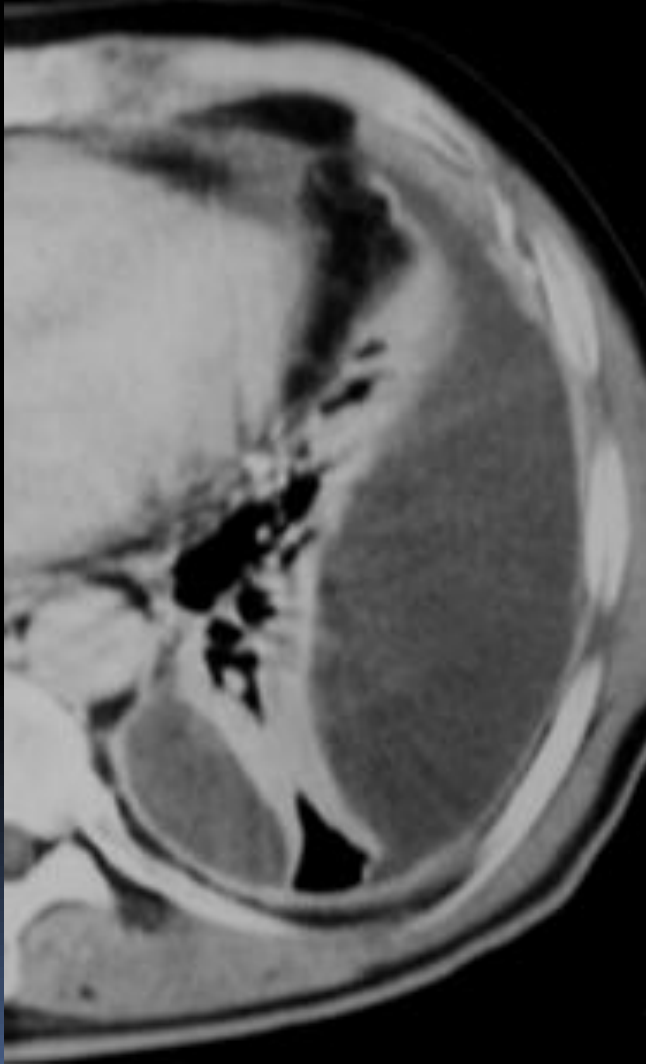
PARANKİM



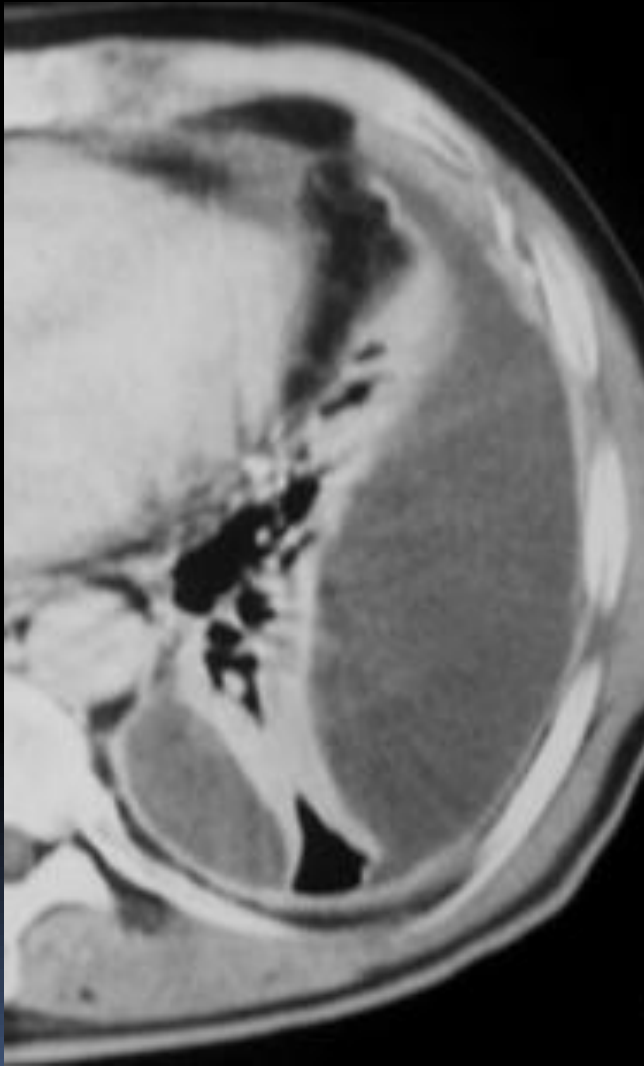
ABSE



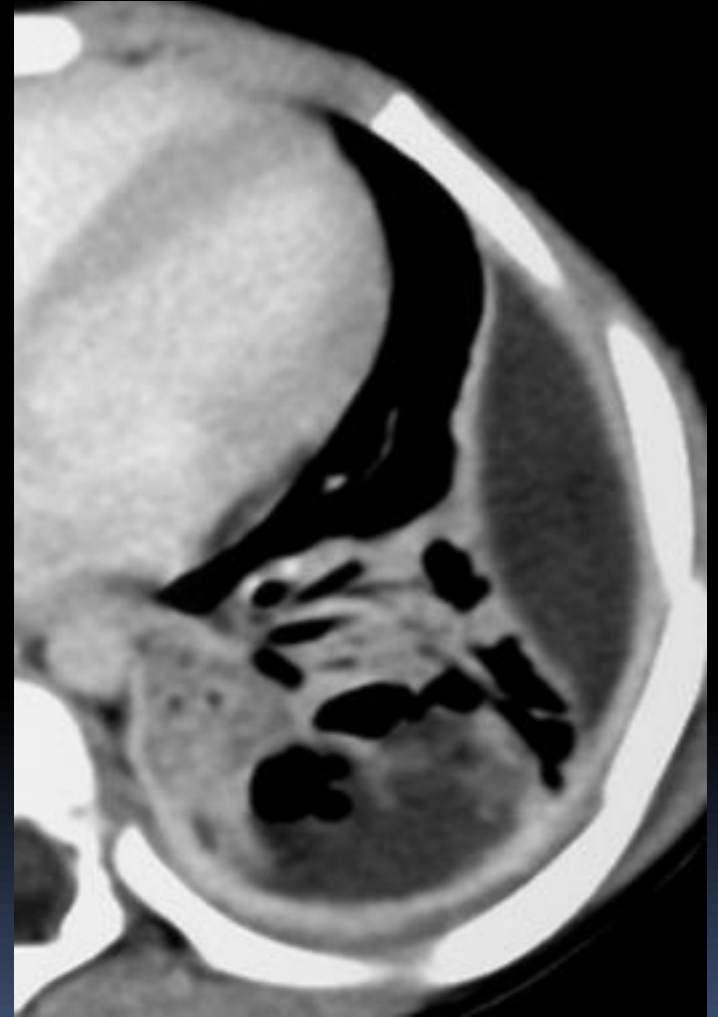
# EKSTRAPLEVRAL YAĞ



# EKSTRAPLEVRAL YAĞ

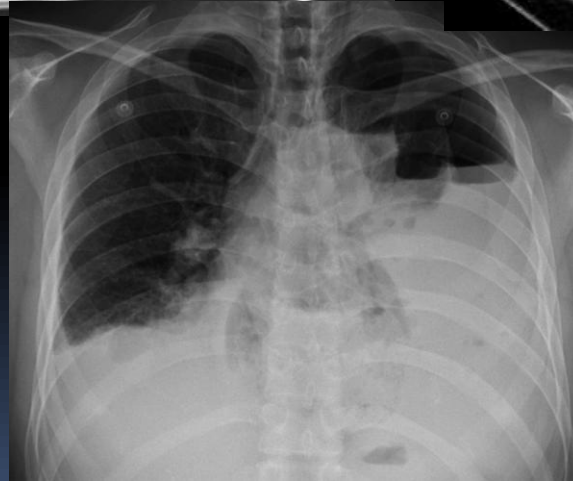
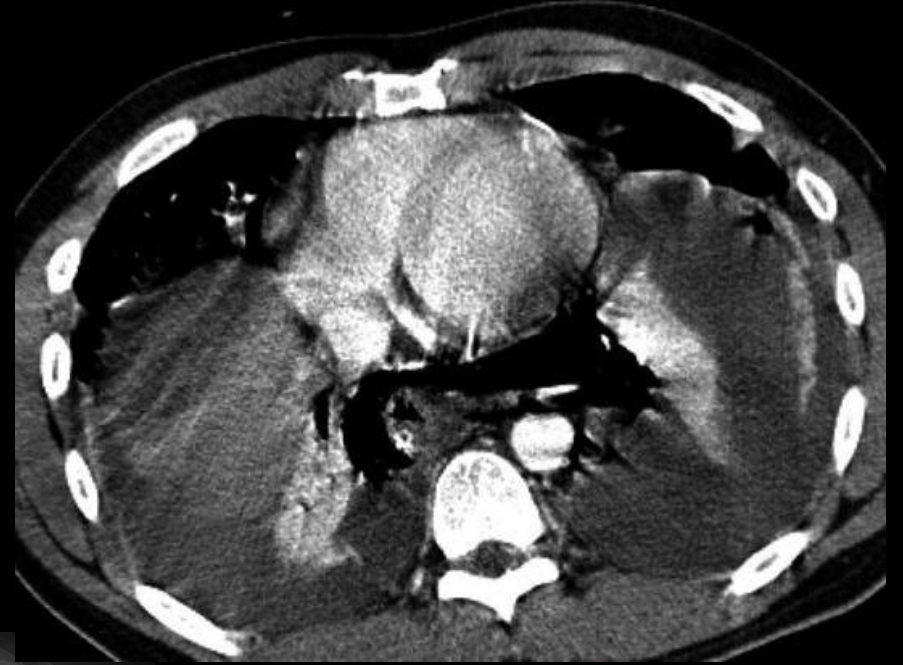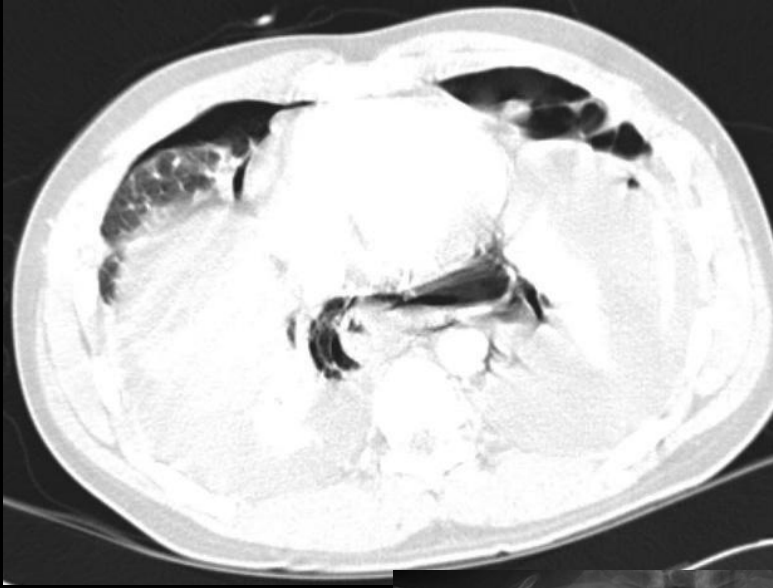


MPM



AMPİYEM

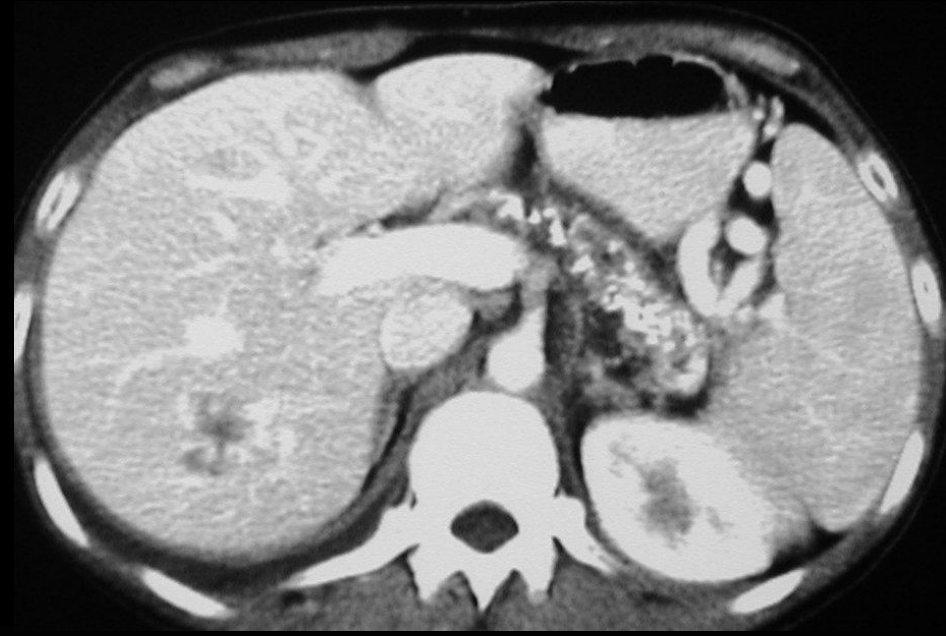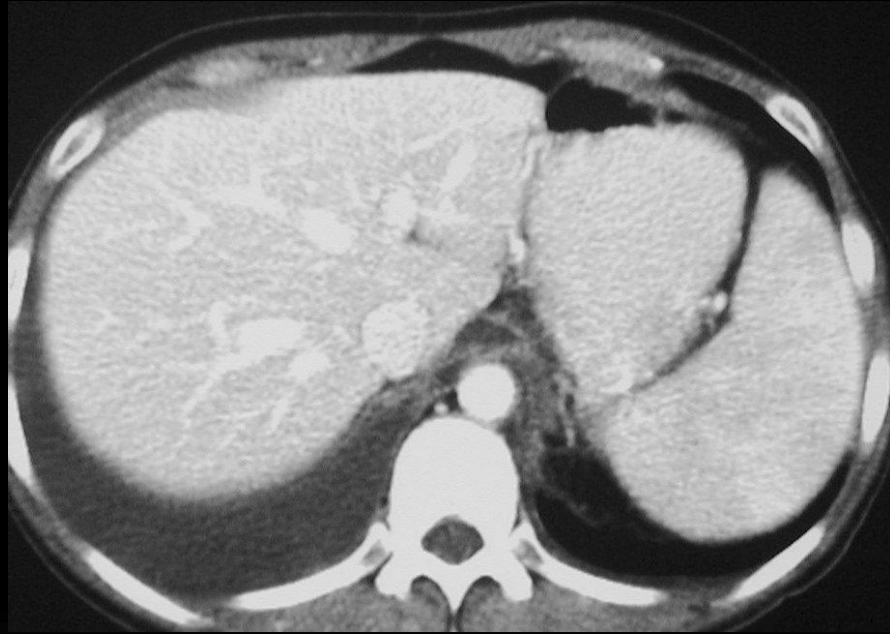
# MEDIASTINUM



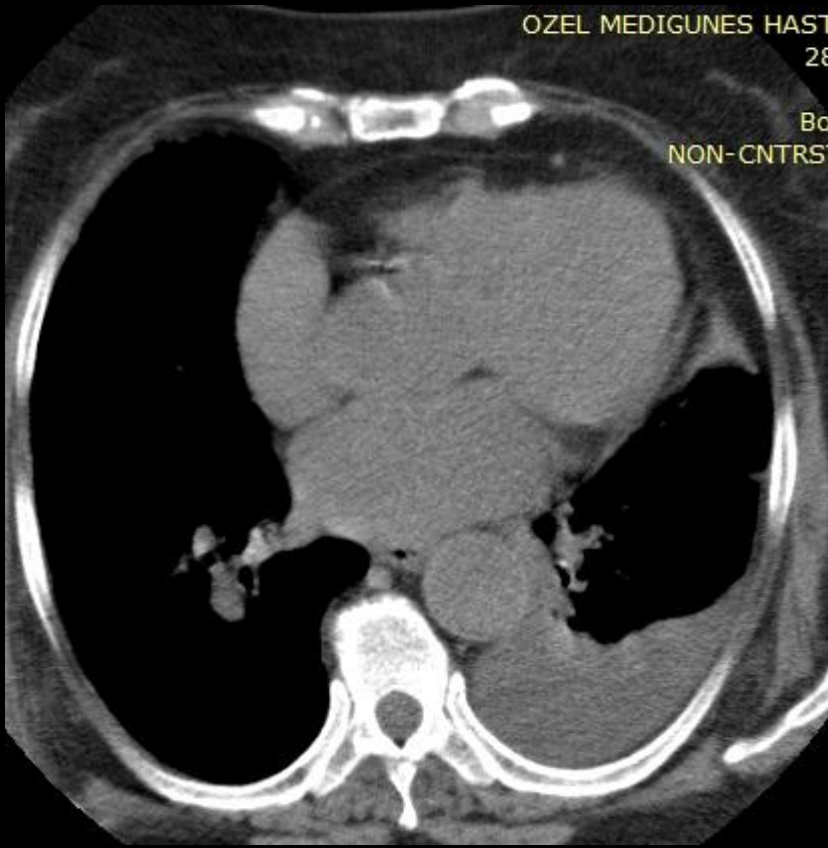
ÖZOFAGUS PERFORASYONU (BOERHAAVE SENDROMU)



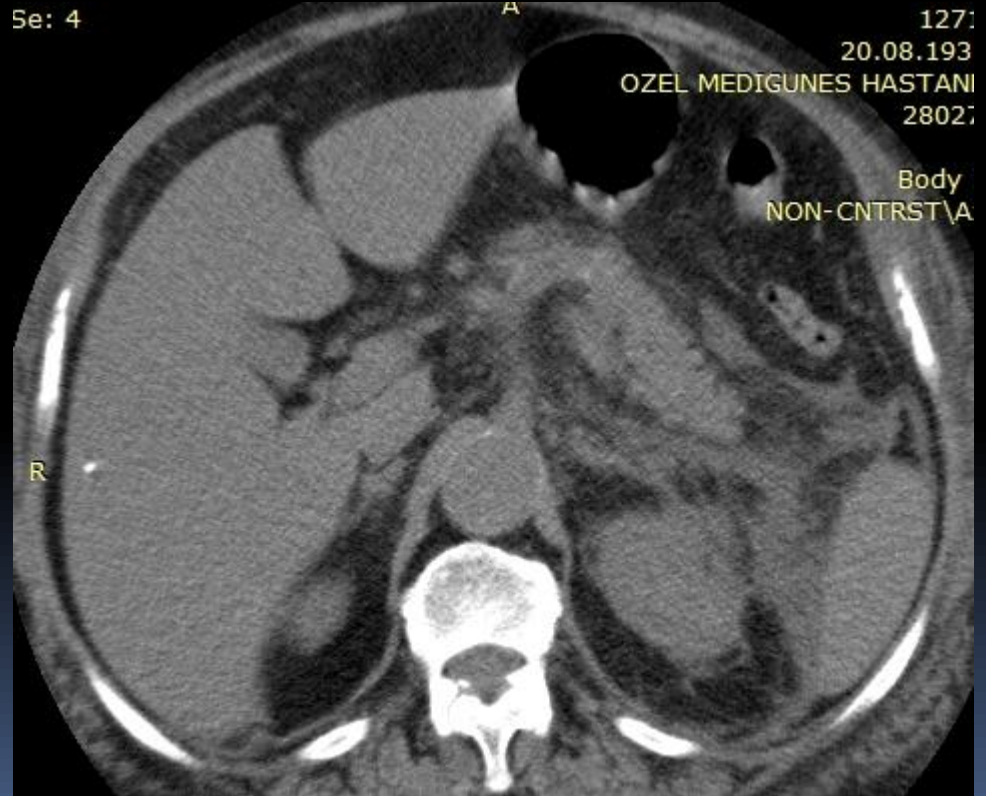
# ABDOMEN



KRONİK PANKREATİT



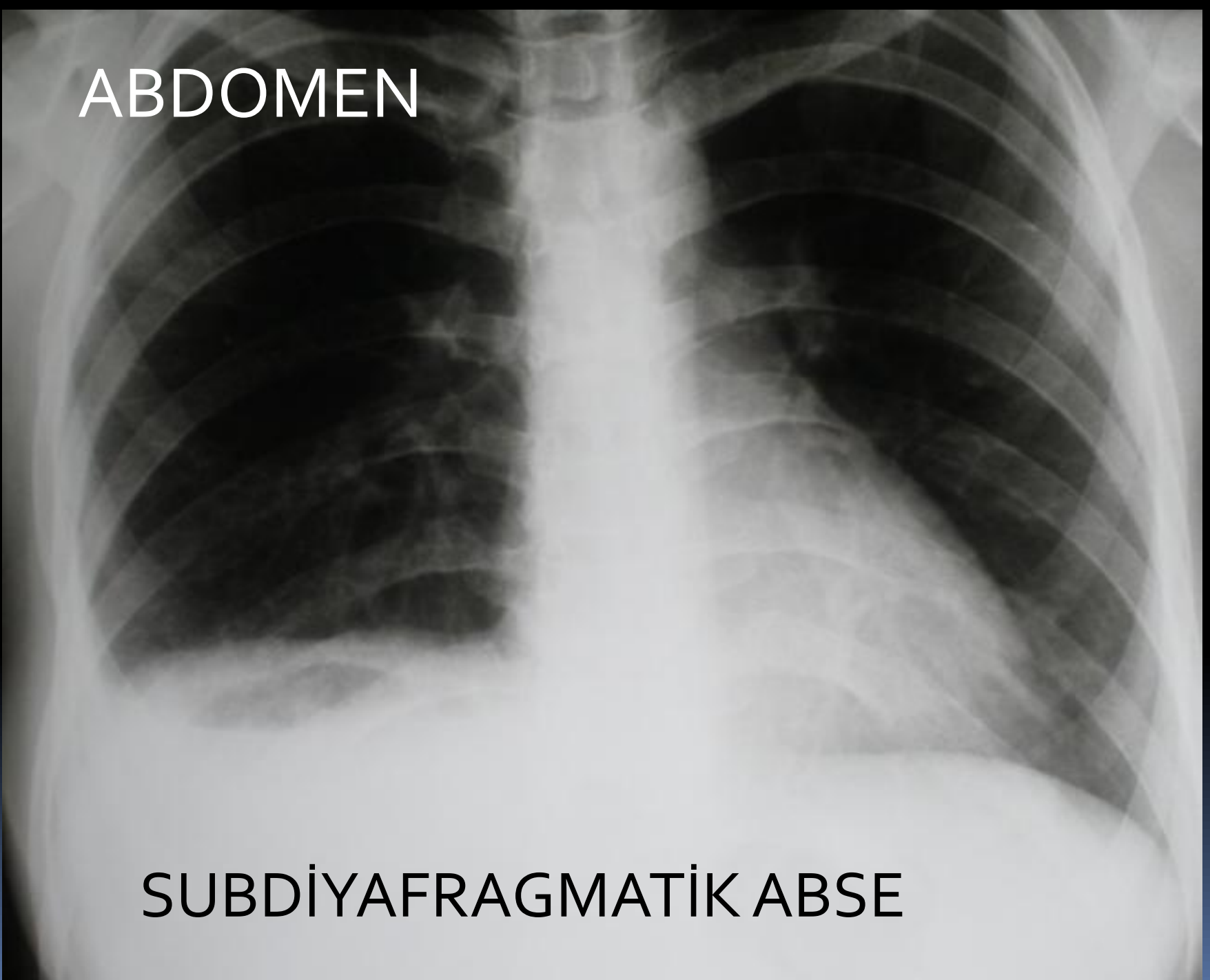
# ABDOMEN



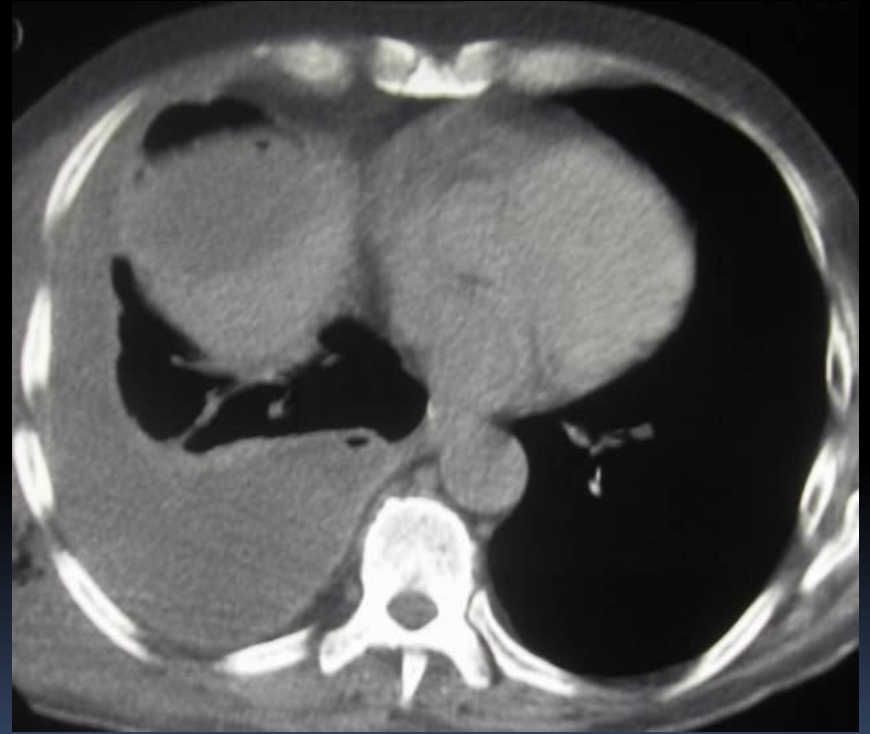
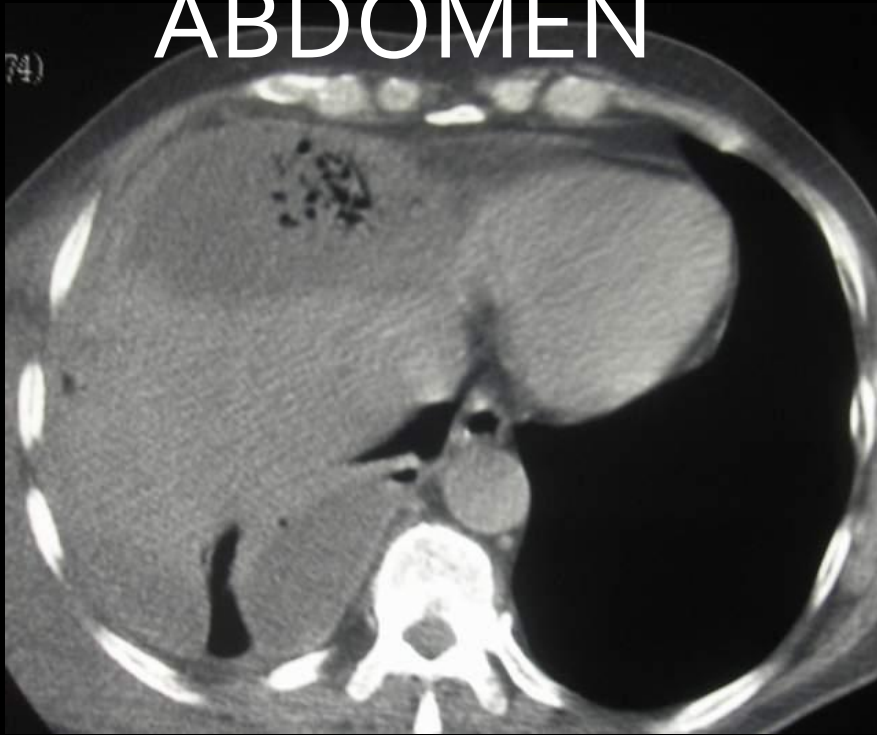
AKUT PANKREATİT

ABDOMEN

SUBDİYAFRAGMATİK ABSE

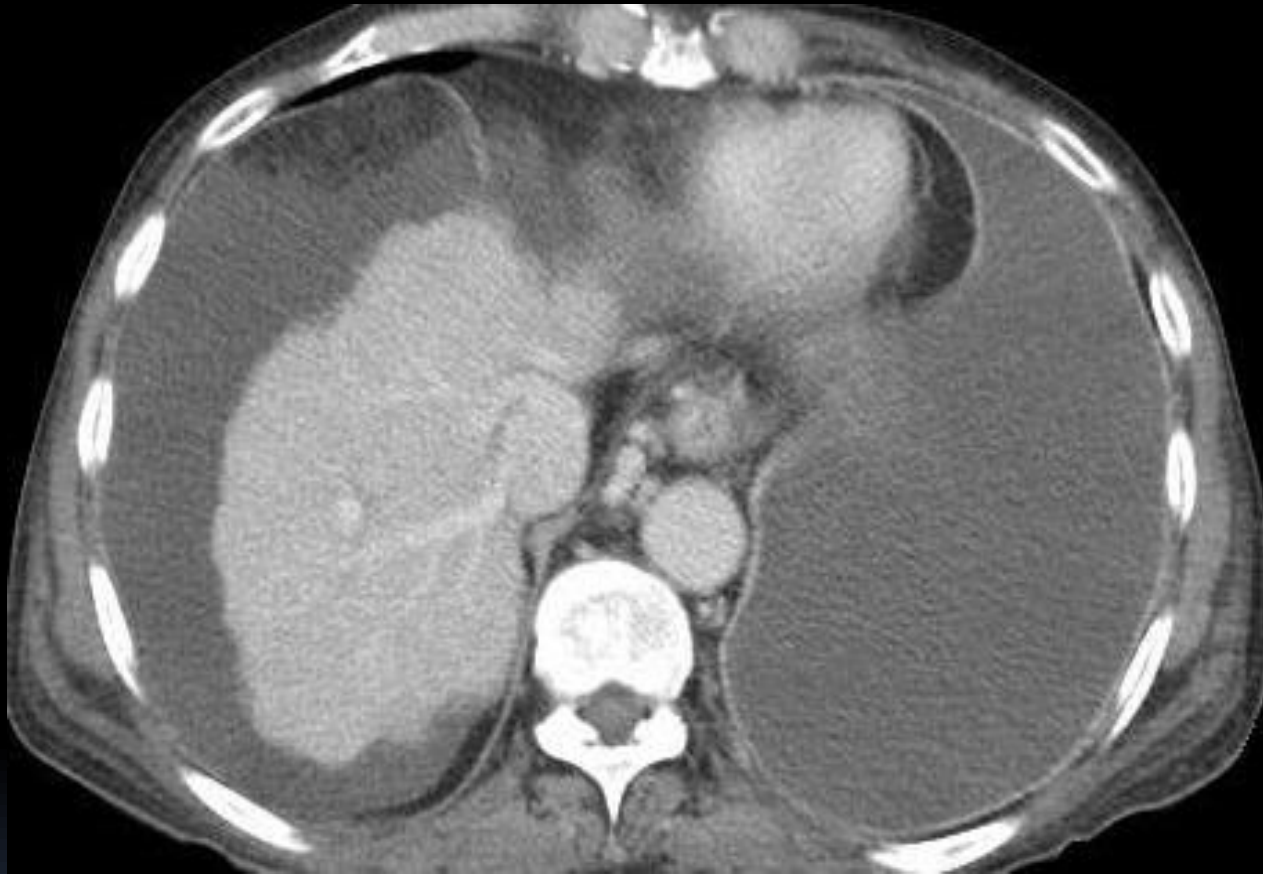

# ABDOMEN



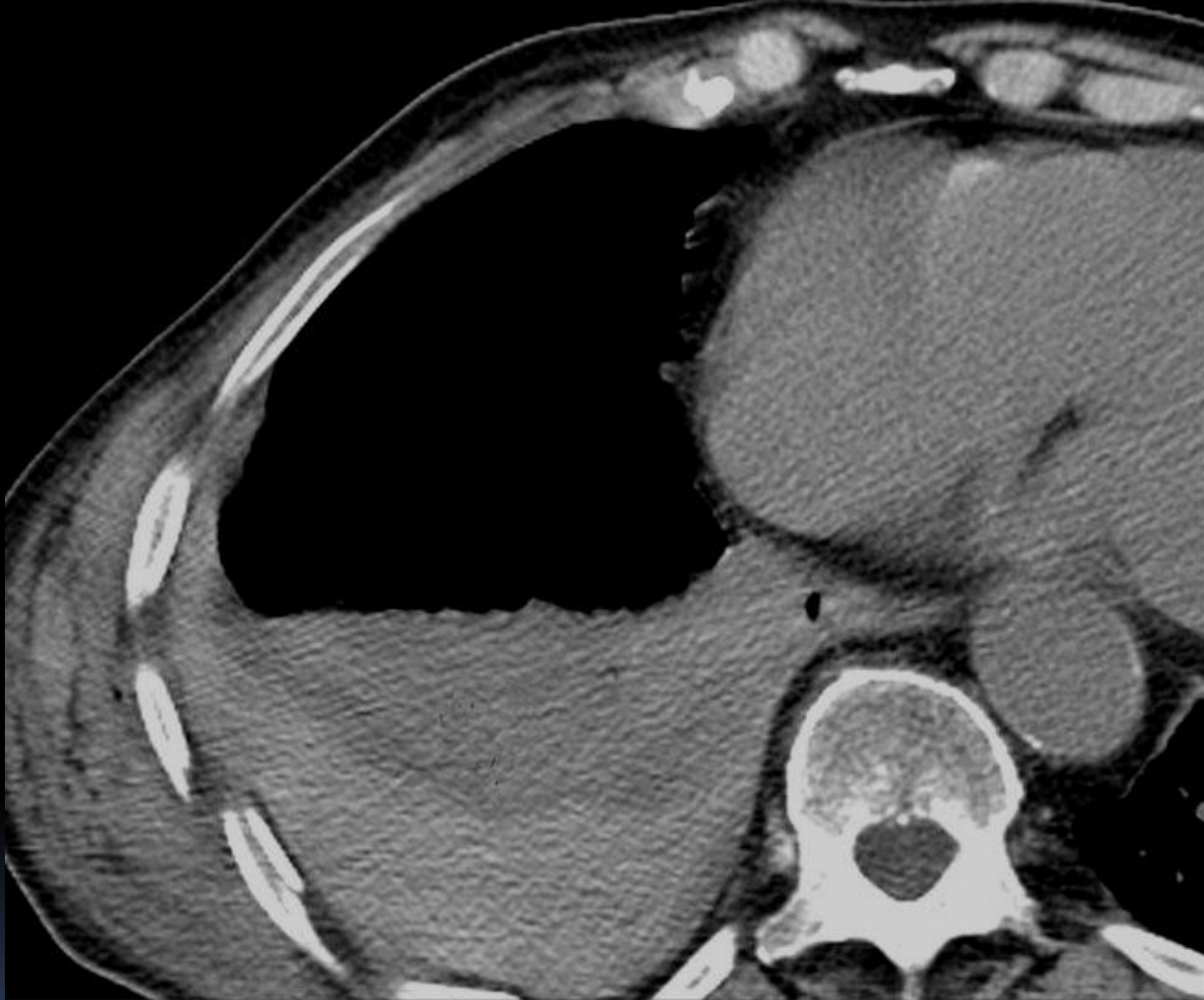SUBDİYAFRAGMATİK ABSE

ABDOMEN



HEPATİK HİDROTORAKS

# EKSÜDA-HEMATOM AYIRIMI



HEMATOM SIVI-SIVI SEVİYESİ

Seri: Body 5.0  
No: 4  
Tarih: 06.09.2018  
Saat: 21:33:23  
Pozisyon: FFS  
Oryantasyon: L/P  
Modalite: CT

İmaj No: 41  
Saat: 21:31:12

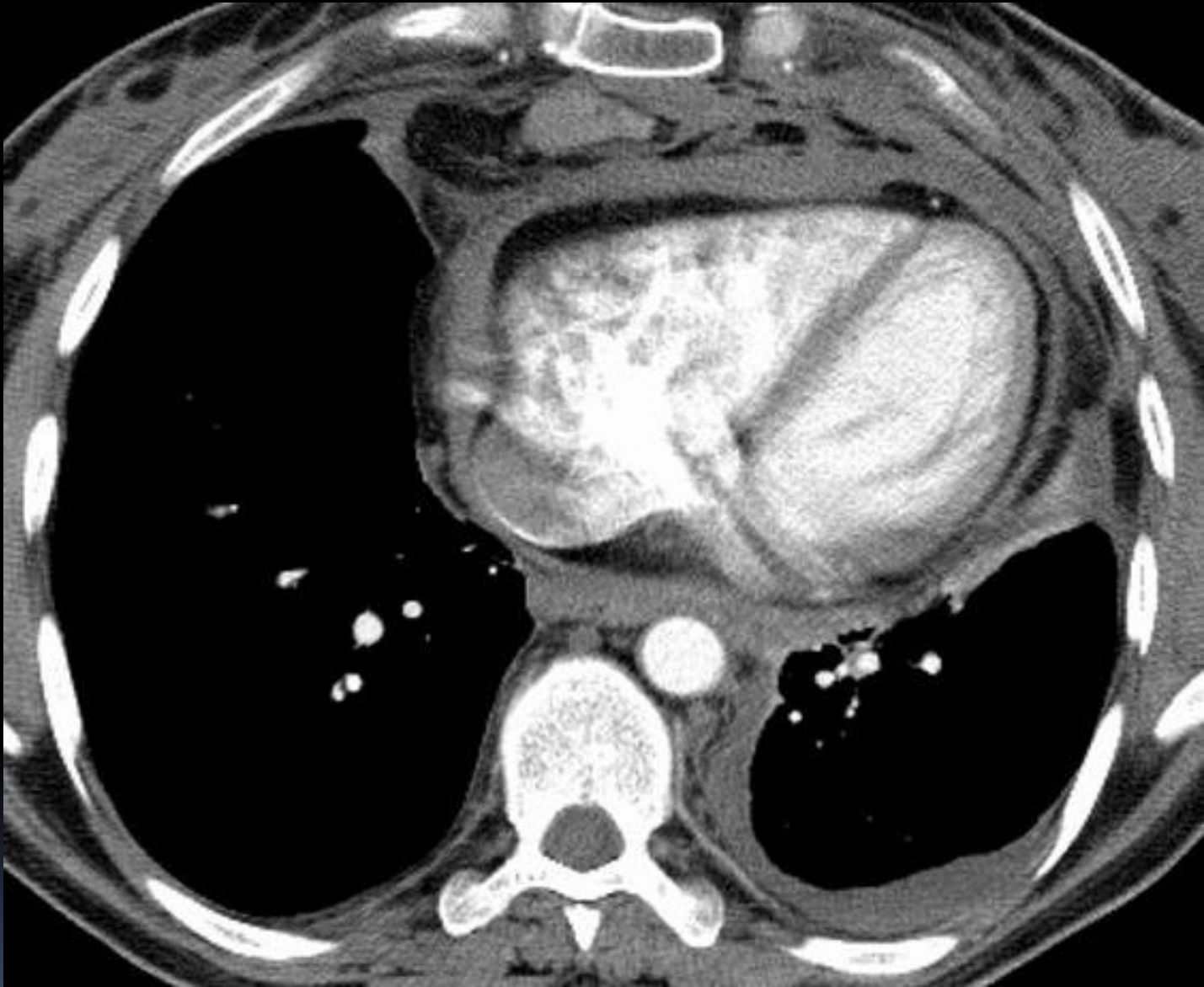
ST: 5.0  
E: 164  
ET: 500  
KVP: 120  
AST: 10.0

HEMATOM SIVI-SIVI SEVİYESİ

# PLEVRAL + PERİKARDİAL SIVI

- Hidrostatik ödem
- İnfeksiyon
- İlaçlar
- Metastaz
- Travma
- Kollajen-vasküler hastalıklar (lupus)
- Dressler sendromu
- İdiopatik

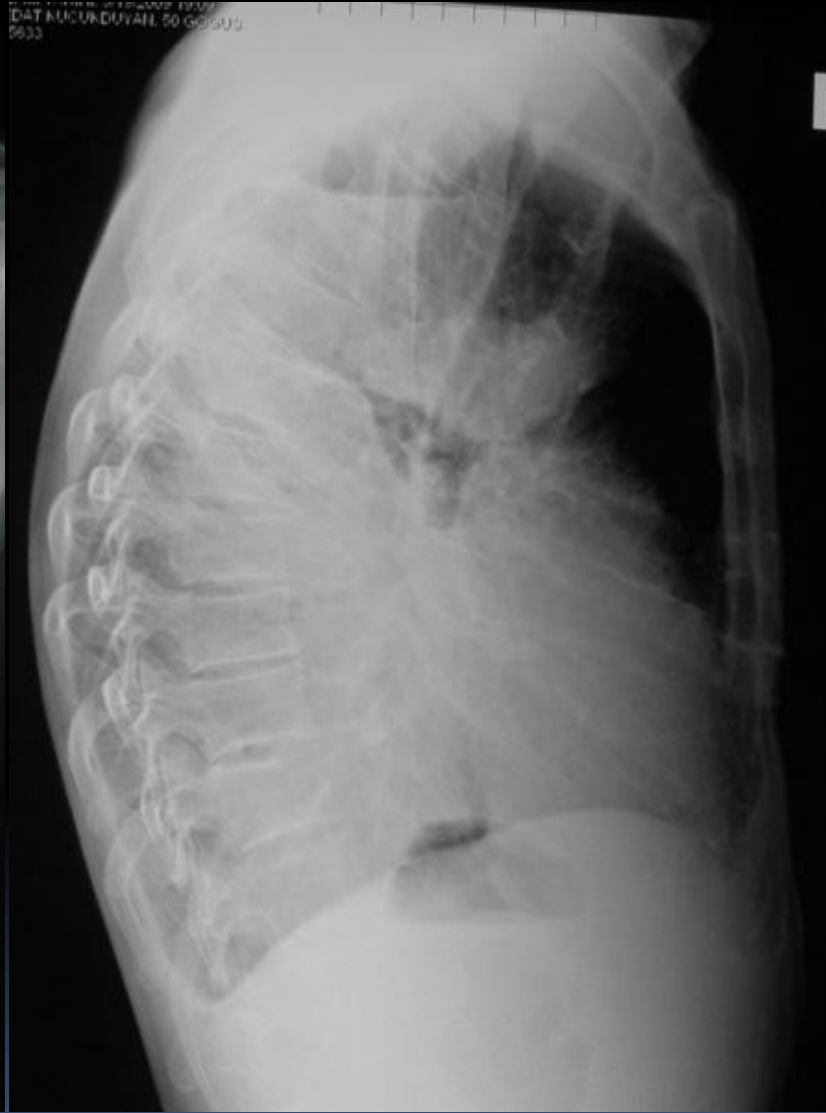
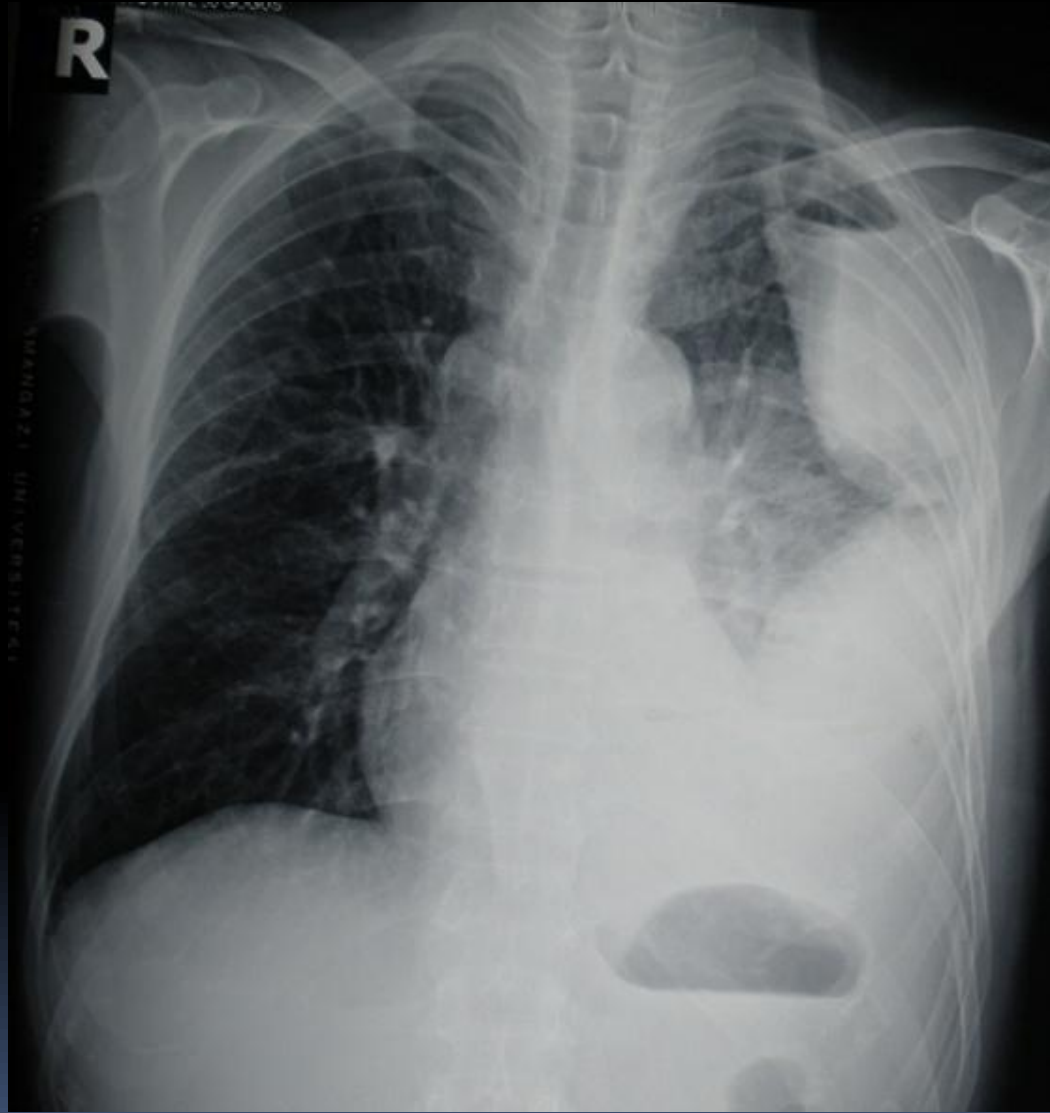


SLE

# AMPIYEM

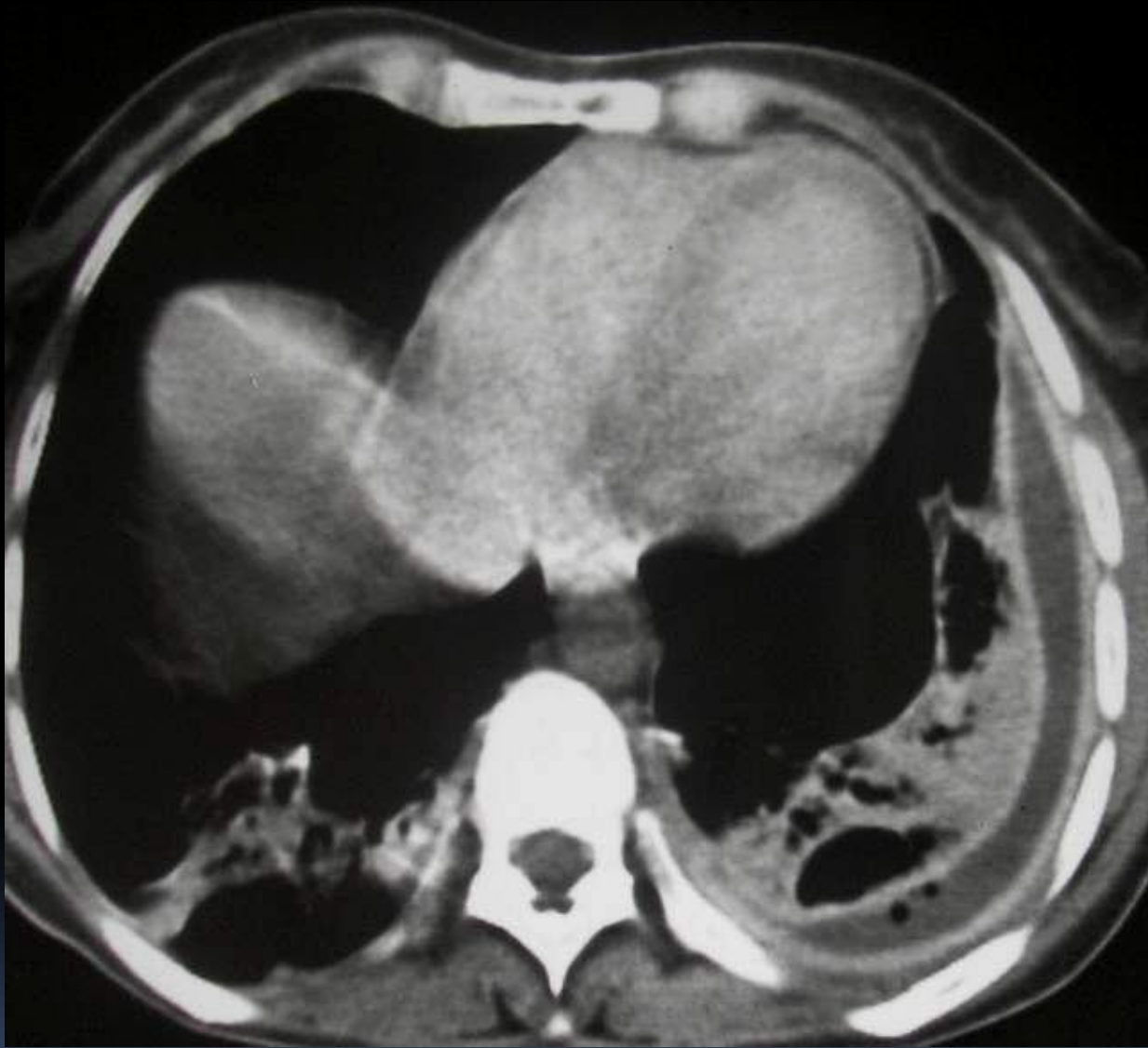
- En iyi tanısal ipucu: Ateşli hastada lokalize SIVI
- Radyografi
  - Konveks kontur
  - Hava içeren ampiyem ile plevraya dayanan abse ayrımı zor olabilir



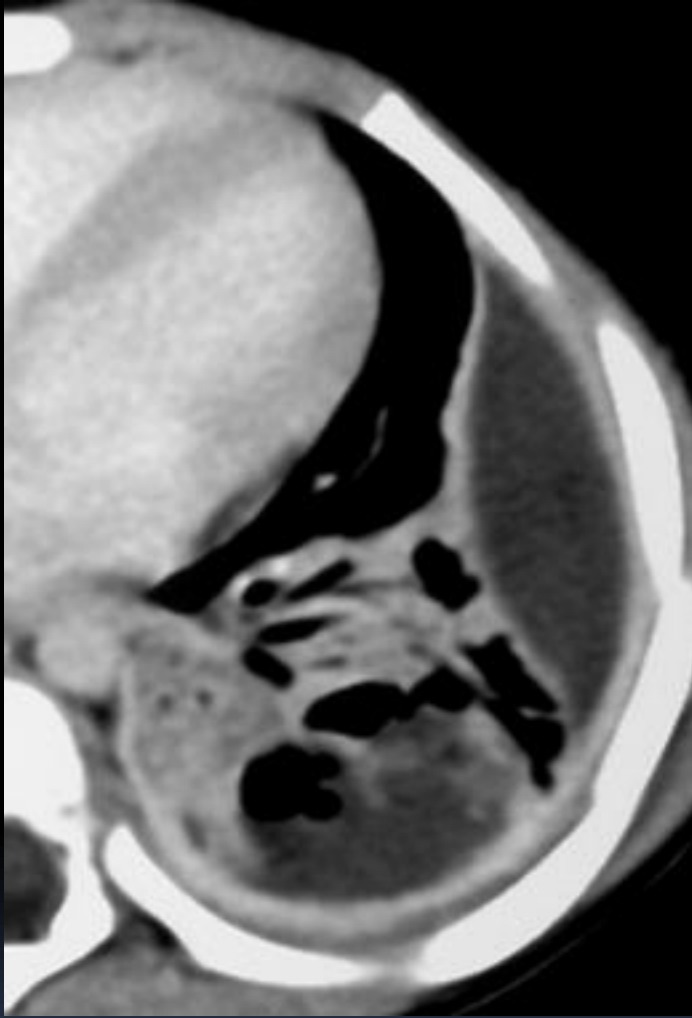
AMPIYEM

# AMPİYEM

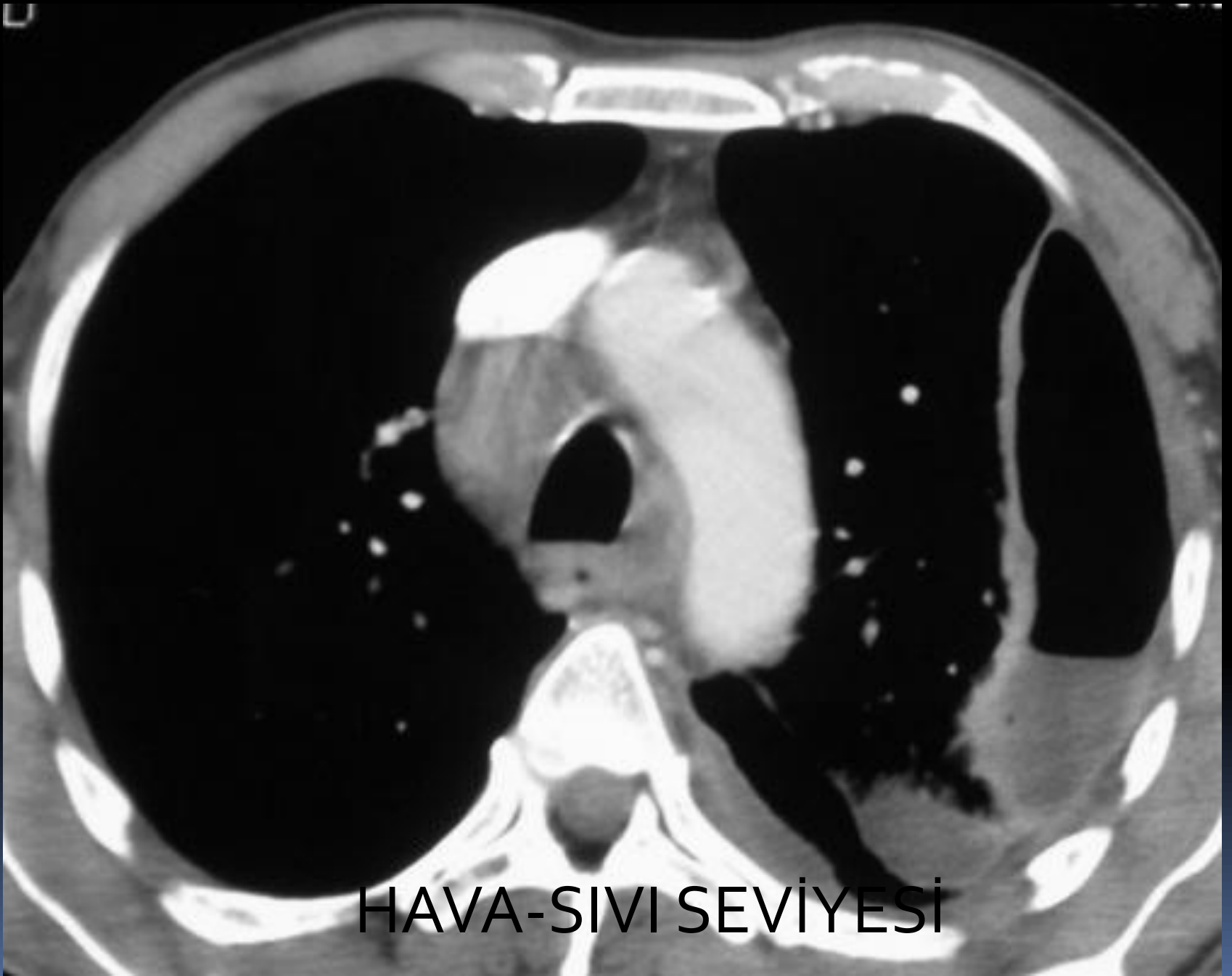
- Oval veya mercek şeklindedir ve komşu akciğerden keskin bir sınırla ayrılır
- Plevra yaprakları düzgün ve aynı kalınlıkta
- Komşu akciğer ve damarlarda yer değiştirme (yeteri kadar büyükse)
- Göğüs duvarının şekline genellikle uyar
- Depandan olmayabilir
- Ayrılmış plevra yaprakları (split-pleura)



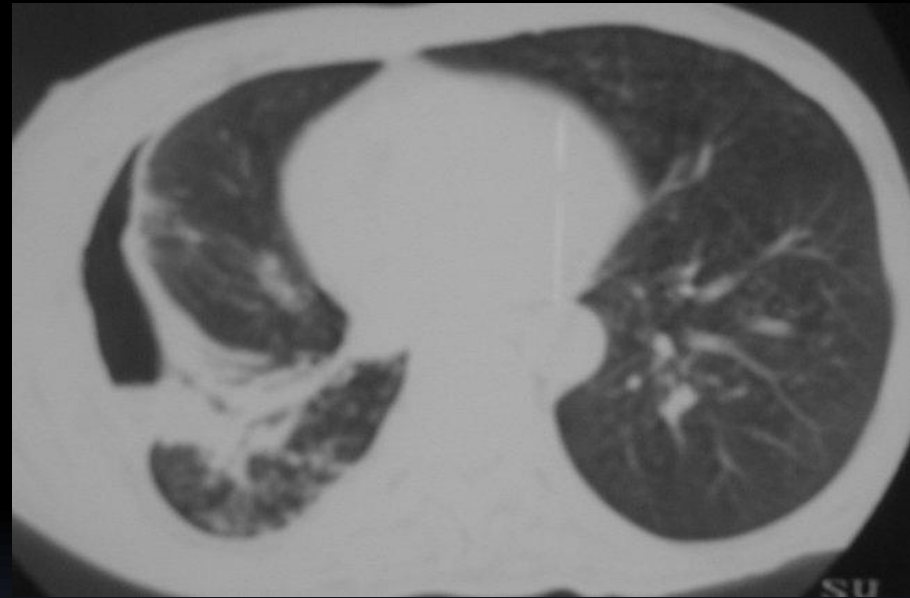
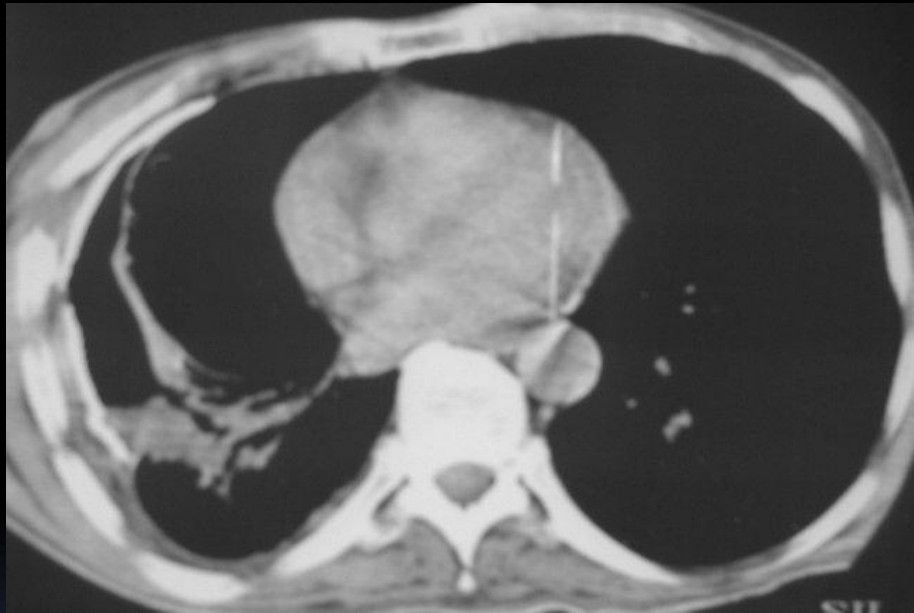
AMPIYEM



AMPIYEM

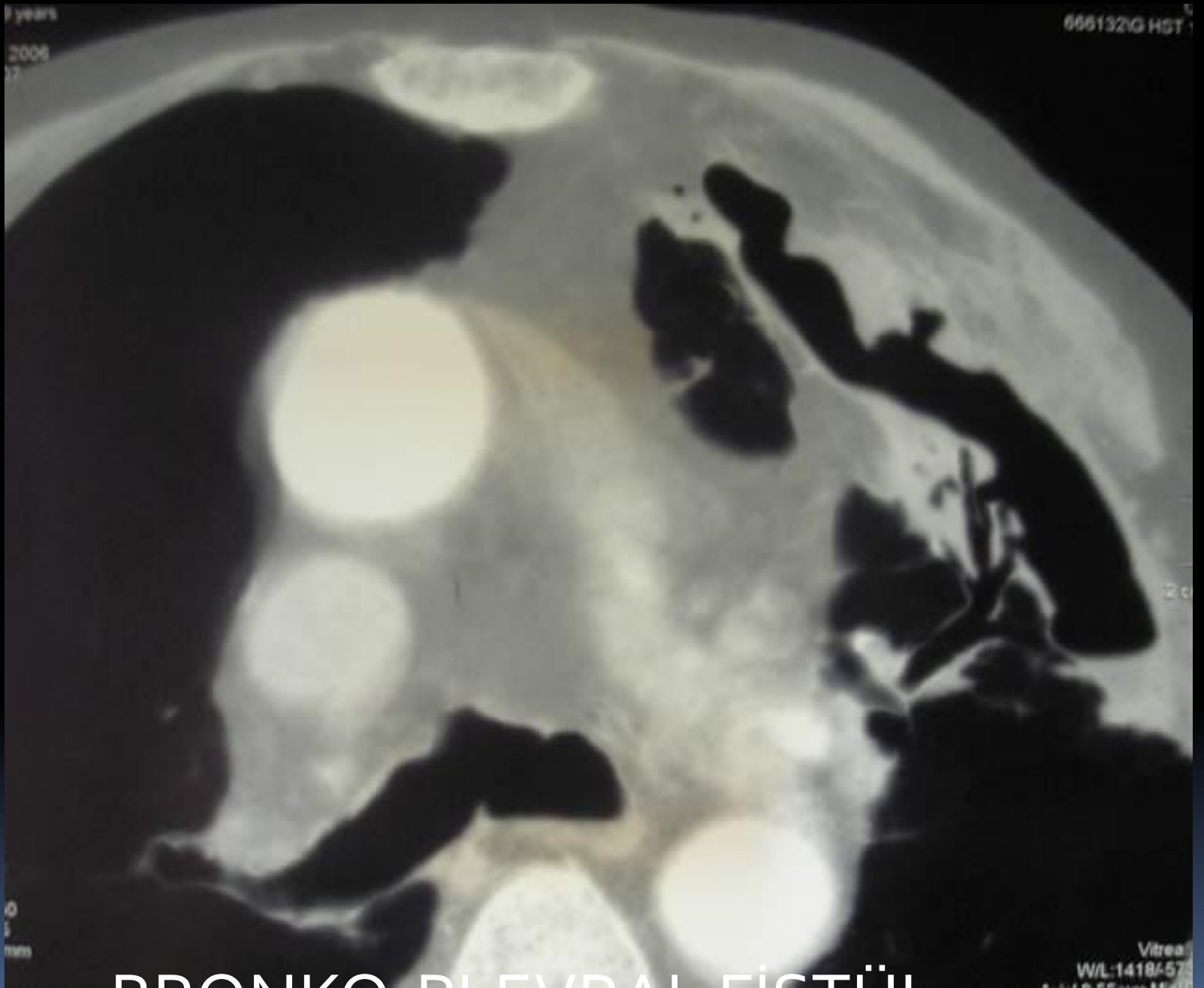


HAVA-SIVI SEVİYESİ



BRONKO-PLEVRAL FİSTÜL





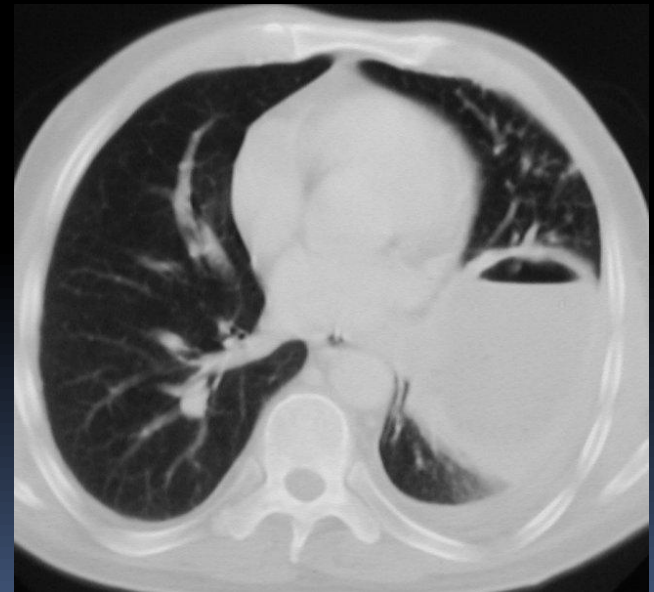
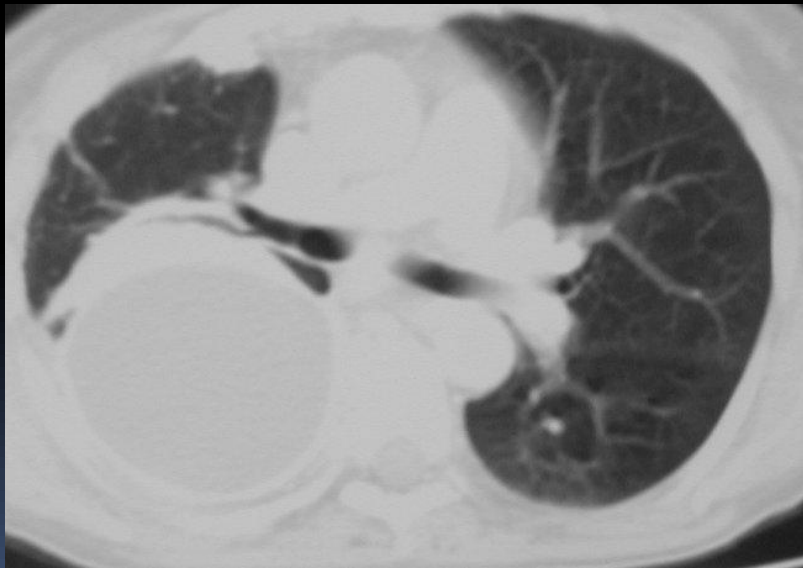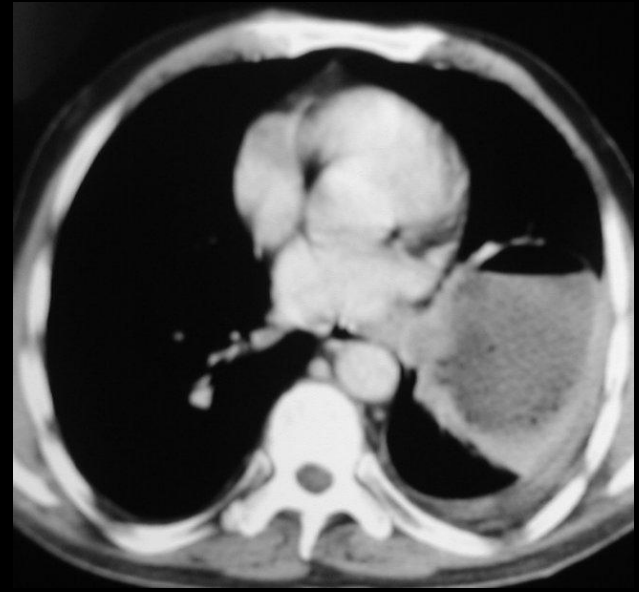
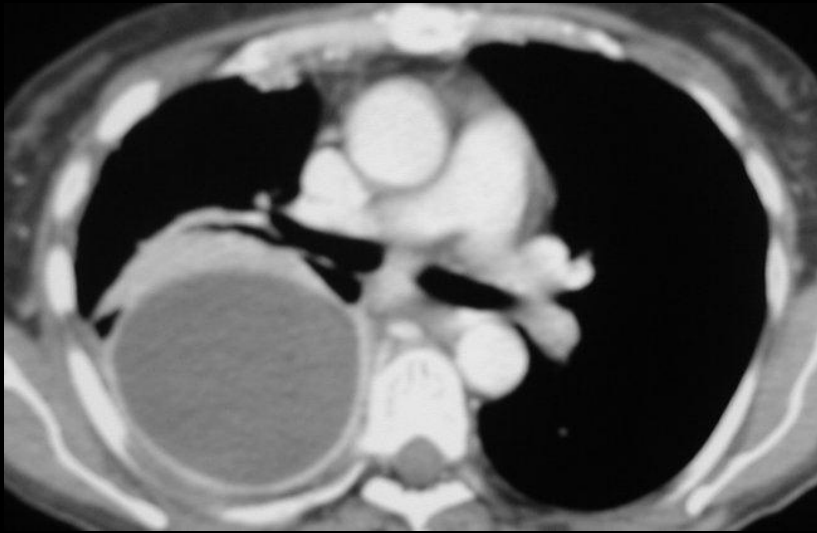
BRONKO-PLEVRAL FİSTÜL

# AMPİYEM

- Oval veya mercek şeklinde
- Komşu akciğerden keskin bir sınırla ayrılır
- Plevra yaprakları düzgün ve aynı kalınlıkta
- Komşu akciğer ve damarlarda yer deęiştirme (yeteri kadar büyükse)

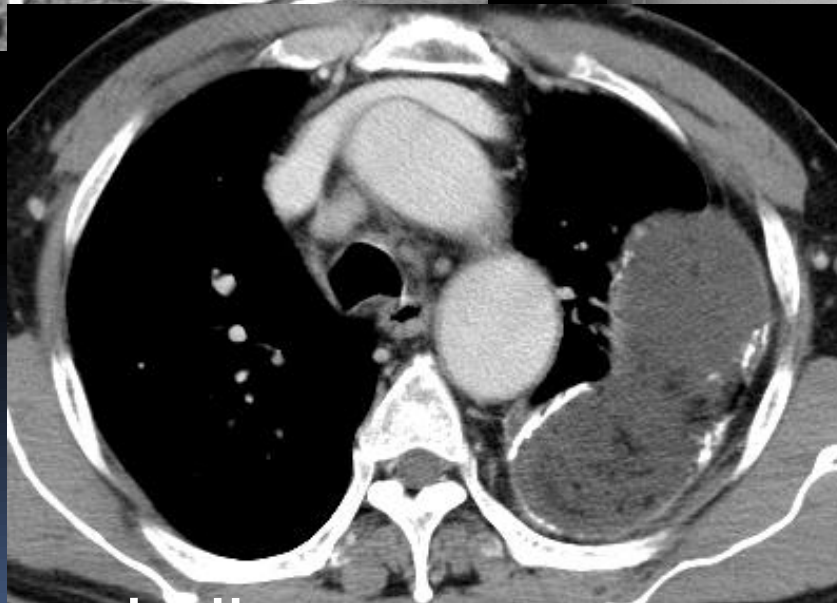
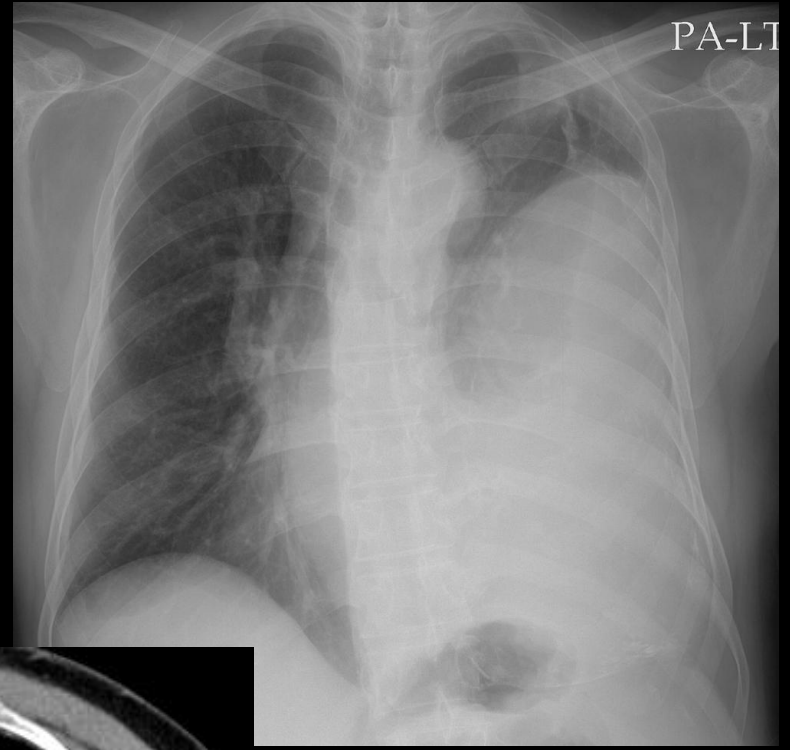
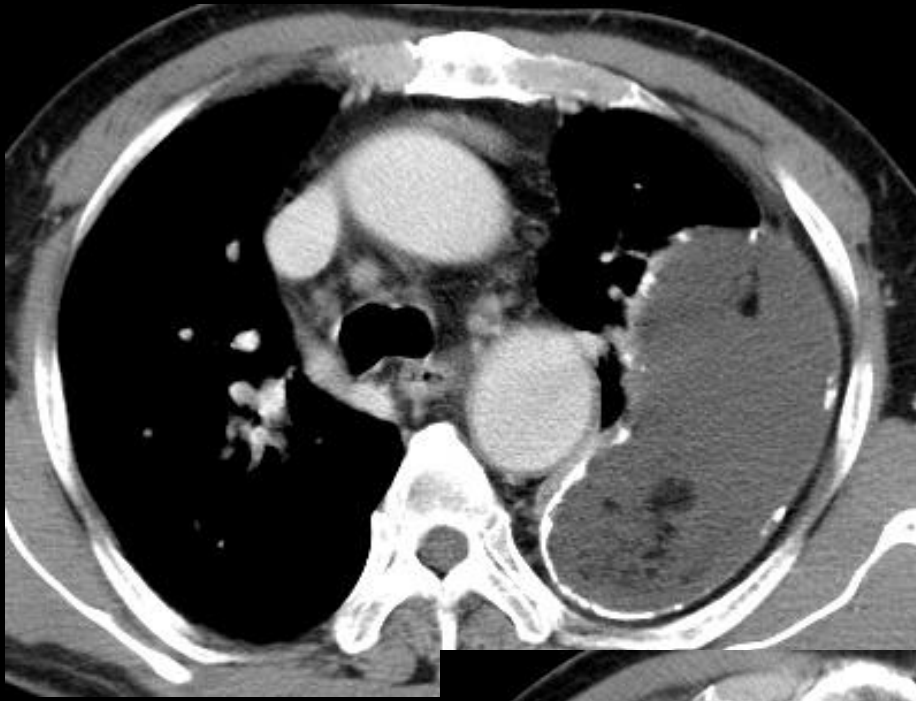
# ABSE

- Yuvarlak
- Konturları keskin deęil
- Düzensiz kalınlıkta duvarlar
- Parankimdeki damarlarda yer deęişikliği olmaması

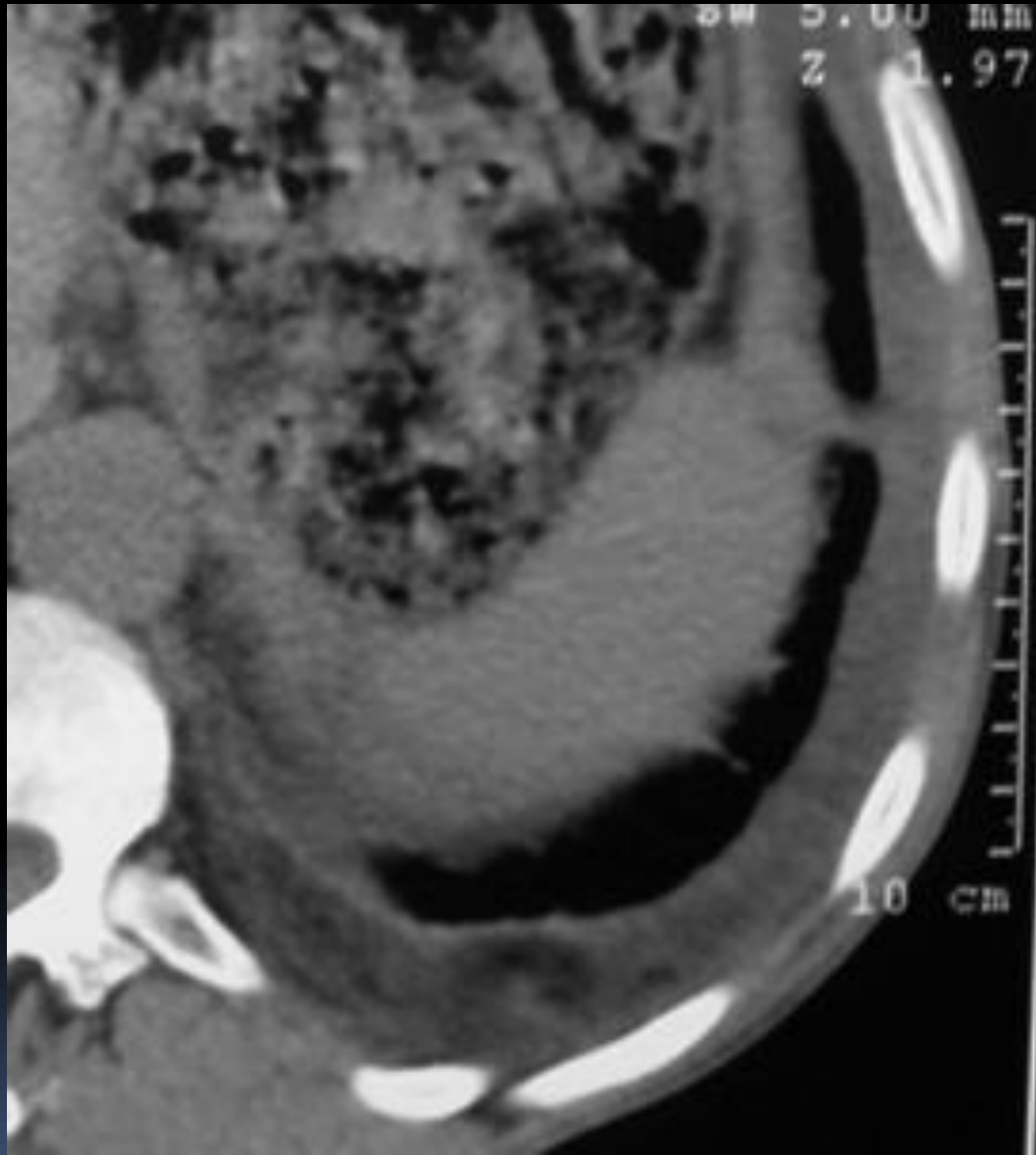


AMPIYEM

ABSE



PSÖDOŞİLÖZ PLEVRA SIVI



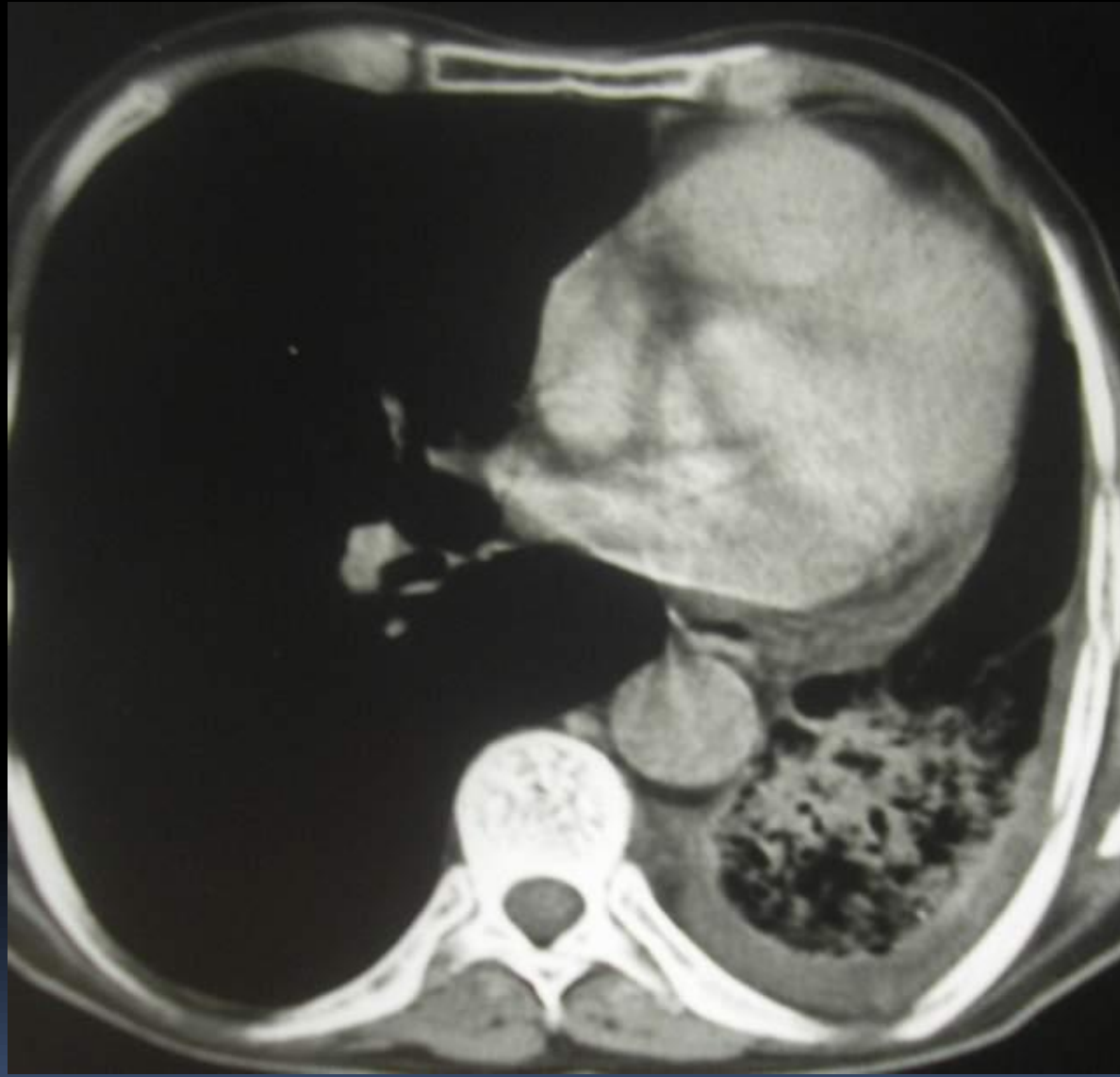
PSÖDOŞİLÖZ PLEVRA SIVI

# PARAPNÖMONİK PLEVRA L SIVI

- Basit PPS
  - Genellikle eksuda
  - Püy (-)
  - Normal glukoz ve Ph değeri
  - Kültür ve gram boyama (-)
- Komplike PPS
  - Kültür ve gram boyama (-)
  - Yüksek LDH seviyesi, düşük Ph, düşük glukoz değeri
- Komplike PPS göğüs tüpü ile drenaj gerektirir
  - Erken dönemde drene edilmezse loküle hale gelir ve perkutan drenaj işe yaramayabilir

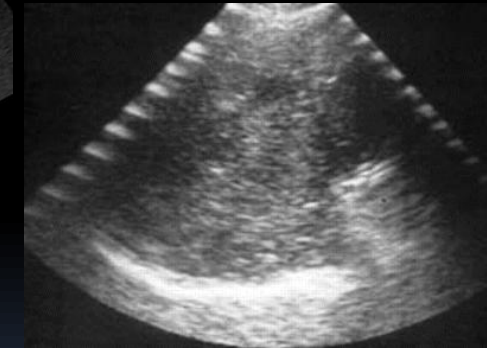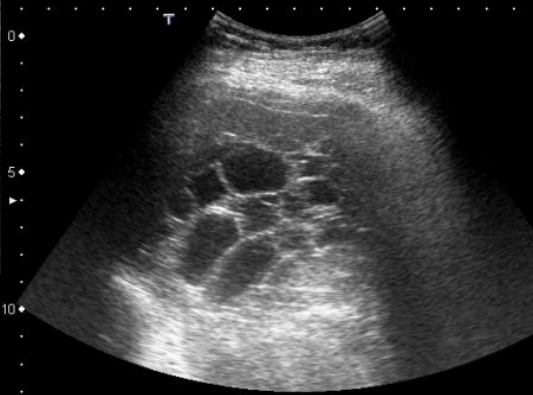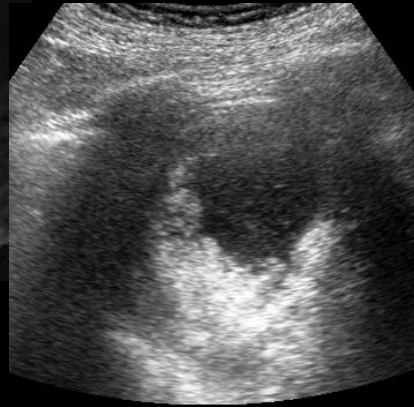
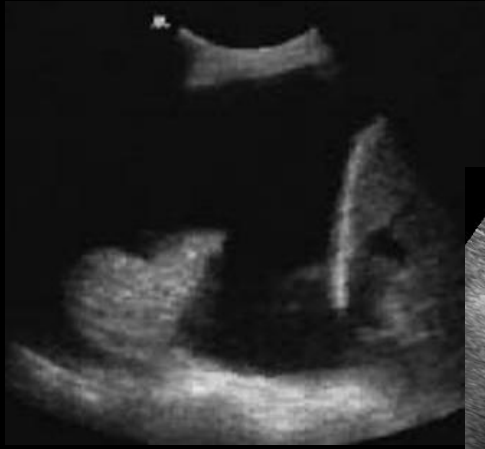# PARAPNÖMONİK PLEVRA SIVI

- US: En iyi tanısal veri elde edilir
  - Basit: Anekoik sıvı
  - Kompleks: Ekojenik debris, septalar, lokalize sıvı
- BT
  - Göğüs tüpü malpozisyonu, lokalize plevral sıvı, kaviter nekroz, abse, pürülan perikardit

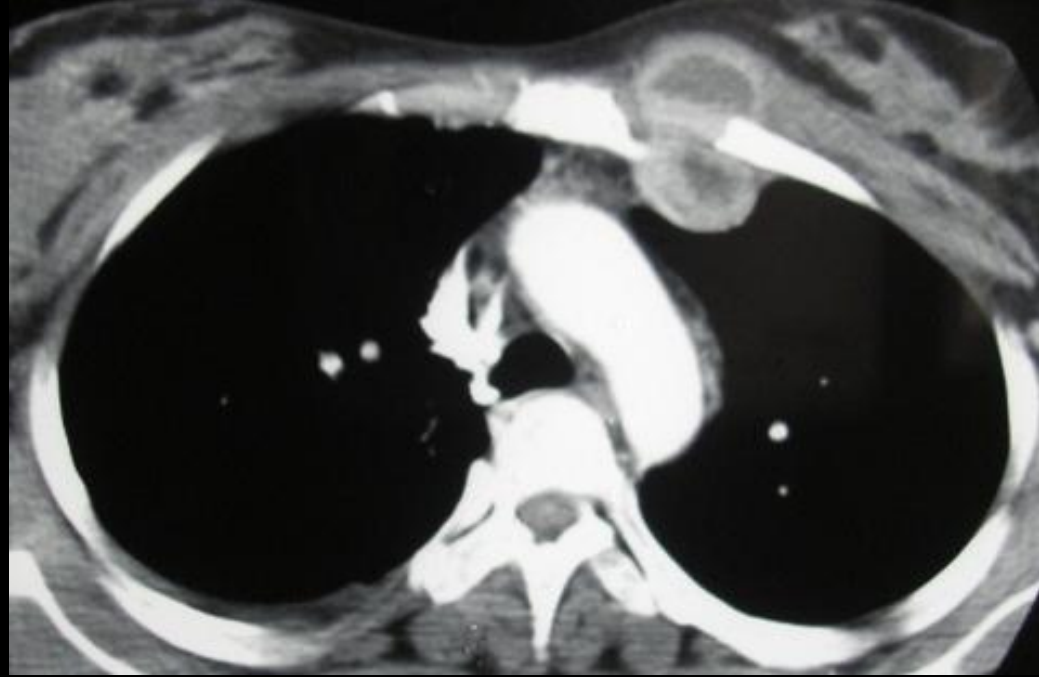
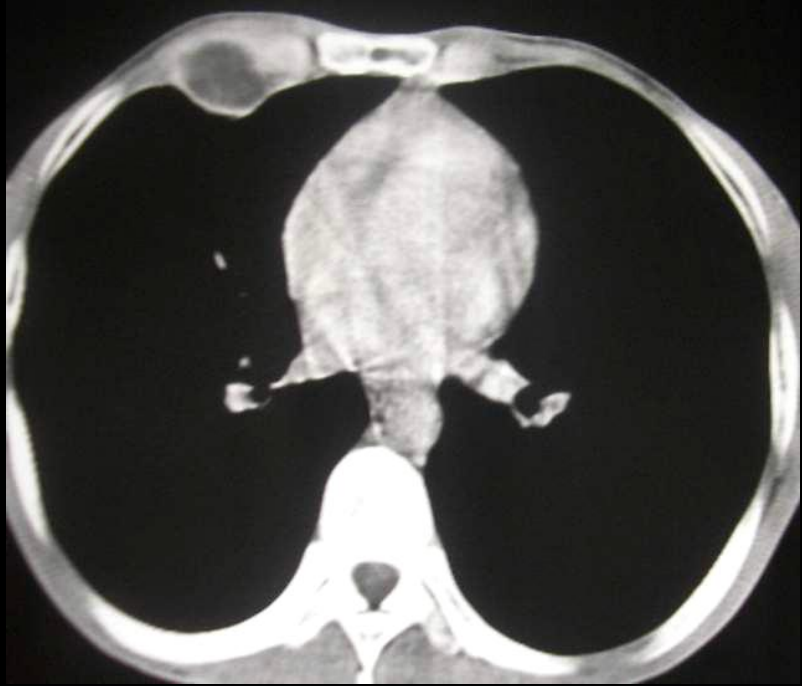

PARAPNÖMONİK PLEVRA SIVI





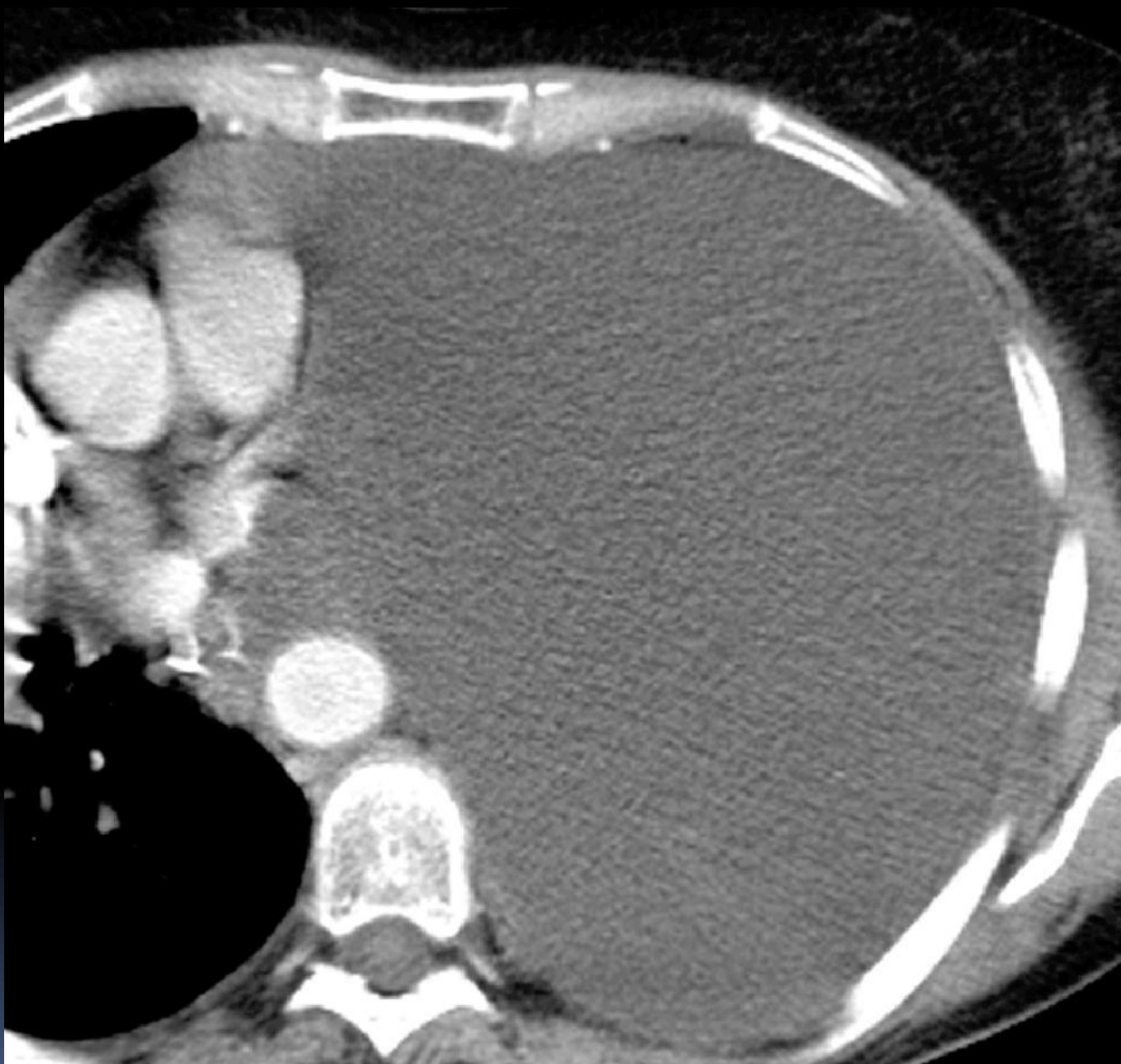
PARAPNÖMONİK PLEVRA SIVI



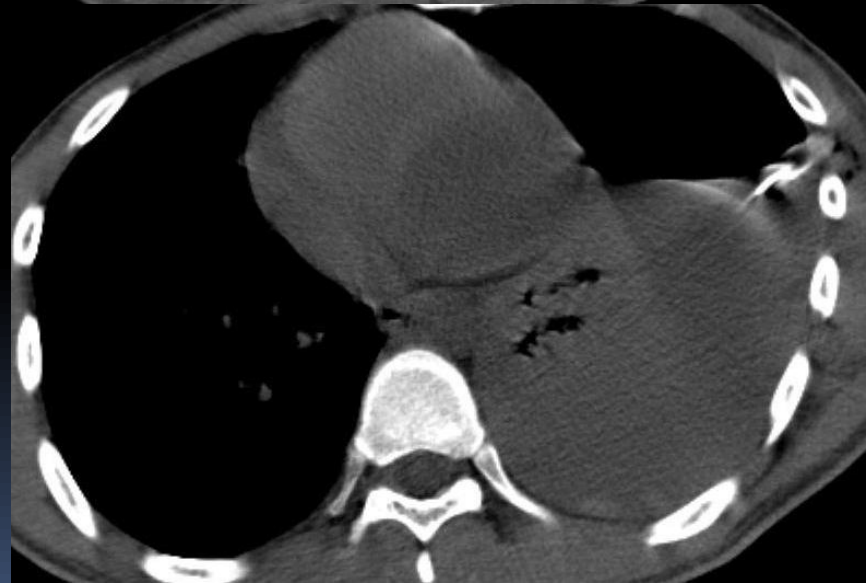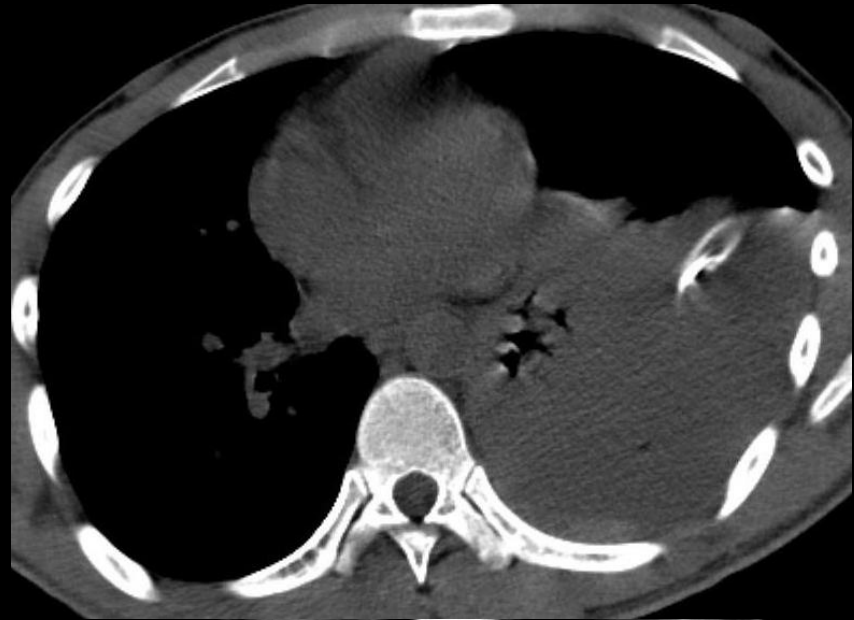
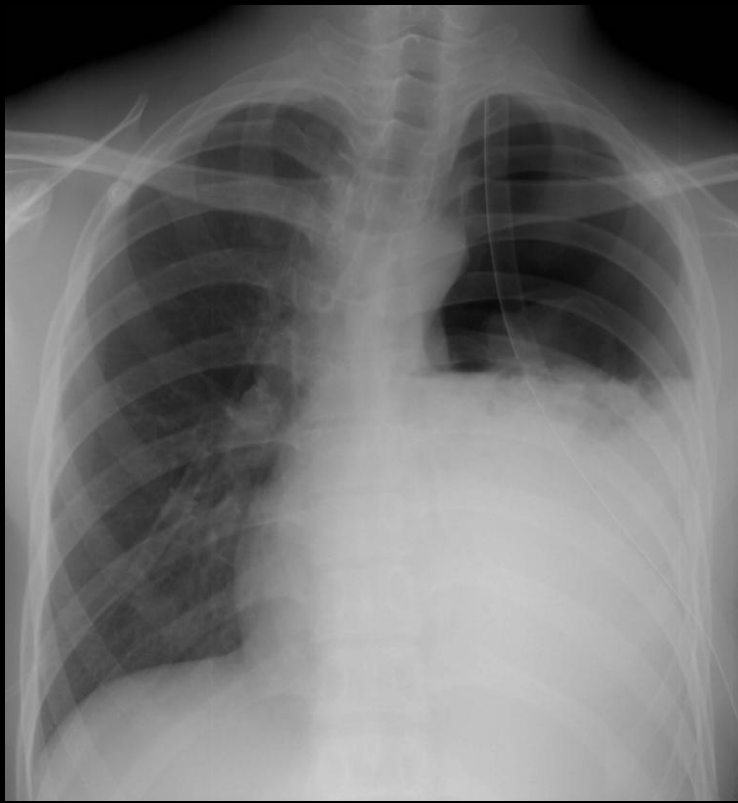AMPIYEM NECESSITATIS

# ŞİLOTORAKS

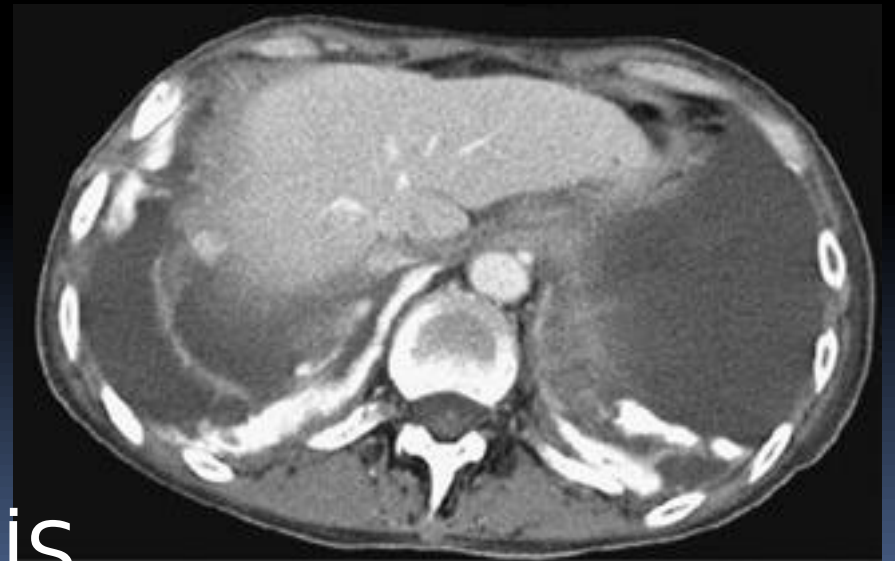
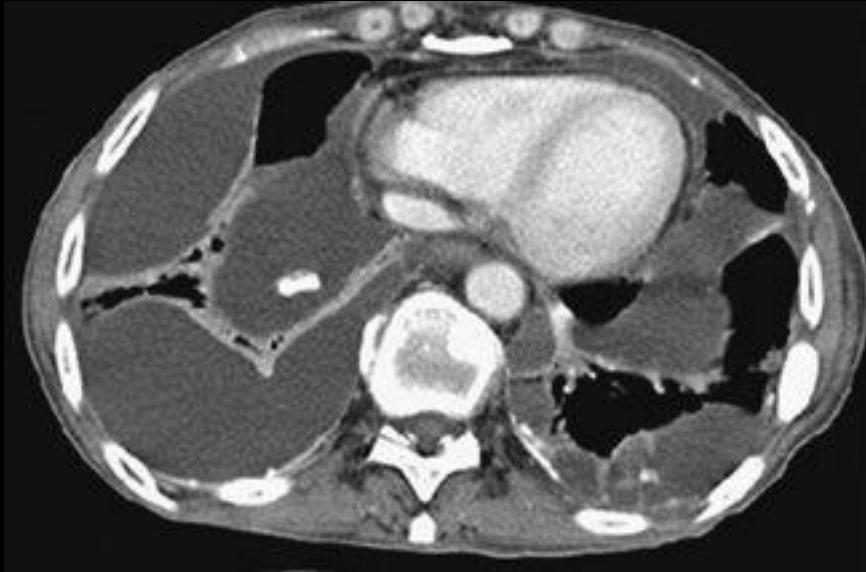- En iyi tanısal ipucu
  - Genellikle tek taraflı büyük plevral sıvı
  - Sıklıkla kardiovasküler cerrahi ve travma sonrası
- BT
  - Tipik olarak tek taraflı büyük sıvı
  - Sıvı yoğunluğunda
  - Genellikle plevral kalınlaşma (-)
  - Genellikle akciğer entrapment (-)
- MR
  - T<sub>1</sub> yüksek sinyal intensite
- BT diğer altta yatan sıvı nedenlerini ekarte edebilir
- Lenfanjiografi veya lenfosintigrafi



ŞİLOTORAKS



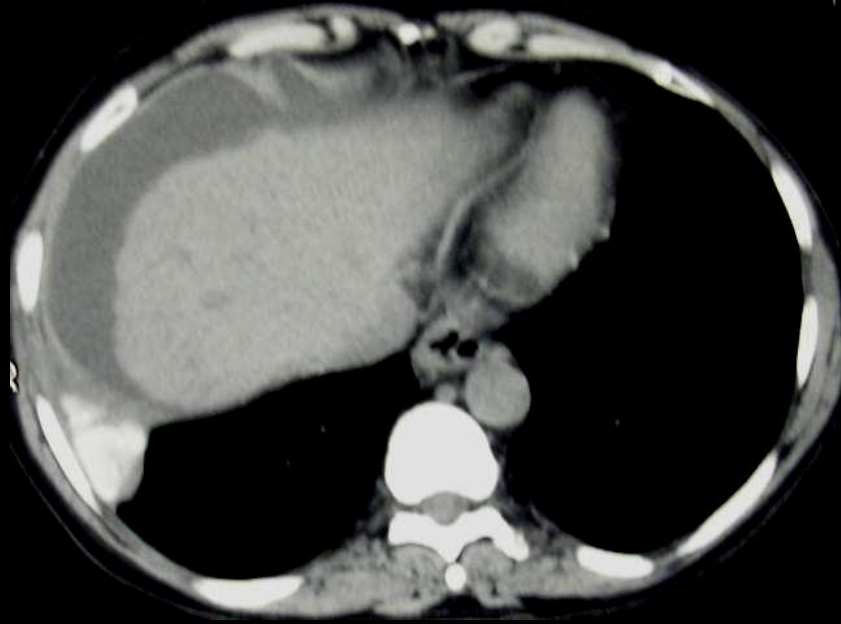
SPONTAN HEMOPNÖMOTORAKS



TALK PLÖREDEZİS

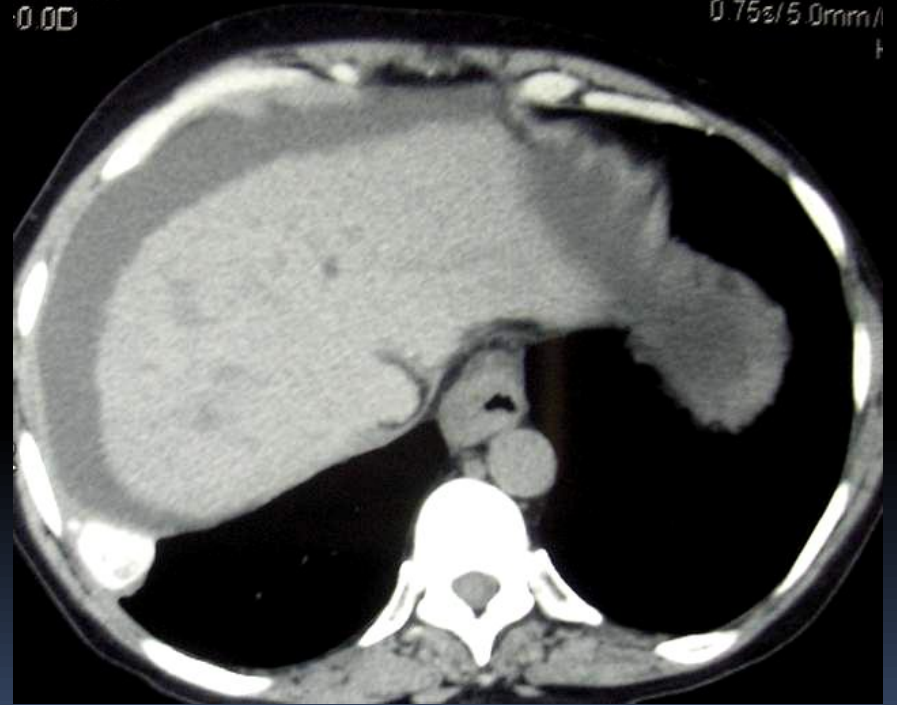
30 00mm  
+0 00

0.75/5.0mm  
f



0.00

0.75/5.0mm  
f



TALK PLÖREDEZİS

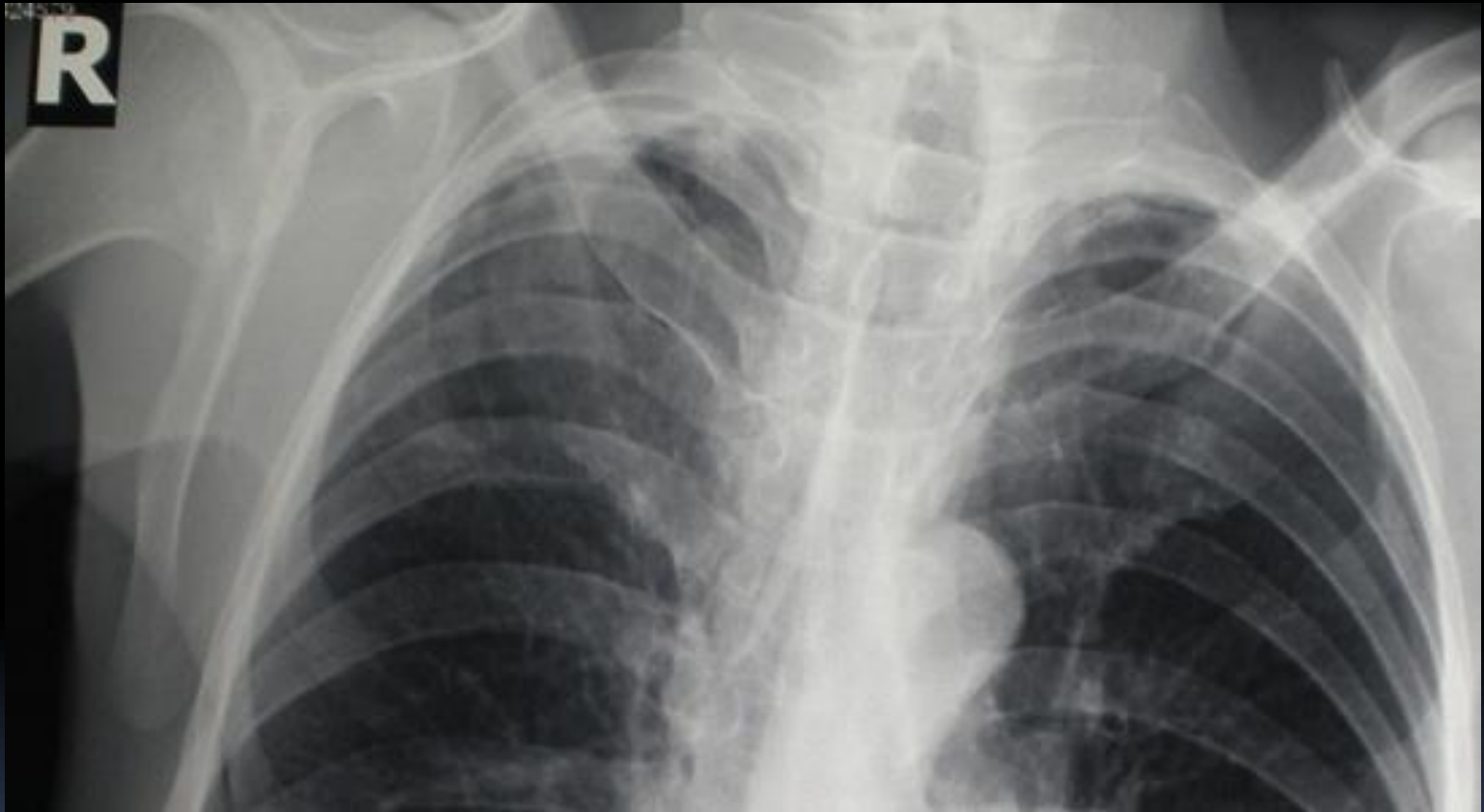
# PLEVRAL KALINLAŐMA



# APİKAL PLEVURAL KALINLAŞMA

- Yarım ay şeklinde, 5 mm < opasite
- Sıklıkla ekstraplevral yağda artma
- Sıklıkla iki taraflı
- Komşuluğunda parasikatriyel amfizem
- Ağrı önemli
- Eşlik eden iskelet destrüksiyonu önemli

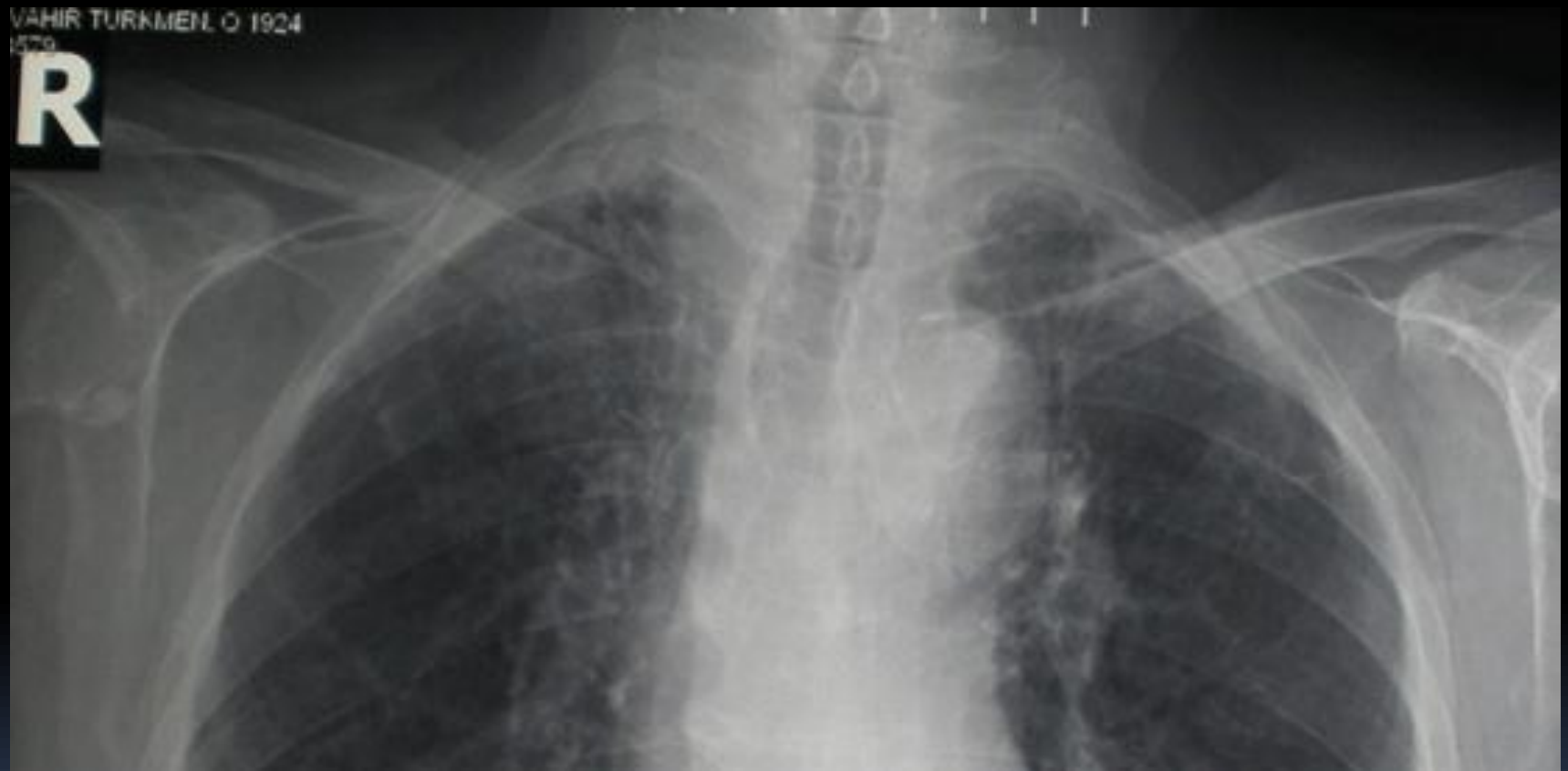
24579  
**R**



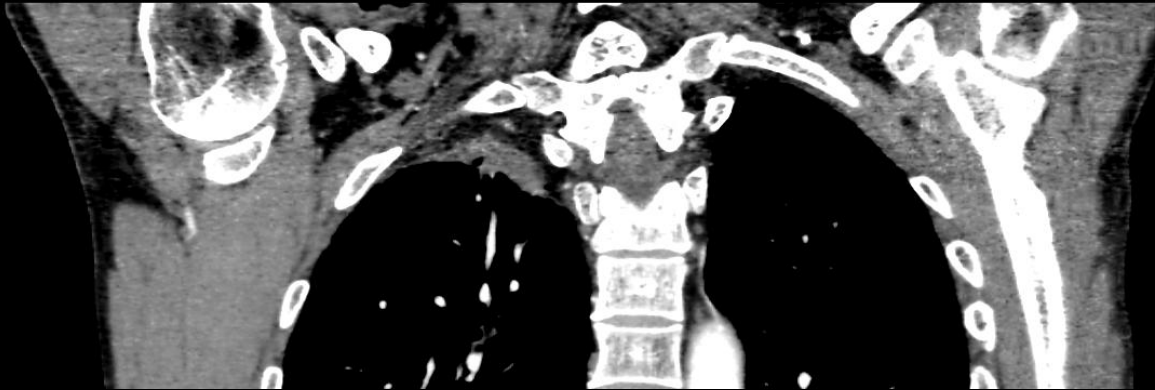VAHIR TURKMEN O 1924

1579

**R**

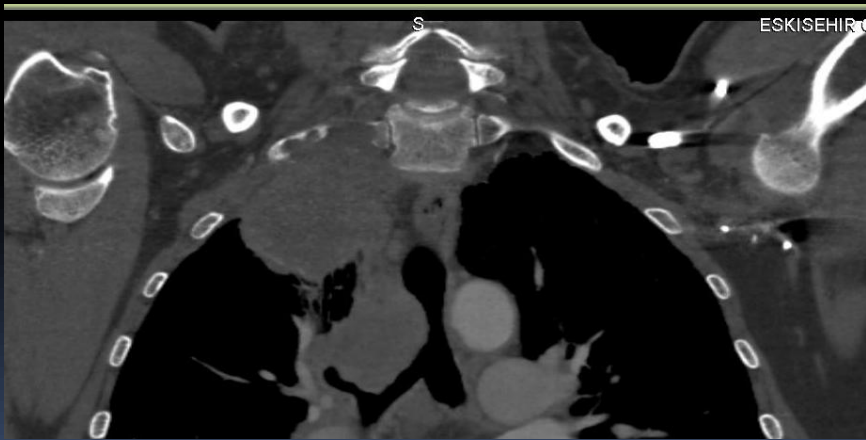

S



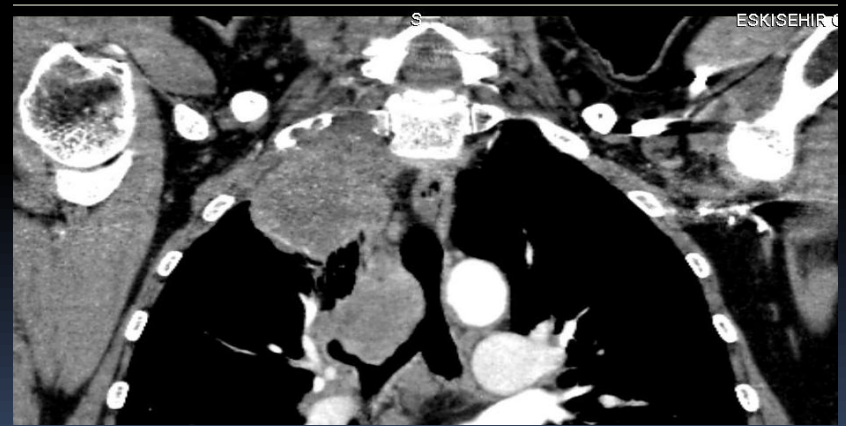S

ESKISEHIR



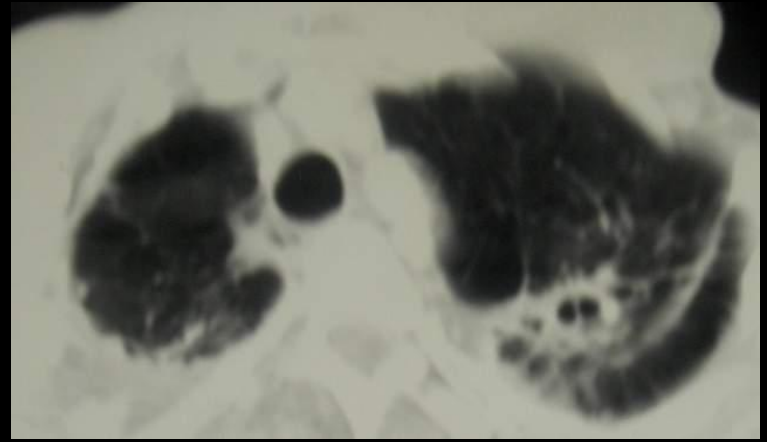
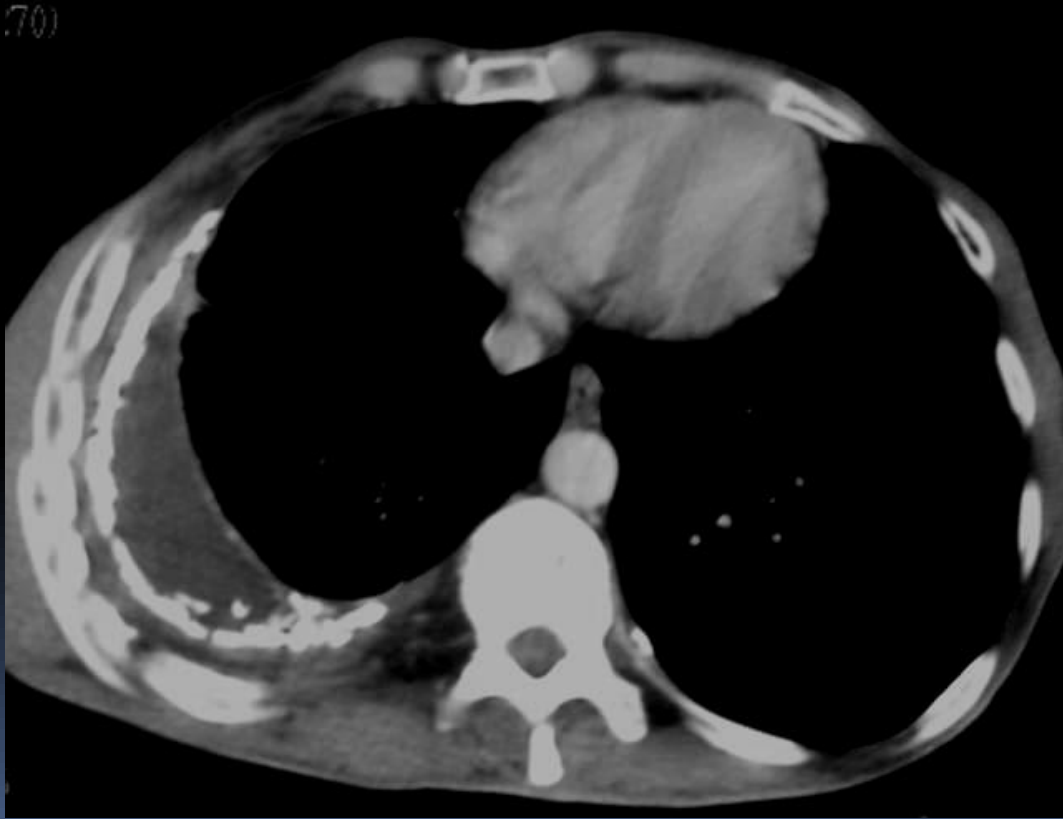
S

ESKISEHIR

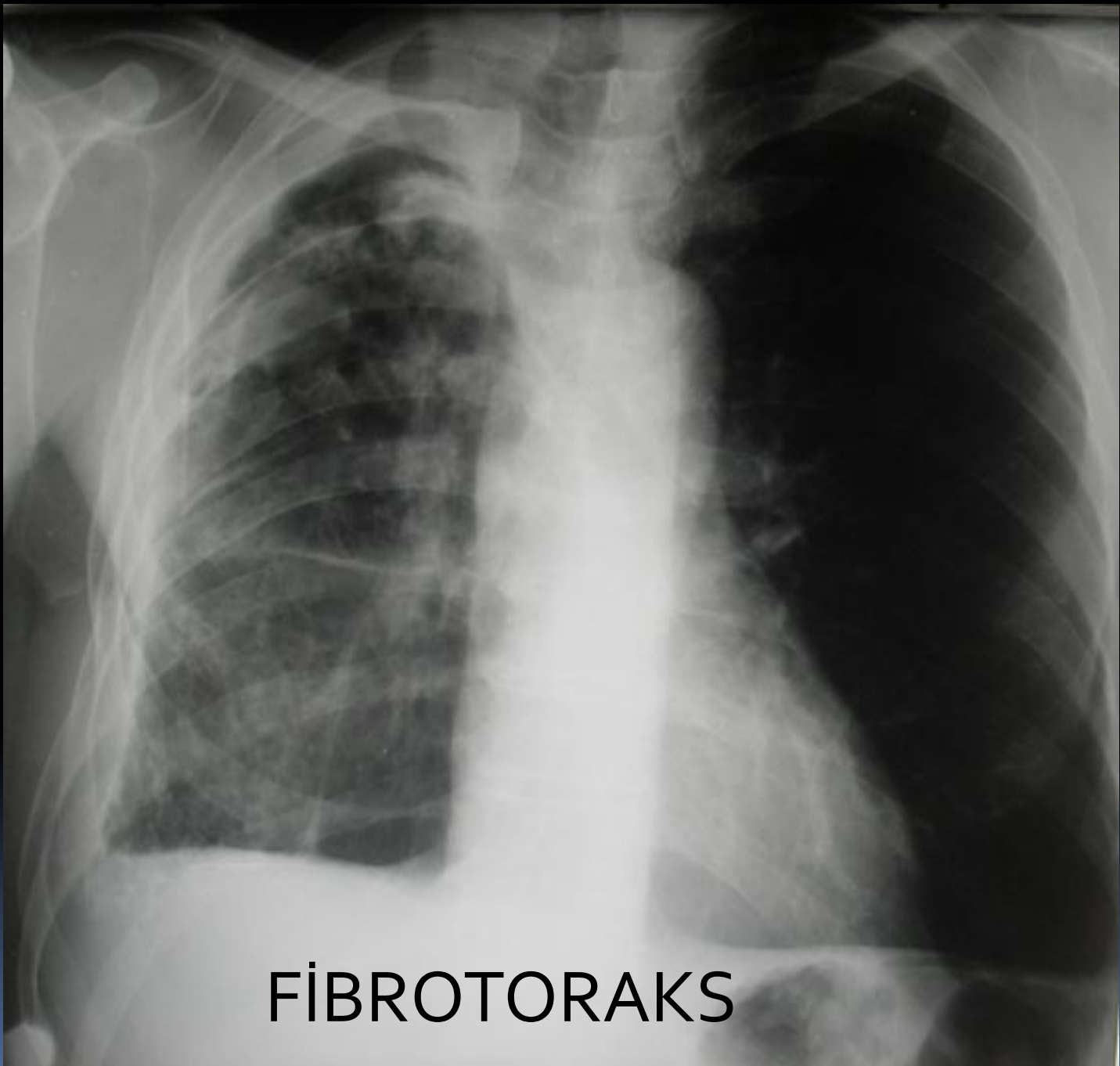


# FİBROTORAKS

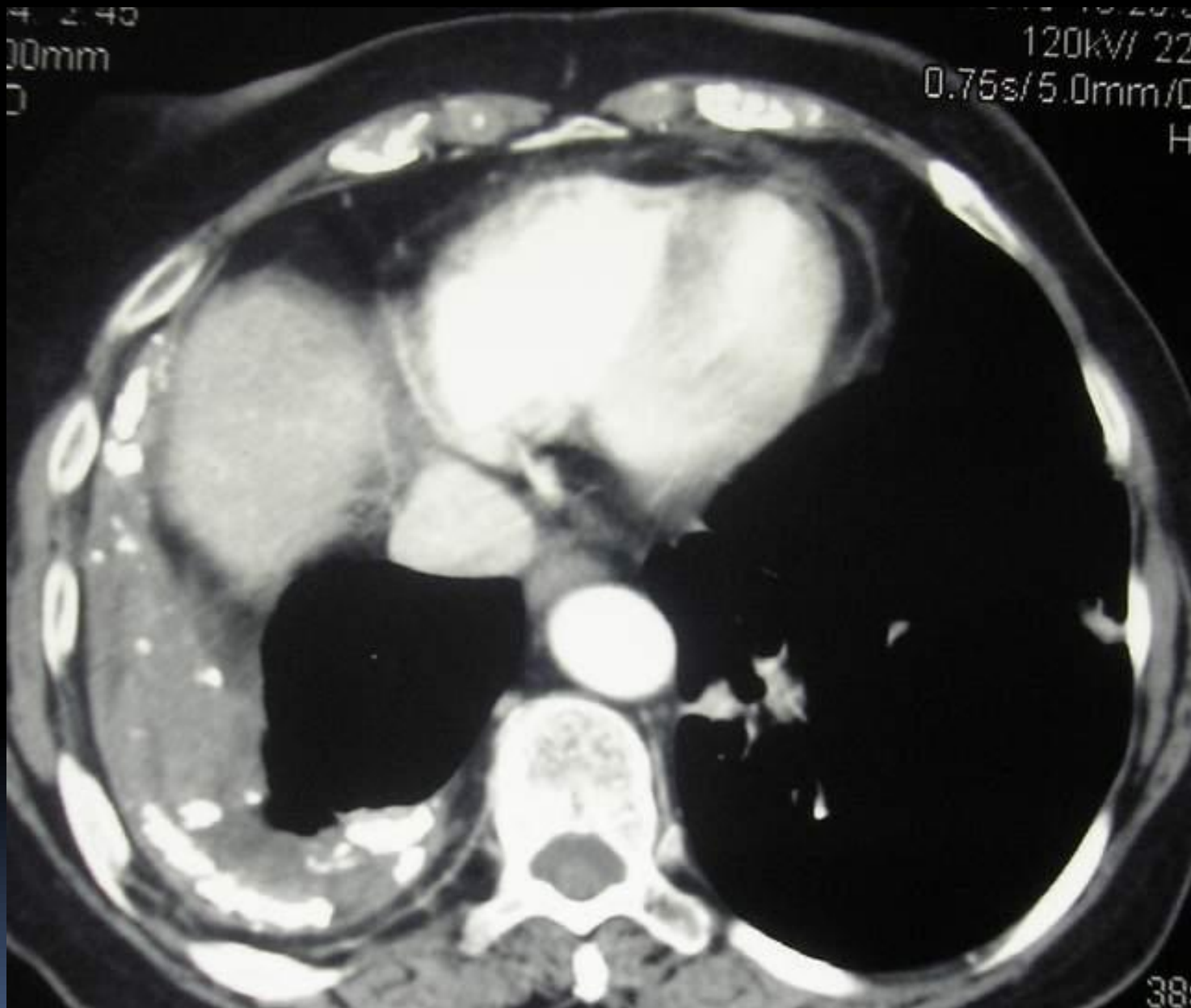- Yoğun, devamlılık gösteren plevral kalsifikasyon
- Hacim kaybı
- İnterkostal aralıklarda daralma
- Aynı tarafa mediastinal yer değiştirme
- Kalsifiye pariyetal ve viseral plevra arasında sıvı
  - Sıvı değişen dansitedir. Sıvı, yumuşak doku
- Mediastinal plevra korunur



FIBROTORAKS



FIBROTORAKS



FIBROTORAKS

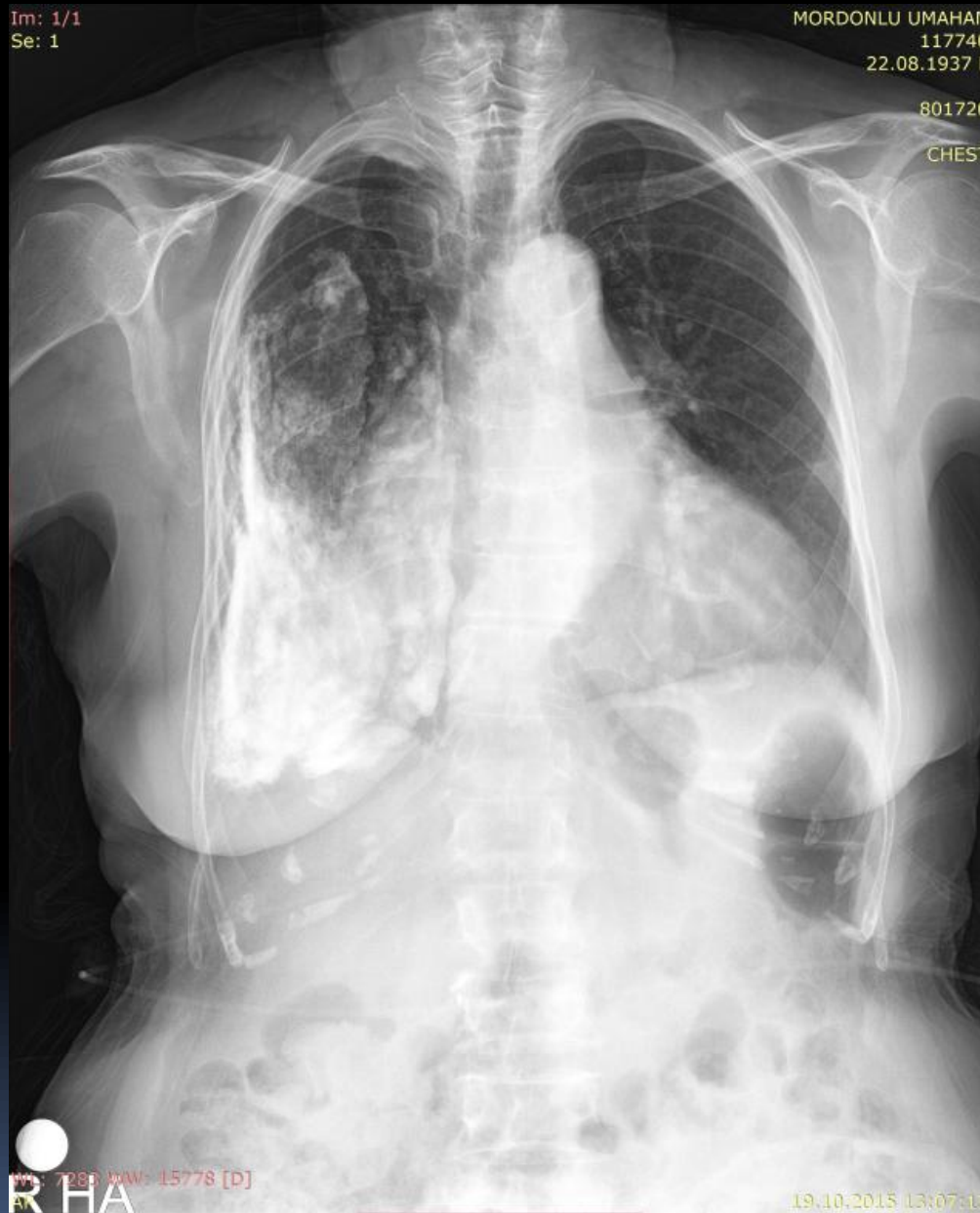

Im: 1/1  
Se: 1

MORDONLU UMAHAN  
117740  
22.08.1937 F

801720

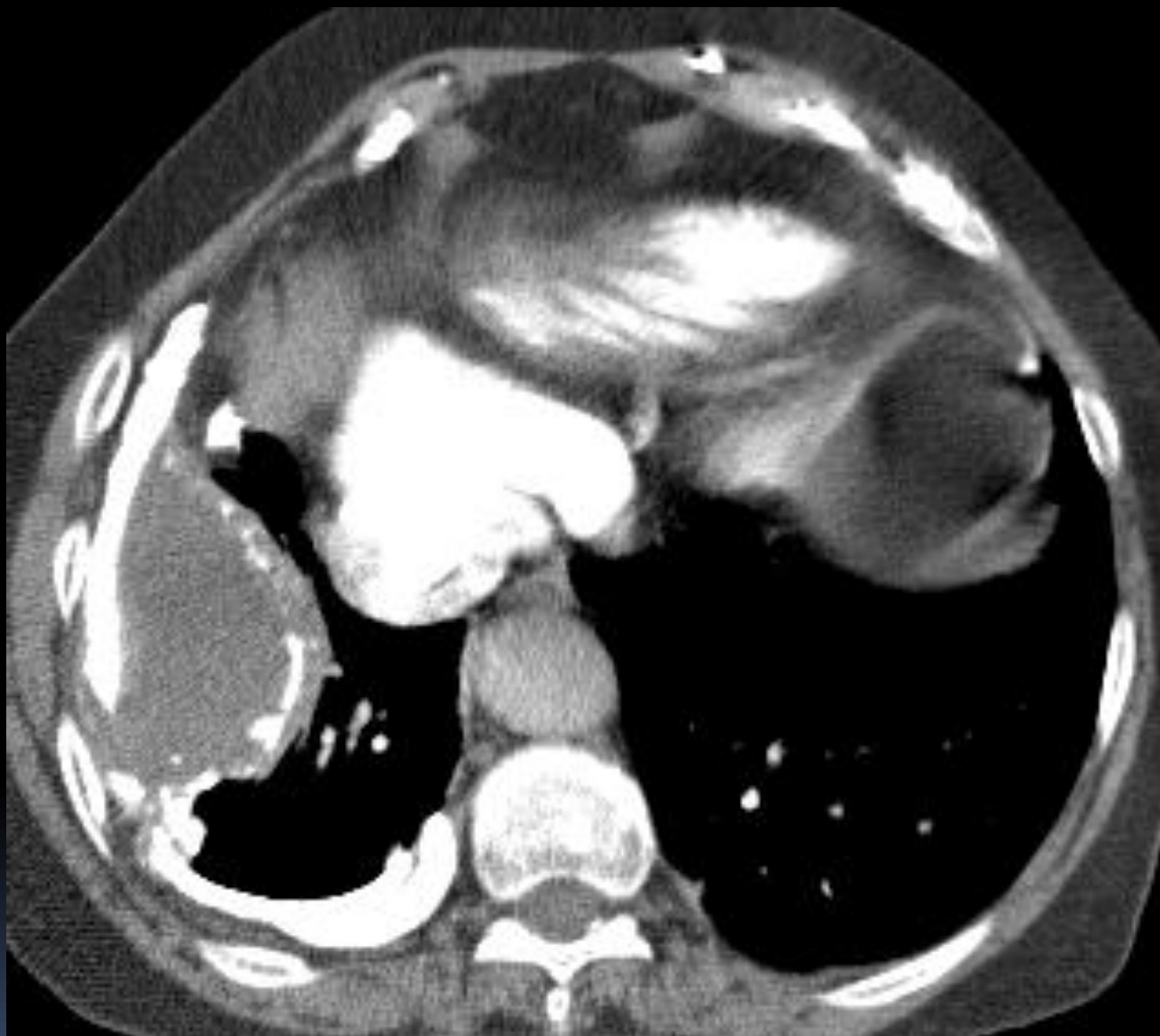CHEST



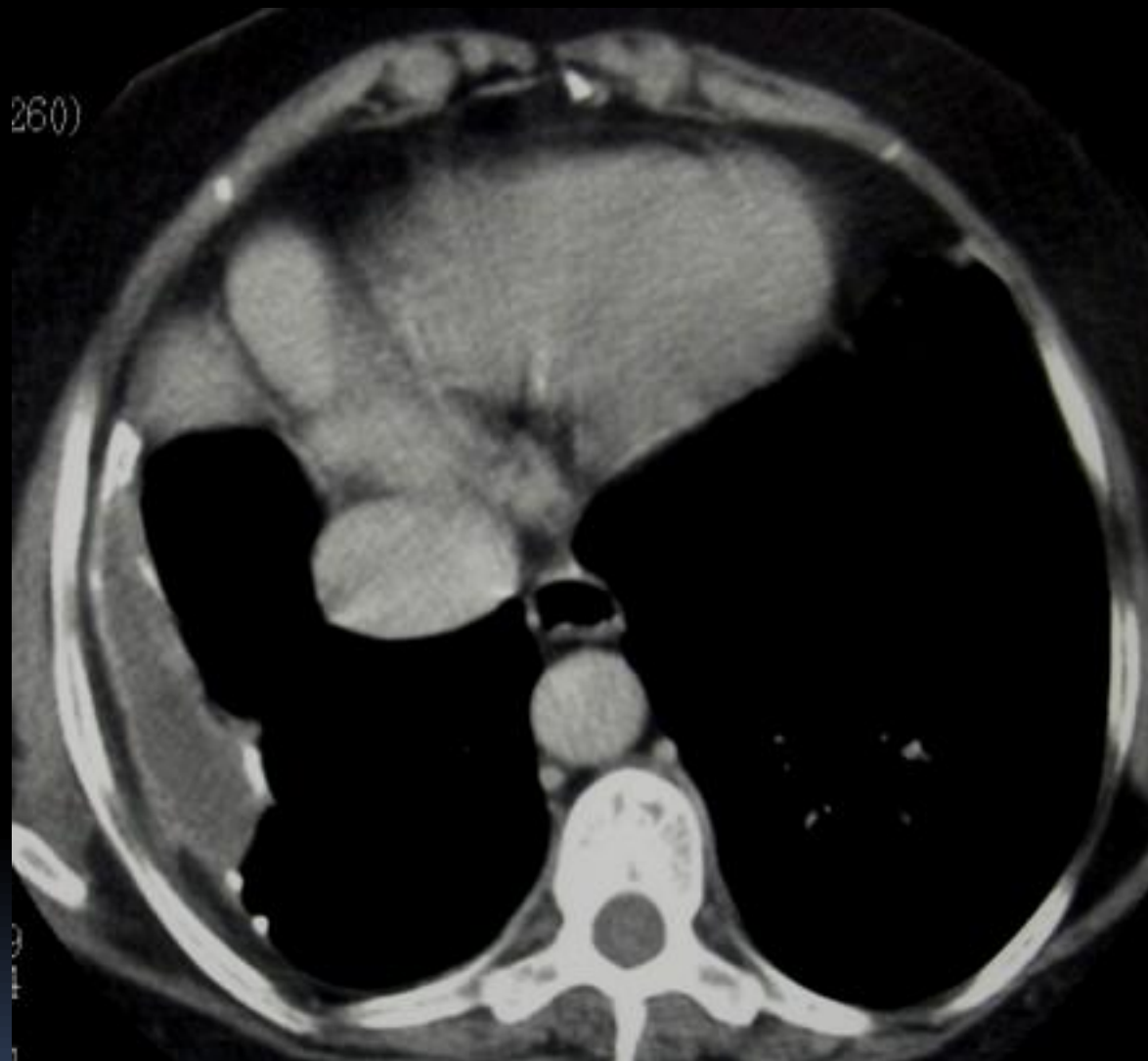
7283 MAV: 15778 [D]  
R HA

19.10.2015 13:07:13

# FIBROTORAKS



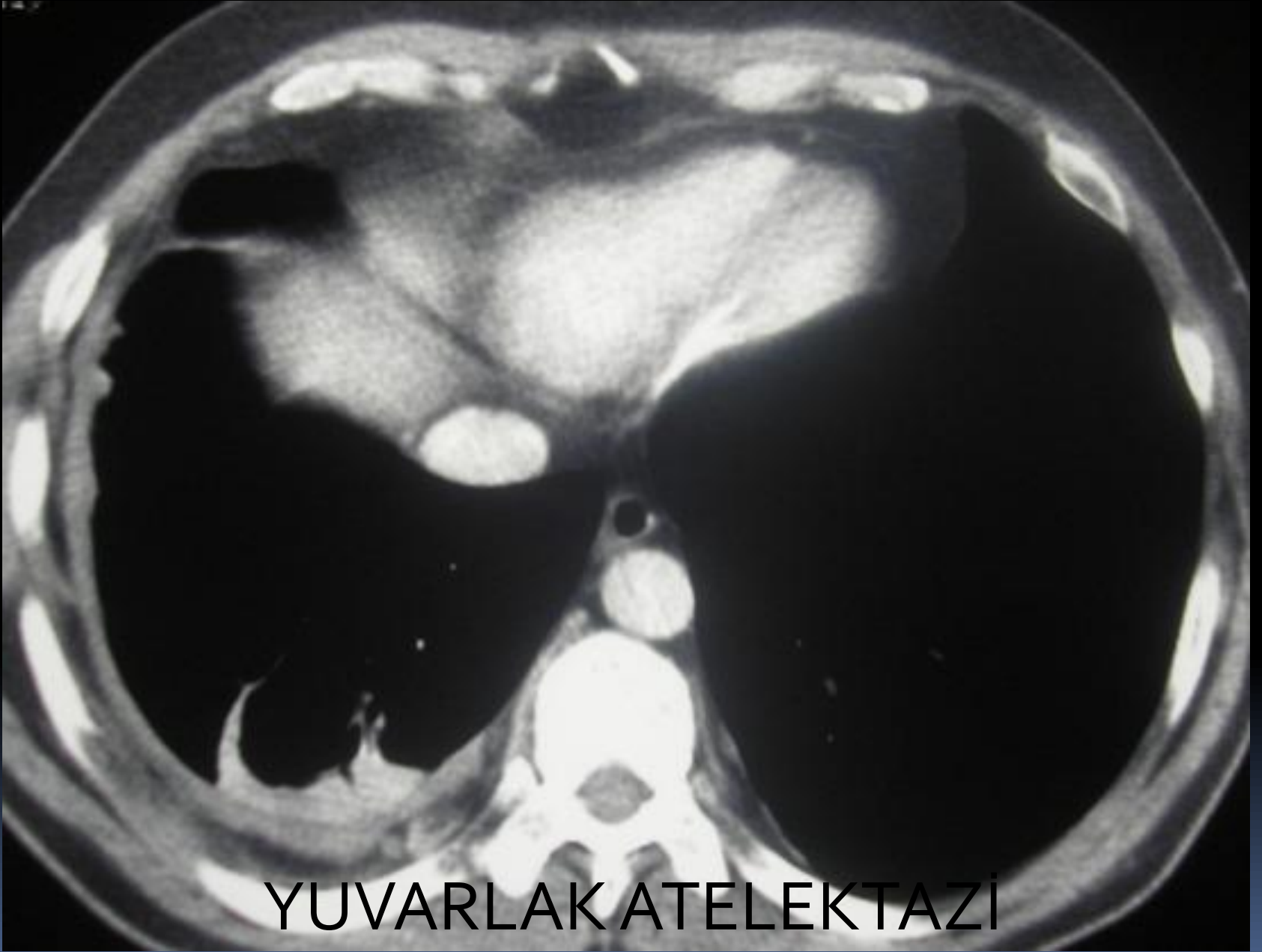FIBROTORAKS



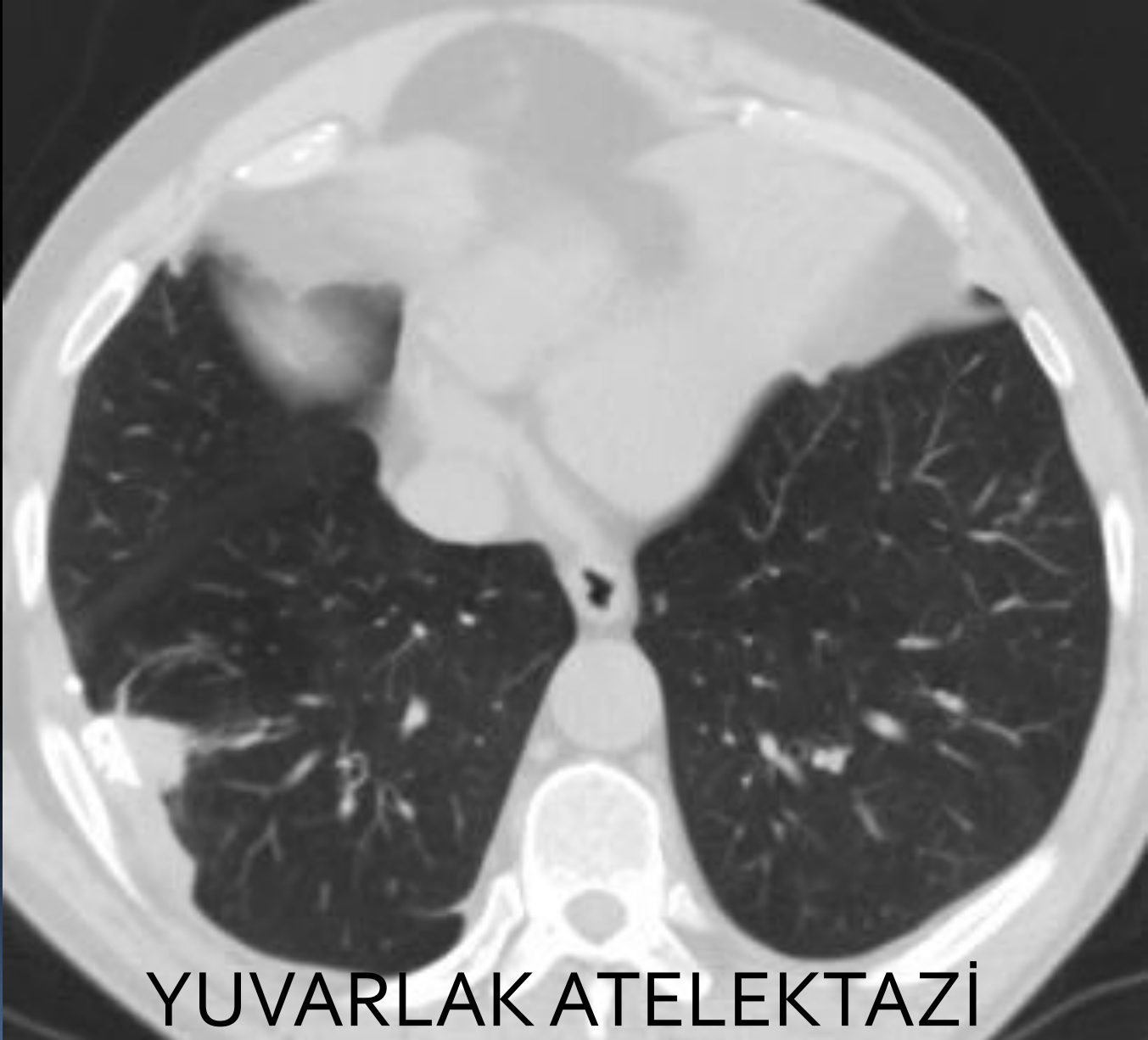FIBROTORAKS

# YUVARLAK ATELEKTAZİ

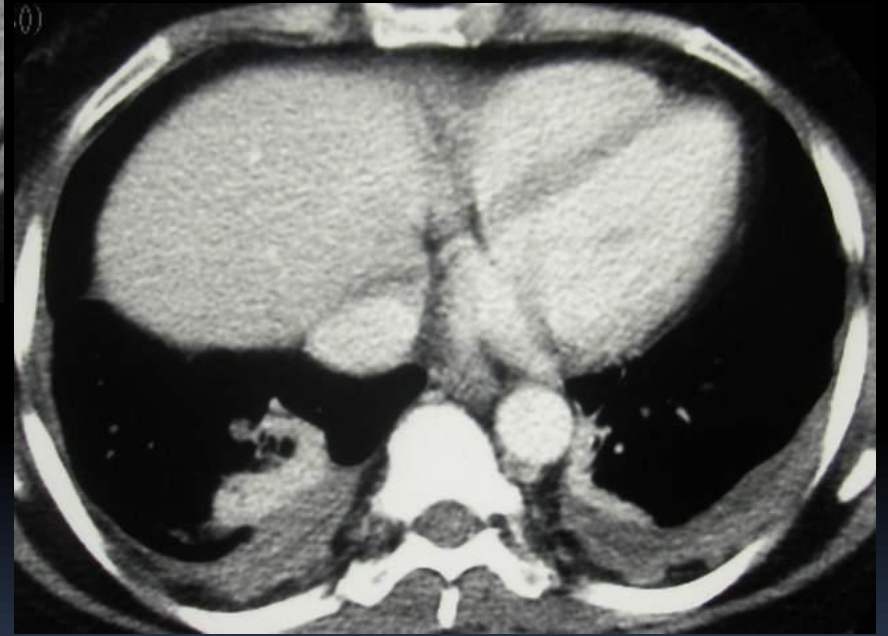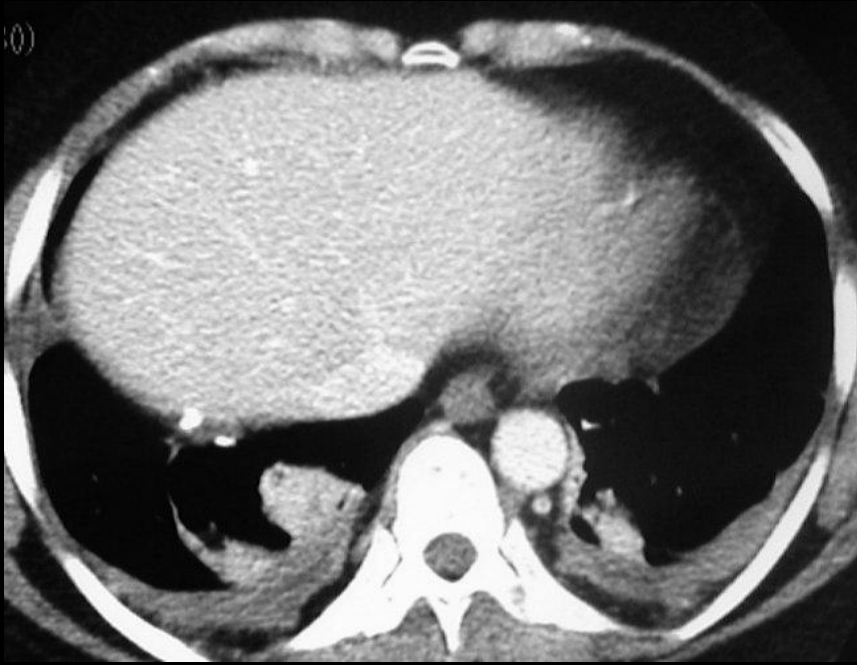- Yuvarlak veya oval
- Aynı tarafta plevral sıvı veya kalınlaşma
- Periferal yerleşimli
- Lezyon kenarına doğru pulmoner damarlar veya bronşlar eğilirler
- Etkilenen lobda hacim kaybı olur
- Kontrastlı BT'de belirgin boya tutarlar
- Kollabe akciğerde hava bronkogramları olabilir



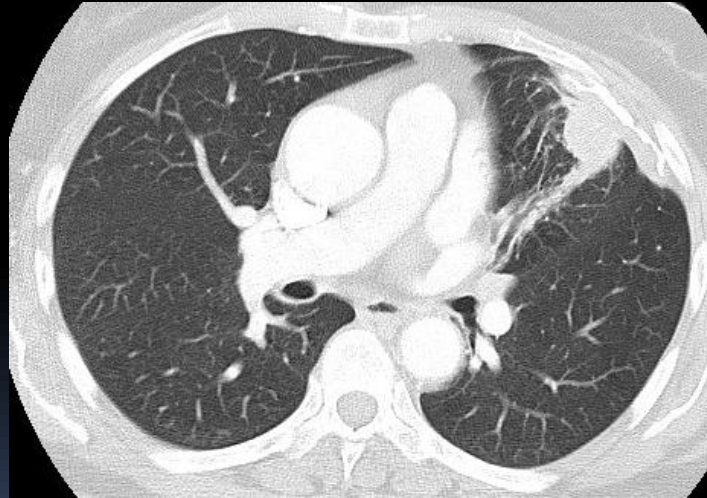
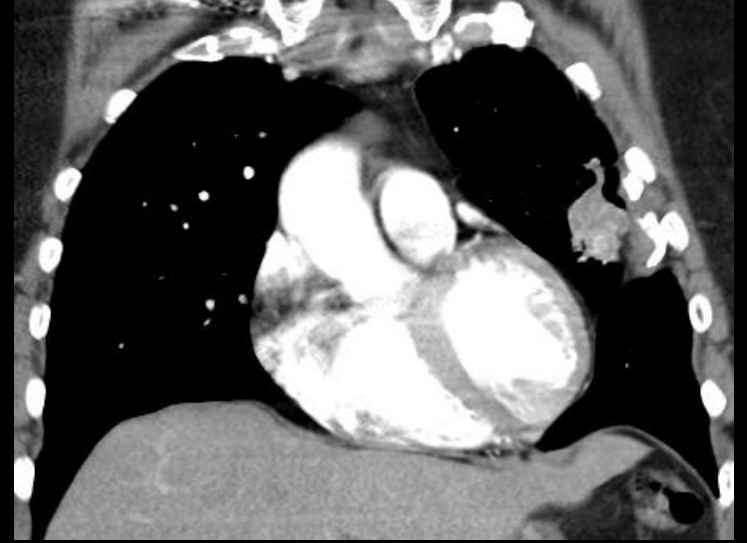
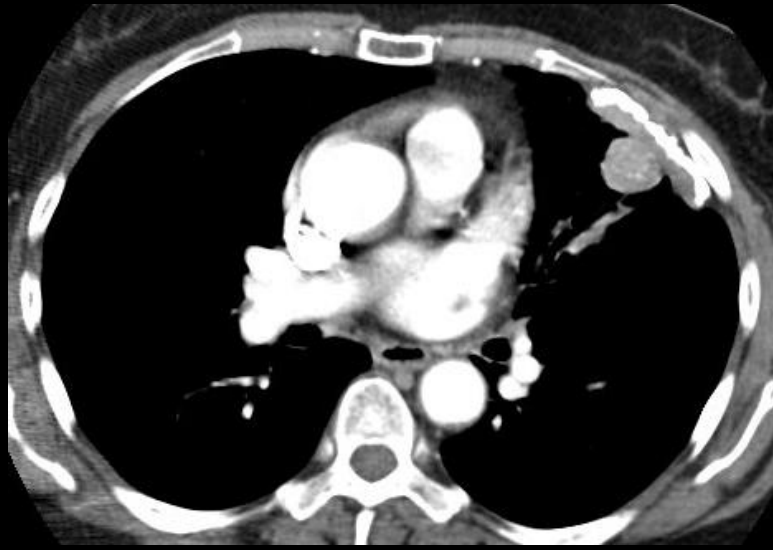
YUVARLAK ATELEKTAZİ



YUVARLAK ATELEKTAZİ



YUVARLAK ATELEKTAZİ



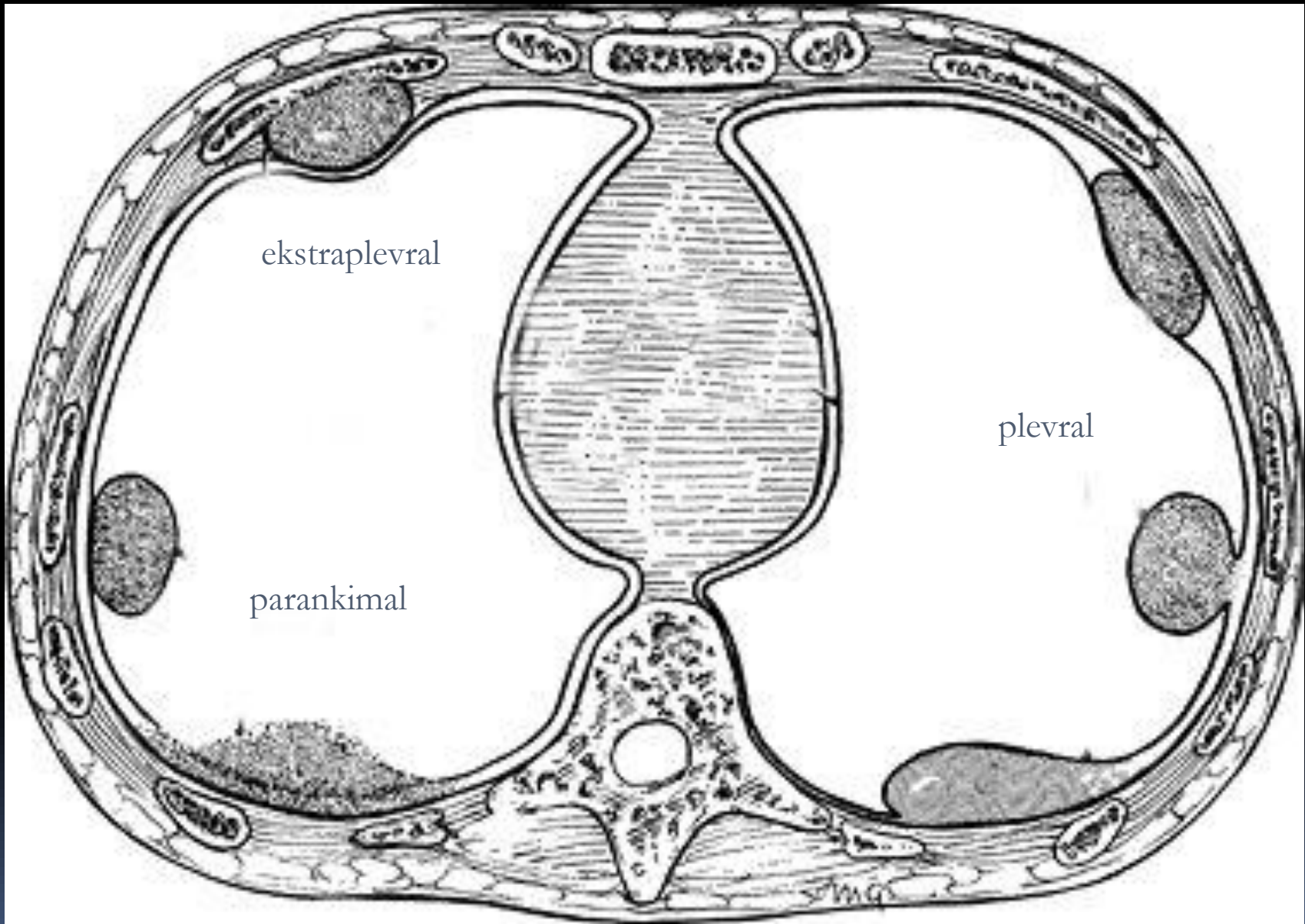
YUVARLAK ATELEKTAZİ



EKSTRAPLEVRAL KİTLE

PLEVRAL KİTLE

PARANKİMAL KİTLE



ekstraplevral

plevral

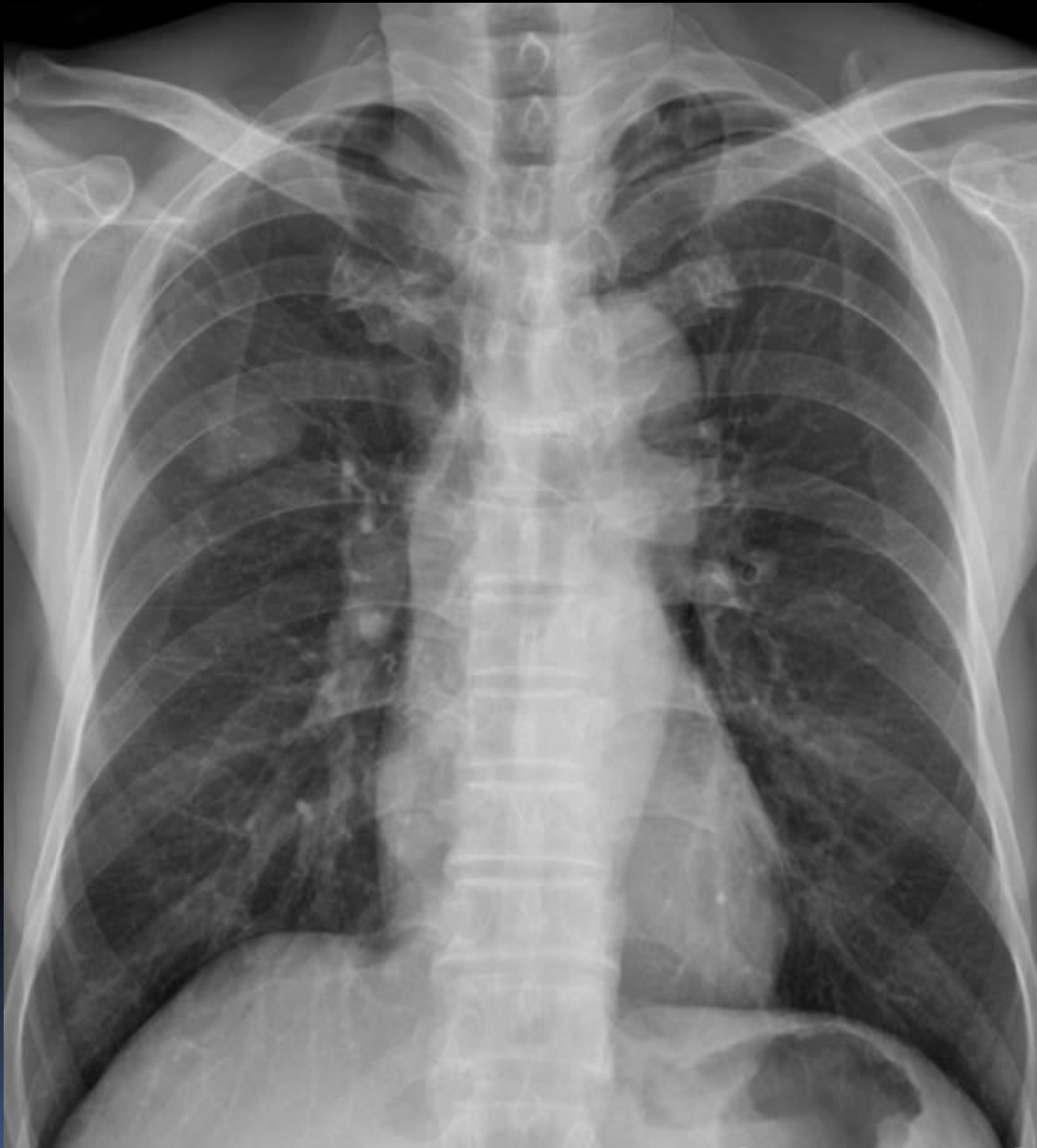parankimal

# LOKALİZE FİBRÖZTÜMÖR

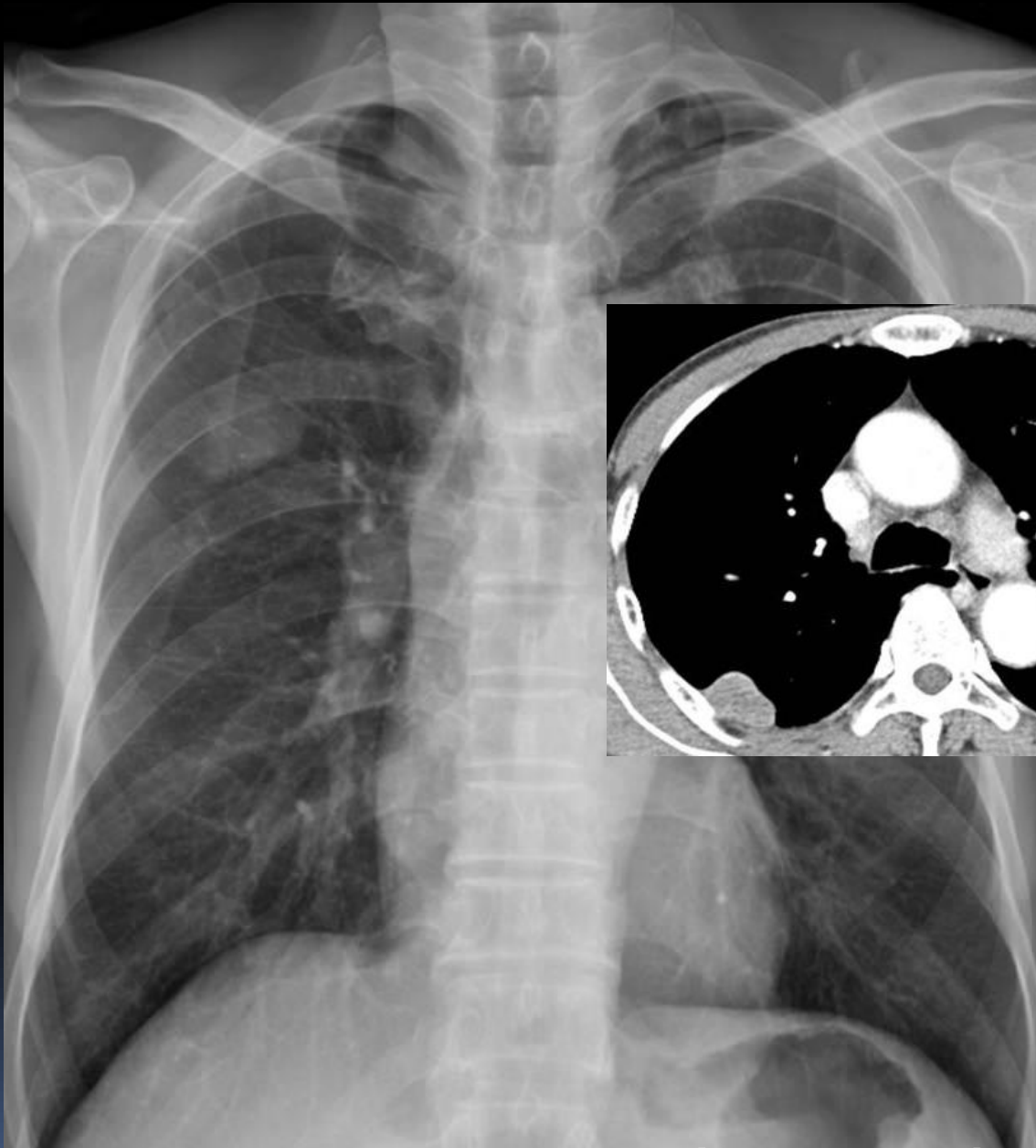
- İyi sınırlı periferal nodül veya kitle, inkomplet kenar işareti
- Fissürle ilişkili nodül veya kitle
- Lezyonun şeklinde ve lokalizasyonunda pozisyonel yer değiştirme, sap içermesi
- Büyük intratorasik kitle şeklinde olanlarda lokal invazyon veya LAP olmaması

# LOKALİZE FİBRÖZTÜMÖR

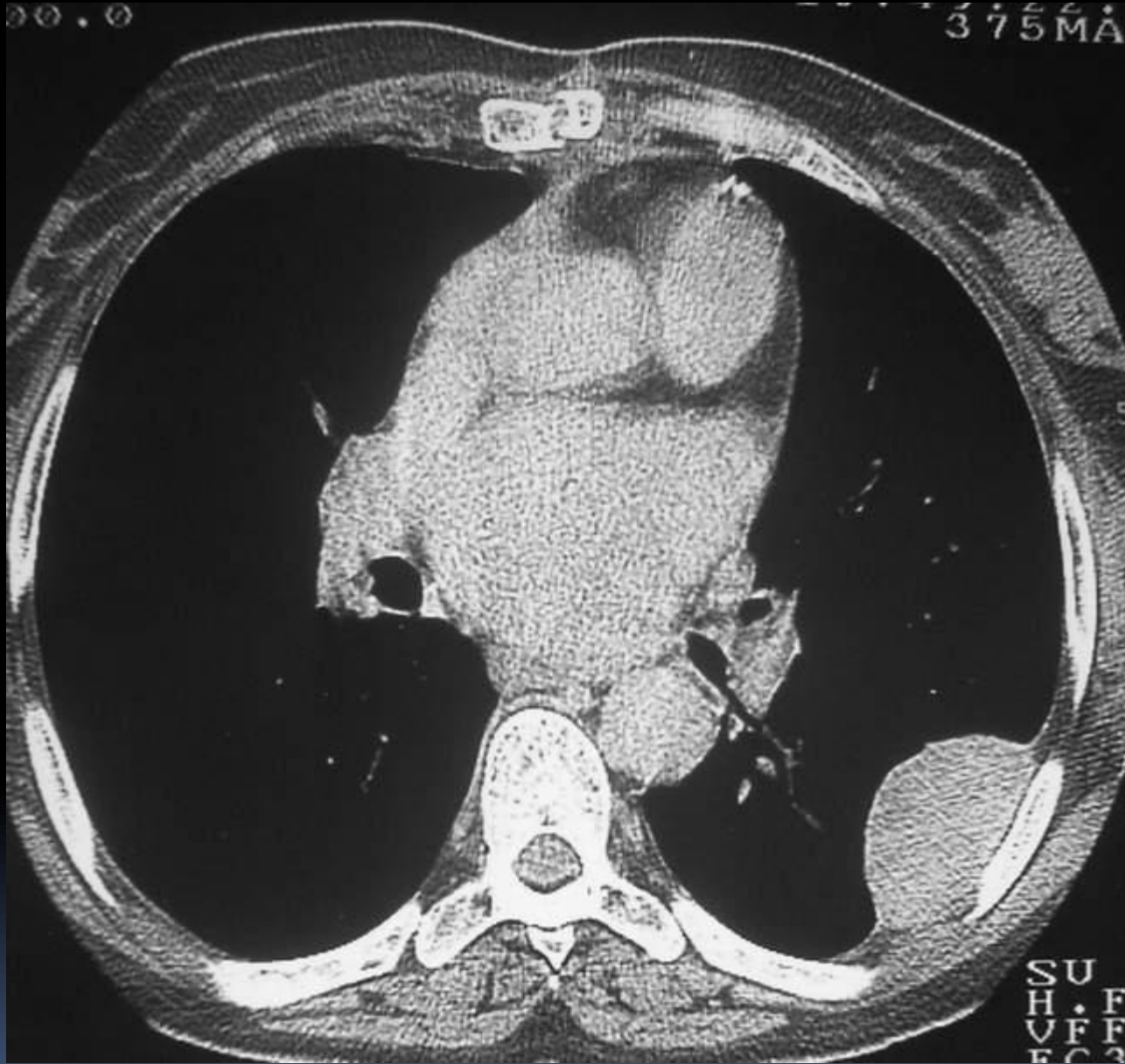
- Göğüs duvar tutulumunun olmaması
- Büyük LFT kontrastlı BT'de boyanabilir
- Sıklıkla küçük LFT plevra ile geniş açı, büyük LFT dar açı yapar
- Malign tipleri vardır



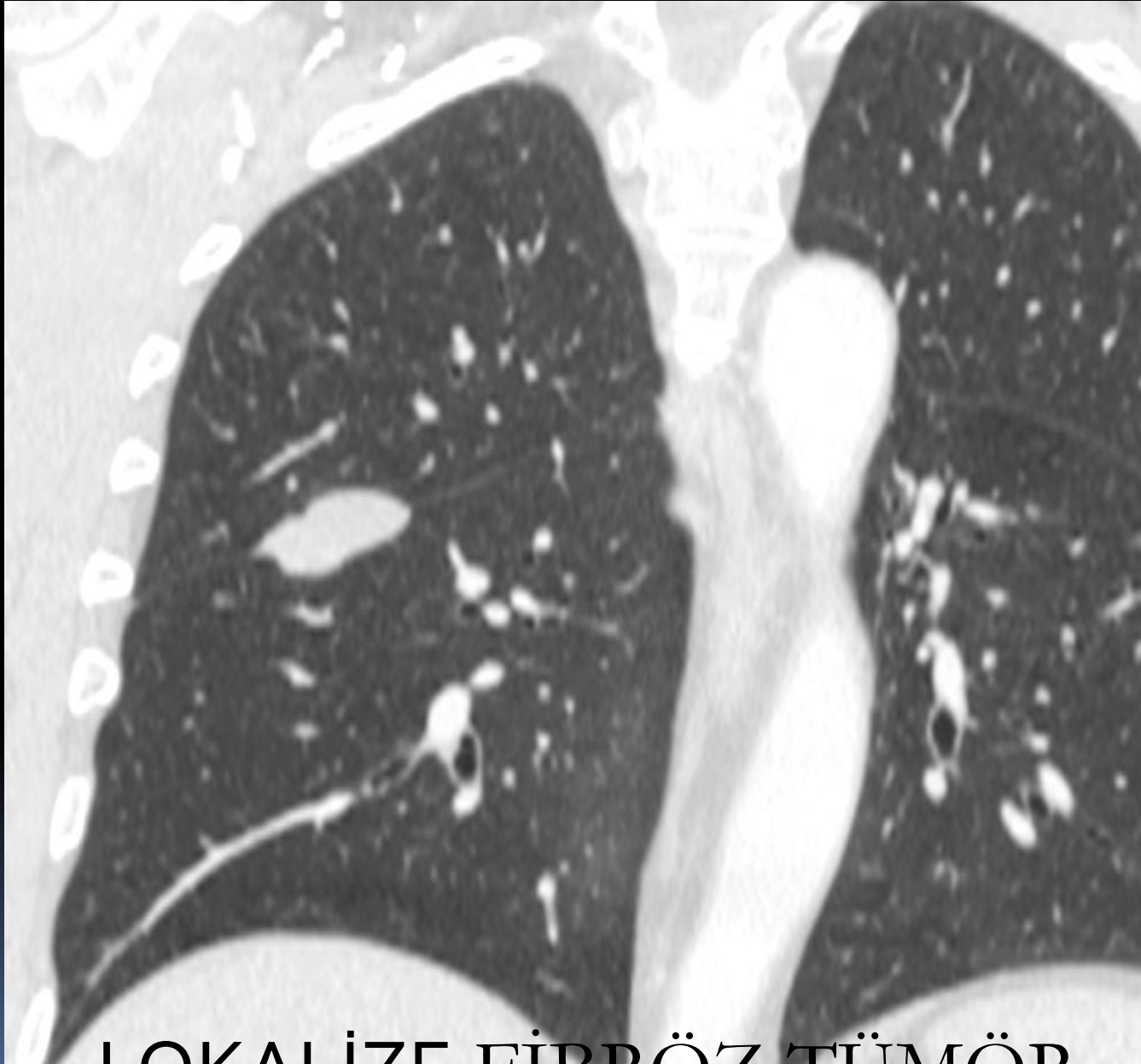İNKOMPLET KENAR İŞARETİ



İNKOMPLET KENAR İŞARETİ

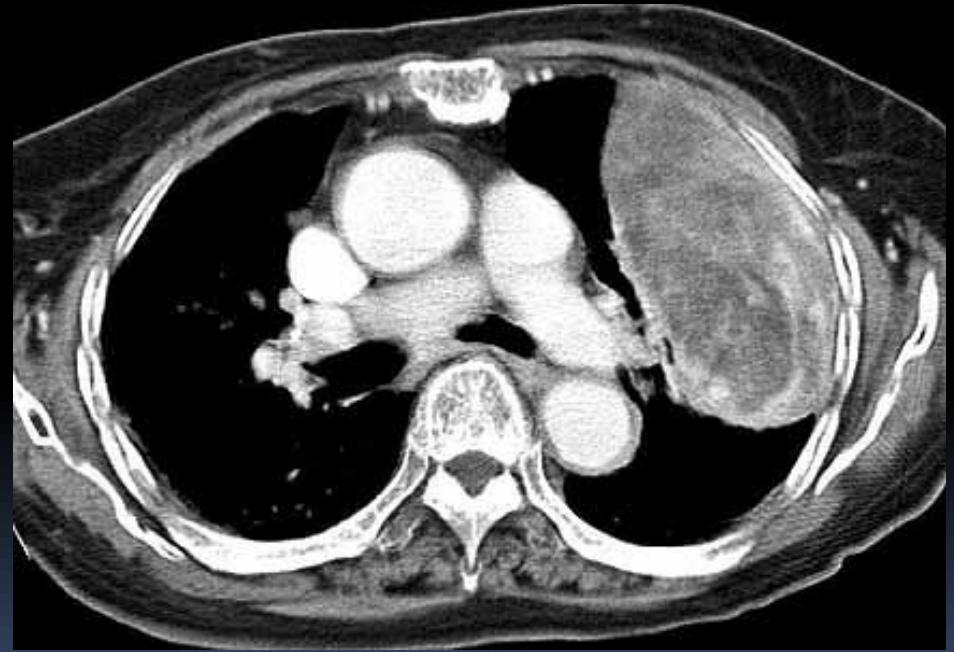
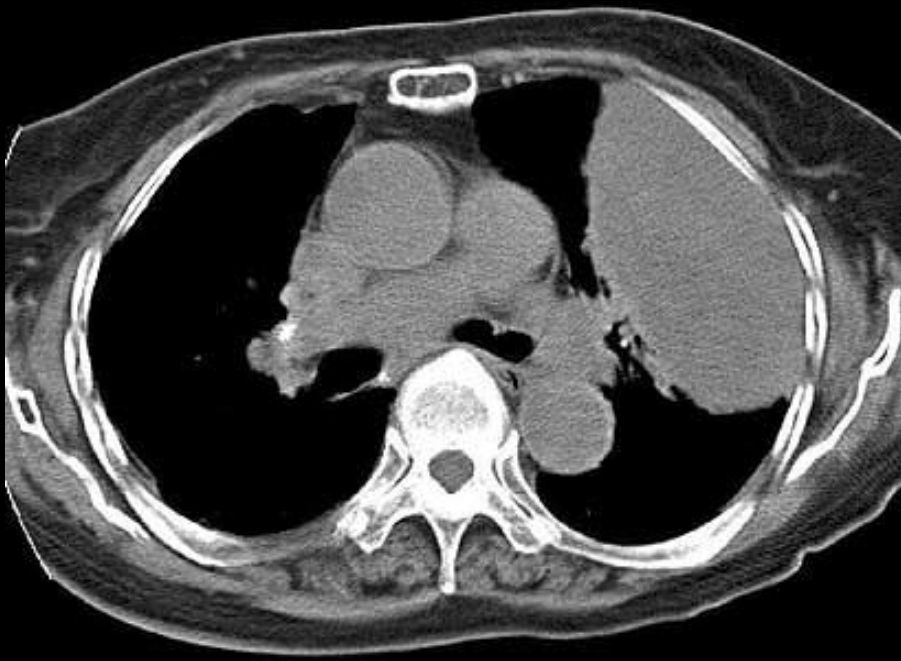


LOKALİZE FİBRÖZ TÜMÖR

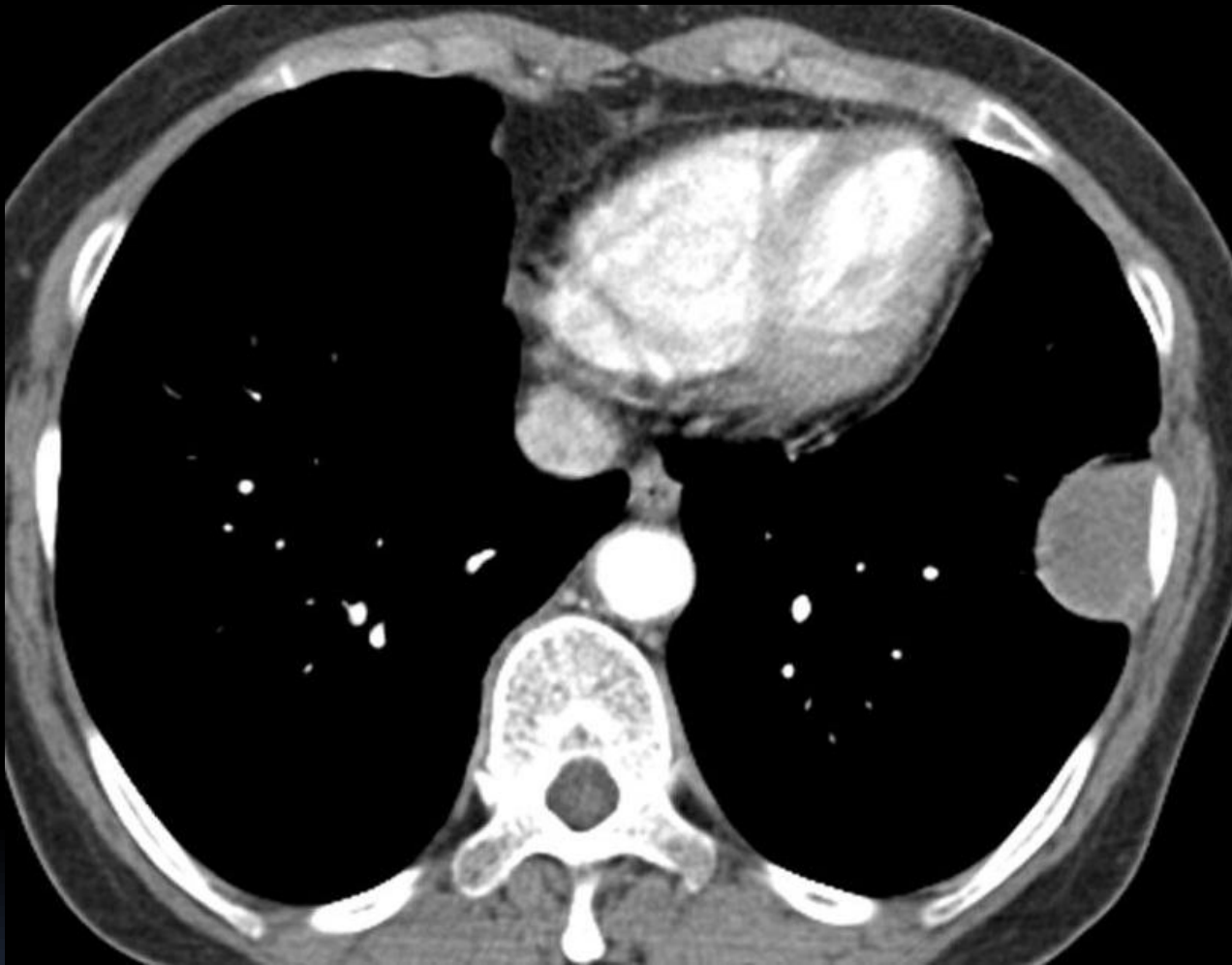

LOKALİZE FİBRÖZ TÜMÖR



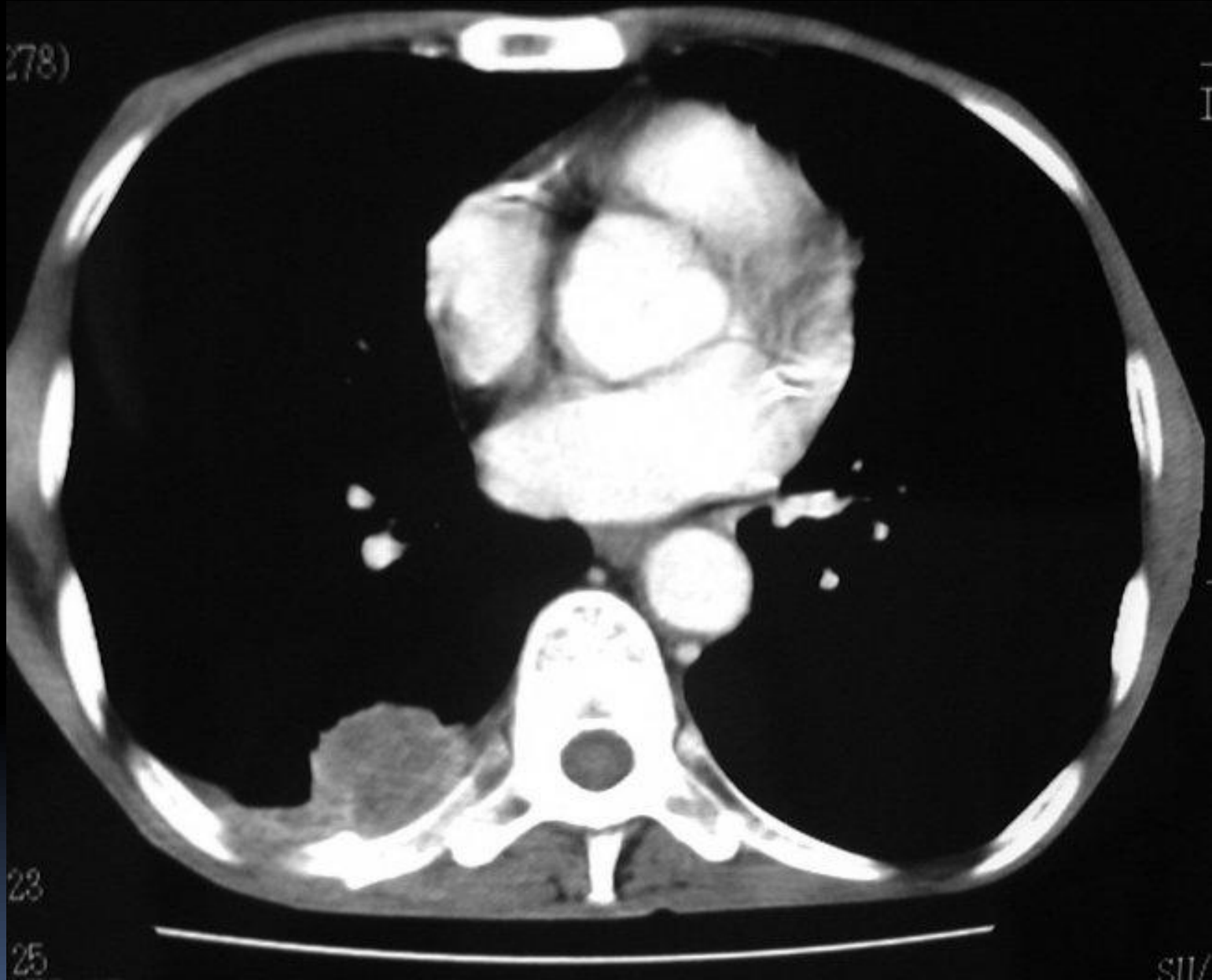


LOKALİZE FİBRÖZ TÜMÖR

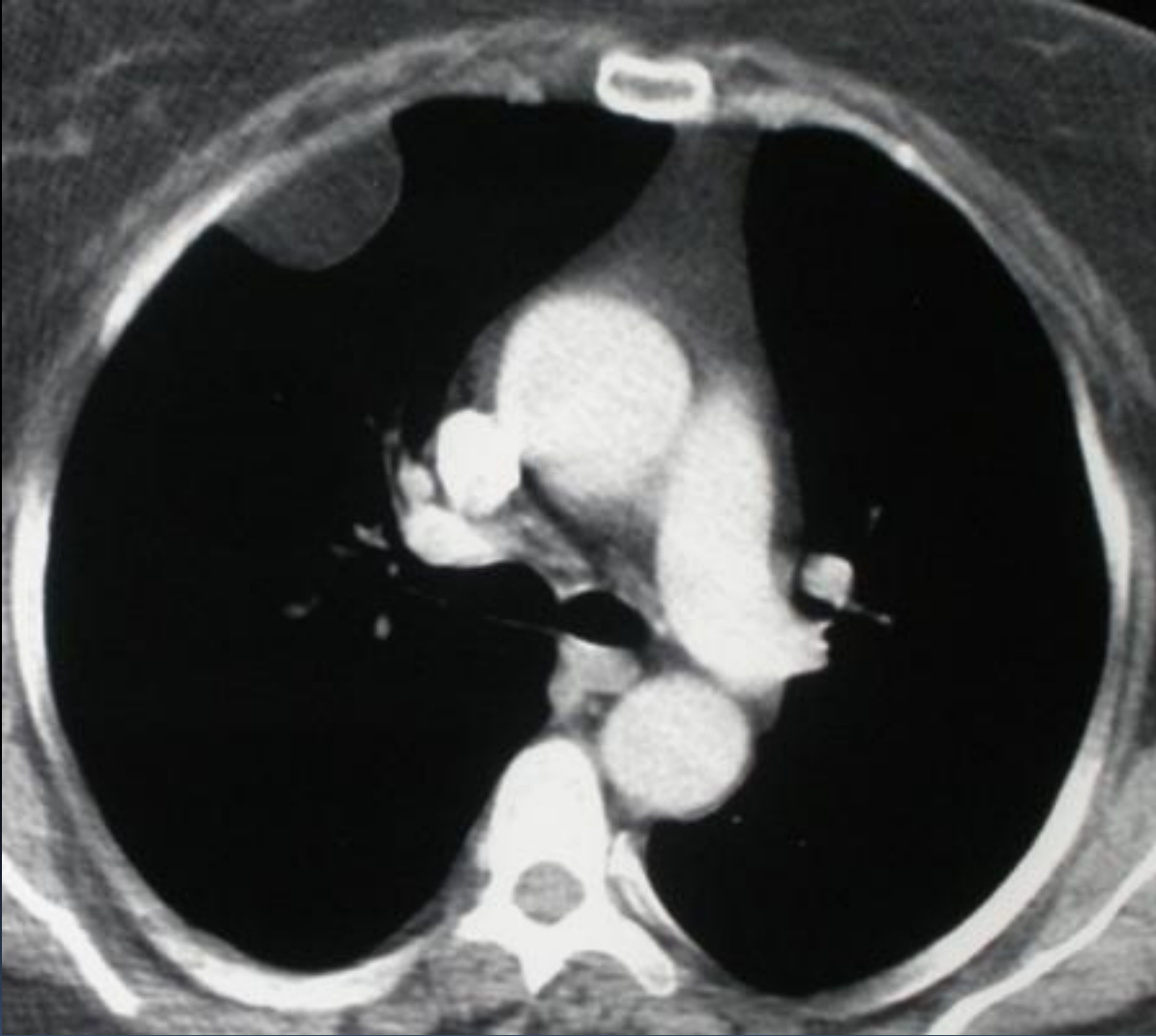

# LOKALİZE MALİGN MEZOTELYOMA

Korean Society of Thoracic Radiology



PRİMER AKCİĞER TÜMÖRÜ

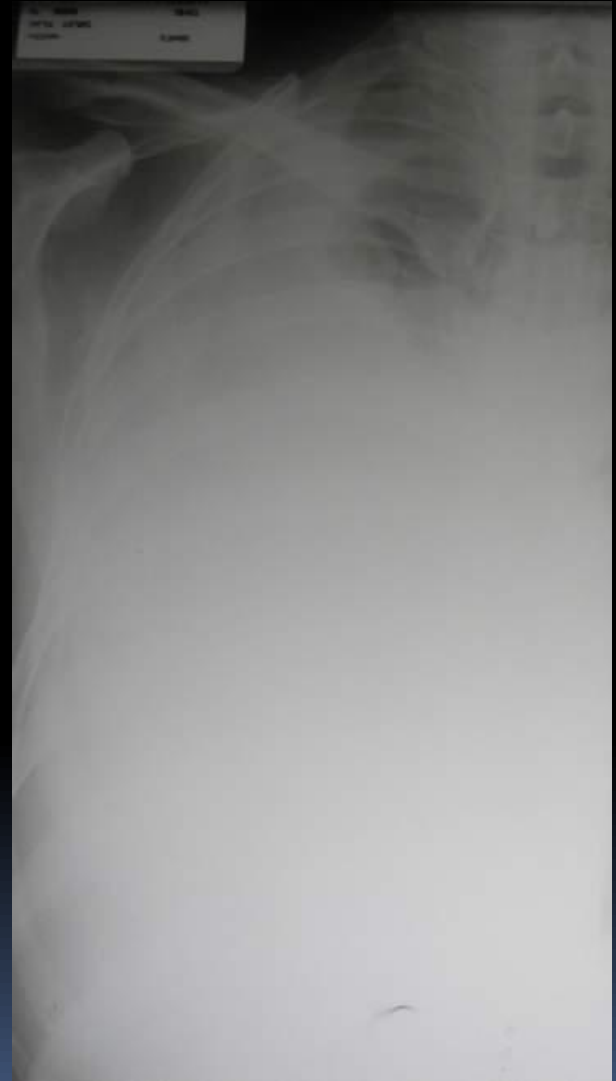
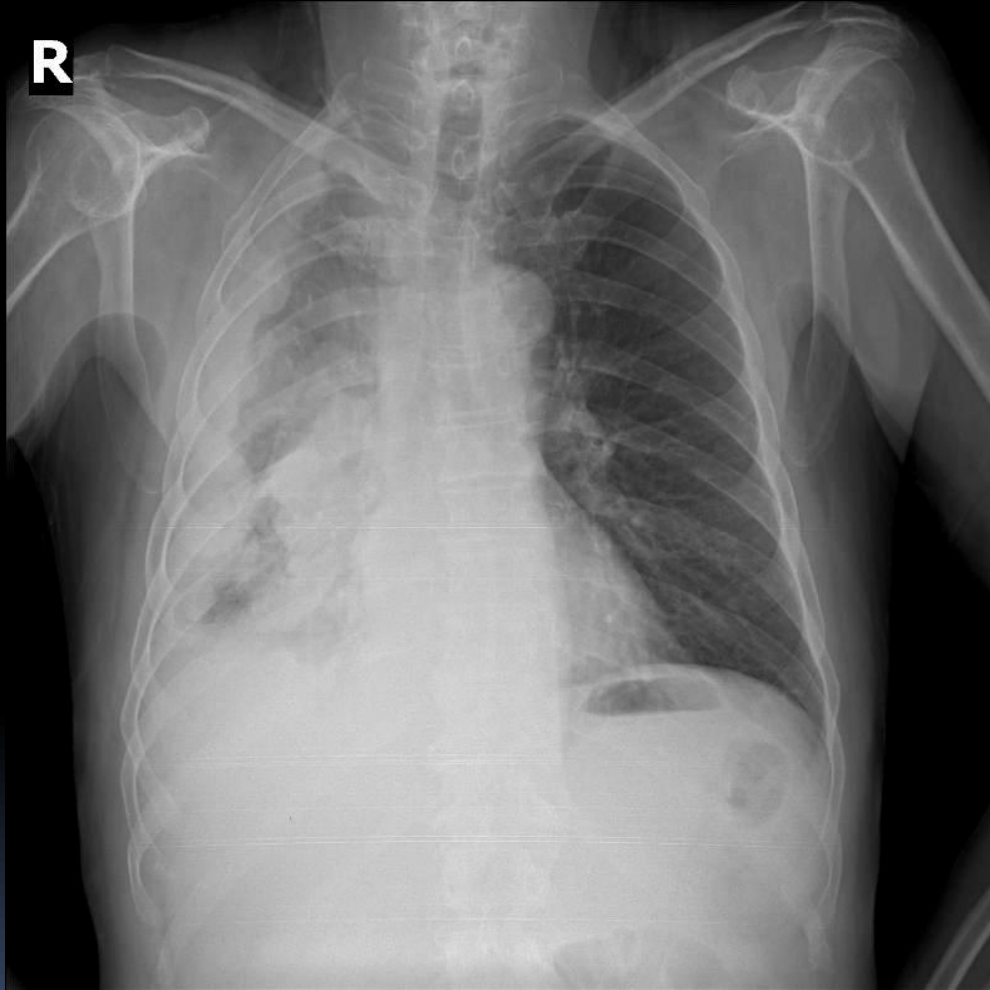


LIPOM

# PLEVRAL NEOPLAZI

# MALIGN PLEVRA LEZYONLARI

- MALIGN PLEVRAL MEZOTELYOMA
- METASTAZ
- LENFOMA
- PNET
- PLEVRAL HEMANJIOENDOTELYOMA
- SARKOM
- SCHWANNOMA

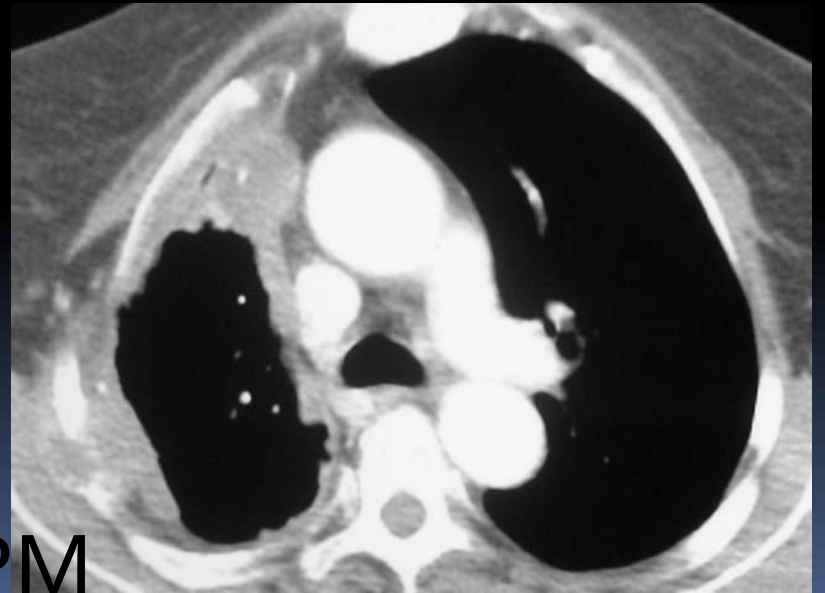
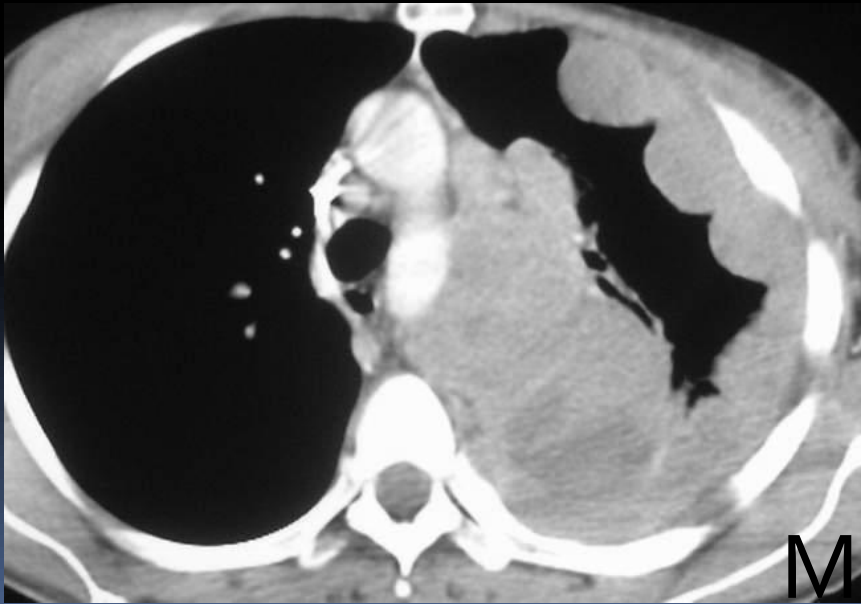
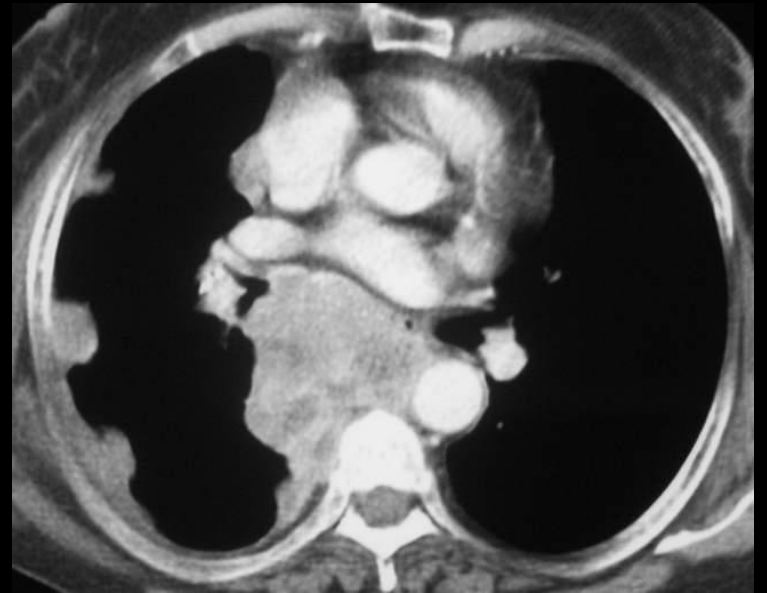
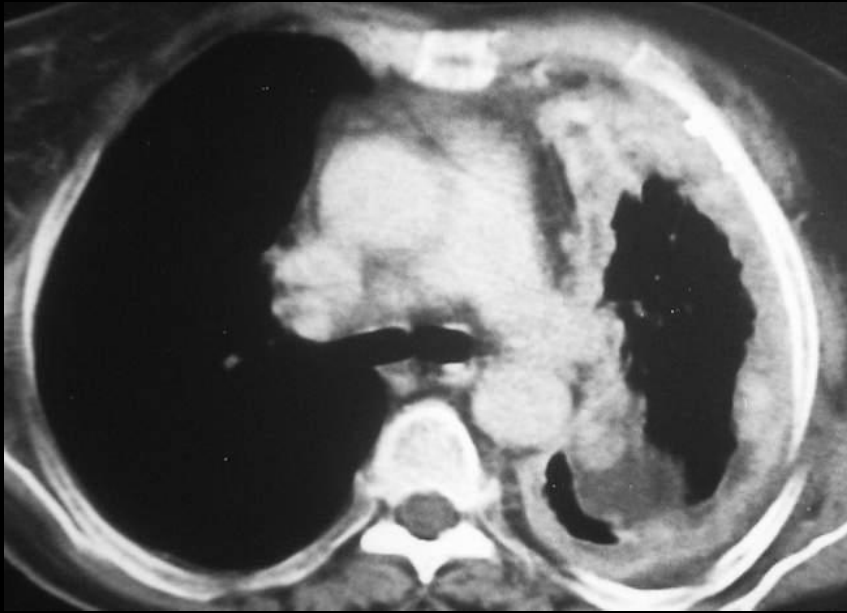


MPM

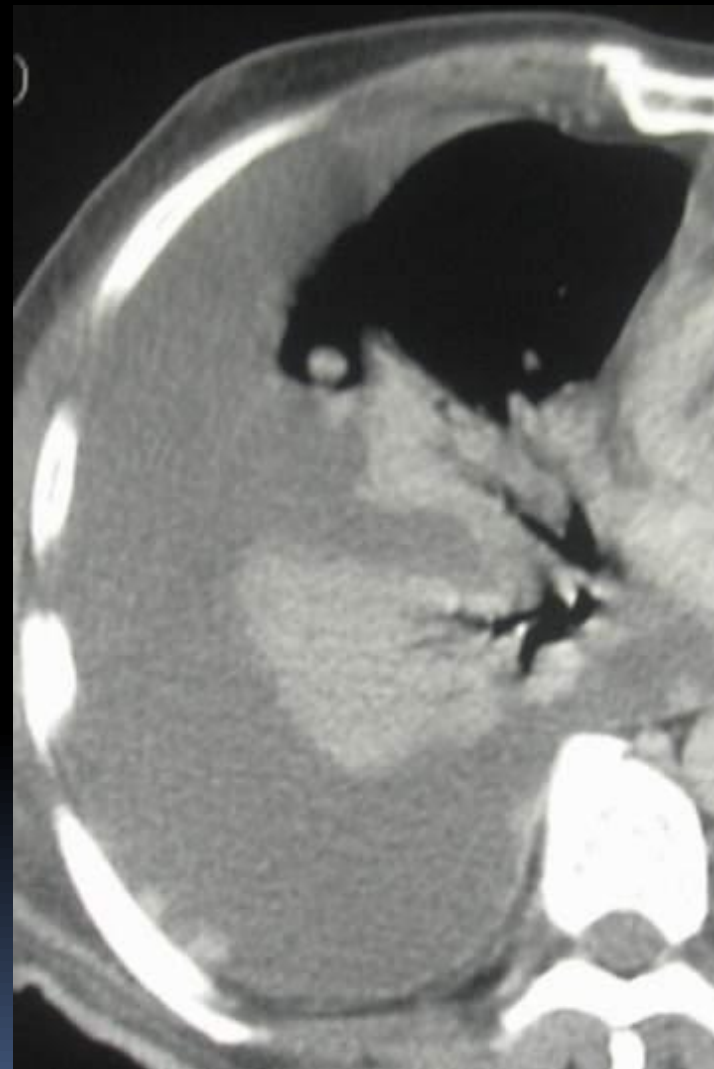
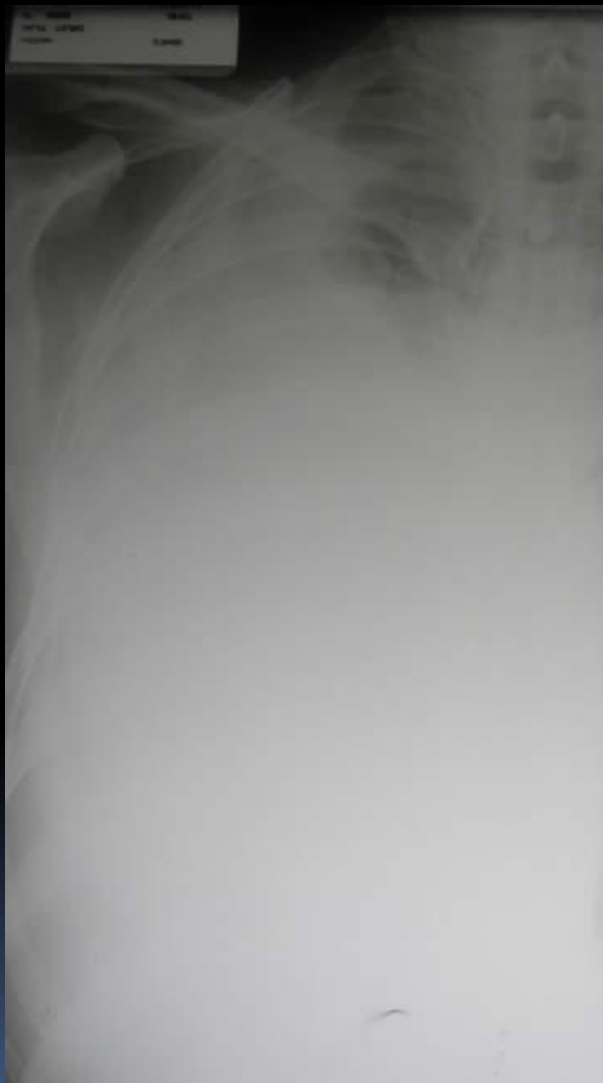# MPM'DA BT BULGULARI

- Çevresel plevral kalınlaşma
- Nodüler plevral kalınlaşma
- Plevral kalınlaşma 1 cm'den fazla
- Mediastinal plevral yayılım

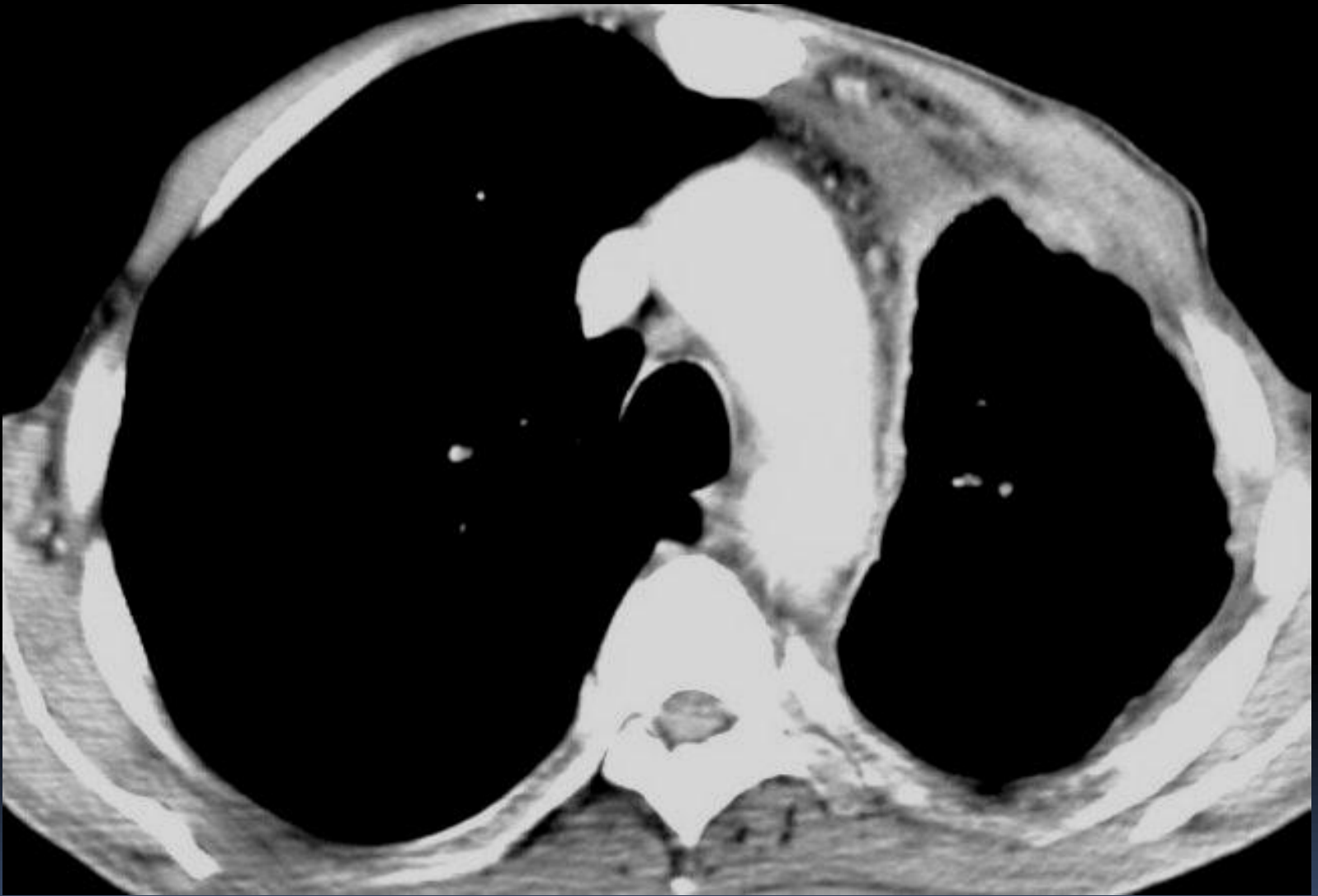



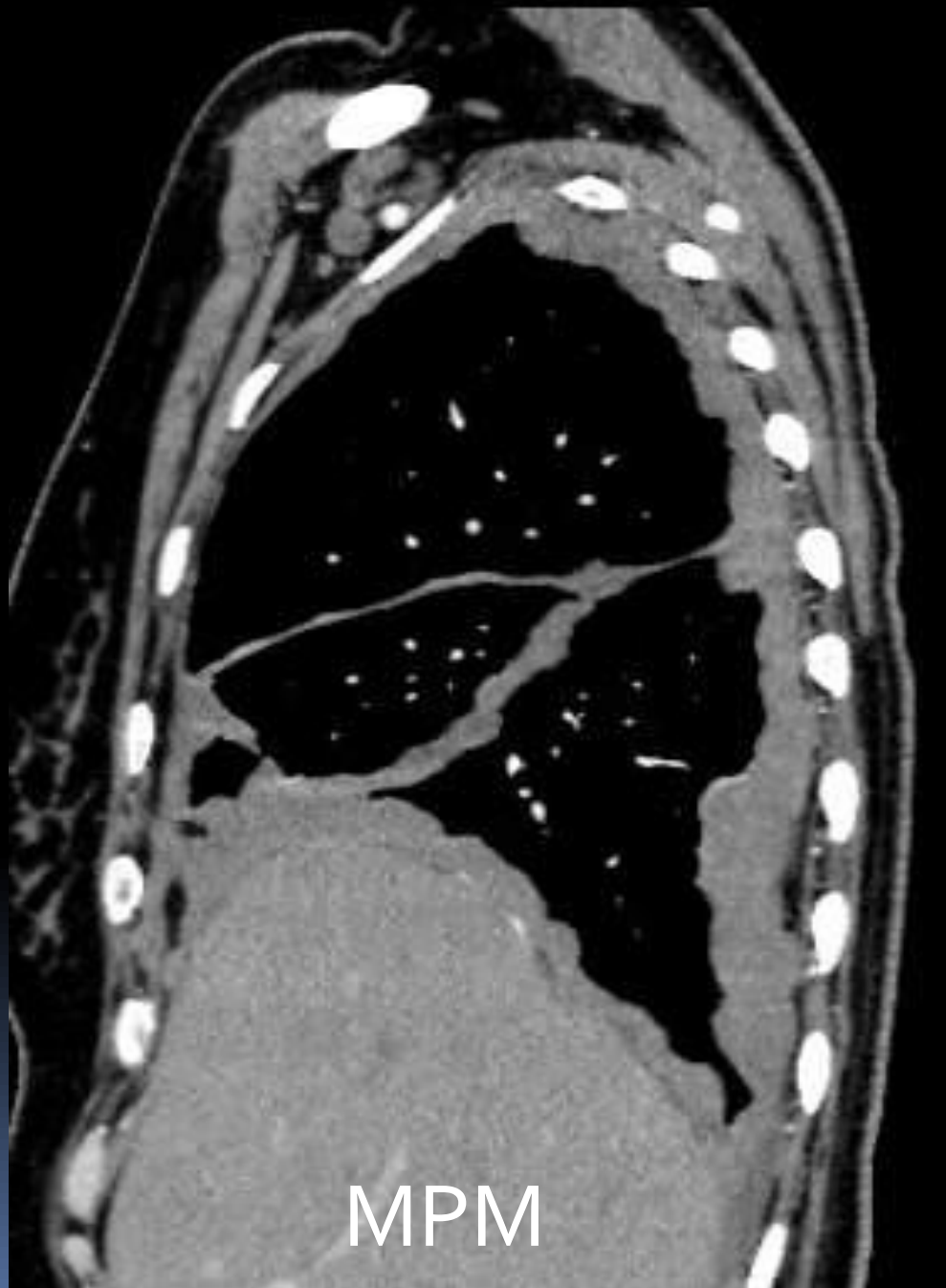MPM



MPM



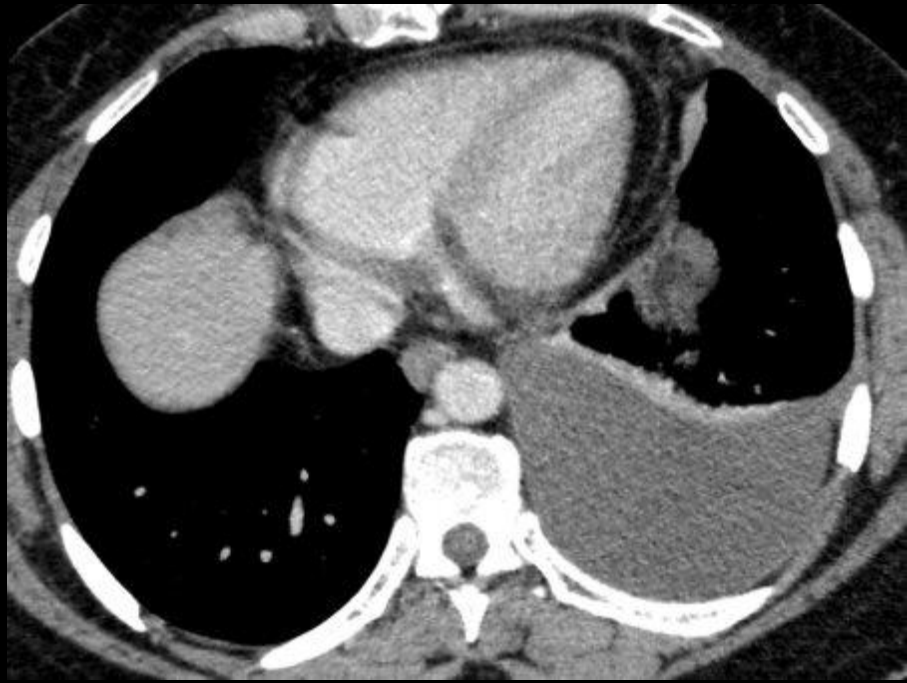
MPM



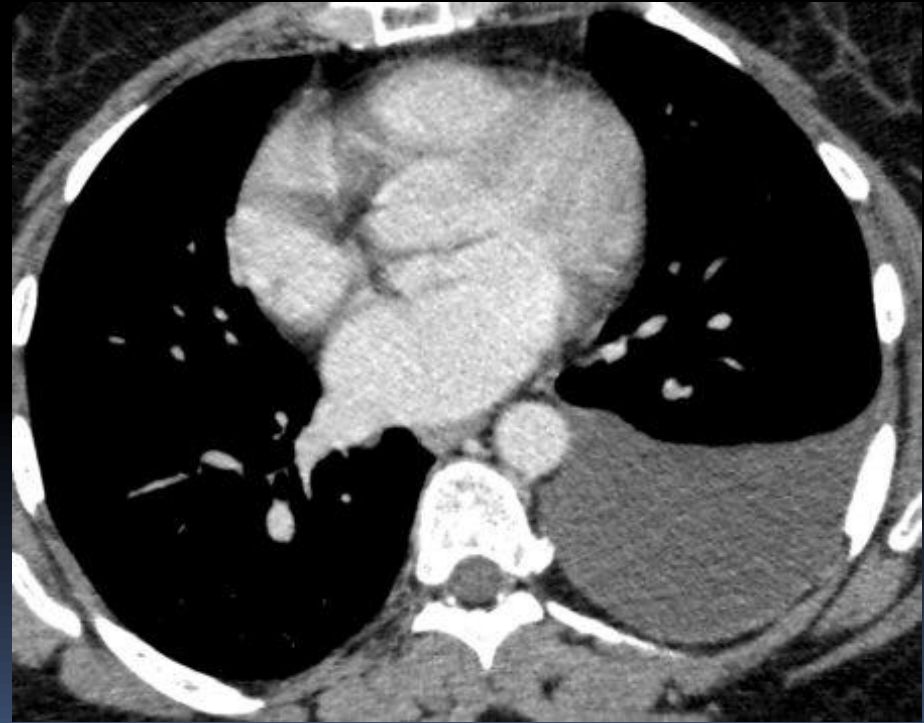
MPM

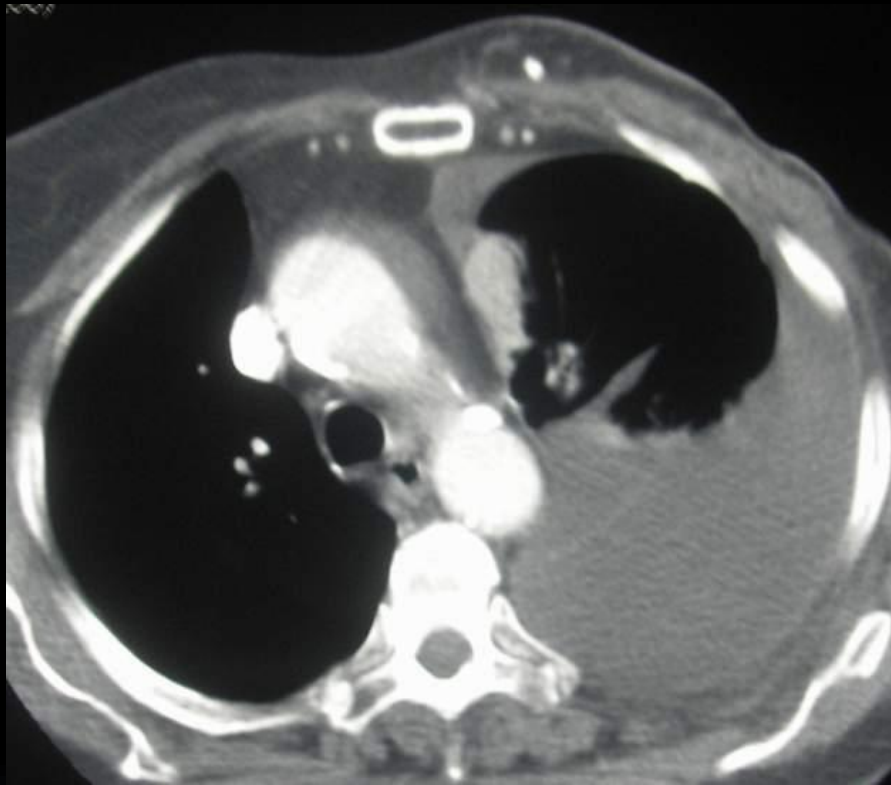
# MPM'DA BT BULGULARI

- Yalnız plevral sıvı
- Plevral kalınlaşma düzgün ve ince
- Plevral tümöral kalınlaşma düşük atenüasyonda
- Komşu dokulara invazyon, miliyer yayılım, metastatik depozitler

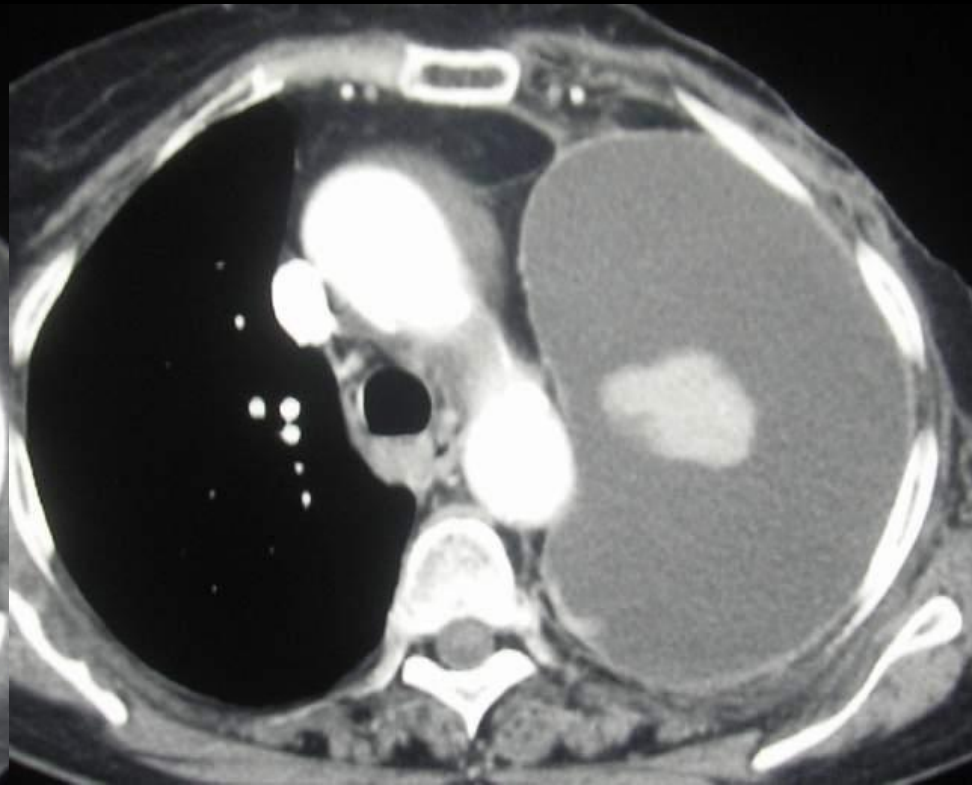


MPM



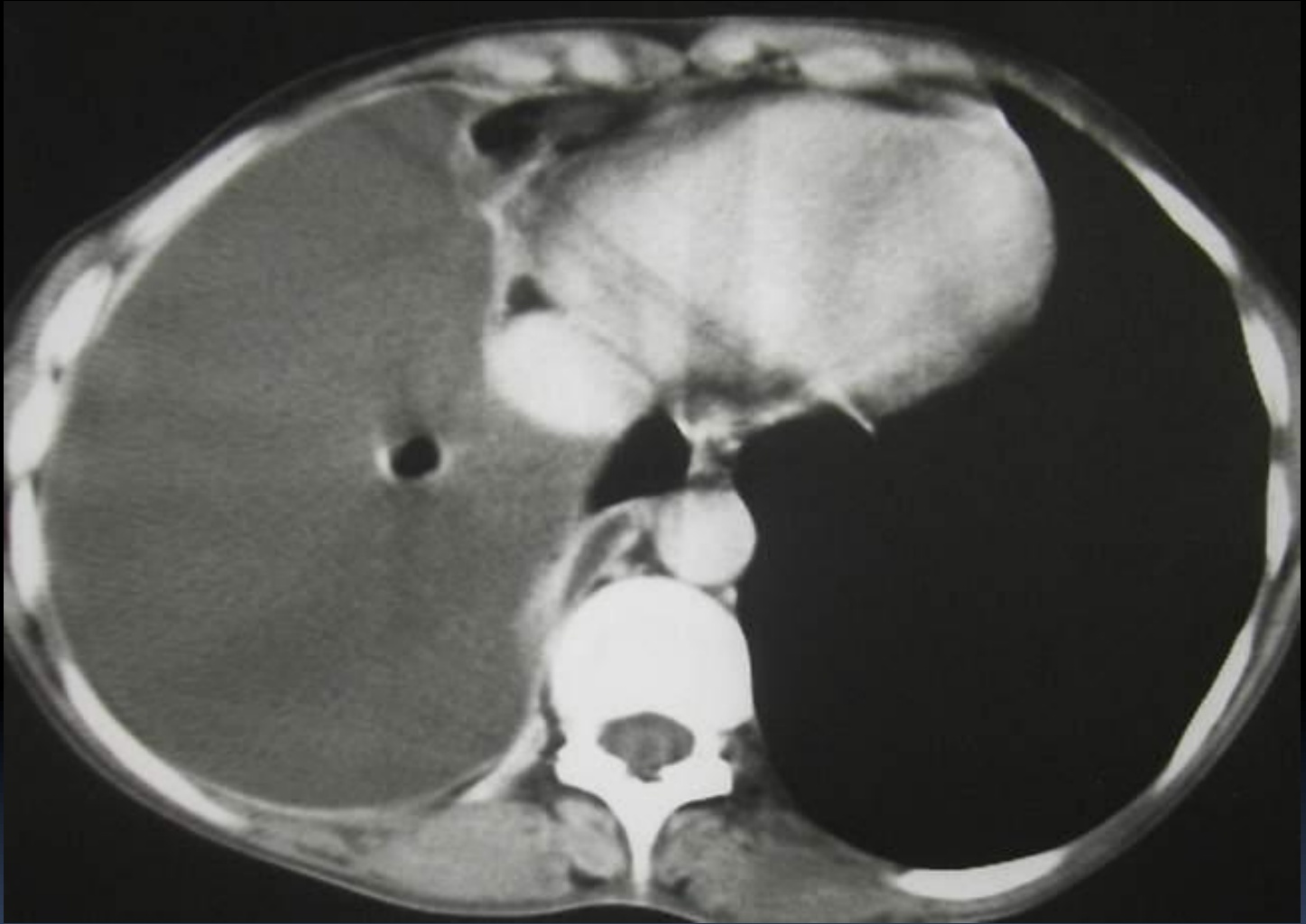


21-03-06



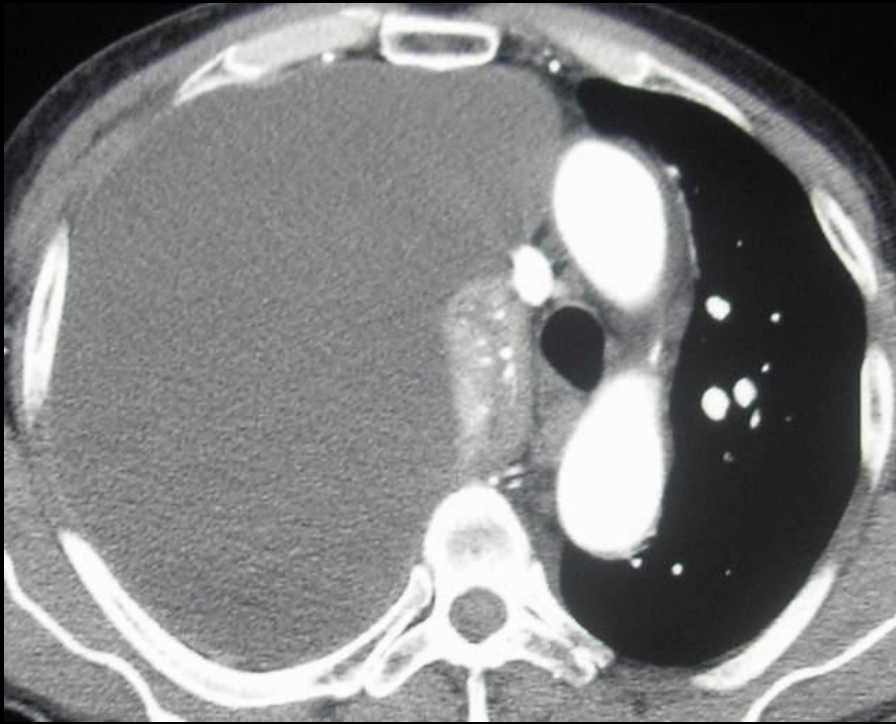
31-05-06

MPM

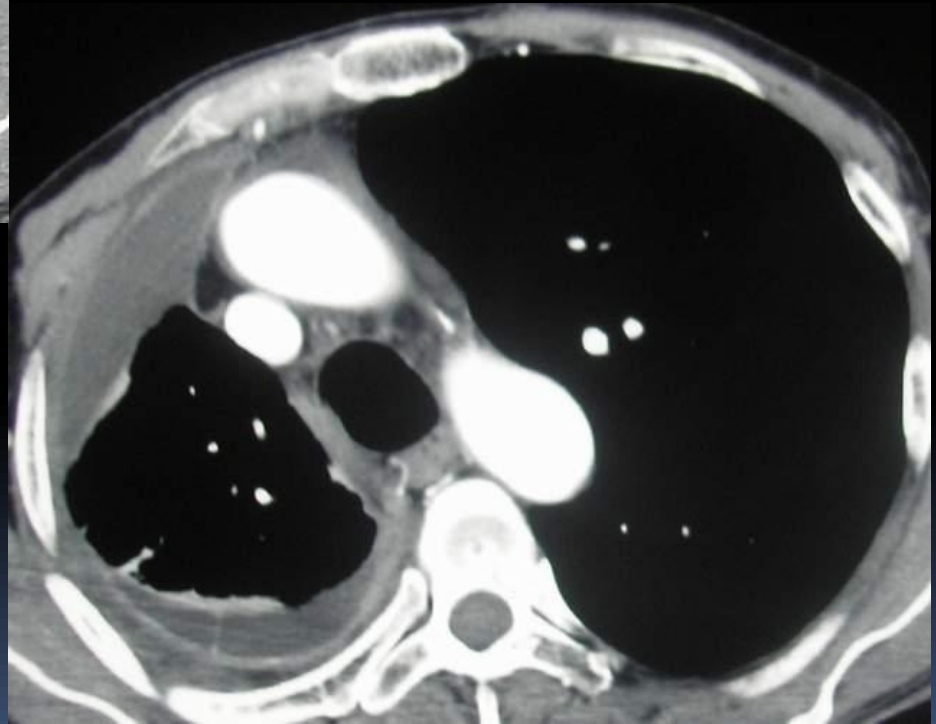


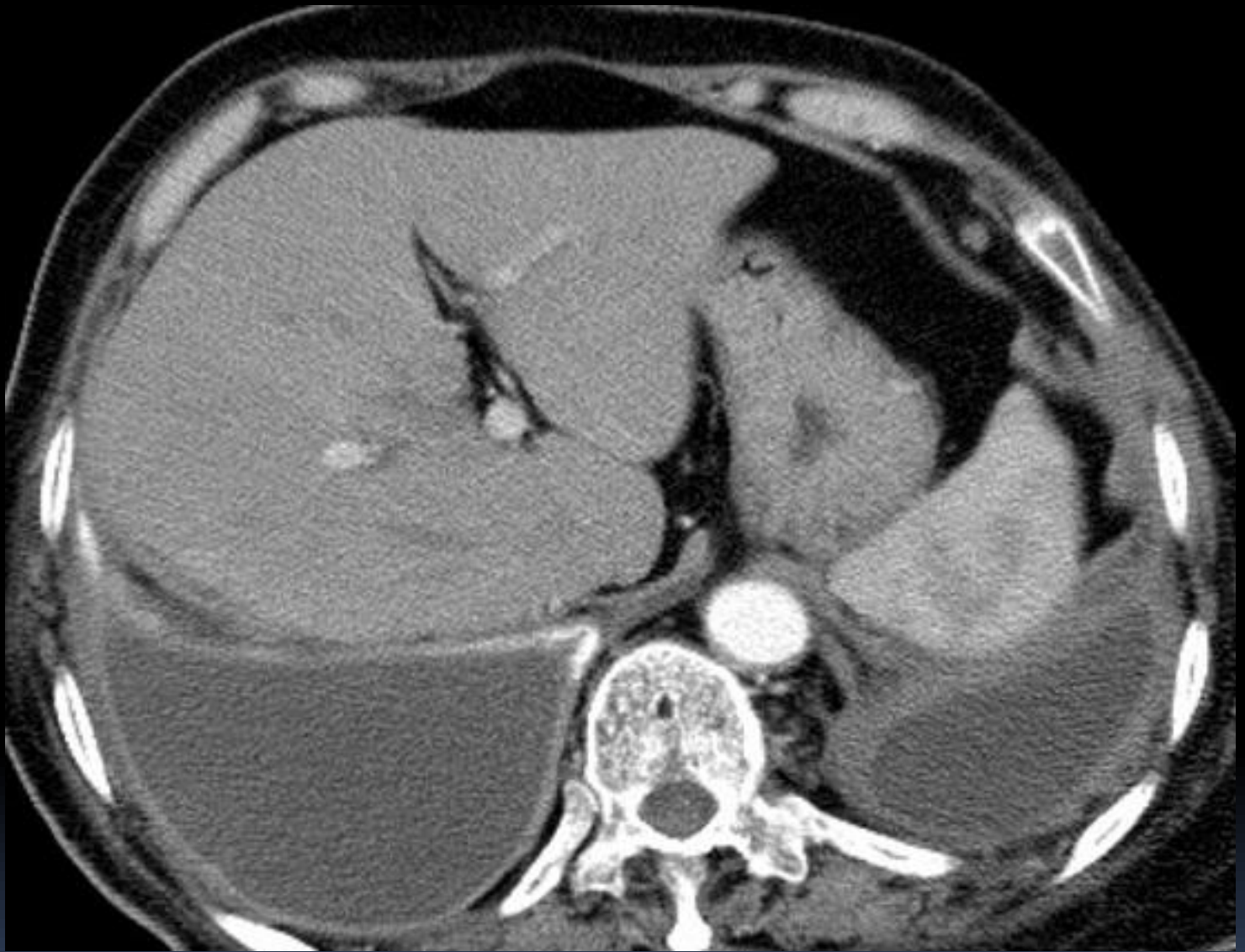
MPM





MPM

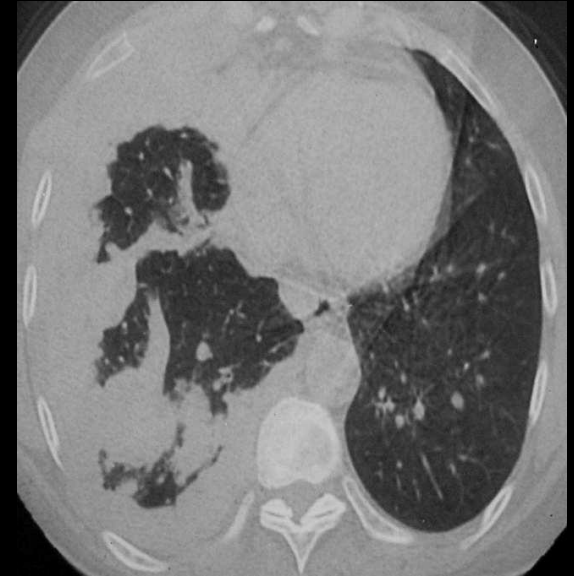
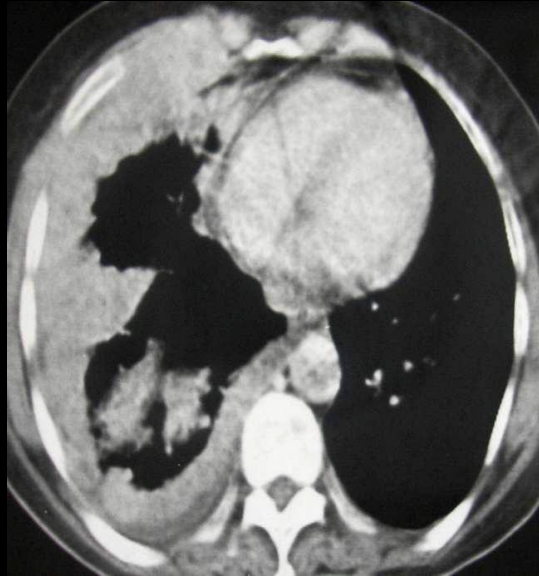


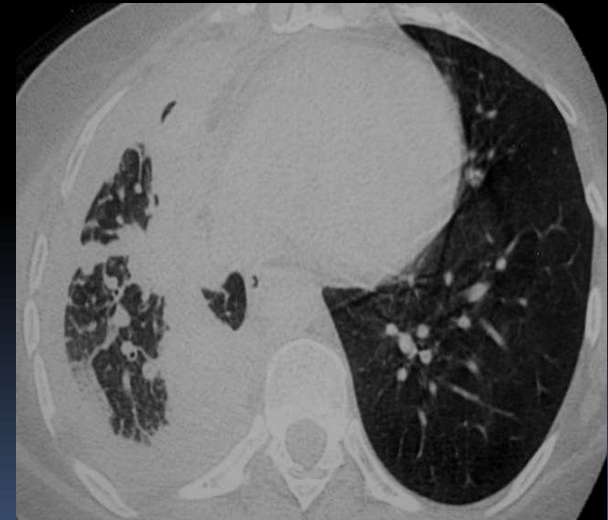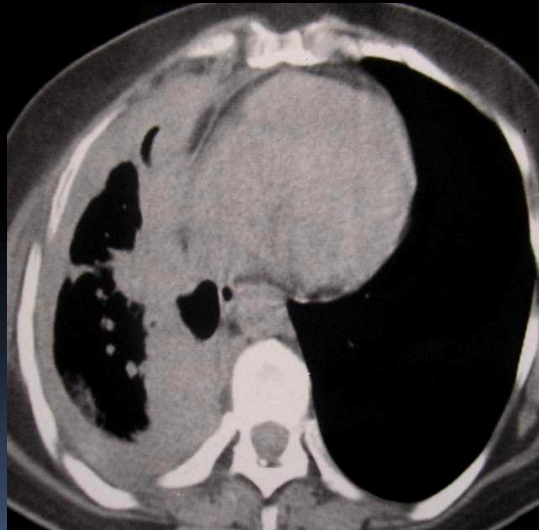
BILATERAL MPM

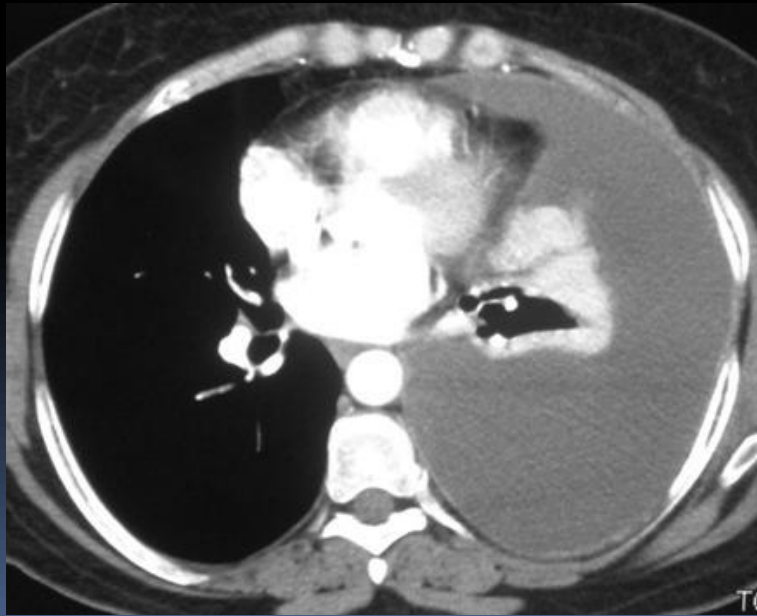
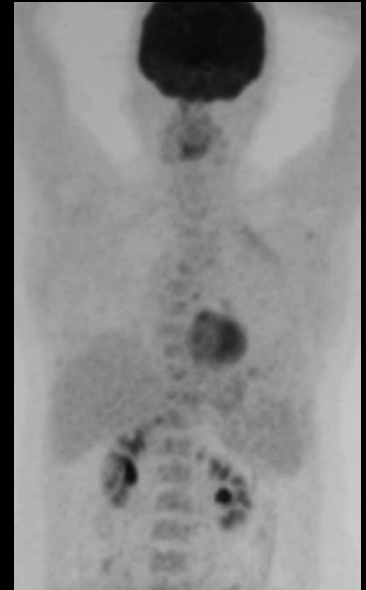
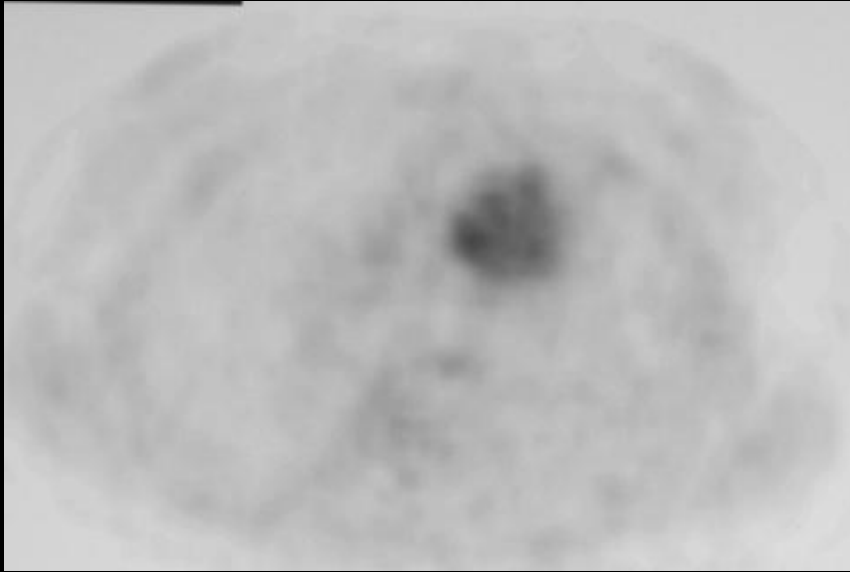
- PLEVRA YITUTAN HERHANGİ BİR MALİGN TÜMÖR MALİGN PLEVRA MEZOTELYOMA GÖRÜNÜMÜNÜ TAKLİT EDEBİLİR

METASTAZ

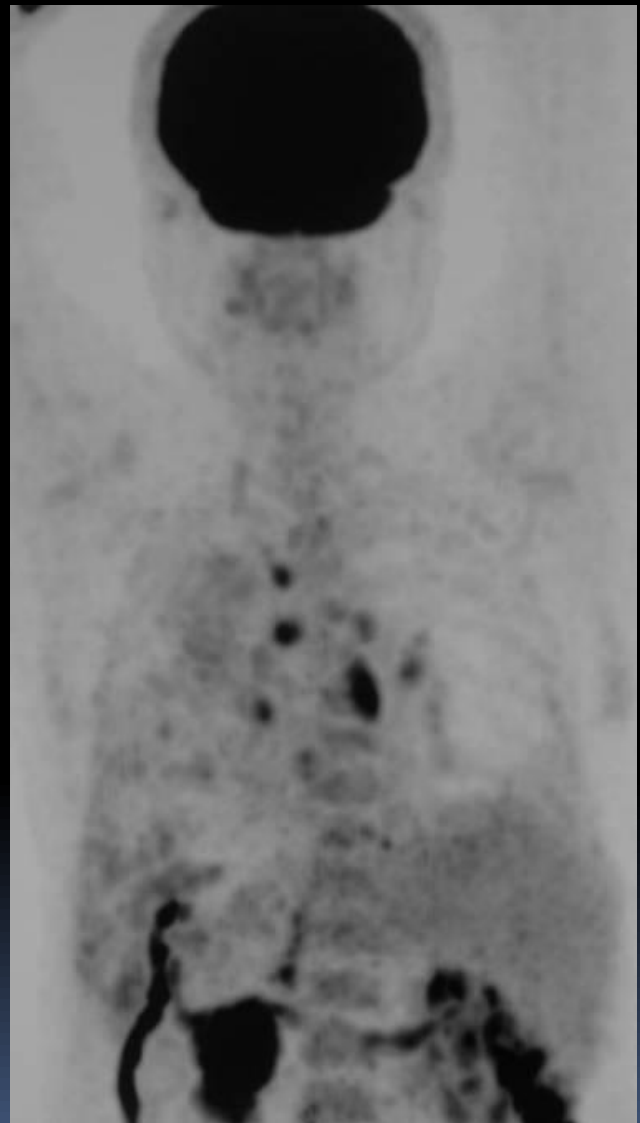
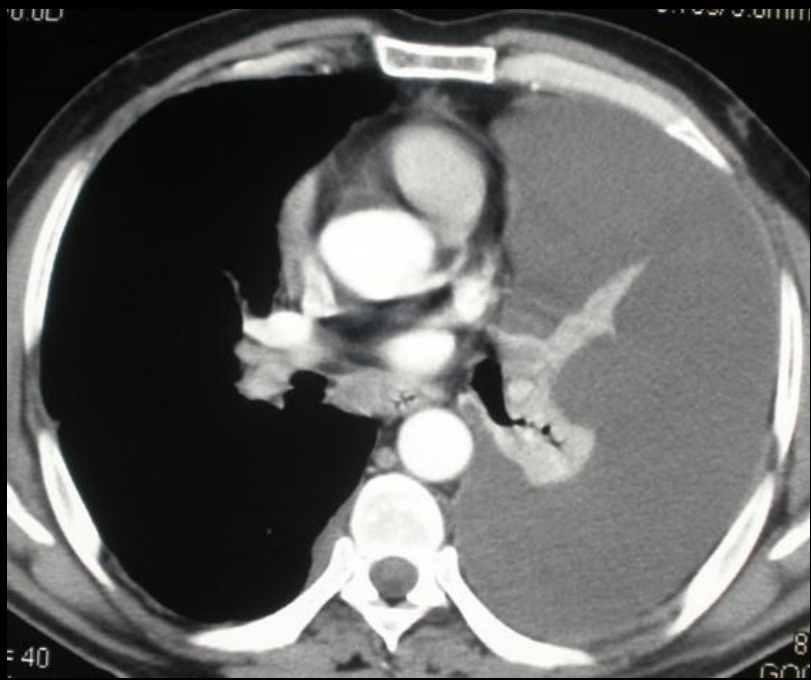


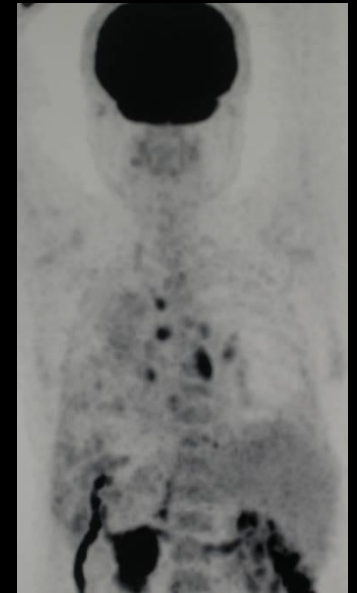
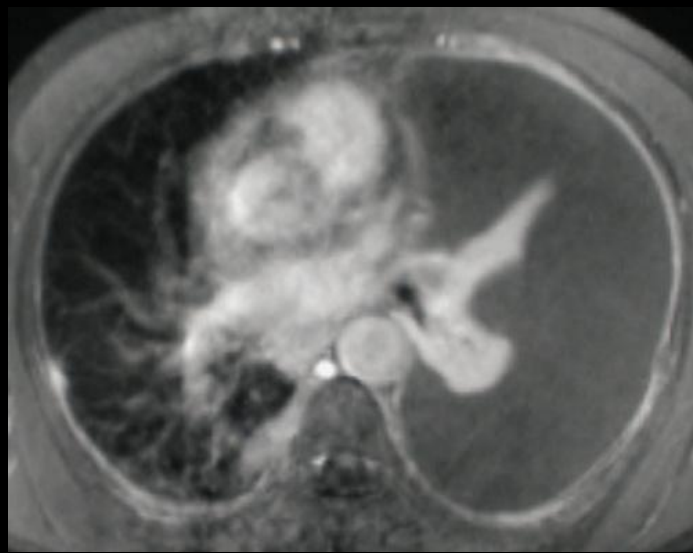
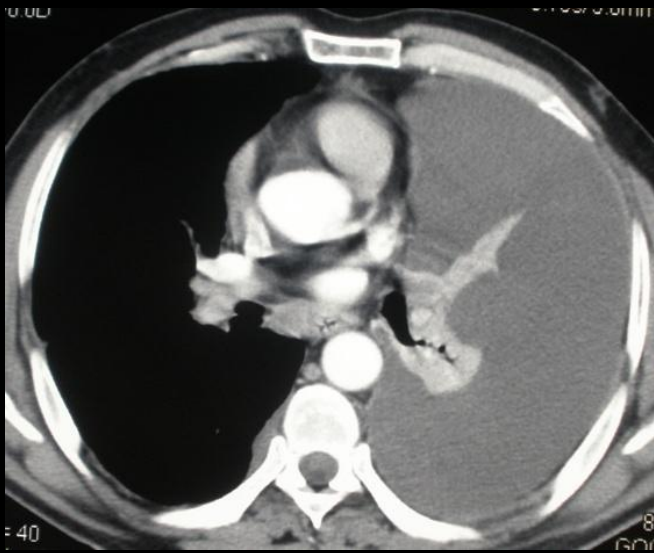
LENFOMA



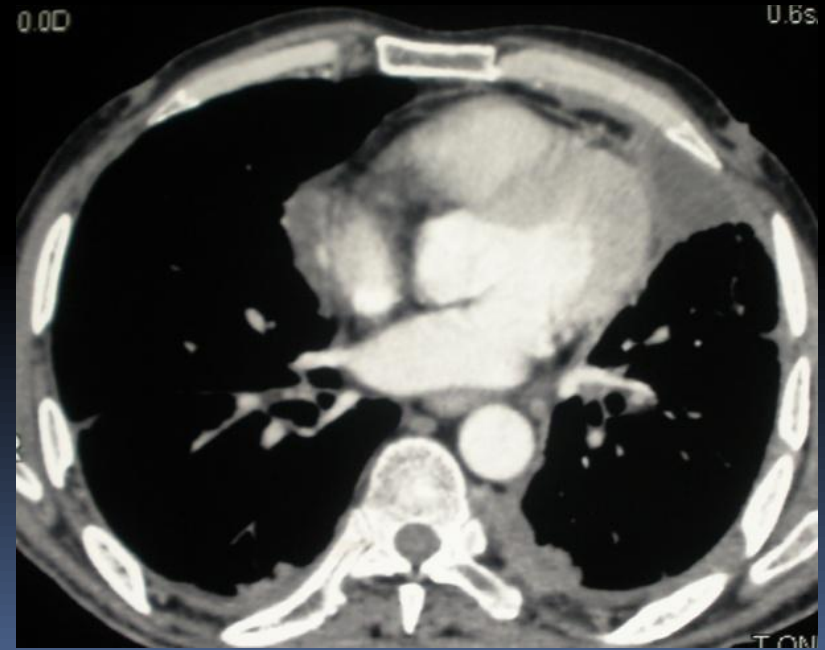


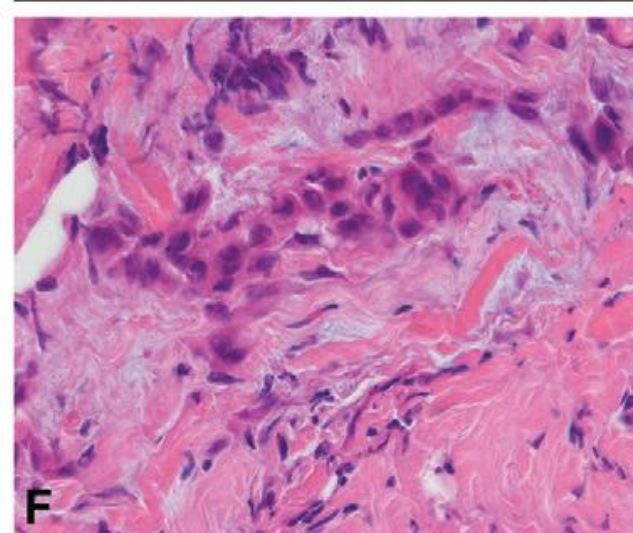
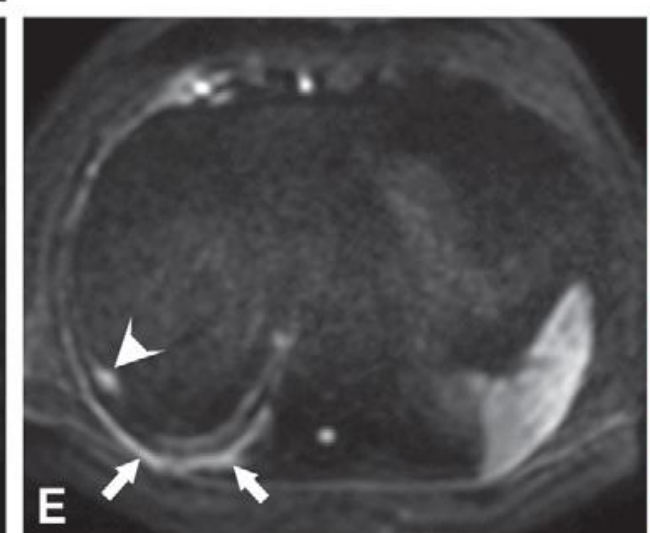
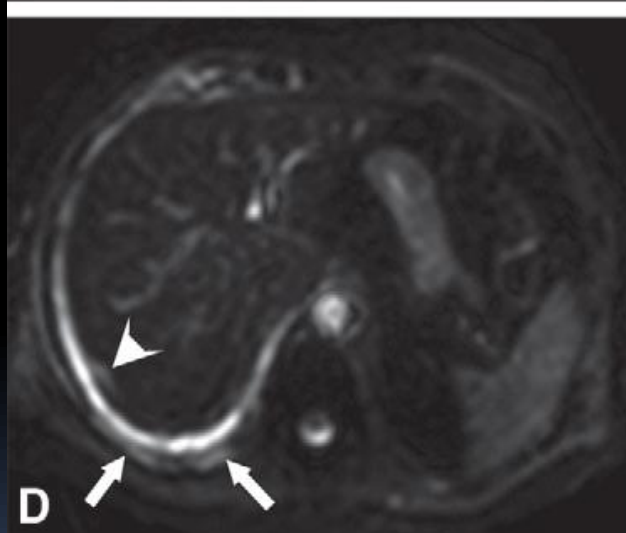
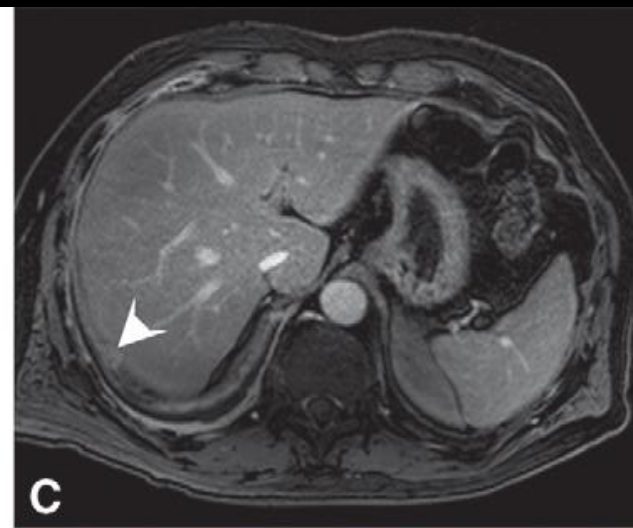
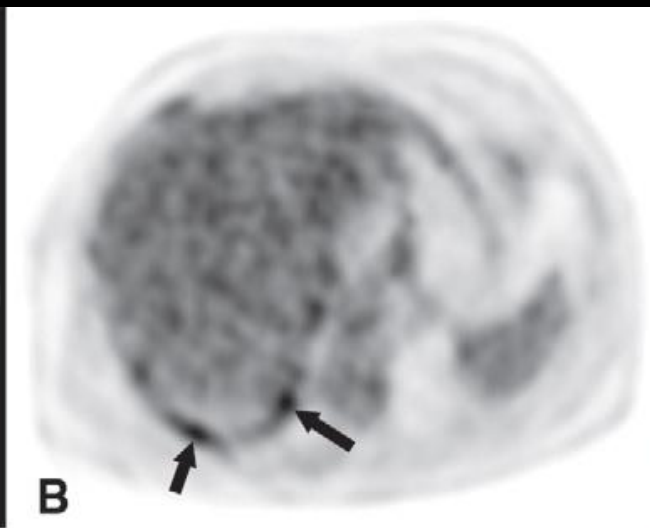
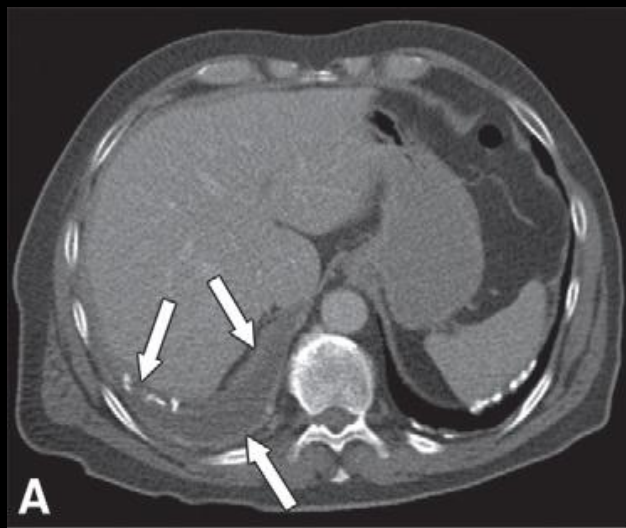
MPM





ADENO CA PLEVURAL  
METASTAZ

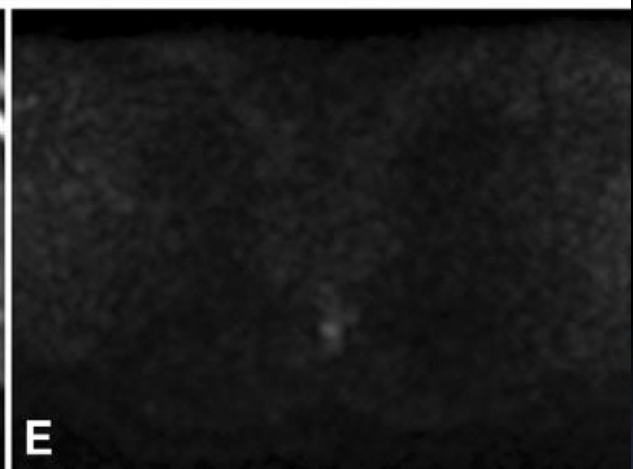
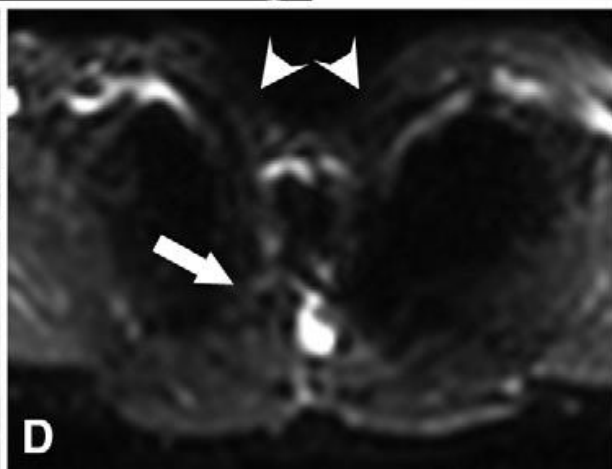
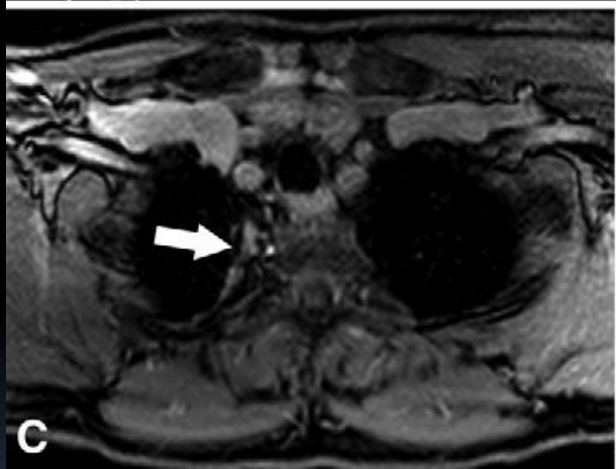

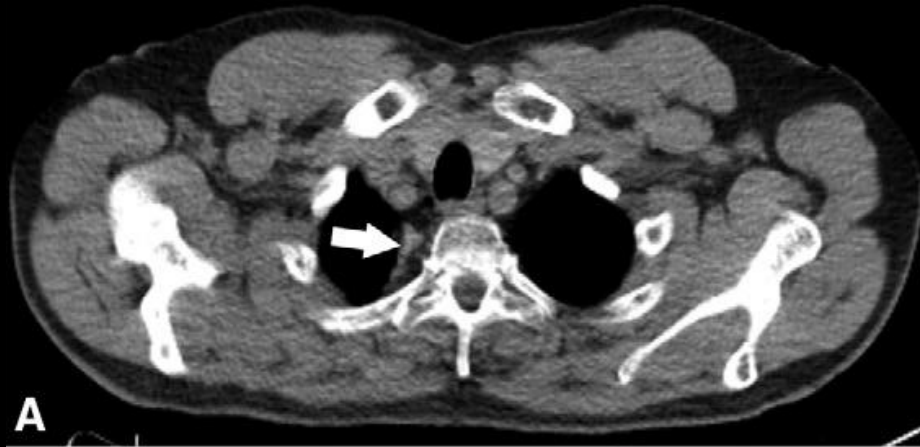




ADC:1.21

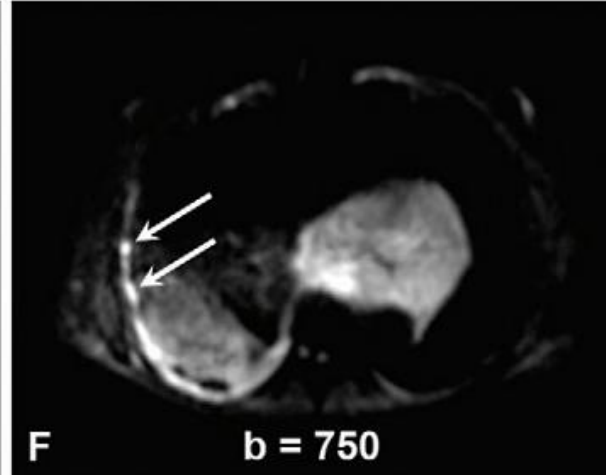
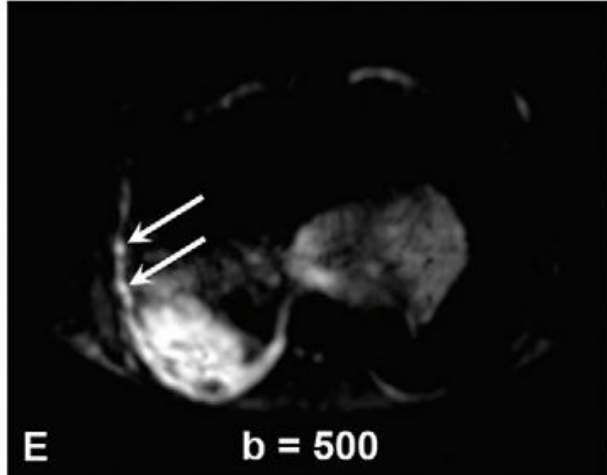
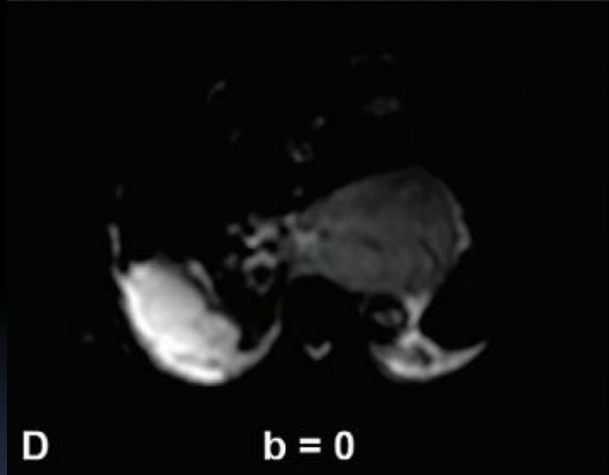
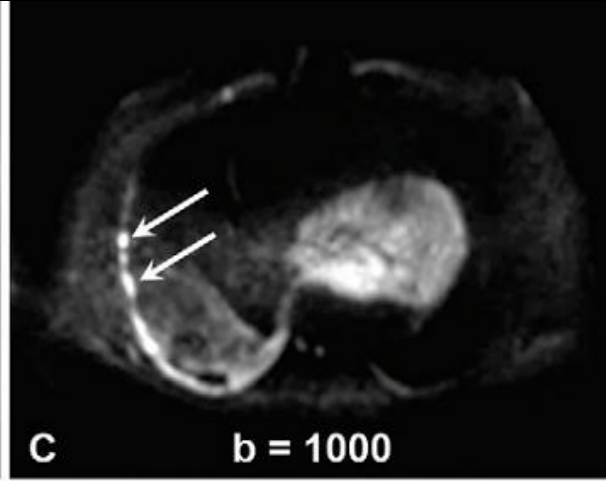
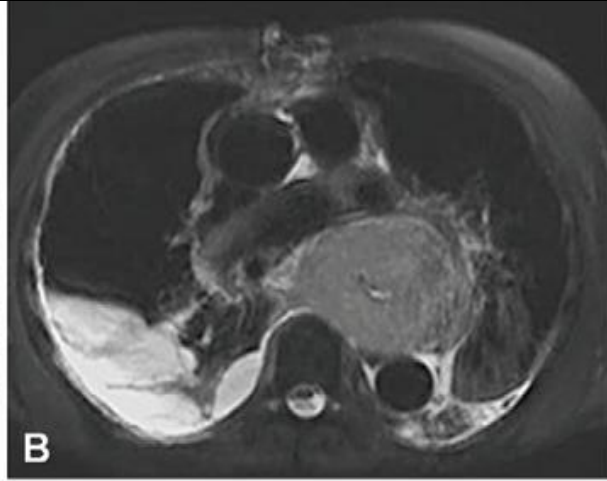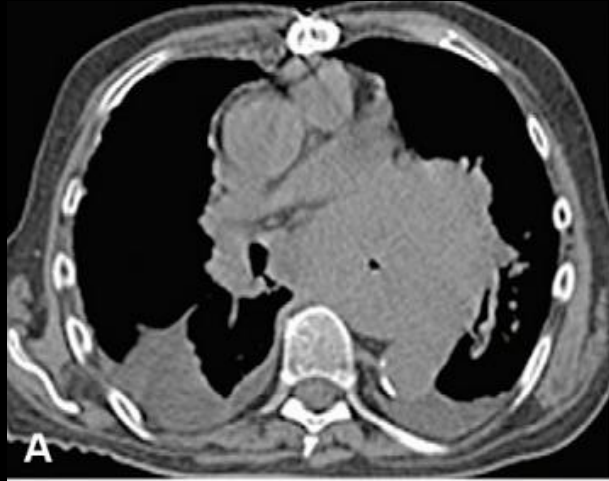Coolen J ve ark.  
Radiology 2012;263(3): 884-892





ADC:2.21

Coolen J ve ark.  
Radiology 2012;263(3): 884-892



Coolen J ve ark  
Radiology 2015; 274:576–584

# MALİGN PLEVRAL HASTALIKLARDA DW MR, DKE MR, PET/BT

- PET/BT
  - Duyarlılık % 100
  - Özgüllük % 35.3
  - Doğruluk % 64,5
- DW MR
  - Duyarlılık % 71.4
  - Özgüllük % 100
  - Doğruluk % 87.1
- DKE MR
  - Duyarlılık % 92.8
  - Özgüllük % 94.1
  - Doğruluk % 93.5

Coolen J ve ark.  
Radiology 2012;263(3): 884-892

# SOLID PLEVRAL METASTAZ

- MR
  - Sensitivity 100%, specificity 93%, positive predictive value (PPV) 96%, negative predictive value (NPV) 100%
- PET-BT
  - Sensitivity 96.8%, specificity 88.5%, PPV 93.8%, NPV 93.9%

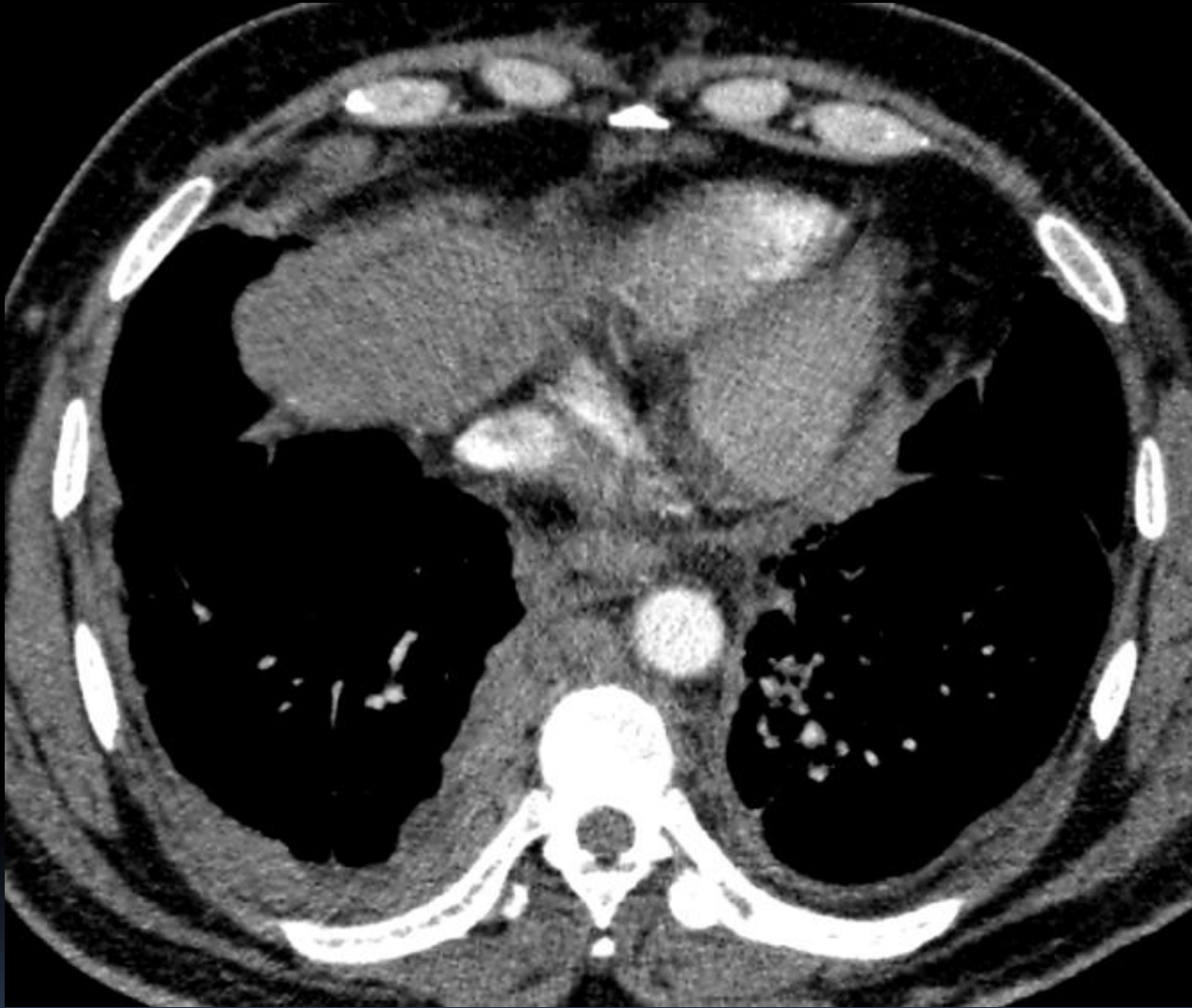
Statdx

# PET-BT

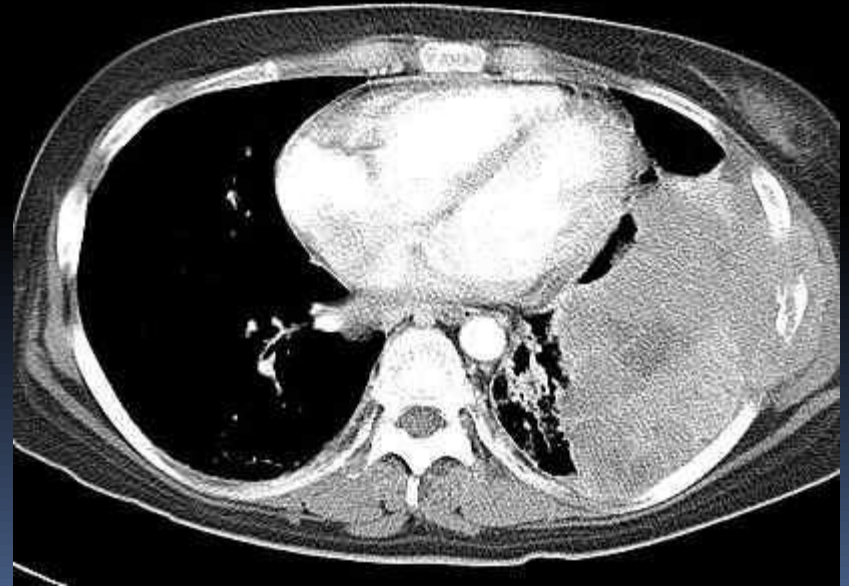
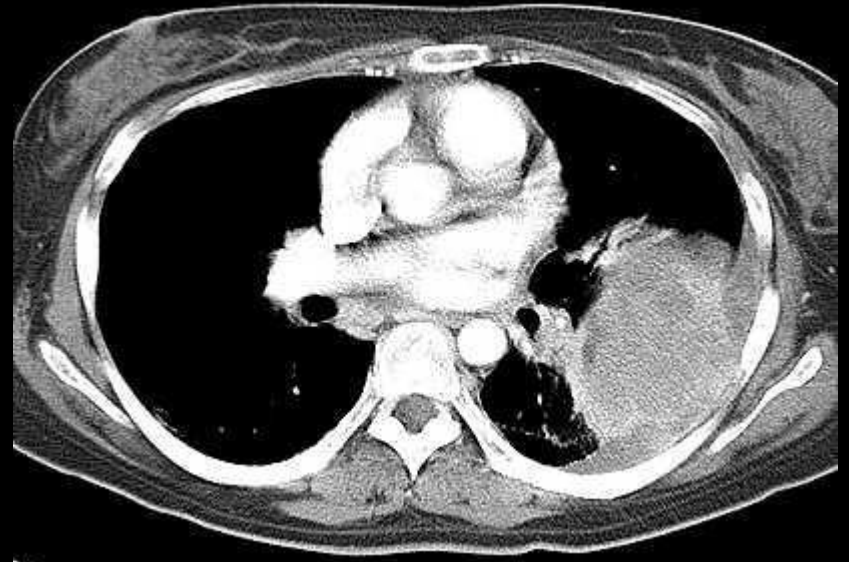
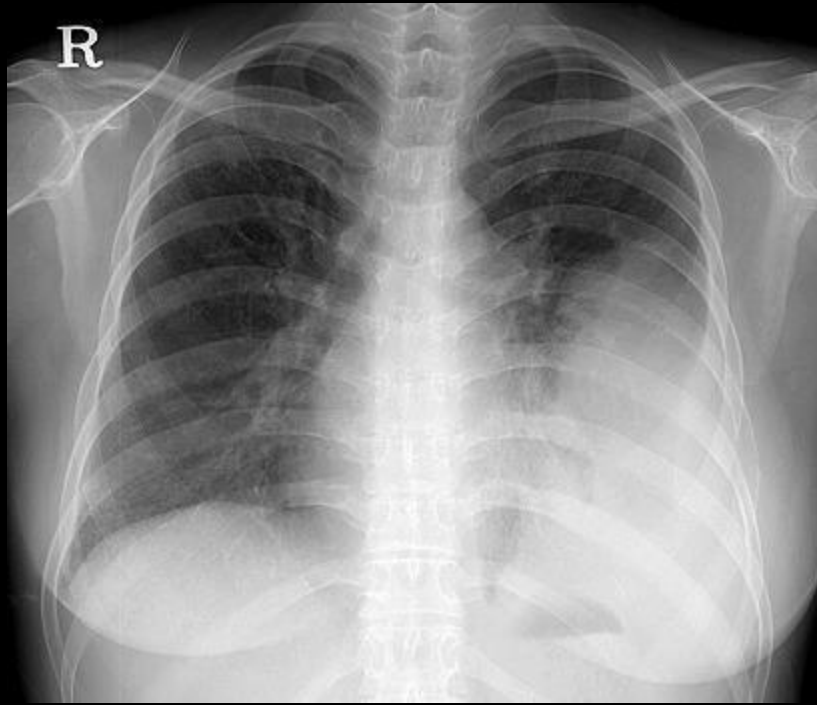
- PET-BT ile yapılan son iki metaanaliz sonuçları
  - Sensitivite % 95, spesifite % 82 (Treglia G, et al., *Acad Radiol*, 2014. 21(1): p. 11-20)
  - Sensitivite % 86, spesifite % 82 (Treglia G, et al., *Lung Cancer*, 2014. 83(1): p. 1-7)
- PET-BT ile olan potansiyel yanlış (-) veya yanlış (+) sonuçları bilmek zorundayız

# PET-BT

- Yanlıř (+) : İnfeksiyon, talk plöredesis
- Yanlıř (-) : Yalnız plevral sıvı ile izlenen malign plevral tümörler (primer veya metastatik)
- Nodal ve uzak metastaz saptamada üstündür
- Plevral biyopsi için optimal bölgeyi saptamada işe yarar

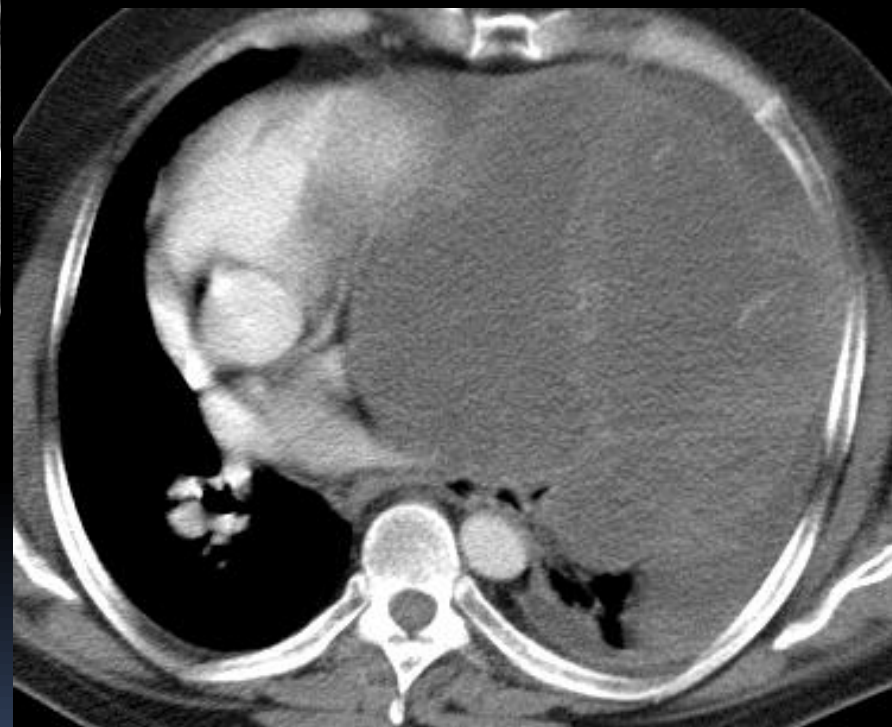
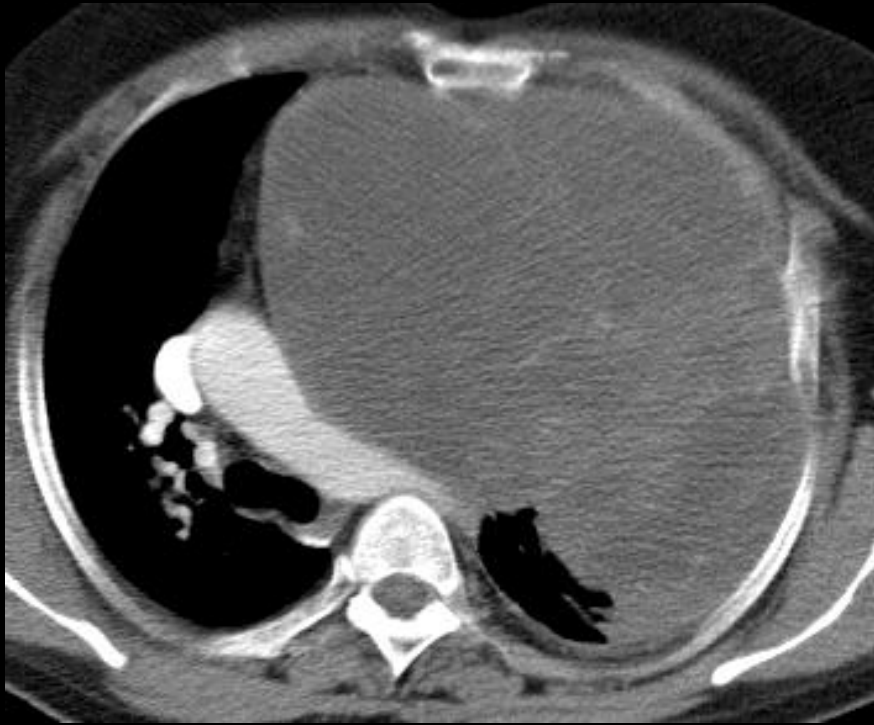
LENFOMA

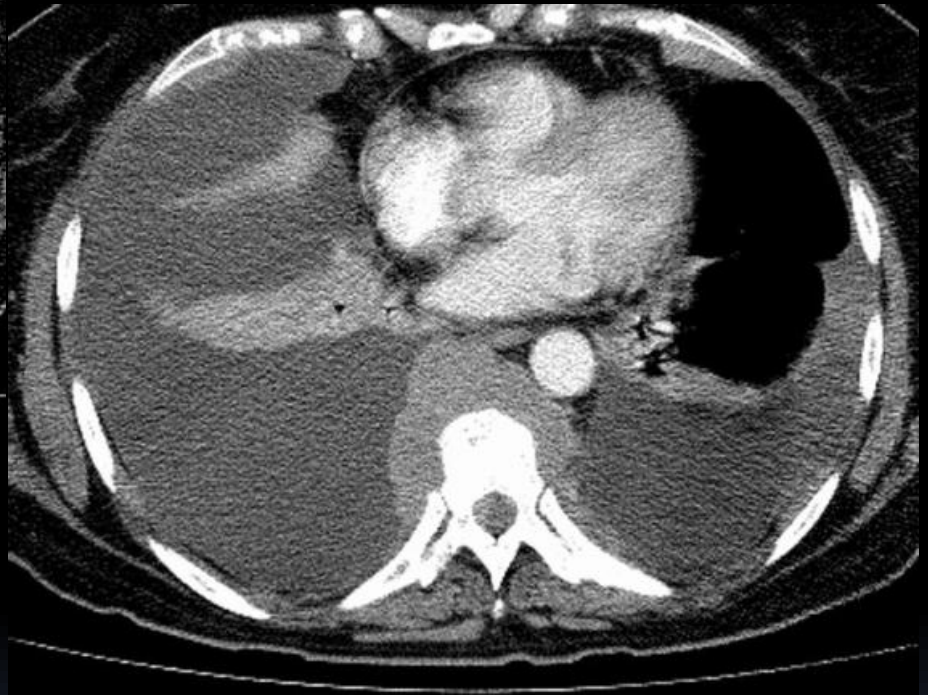
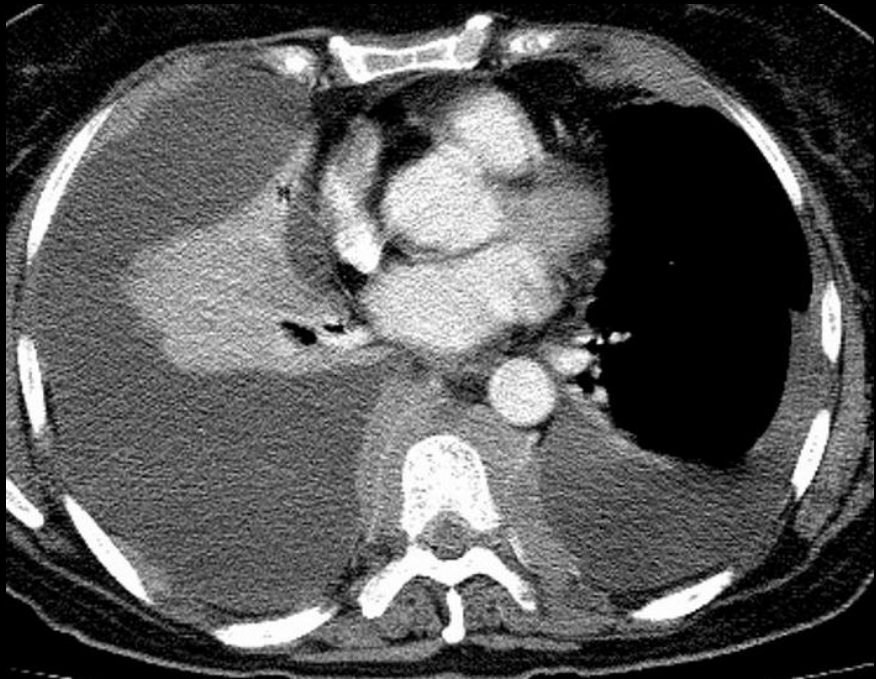


PNET



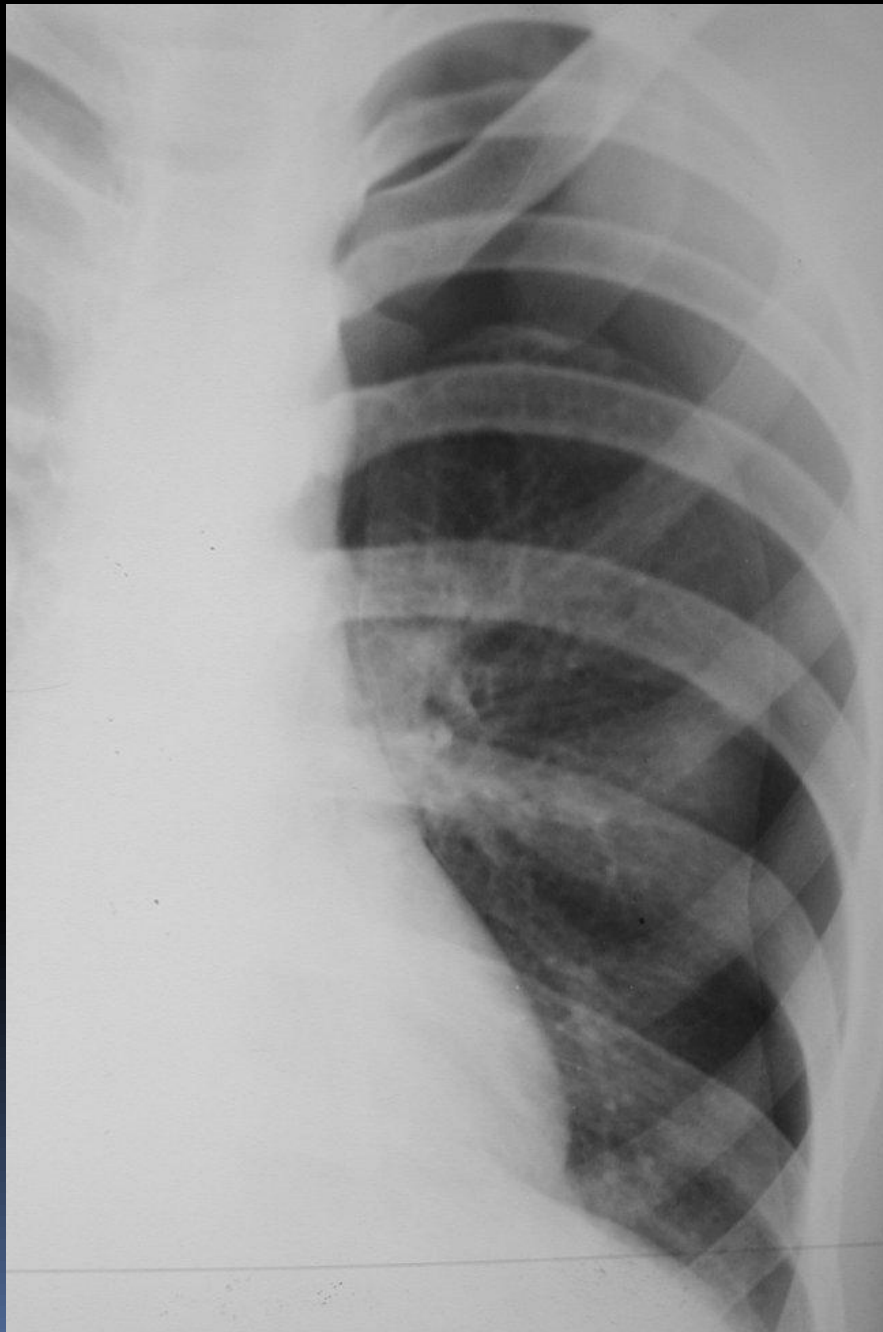


SARKOM



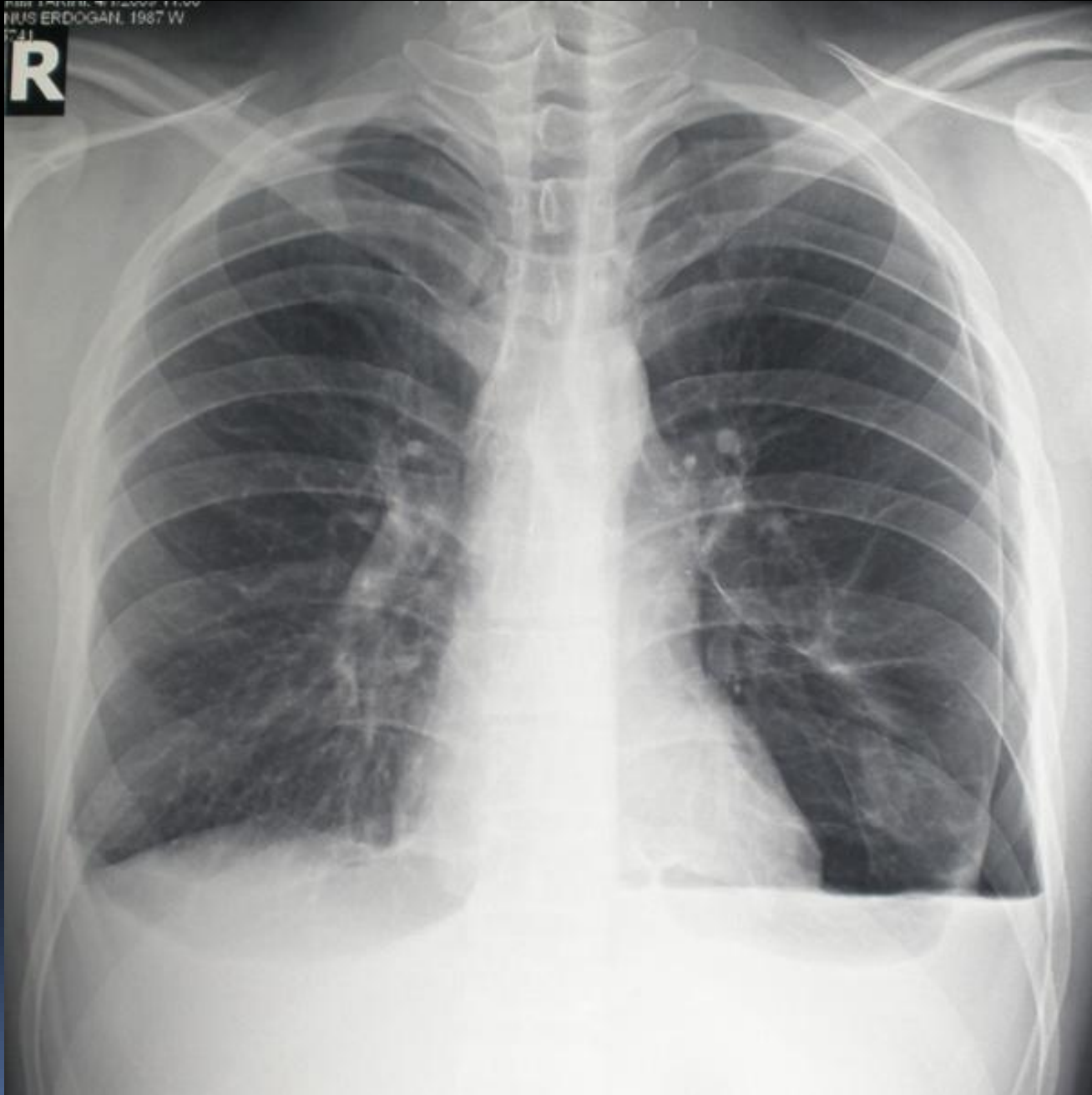
PLEVRAL HEMANGIOENDOTELIOMA

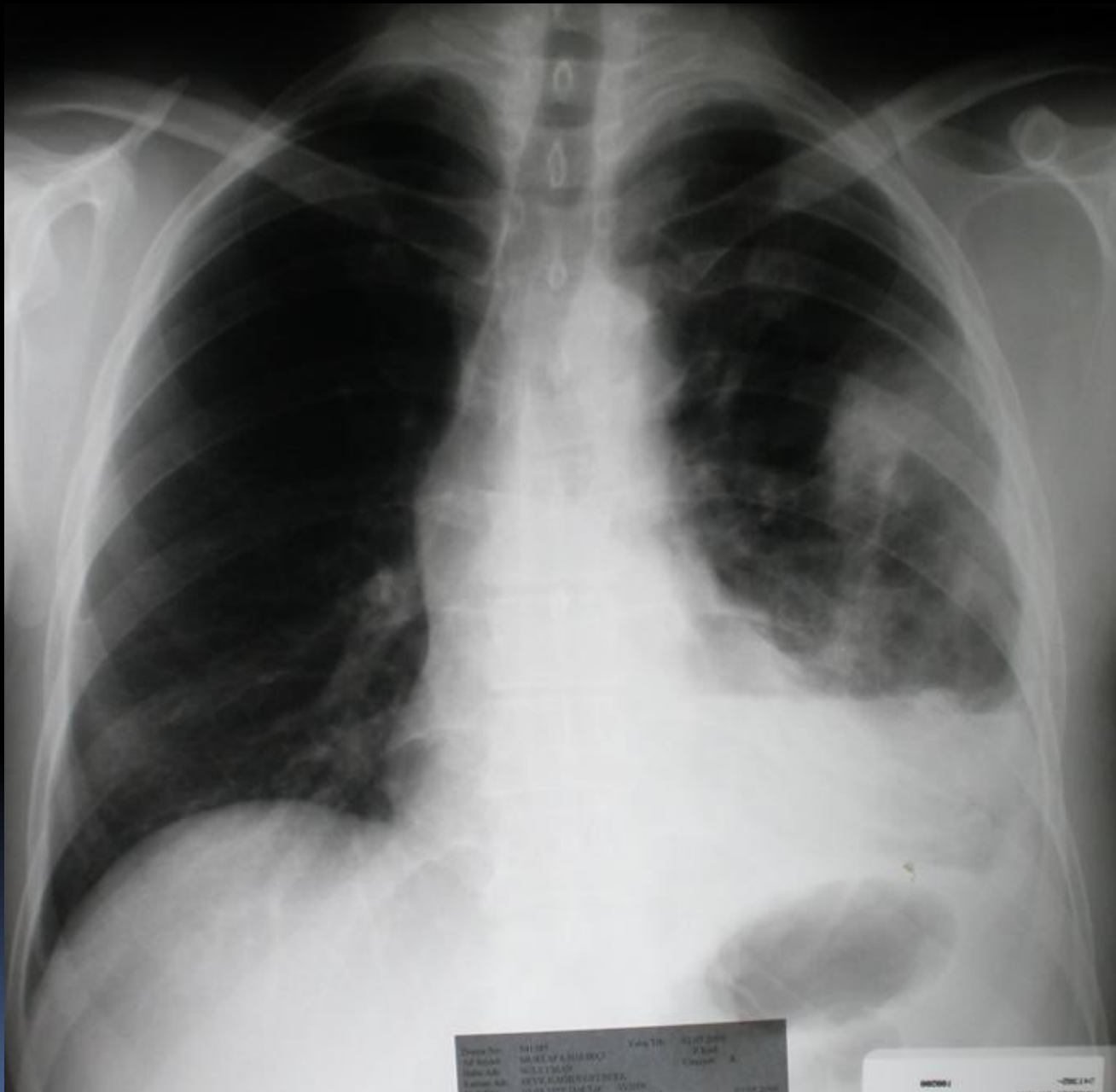
PNÖMOTORAKS

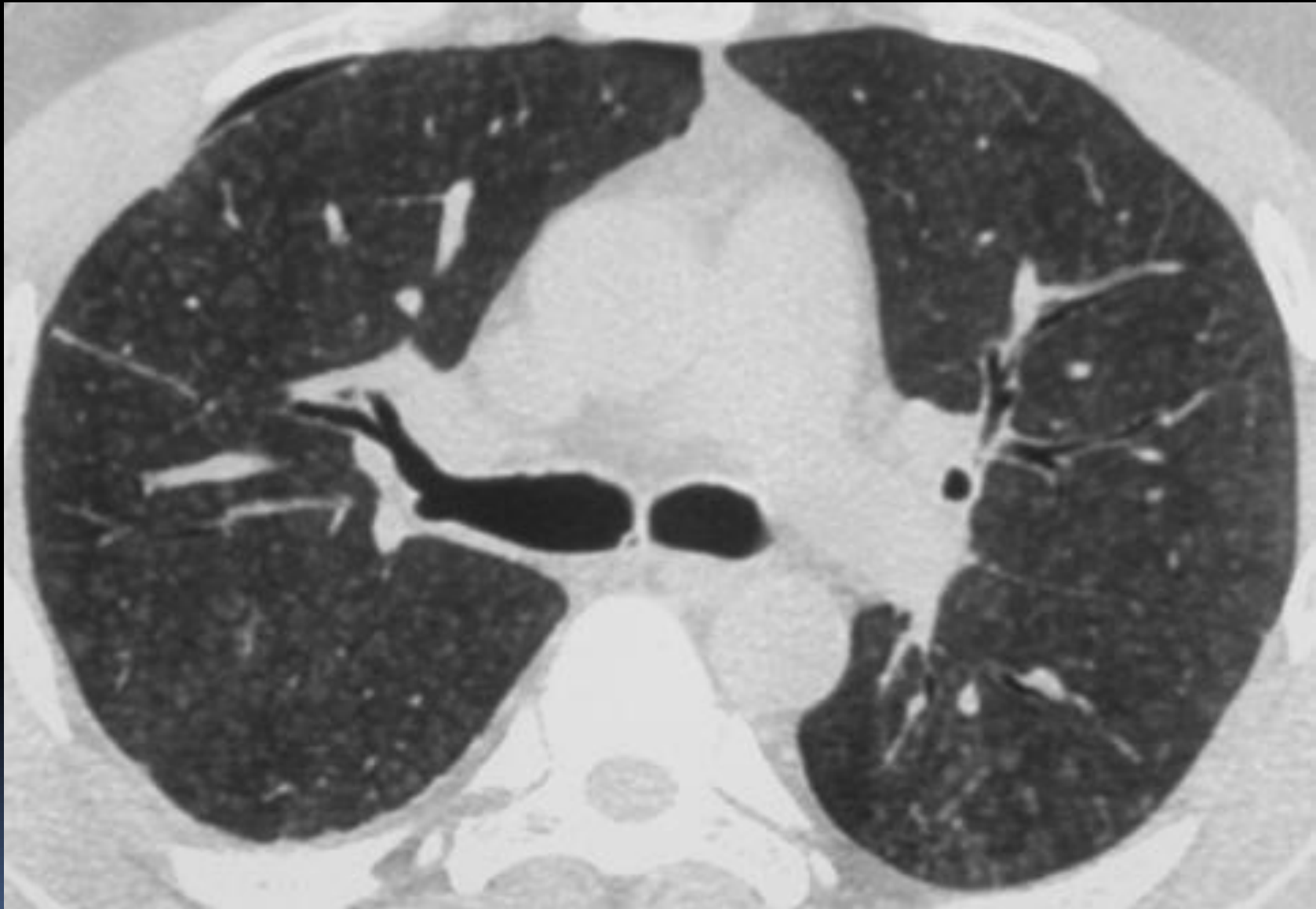


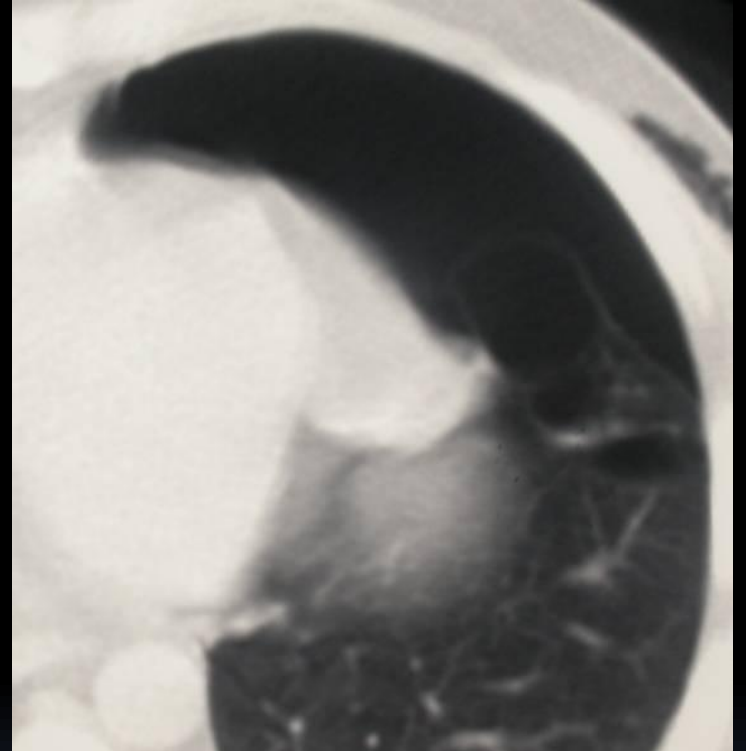
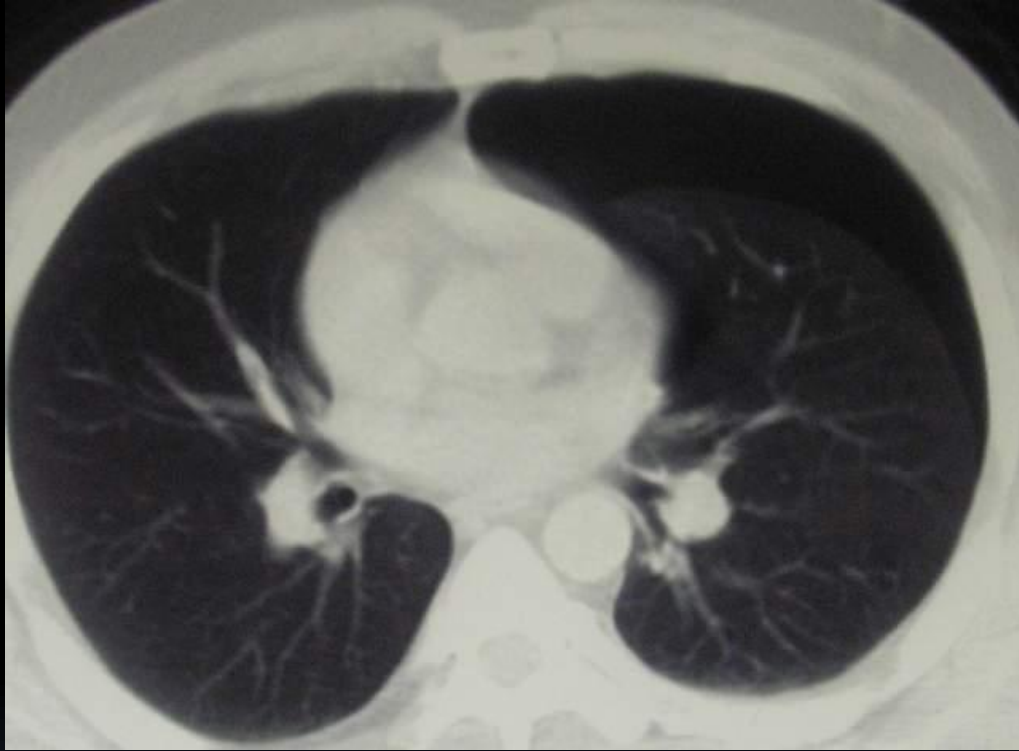
1987 ERDOGAN, 1987 W  
1987

**R**



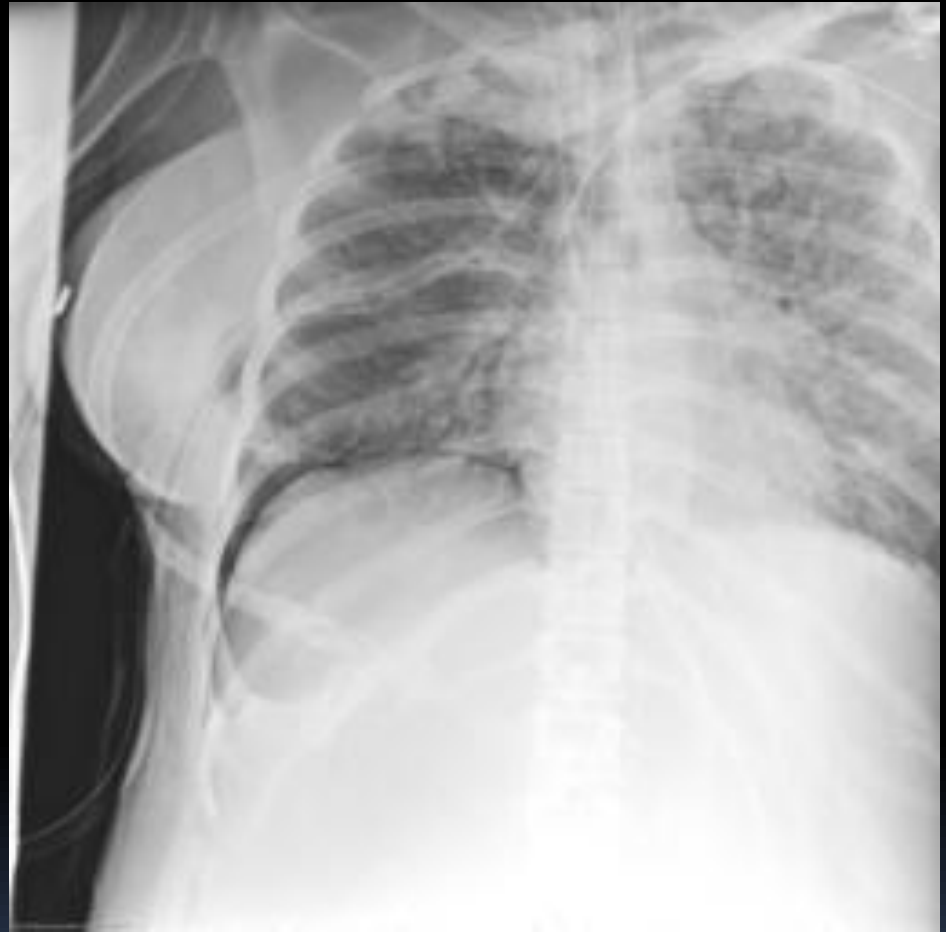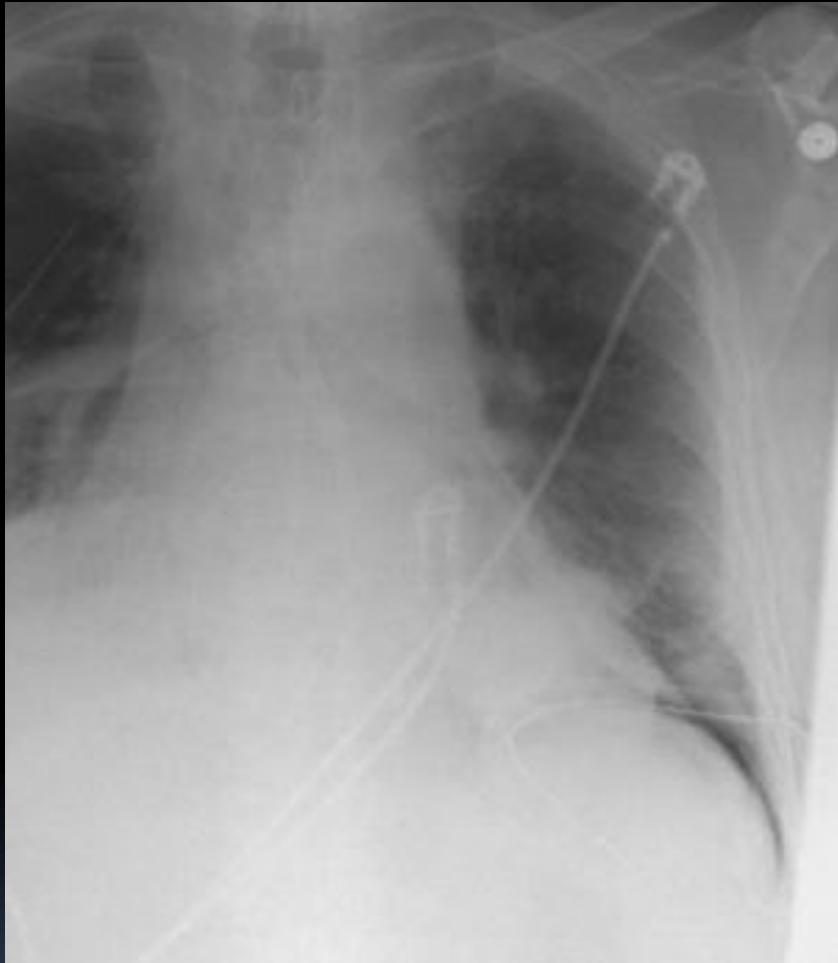


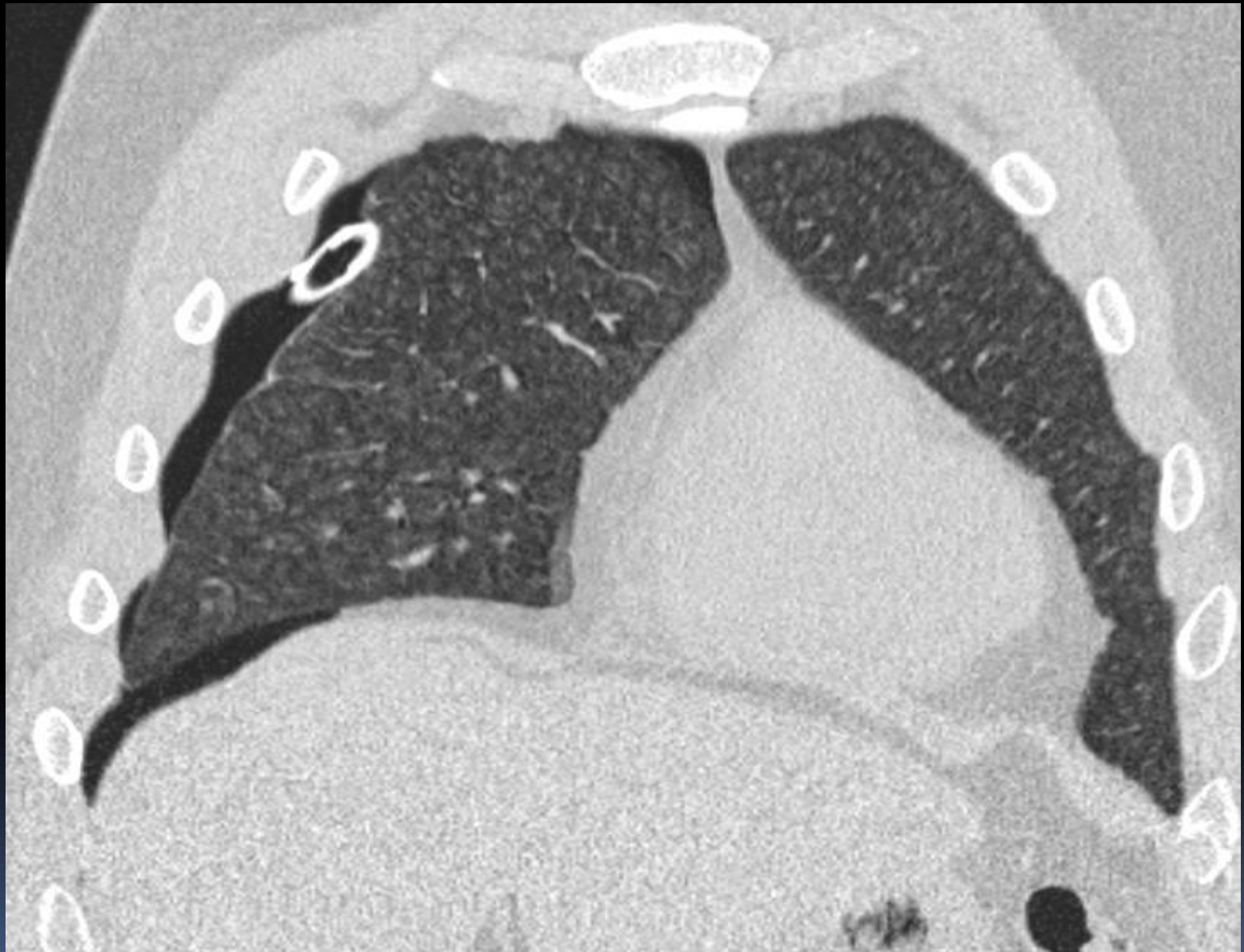


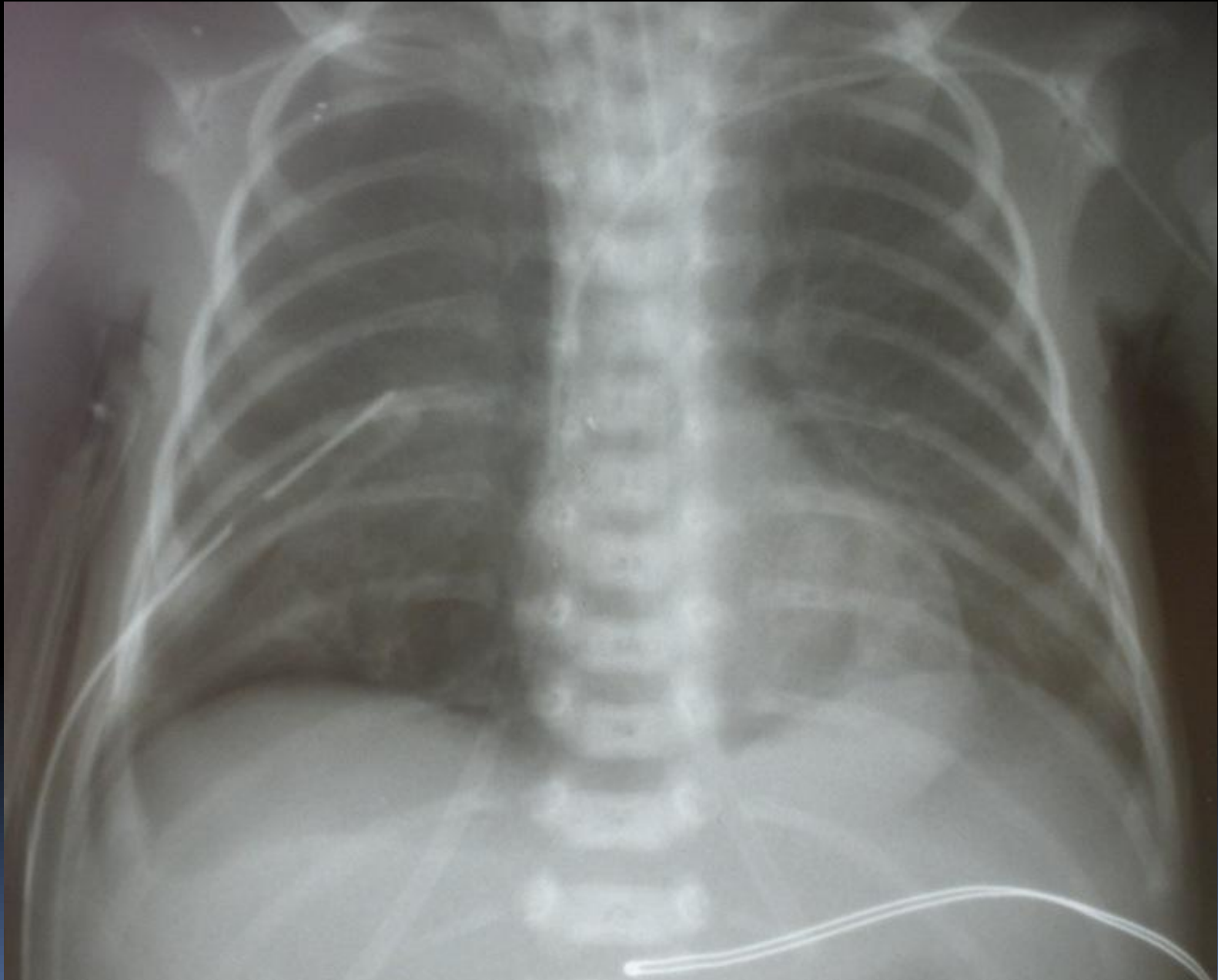


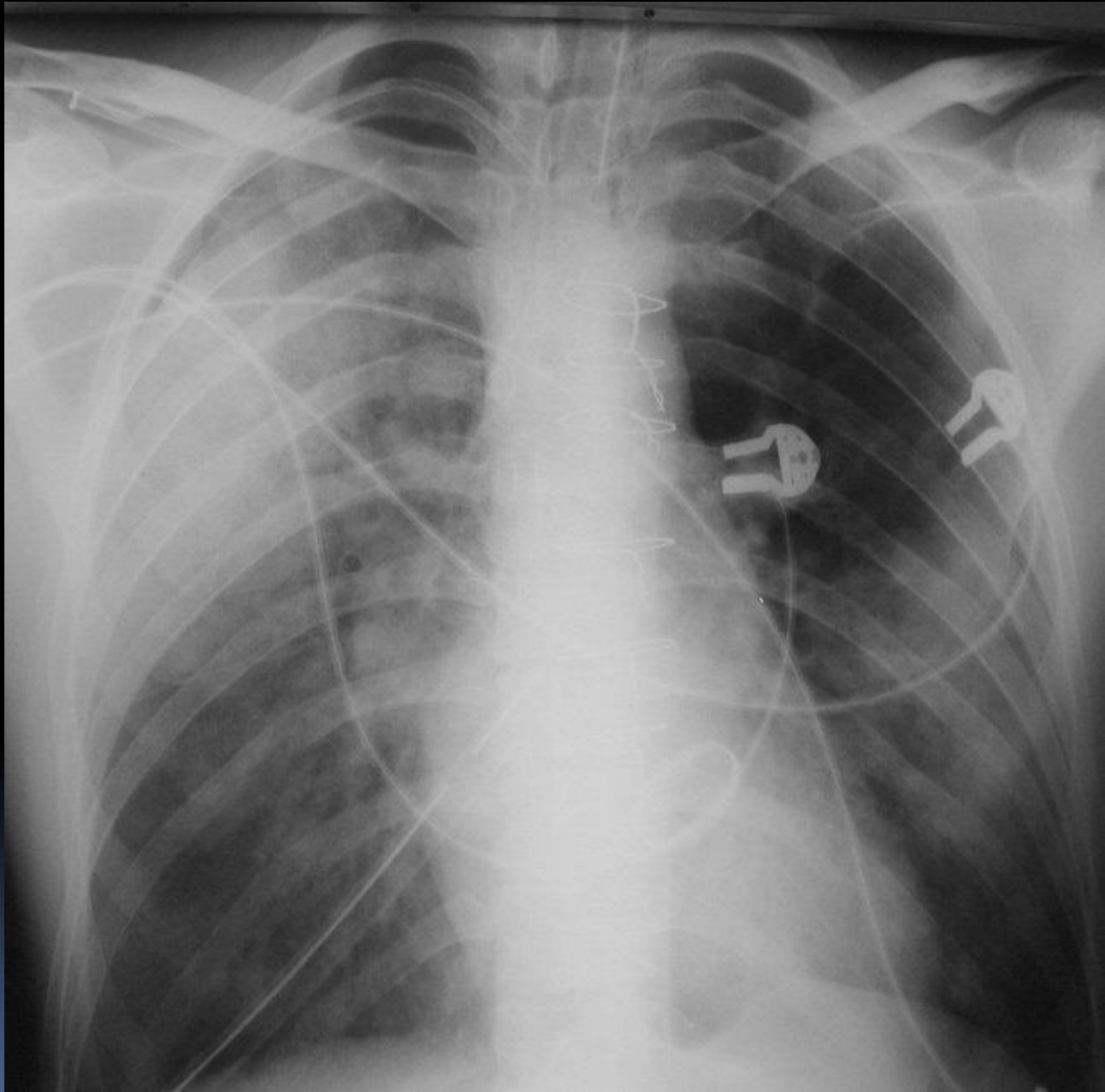


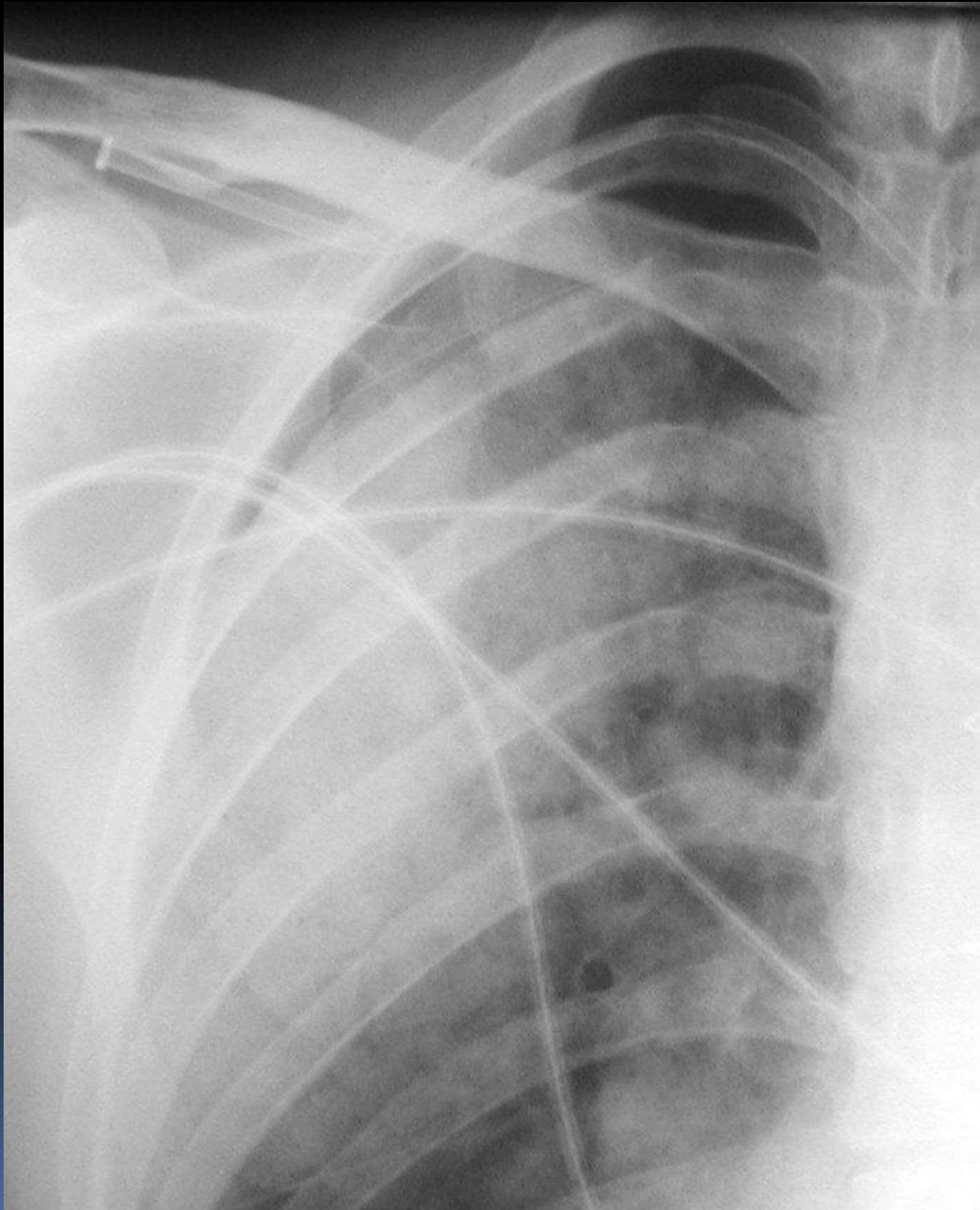


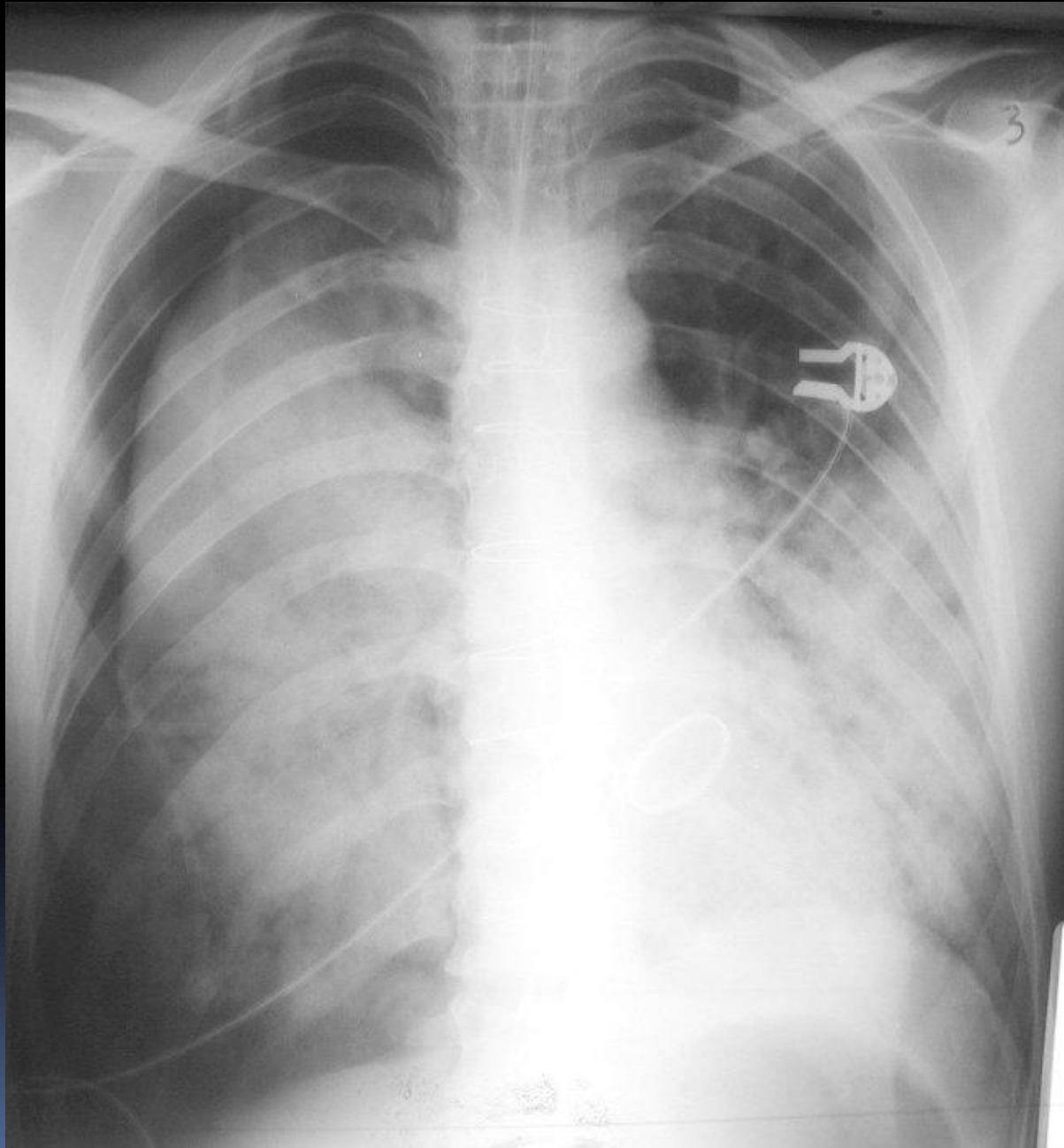


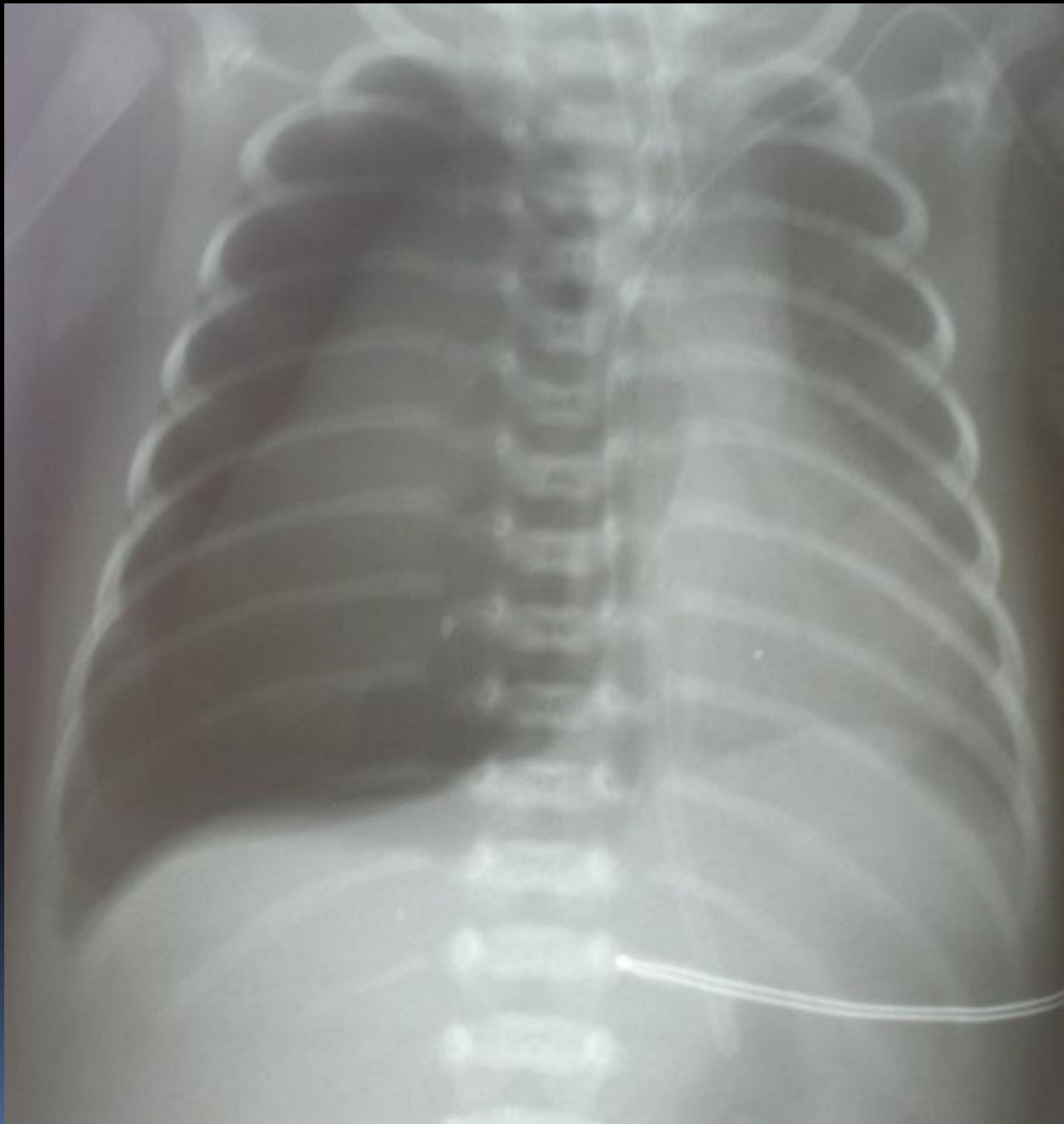






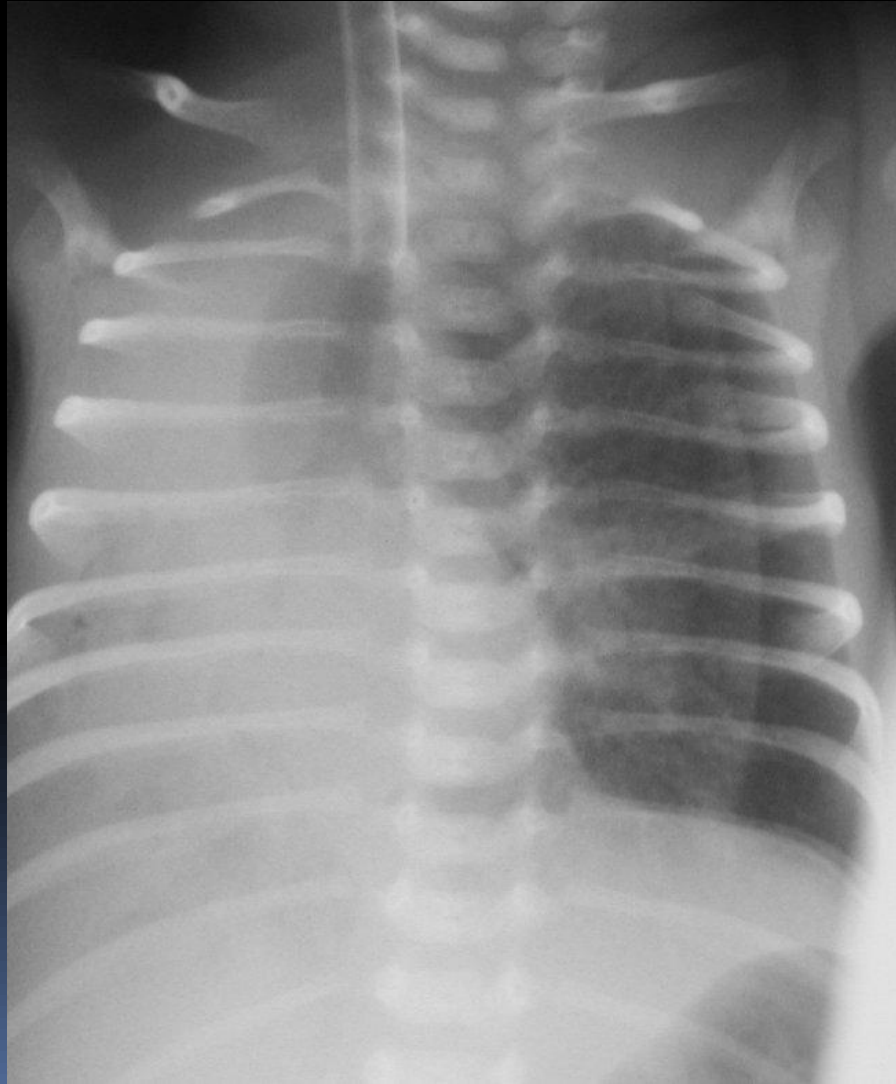




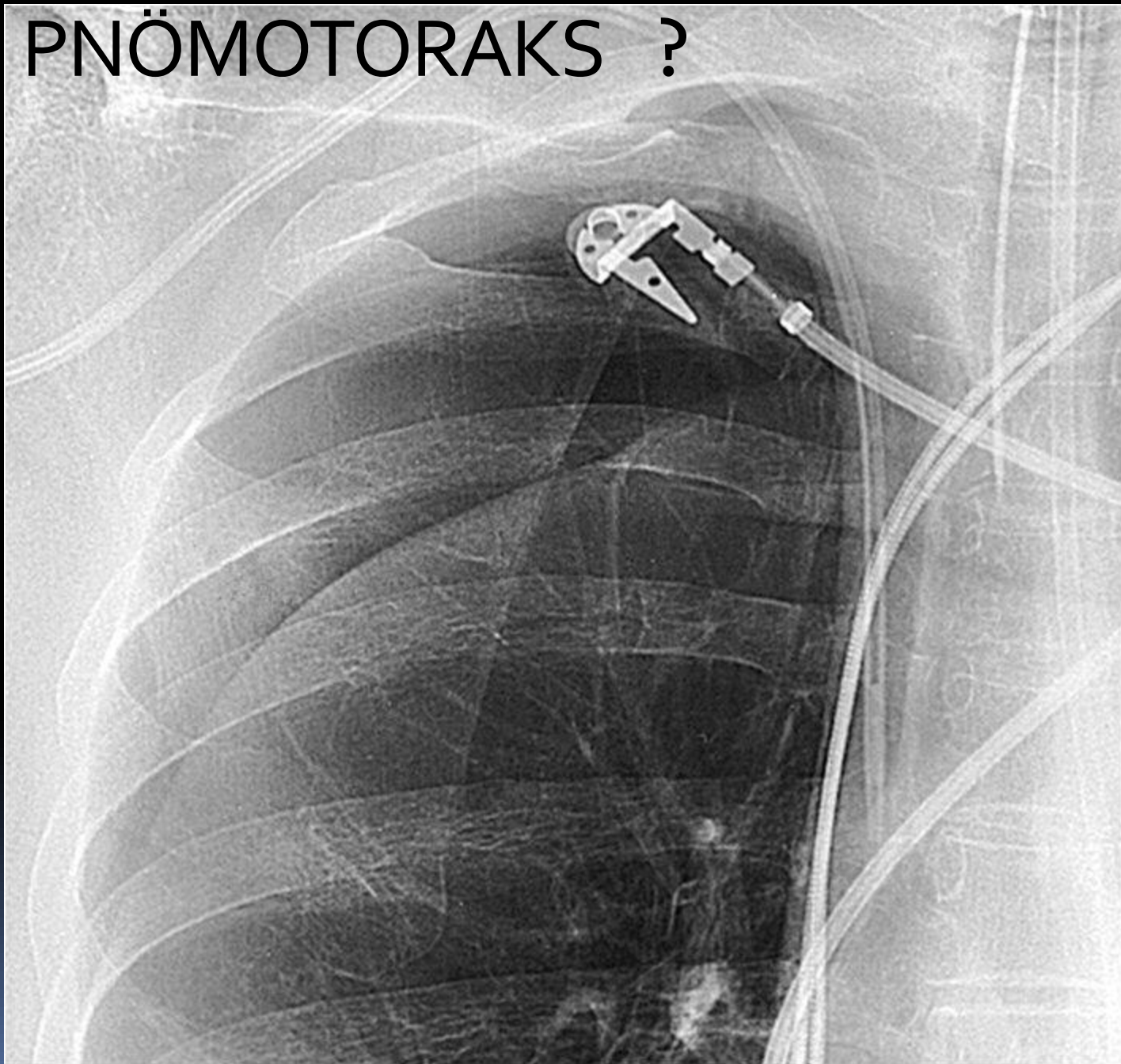




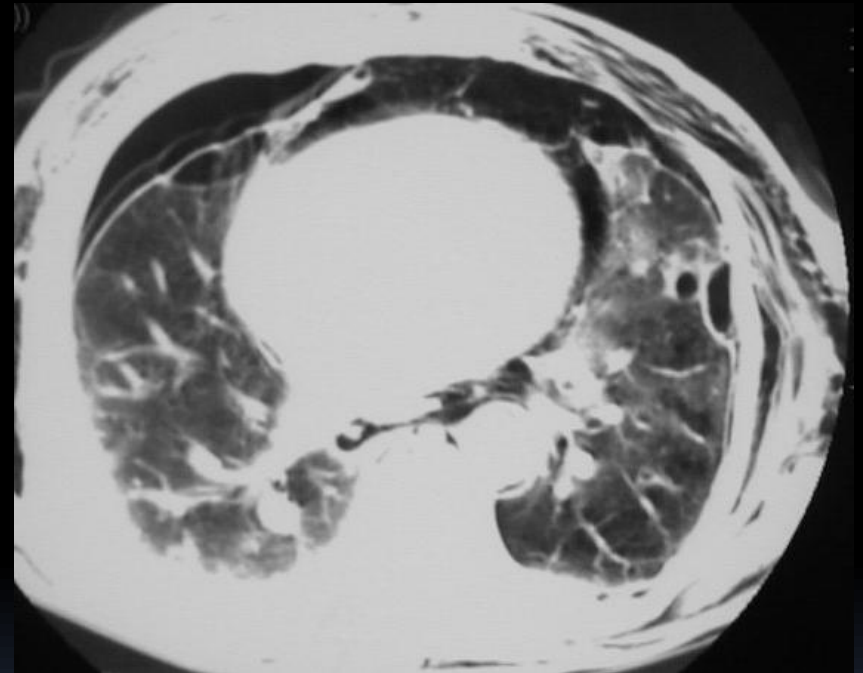
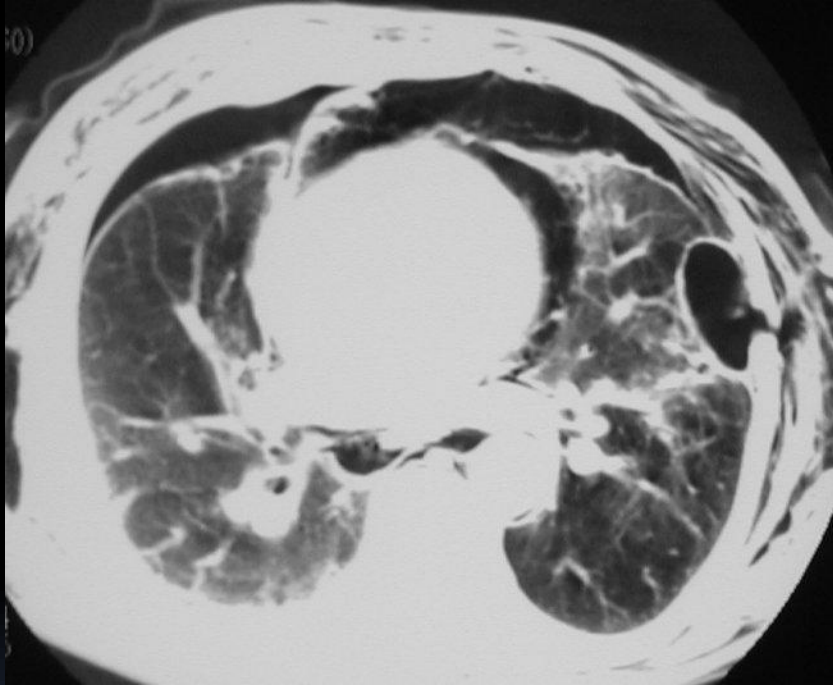
# PNÖMOTORAKS ?

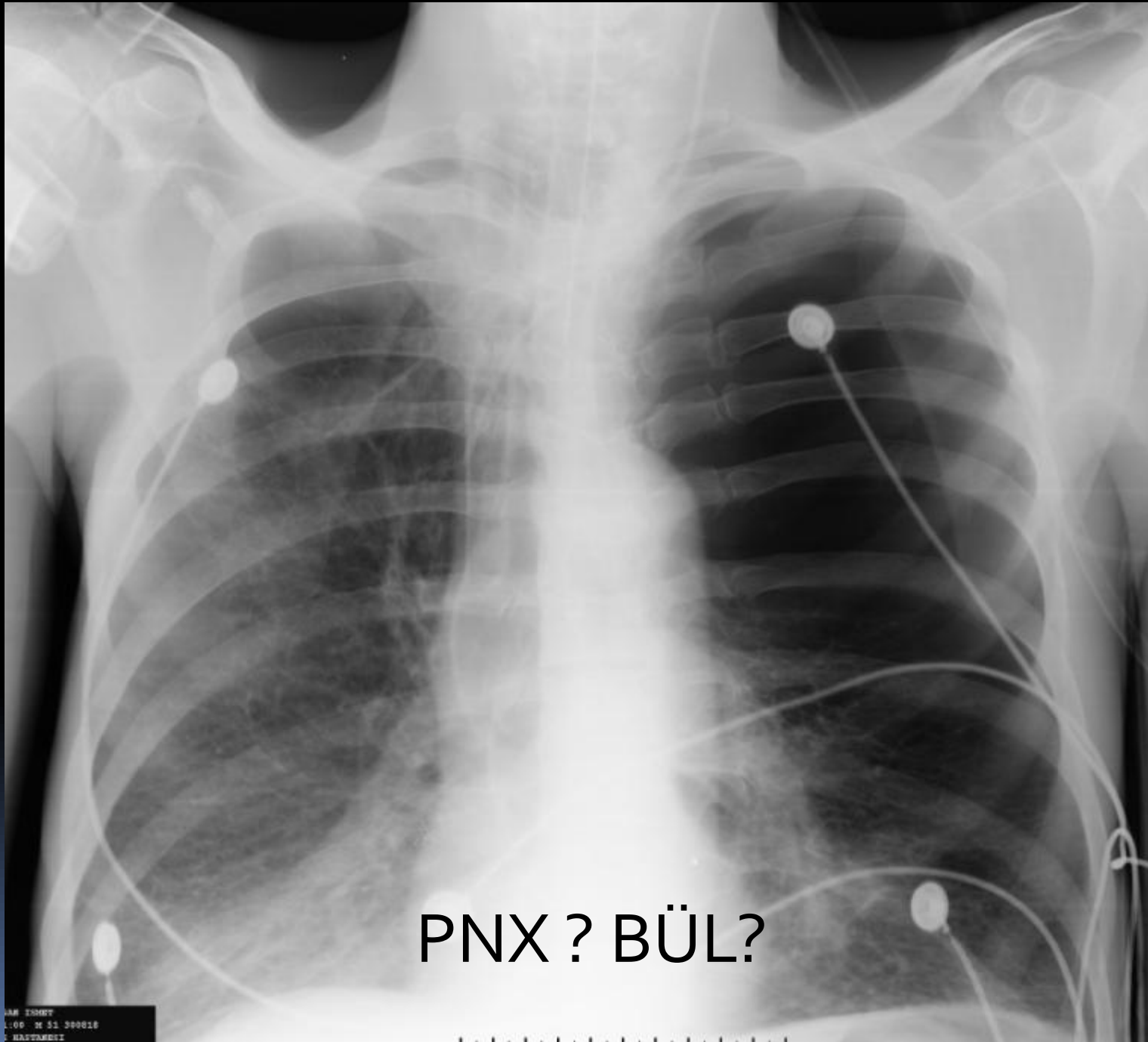


# PNÖMOTORAKS ?

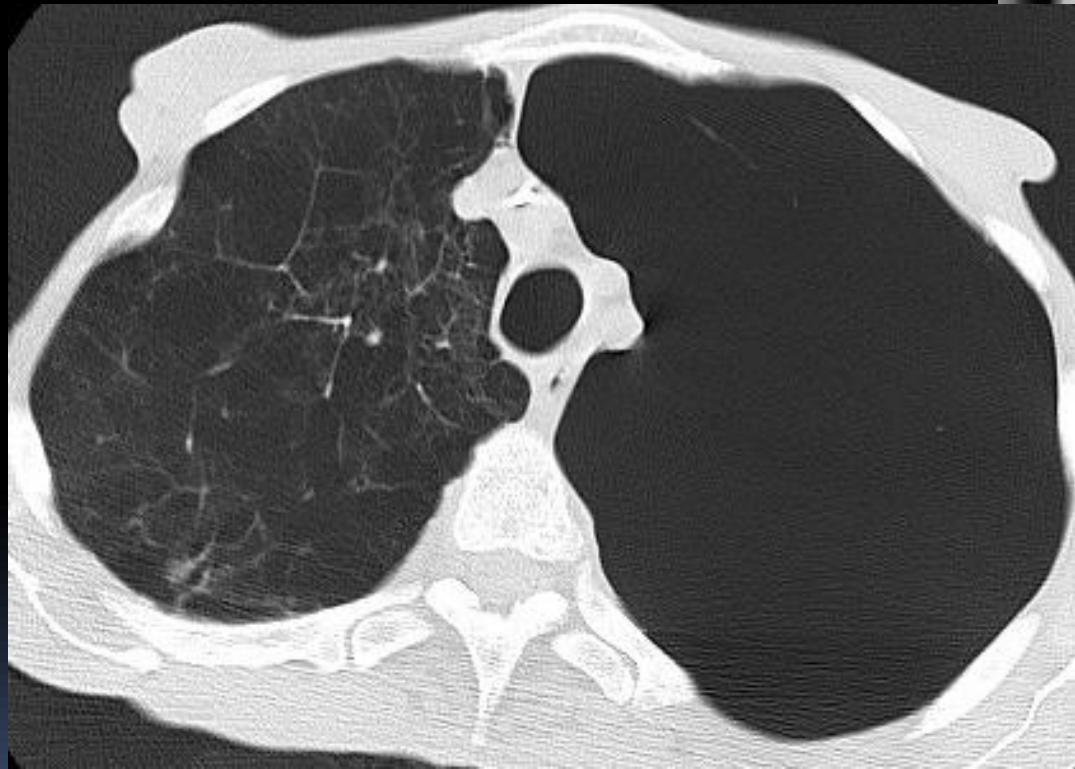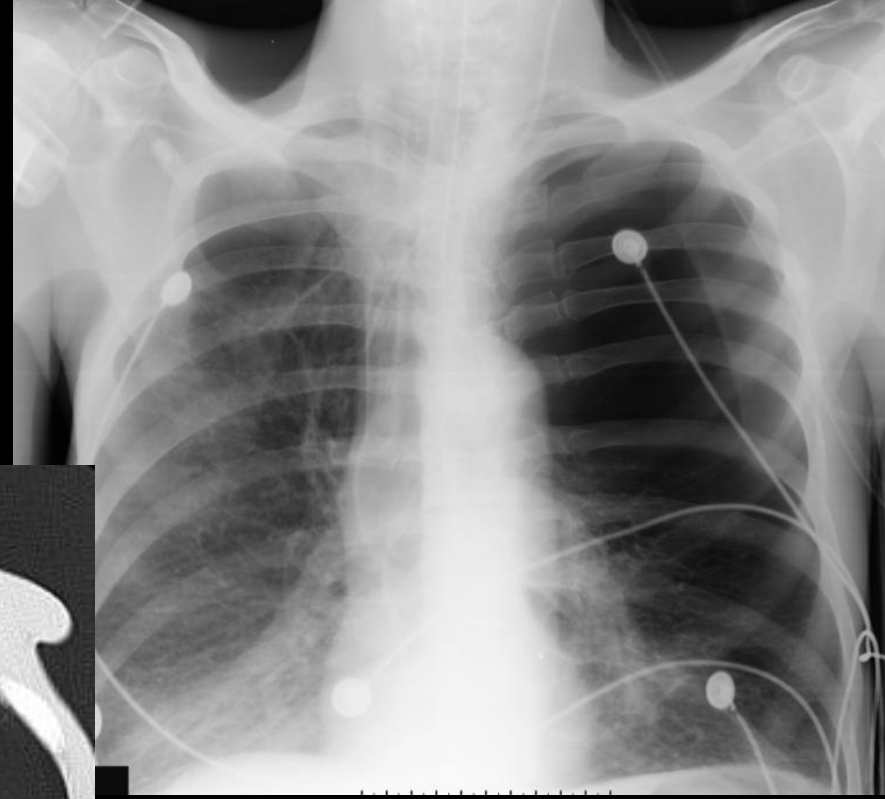


# PNÖMOTORAKS ?

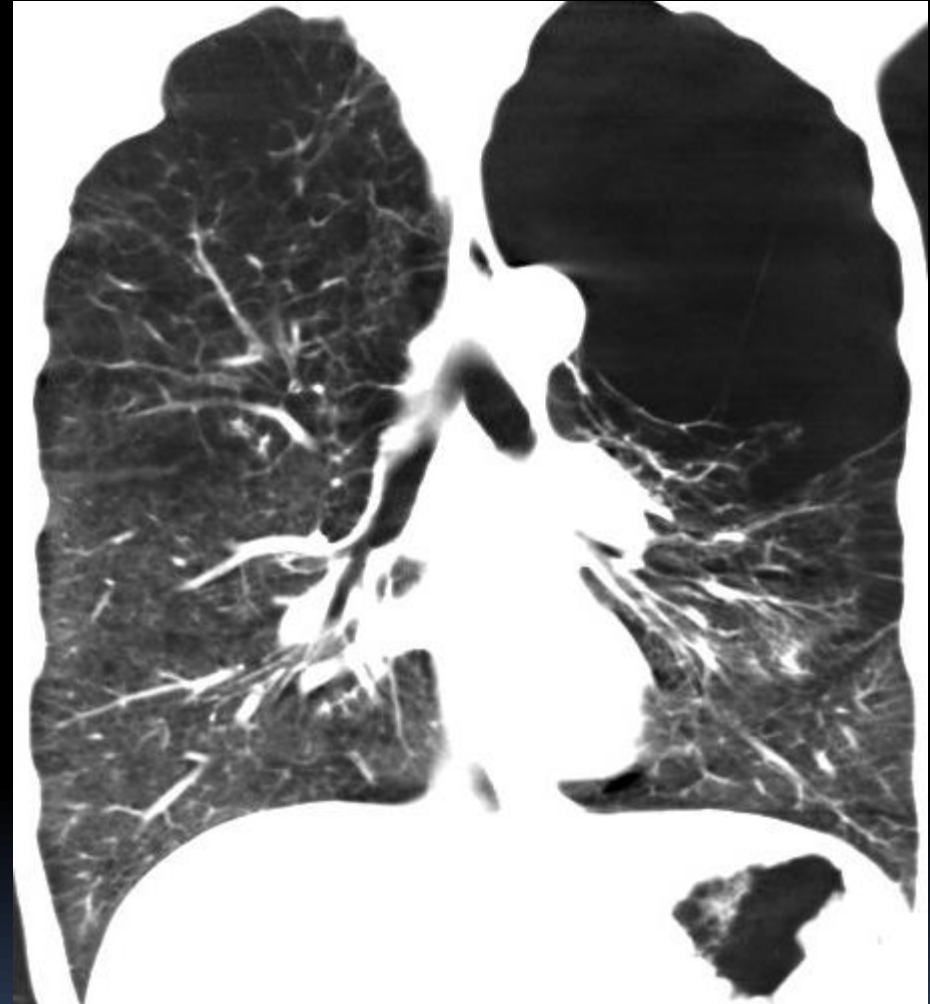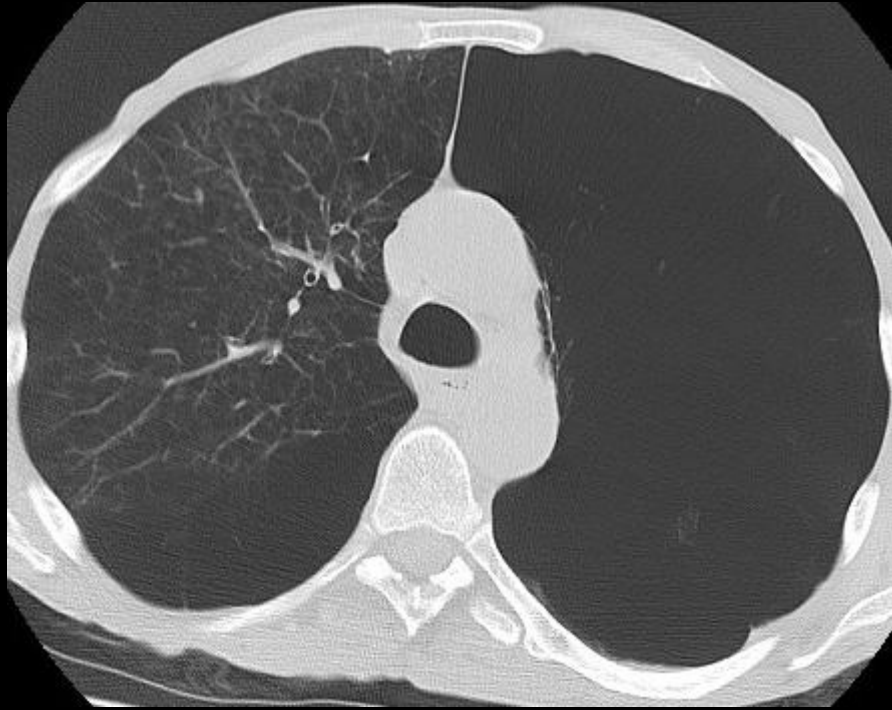




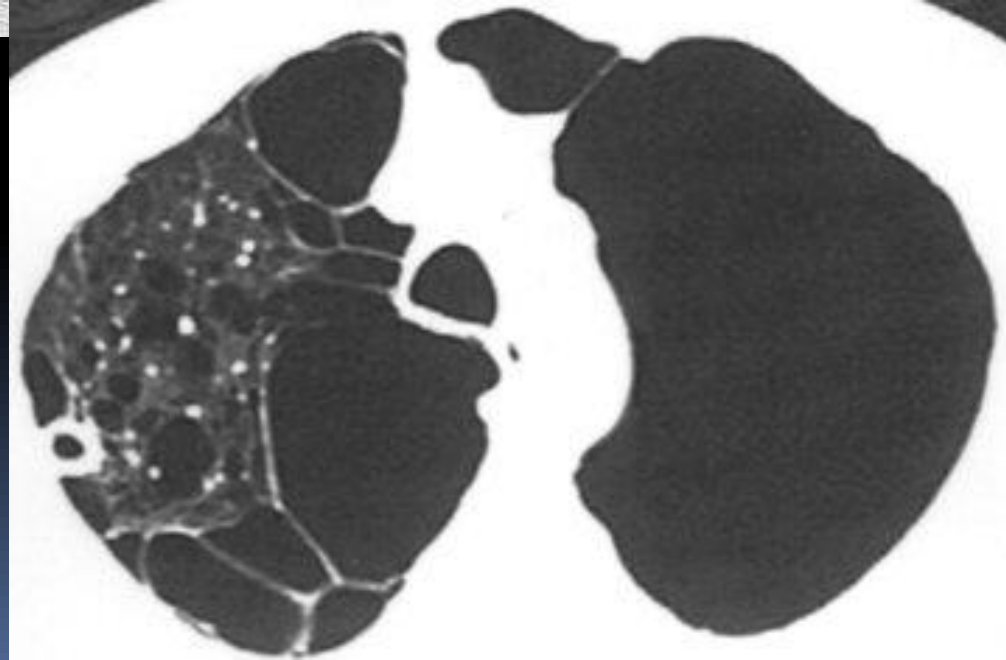
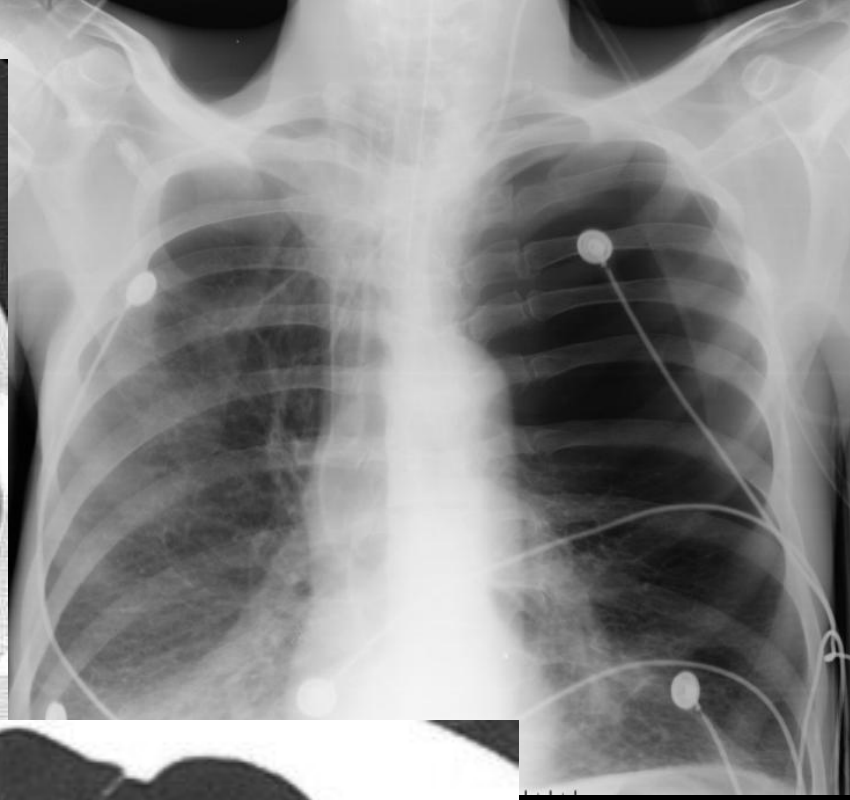
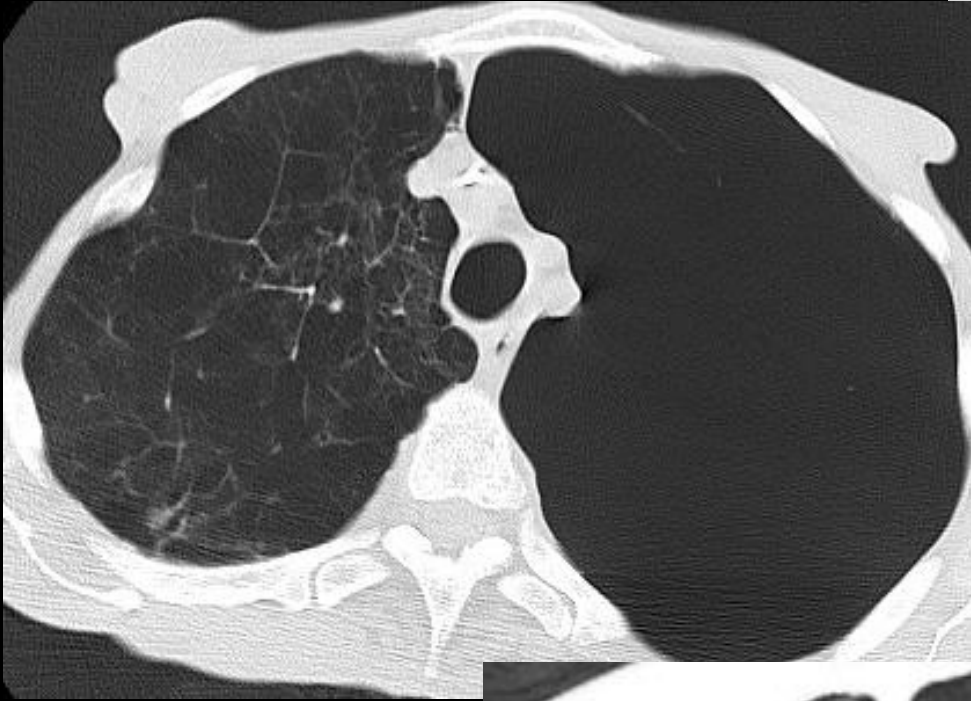PNX ? BÜL?



PNX ? BÜL?

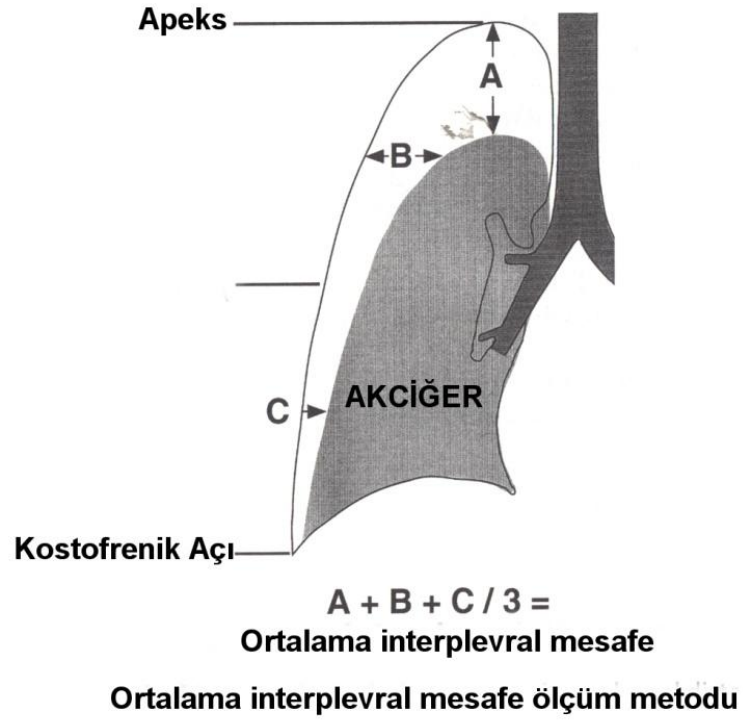


PNX ? BÜL?



PNX ? BÜL ?


ÇİFT DUVAR  
İŞARETİ



Ortalama interplevral boşluk (mm)	Pnömotoraks yüzdesi	
	Ayakta film	Yatarak film
10	%14	%19
20	%23	%29
30	%32	%39
40	%40	%49
50	%49	%59



# TEŐEKKÜRLER



**Türk Toraks Radyolojisi Derneđi**