

Temel YÇBT Paternleri 1

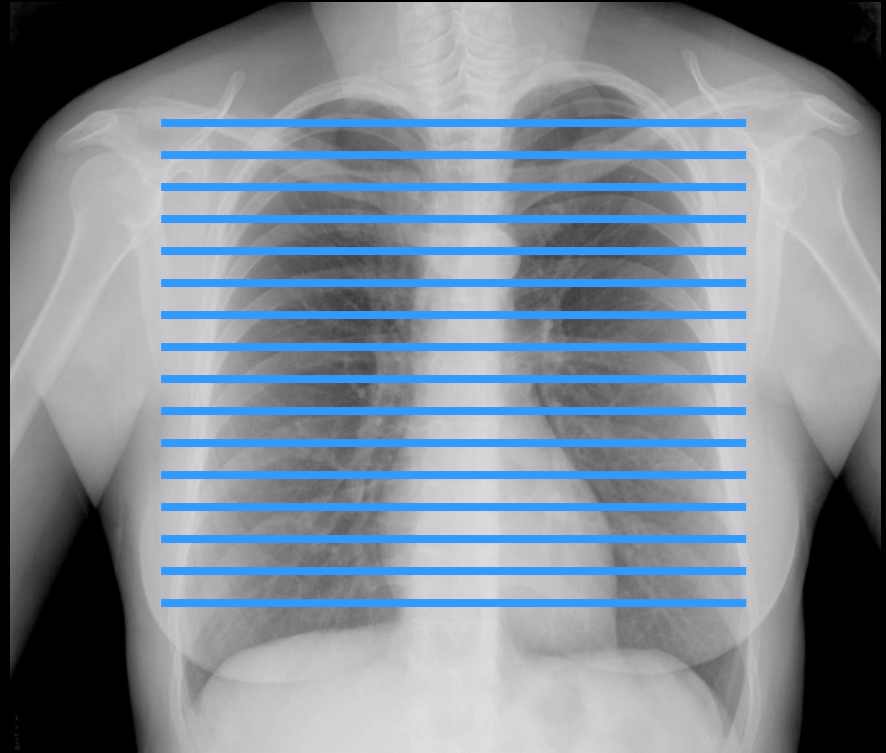
Dr. Figen Başaran Demirkazık
Hacettepe Üniversitesi Radyoloji AD

İnterstisyel AC Hastalığında YÇBT

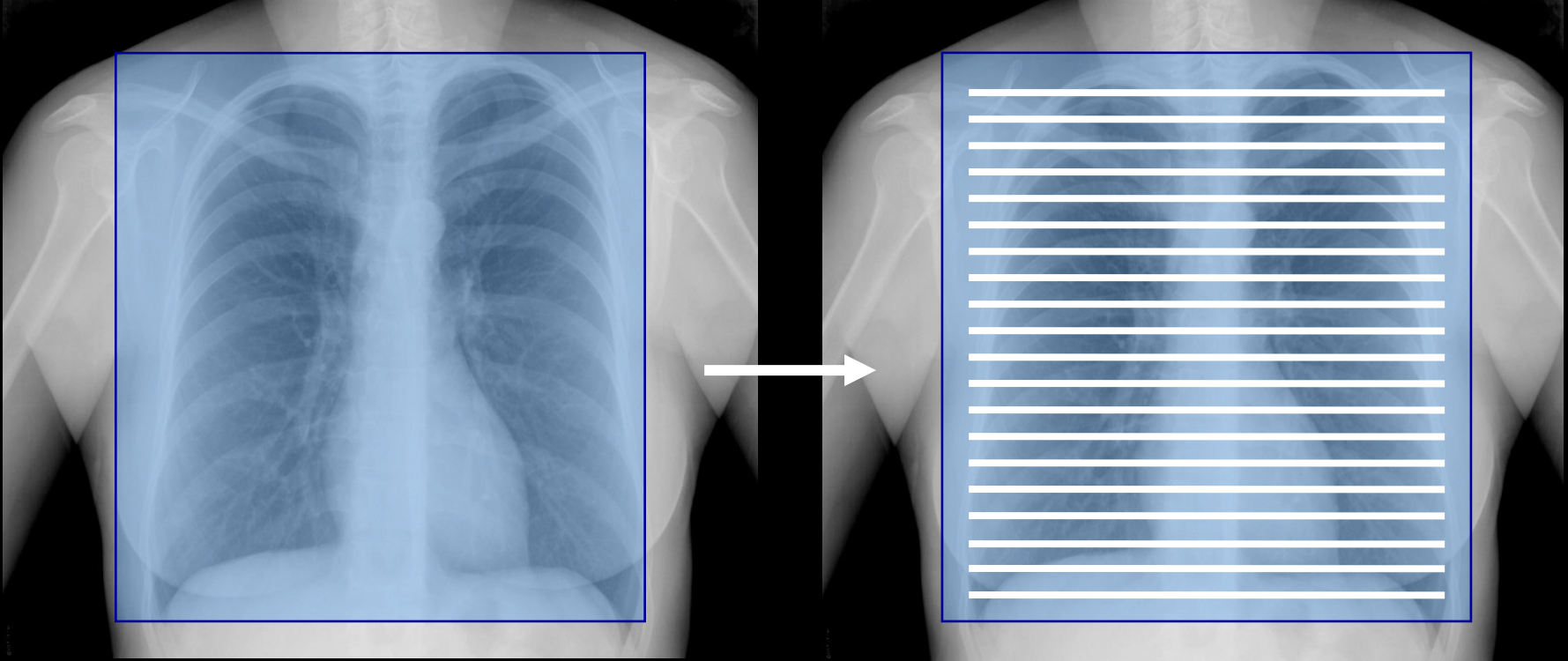
- Tanı- ayırıcı tanıda
 - Hastalık aktivitesinin tahmininde
 - Biyopsi yerinin ve yönteminin belirlenmesinde
 - Tedaviye yanıtın izleminde
-

Yüksek Çözünürlüklü BT

- Her 10 mm'de bir 1- 1.5 mm kalınlığında aralıklı kesitler
- Yüksek kVp (140)
- Parenkim değerlendirilir
- Kontrastsız yapılır
- Reformat yapılamaz
- 1-2 mSv

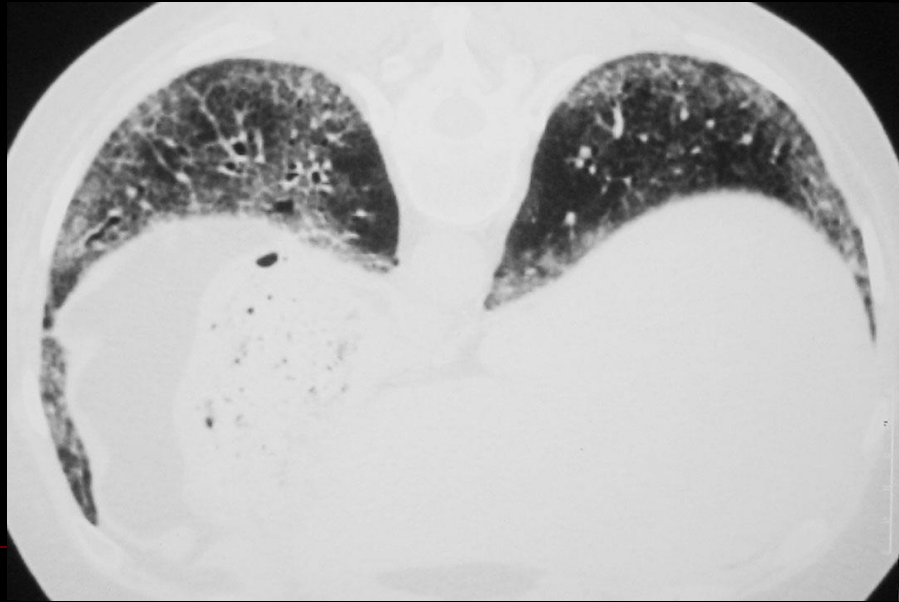
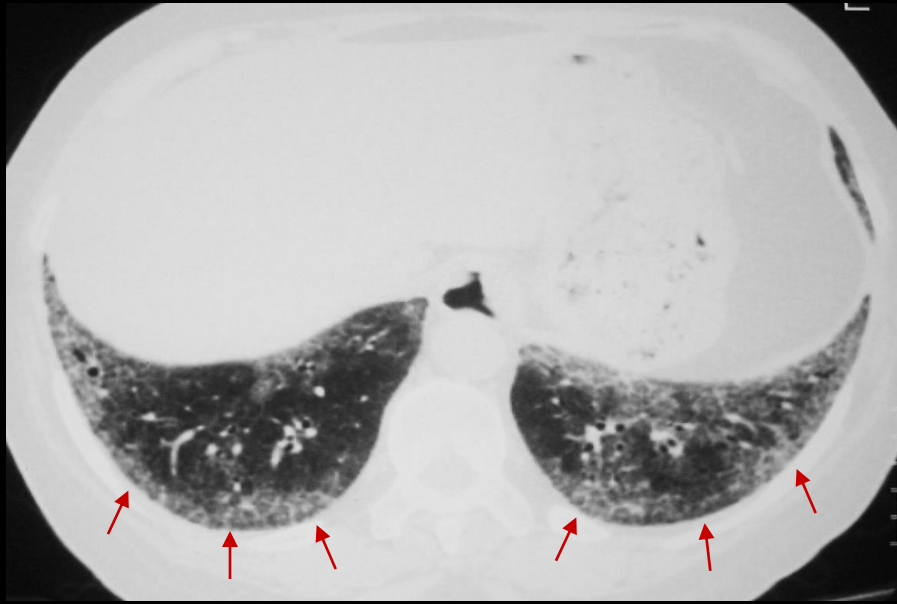


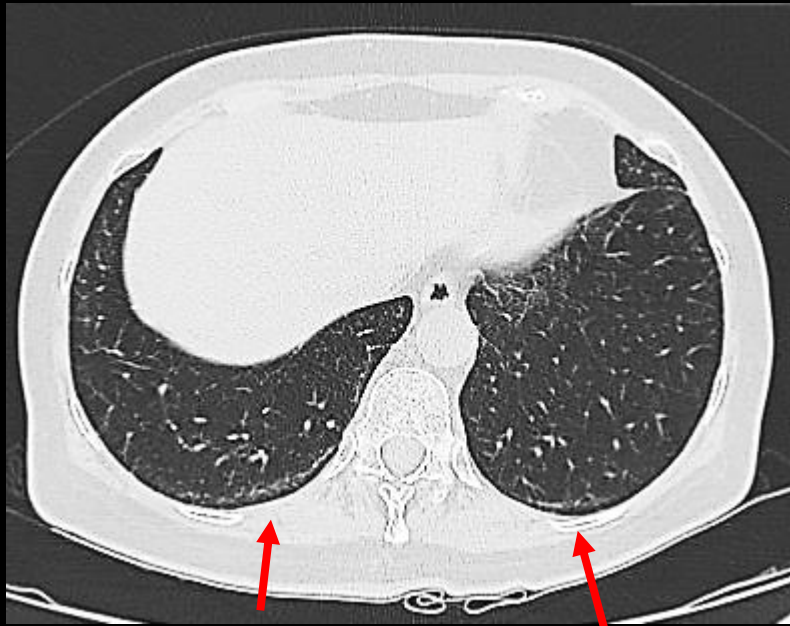
Çok Kesitli Spiral BT



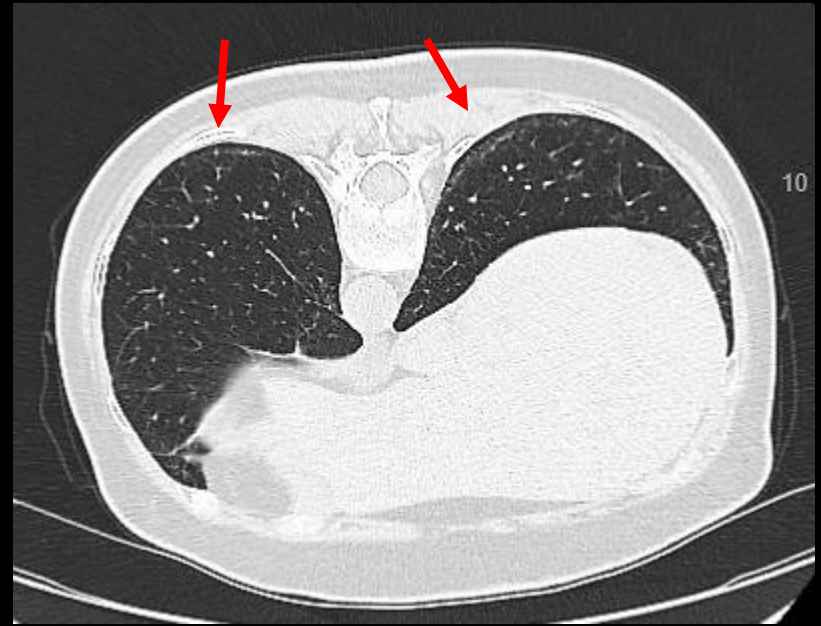Tek nefes tutmada
“hacimsel tarama”

İstenilen kesit kalınlığı
sonra seçilir.
İnce kesitler kullanılarak
reformat yapılabilir





Supin



Pron

Sekonder
pulmoner
lobül

Sentrilobüler
interstisiyum

Periferik
interstisiyum

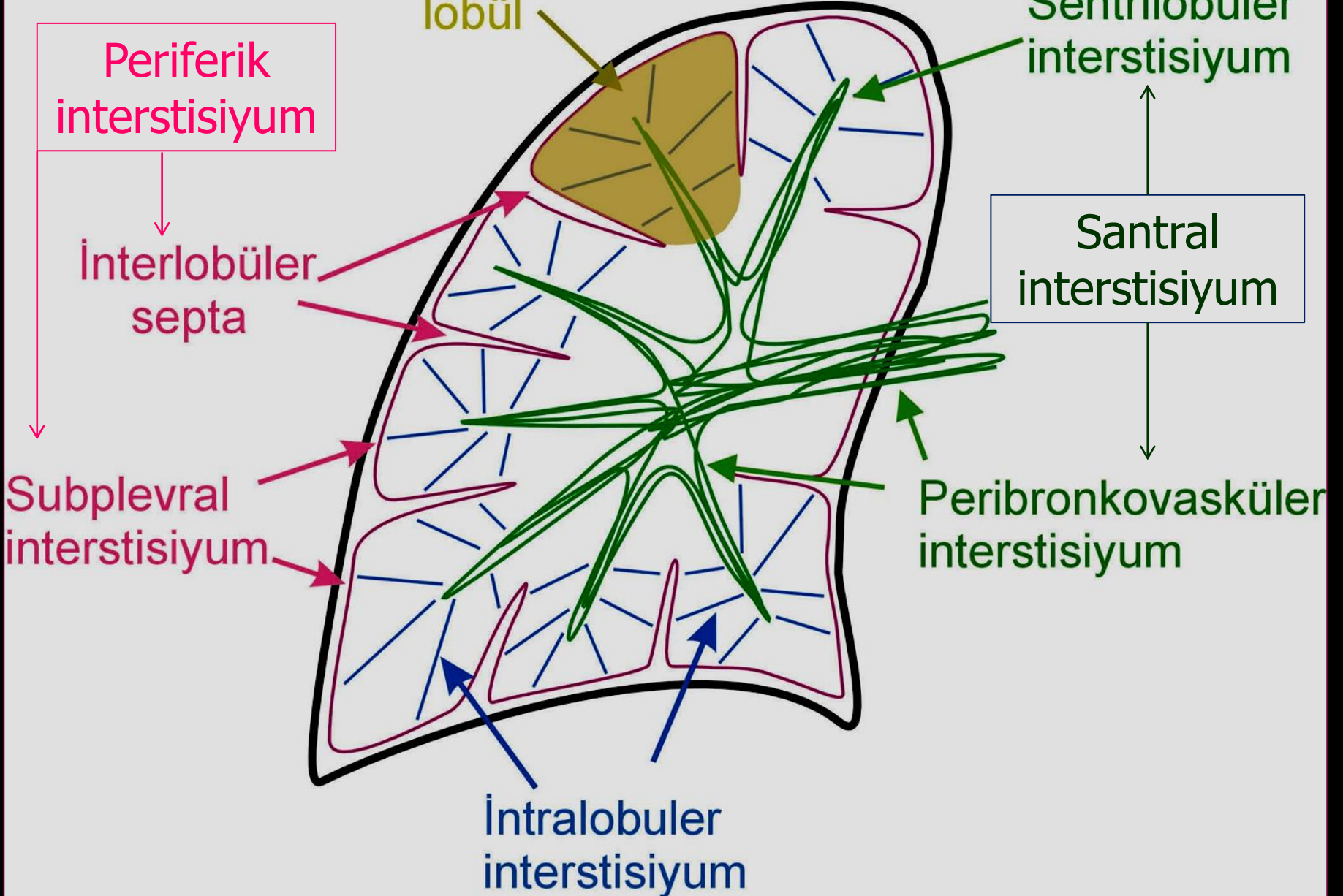
Santral
interstisiyum

İnterlobüler
septa

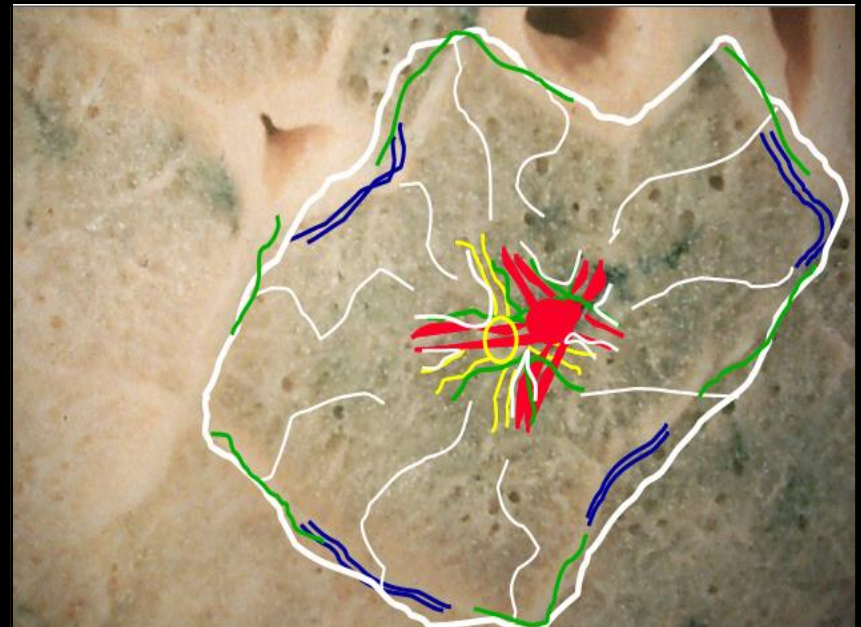
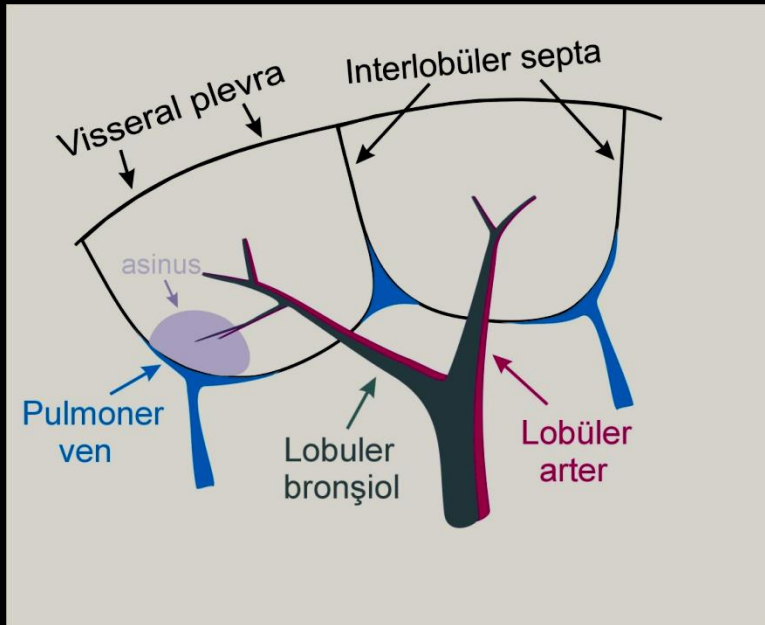
Peribronkovasküler
interstisiyum

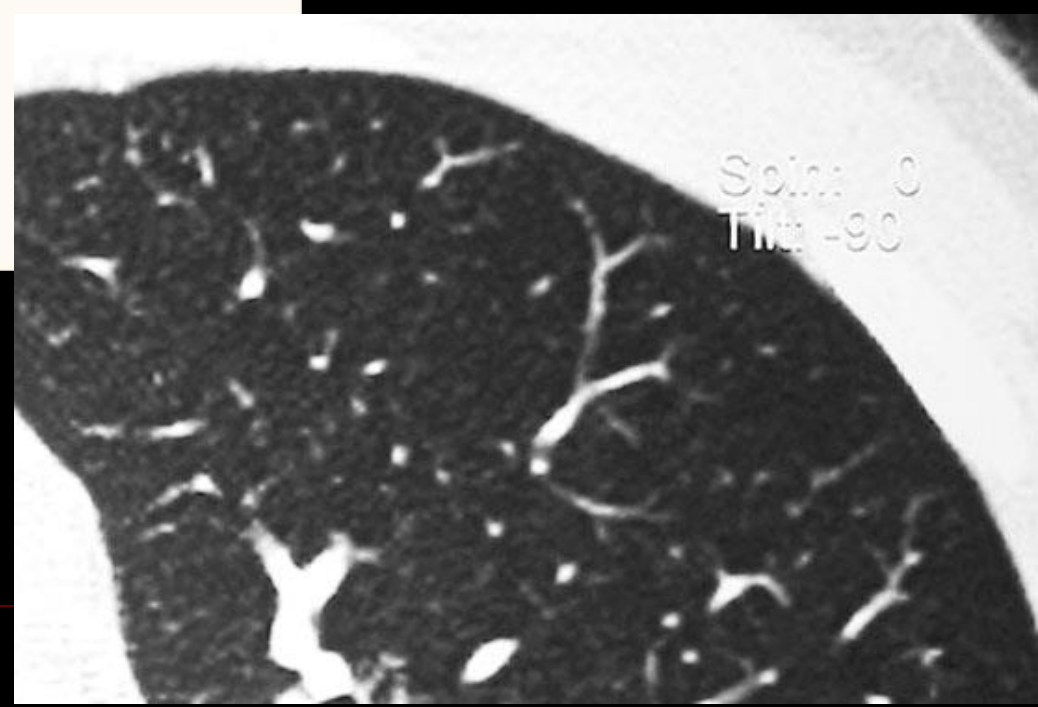
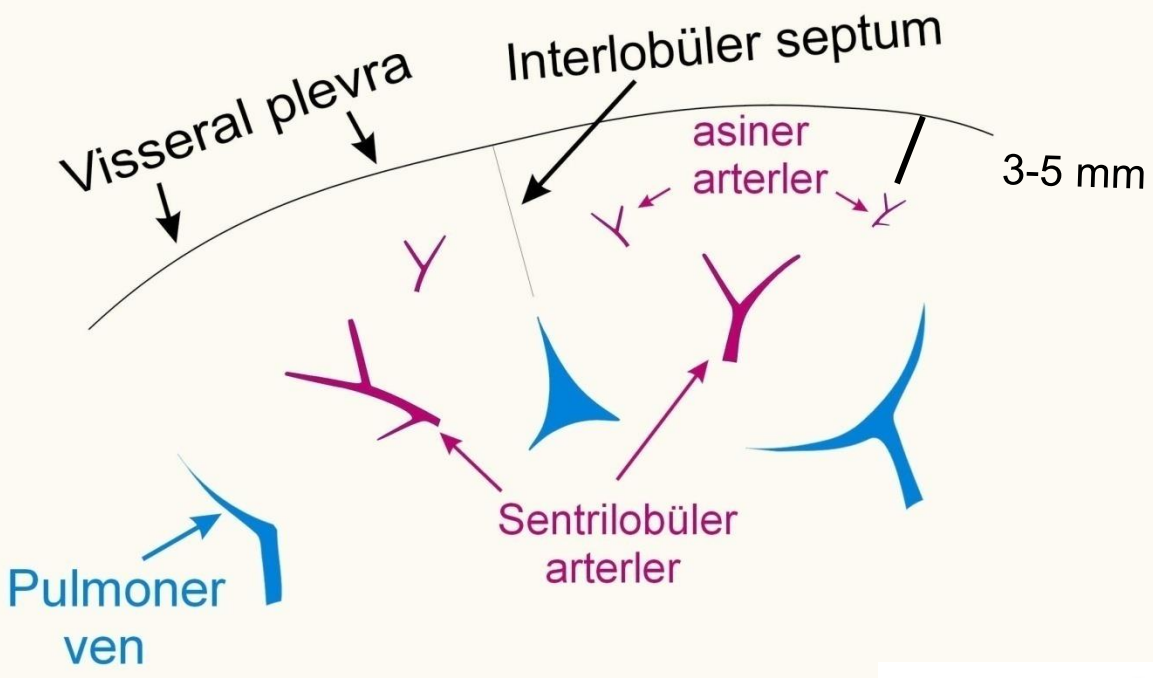
Subplevral
interstisiyum

İntralobuler
interstisiyum



Sekonder pulmoner lobül





Klinik-
laboratuvar

YÇBT
bulguları

Dağılım
paterni

YÇBT yorumu

```
graph TD; A[Klinik-laboratuvar] --> D[YÇBT yorumu]; B[YÇBT bulguları] --> D; C[Dağılım paterni] --> D;
```

YBÇT'de İnterstisyel Hastalık Bulguları

- Çizgisel (Retiküler) Dansiteler
 - Akciğer Dansitesinde Azalma: Kistler
 - Nodüller
 - Akciğer Dansitesinde Artış: Buzlu cam
Konsolidasyon
-

Akut diffüz retikülasyonlar

1. Akut interstisyel ödem

konjestif kalp yetmezliği

sıvı yüklenmesi

üremi

2. Akut interstisyel pnömoni

viral

mikoplazma

PJP

Kronik diffüz retikülasyonlar

A. Venöz obstrüksiyon

mitral darlığı, sol atrial miksoma,
pulmoner venooklusif hastalık
sklerozan mediastinit

B. Lenfatik obstrüksiyon

lenfoma/ lösemi
lenfanjitis karsinomatoza
lenfositik interstisyel pnömoni

Kronik diffüz retikülasyonlar

C. İnhalasyon hastalıkları

silikozis

asbestozis

ağır metaller

hipersensitivite pnömonisi (kronik)

D. Granülomatöz hastalıklar

sarkoidoz

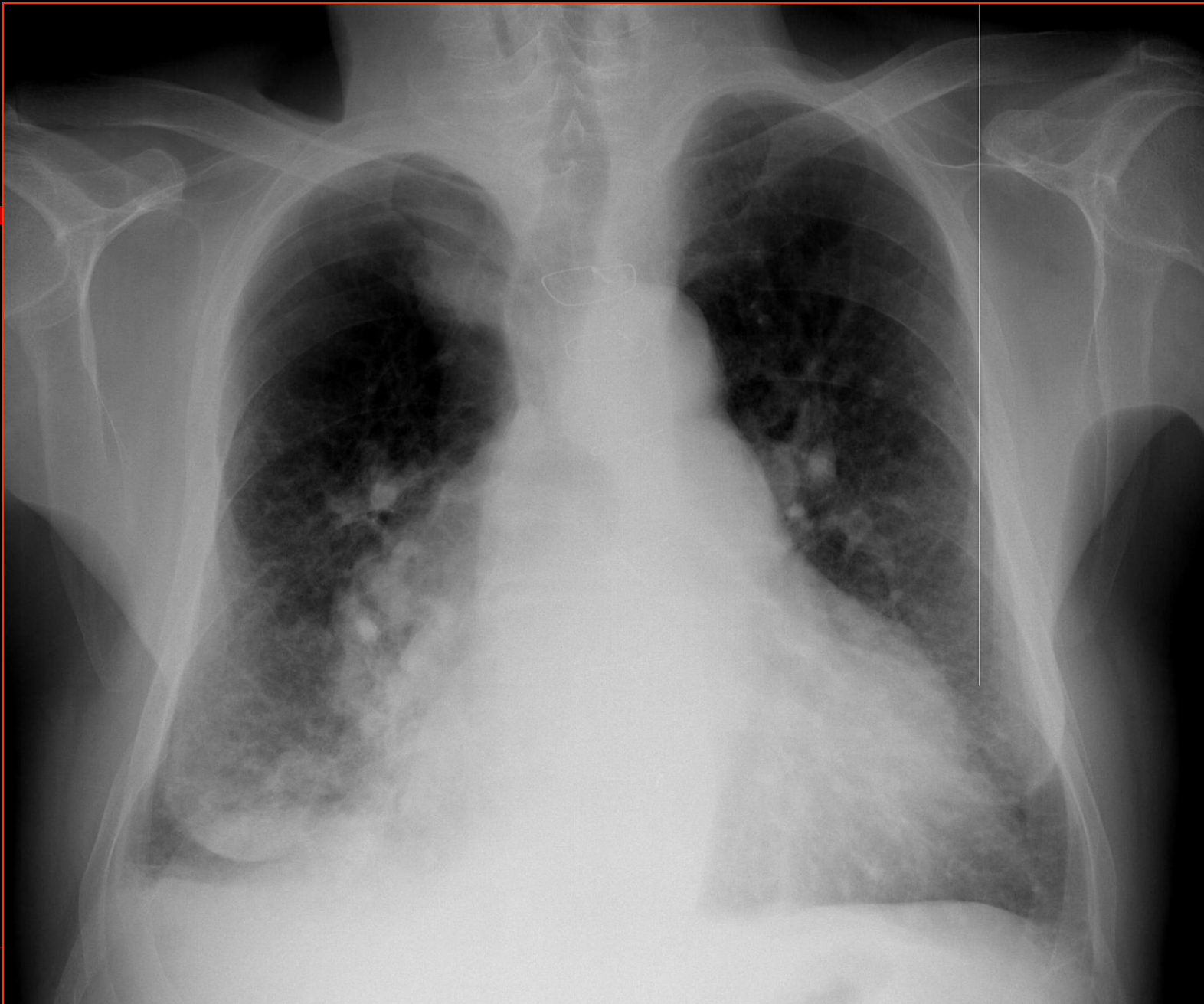langerhans h.li histiositozis

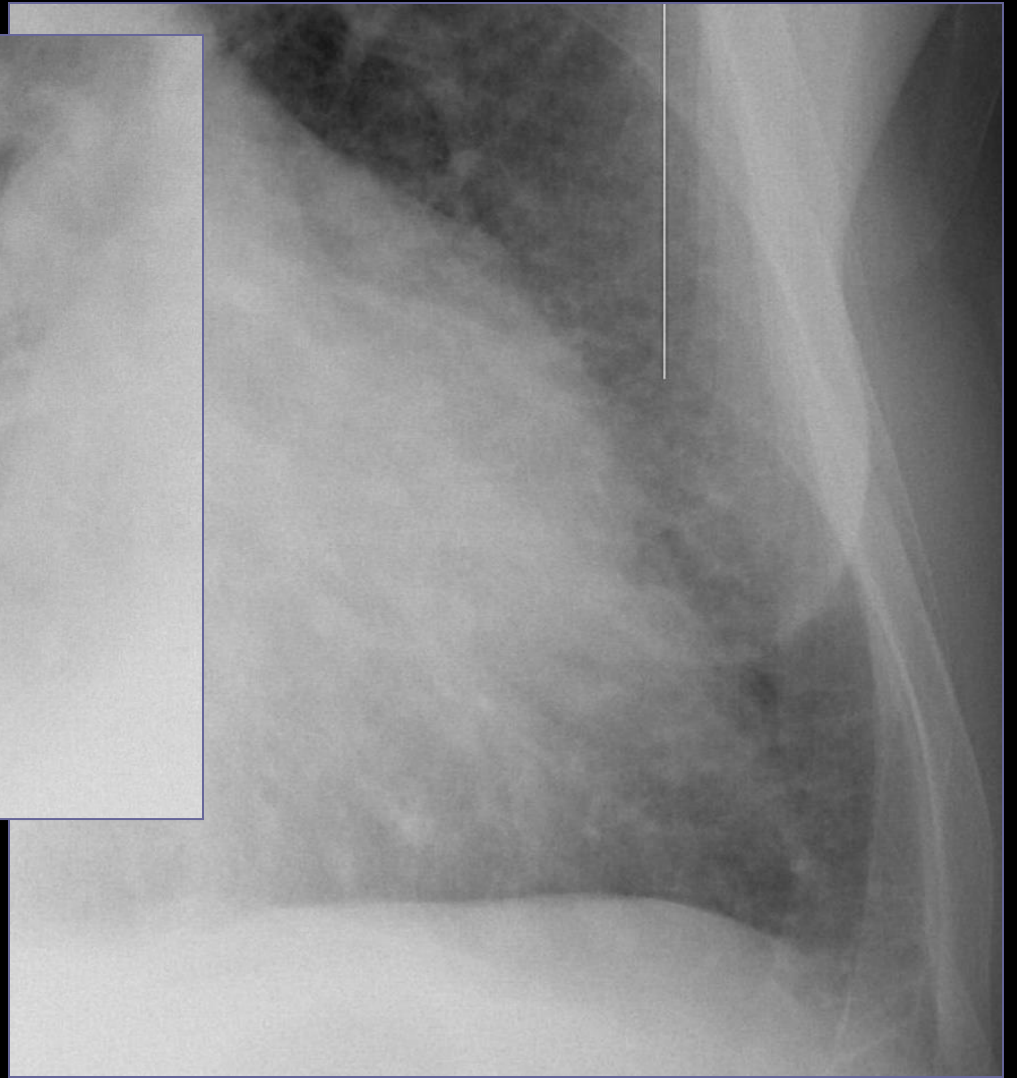
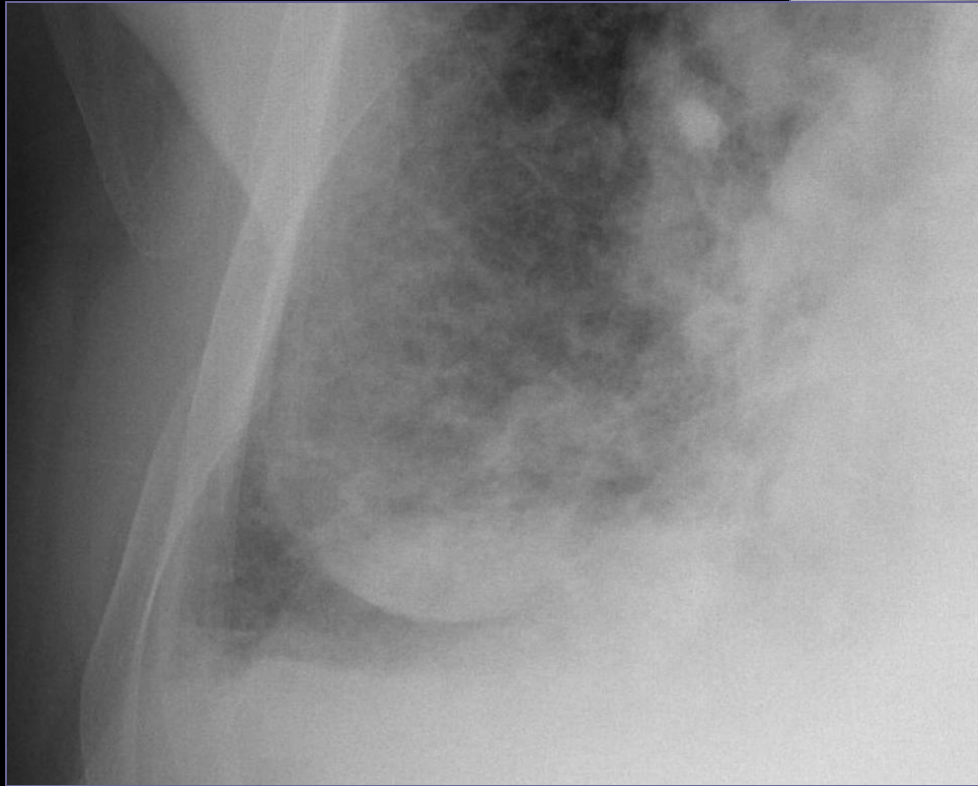
Kronik diffüz retikülasyonlar

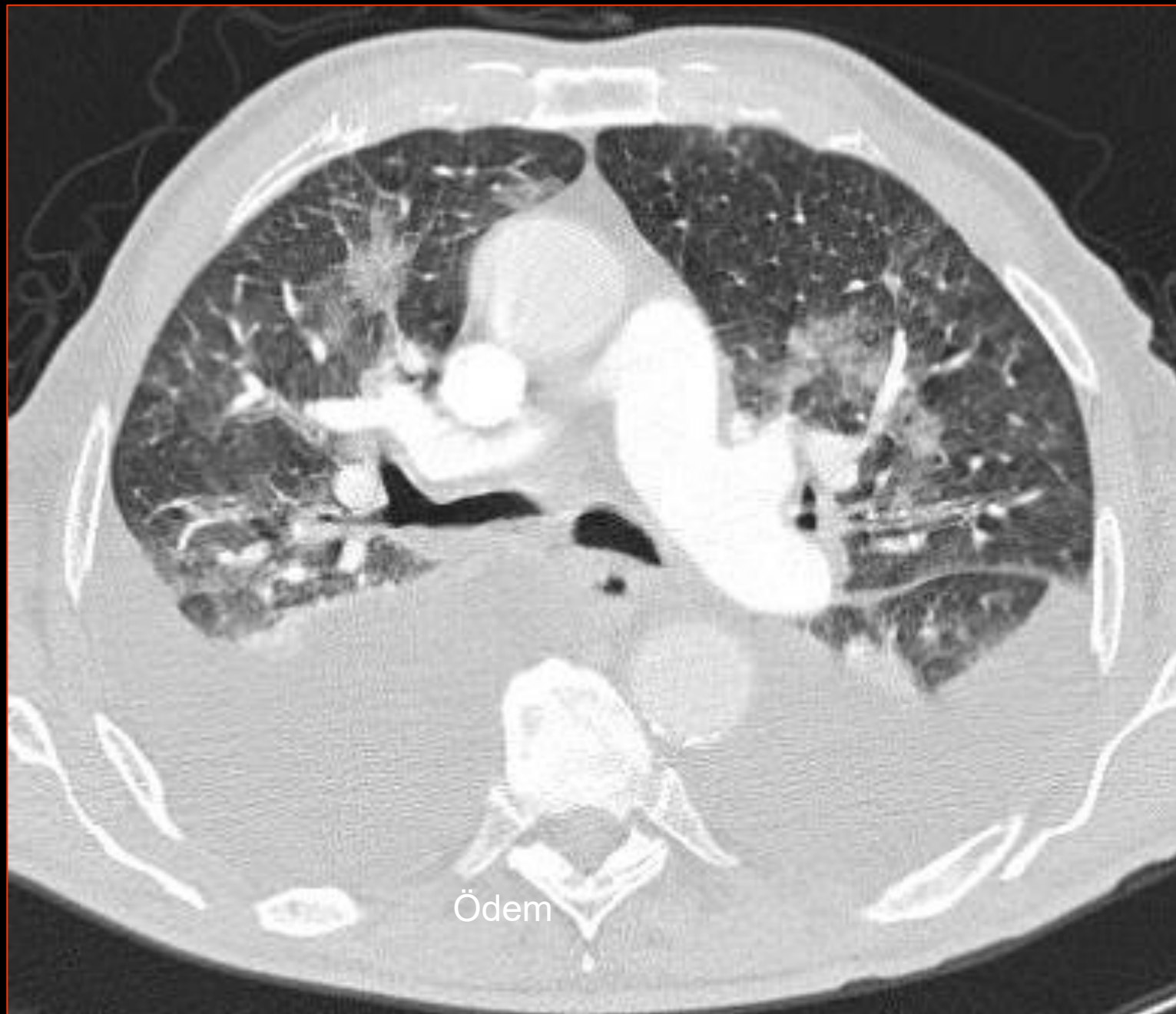E. Kollajen doku hastalıkları
romatoid artirit
skleroderma

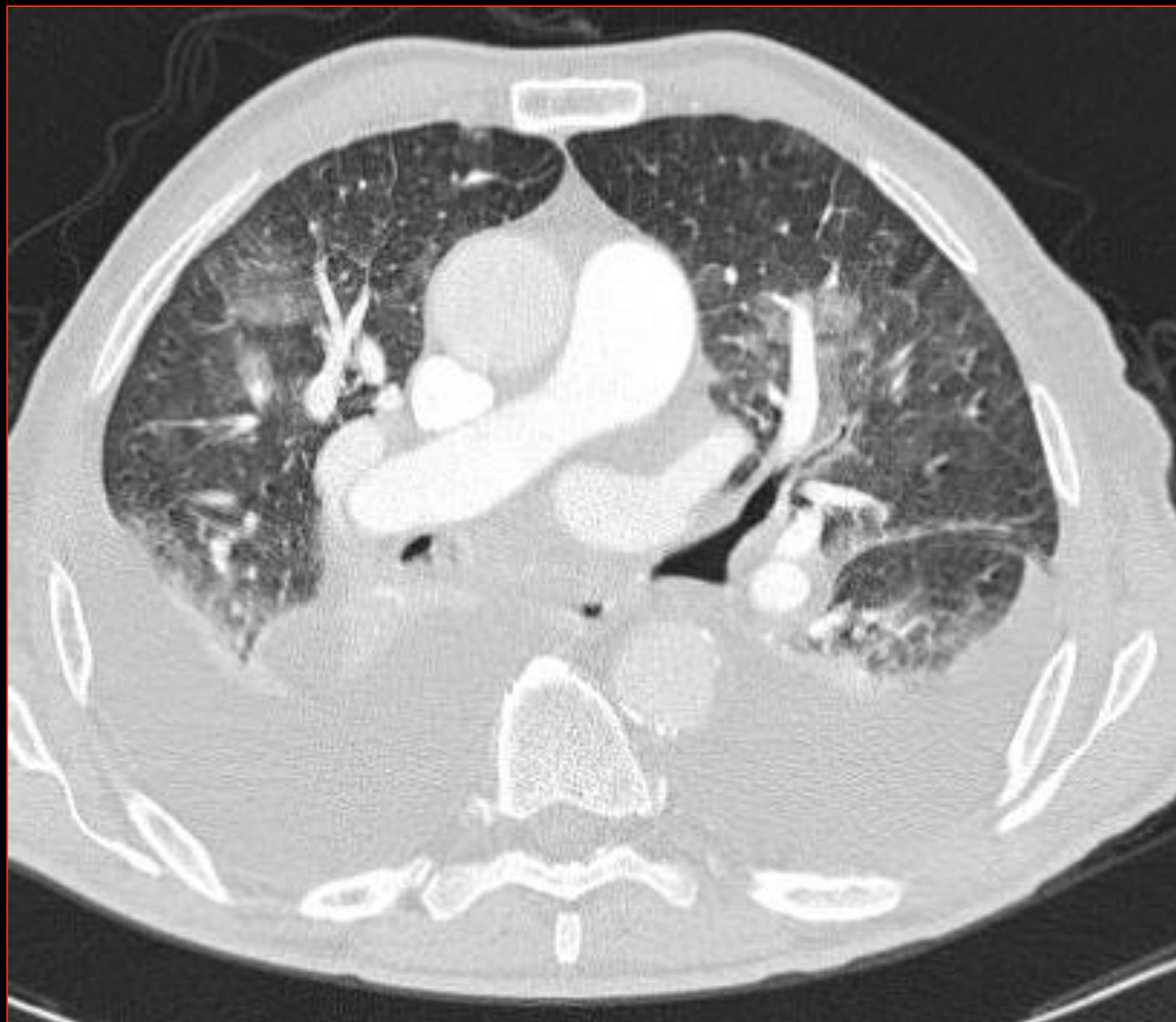F. İlaç reaksiyonları

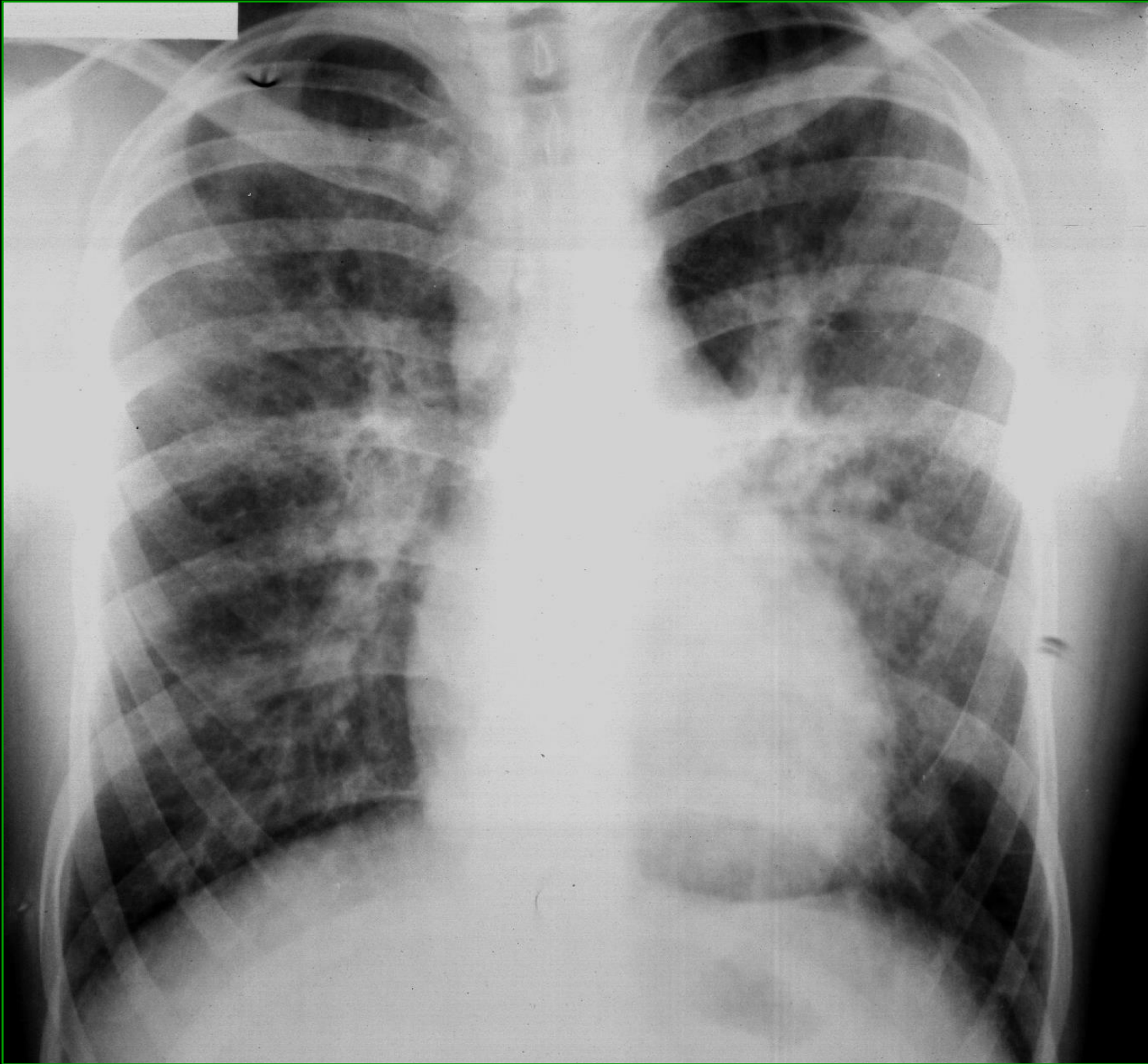
G. İdyopatik
OİP, DİP,
idyopatik pulmoner hemosiderozis
amiloidozis
interstisyel kalsifikasyon
(kronik böbrek y)



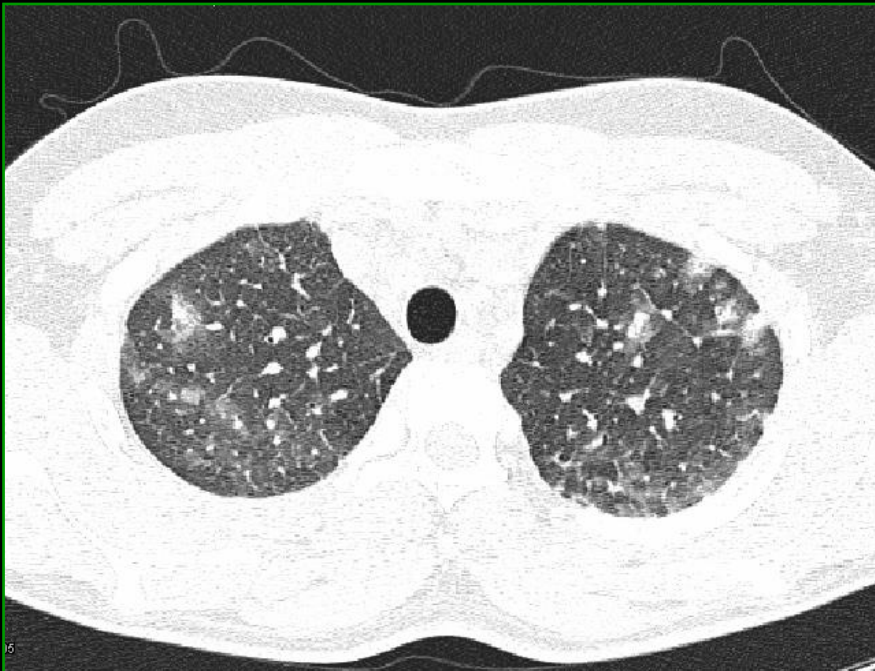



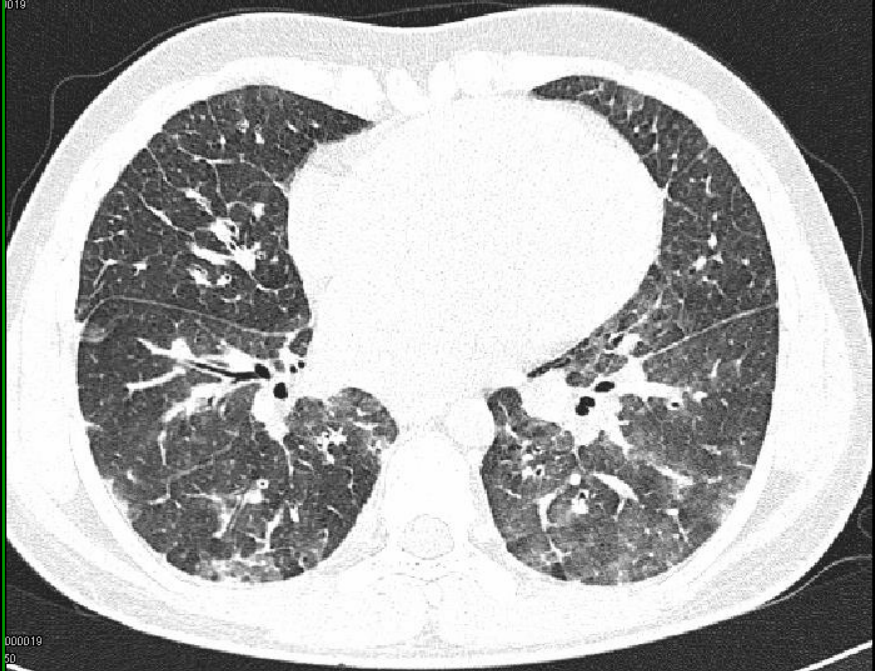




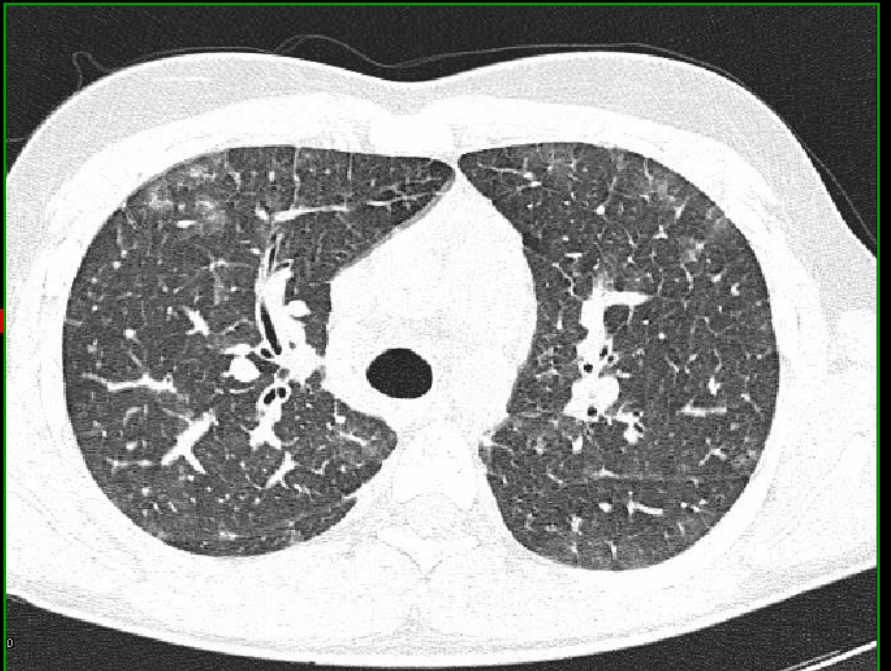
Kor triatrium



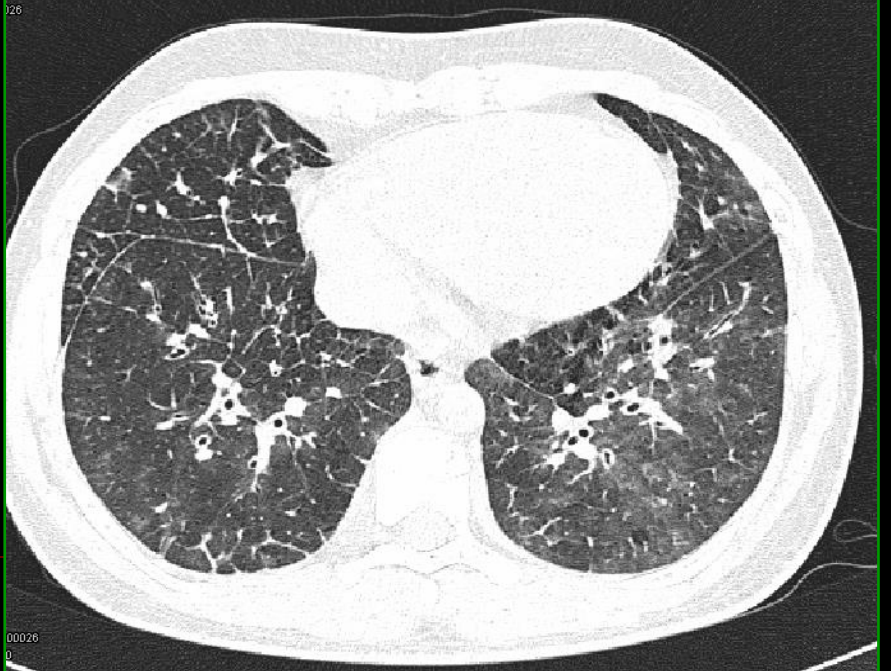
1/2004
3:37 PM
019



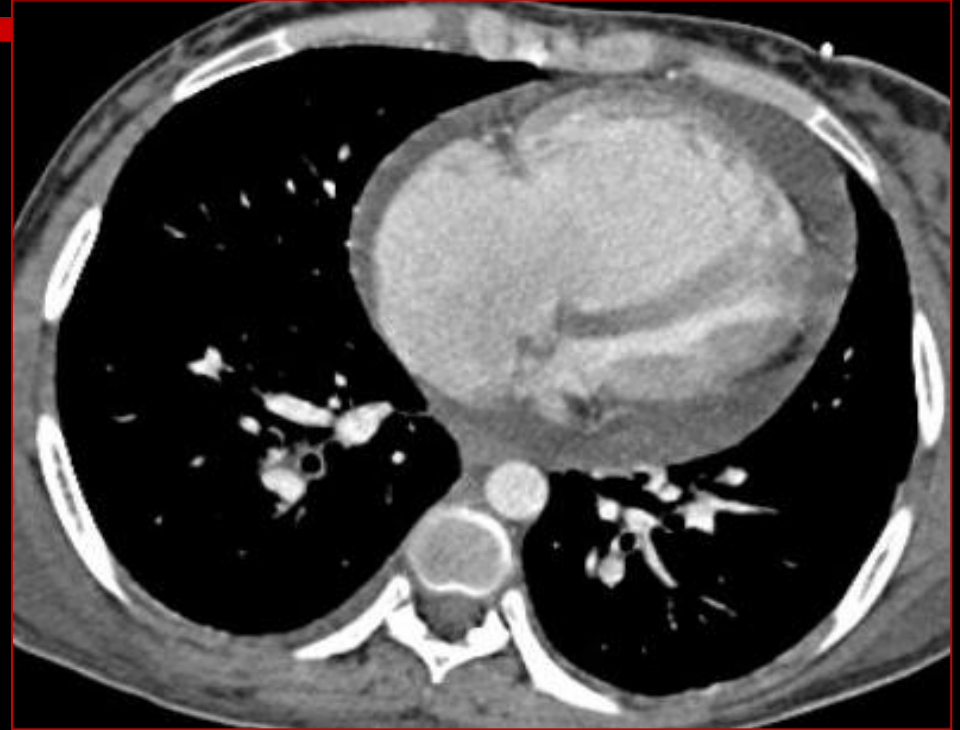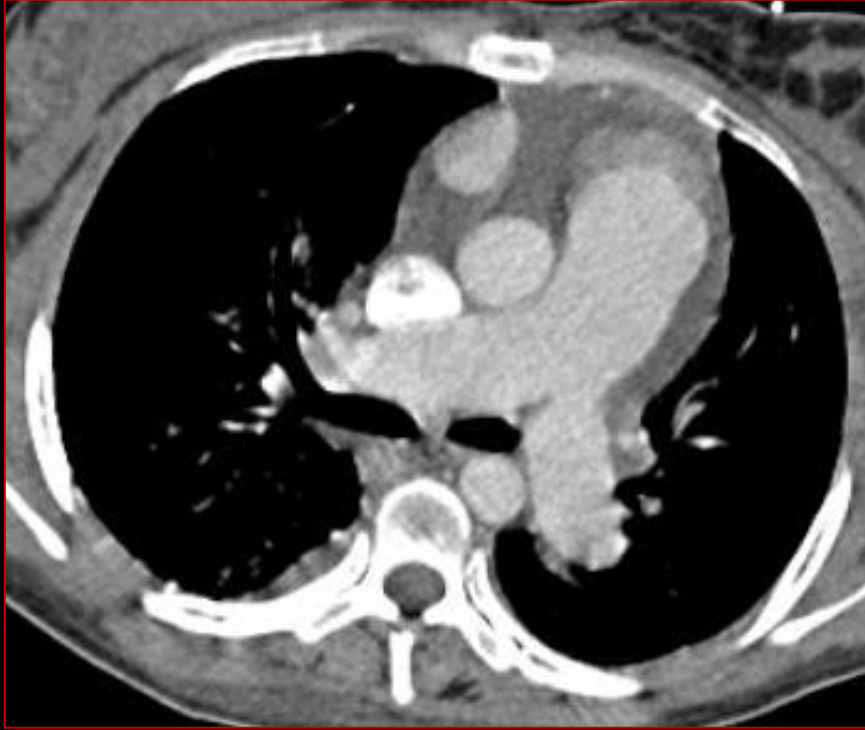
000019
50



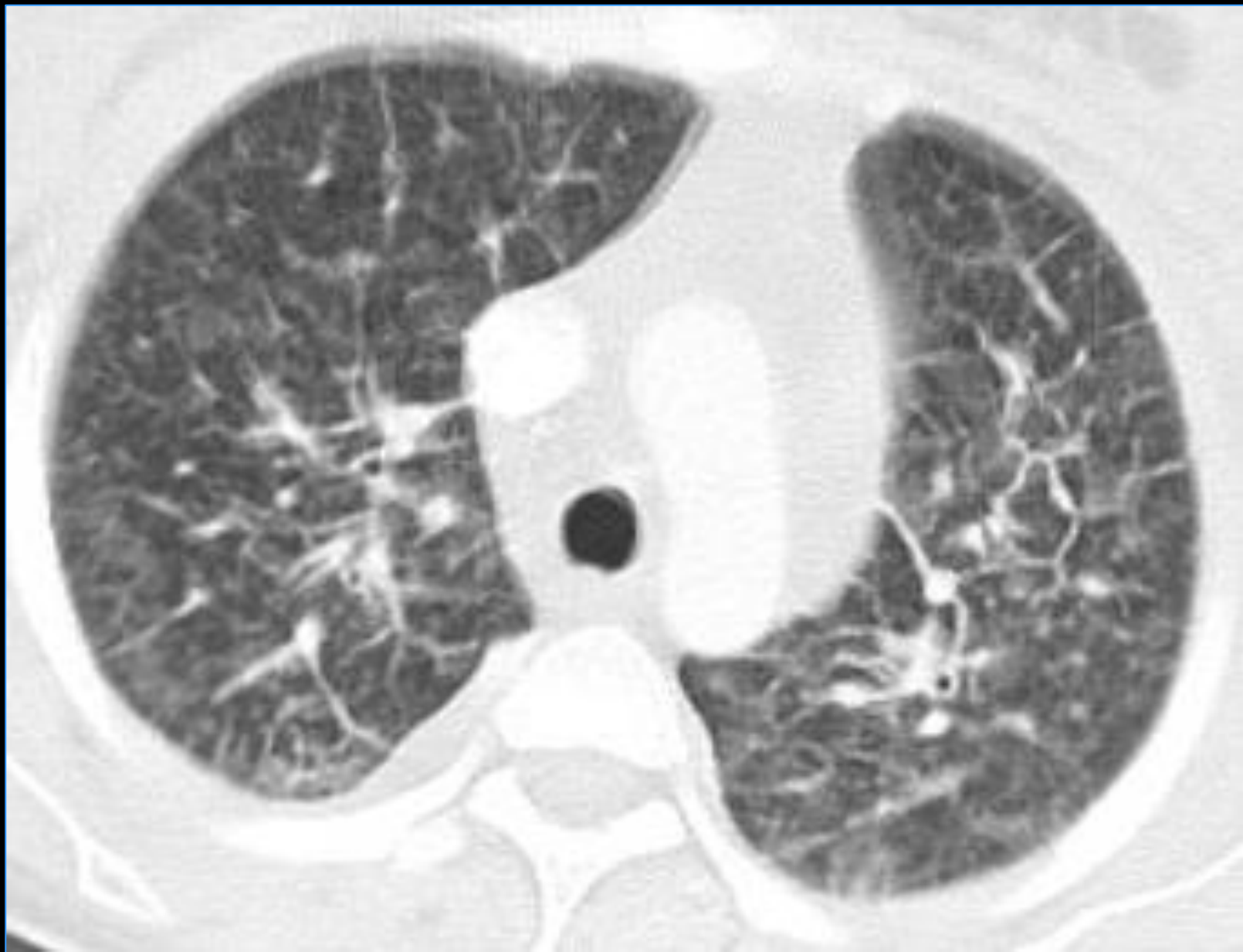2/2004
6:40 PM
026

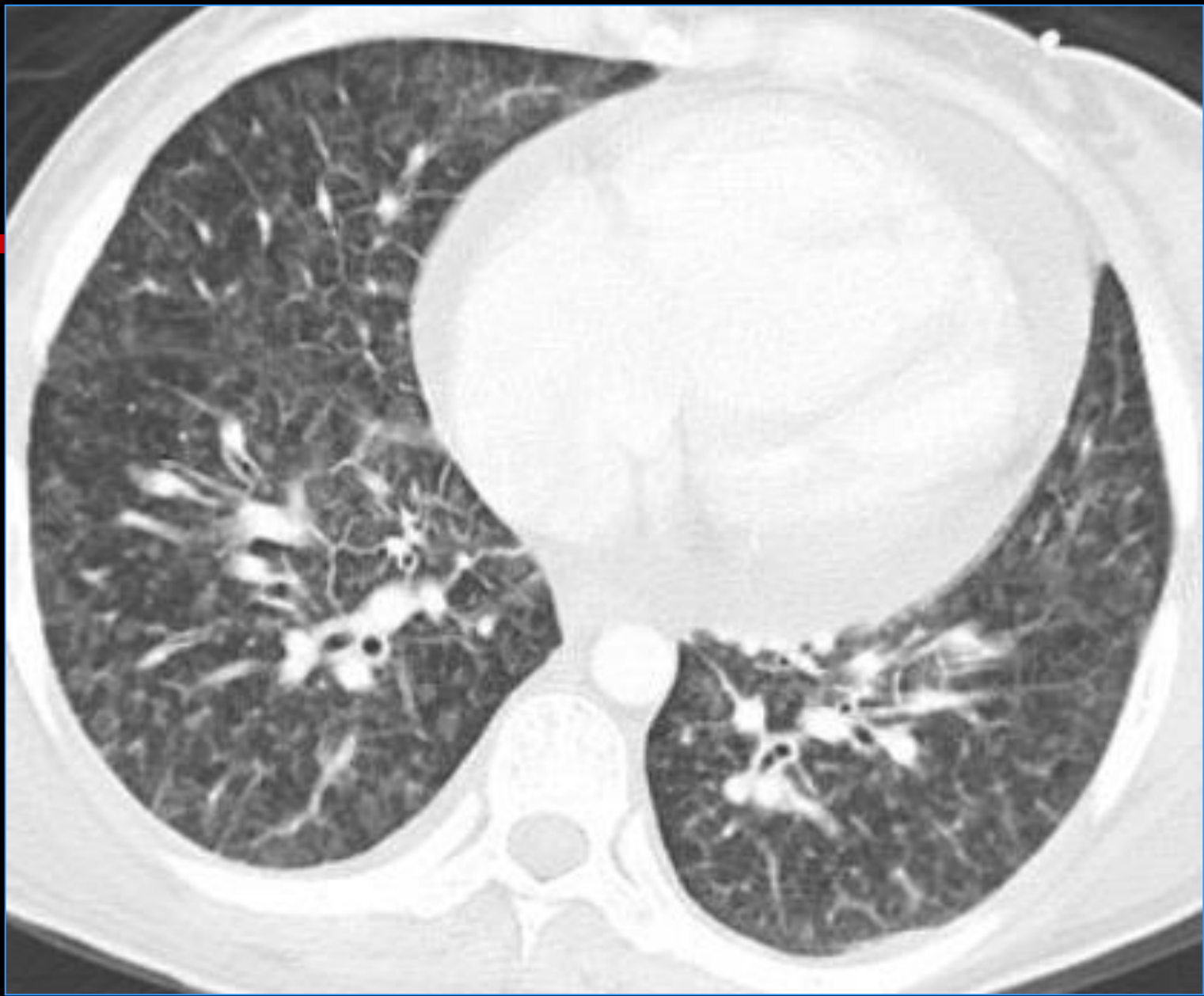


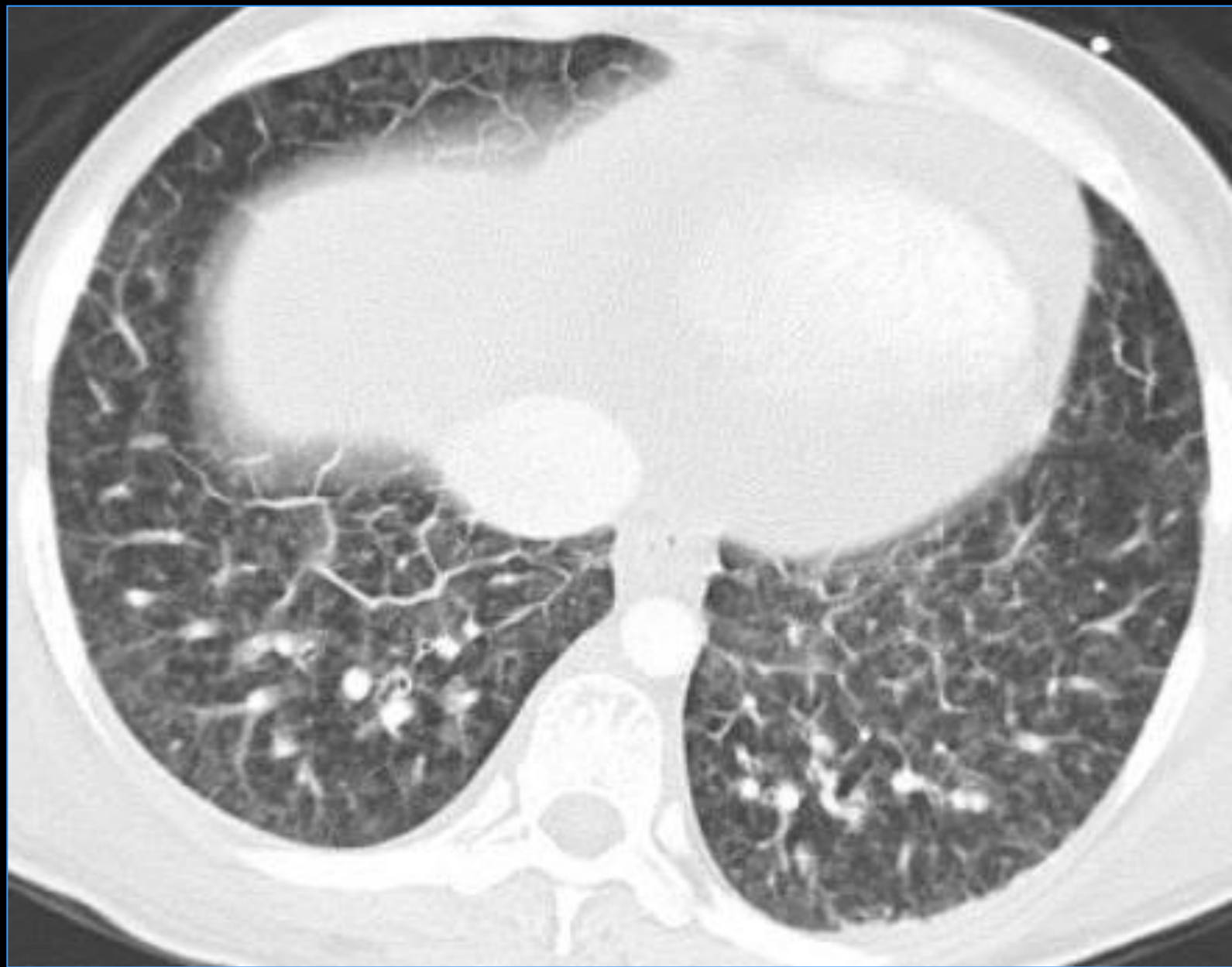00026
0

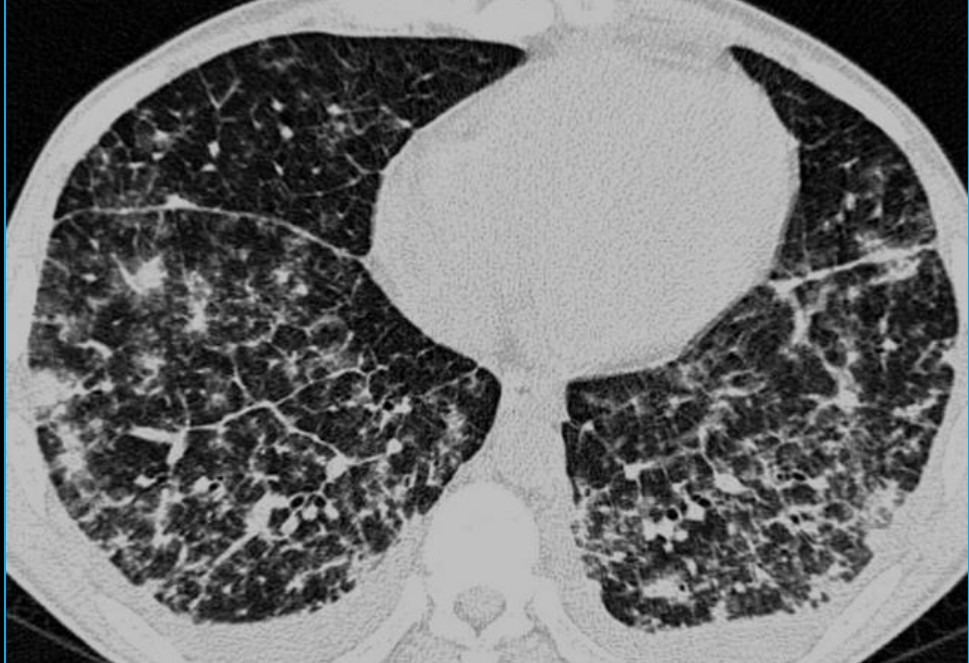
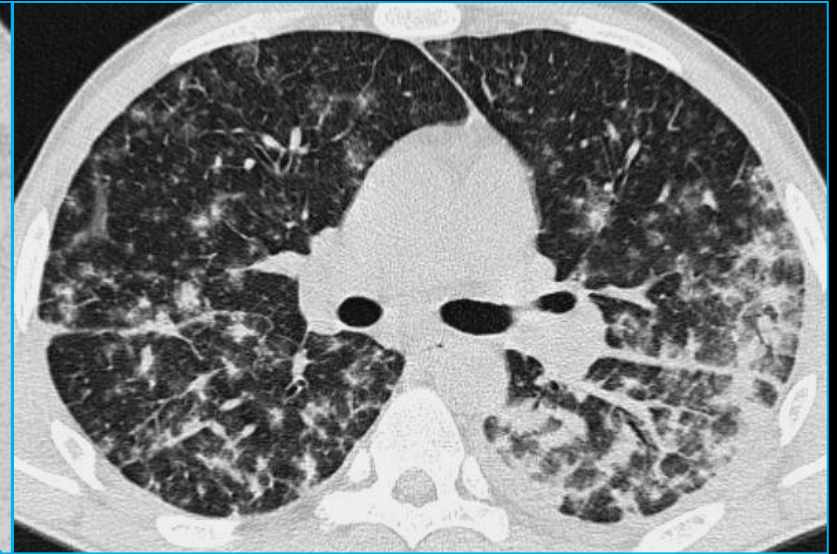
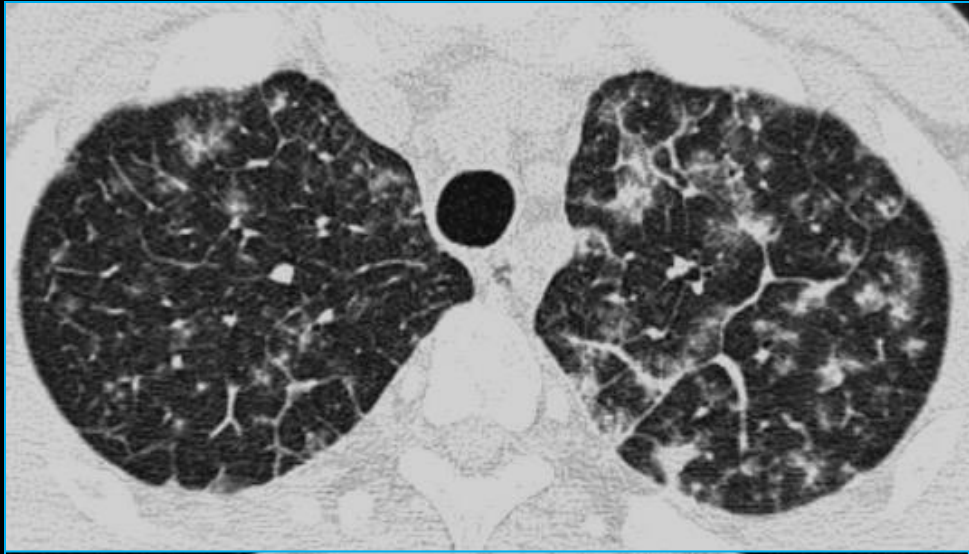

Pulmoner venoklüsif hastalık







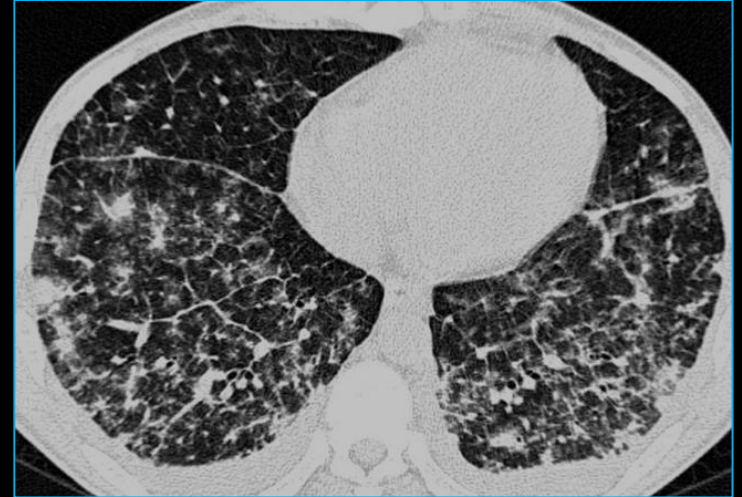


“Arnavut kaldırımı”

PJP

Arnavut Kaldırımı Bulgusu

- Akut interstisyel pnömoni: ARDS
- Pulmoner ödem- hemoraji
- Pnömoni (PJP, Mikoplazma, Bakteriyel P)
- Akut eozinofilik pnömoni
- Radyasyon pnömonisi
- Alveolar proteinozis
- Nonspesifik inters. Pnömoni
- Hipersensitivite pnömonisi
- OP
- Eozinofilik granülomatöz polianjit
(Churg- Strauss send)
- Lipoid pnömoni
- In situ karsinom



Çizgisel (Retiküler) Dansiteler

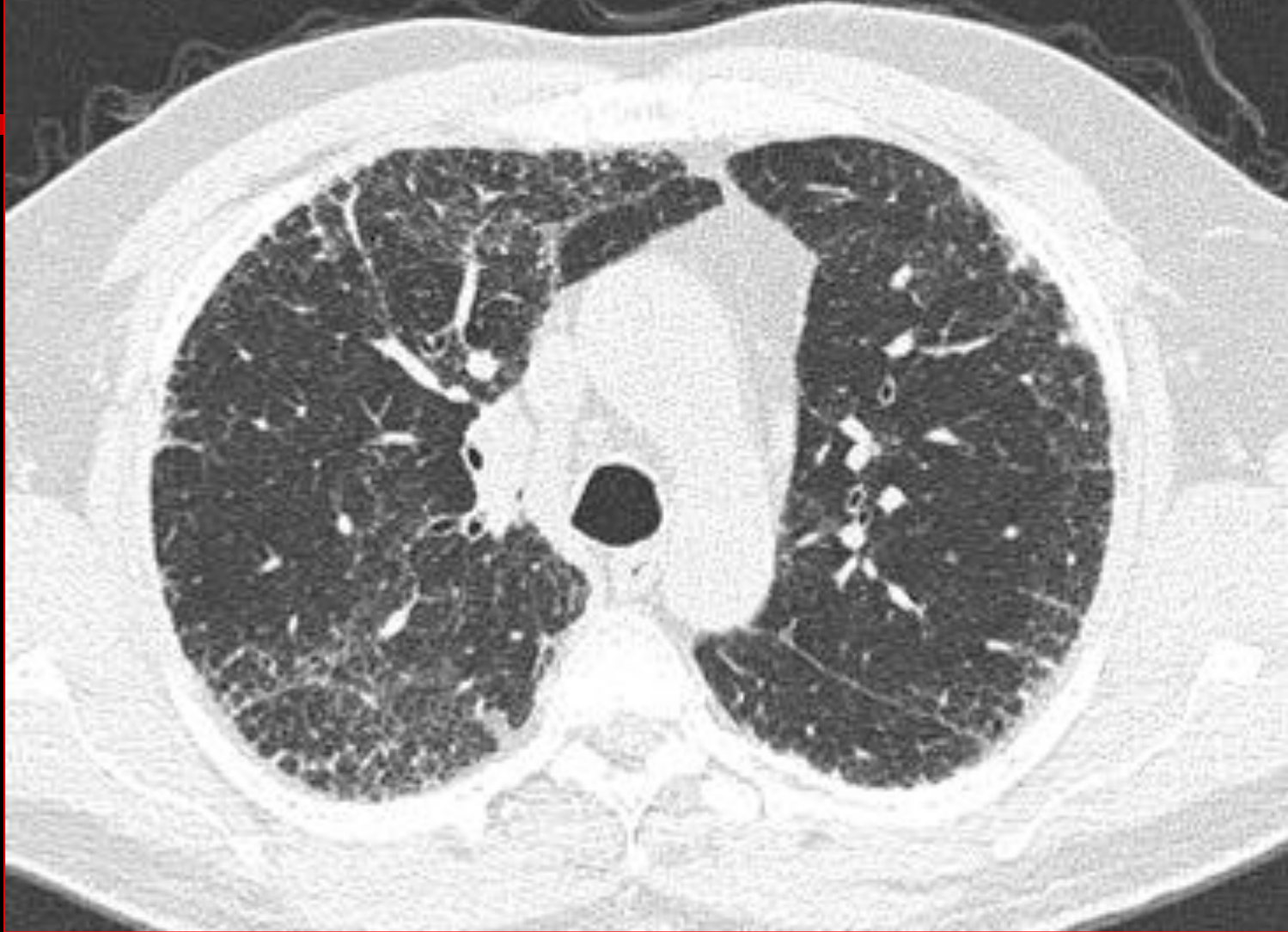- Kronik interstisyel pnömoniler -İPF
 - Kollajen doku hastalıkları
 - Asbestoz
 - Lenfanjitik karsinomatosis
 - İlaç reaksiyonları

 - Sarkoidoz
 - Radyasyon fibrozisi
 - KKY-interstisyel ödem
-

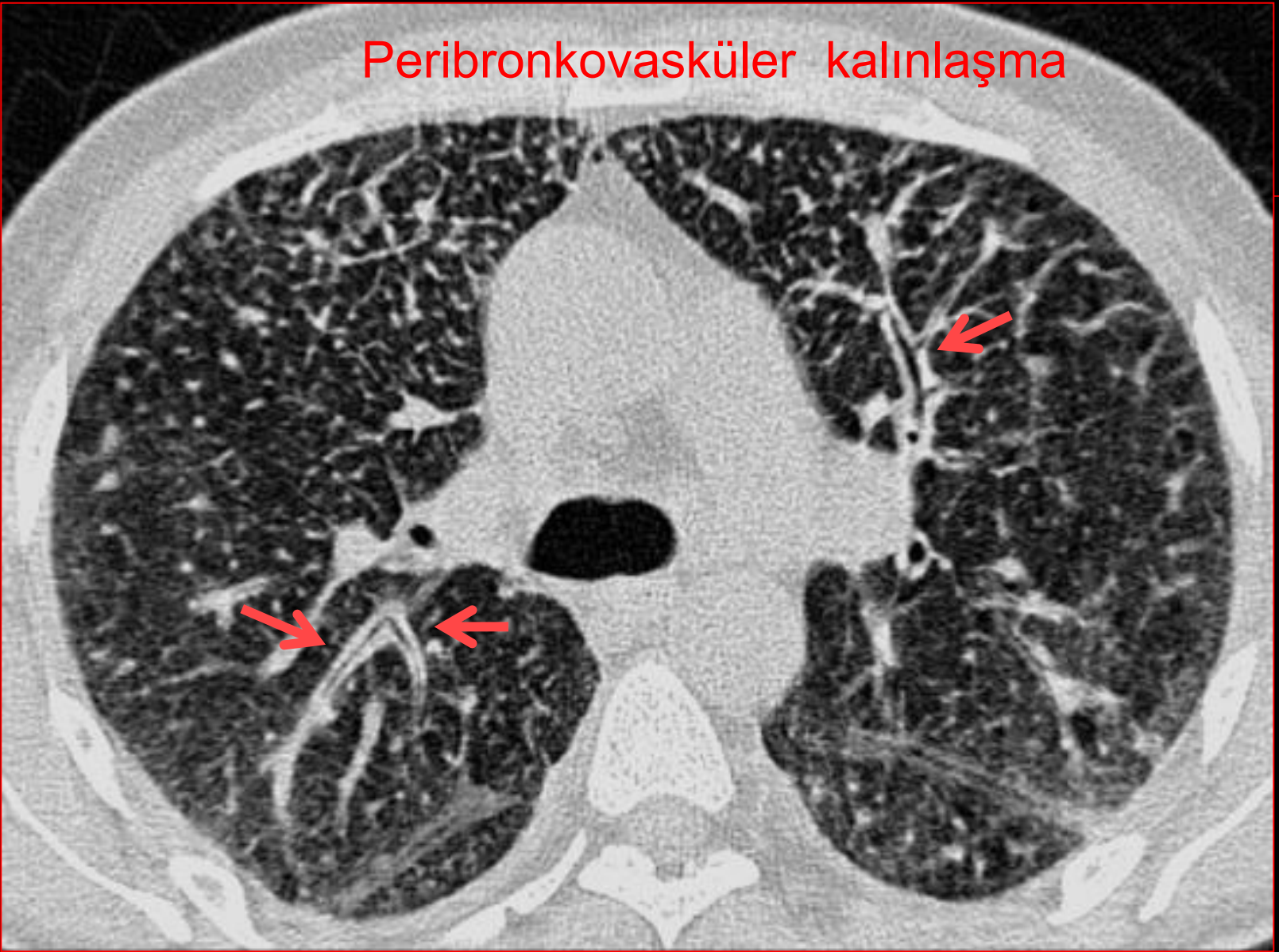
Çizgisel ve Retiküler Dansiteler

- İnterstisyel kalınlaşmalar:
 - Peribronkovasküler
 - İnterlobüler
 - İntralobüler
 - Subplevral
 - Arayüzey bulgusu
 - Subplevral çizgiler
 - İrregüler çizgisel opasiteler
 - Parenkimal bantlar
 - Balpeteği
-

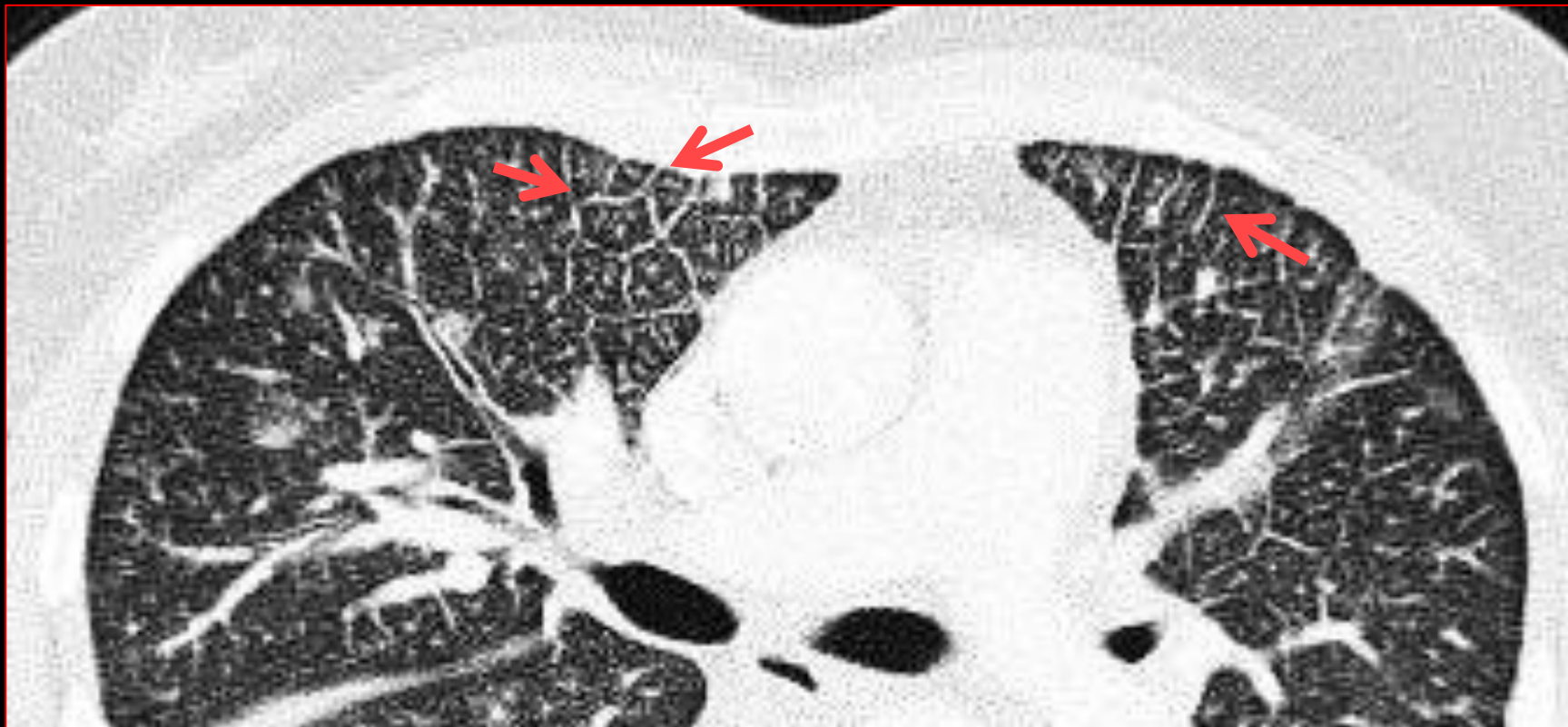
Peribronkovasküler kalınlaşma



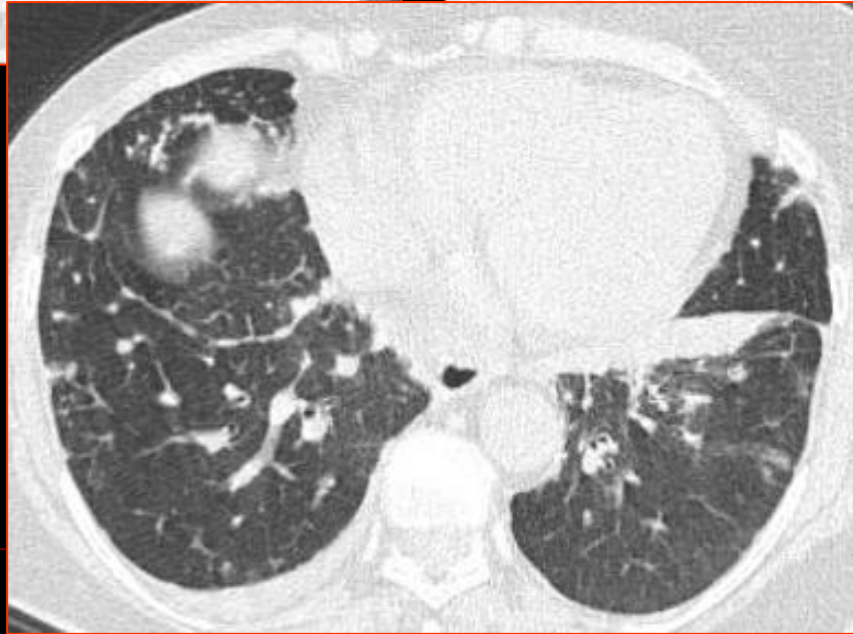
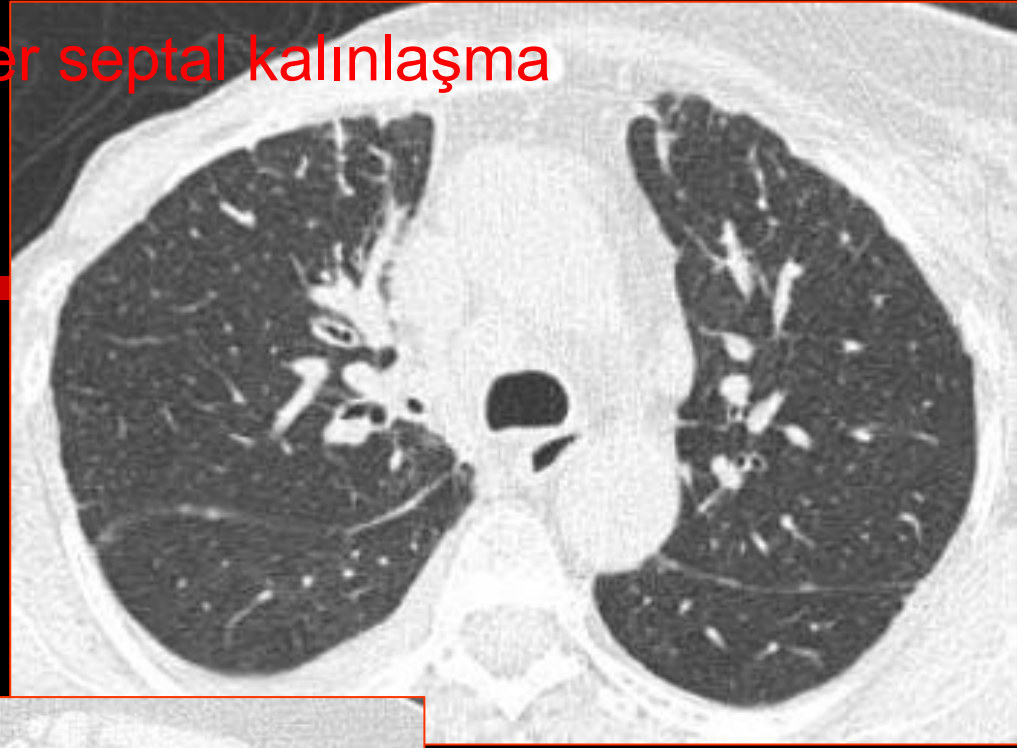
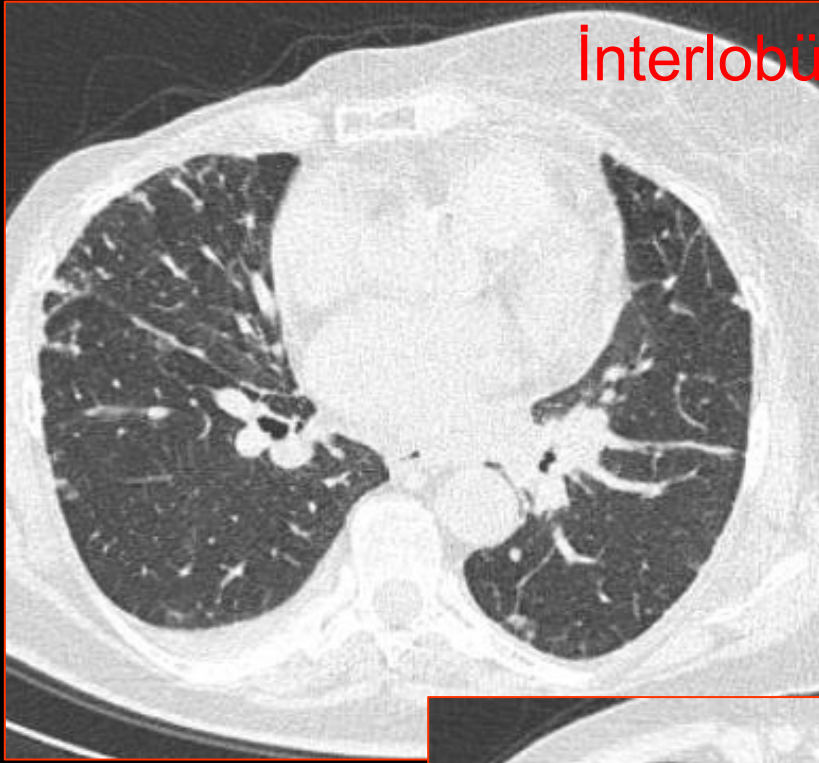
Peribronkovasküler kalınlaşma



İnterlobüler septal kalınlaşma

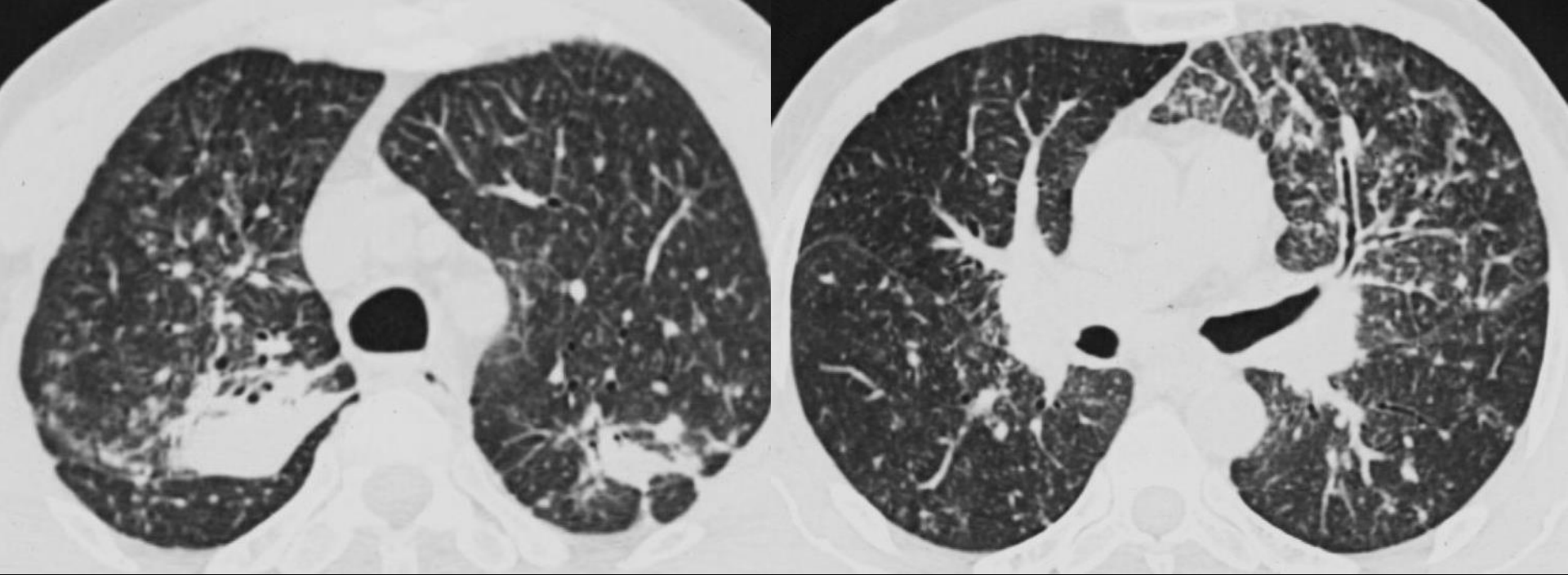


İnterlobüler septal kalınlaşma



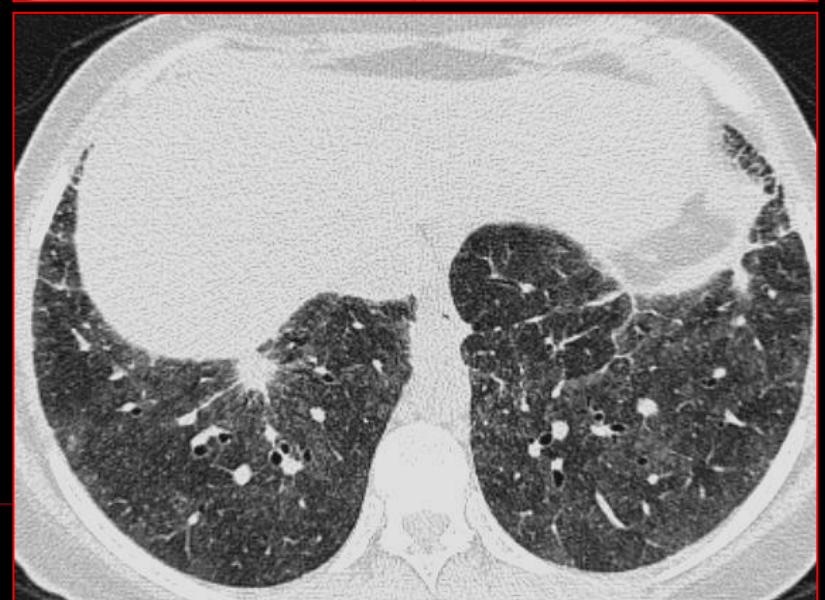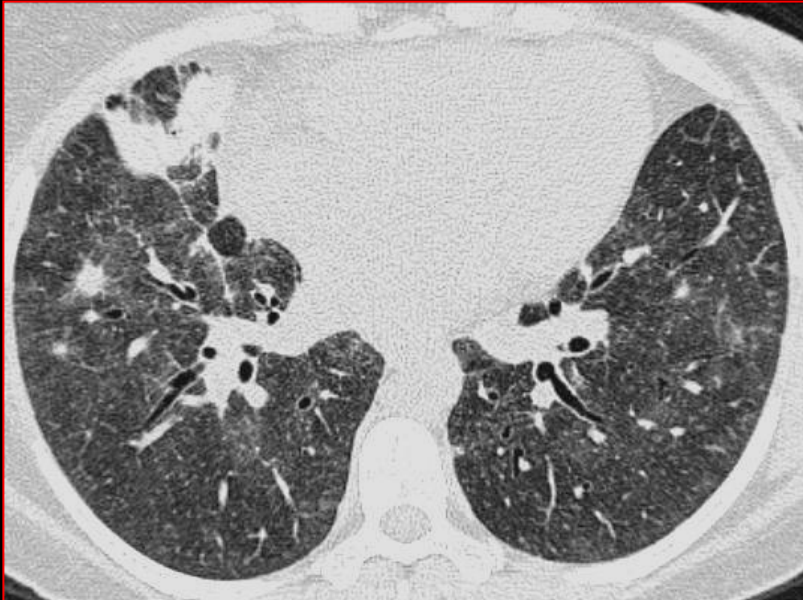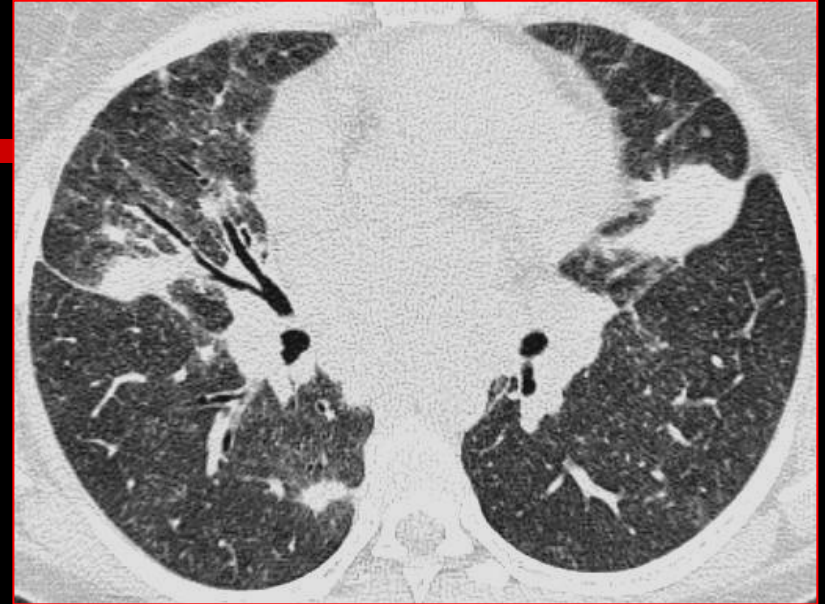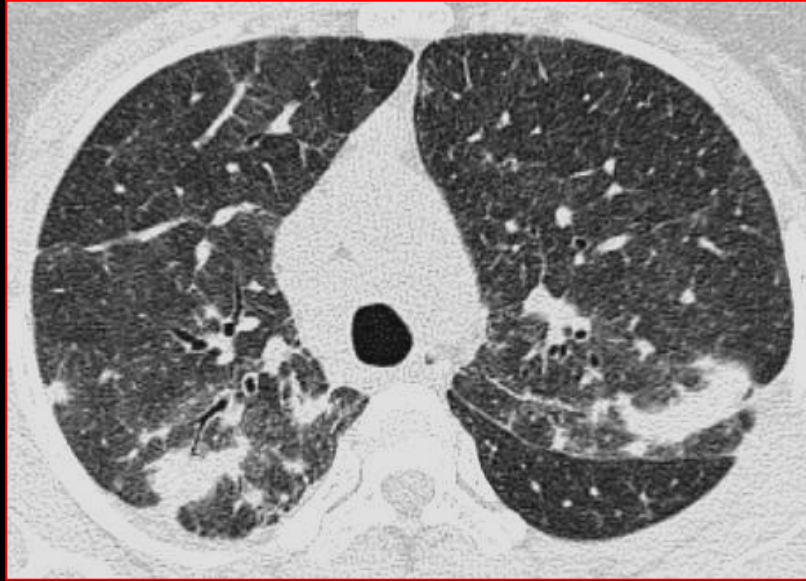Meme CA

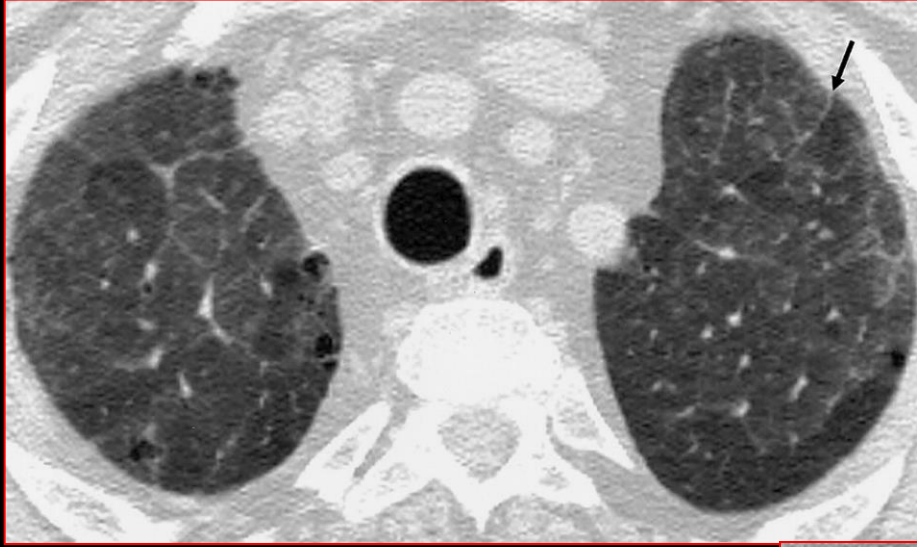İnterlobüler septal kalınlaşma



Silikozis

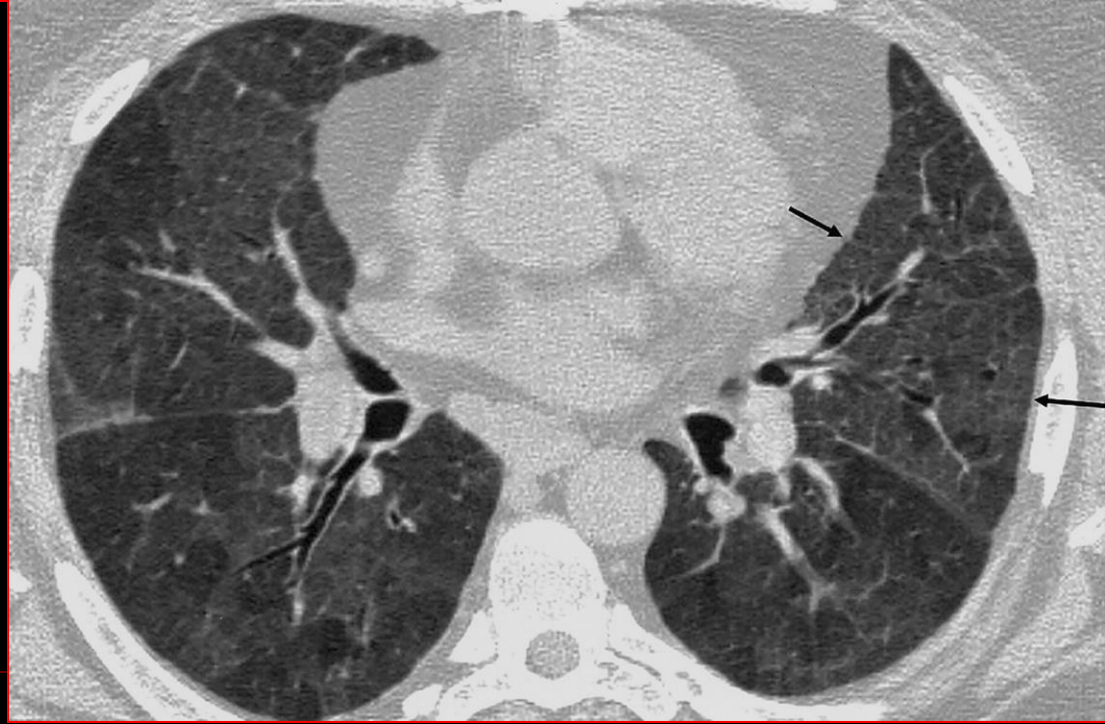Sarkoidoz

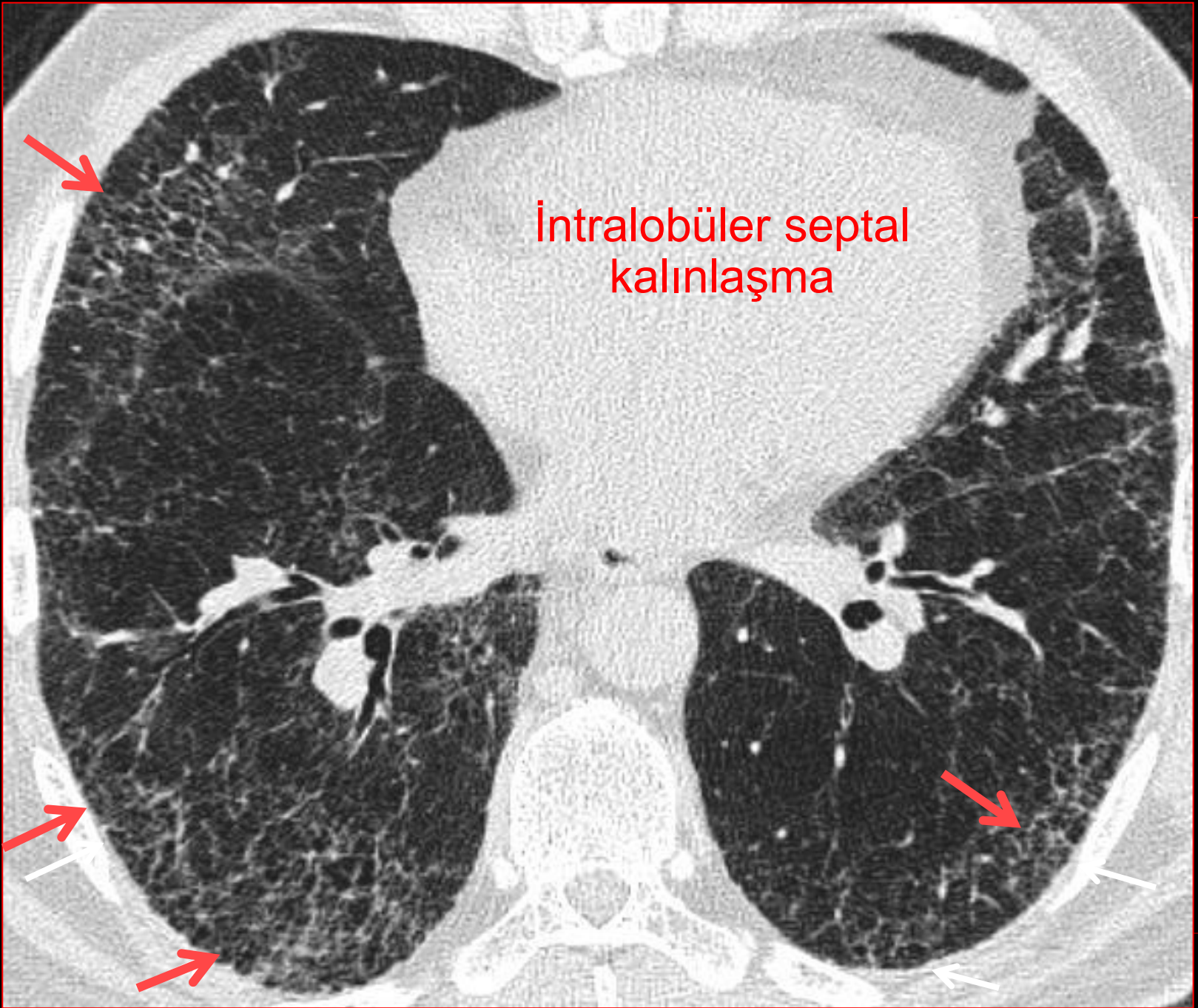




İnterlobüler septal kalınlaşma

Deskuamatif
İnterstisyel Pnömoni

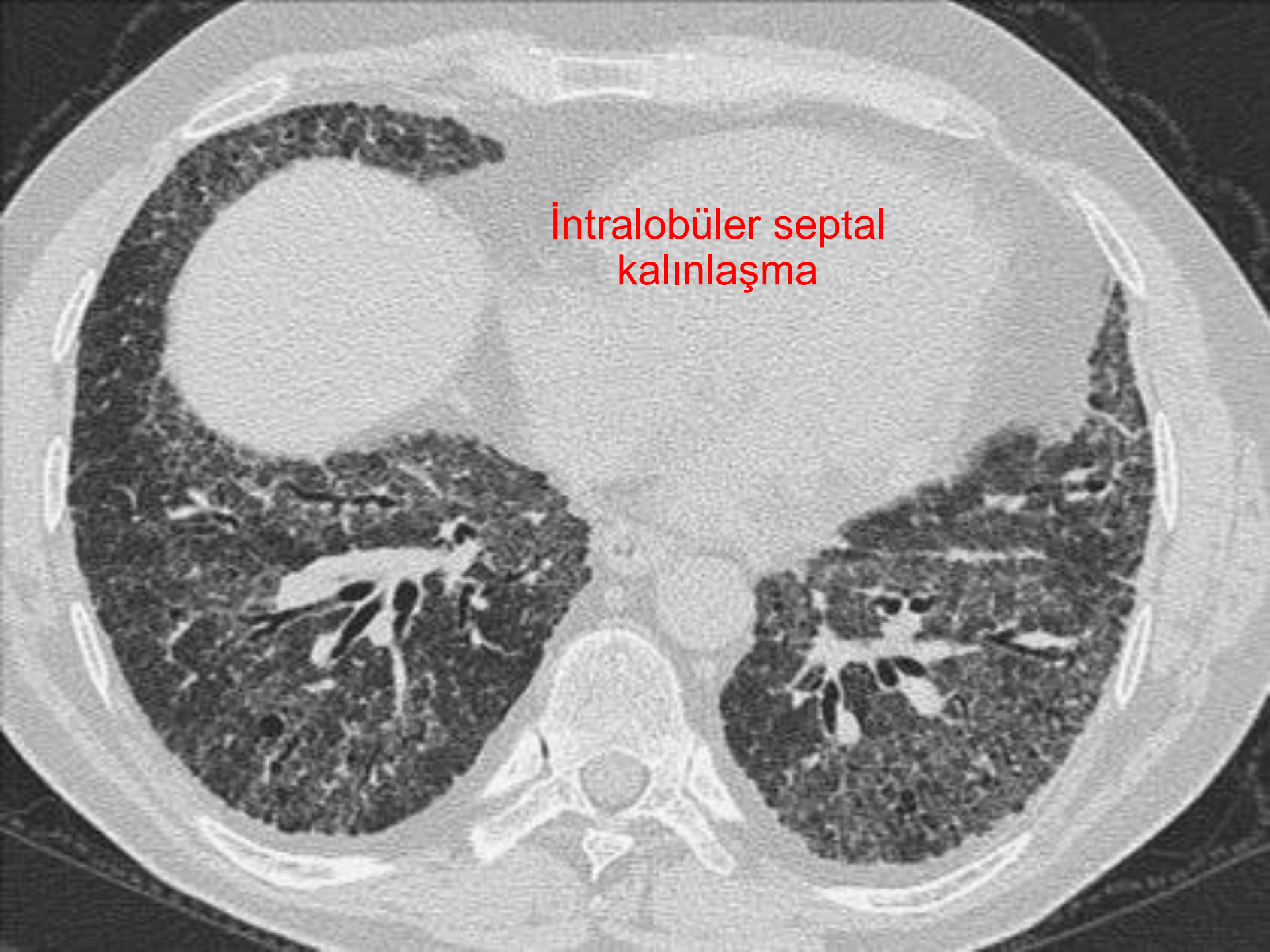




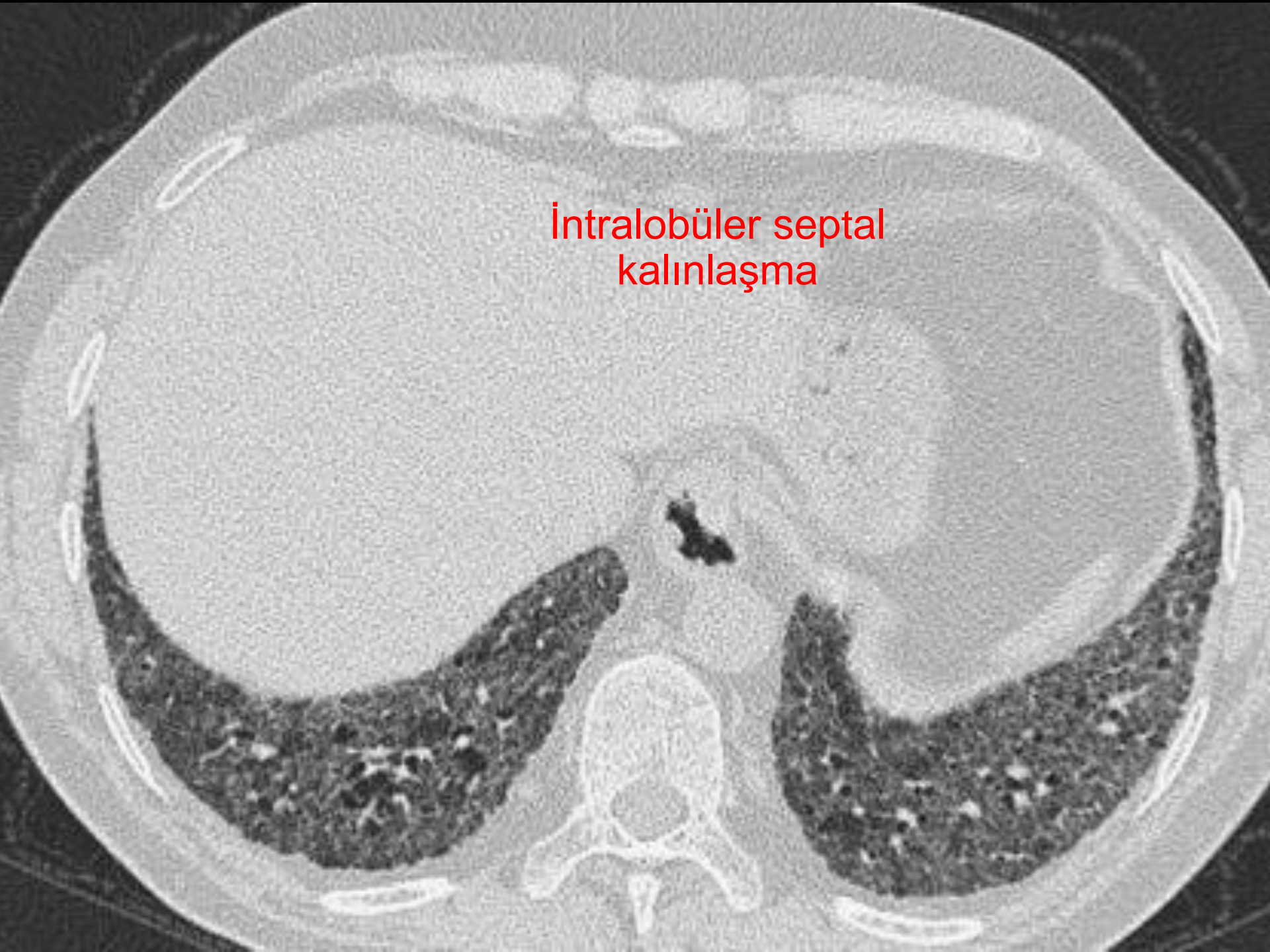
İntralobüler septal kalınlaşma

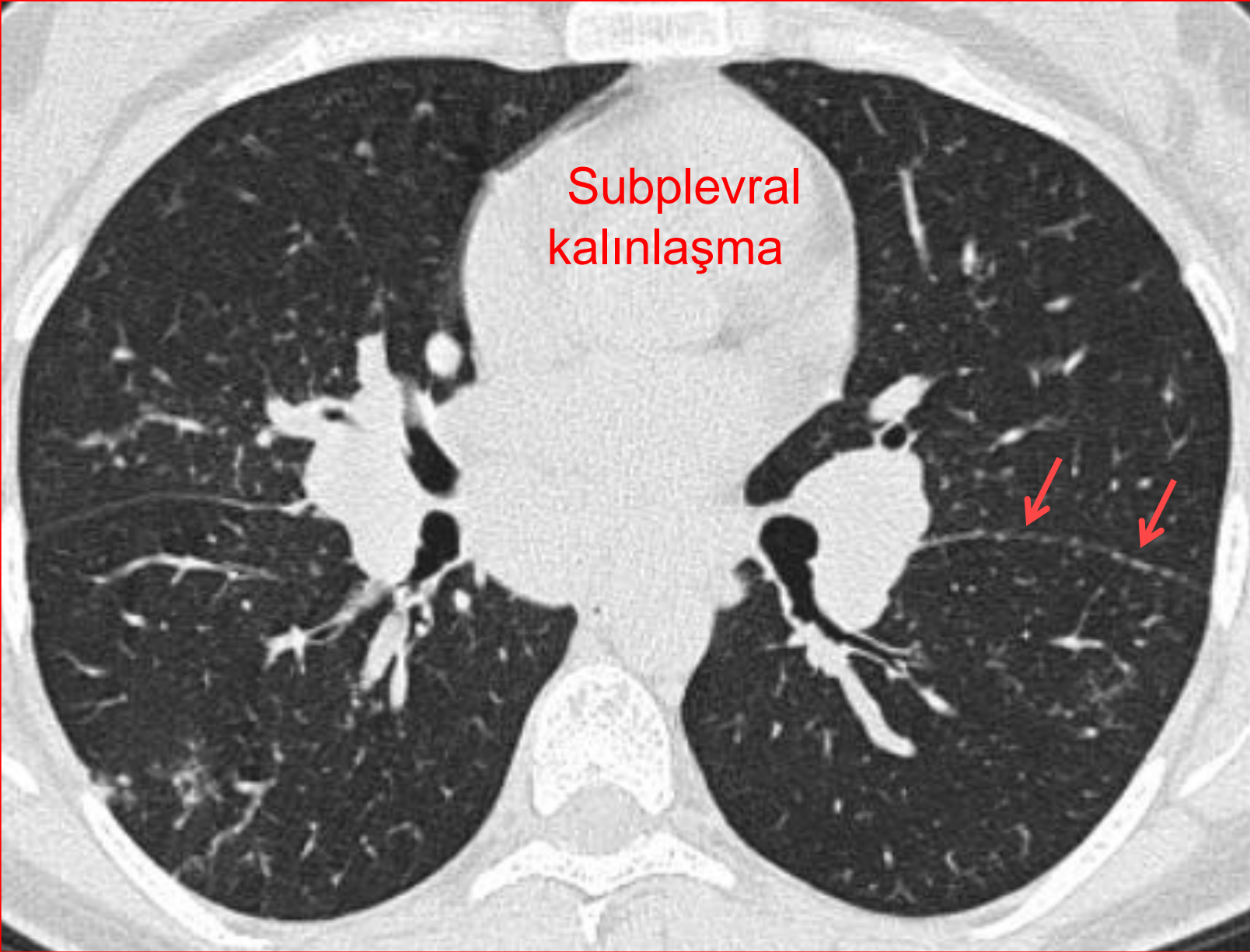
İPF

İntralobüler septal kalınlaşma




İntralobüler septal kalınlaşma

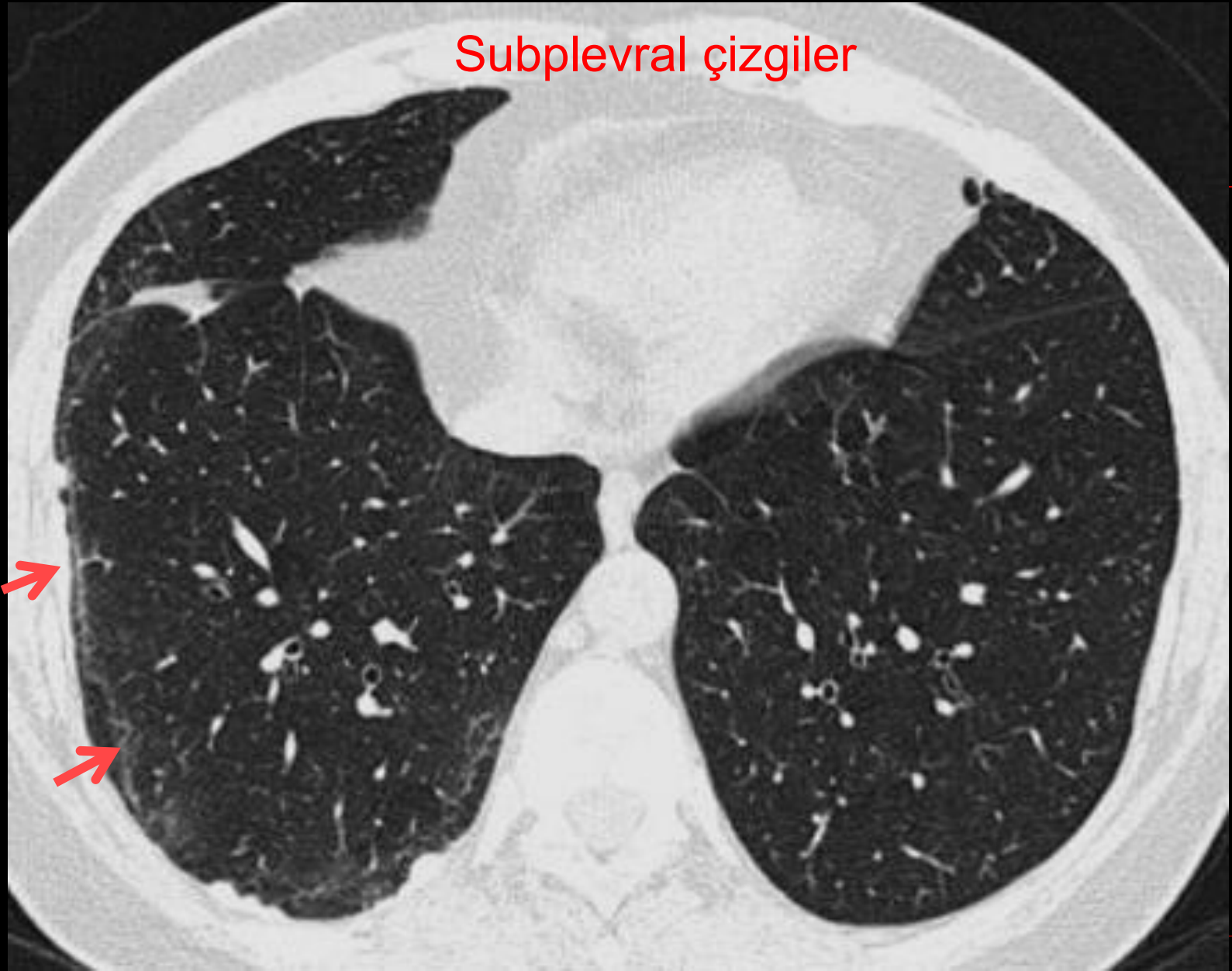




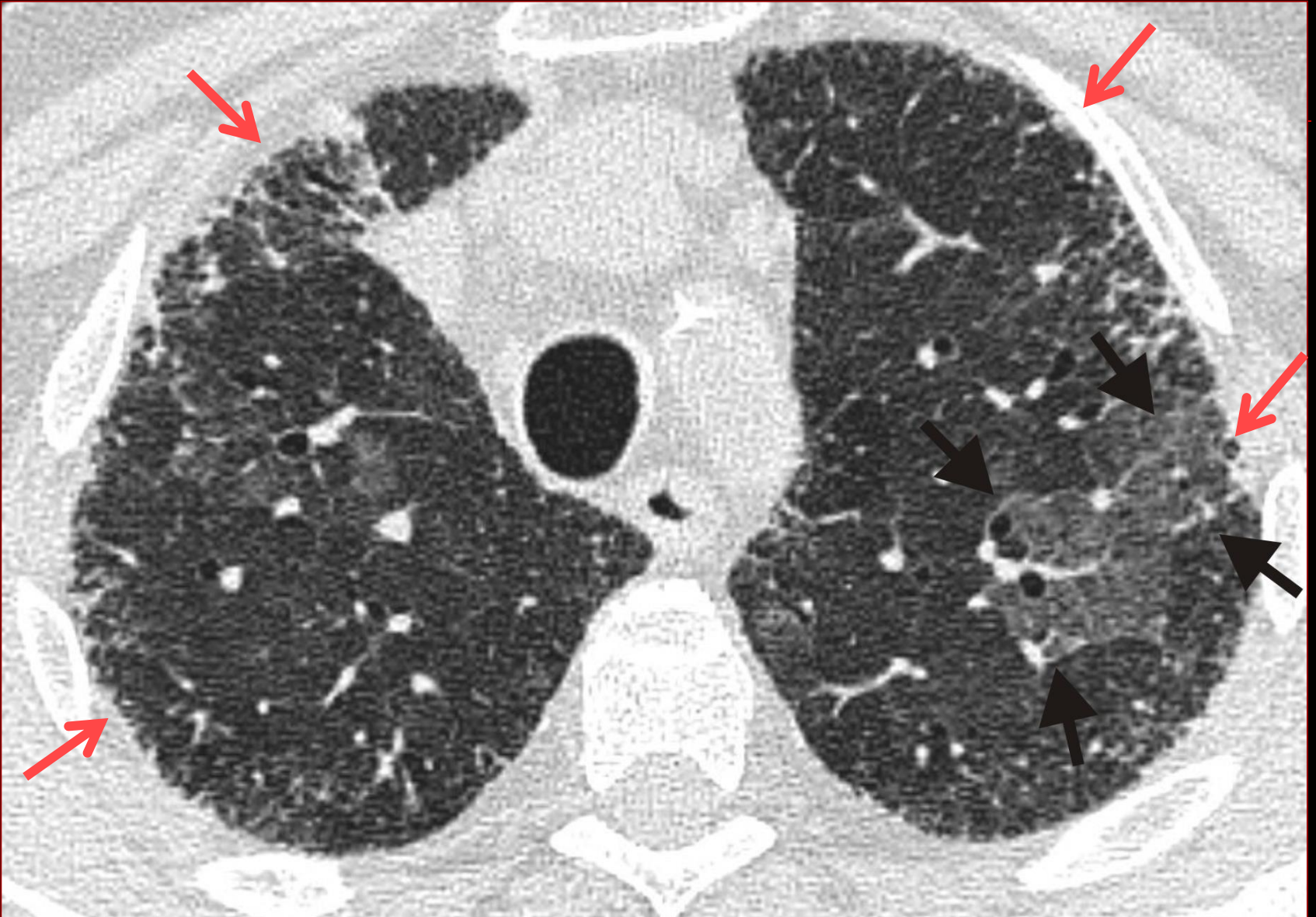Subplevral
kalınlaşma

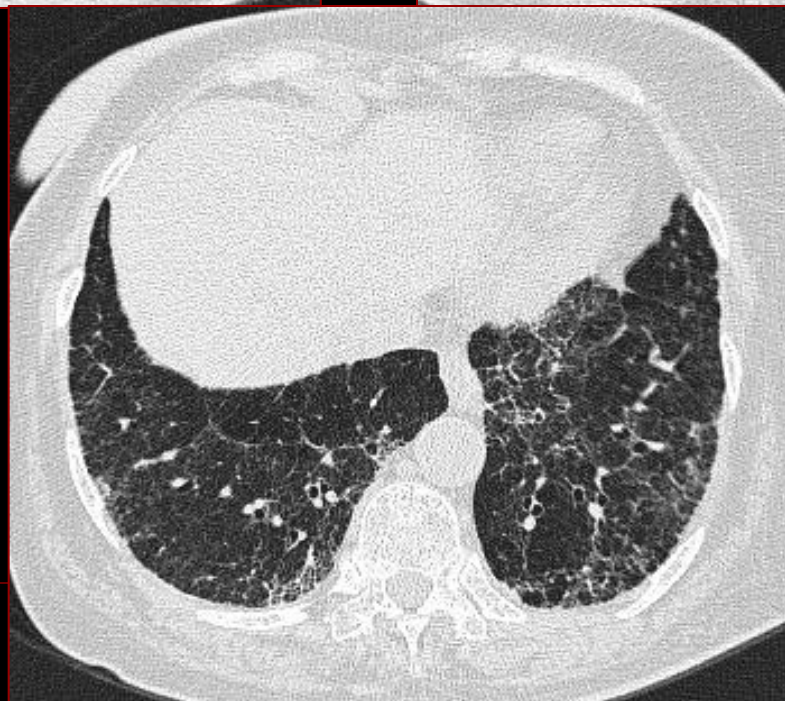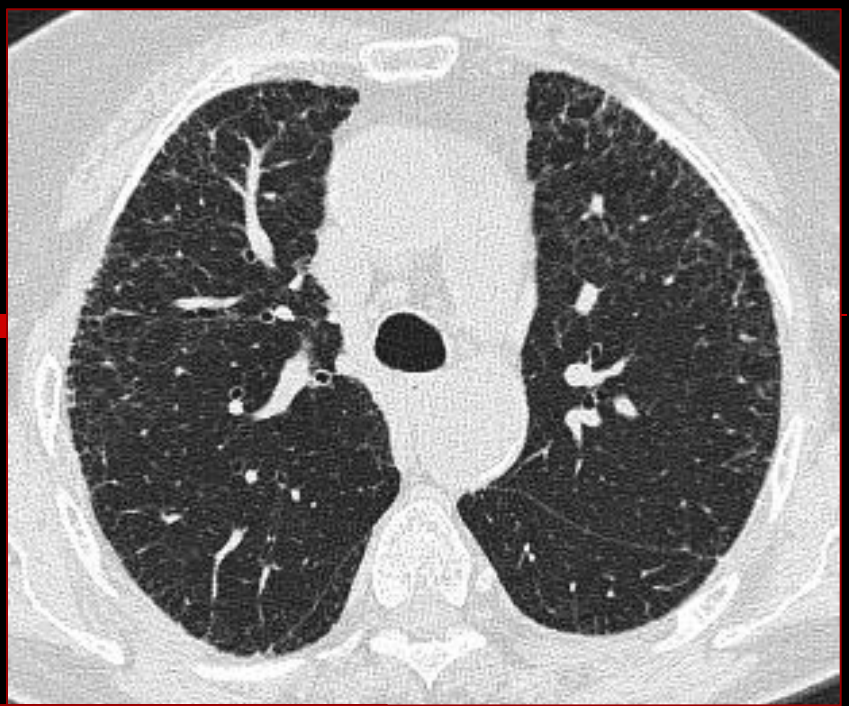
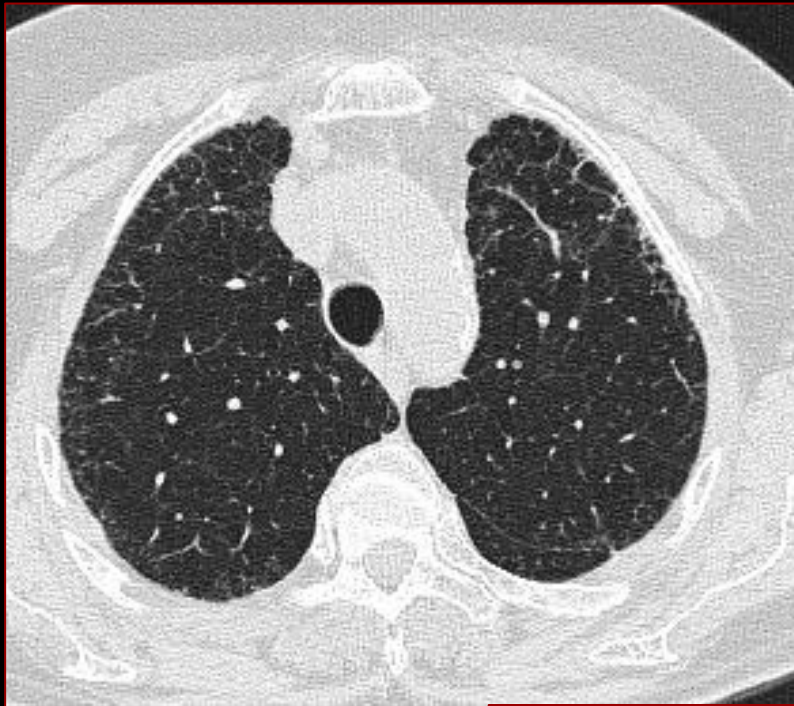


Subplevral çizgiler



Ara yüzey bulgusu



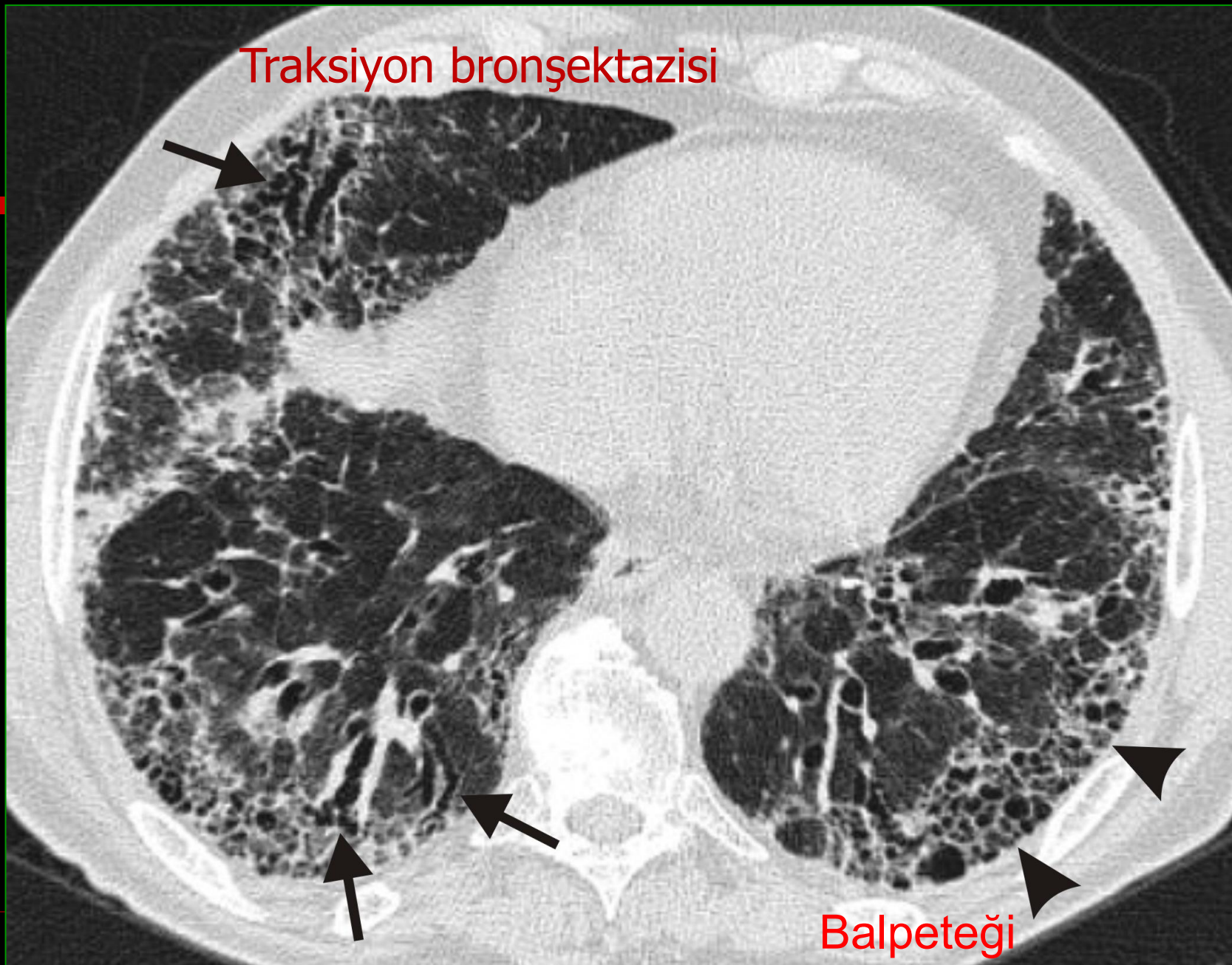


Skleroderma

Traksiyon bronşektazisi

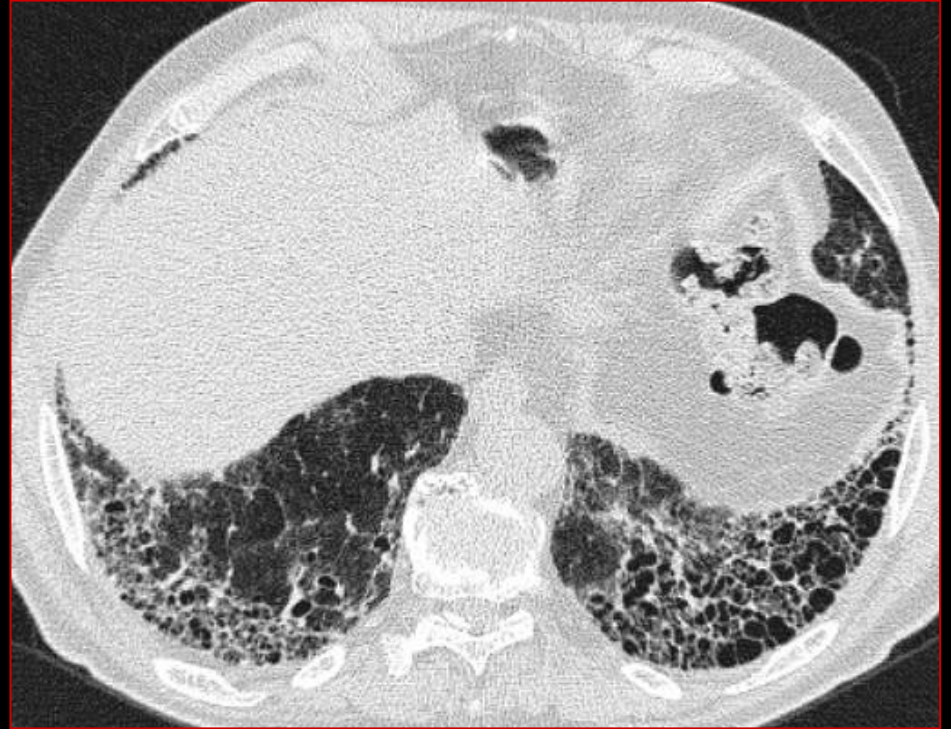

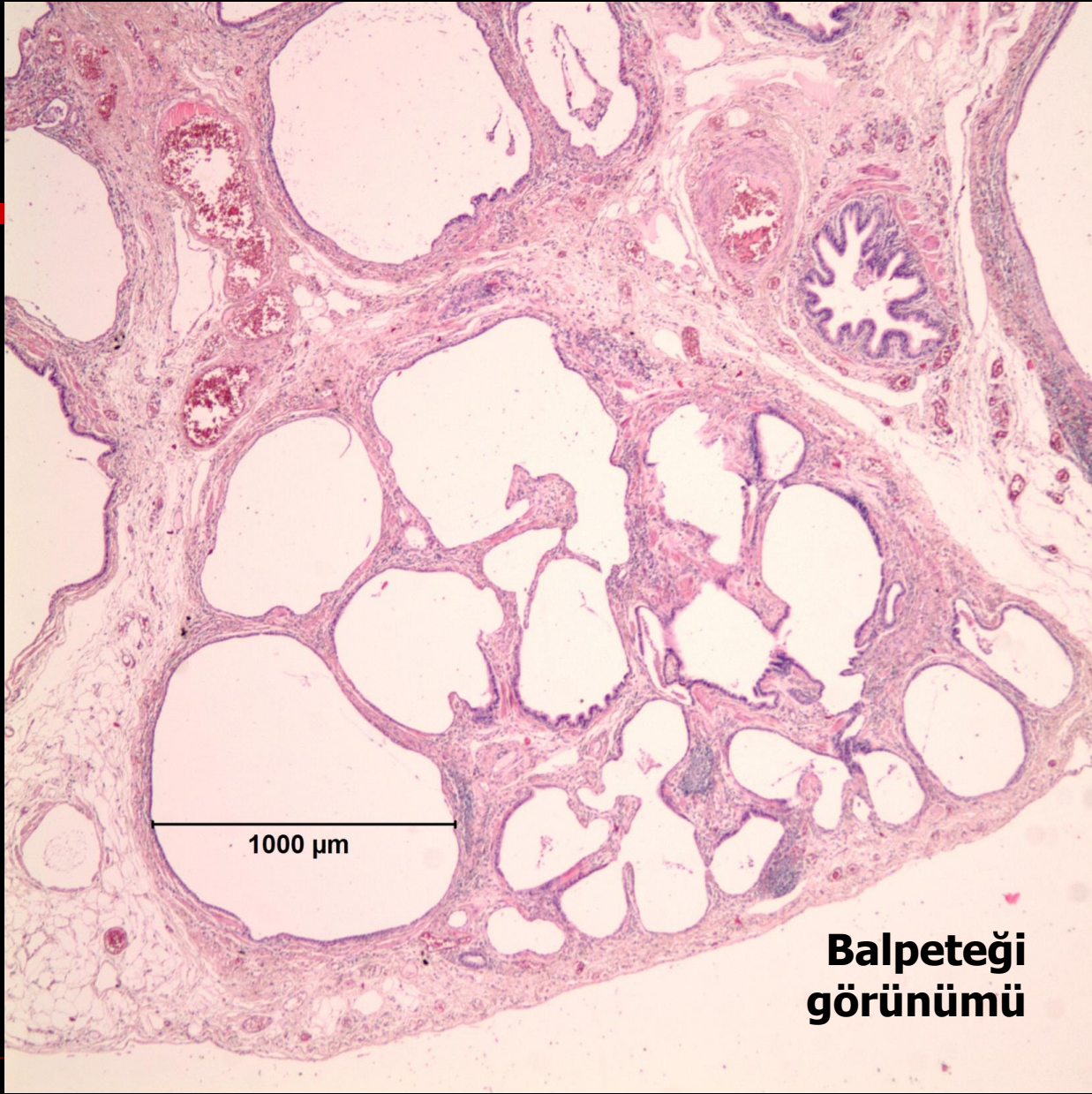
Balpeteği



Bal Peteđi Bulgusu

- Tipik olarak 3-10 mm apında, kalın fibrotik duvarlı, kistik hava boşluklarıdır.
- apları 25 mm'ye kadar olabilir.
- İleri metaplastik bronşolar epitel ile dşelidir.





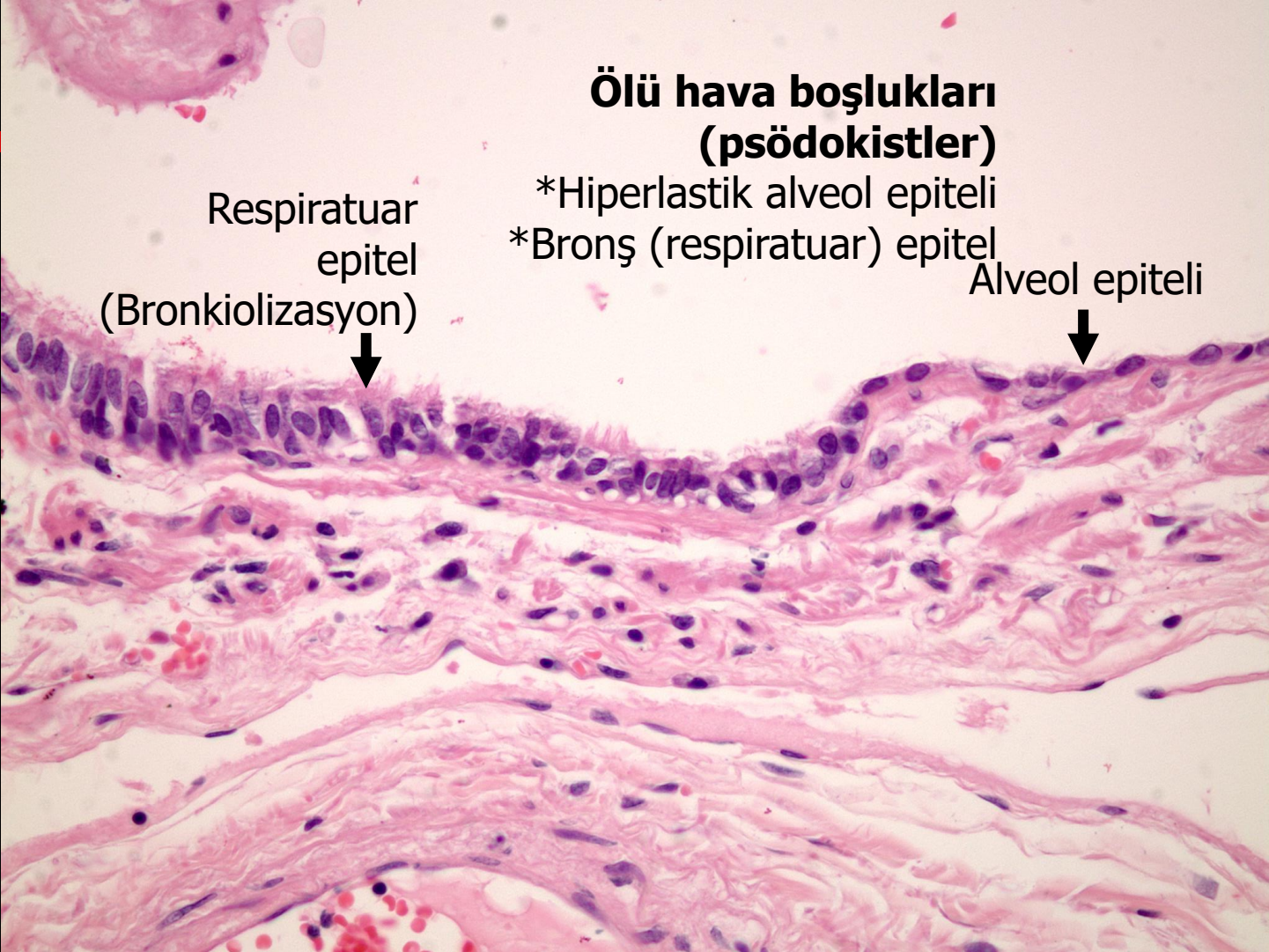**Balpeteđi
görünümü**

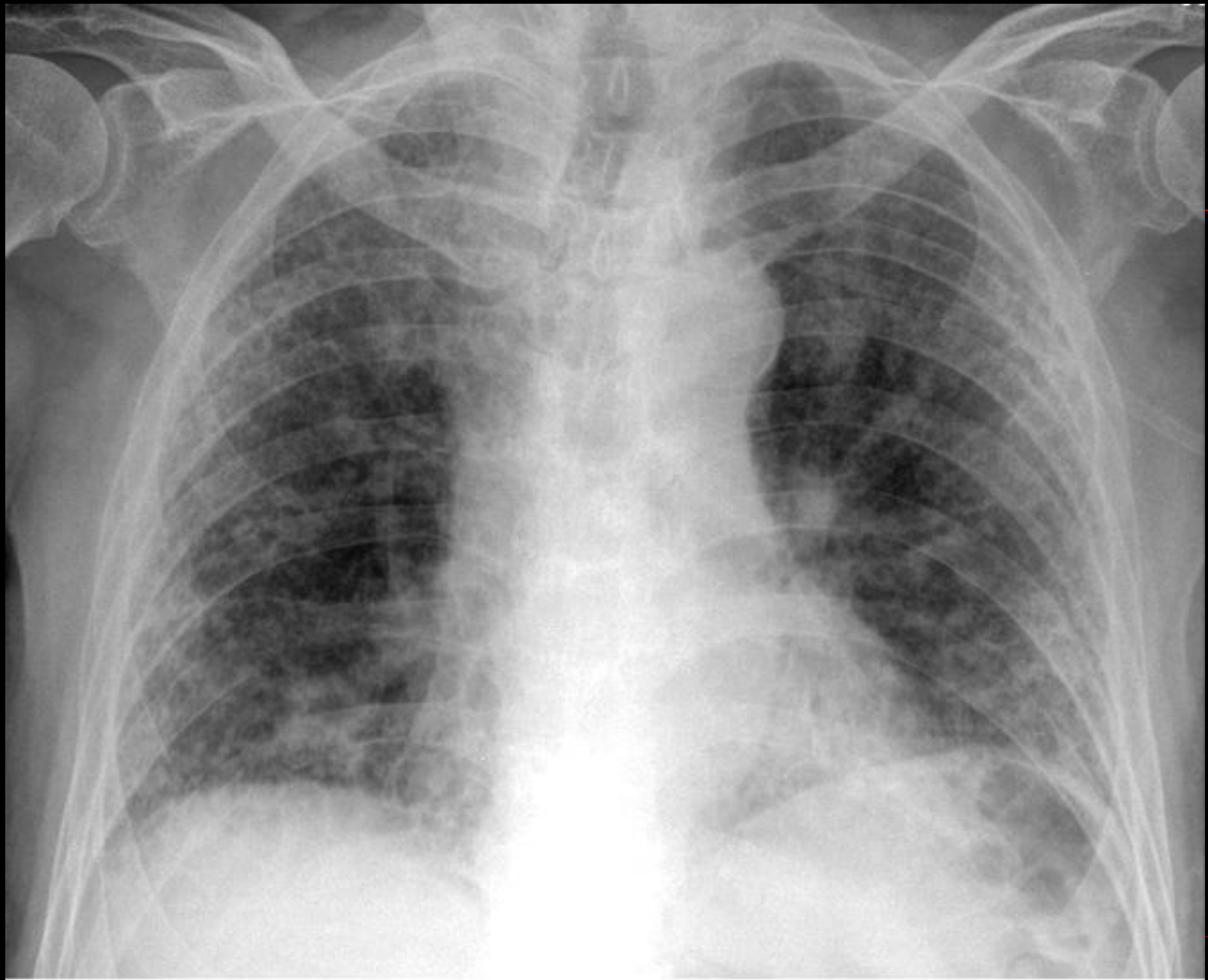
**Ölü hava boşlukları
(psödokistler)**

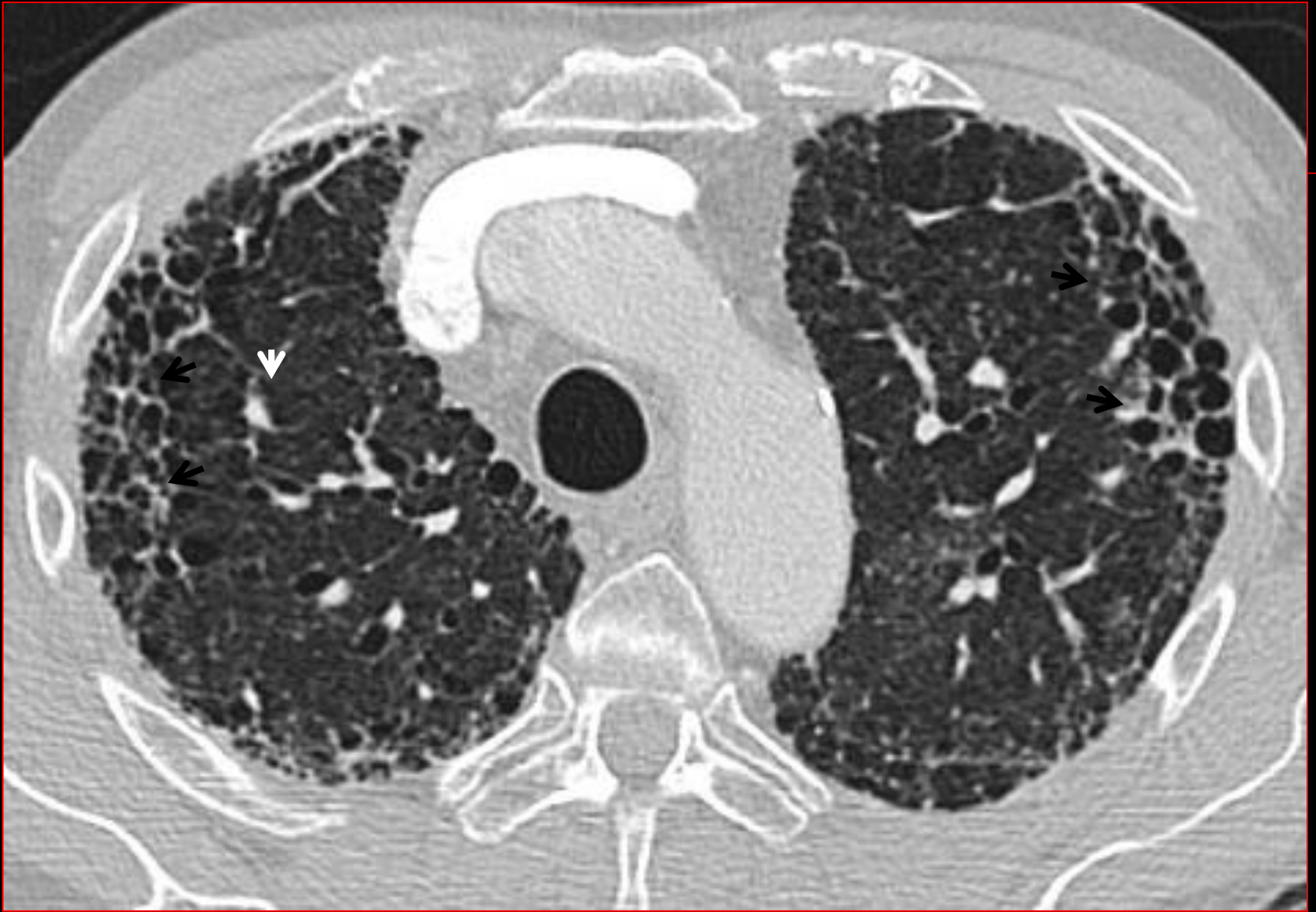
- *Hiperlastik alveol epitel
- *Bronş (respiratuar) epitel

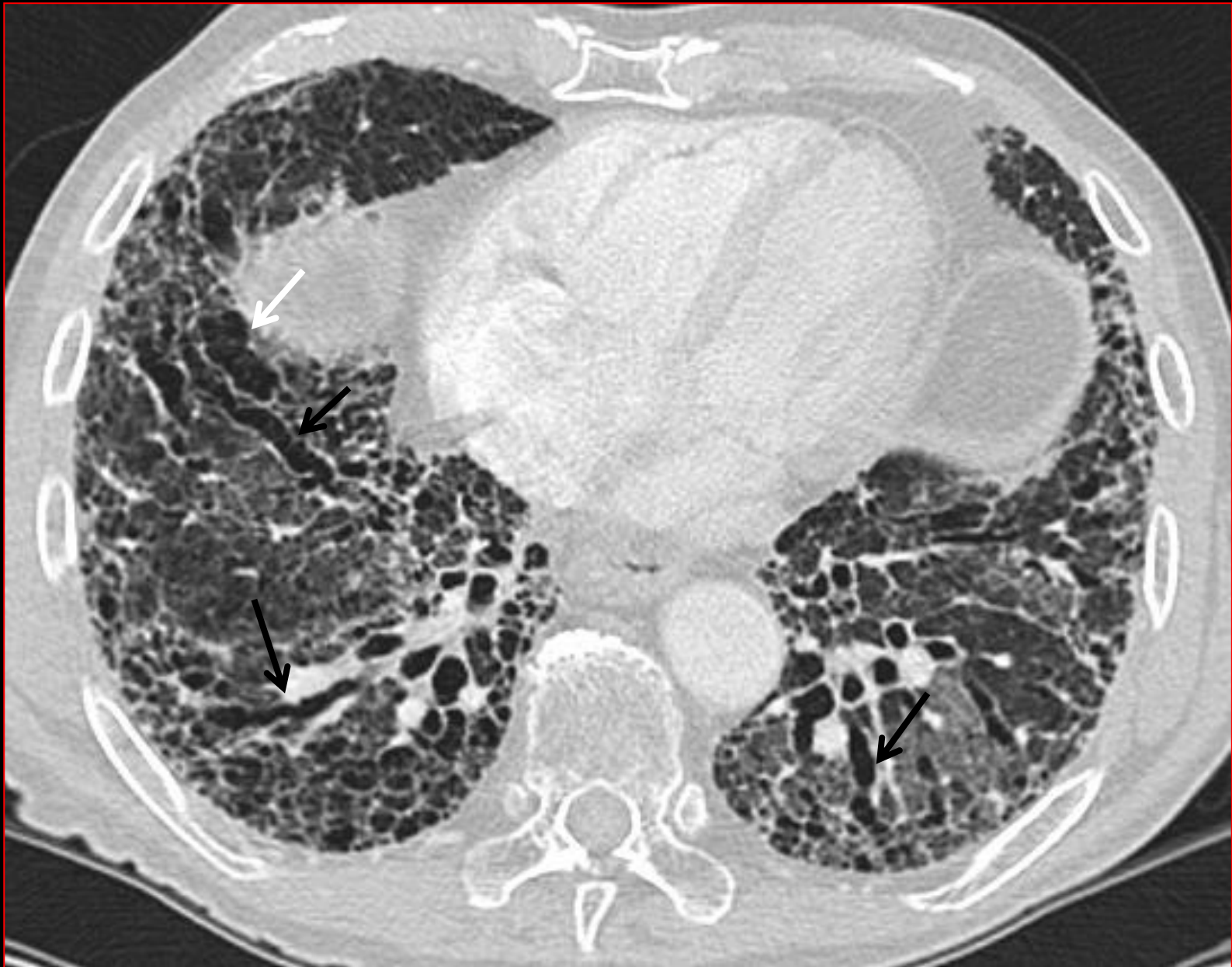Respiratuar
epitel
(Bronkiolizasyon)

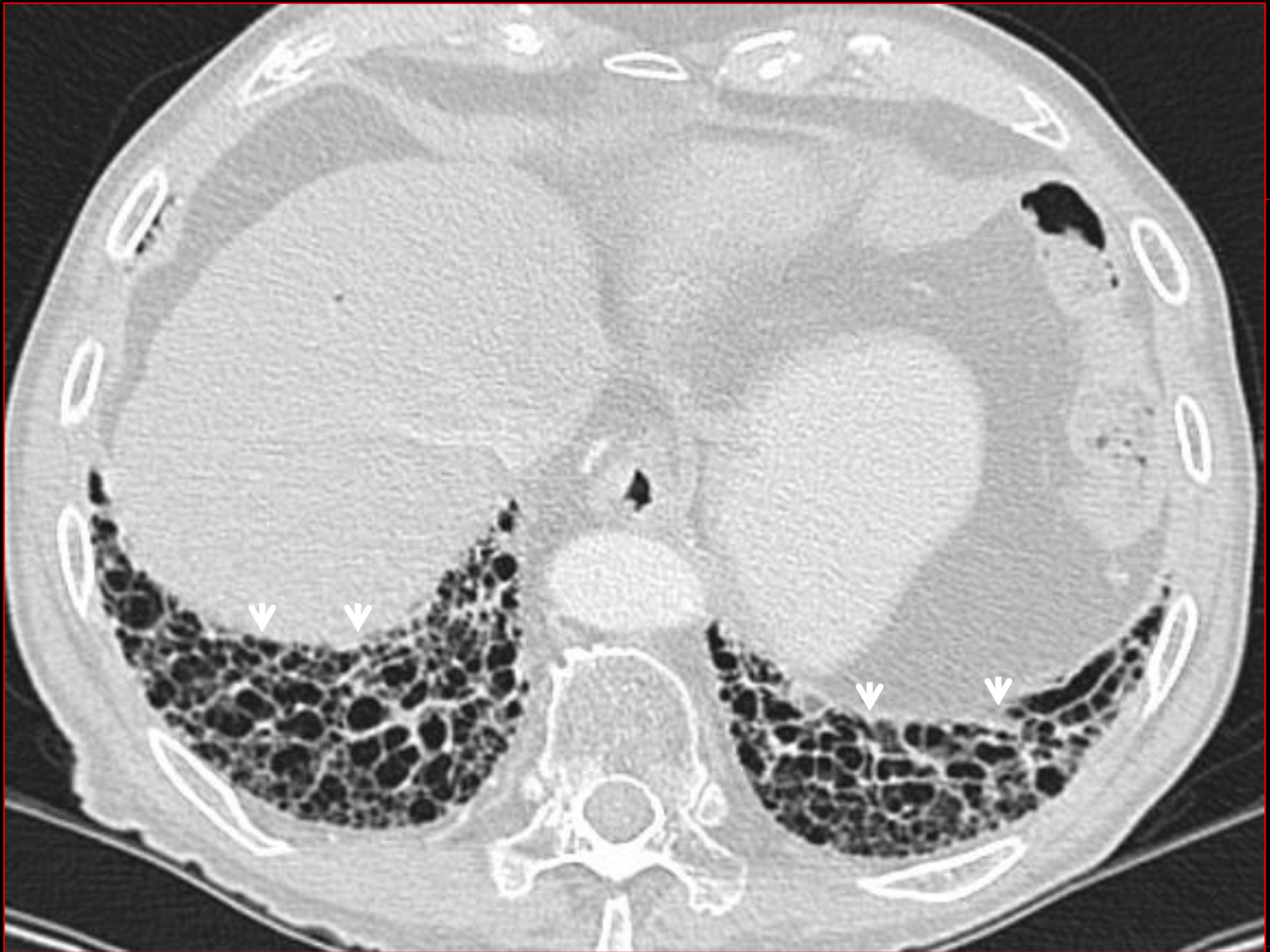
Alveol epiteli



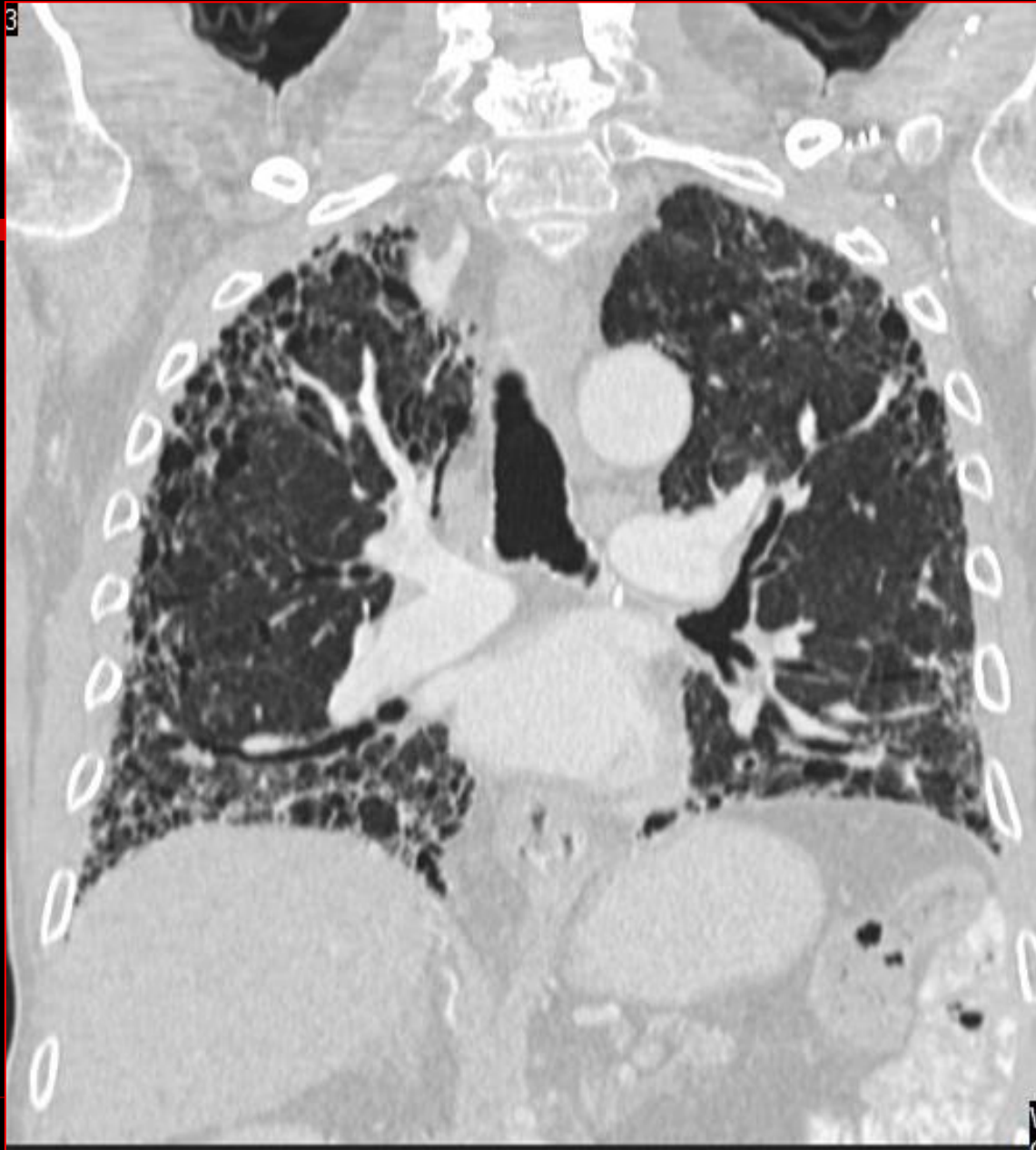


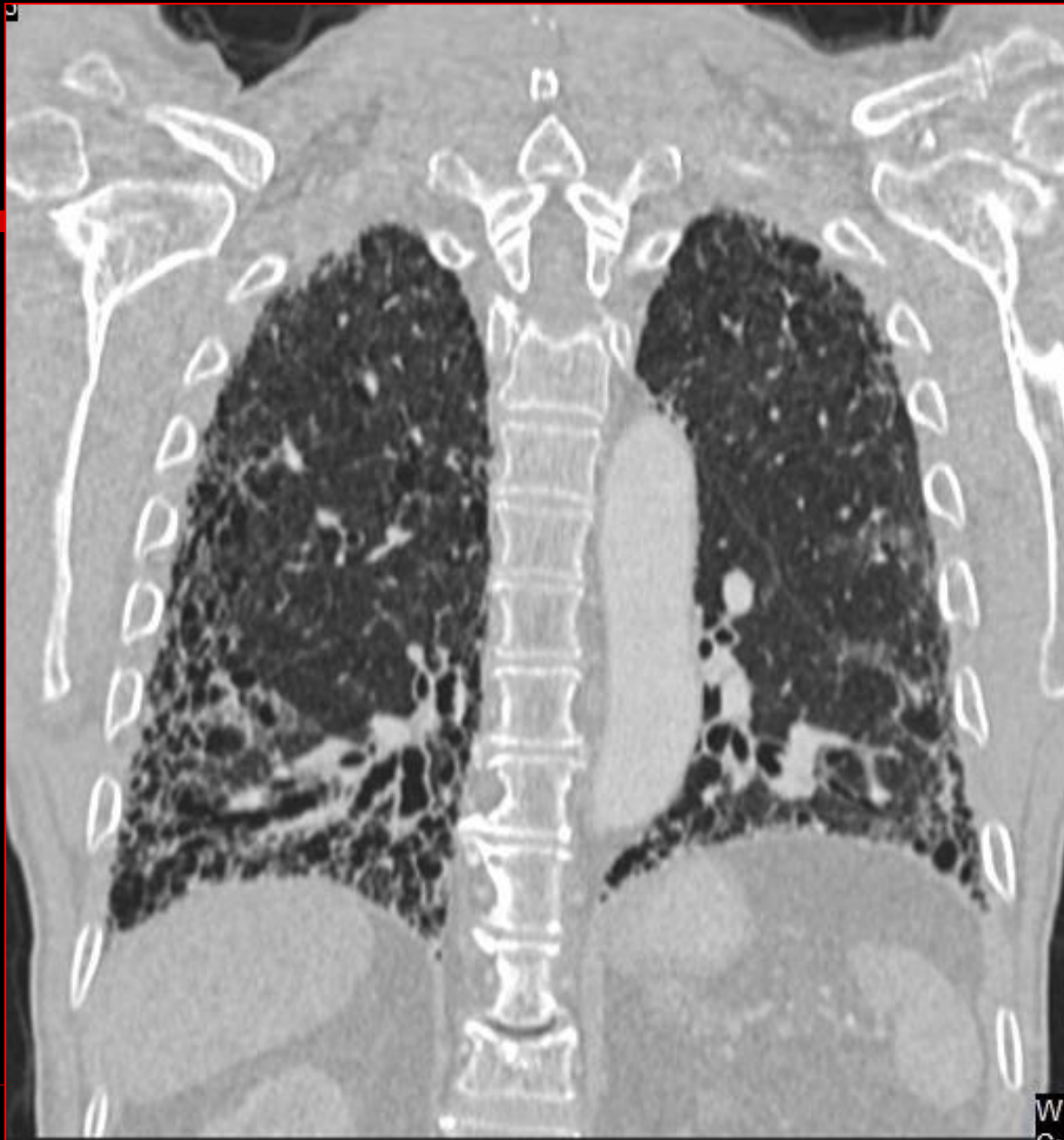


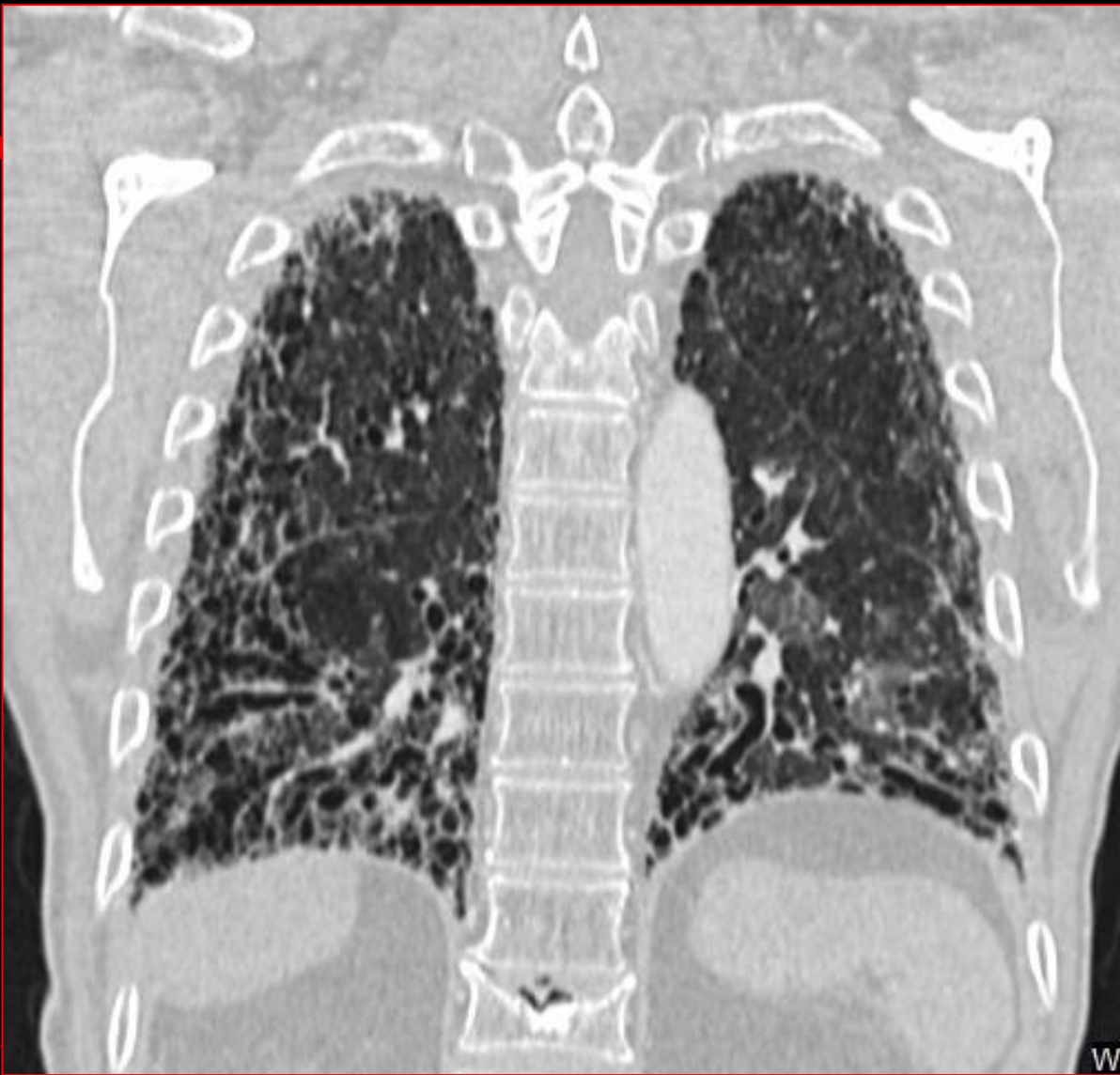

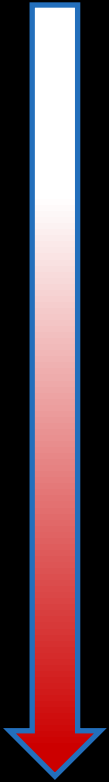
IPF







W



Bal Peteđi

Subplevral, posterior,
Alt loblarda daha
fazla

İPF (%60)

Kollajen doku hast.

Asbestoz

İlaç fibrozisi

Hipersensitivite P

Sarkoidoz (nadir)

Santral, üst lob

Sarkoidoz (sık)

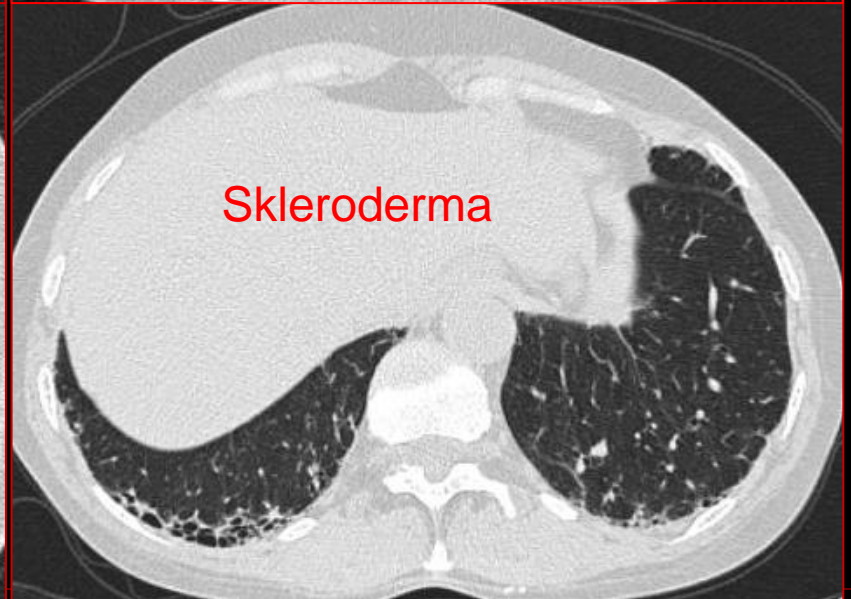
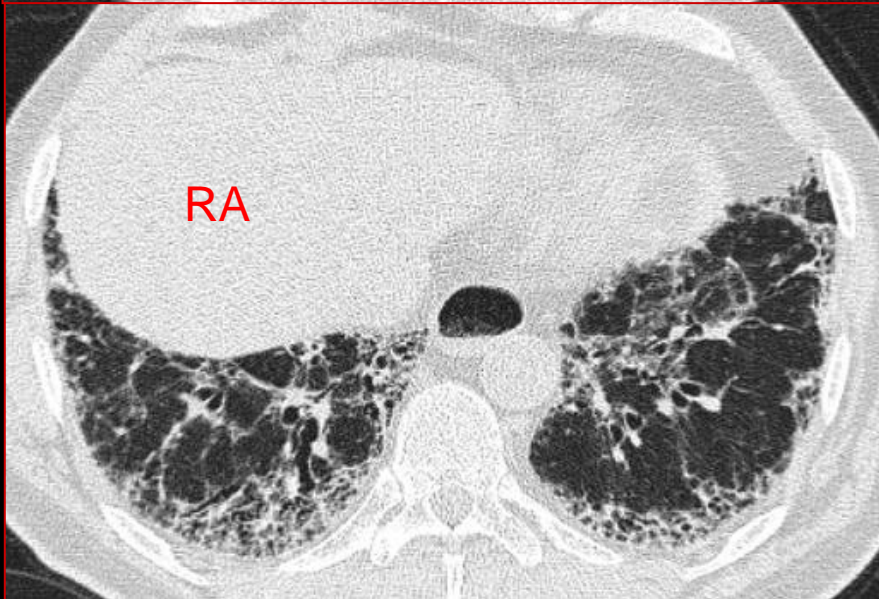
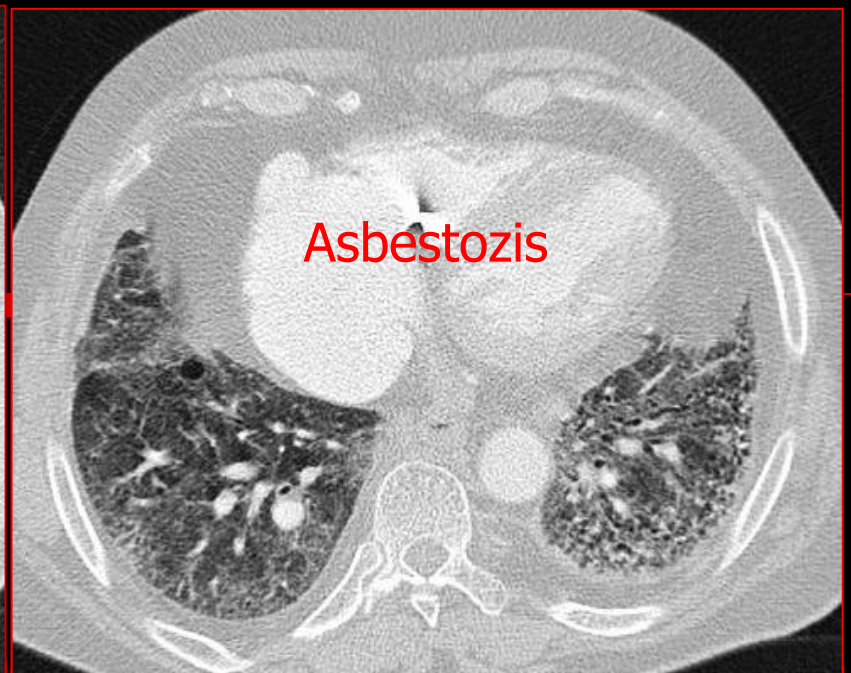
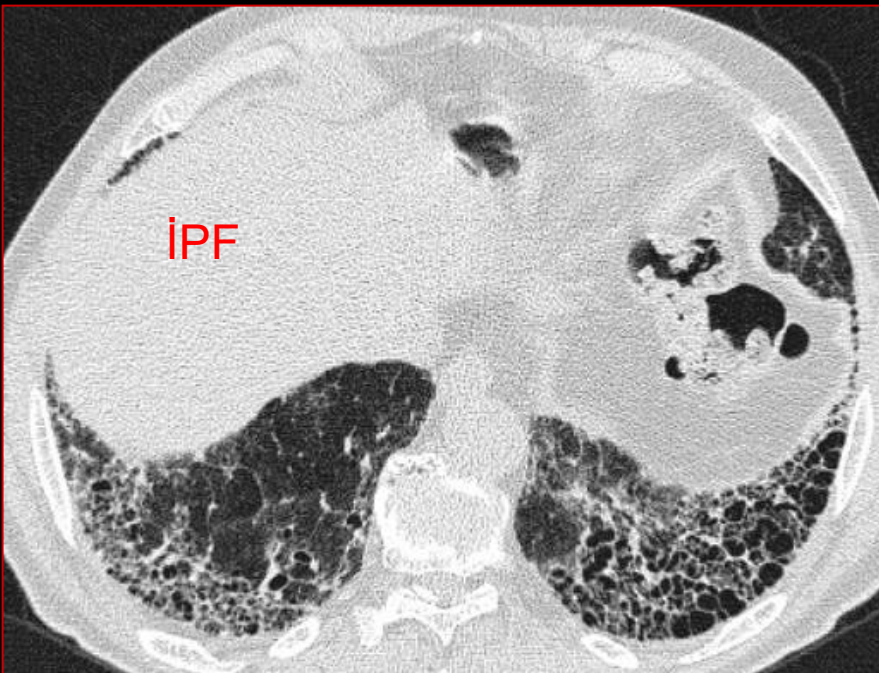
Hipersensitivite
pnömo.

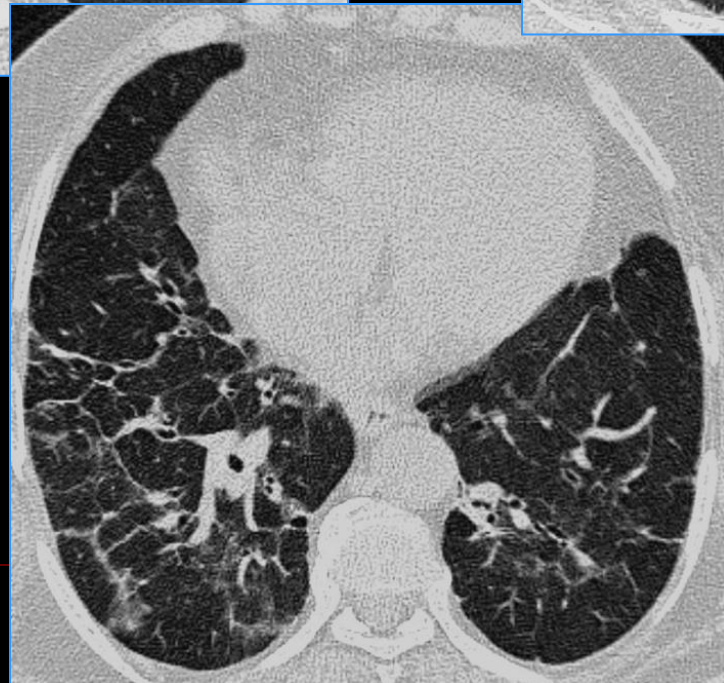
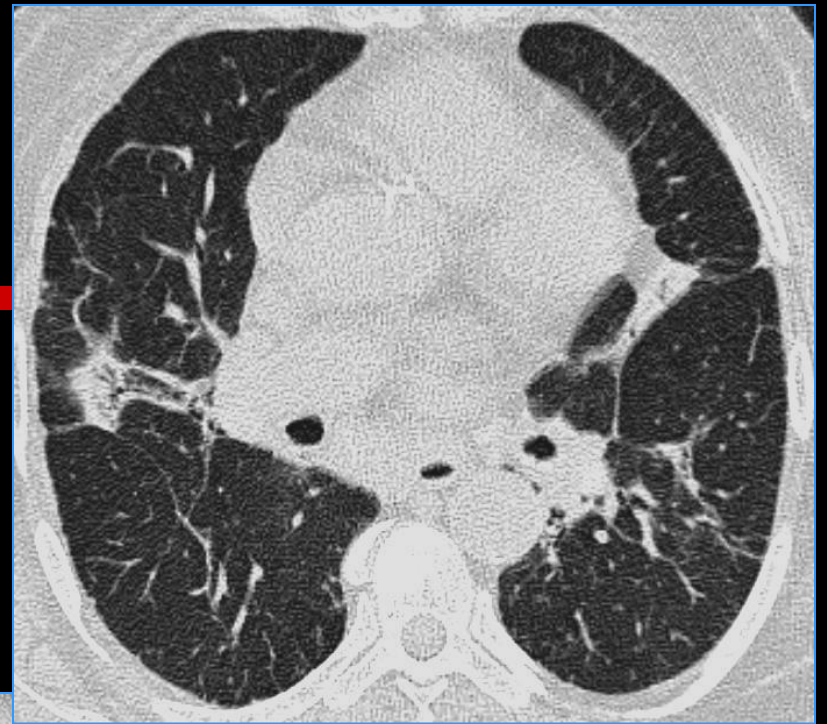
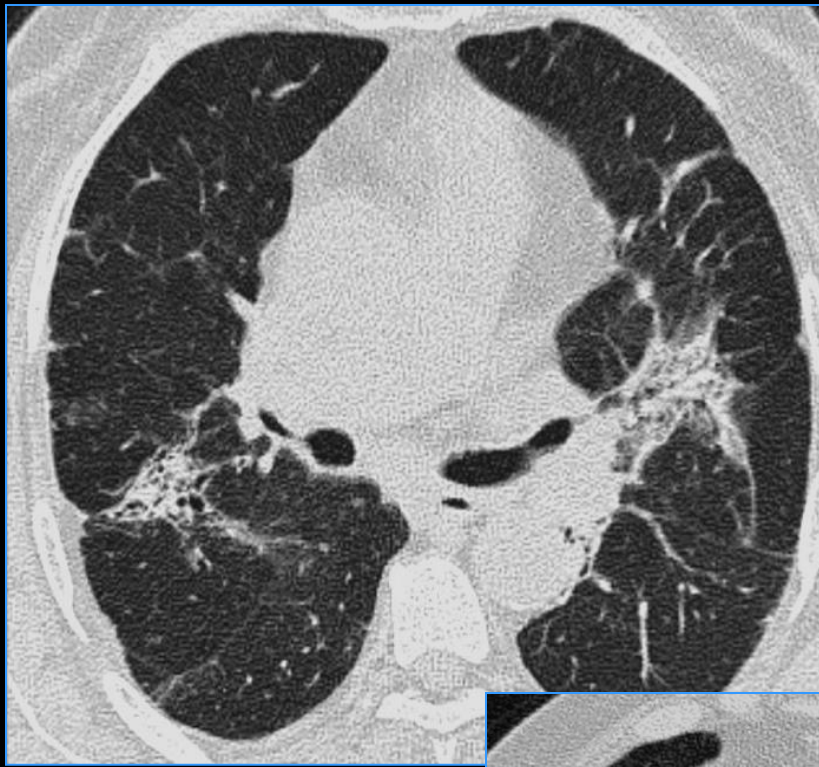
Radyasyon

Son dönem ARDS

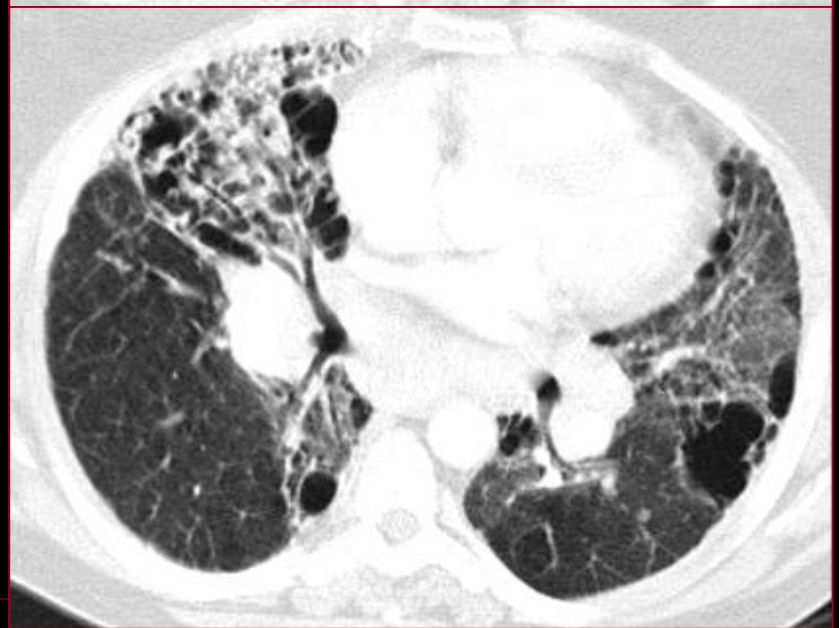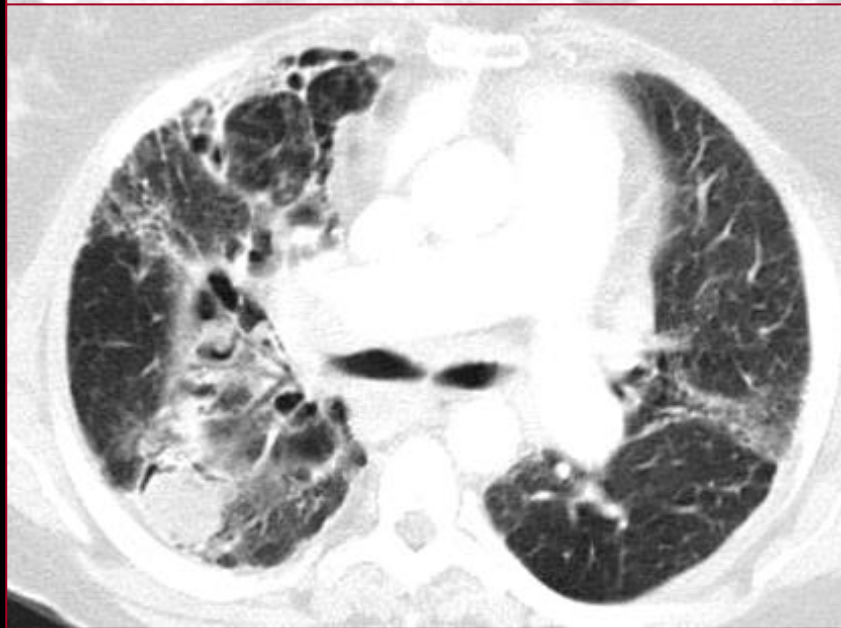
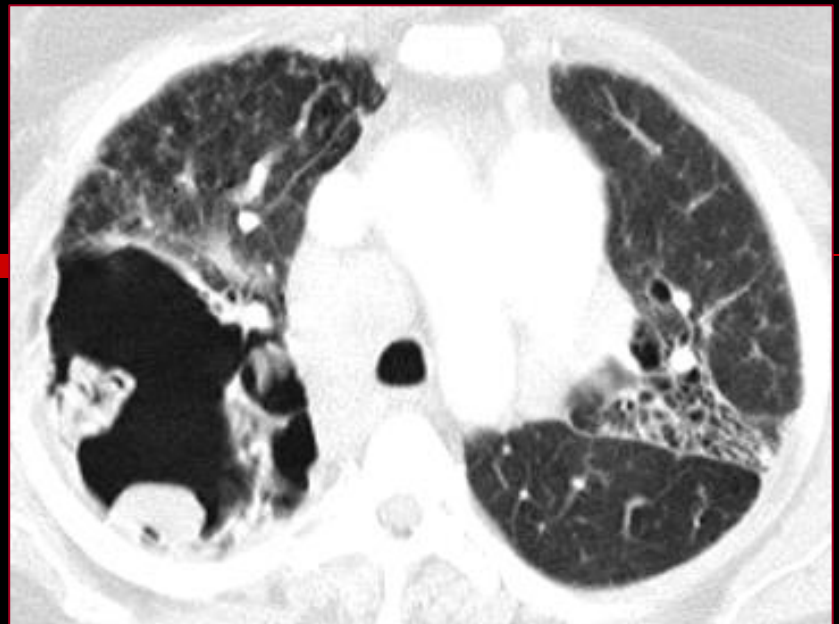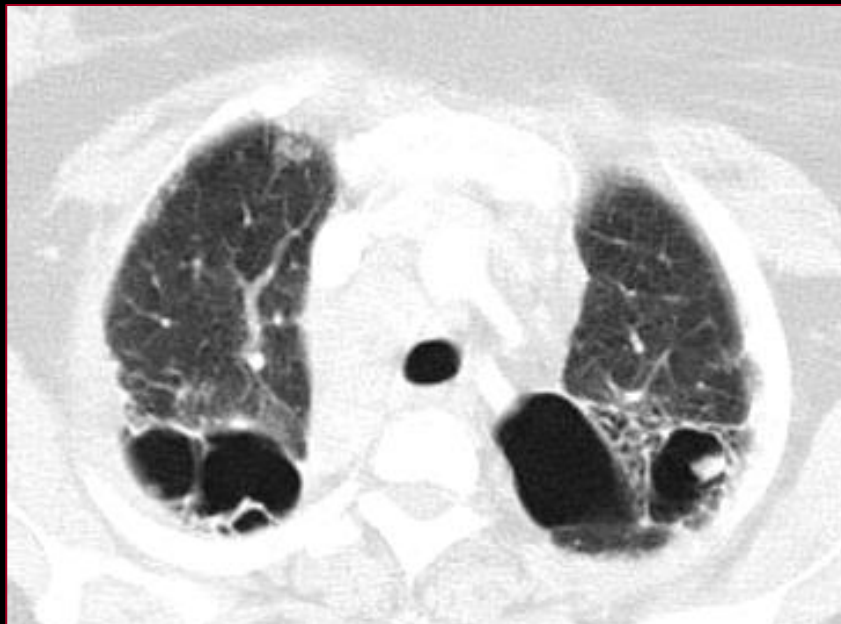Kollajen doku hast.

İlaç fibrozisi





Sarkoidoz



Diagnosis of Idiopathic Pulmonary Fibrosis

An Official ATS/ERS/JRS/ALAT Clinical Practice Guideline

Table 4. High-Resolution Computed Tomography Scanning Patterns

UIP	Probable UIP	Indeterminate for UIP	Alternative Diagnosis
Subpleural and basal predominant; distribution is often heterogeneous*	Subpleural and basal predominant; distribution is often heterogeneous	Subpleural and basal predominant	Findings suggestive of another diagnosis, including: <ul style="list-style-type: none"> • CT features: <ul style="list-style-type: none"> ◦ Cysts ◦ Marked mosaic attenuation ◦ Predominant GGO ◦ Profuse micronodules ◦ Centrilobular nodules ◦ Nodules ◦ Consolidation • Predominant distribution: <ul style="list-style-type: none"> ◦ Peribronchovascular ◦ Perilymphatic ◦ Upper or mid-lung • Other: <ul style="list-style-type: none"> ◦ Pleural plaques (consider asbestosis) ◦ Dilated esophagus (consider CTD) ◦ Distal clavicular erosions (consider RA) ◦ Extensive lymph node enlargement (consider other etiologies) ◦ Pleural effusions, pleural thickening (consider CTD/drugs)
Honeycombing with or without peripheral traction bronchiectasis or bronchiolectasis†	Reticular pattern with peripheral traction bronchiectasis or bronchiolectasis May have mild GGO	Subtle reticulation; may have mild GGO or distortion ("early UIP pattern") CT features and/or distribution of lung fibrosis that do not suggest any specific etiology ("truly indeterminate")	
OİP paterni	Olası OİP paterni	OİP için belirsiz	Alternatif tanı

OİP paterni için YÇBT kriterleri

Güvelinir: > %90

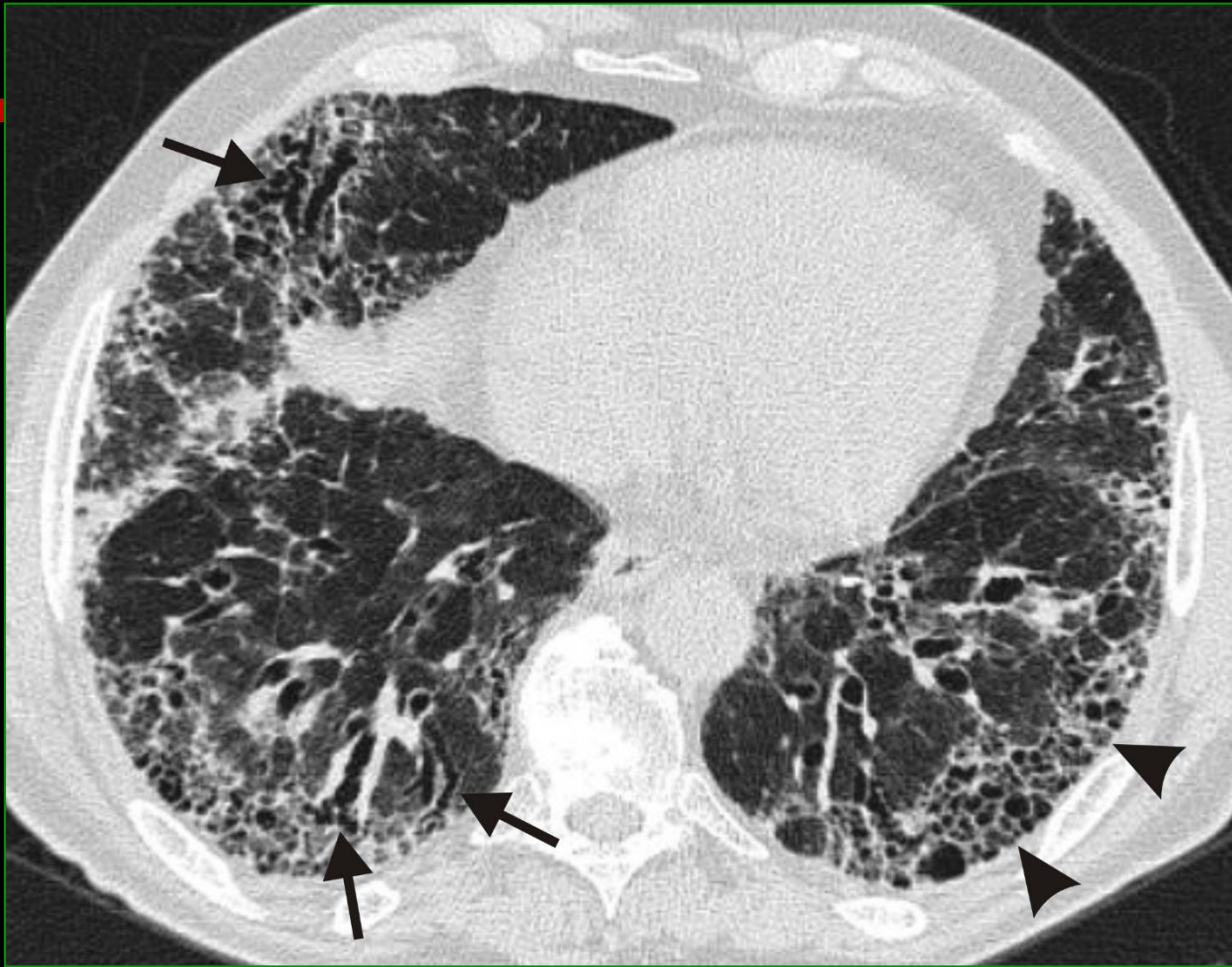
BT bulguları:

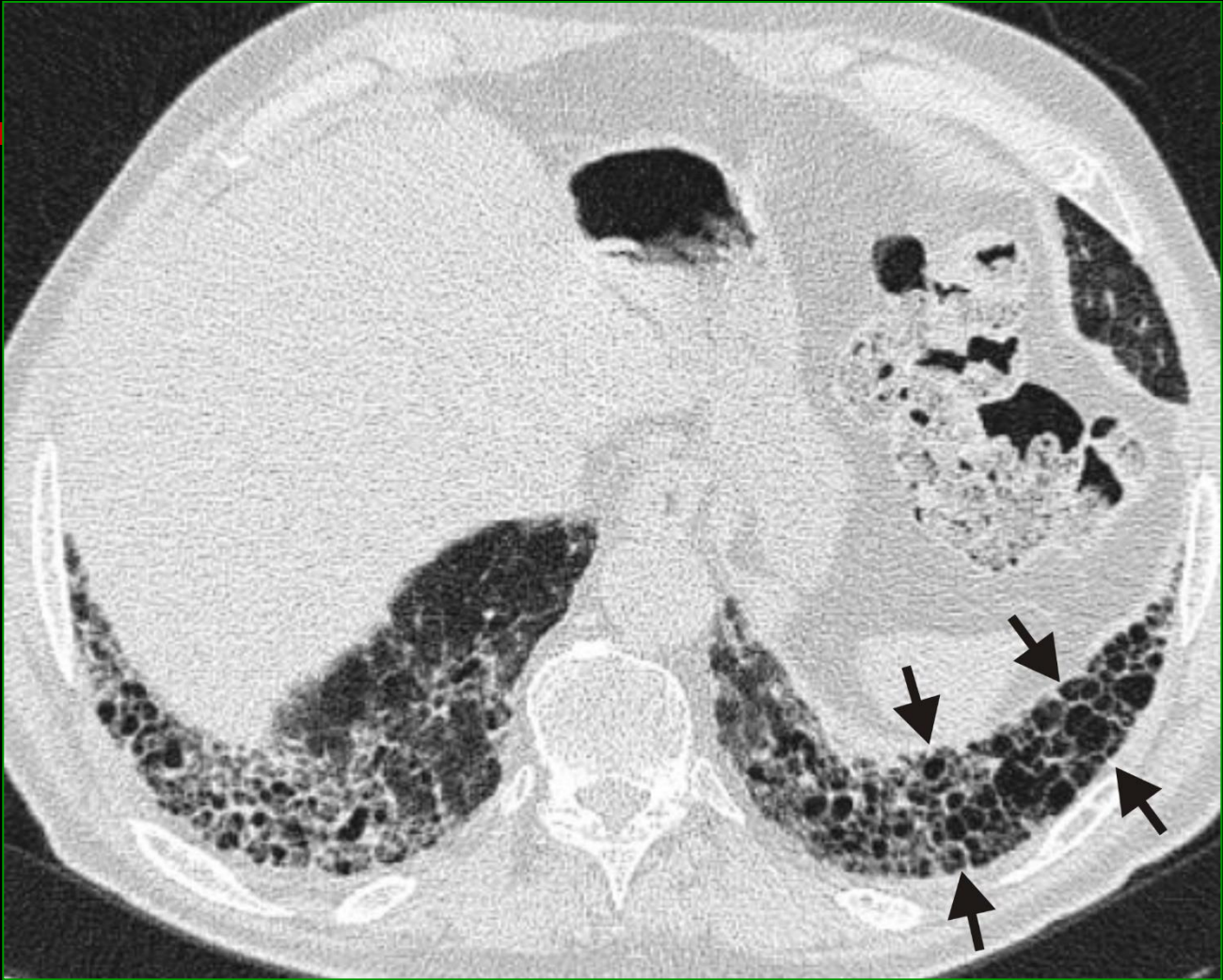
- Bal peteği + traksiyon bronşektazileri- bronşiolektazileri
- İnterlobüler septalarda düzensiz kalınlaşmalar
- Az miktarda süperpoze buzlu cam opasiteleri
- Pulmoner ossifikasyonlar olabilir

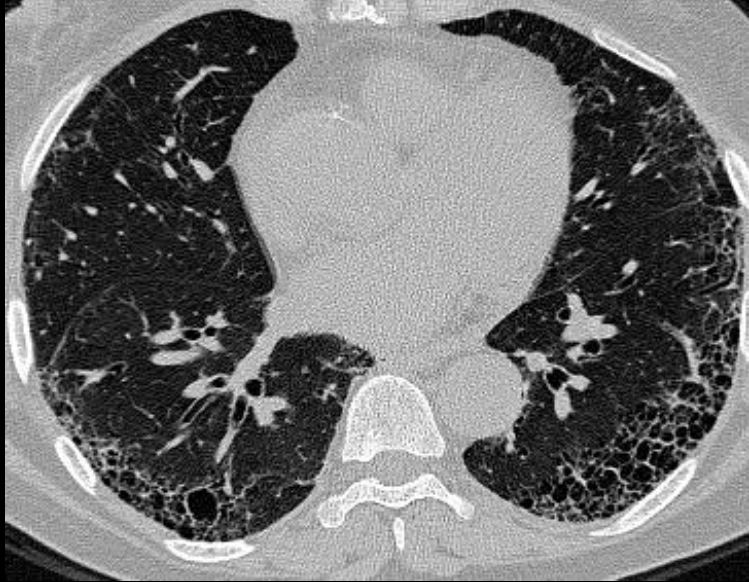
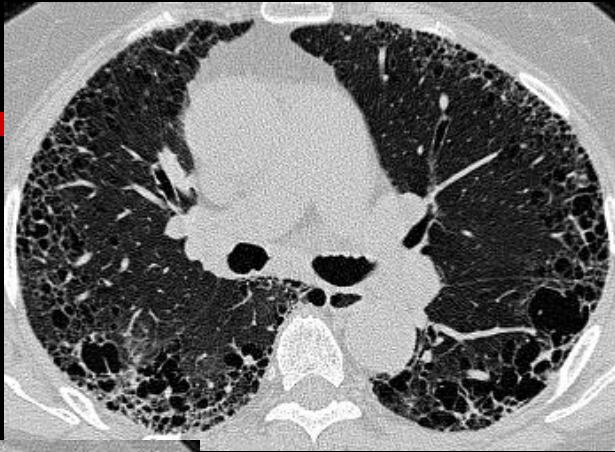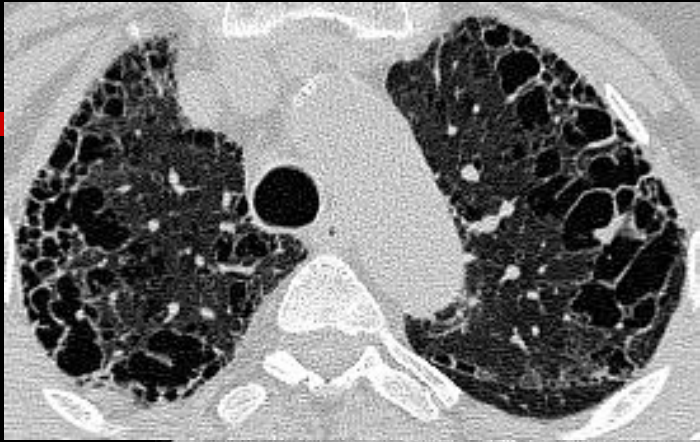Dağılım:

- Subplevral, bazal ağırlıklı, genellikle heterojen dağılım.
- Bazen diffüz, simetrik olabilir

9

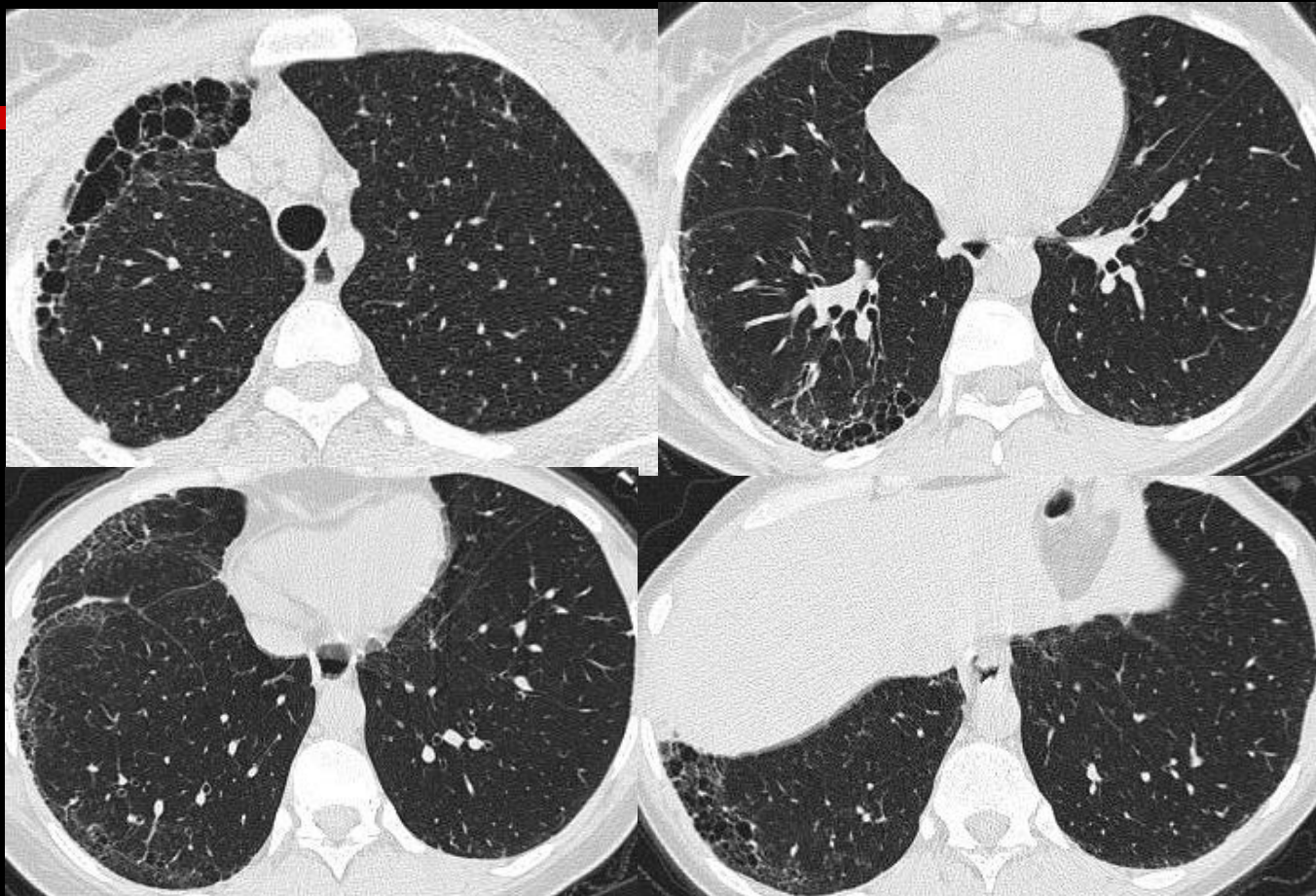






Patoloji: OİP

Pat: OIP



Olası OİP paterni için YÇBT kriterleri

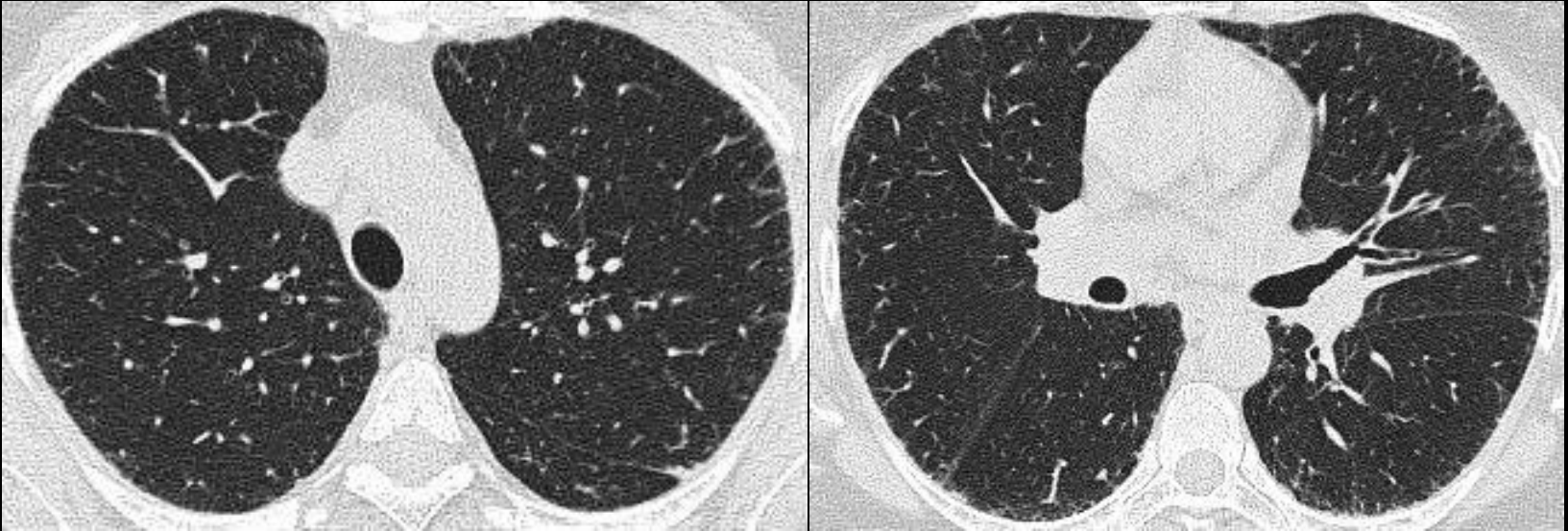
Yüksek güvelinirlilik: % 70- 89

BT Bulguları:

- Retiküler patern + periferik traksiyon bronşektazileri-bronşiolektazileri
- Hafif buzlu cam opasiteleri olabilir
- Subplevral korunma yok

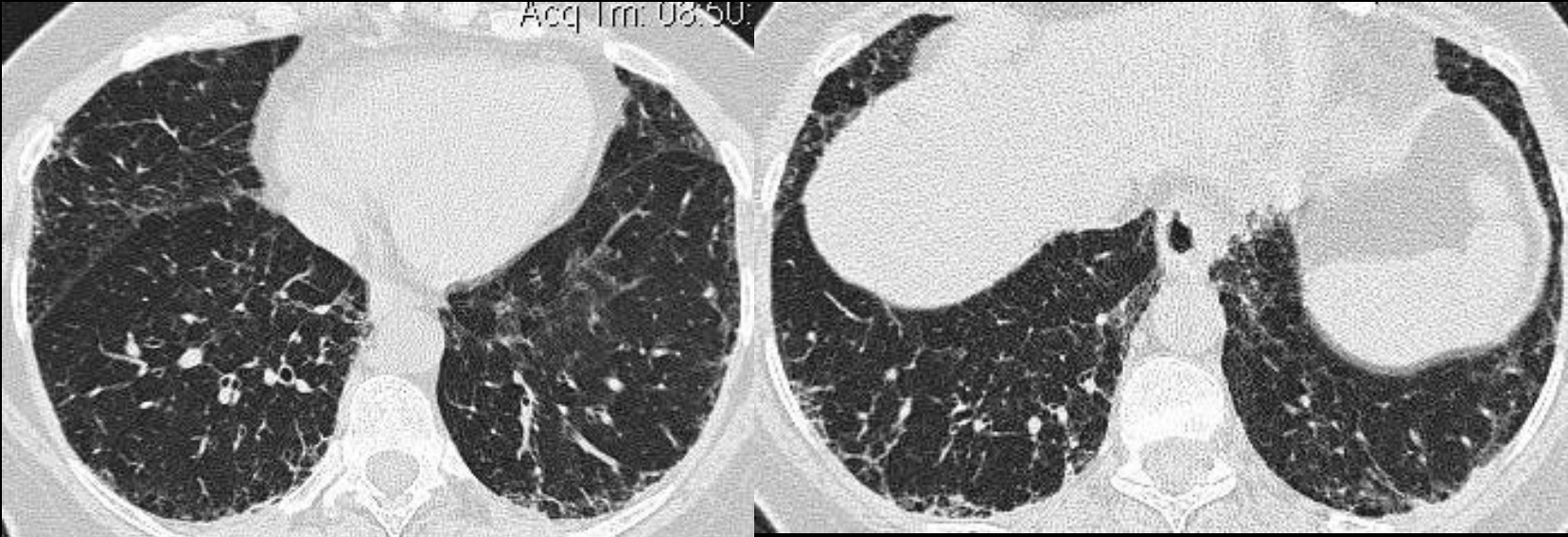
Dağılım:

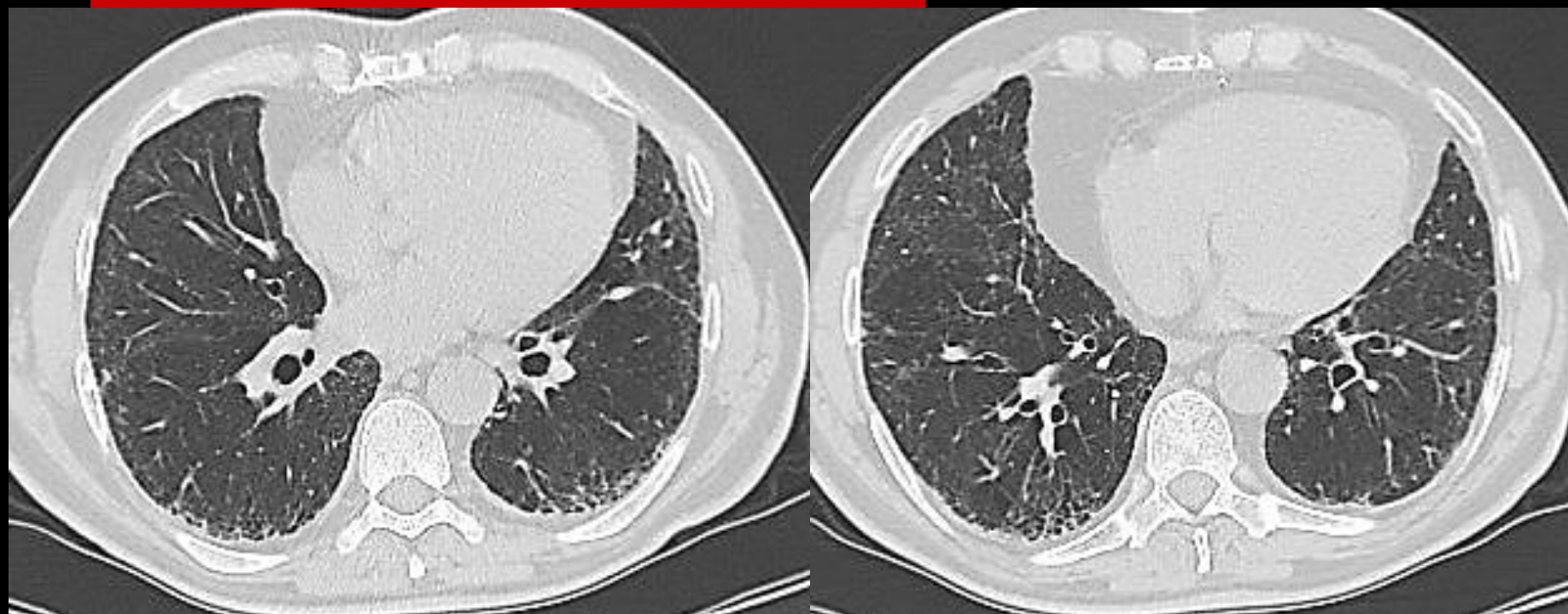- Subplevral, bazal ağırlıklı,
- Genellikle heterojen dağılım (aralarda normal alanlar bulunur)



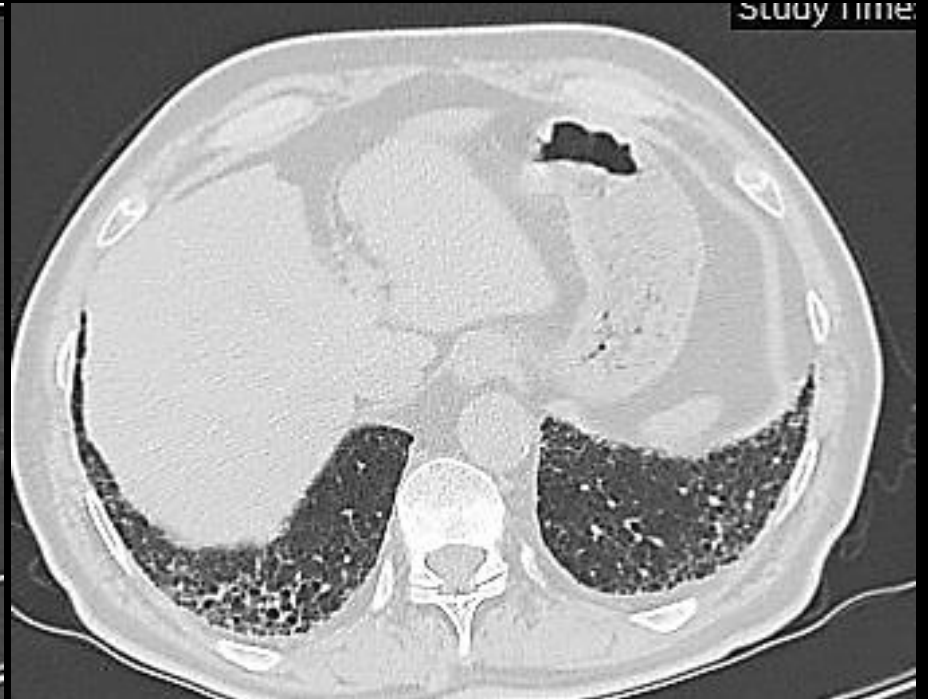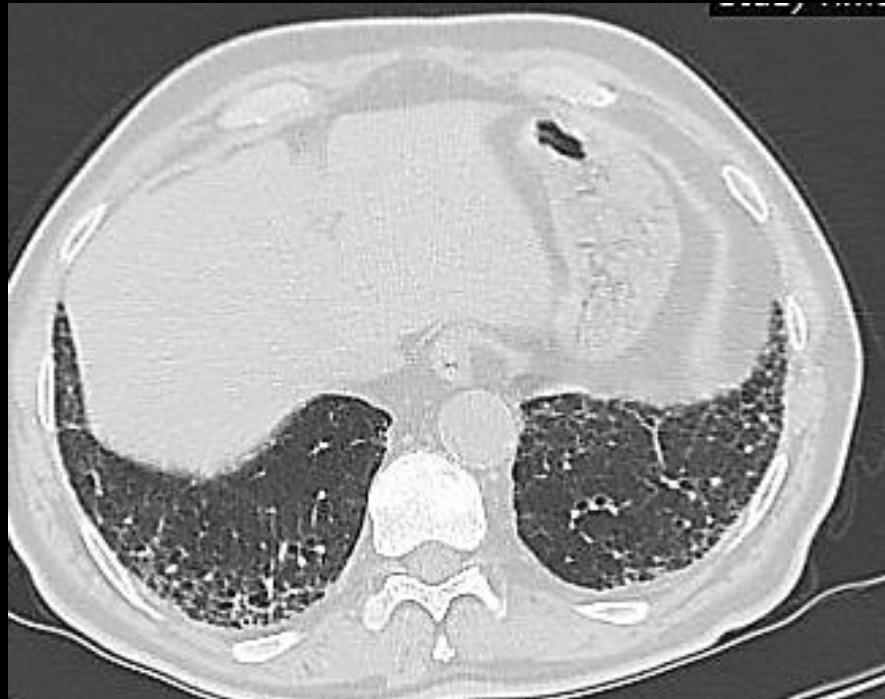Olası OİP

Pat: OİP

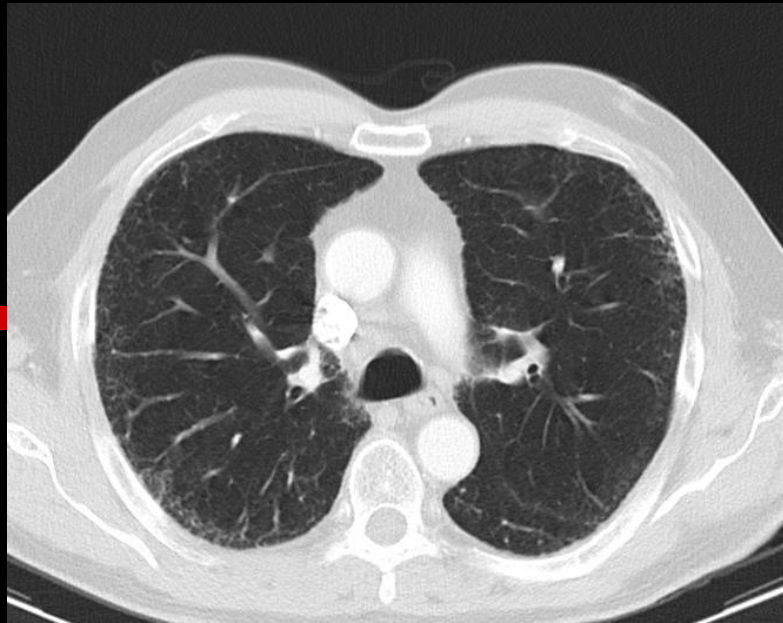




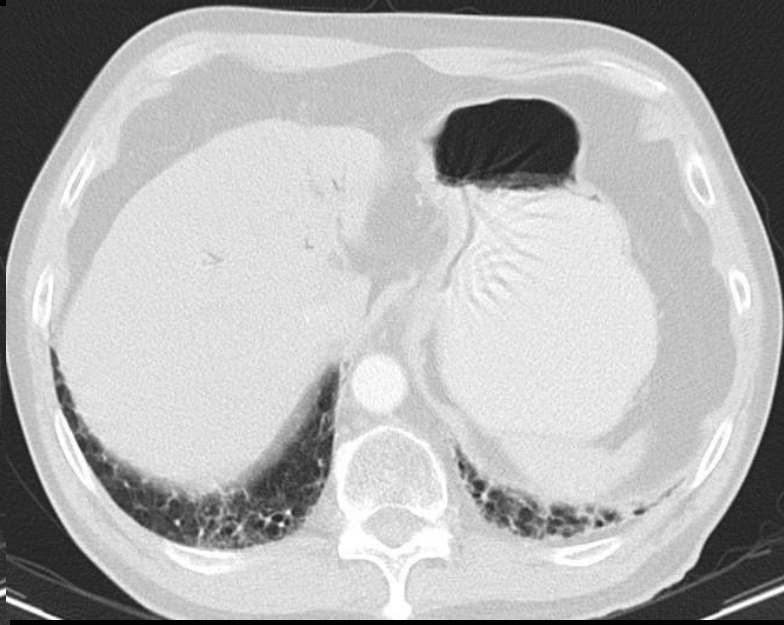
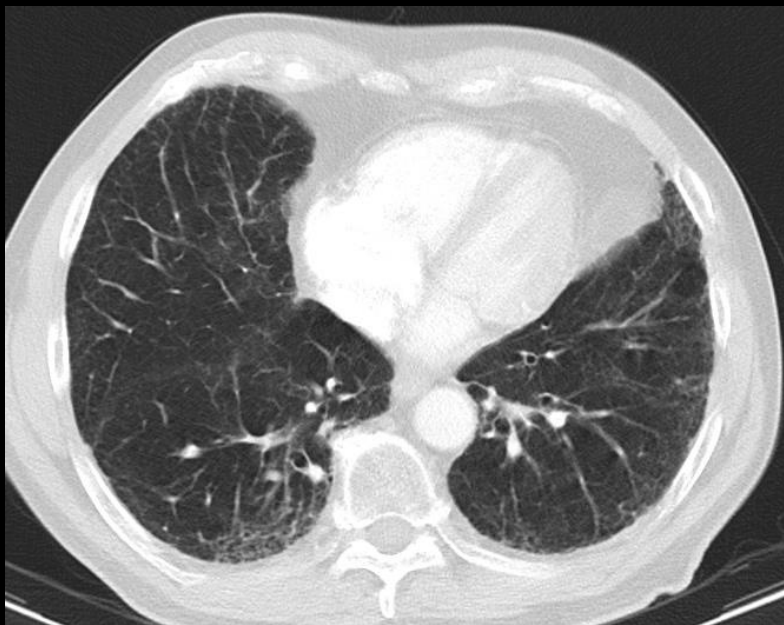
Olası OİP paterni



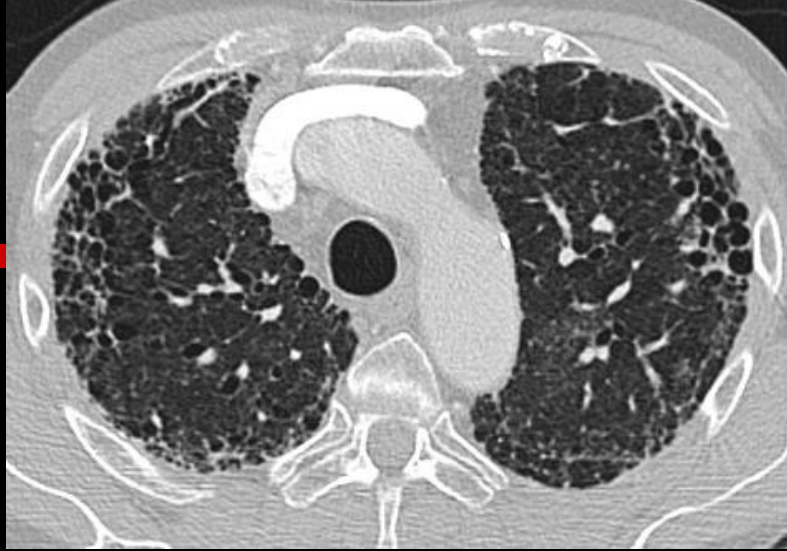Study time:



**Olası OİP
paterni**

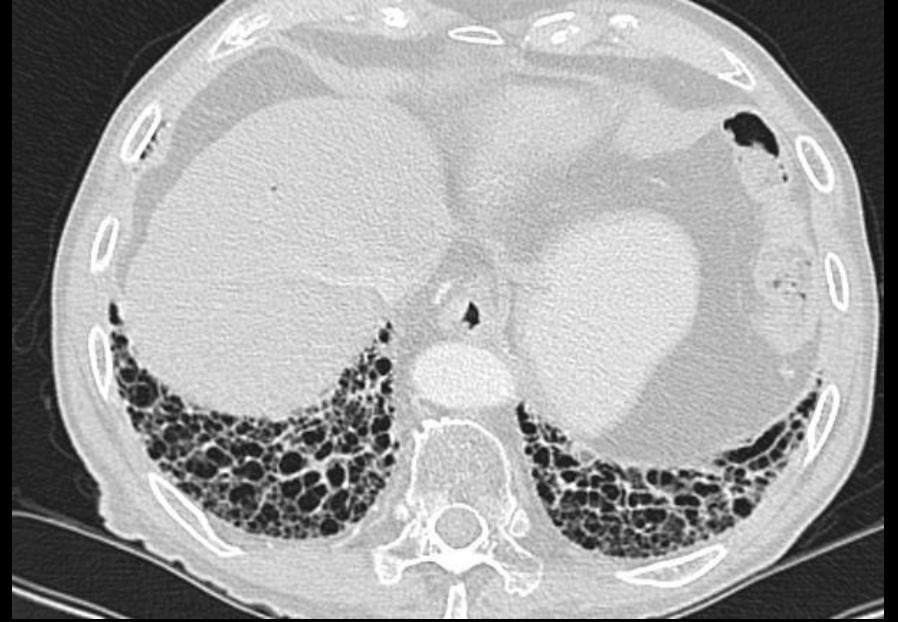
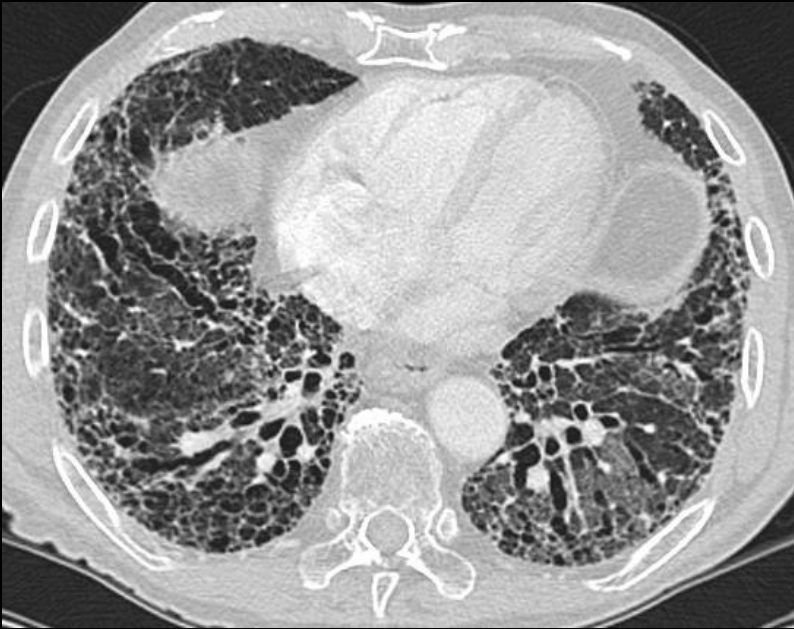

5 yıl
sonra



OİP Paterni

**Klinik tanı:
İPF**



OİP için belirsiz*

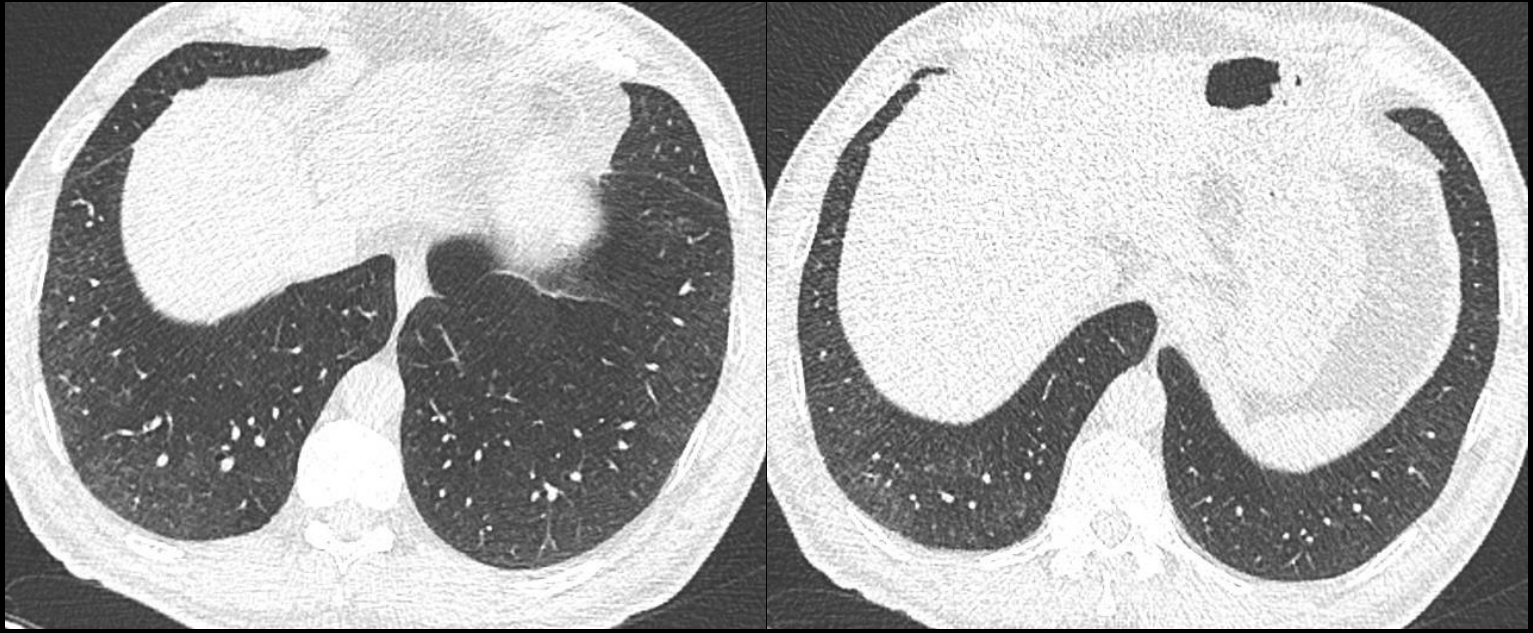
Düşük güvenirlilik: % 51-69

BT bulgusu:

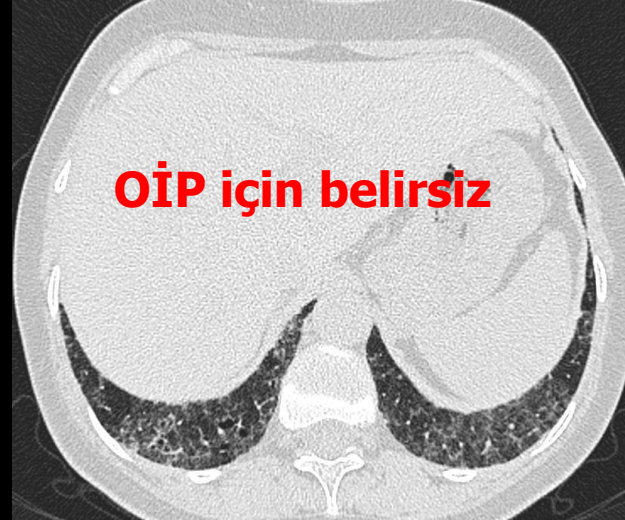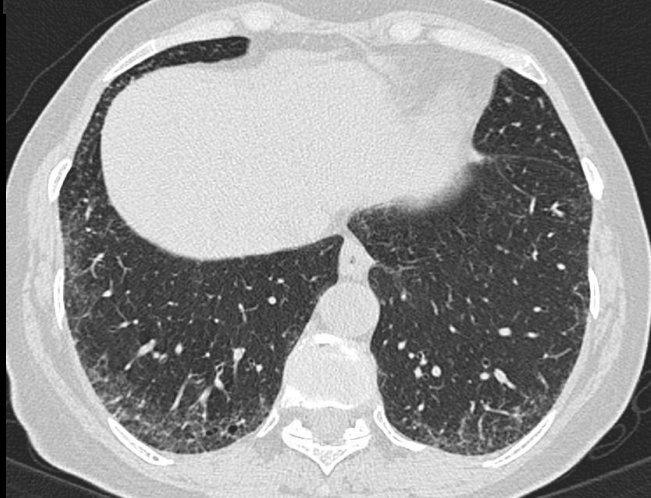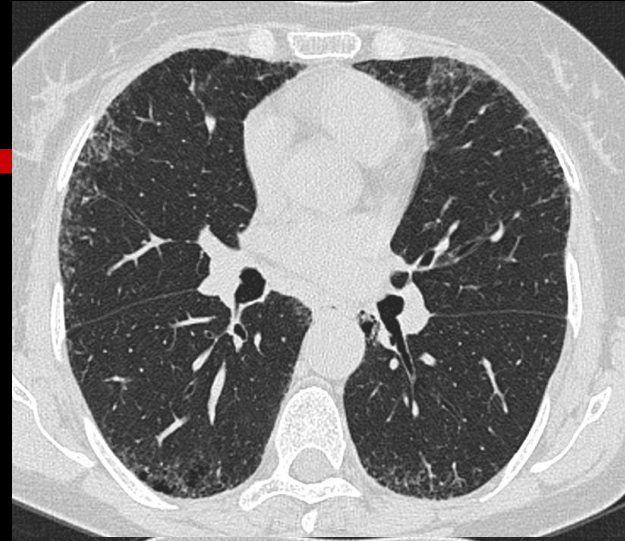
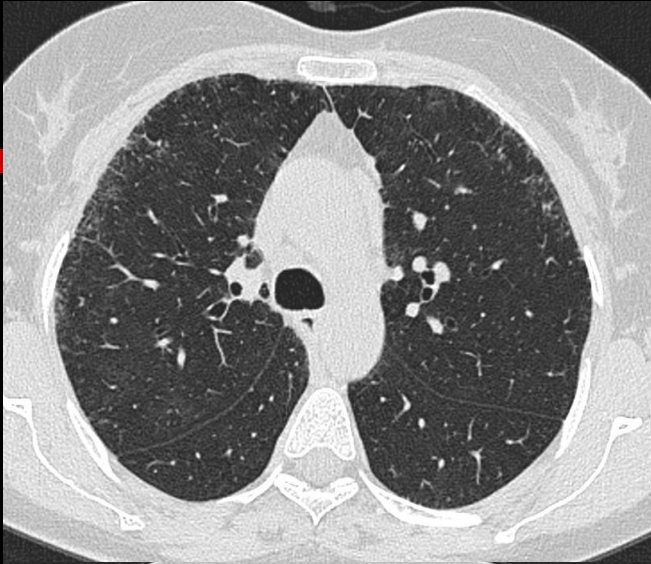
- Spesifik bir etyolojiyi işaret etmeyen fibrozis bulguları

Dağılım:

- Subplevral ağırlık olmadan diffüz dağılım



OİP için belirsiz



OİP için belirsiz

Alternatif Tanı

(OİP paterni ile uyumsuz bulgular)

Düşük veya çok düşük güvenirlilik:

≤ %50

BT özellikleri

- Kistler
- Belirgin mozaik perfüzyon
- Ağırlıklı buzlu cam dansiteleri
- Yaygın mikronodüler
- Sentrilobüler nodüller
- Nodüller
- Konsolidasyon

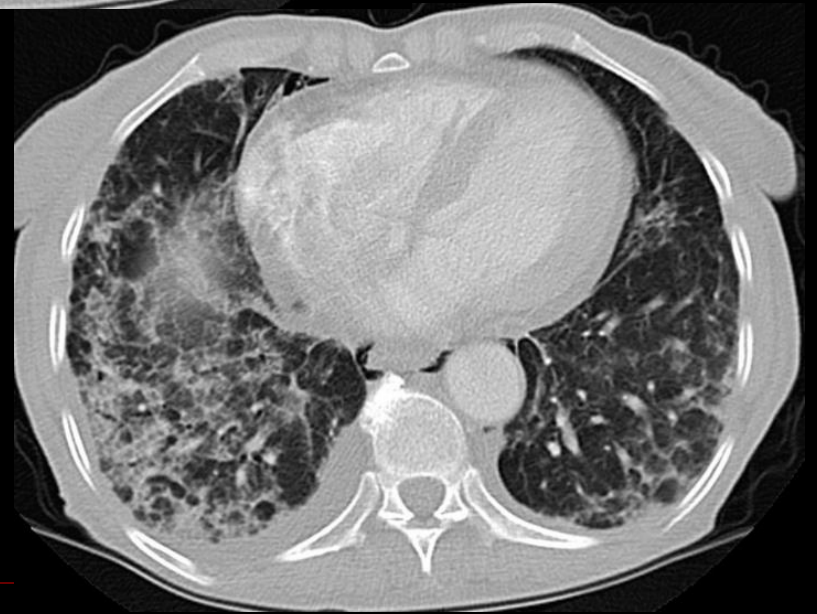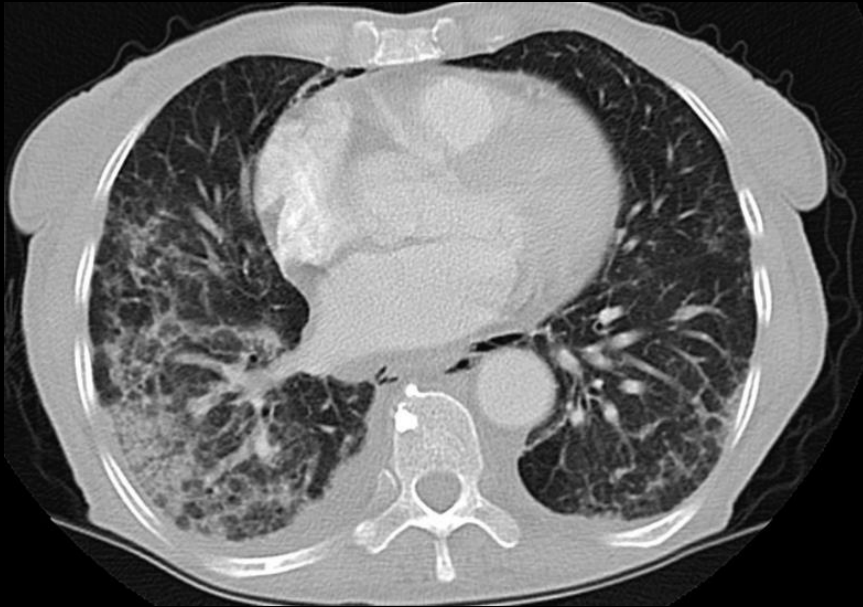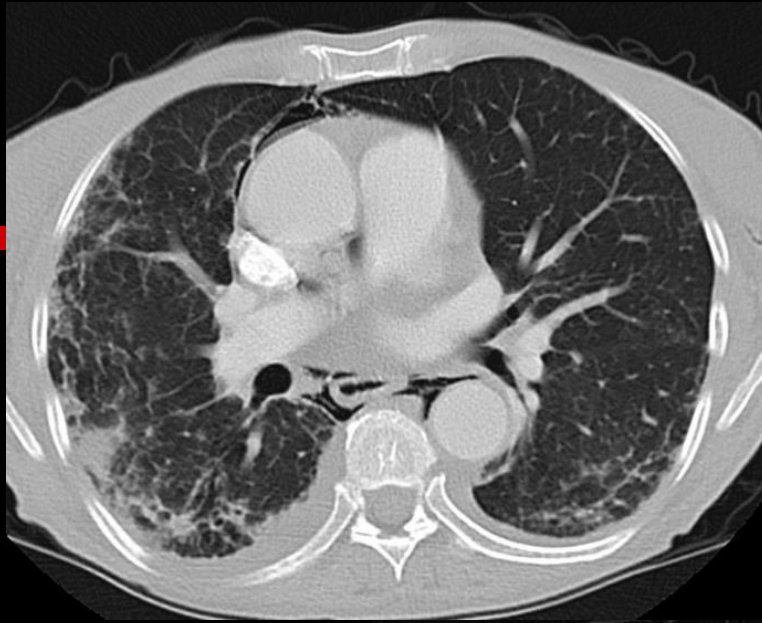
Dağılım

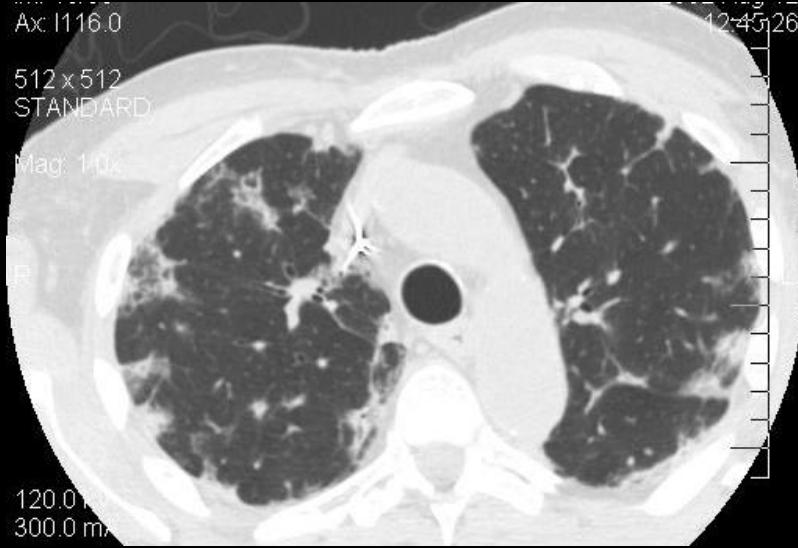
- Peribronkovasküler
- Perilenfatik
- Üst veya orta- zonlar

Diğer

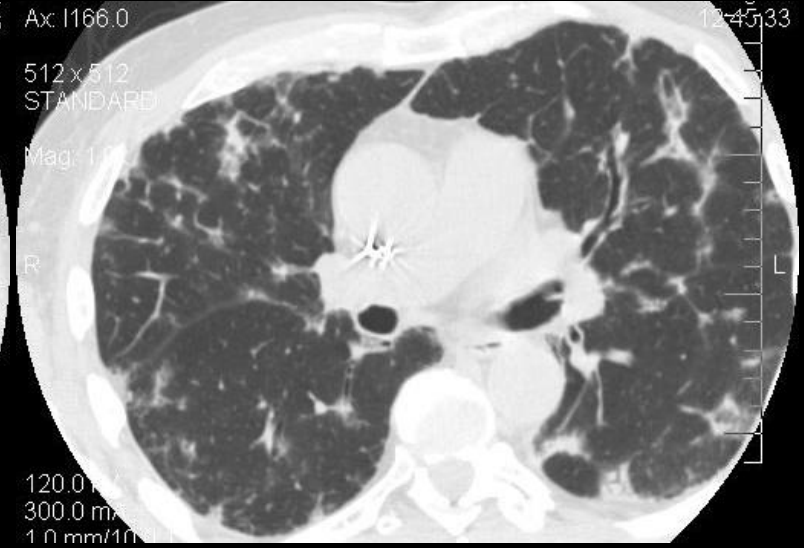- Plevral plaklar (asbestozis)
 - Dilate özefagus (kollajen doku h.)
 - Distal klaviküler erozyon
 - Yaygın LAP'ler
 - Plevral efüzyon- kalınlaşma (kollajen doku h./ ilaç)
-

**Kemoterapi
etkisi**



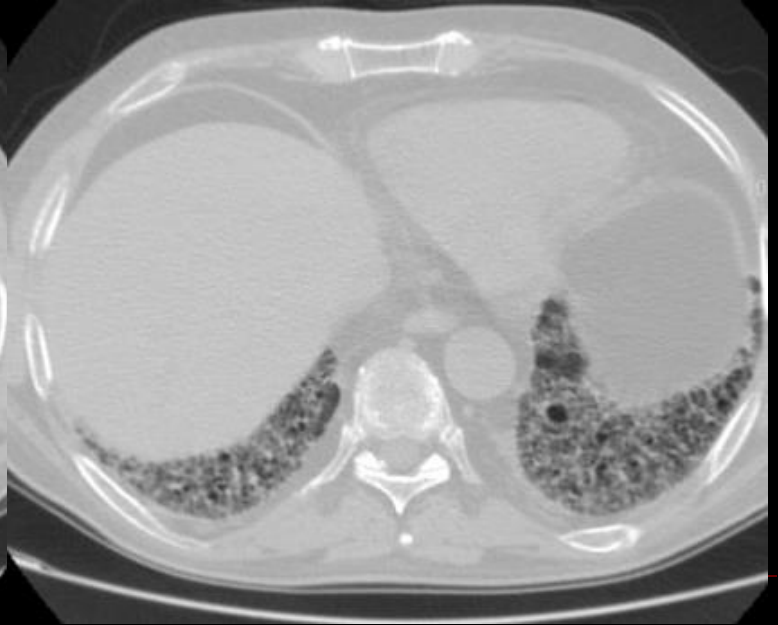
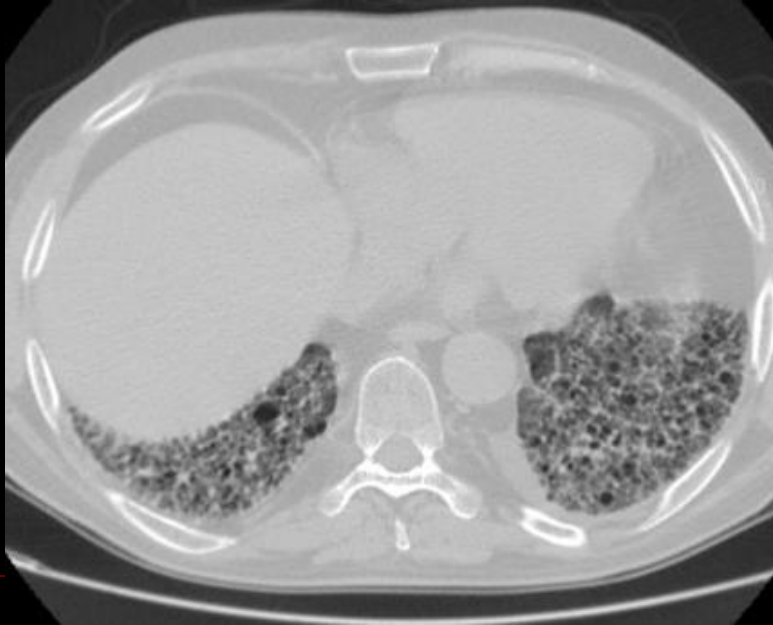
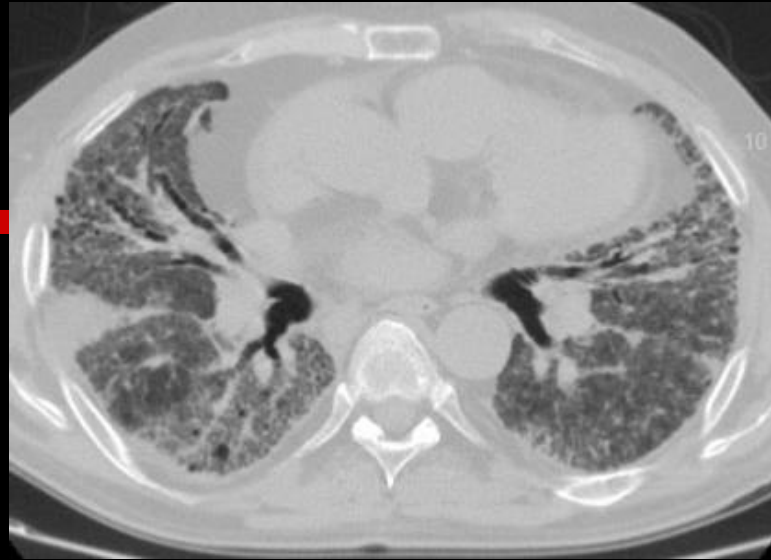Uyumsuz bulgular



Organize Pnömoni

Uyumsuz bulgular
Pat: DİP



Olađan İnterstisyel Pnömoni

Ayırıcı Tanı

OİP paterni:

- İPF
- Kollajen doku hastalıkları
- Asbestoz
- İlaç etkisi

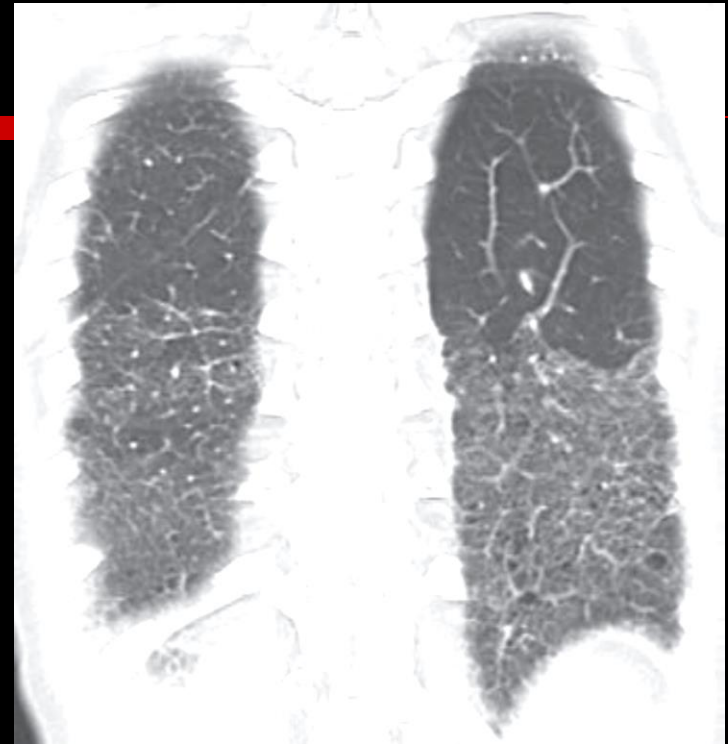
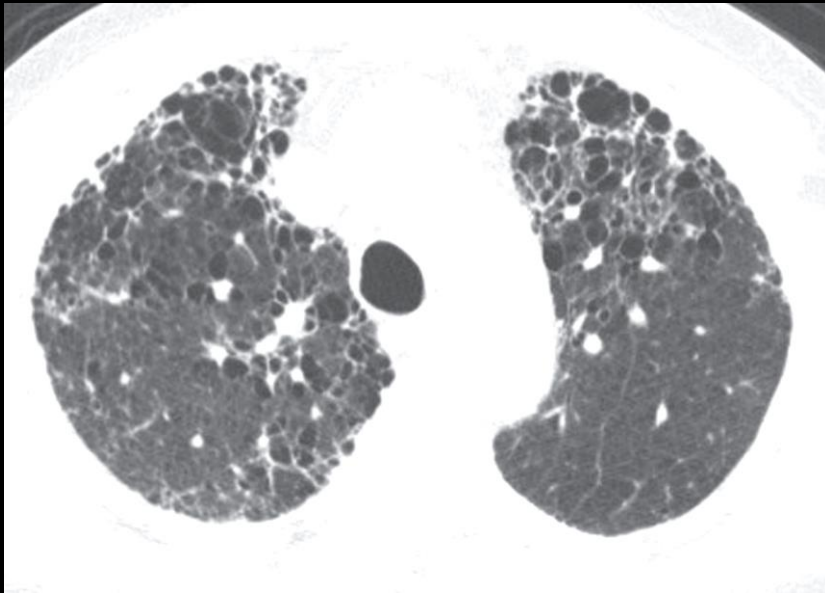
Diđer paternler:

- Nonspesifik interstisyel pnömoni
 - Kronik hipersensitivite pnömonisi
 - İdyopatik plöroparenkimal fibroelastozis
 - Kombine pulmoner fibrozis-amfizem sendromu
 - Fibrotik sarkoidoz
-

İPF vs kollajen doku hastalığı tutulumu

	duyarlılık %	özgüllük
Aşırı balpeteği	22.2	94
Üst ön lob tutulumu	25.4	87.2
Keskin kenar bulgusu	25.4	94

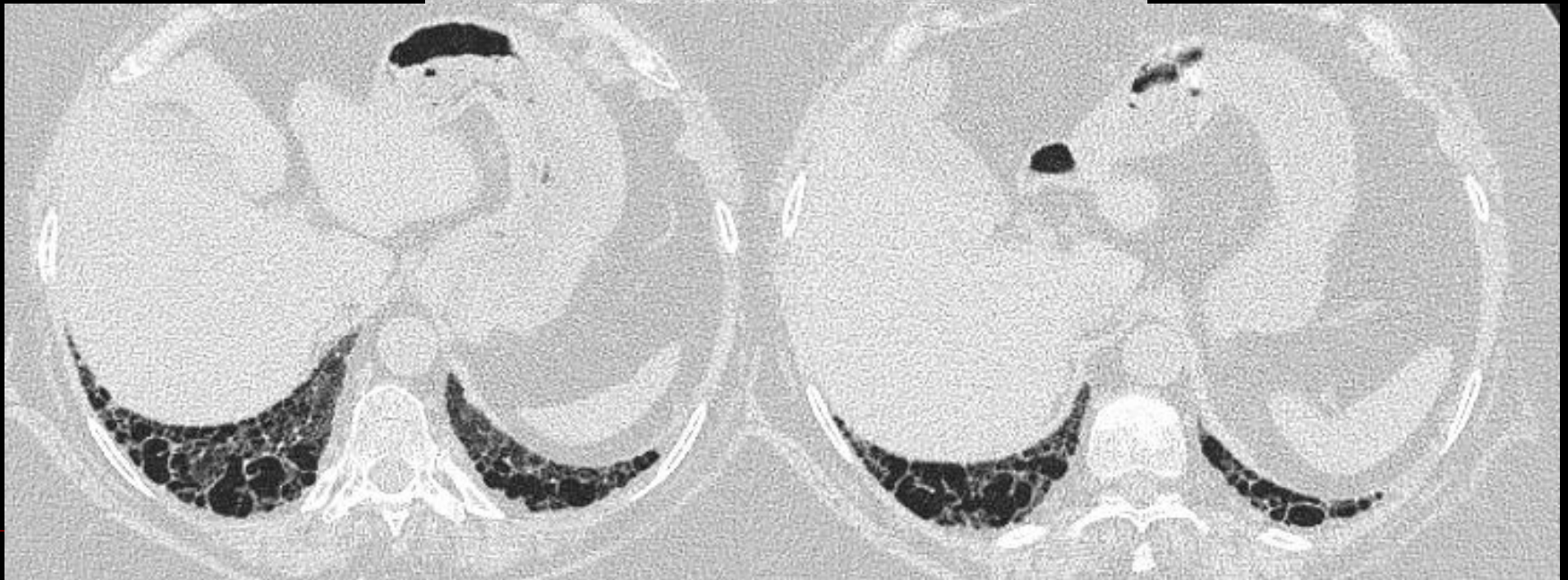
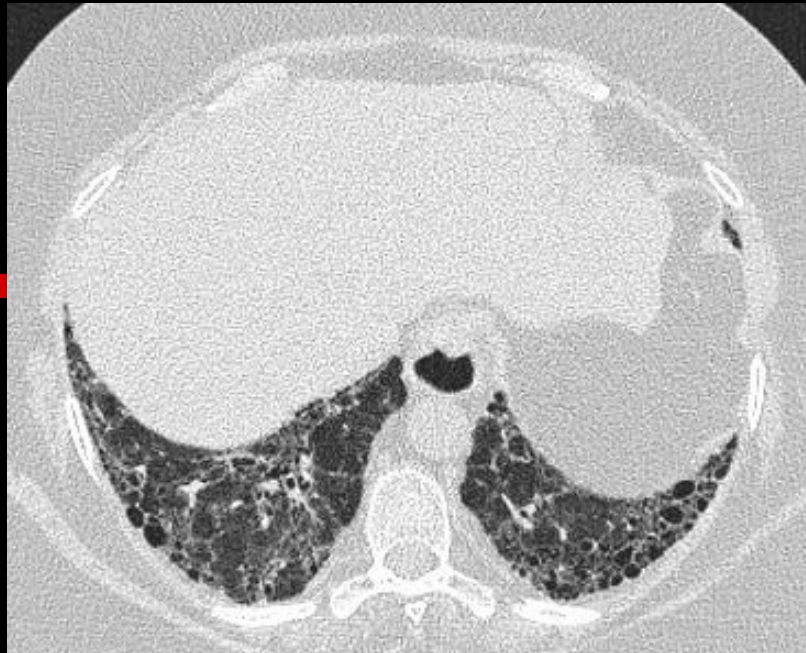
Chung JH, AJR 2018; 210:307

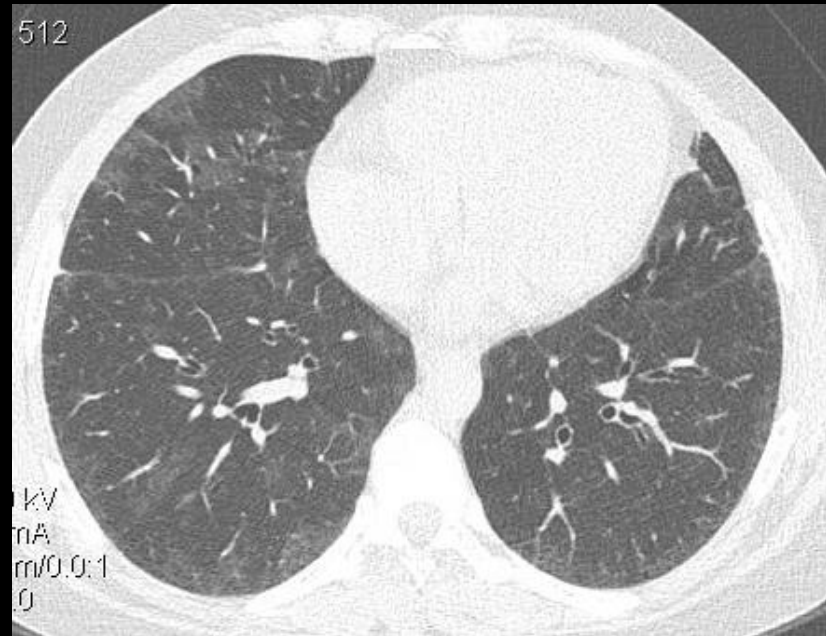
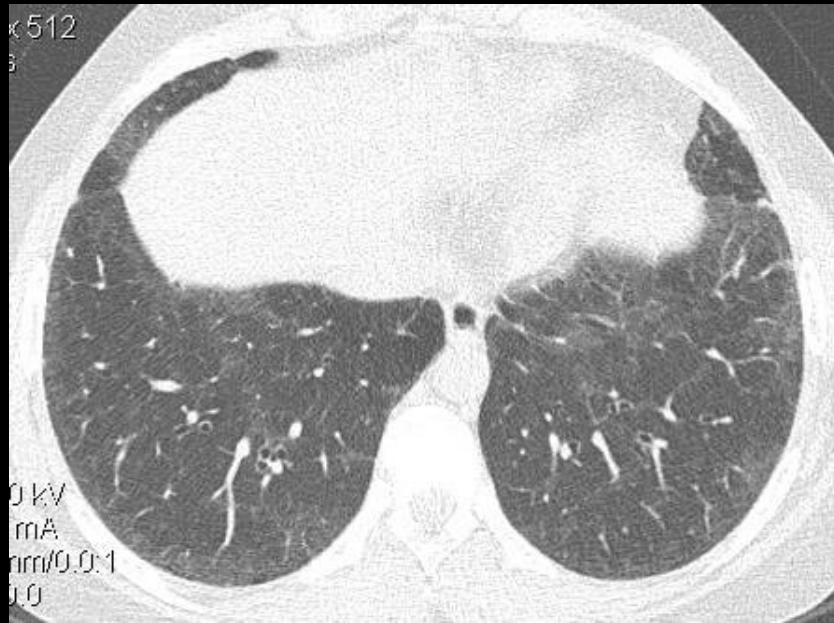


Kollajen doku hastalığı

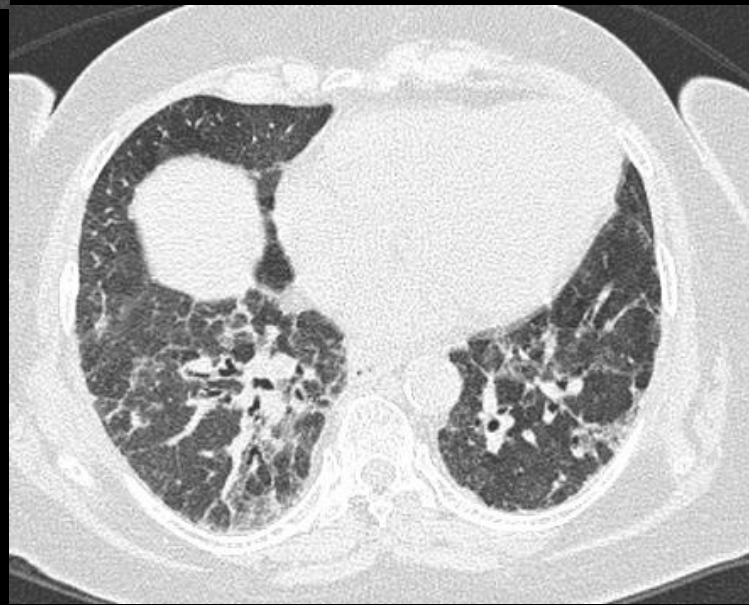
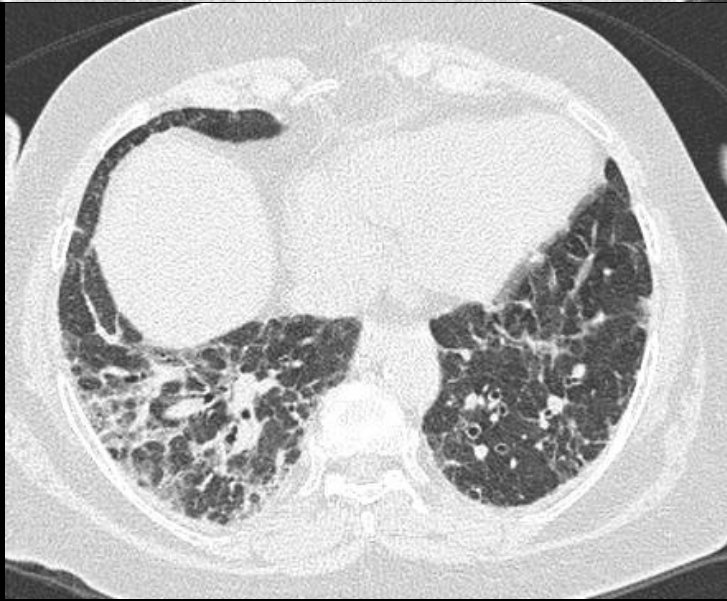
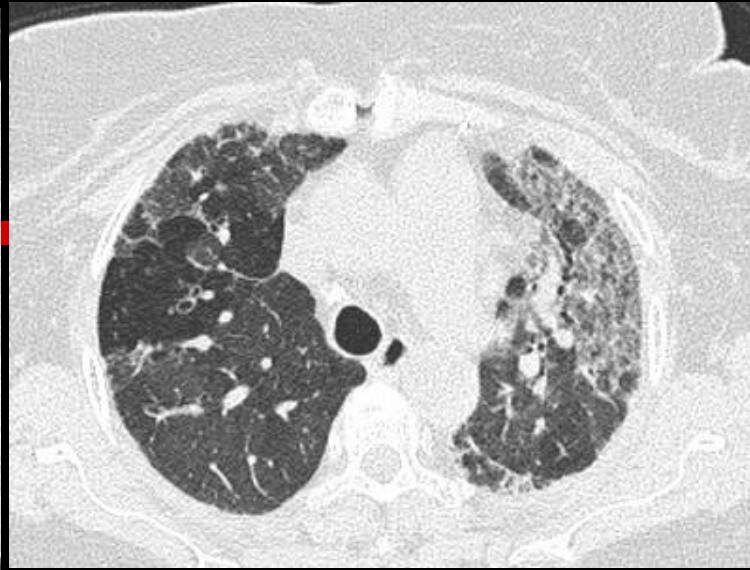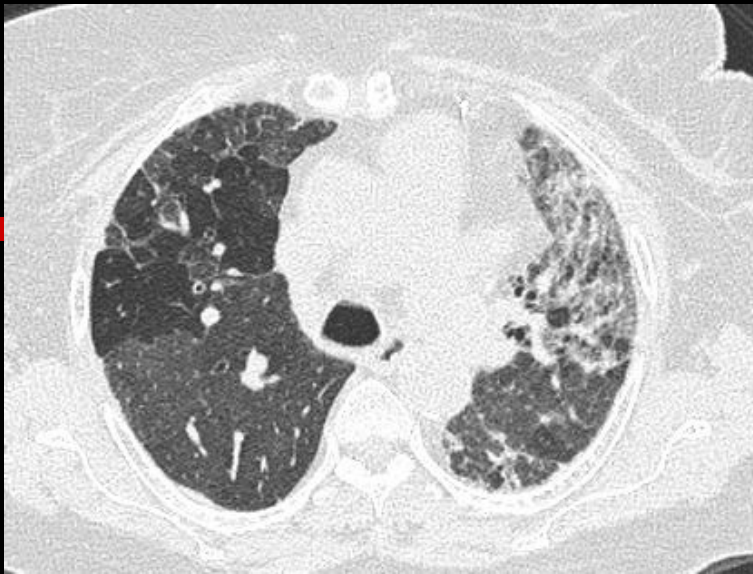
Chung JH, AJR 2018; 210:307

Skleroderma

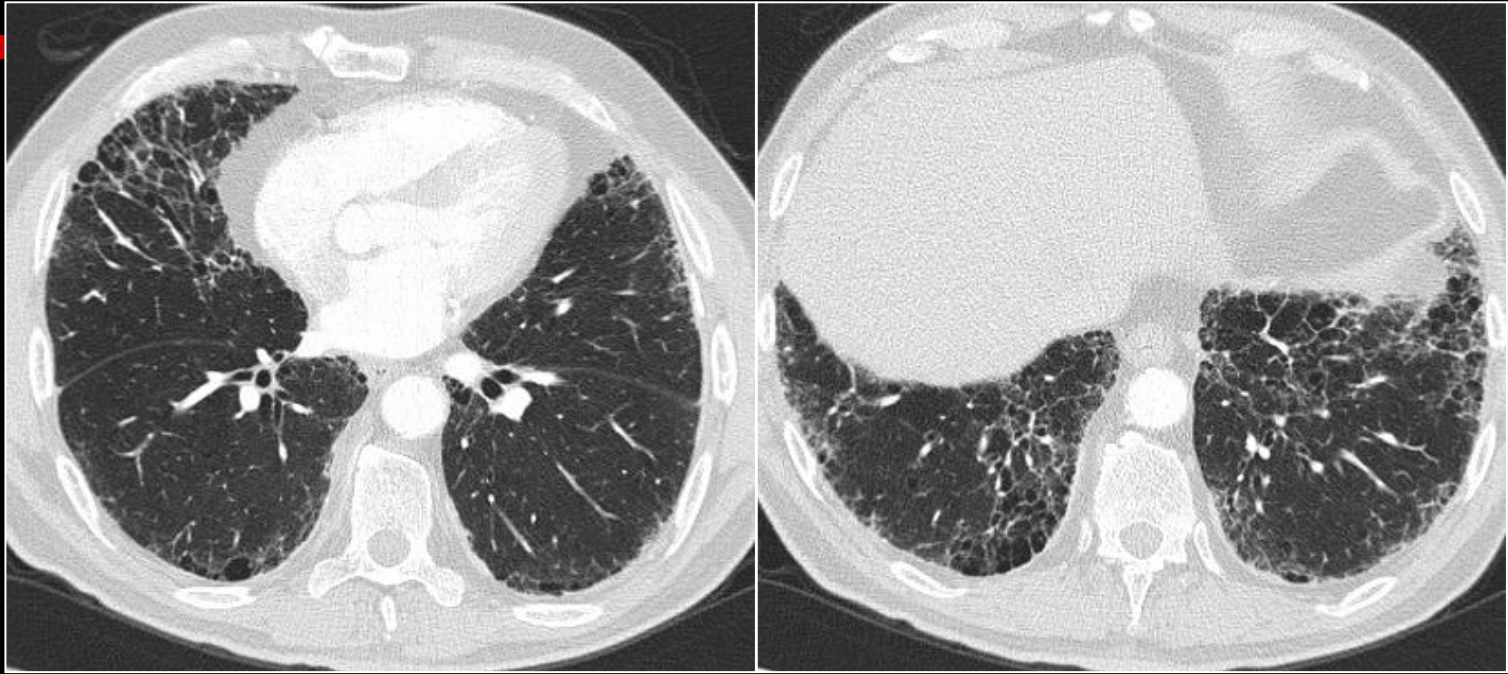




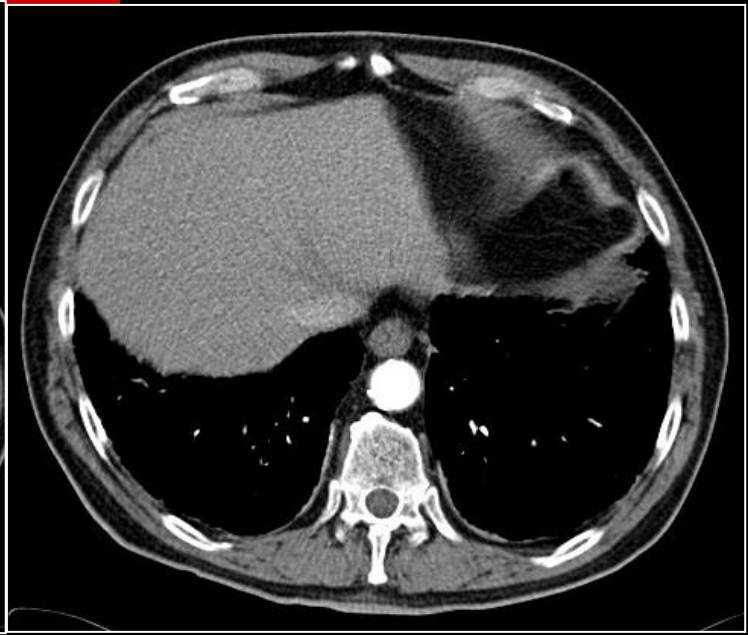
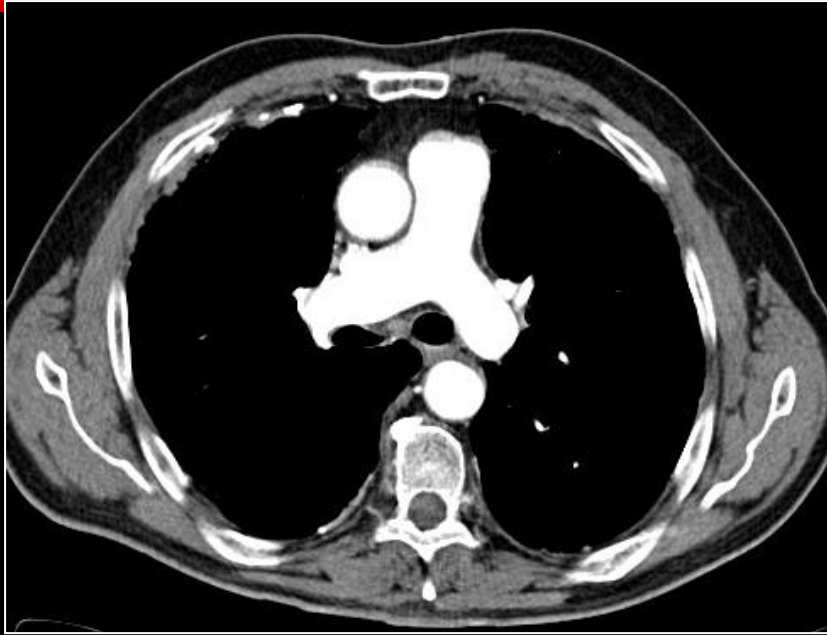
Skleroderma

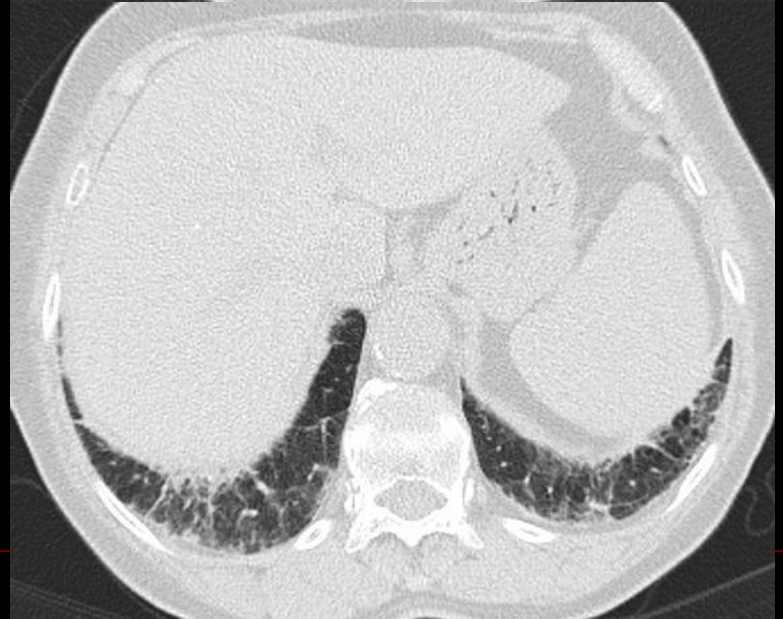
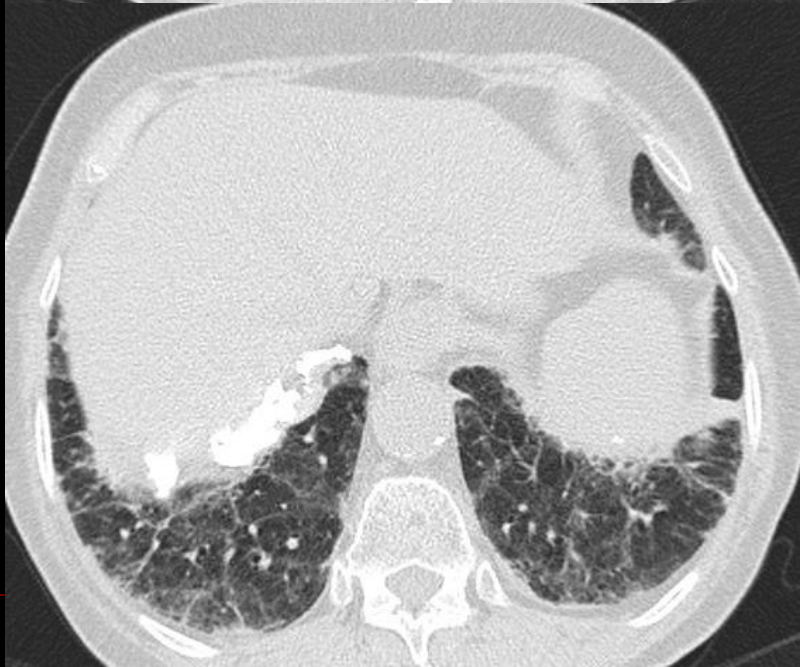
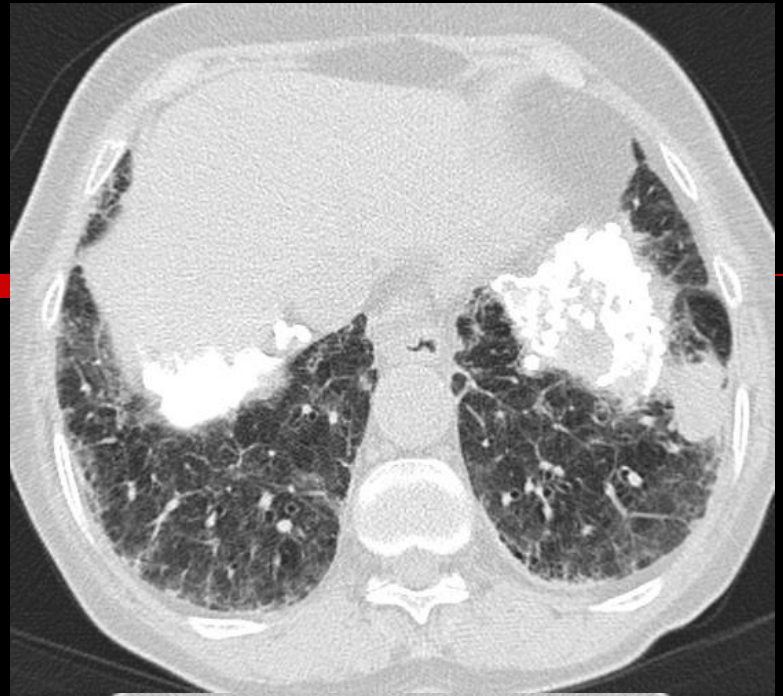
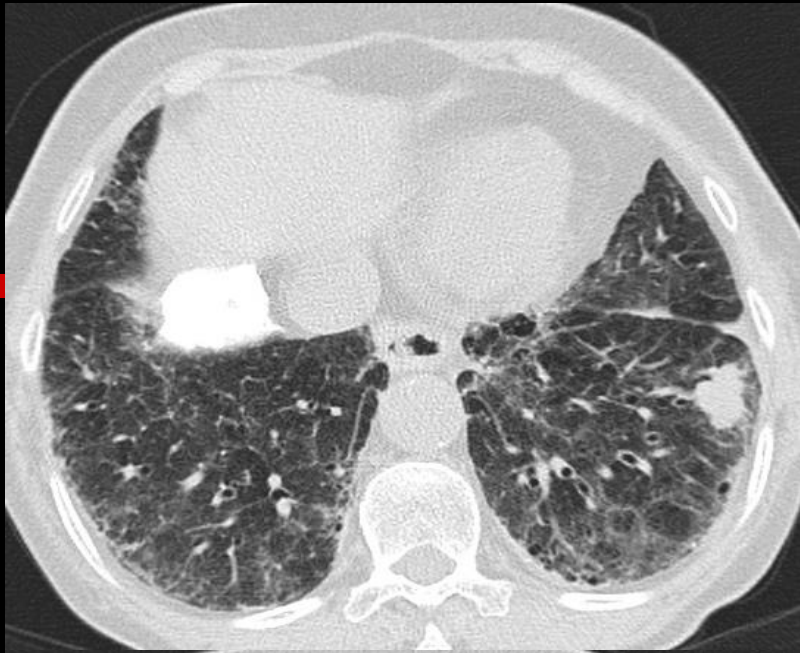


Romatoid Artirit



Asbestosis





Akciğer Dansitesinde Azalma- Kistler

- Traksiyon bronşektazisi
 - Bal peteđi
 - Akciğer kistleri
 - Kaviter nodüller
-

Akciğer Dansitesinde Azalma- Kistler

- İdyopatik interstisyel pnömoni (bal peteği)
 - Langerhans h.li histiositozis
 - Lenfanjioleimyomatozis
 - Lenfositik interstisyel pnömoni
-

Langerhans H.li Histiositozis

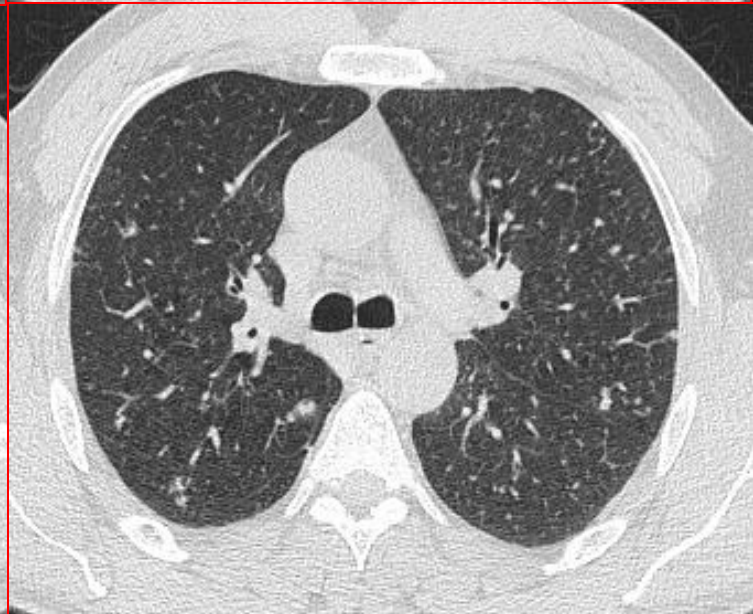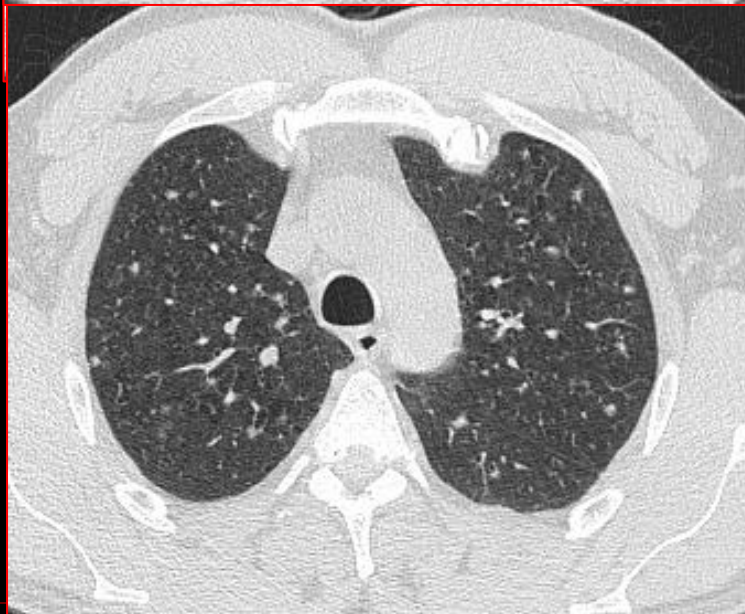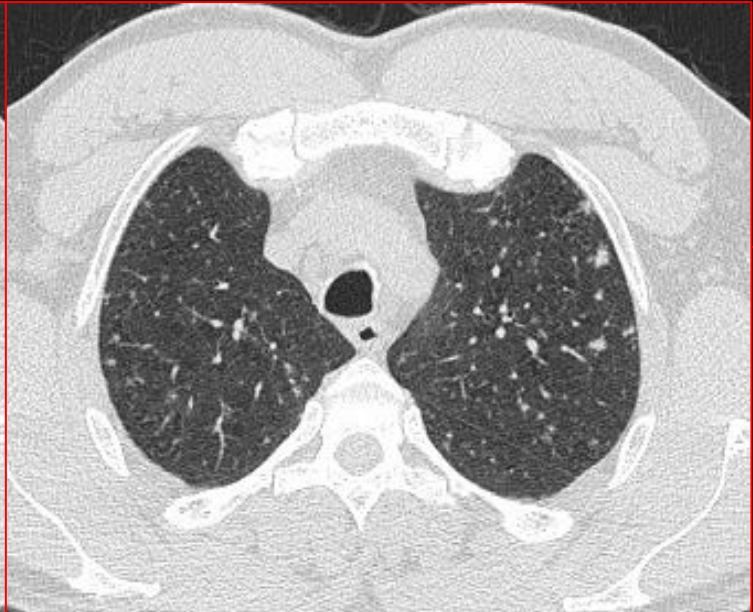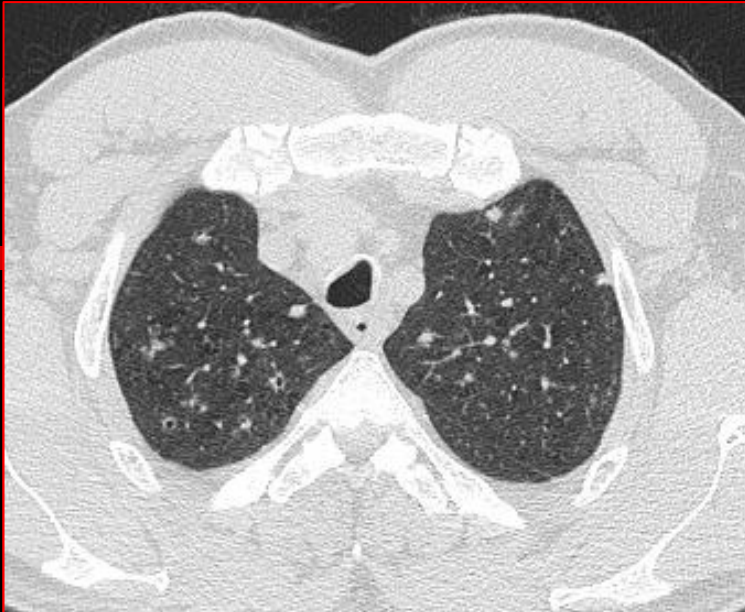Erken dönem:

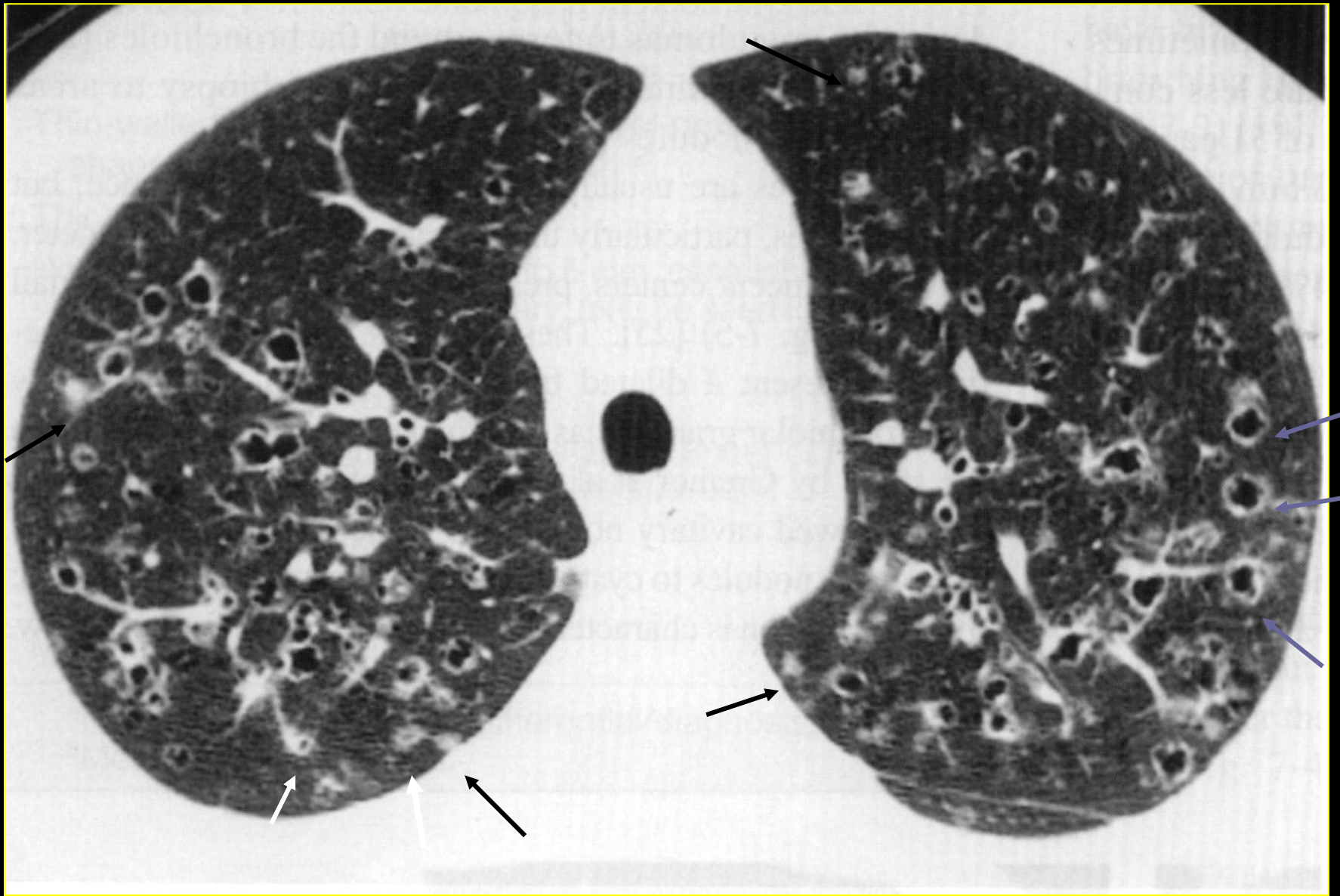
- Sentrilobüler nodüller , genellikle <5mm, daha az olarak >10 mm
 - Solid veya lüsent merkezli
 - “ kavitasyon ” : dilate bronş + çevresindeki granülomlar ve interstisyel kalınlaşma
 - Kaviter nodüller, hava kistlerine dönüşür
 - Tutulum üst loblarda daha fazla, akciğer bazalleri ve kostofrenik sinüsler korunur
 - Akciğer hacmi artar
-

Langerhans H.li Histiositozis

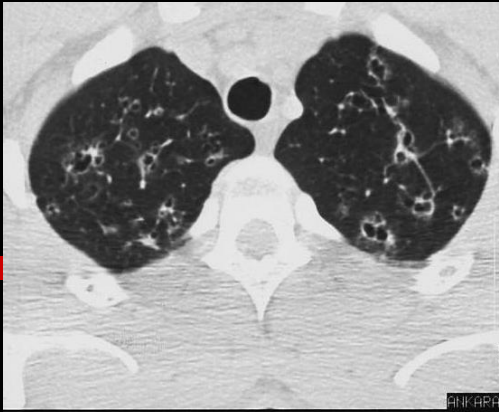
İleri dönem:

- Nodüller azalırken ince duvarlı kistler artar
 - Kistler yuvarlak veya acaip şekilli olabilir
 - Birleşerek 20 mm'yi geçebilirler
 - Septal kalınlaşma yoktur
-





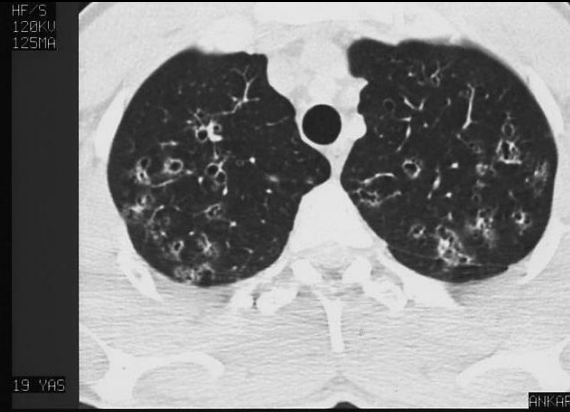LHH



W1719
-682

512+512
MAG*1.7

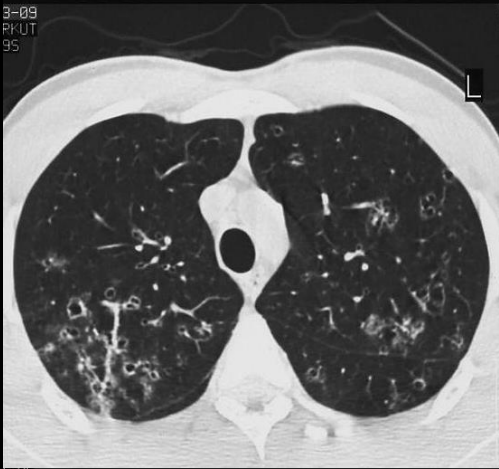ANKARA AKADEMI



HF/S
120KV
125MA

19 YAS

ANKARA

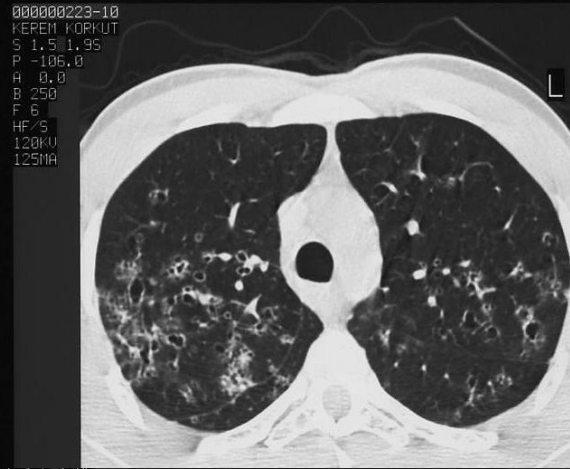

8-09
RKUT
95

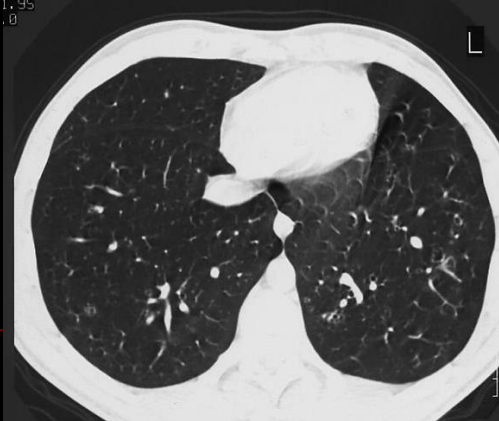08/10/04
10:52:43

W1665
-727

512+512
MAG*1.7



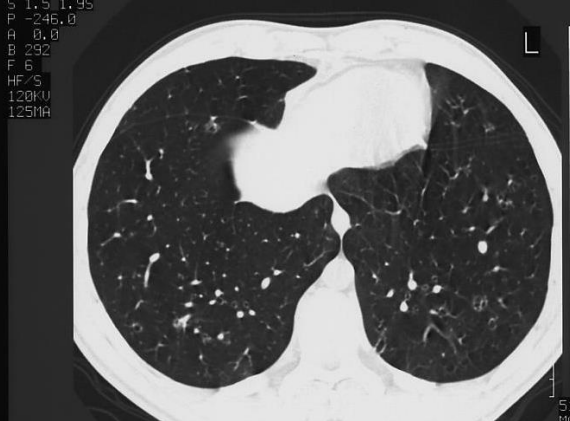000000223-10
KEREM KORKUT
S 1.5 1.95
P -106.0
A 0.0
B 250
F 6
HF/S
120KV
125MA



1.95
0

W1501
-742

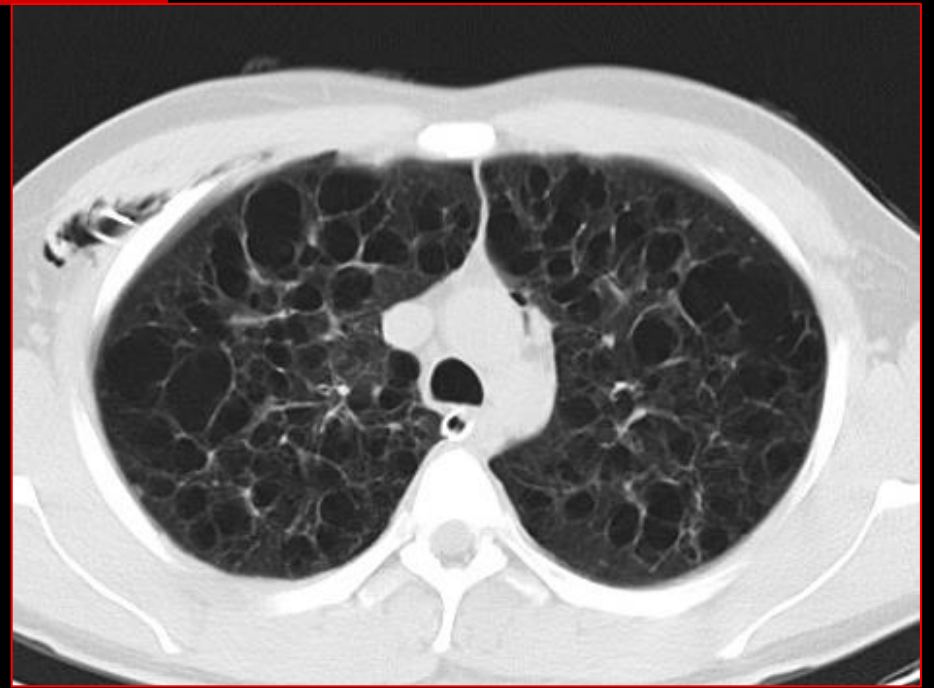
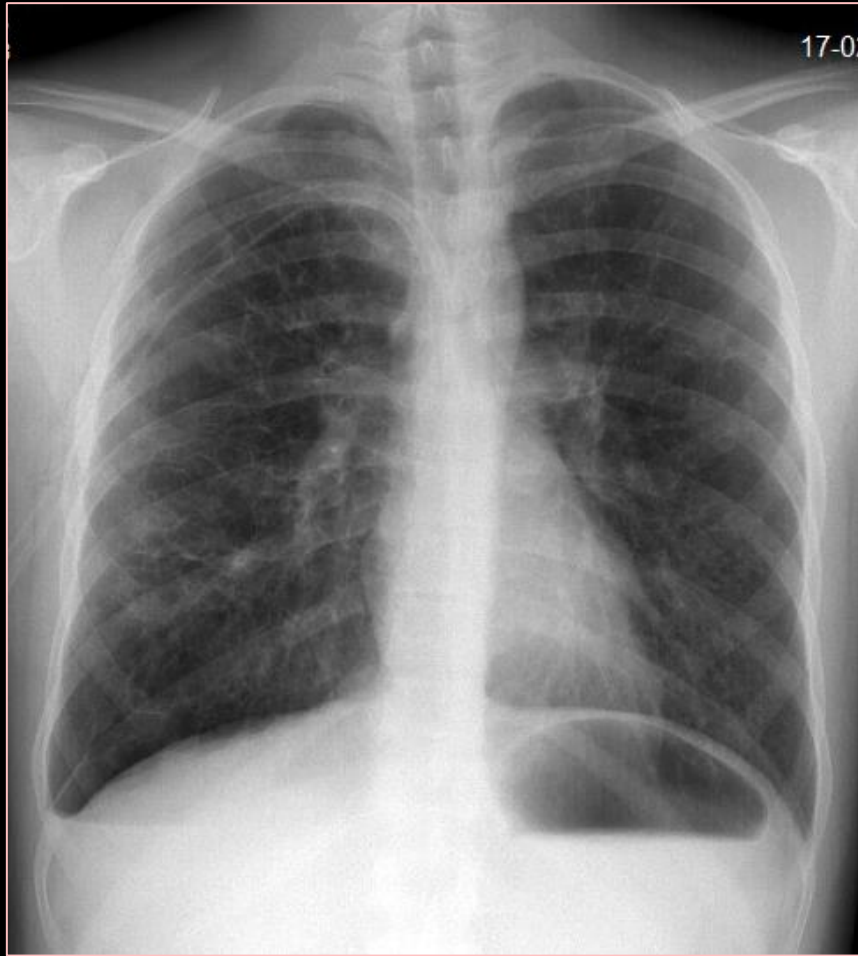
512+512
MAG*1.7



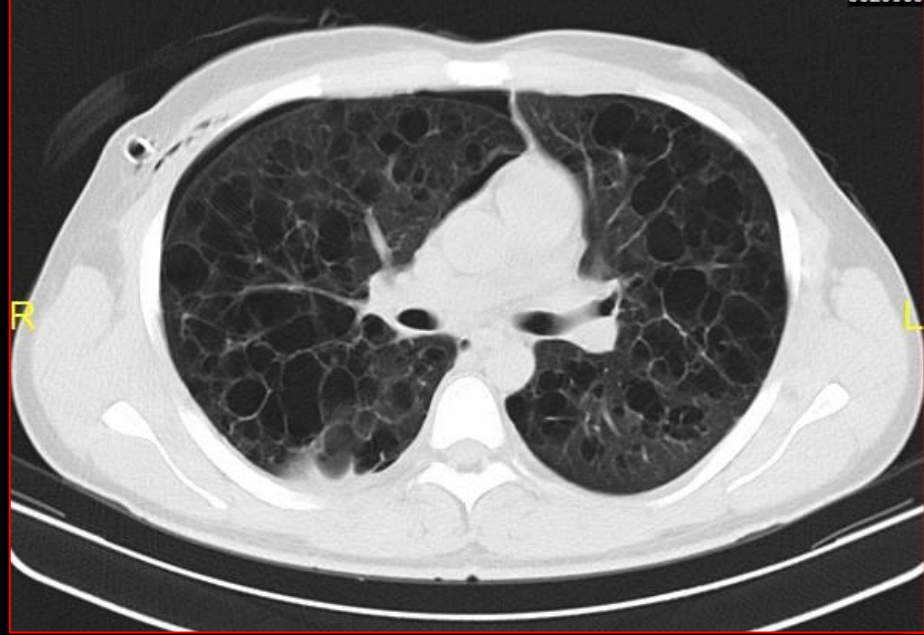
S 1.5 1.95
P -246.0
A 0.0
B 292
F 6
HF/S
120KV
125MA

512
MAG

Langerhans H.li
Histiositoz

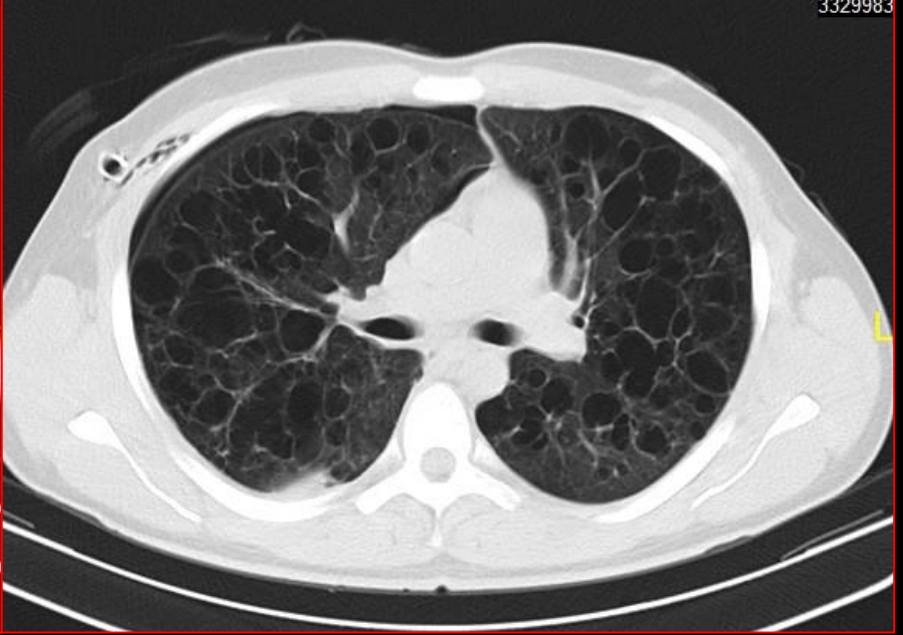


Thoraks... 5.0 B60s



Emotion Duo
3329983

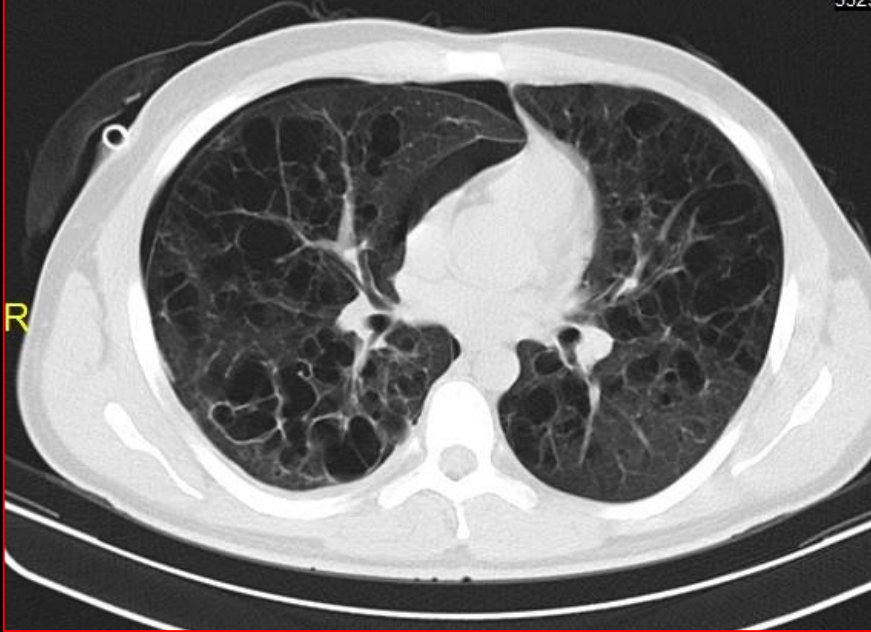Thoraks... 5.0 B60s



Emotion Duo
3329983

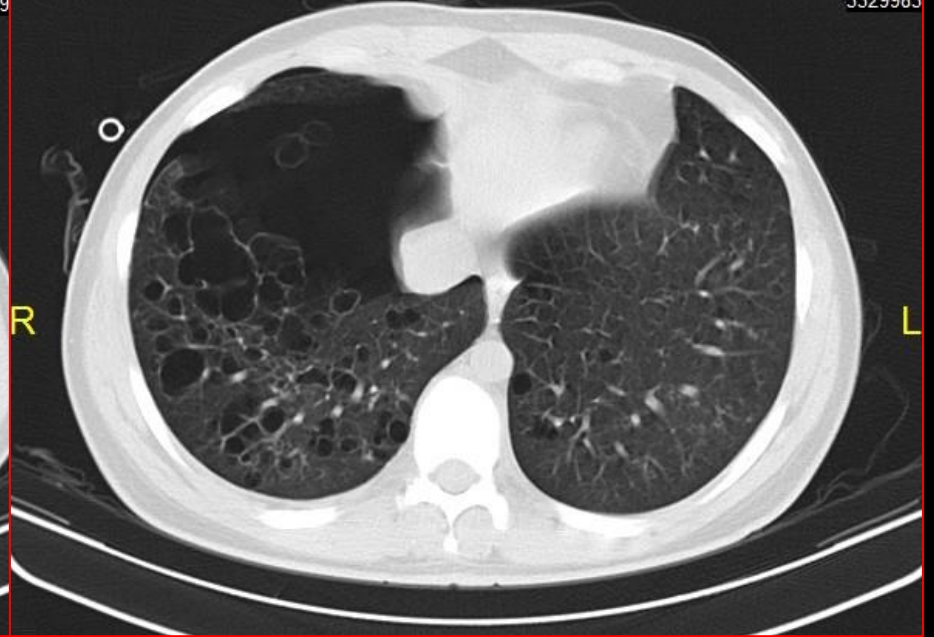Thoraks... 5.0 B60s

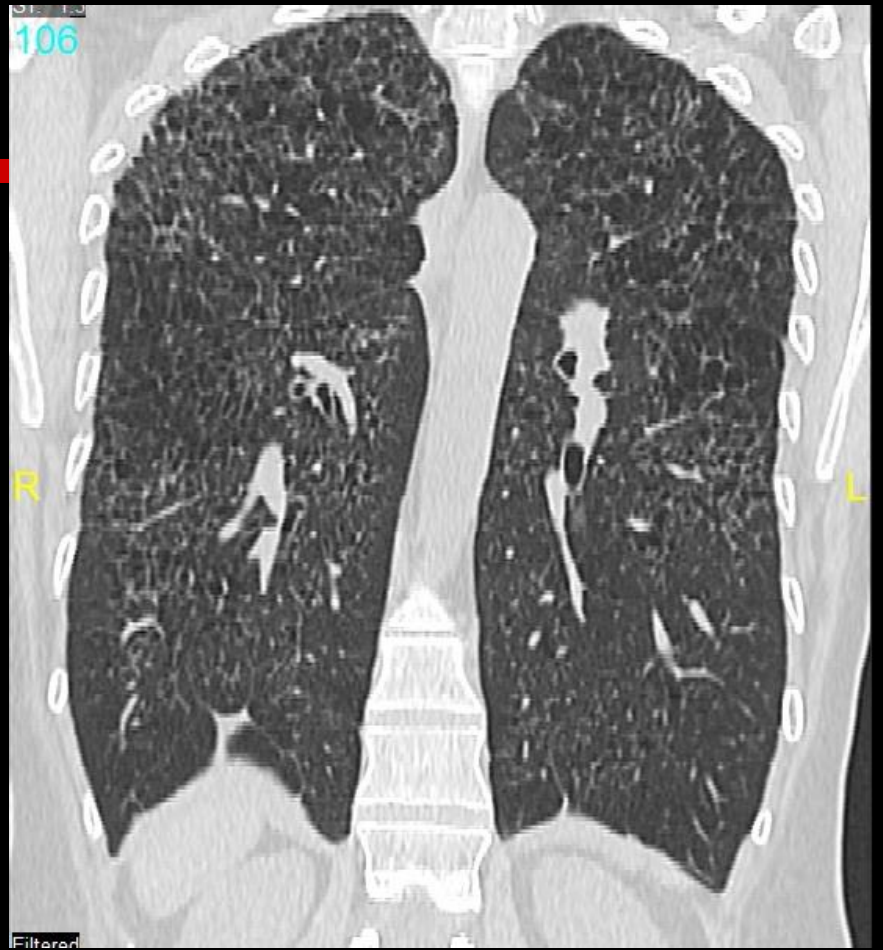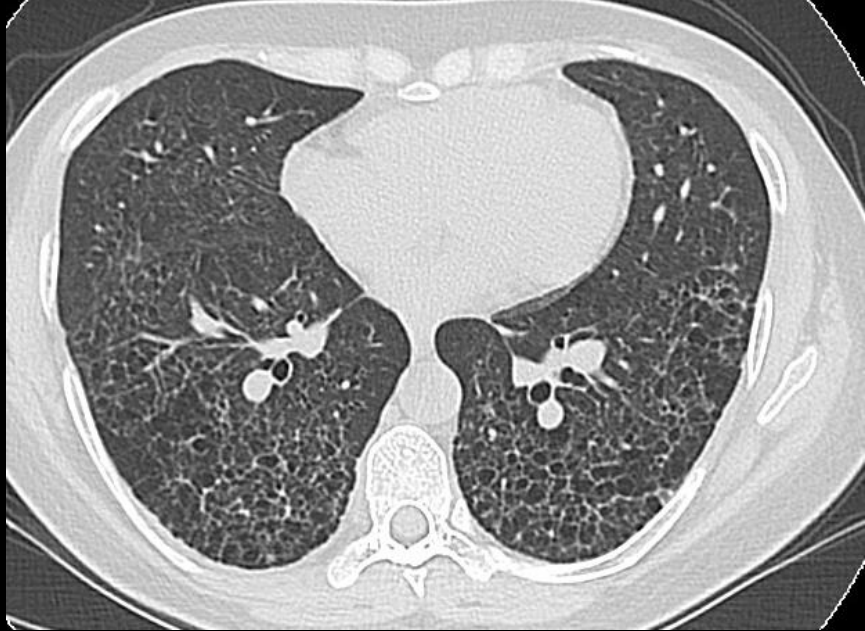
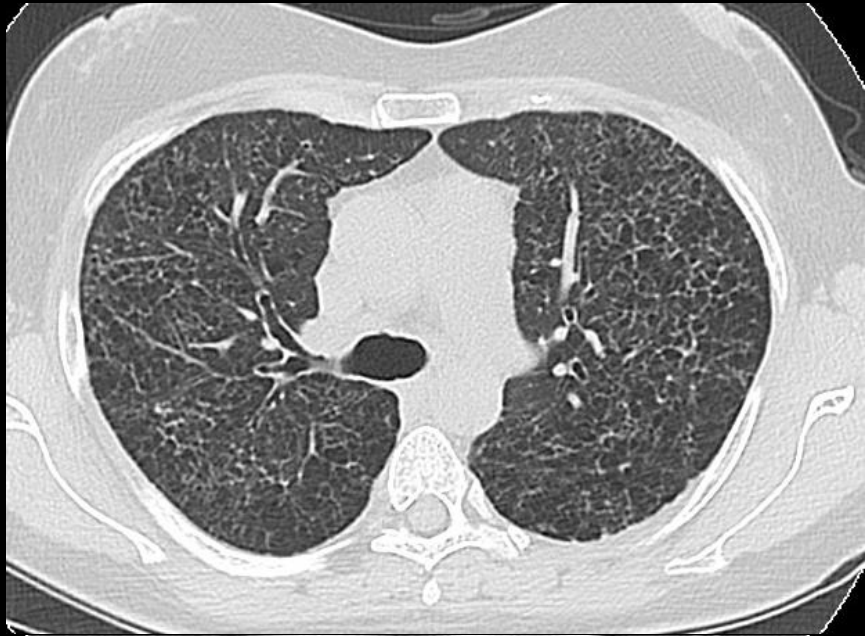Emotion
3329



Thoraks... 5.0 B60s

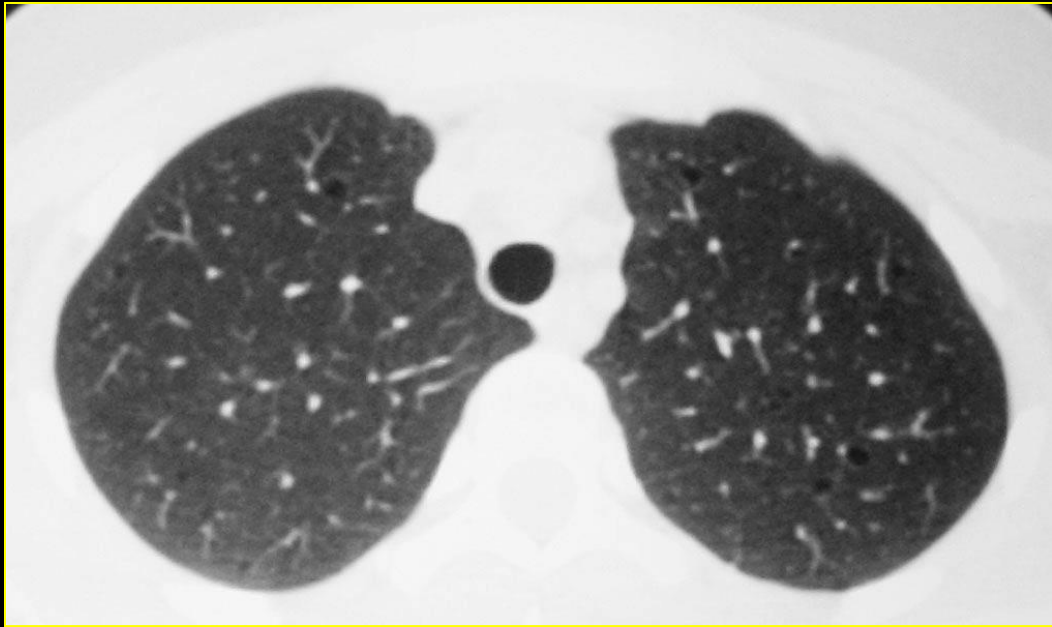
Emotion Duo
3329983



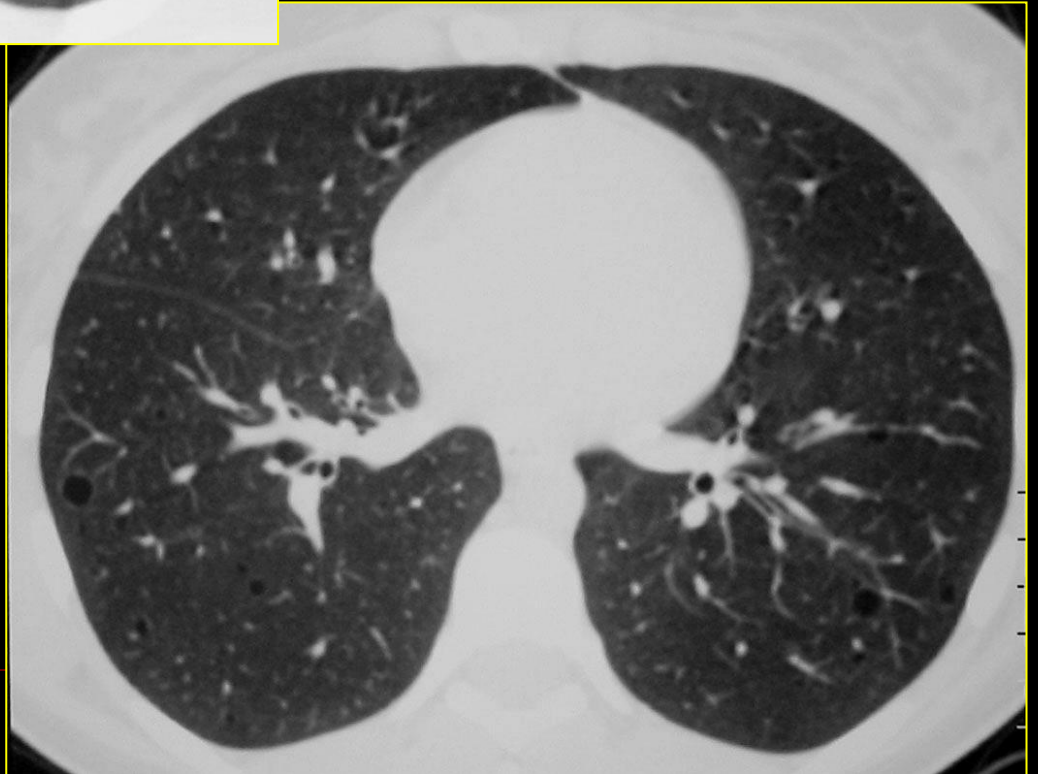


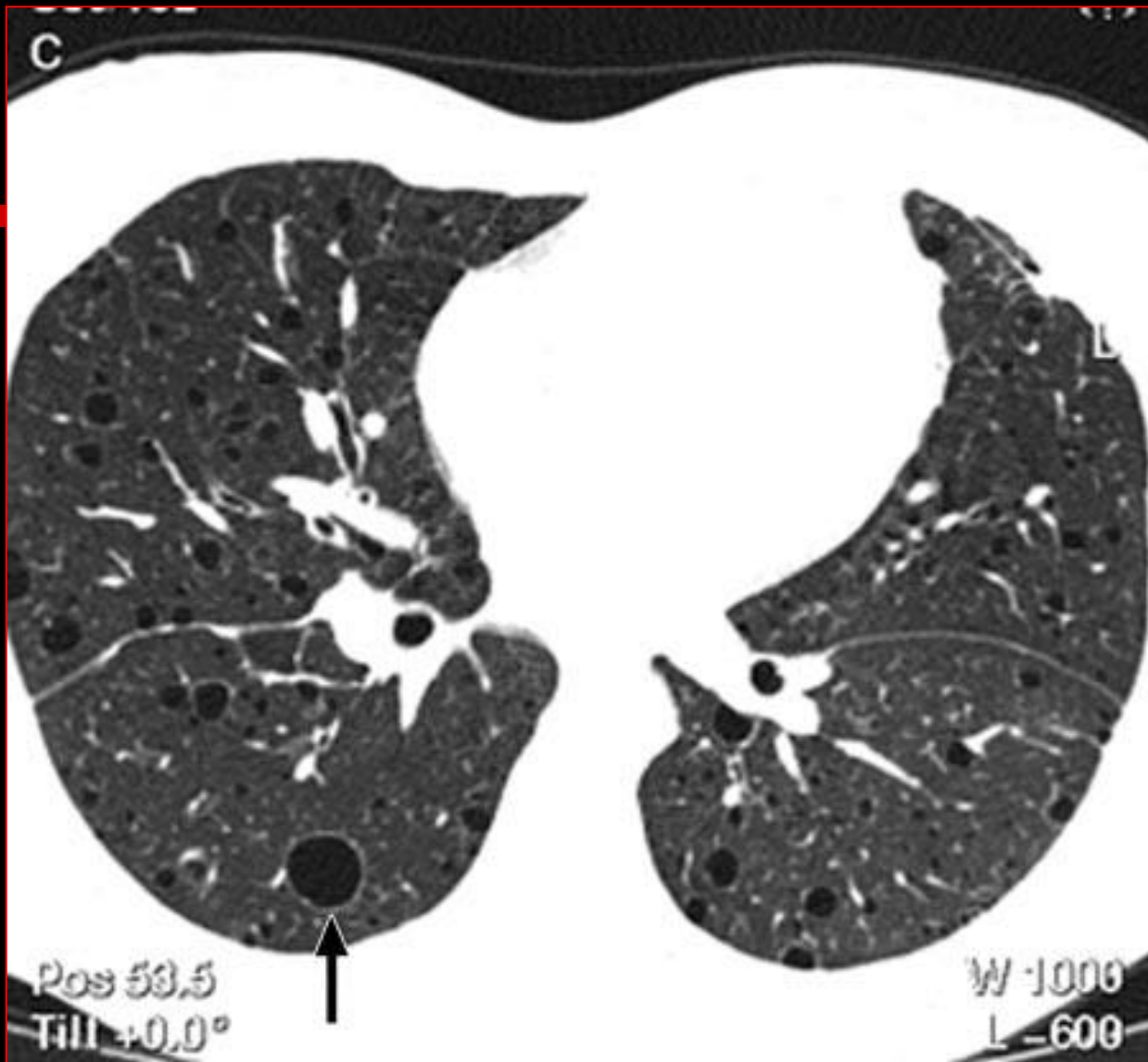
Lenfanjiroleimyomatozis

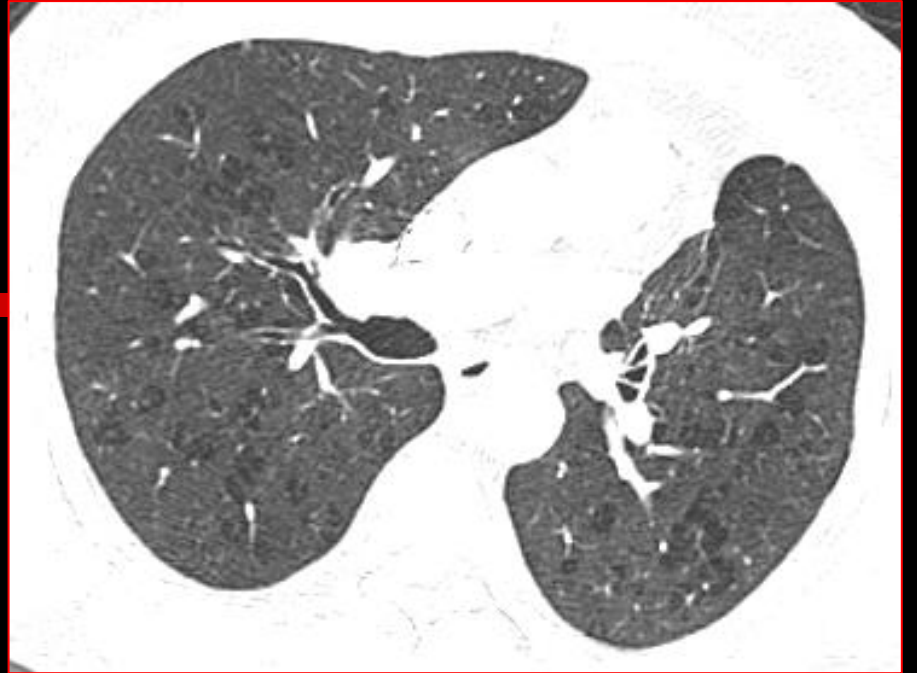
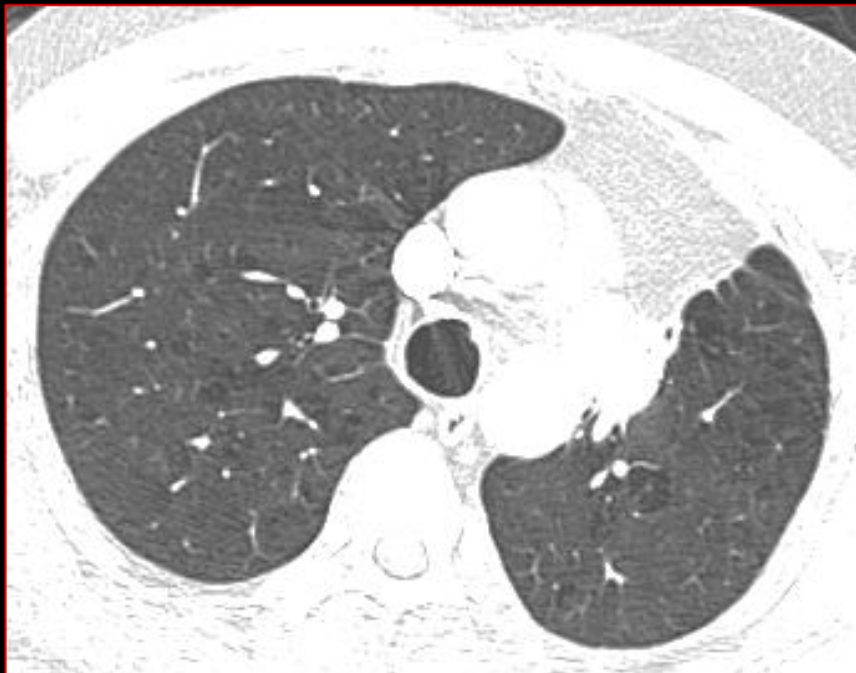- Çok sayıda ince duvarlı kistler, 2mm- 5 cm çapında
 - Genellikle yuvarlak
 - Kist duvarı zorlukla seçilebilir , 4 mm'ye kadar olabilir
 - Aralarında normal akciğer parenkimi
 - Diffüz olarak dağılırlar, zonal tercih yoktur
 - Parenkimal nodül çok nadir
 - %50 mediastinal, hiler LAP
-



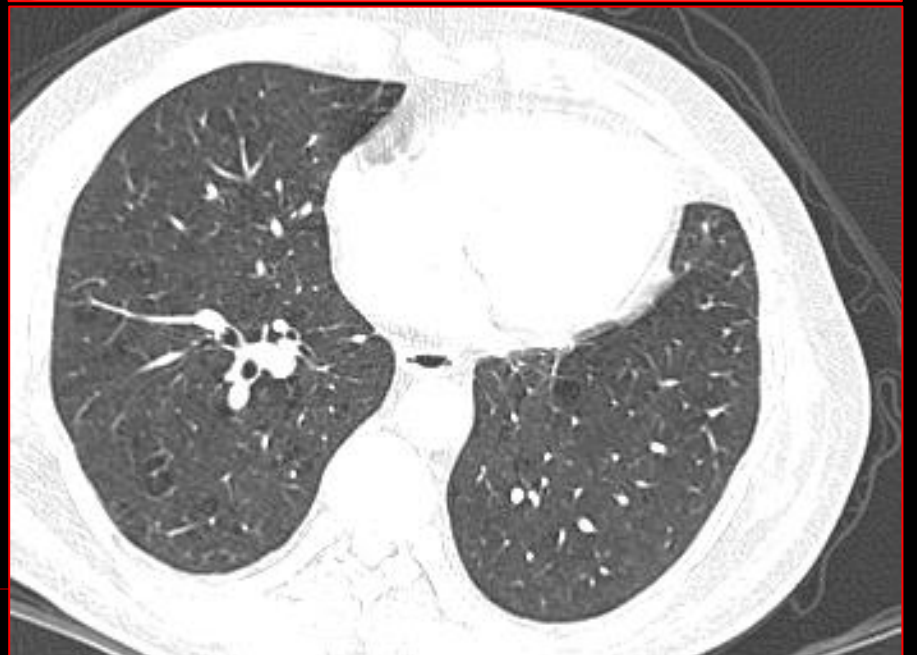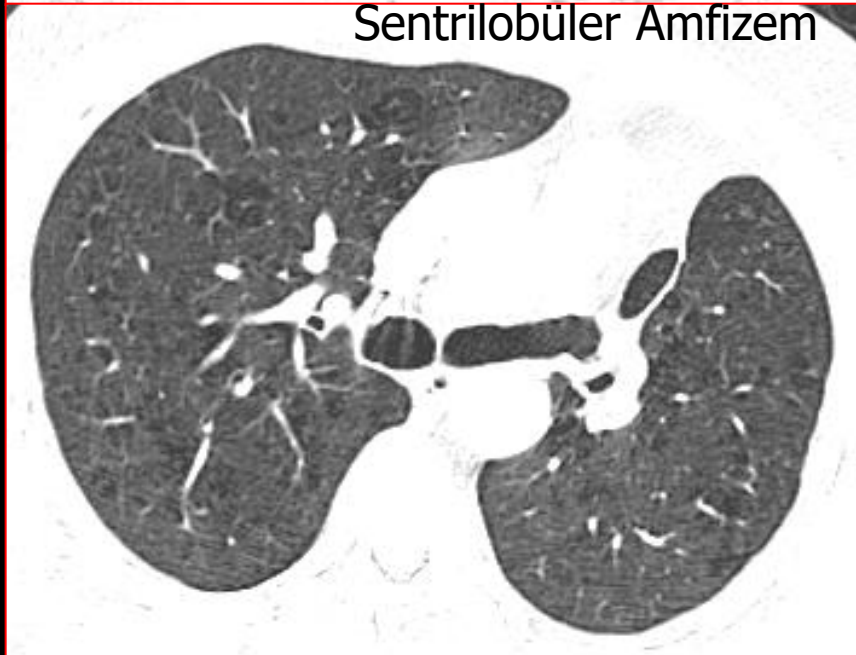
LAM







Sentrilobüler Amfizem

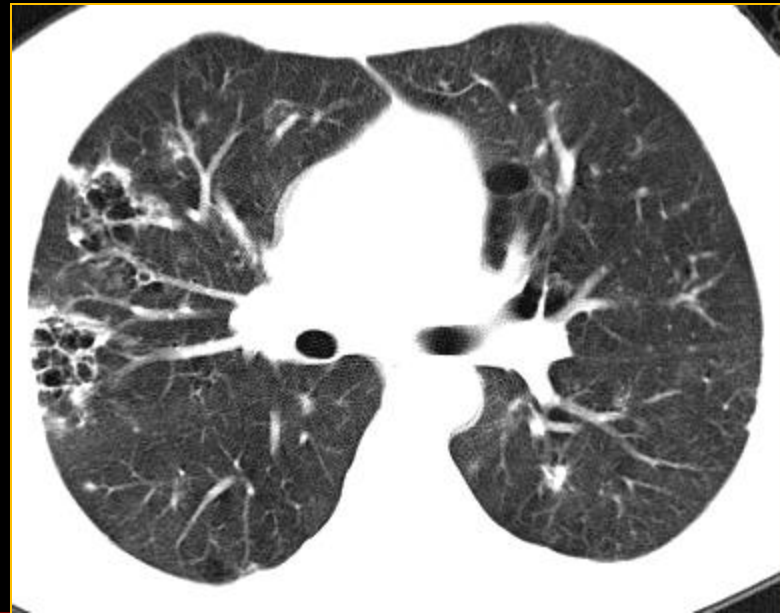
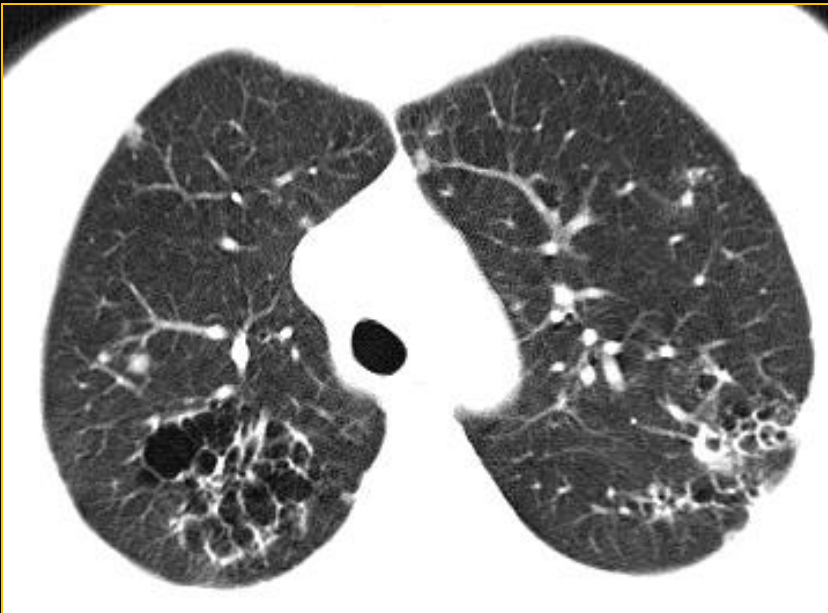
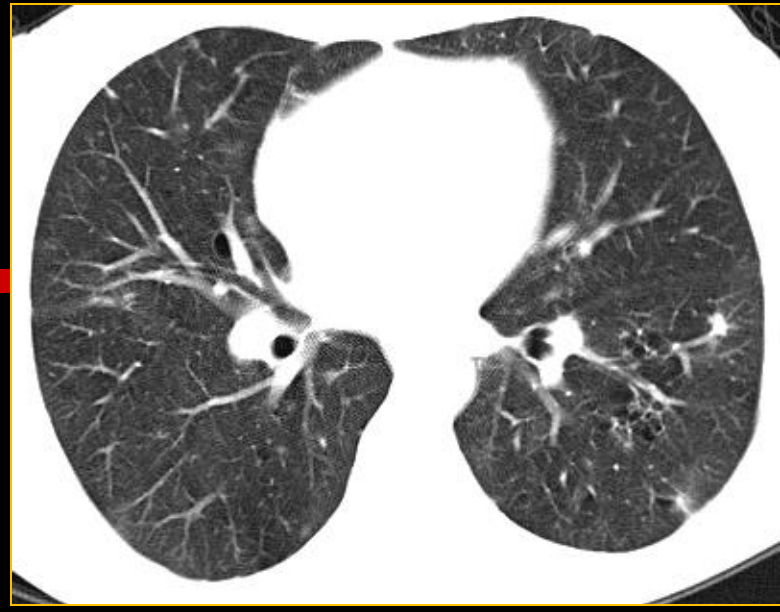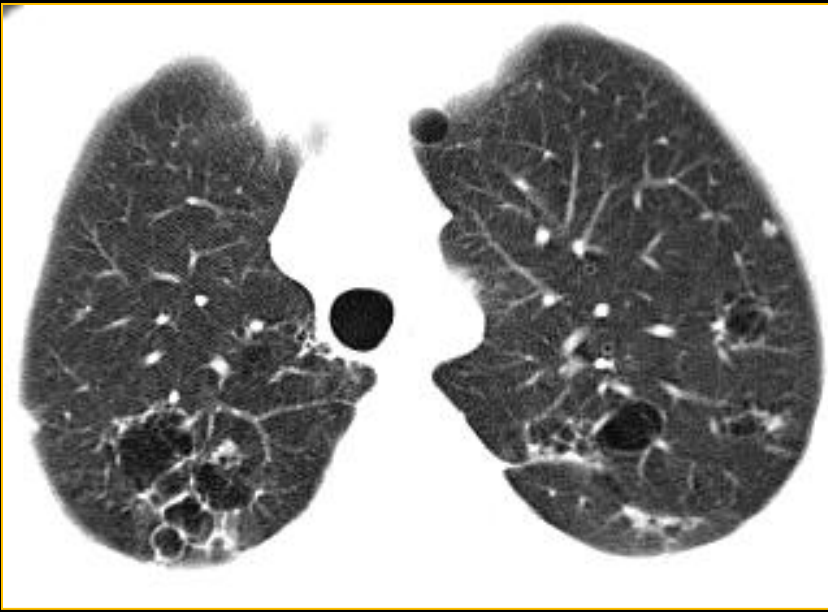


LAM vs LHH

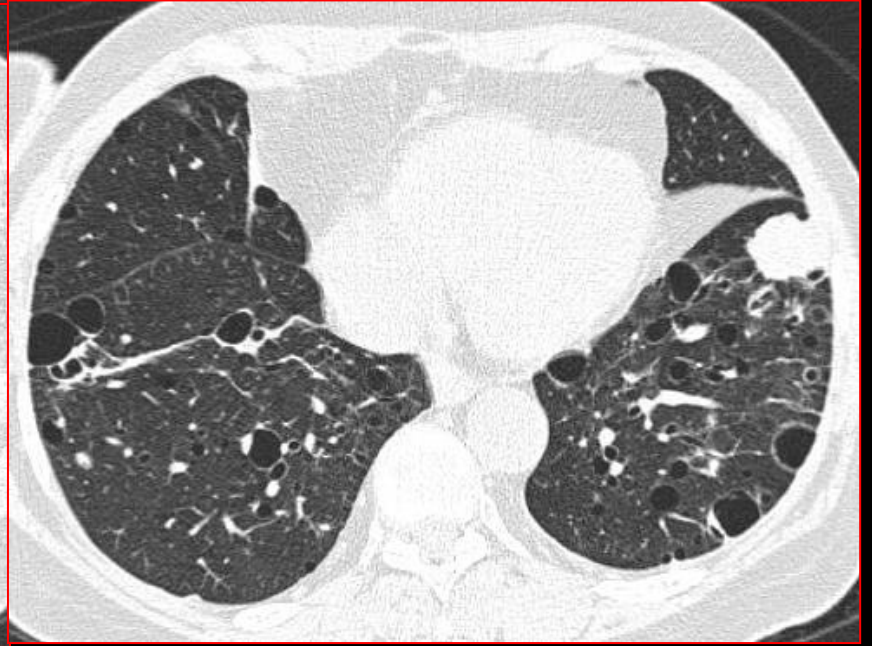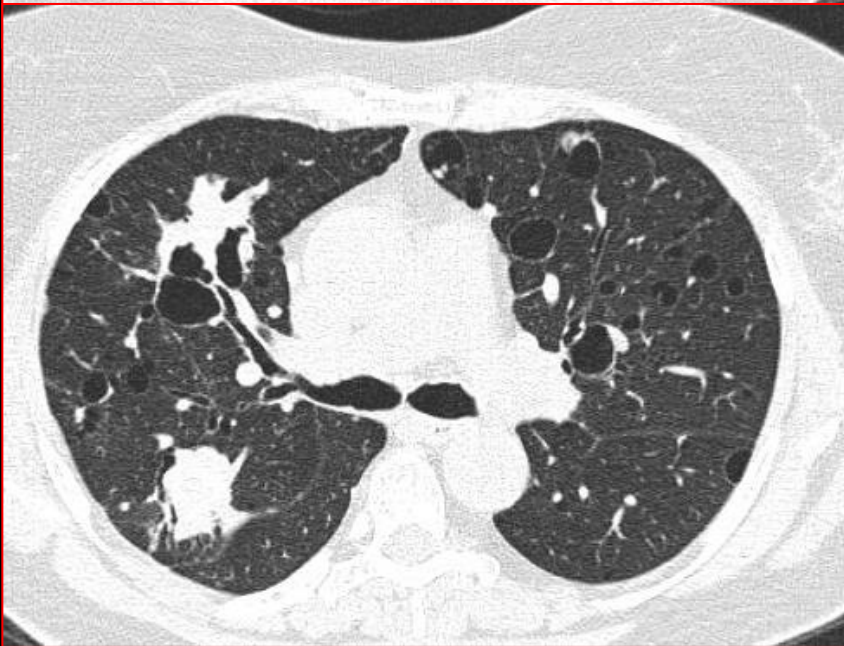
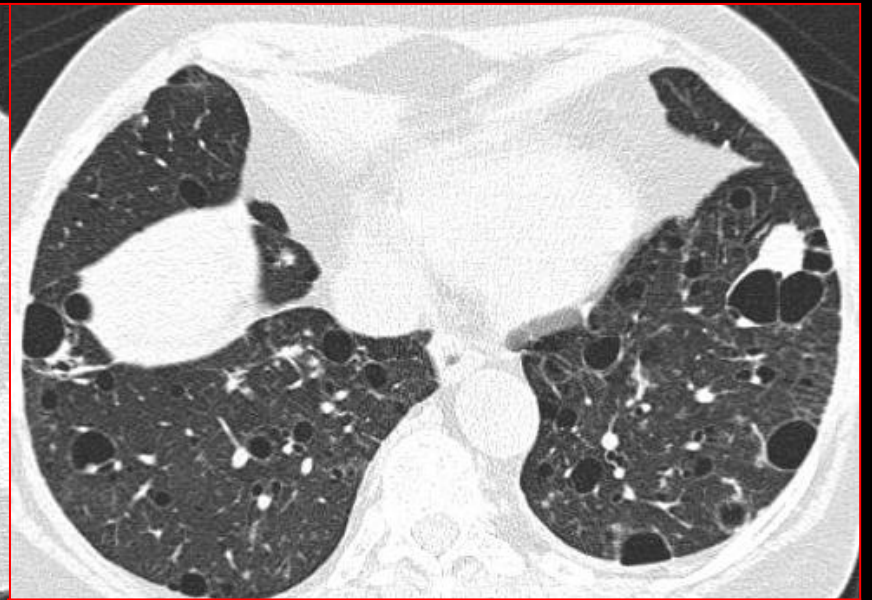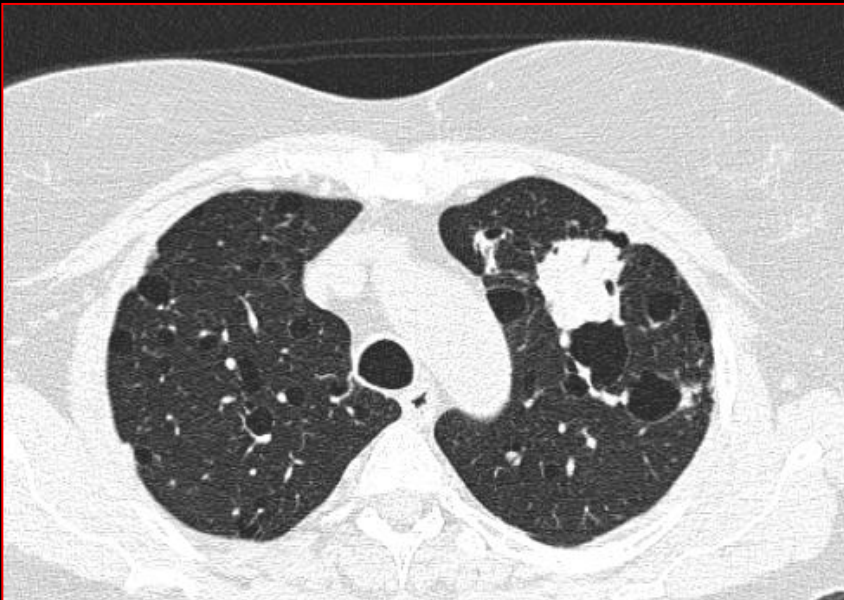
	LAM	LHH
Tutulum kostofrenik	diffüz	bazaller ve sinüsler korunur
Nodül	--	+
Kistler	yuvarlak	farklı şekillerde
Sigara	-	+

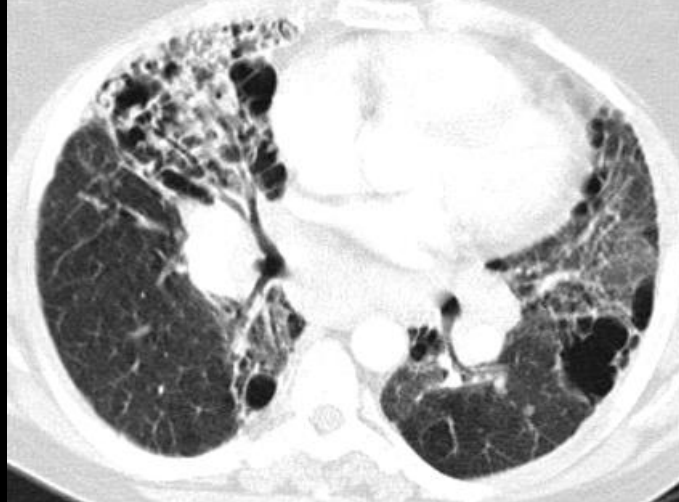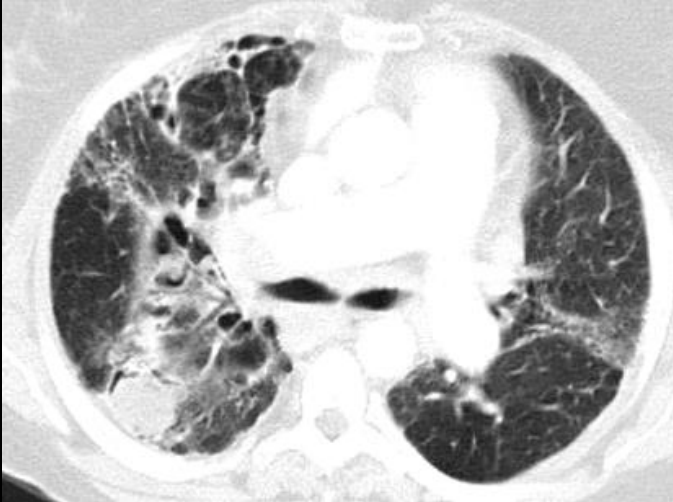
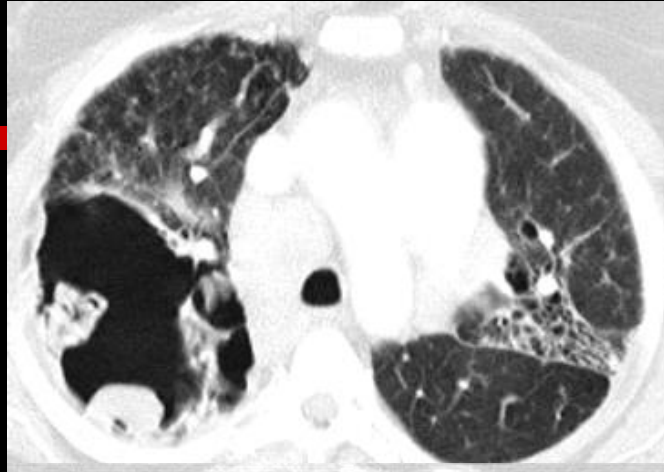
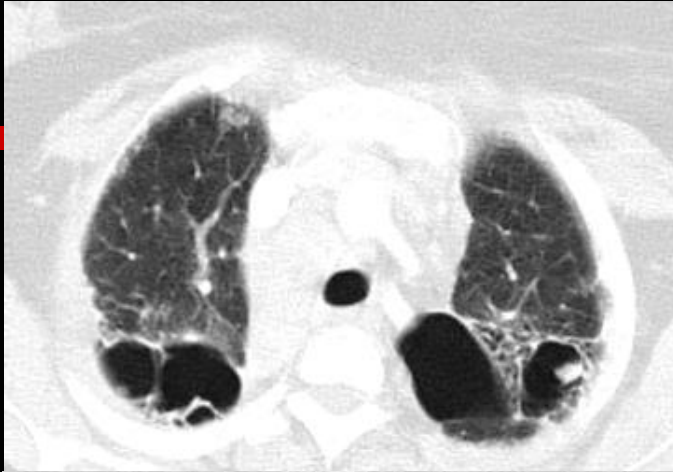Lenfoid İnterstisyel Pnömoni (LİP)

- **Patoloji:** İnterstisyumun lenfositler, plazma hücreleri ve histiositlerle infiltrasyonu ile karakterizedir.
- Buzlu cam dansiteler
- Sentrilobüller, sınırları belirsiz nodüller
- Subplevral nodüller
- İnterlobüller septumlarda ve peribronkovasküler interstisyumda kalınlaşmalar
- Hava kistleri
- Lenf nodlarında büyüme
- **Dağılım:** bölgesel veya diffüz

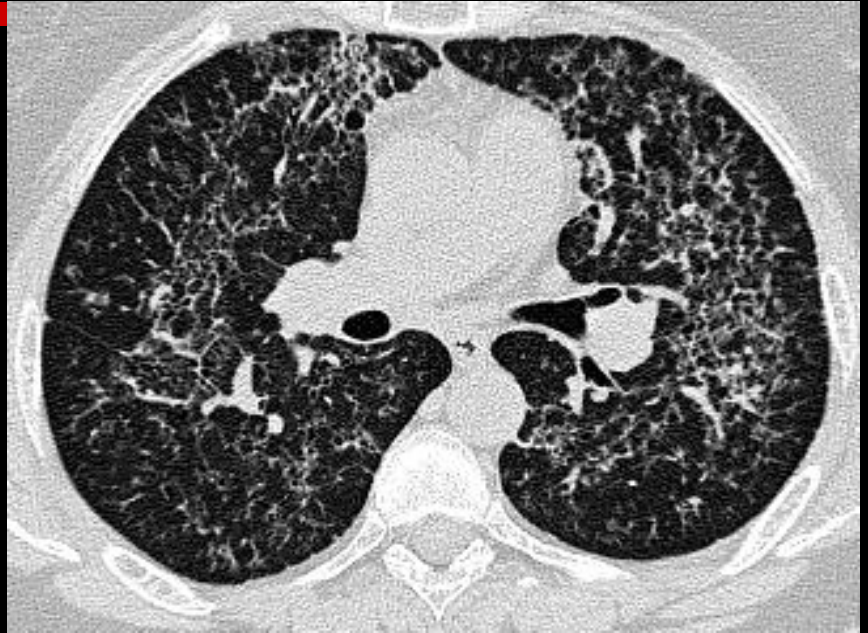
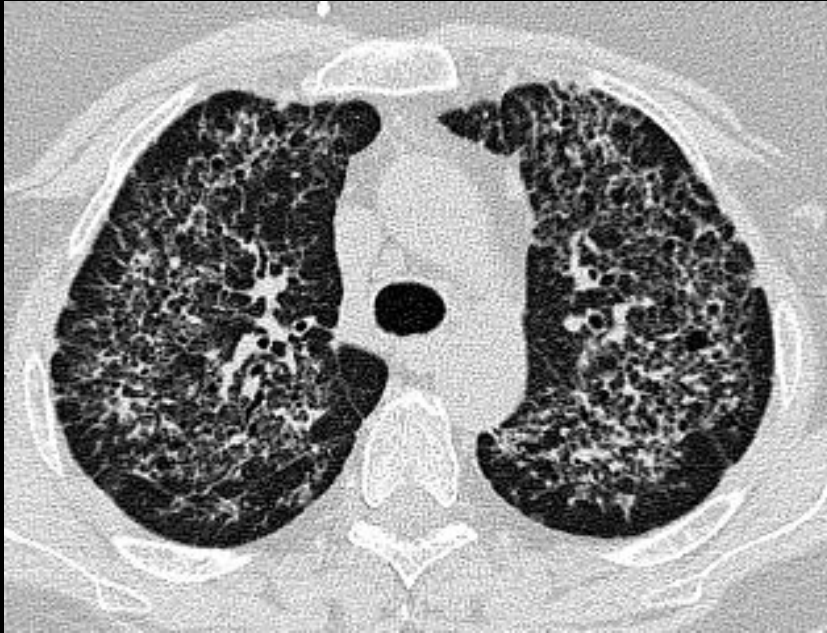

Lenfoid İnterstisyel Pnömoni

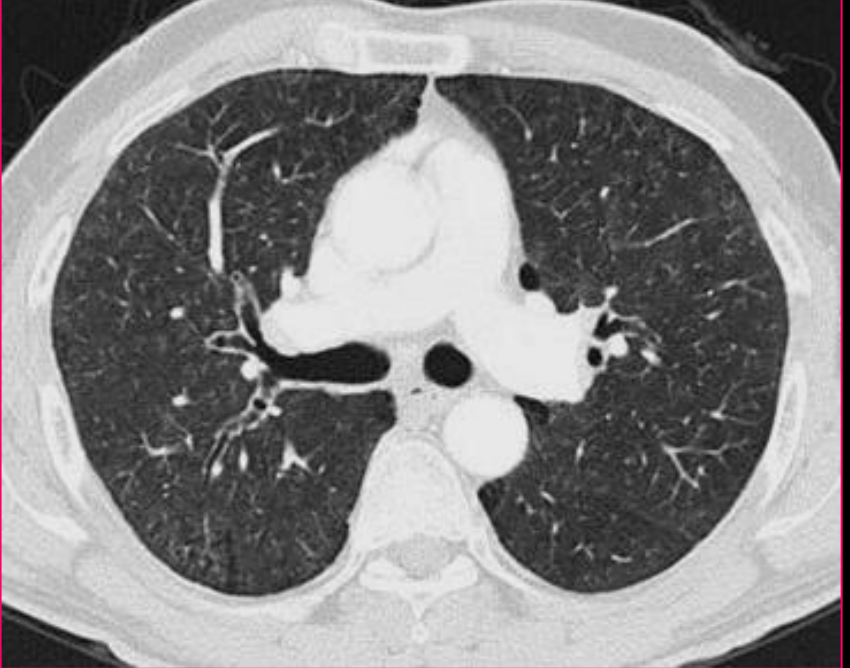
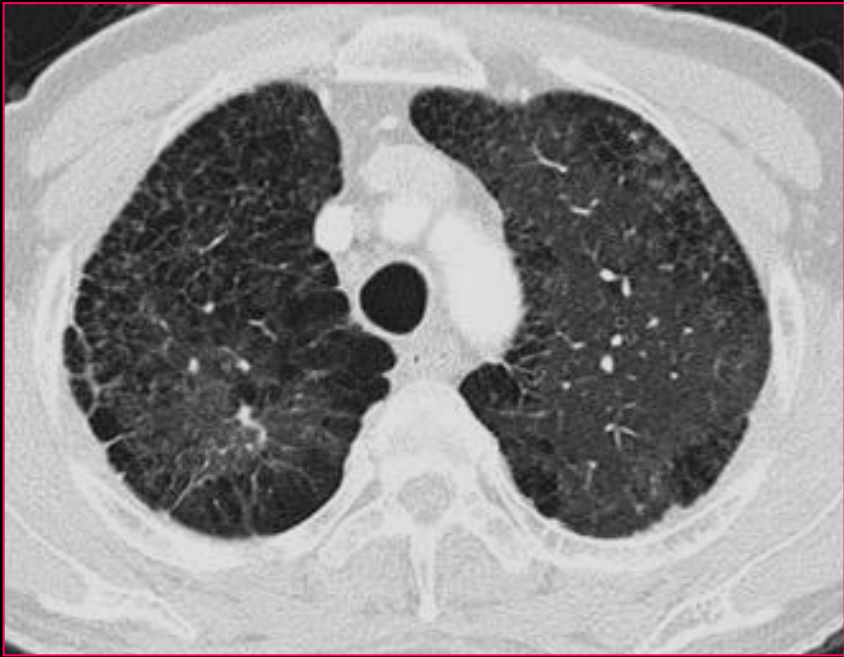


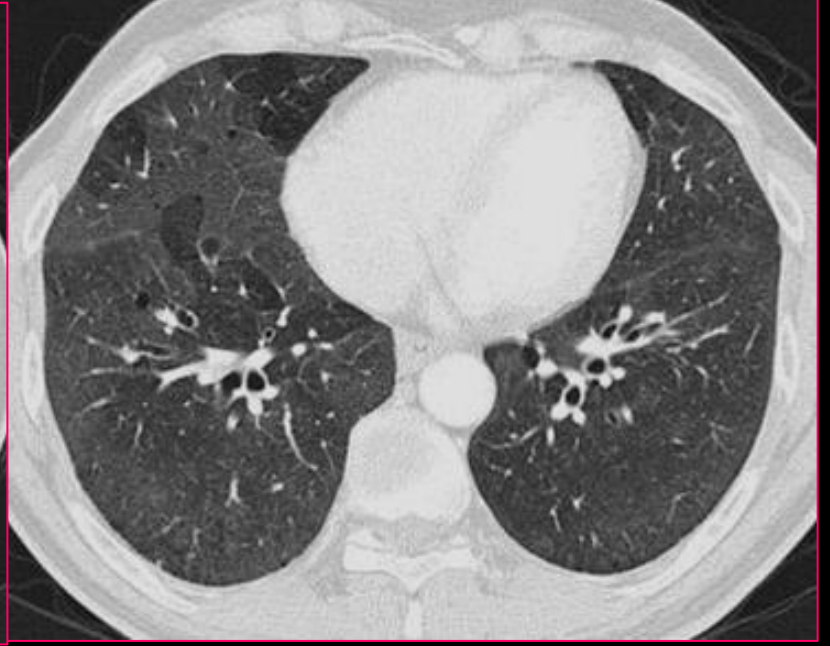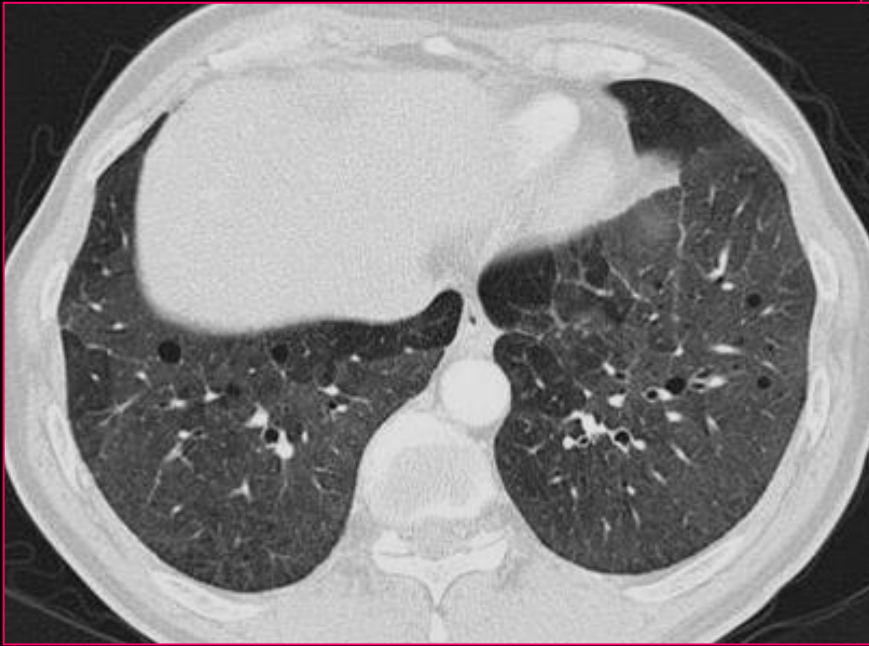Sarkoidoz

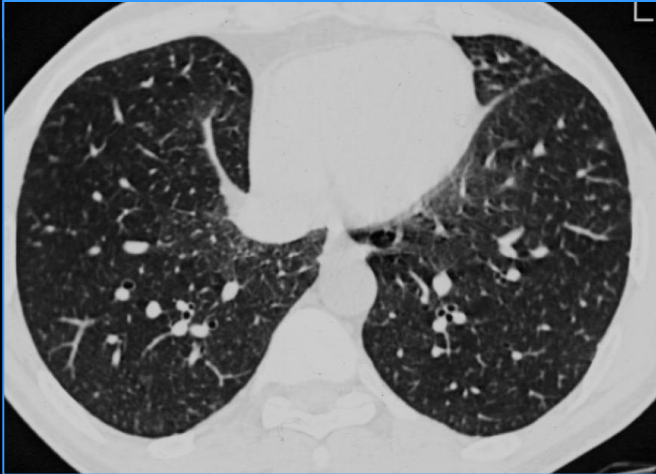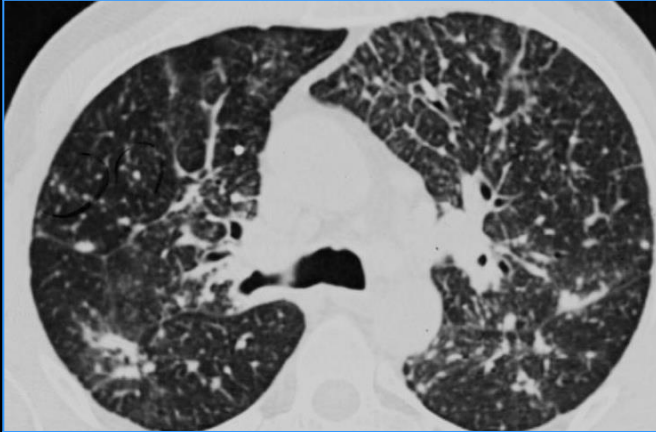
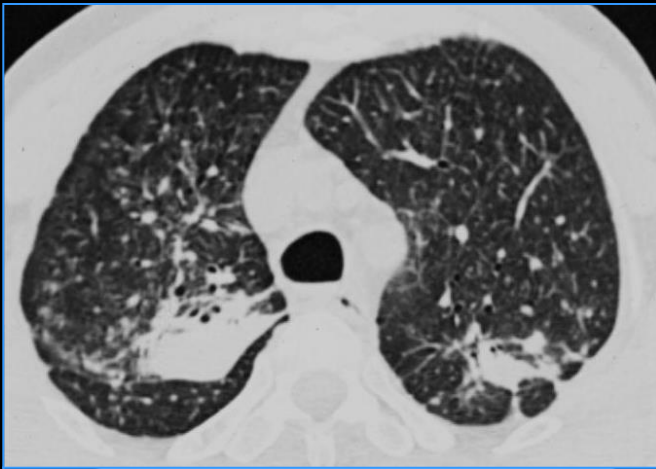


Sarkoidoz



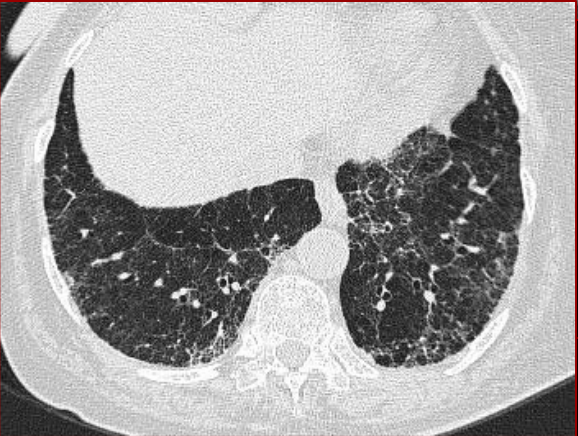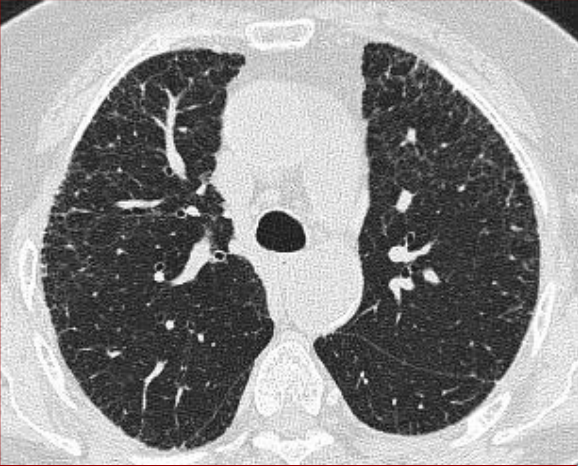

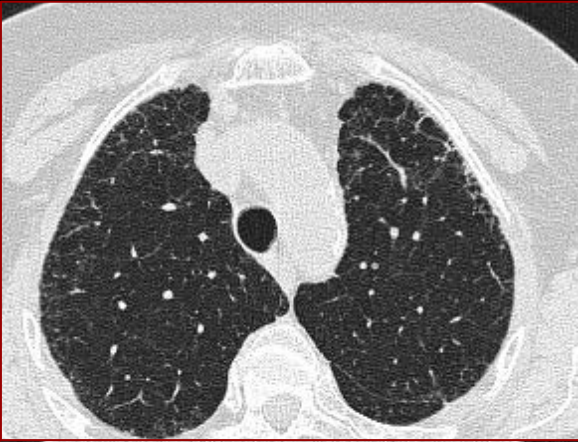
DIP



Üst Zonlar

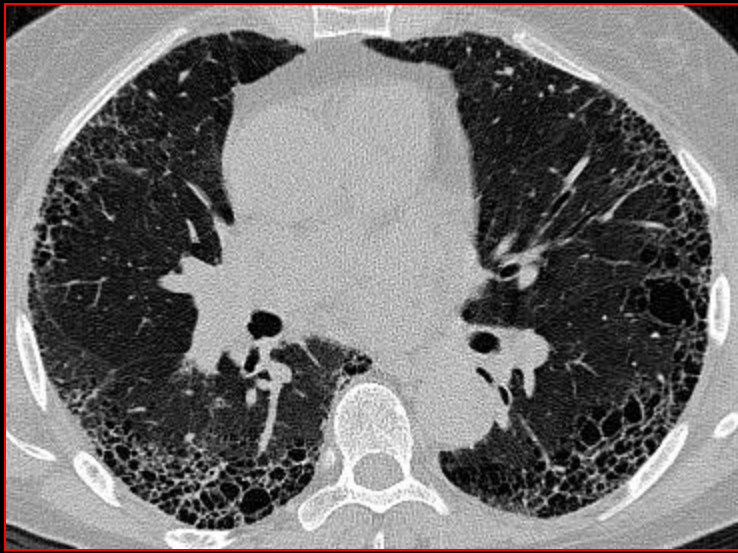- Silikozis
- Kömür işçileri P.
- Sarkoidoz
- Langerhans HH
- Ankilozan spondilit



Alt Zonlar

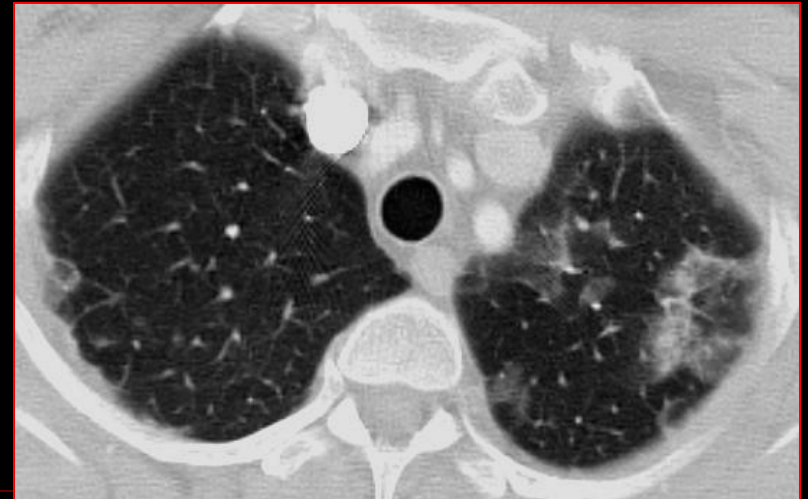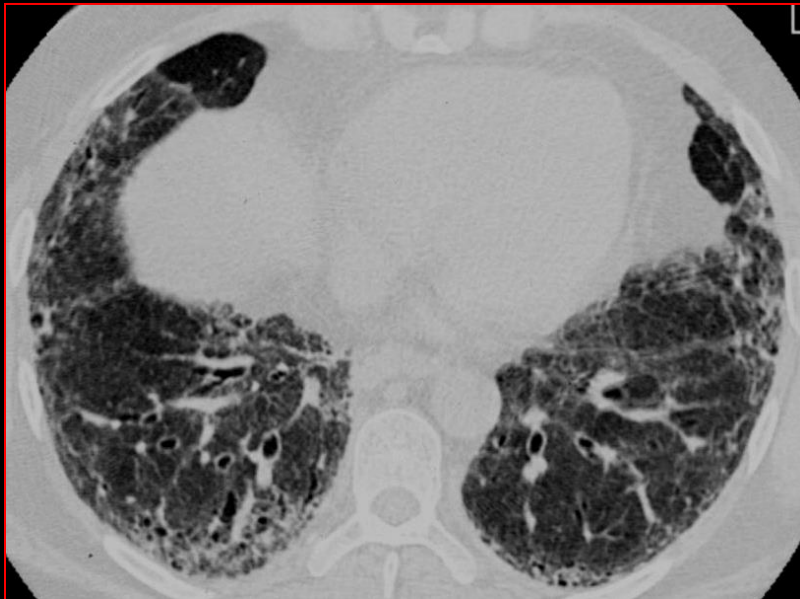
- İdyopatik PF
- Asbestoz
- Kollajen doku h. PF
- İlaç etkisi

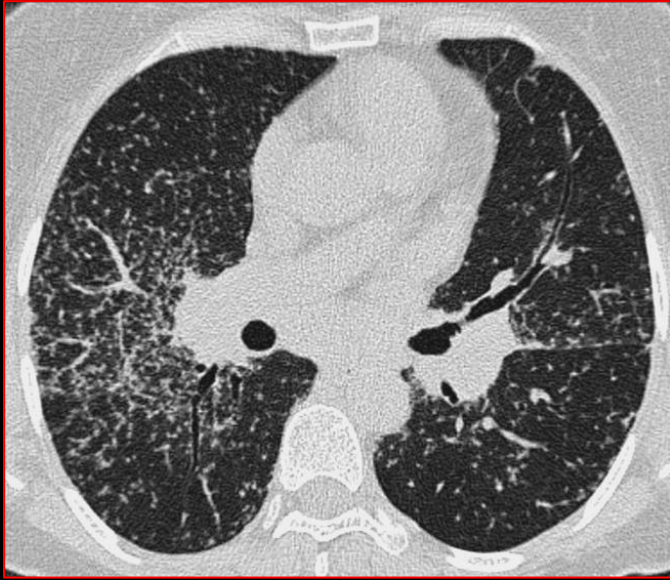
Skleroderma



Periferik

- İdyopatik PF
- Kriptojenik OP
- Kronik eozinofilik p.





Santral

- Akciğer ödemi
- Pulmoner alveolar proteinozis
- Sarkoidoz
- Bazı lenfanjitik tümörler (Kaposi sar)
- Lenfoma

