



GİRİŐİMSEL PULMONOLOJİ TEKNİKLERİ KİME NE ZAMAN VE OLGULAR

PROF.DR.MEHMET AKİF ZGL

SB BAŐAKŐEHİR AM VE SAKURA őEHİR HASTANESİ

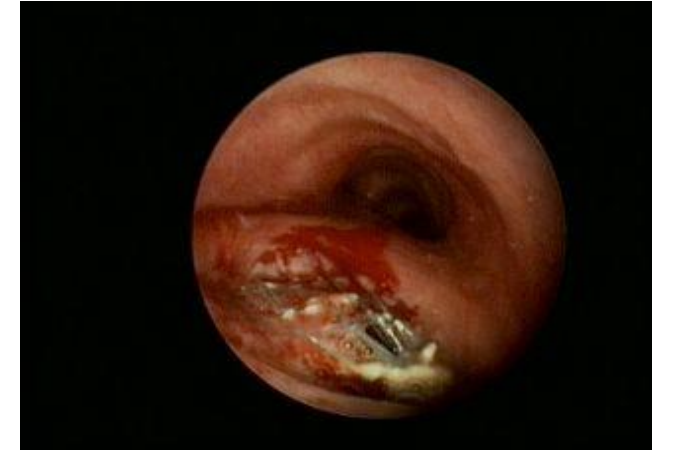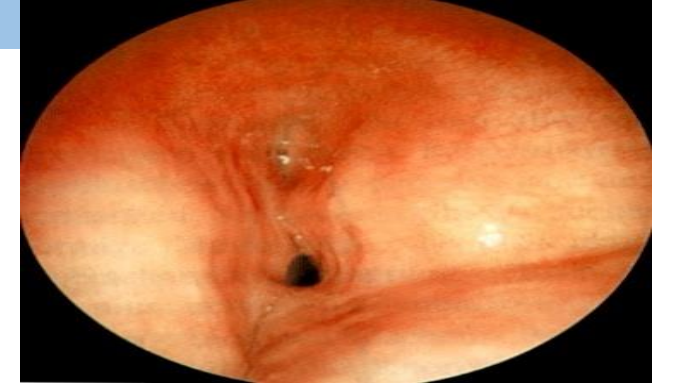TEDAVİ AMAÇLI BRONKOSKOPİ

- **1.Küratif**
 - **Karsinoma in situ**
 - **Periferik tümörler**
 - **Bening hava yolu obstrüksiyonları**
- **2.Palyatif**
 - **Malign hava yolu obstrüksiyonları**
 - **Hemoptizi**
 - **Fistüller**

Akciğer Kanseri - Ölüm

Akciğer kanserli hastaların % 35-40'ı lokal hastalığın progresyonundan ölürlər

- Malign Plevral /Perikardiyal Effüzyon
- Vena Cava Superior Sendromu
- Masif Hemoptizi
- Trakeo Özefagial Fistül
- Büyük Hava Yolu Darlıkları



Chen K, et al. J Emerg Med. 1998;16(1):83-92.

Ernst A, et al. Am J Respir Crit Care Med. 2004;169(12):1278-1297.

Carrol et al. Eur J Cancer Clin Oncol 1986;22:1352-56

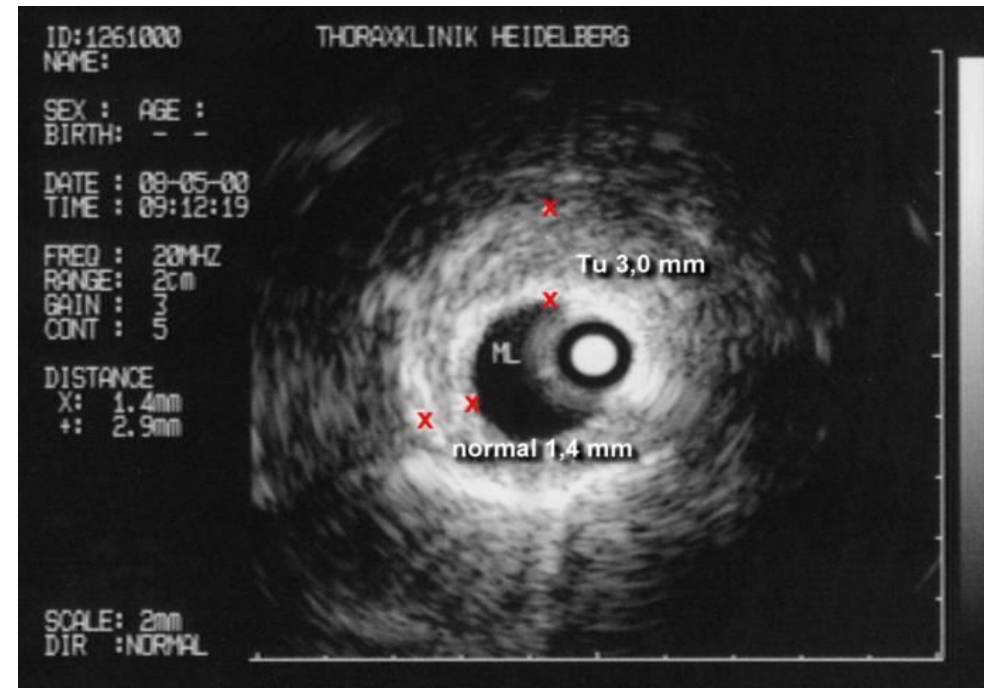
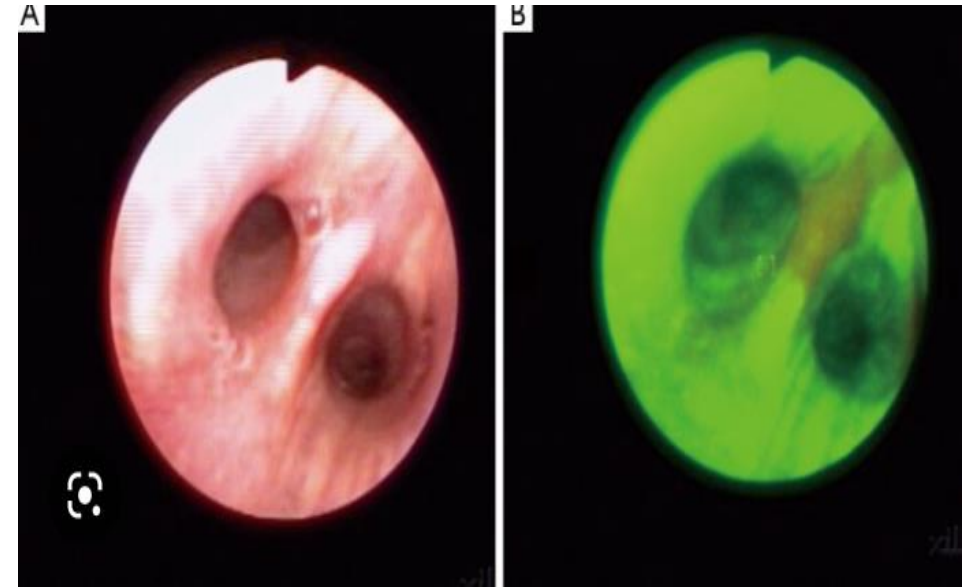
Karsinoma in situ

.Fotodinamik tedavi

.Brakiterapi

.Sıcak tedaviler

.Kriyoterapi



Review

Endoscopic Technologies for Peripheral Pulmonary Lesions: From Diagnosis to Therapy




Alberto Fantin ^{1,*}, Massimiliano Manera ², Vincenzo Patruno ¹ , Giulia Sartori ², Nadia Castaldo ¹ 
and Ernesto Crisafulli ² 

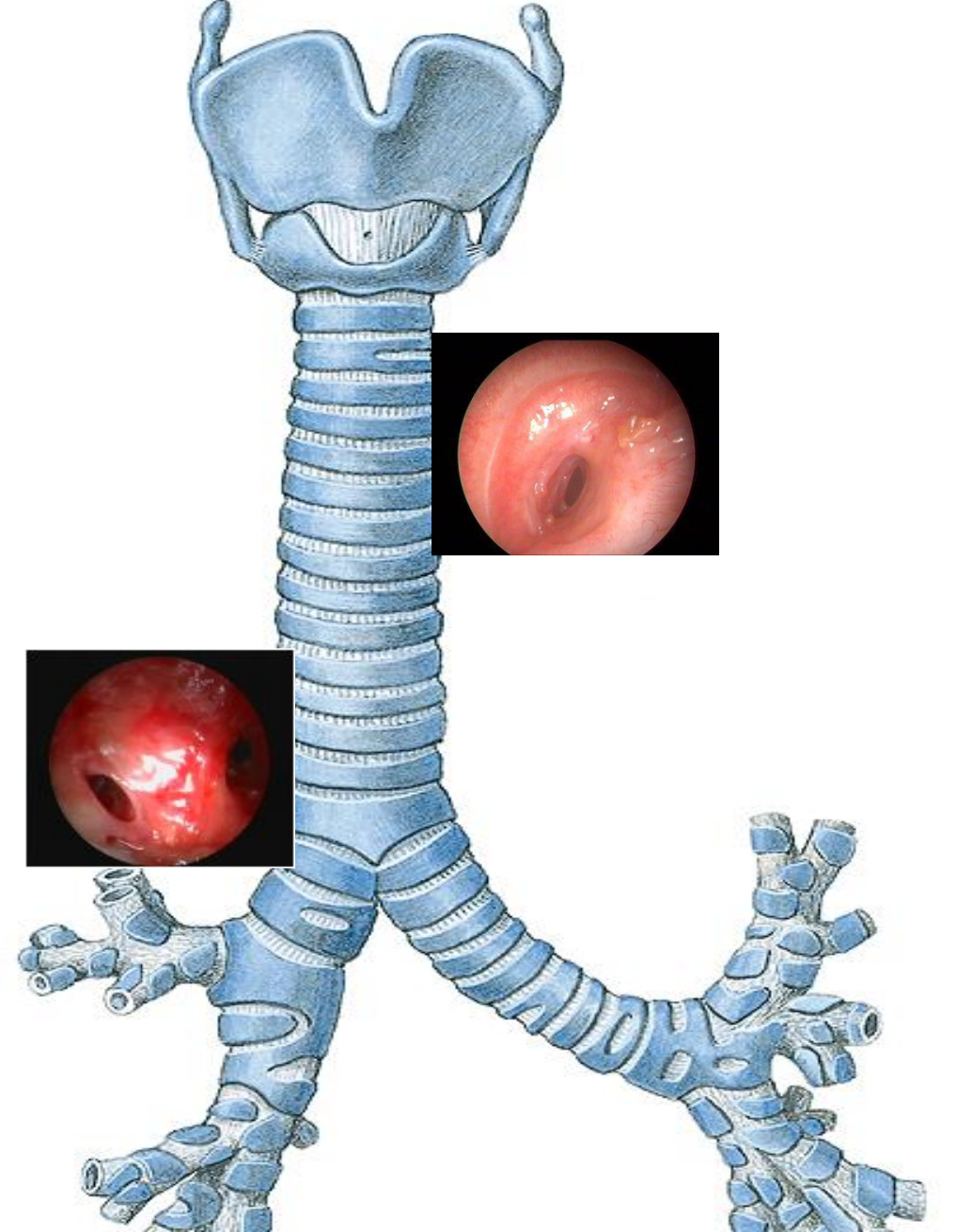
Table 2. Ablation technologies for PLEs and related mechanisms of action.

Method	Mechanism of Action
RFA	Electromagnetic-induced selective heat damage
MWA	Microwave-induced selective heat damage
PDT	Oxidative damage by a photosensitizing agent
Brachytherapy	Selective, high-dose radiation exposure
Cryoablation	Freezing-induced cytotoxicity and delayed cell apoptosis
BLITT	Heat-induced damage and charring
Thermal vapor ablation	Vapor-induced regional heat damage
Intralesional therapeutic drugs	Direct injection of an antineoplastic drug

RFA, radiofrequency ablation; MWA, microwave ablation; PDT, photodynamic therapy; BLITT, bronchoscopic laser interstitial thermal therapy; AEs, adverse events.


Stenozlarda Tedaviyi Etkileyen Faktörler

- Etyoloji
- Havayolu darlığının derecesi
- Stenozun uzunluğu
- Stenozun yeri
- Morfoloji (stenozun şekli/multifokal hastalık)



Bronkoskopik Teknikler İle

**Hava Yolu Açıklığı Sağlanarak
Yeterli oksijenasyon ve ventilasyon
ile**



- **Semptomlarda rahatlama, fonksiyonel düzelme**
- **Enfeksiyon Kontrolü**
- **Onkolojik tedaviye hazırlık (RT, KT)**



YAŞAM KALİTESİ ve SURVİ



Interventional pulmonology for patients with central airway obstruction

An 8-year institutional experience

[Chia-Hung Chen](#),^{a,b,c} [Biing-Ru Wu](#),^{a,e} [Wen-Chien Cheng](#),^{a,e,d} [Chih-Yu Chen](#),^{a,e} [Wei-Chun Chen](#),^{a,e,d} [Te-Chun Hsia](#),^{a,b,d} [Wei-Chih Liao](#),^{a,c,d,*} [Chih-Yen Tu](#),^{a,e,f,*} and [Wu-Huei Hsu](#)^{a,e}

Medicine®

Variable	No., %
Endoscopic success	583 (95)
Mortality after procedure	4 (0.7)
Major morbidity	
Halitosis	41 (6.7)
Iatrogenic pneumonia	24 (3.9)
Granulation tissue formation	16 (2.6)
Stent infections	11 (1.8)
Stent migration	8 (1.3)
Stent fracture	2 (0.3)
Pneumothorax	6 (1.0)

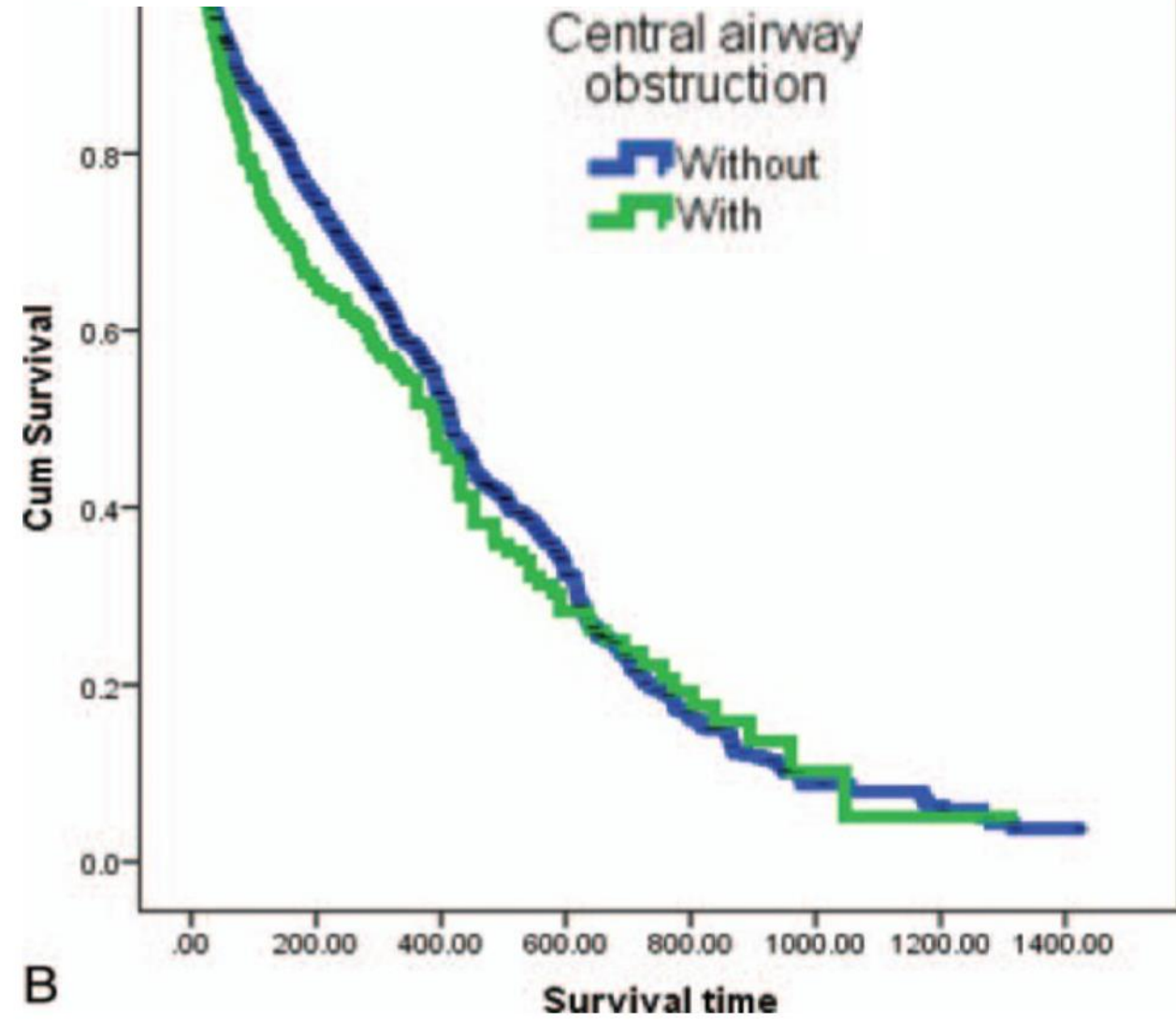
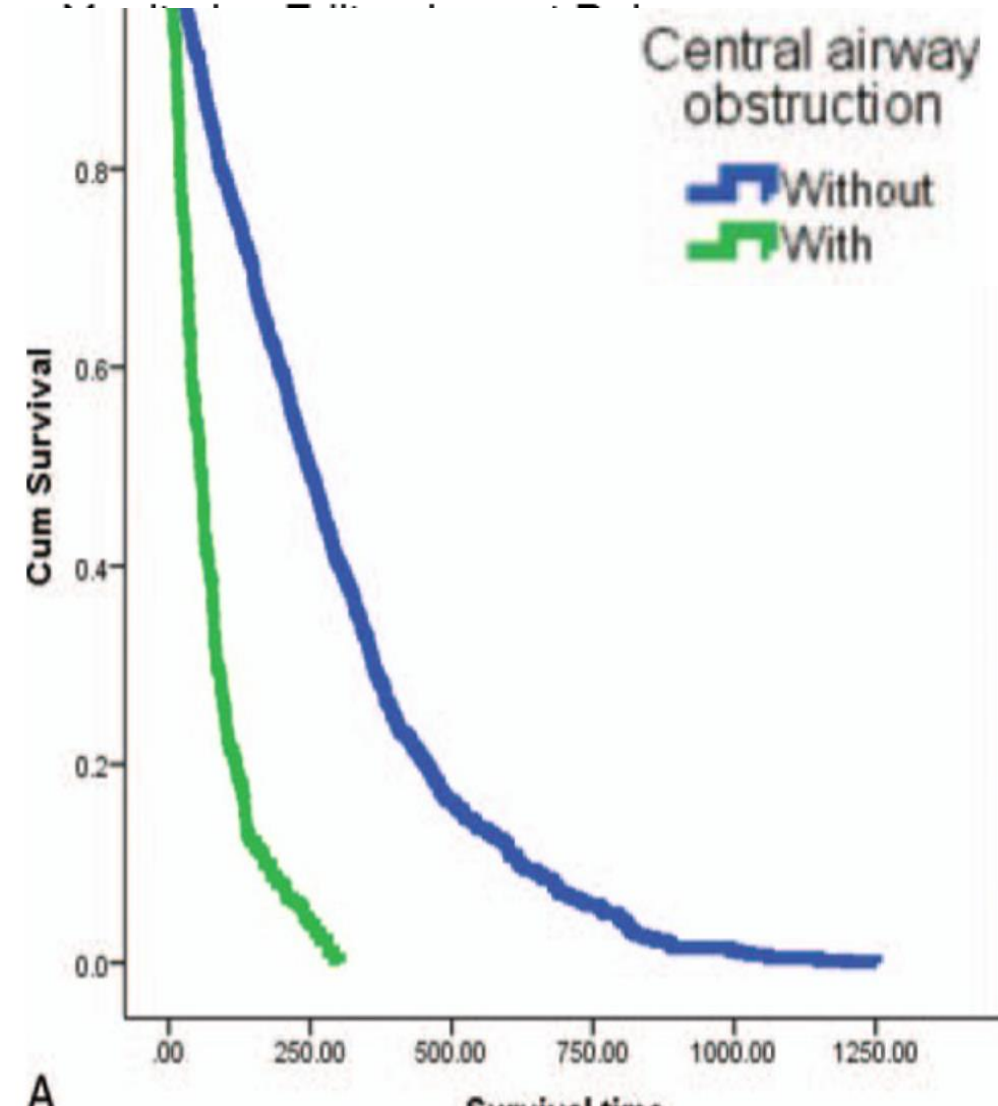
Interventional pulmonology for patients with central airway obstruction

An 8-year institutional experience

[Chia-Hung Chen](#)^{a,b,c} [Biing-Ru Wu](#)^{a,e} [Wen-Chien Cheng](#)^{a,e,d} [Chih-Yu Chen](#)^{a,e} [Wei-Chun Chen](#)^{a,e,d} [Te-Chun Hsia](#)^{a,b,d}
[Wei-Chih Liao](#)^{a,c,d,*} [Chih-Yen Tu](#)^{a,e,f,*} and [Wu-Huei Hsu](#)^{a,e}

[Medicine \(Baltimore\)](#). 2017 Jan; 96(2): e5612.

Published online 2017 Jan 13. doi: [10.1097/MD.00000000000005612](https://doi.org/10.1097/MD.00000000000005612)

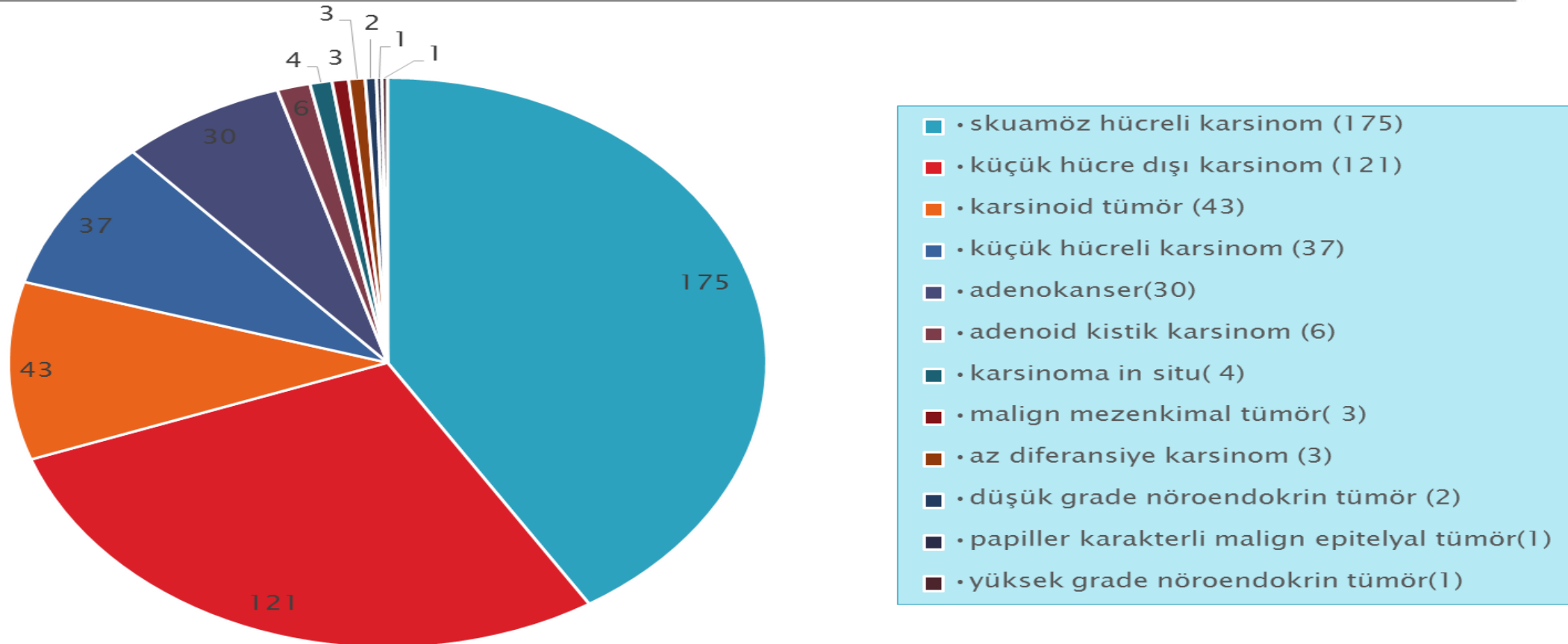


What have we learned in interventional pulmonology in the past decade?

Mehmet Akif ÖZGÜL¹ , Erdoğan ÇETİNKAYA¹ , Demet TURAN¹ ,
Efsun Gonca UĞUR CHOUSEIN^{1,*} , Deniz DOĞAN² , Ekrem Cengiz SEYHAN¹ 

¹Department of Pulmonology, Yedikule Chest Diseases and Thoracic Surgery Training and Research Hospital, Health Sciences University, İstanbul, Turkey

²Department of Pulmonology, Gulhane Training and Research Hospital, Health Sciences University, Ankara, Turkey



Endobronşiyal tedavi yöntemleri

• Sıcak yöntemler

**Elektrokoter,
Argon plazma koagulasyon(APC),
Lazer**

• Soğuk yöntemler

Kriyoterapi

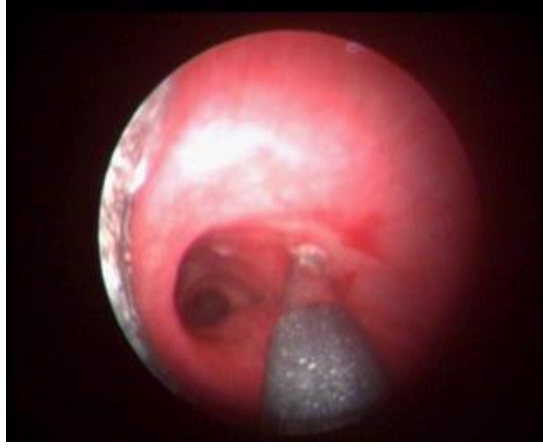
- **Rijid bronkoskopi mekanik temizleme**
- **Dilatasyon**

Endobronşiyal stent uygulanması

Brakiterapi

Fotodinamik tedavi

KRYOTERAPİ



FİZİKSEL ETKİ

Hızlı donma ve yavaş erime döngüsü ile hücre içi buz kristalleri oluşumu hücre içi asiditenin artması

VASKÜLER ETKİ

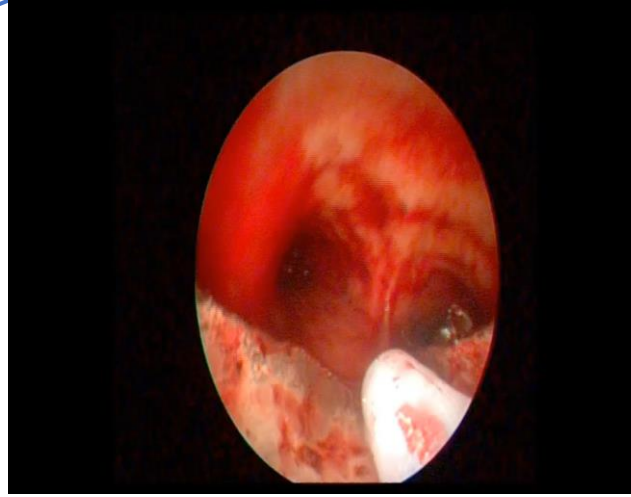
Vazokonstriksiyon (**İskemi**)
Trombosit agregasyonu (**Tromboz**)
Artmış kan viskozitesi

KRİYOTERAPİ

ENDİKASYON

Kriyoablasyon

- Egzofitik tümör
- Erken evre tümör
- Kriyoadeziv etki
- Kriyorekanalizasyon
- Kriyobiopsi ve Kriyo TBB
- Yabancı cisim



GÜVENLİK

Perforasyon riski

Rezidüel stenoz

Genişlik → 10 mm

Derinlik → 3 mm

Argon plazma koagulasyon

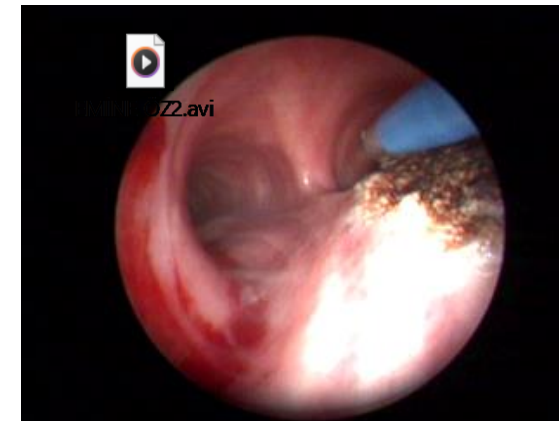
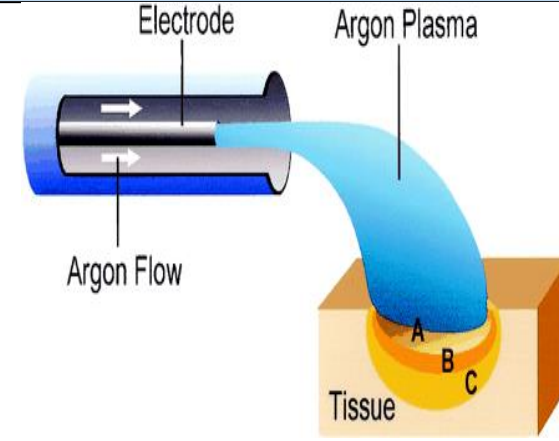
APC *nonkontak (doku teması yok)*

Yüksek voltajlı elektrik akımı ile termal koagülasyon sağlayan bir tür monopolar elektrokoterizasyondur.

- Gücü 40-120 watt, uygulama süresi 2 sn altında olduğunda penetresyonu 3 mm derinliğe kadar iner.
- Rekanalizasyon başarısı %67-92

Minimal manuplasyon ile daha geniş ve hızlı etki sağlayarak tümör koagülasyonu ve hemoptizi kontrolünde çok başarılı olur.

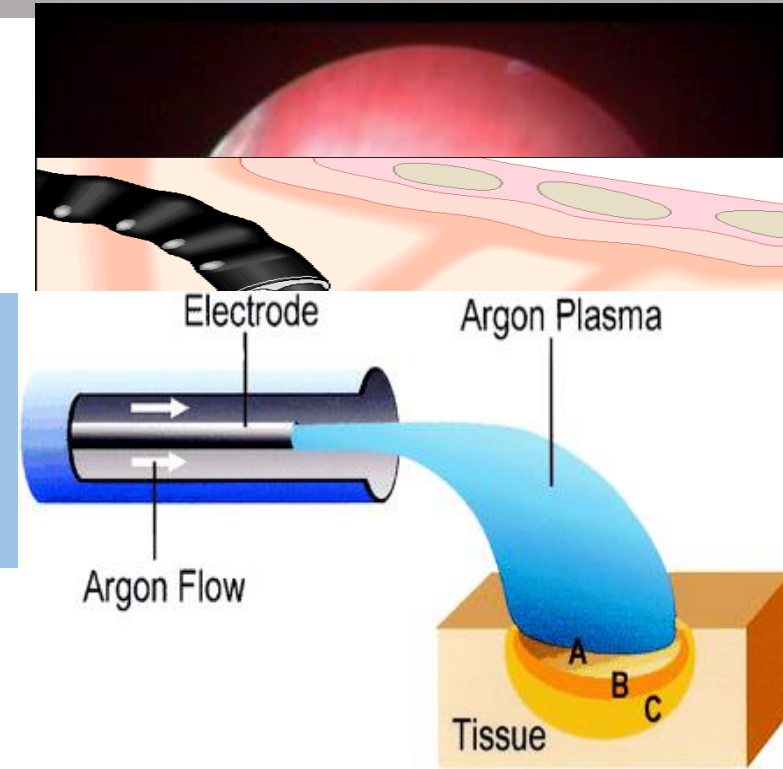
Stent granülasyon dokusu-APC



KARŞILAŞTIRMA


DOKU TEMASI

- Kriyoterapi
- Elektrokoter



PENETRASYON

- Kriyoterapi
- APC
- Elektrokoter
- Laser



Endobronşiyal tedavi yöntemleri

Hızlı etki

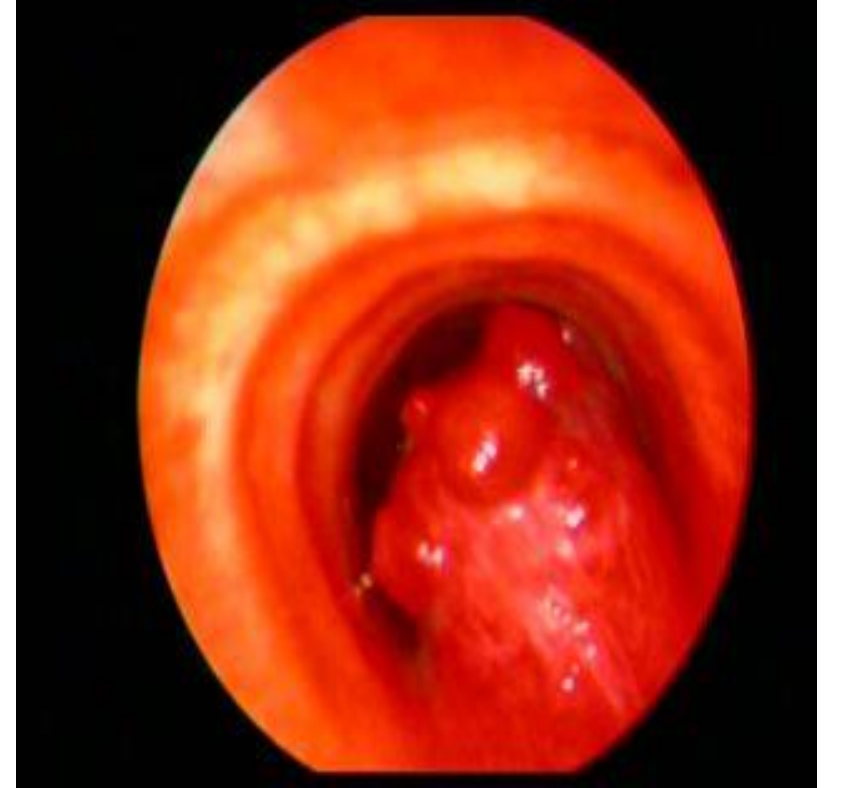
Mekanik debulking

Laser, APC

Stent

PDT

Kriyoterapi



SICAK YÖNTEMLER KOMPLİKASYON

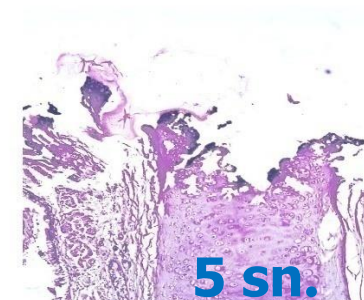
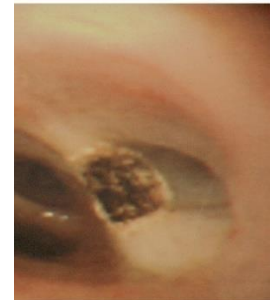
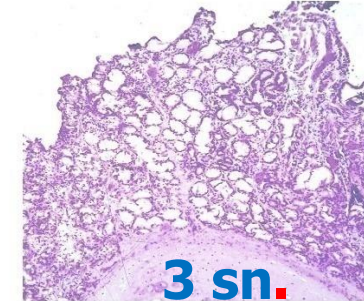
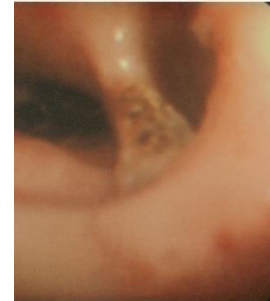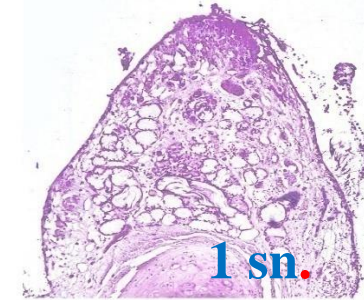
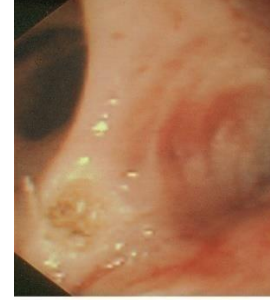
Hava yolu yanığı Perforasyon

NE YAPALIM?

FiO2 %40 dan az

Düşük güç

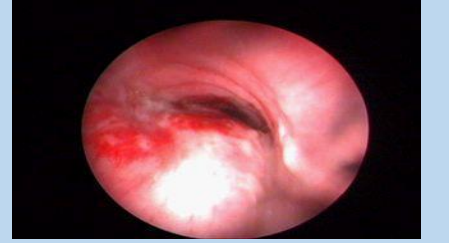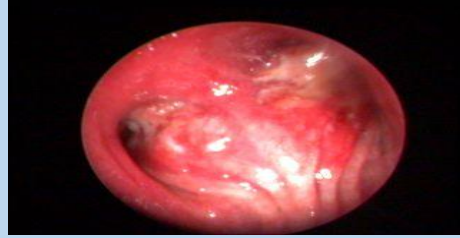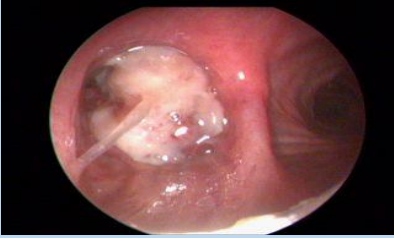Düşük uygulama zamanı



MALİNG HAVA YOLU OBS

**ACİL
RİJİT**

**ACİL DEĞİL
FOB YA DA RİJİT**

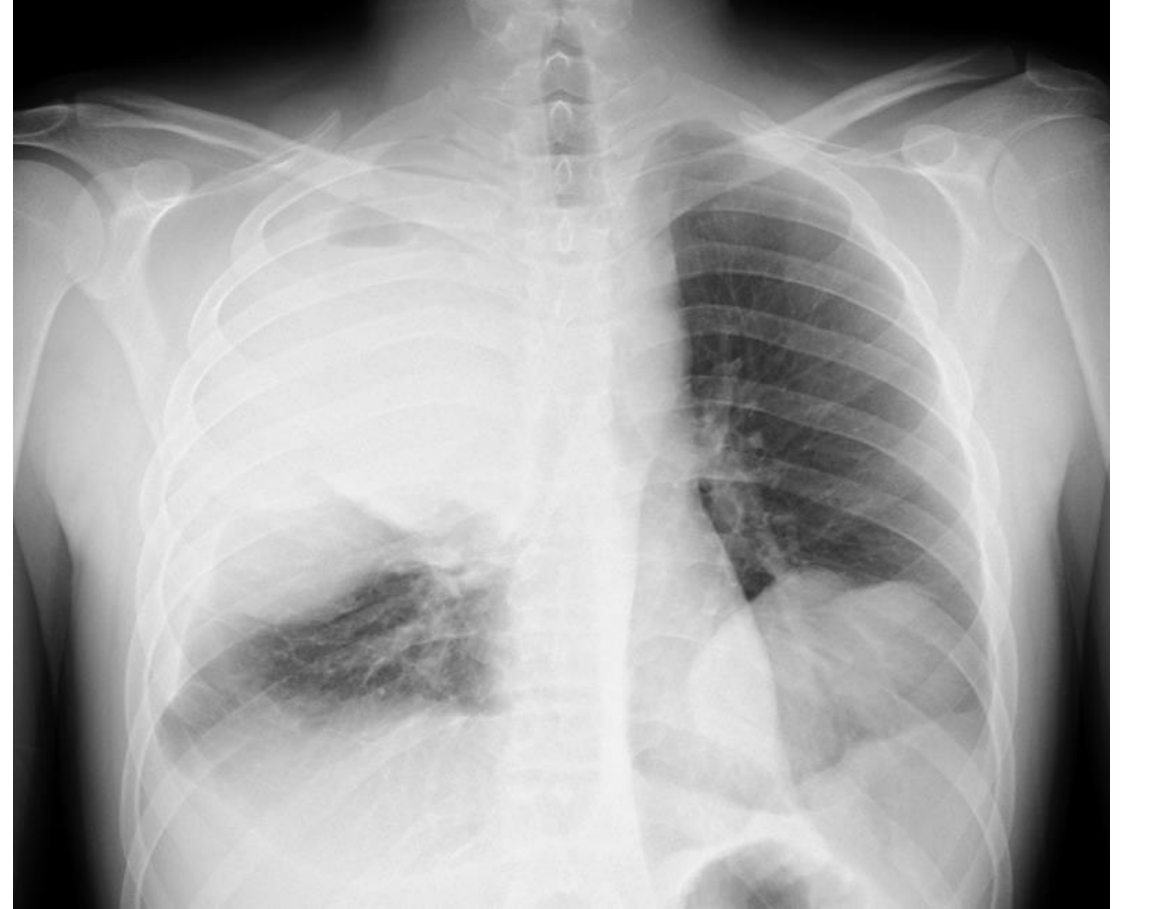

ABLATİF TEKNİKLER VE MEKANİK REZEKSİYON

STENT

OLGU 1

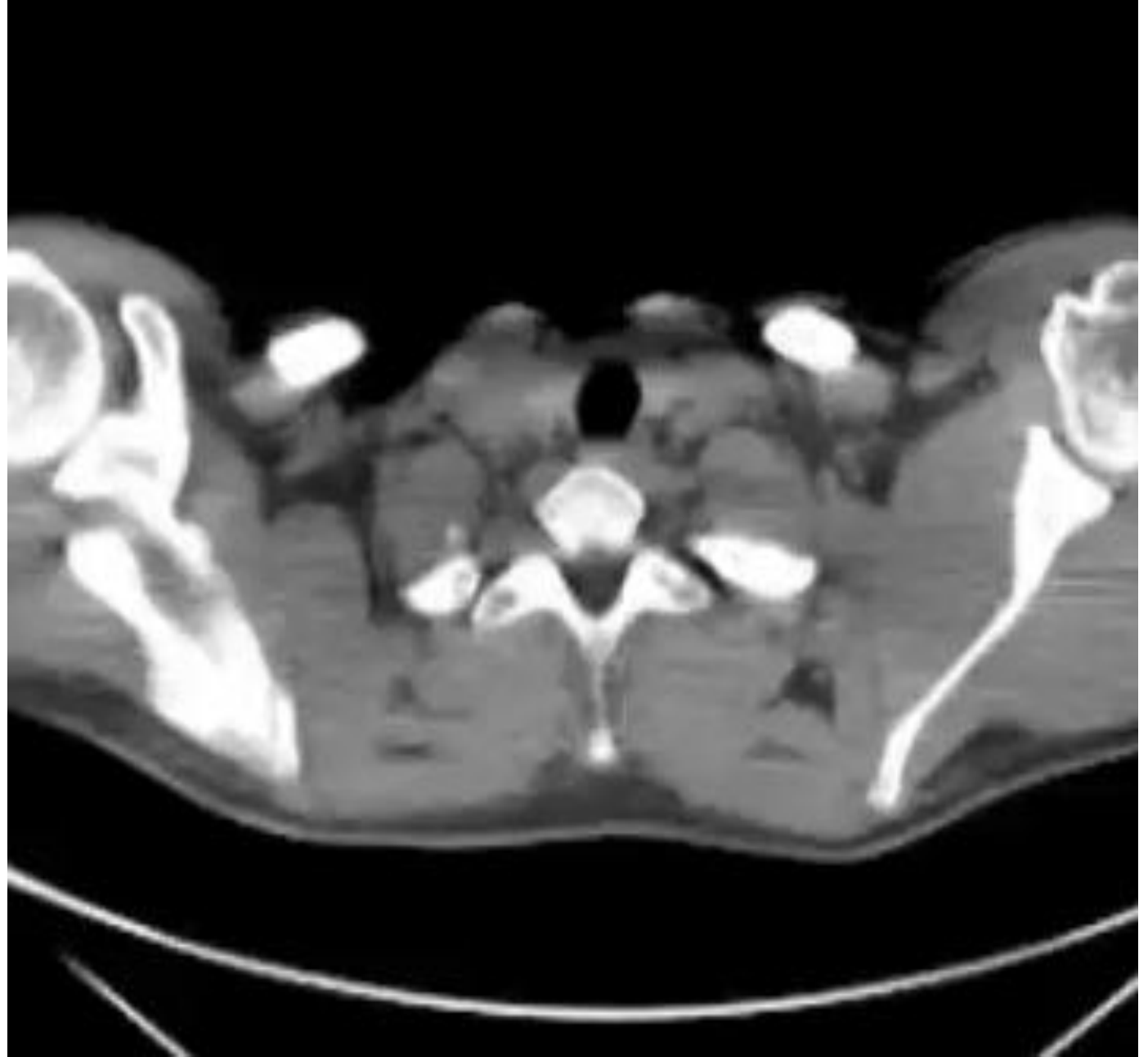
- 23 yaşımda, erkek
- Şikayeti: Nefes darlığı
- Hikayesi: Nisan 2018'de Ewing sarkomu tanısı ile onkolojik tedavi görmüş. 1.5 yıl kontrol altında kaldıktan sonra giderek artan nefes darlığı nedeni ile hastanemiz aciline başvurmuş ve interne edilmiş



PA AKCİĞER GRAFİSİ

OLGU 1

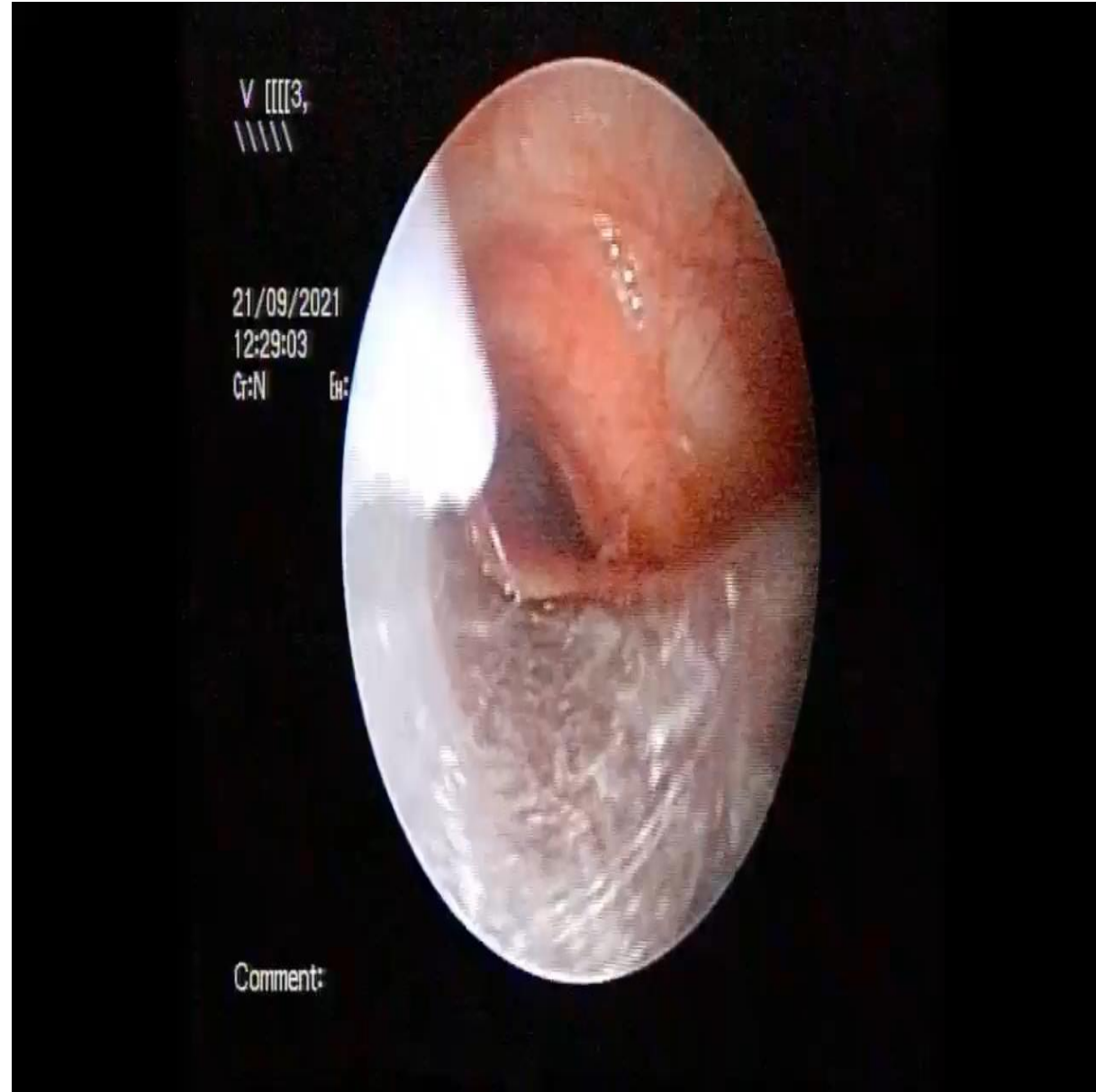
- Özgeçmiş: Ewing sarkomu (2018)
- Alışkanlık: 4p/yıl sigara, aktif içici
- Fizik muayene:
TA: 110/80 NDS: 130/dak
SDS: 30/dak
Solunum sistemi: stridor(+)
- Laboratuvar:
WBC: $14.39 \times 10^3/\mu\text{L}$ PLT: $579 \times 10^3/\mu\text{L}$
CRP: 132 mg/dL L



TORAKS BT

OLGU 1

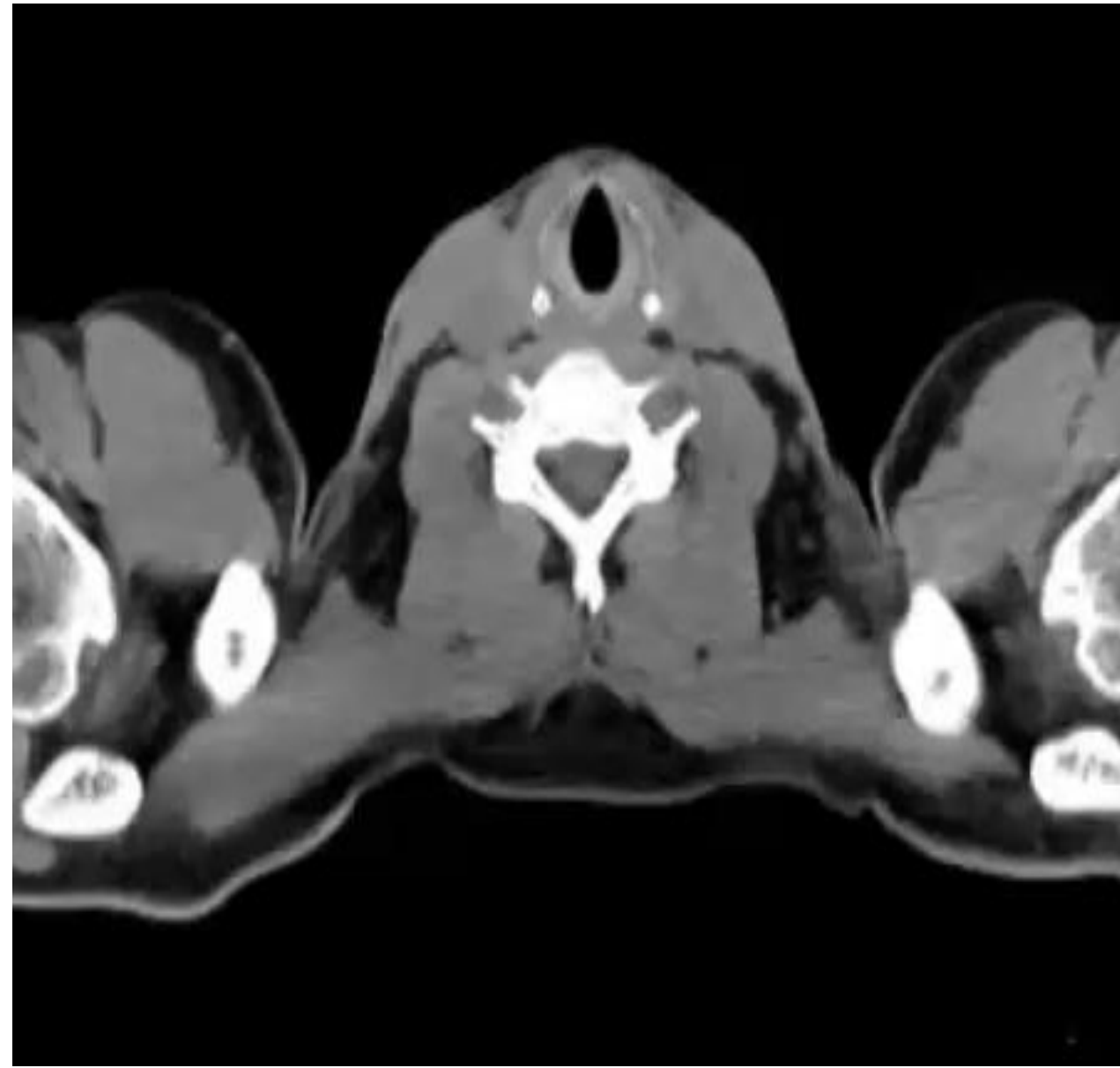
İşlem öncesi satürasyonu % 70
(16/dakika O2 ile)



İşlem sonrası
satürasyonu % 98
(2/dakika O2 ile)

OLGU 1

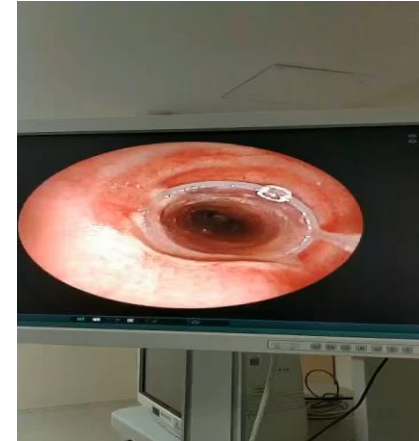
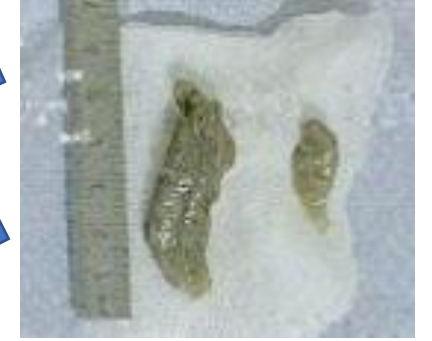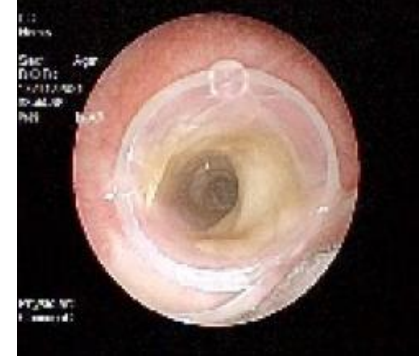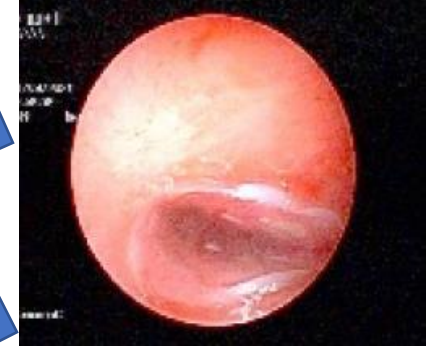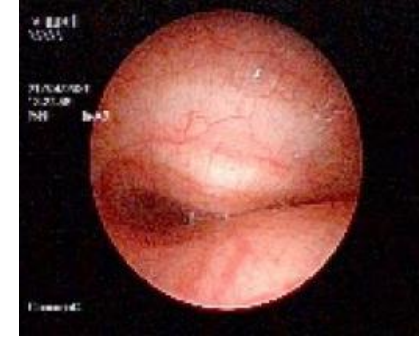- Hastamız onkolojik tedavisi devam etmekte. RT'ye sekonder ağır bir özofajit atağı geçirdi, bu nedenle oral alımı kısıtlanınca dehidrate kaldı
- Stentinde gelişen mukostaz nedeni ile 2 kez rijid bronkoskopi uygulandı
- Pulmozyme ile mukostazı da kontrol altına alındı



İŞLEM SONRASI TORAKS BT

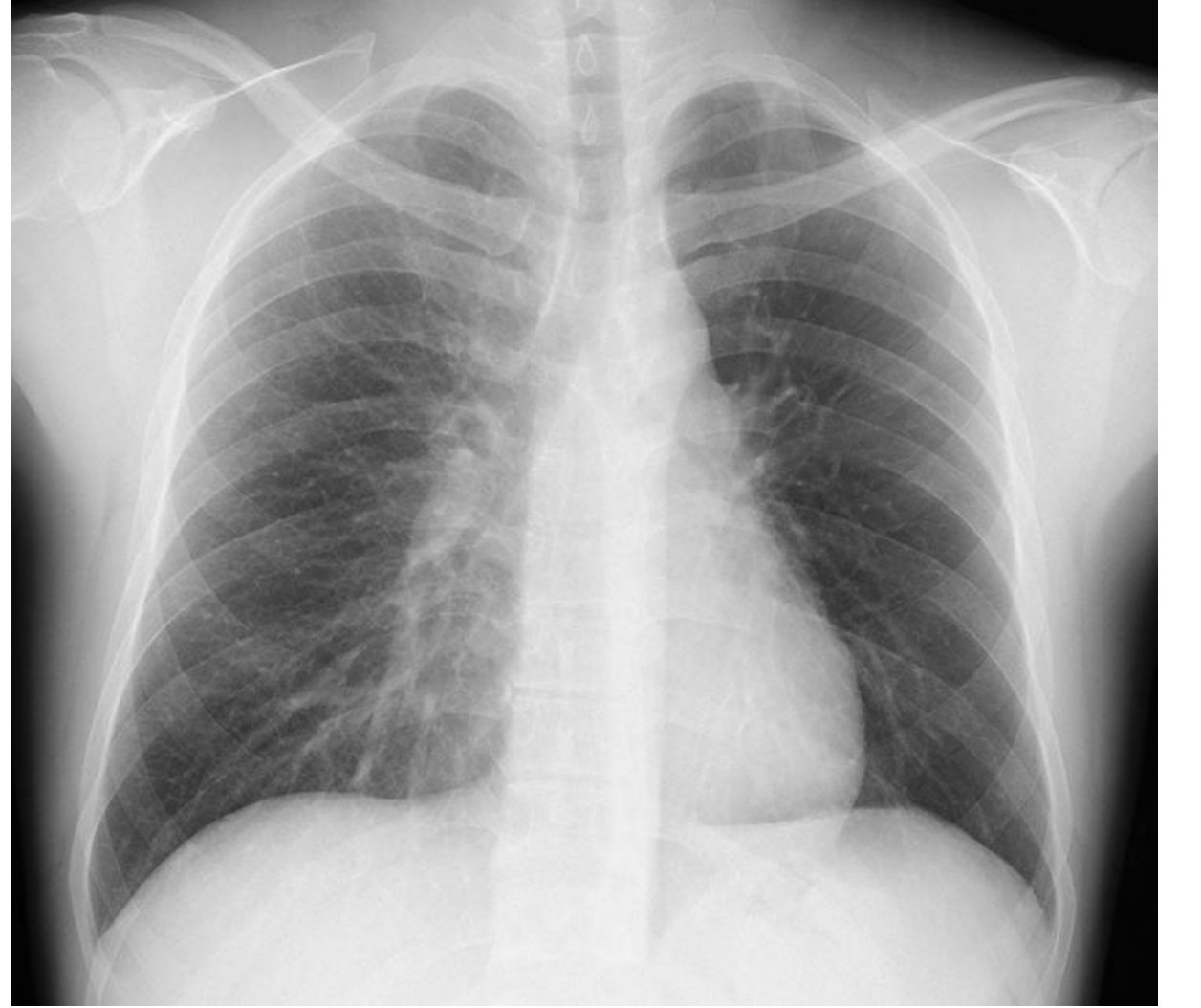OLGU 1

- Hastamız onkolojik tedavisi devam etmekte. RT'ye sekonder ağır bir özofajit atağı geçirdi, bu nedenle oral alımı kısıtlanınca dehidrate kaldı
- Stentinde gelişen mukostaz nedeni ile 2 kez rijid bronkoskopi uygulandı
- Pulmozyme ile mukostazı kontrol altına alındı.



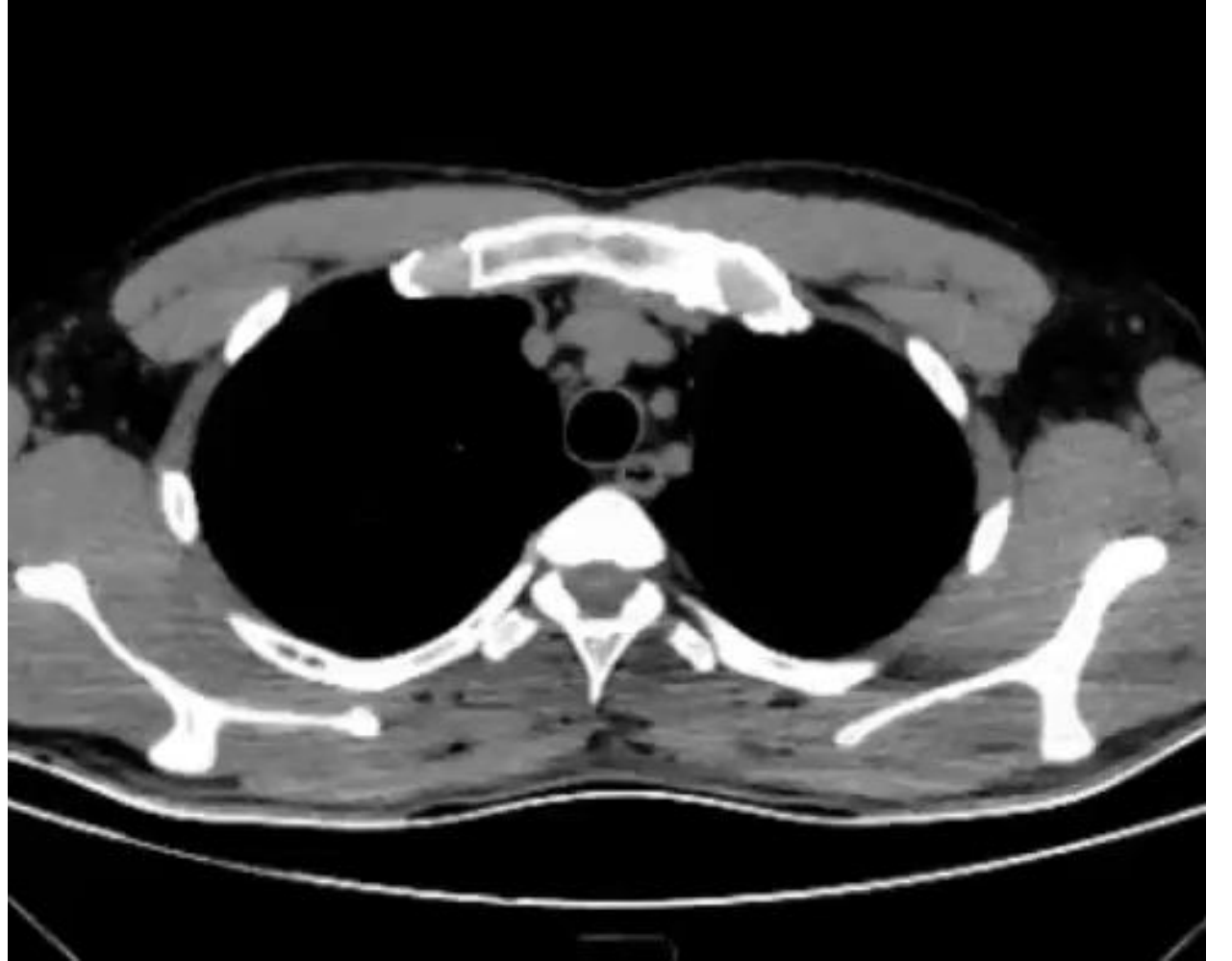
OLGU 2

- 34 yaşımda, erkek
- Şikayeti:Nefes darlığı, solunum sıkıntısı
- Hikaye: Diyarbakır'da 1 hafta önce bu şikayetleri üzerine çekilen BT ve sonrasında bronkoscopisinde sol ana bronşu tam oblitere eden kitle görülmesi üzerine biyopsi alınmayıp bize refere edilmiş



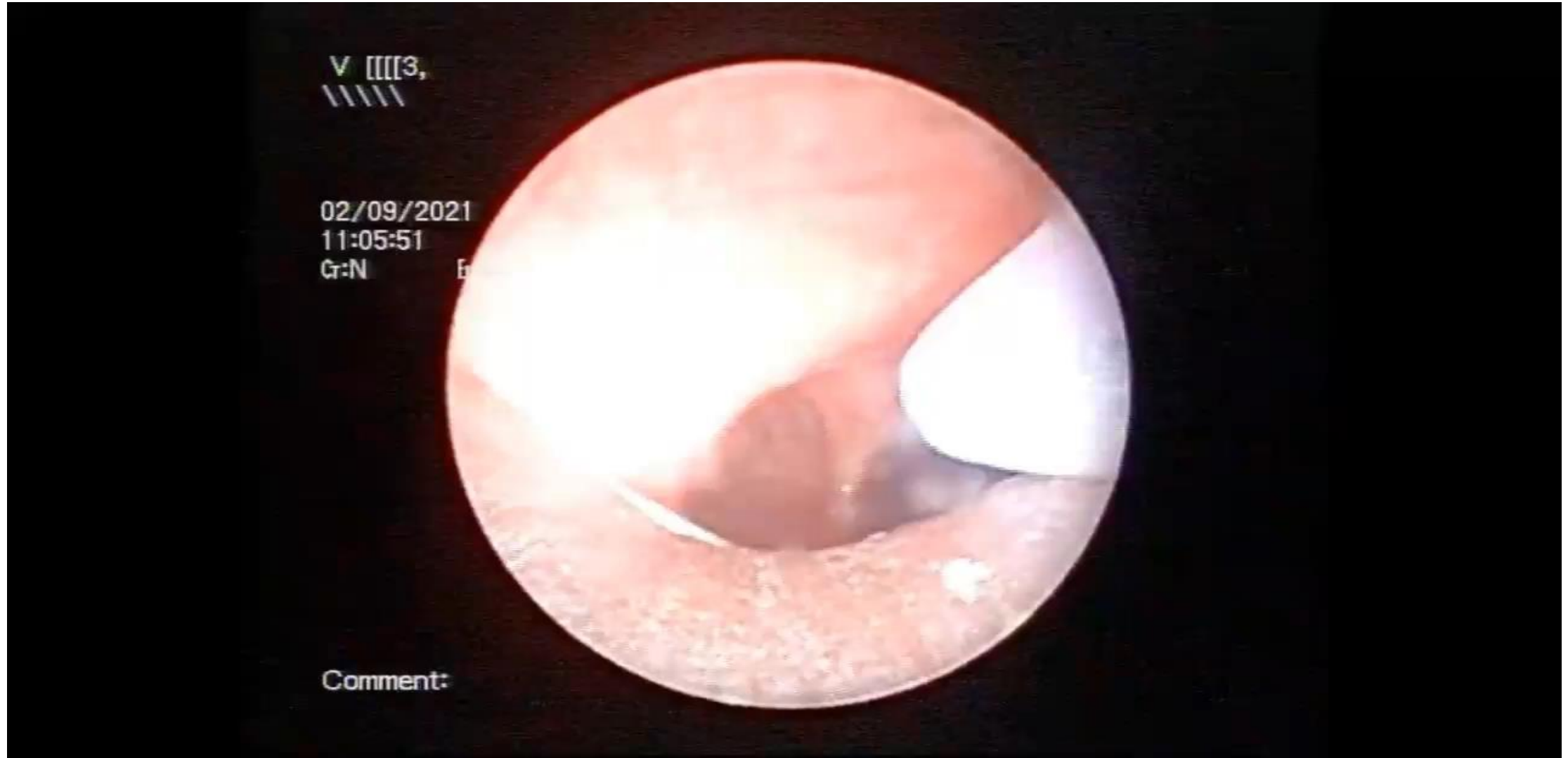
OLGU 2

- Özgeçmiş: Bir özellik yok
- Alışkanlık: Sigara: 15p/yıl, aktif içici
- Fizik Muayene:
 - TA: 100/70 NDS:78/dak
 - Sat: %95(oda) SDS: 13/dakika
 - Solunum sistemi: Solda solunum sesleri azalmış



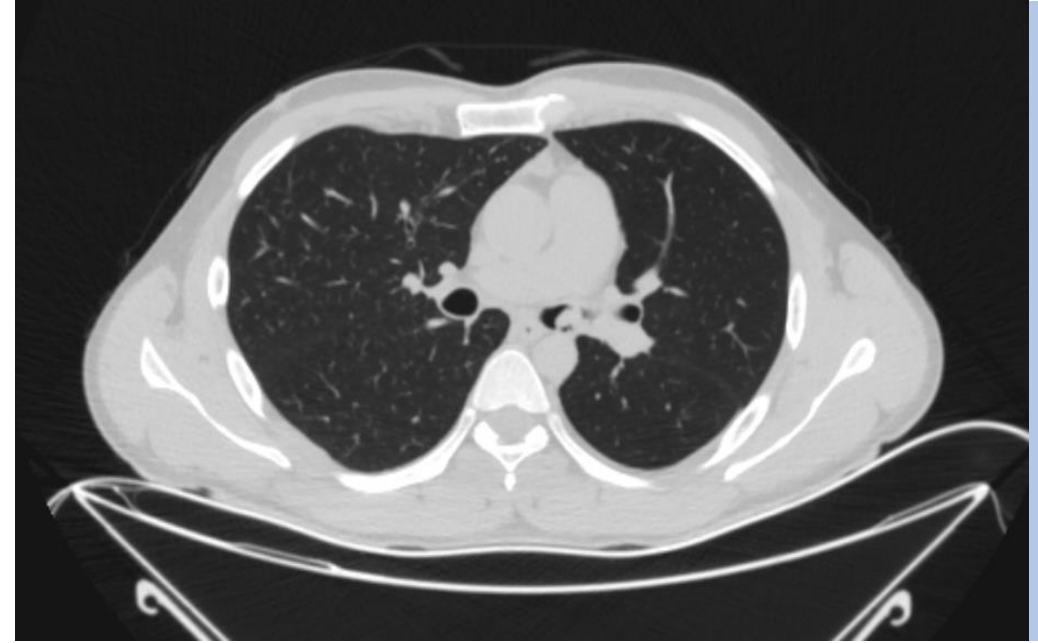
OLGU 2

RİJİD BRONKOSKOPİ

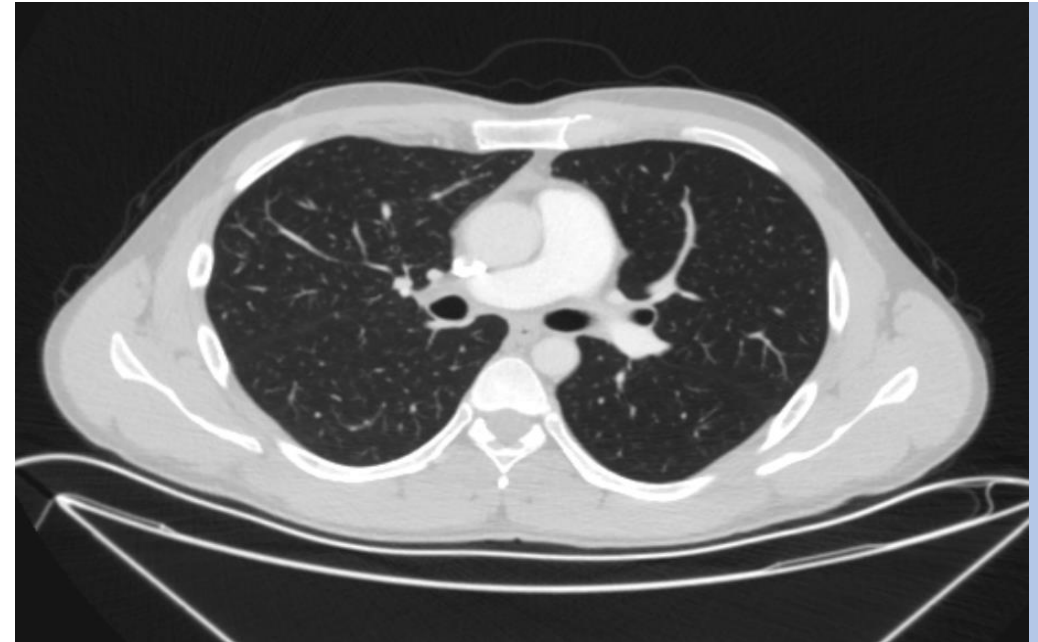

OLGU 2

- Patoloji: Düşük gradeli mukoepidermoid karsinom



Ö
N
C
E
S
İ



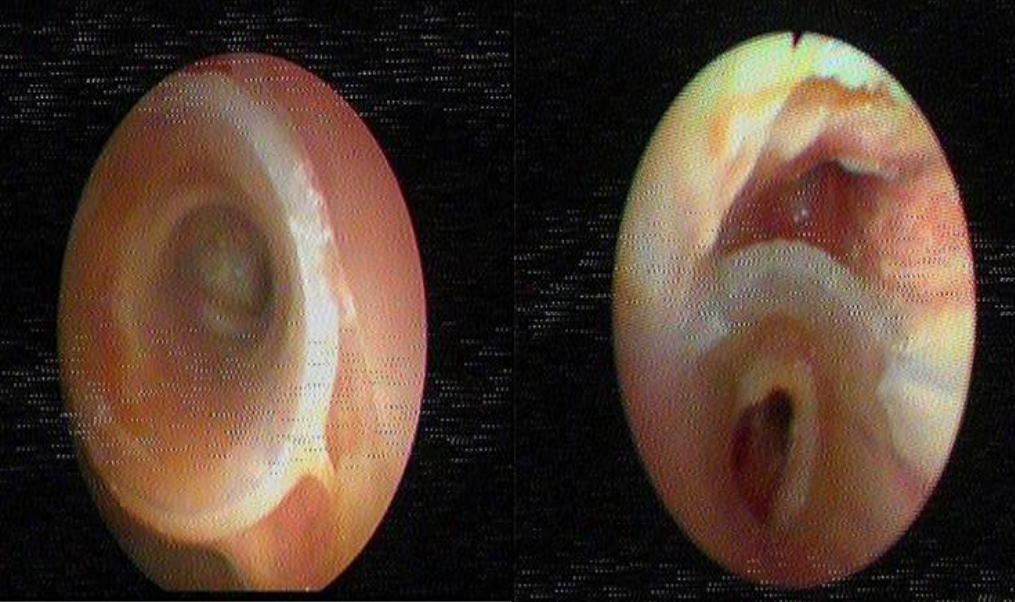
S
O
N
R
A
S
I

STENTLER


SİLİKON

METALİK

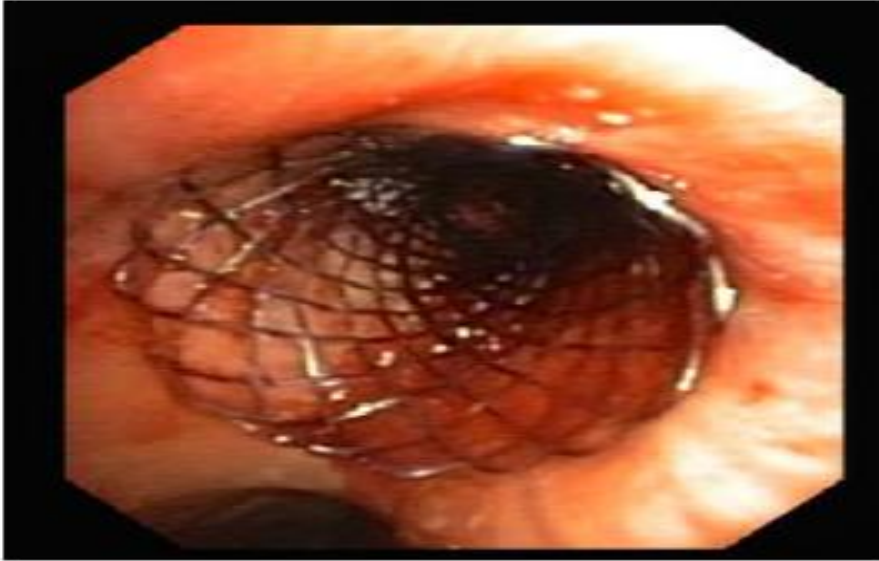
• Hava



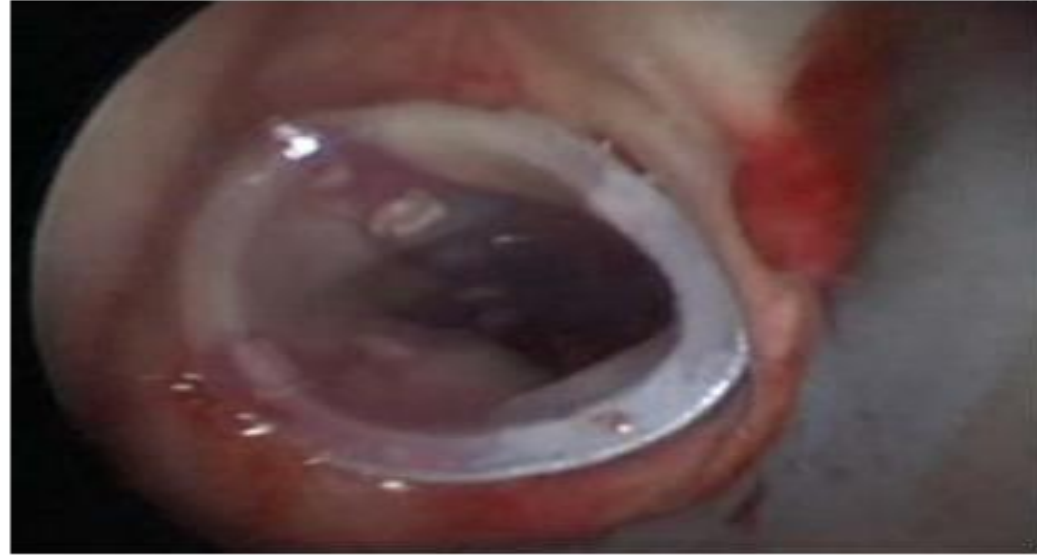- Pahalı
- Kalıcı
- FOB
- Lokal Anestezi
- **İdeal iç çap oranı**
- Modifiye edilemez
- **Hava yolu dinamiklerine adaptasyon**



Farklı duvar kalınlıkları

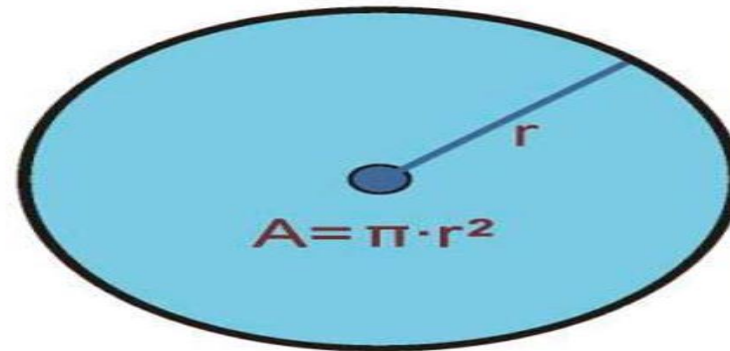


0.25 mm

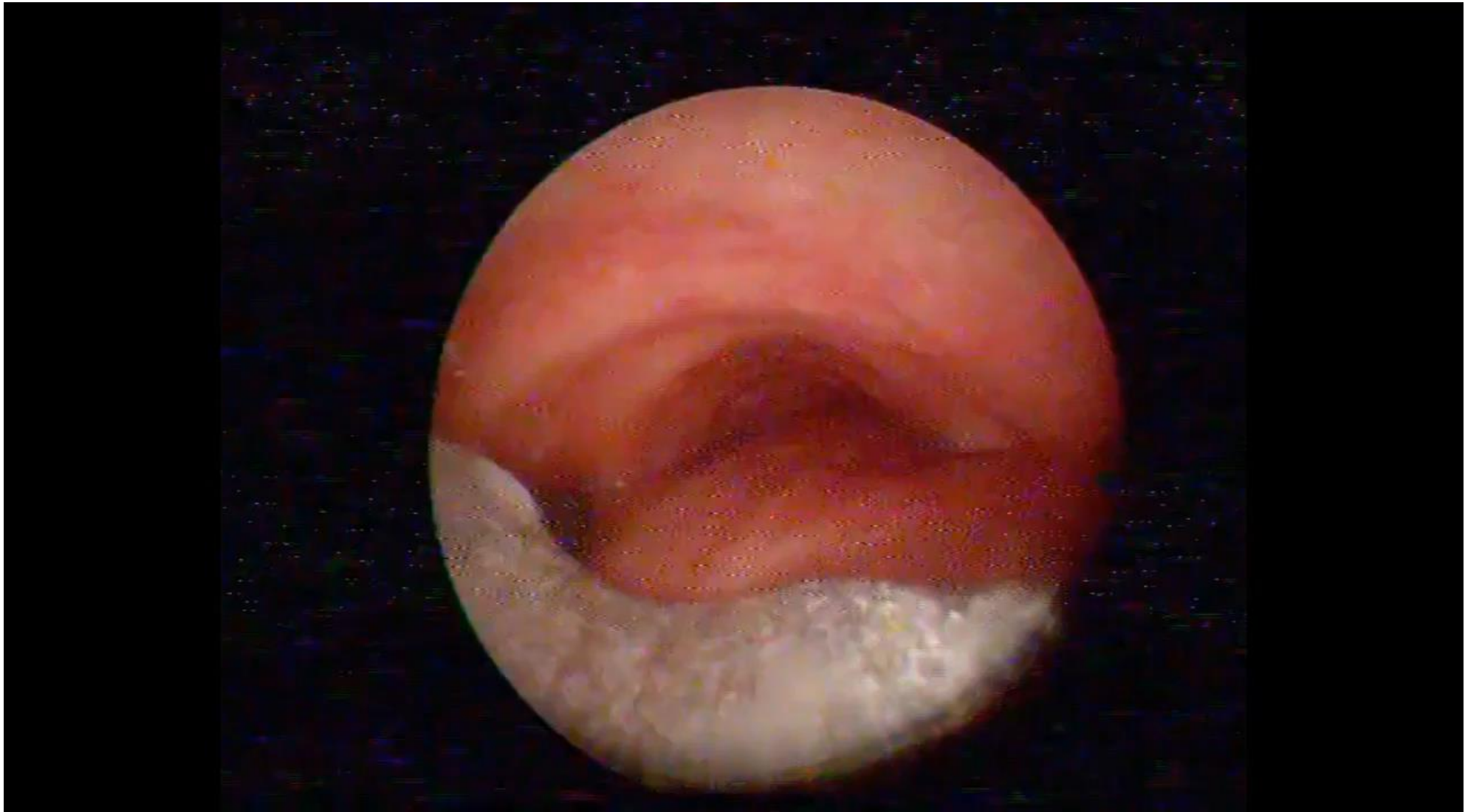


1.5 mm

 LIV SOCIETY
every breath counts



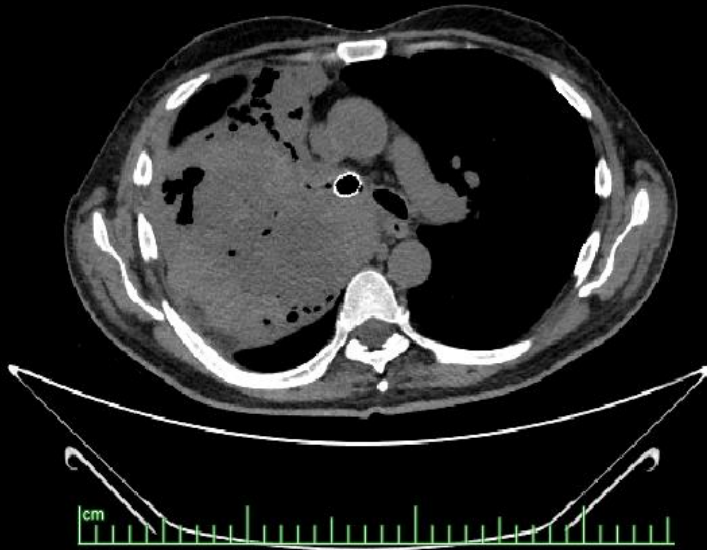
	Ext Diam	Int Diam	r	Area
SILICONE SEMS 14		11	5.5	95.03
SEMS	14	13.5	6.75	143.13
				48.105 mm2



OLGU

AYDIN OZDEMIR
049Y M
40786590920
1
07.02.2019 13:41:09
RESIM 82

Ingenuity CT
CHEST

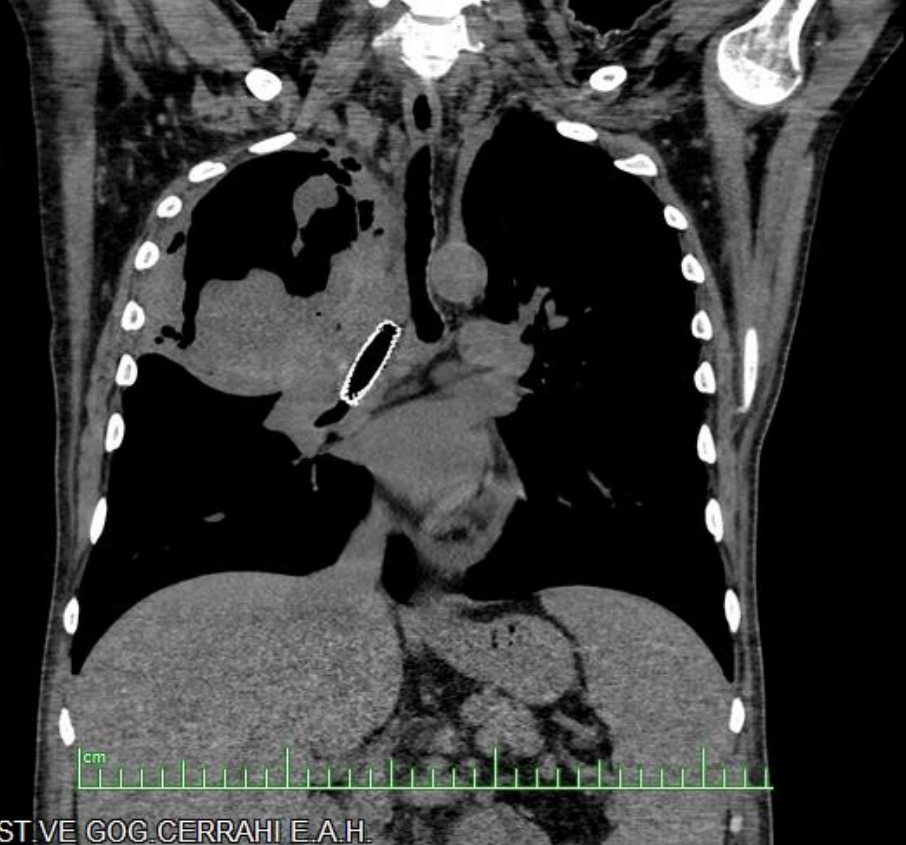

YEDIKULE GOG.HAST.VE GOG.CERRAHI E.A.H.

%100
W:350 C:60

AYDIN OZDEMIR
049Y M
40786590920
1
07.02.2019 13:41:09
RESIM 72

Ingenuity CT
CHEST



YEDIKULE GOG.HAST.VE GOG.CERRAHI E.A.H.

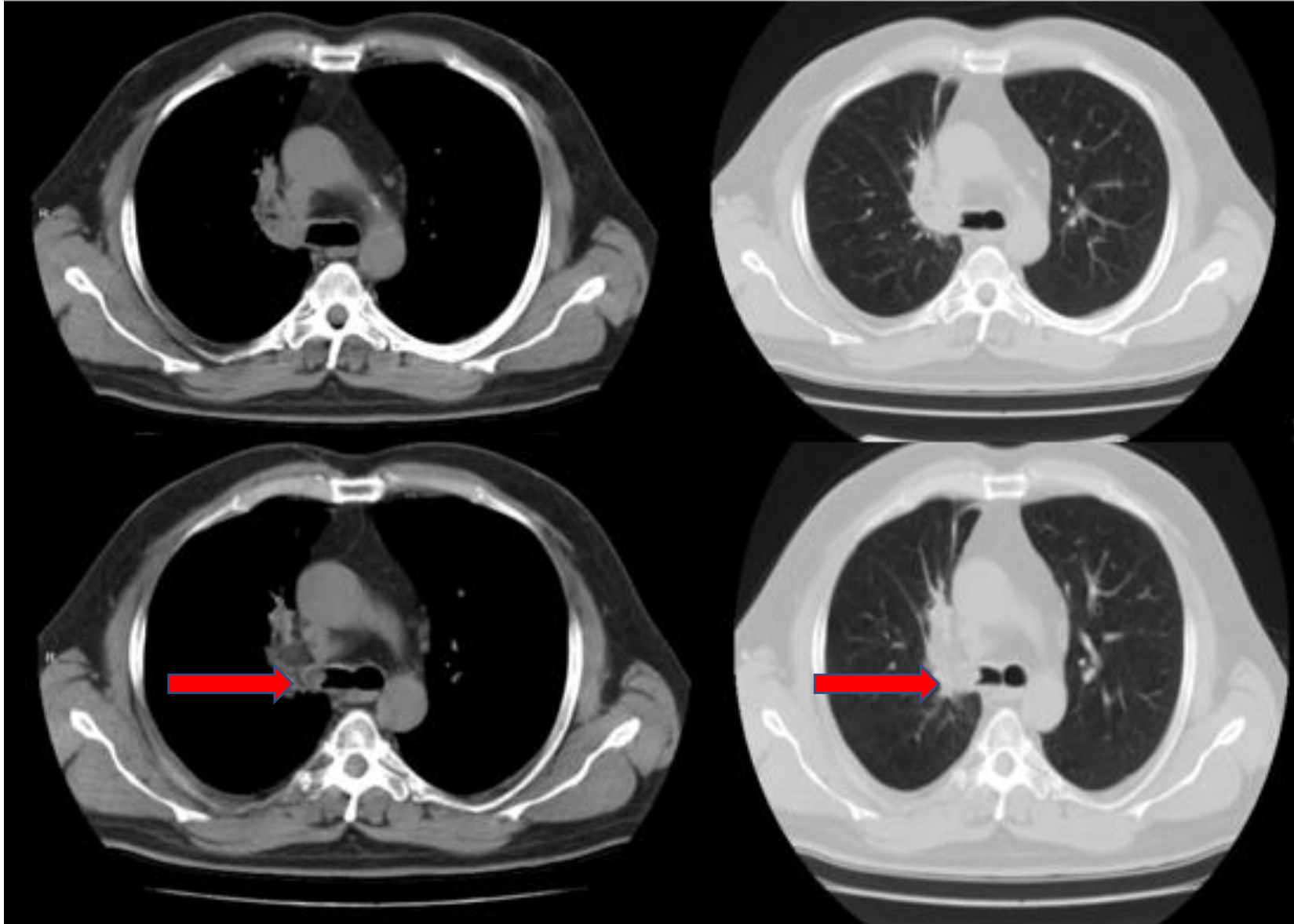
%100
W:350 C:60

OLGU 3

- **61 yaşında,erkek**
- **Şikayeti: Öksürük, nefes darlığı, ağızdan kan gelmesi**
- **Hikayesi: 1 aydır nefes darlığı, öksürük, ağızdan kan gelmesi şikayeti olan hasta, çekilen Toraks BT'sinde sağ akciğerde lezyon saptanması üzerine bronkoskopi planlanmış**
- **Solunum sıkıntısı artması üzerine dış merkeze başvuran hasta entübe edilerek yoğun bakıma alınmış**
- **Özgeçmiş: HT**
- **Alışkanlıkları: Sigara 50 paket/yıl**

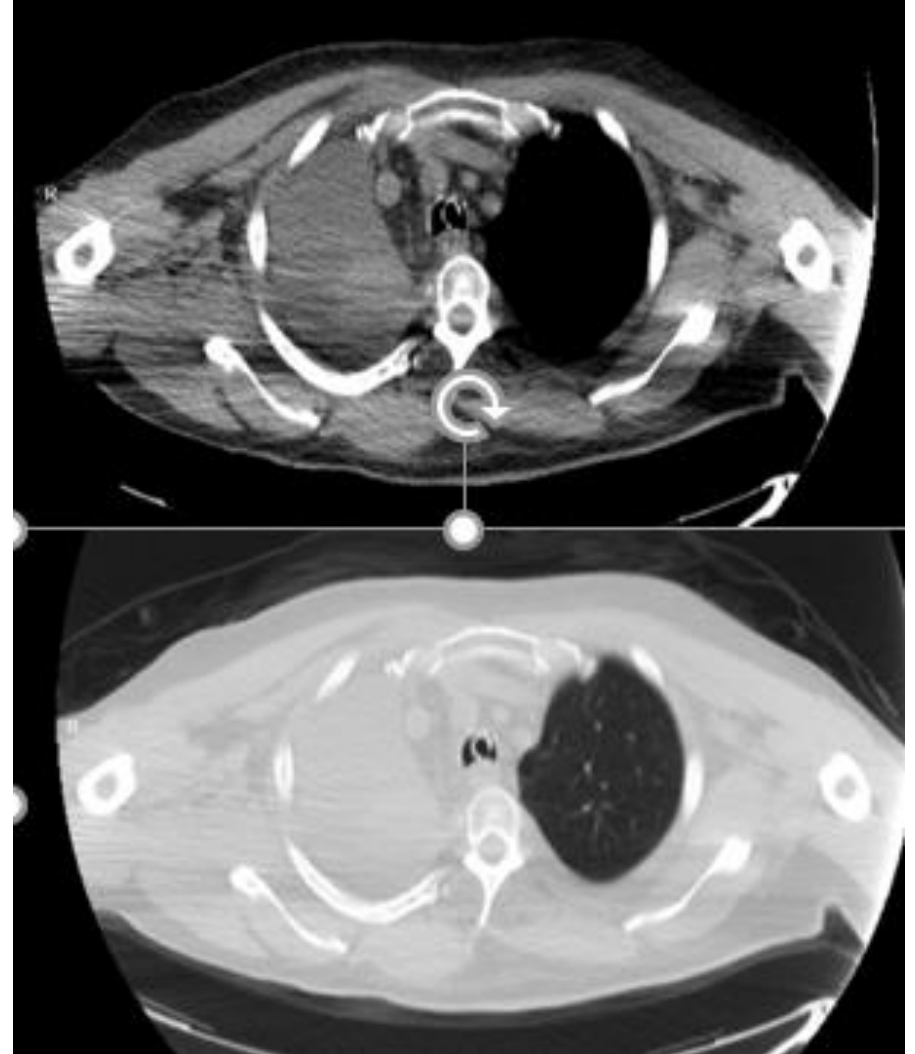
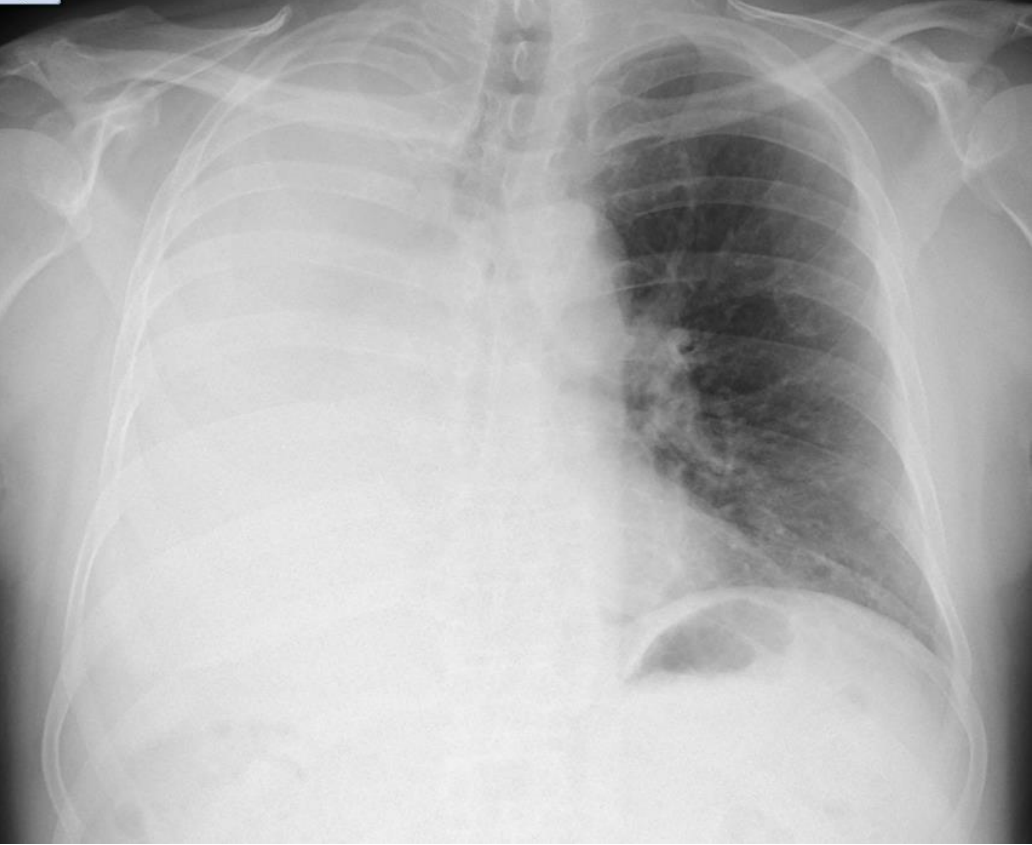
OLGU 3

Eylül 2020 Toraks BT



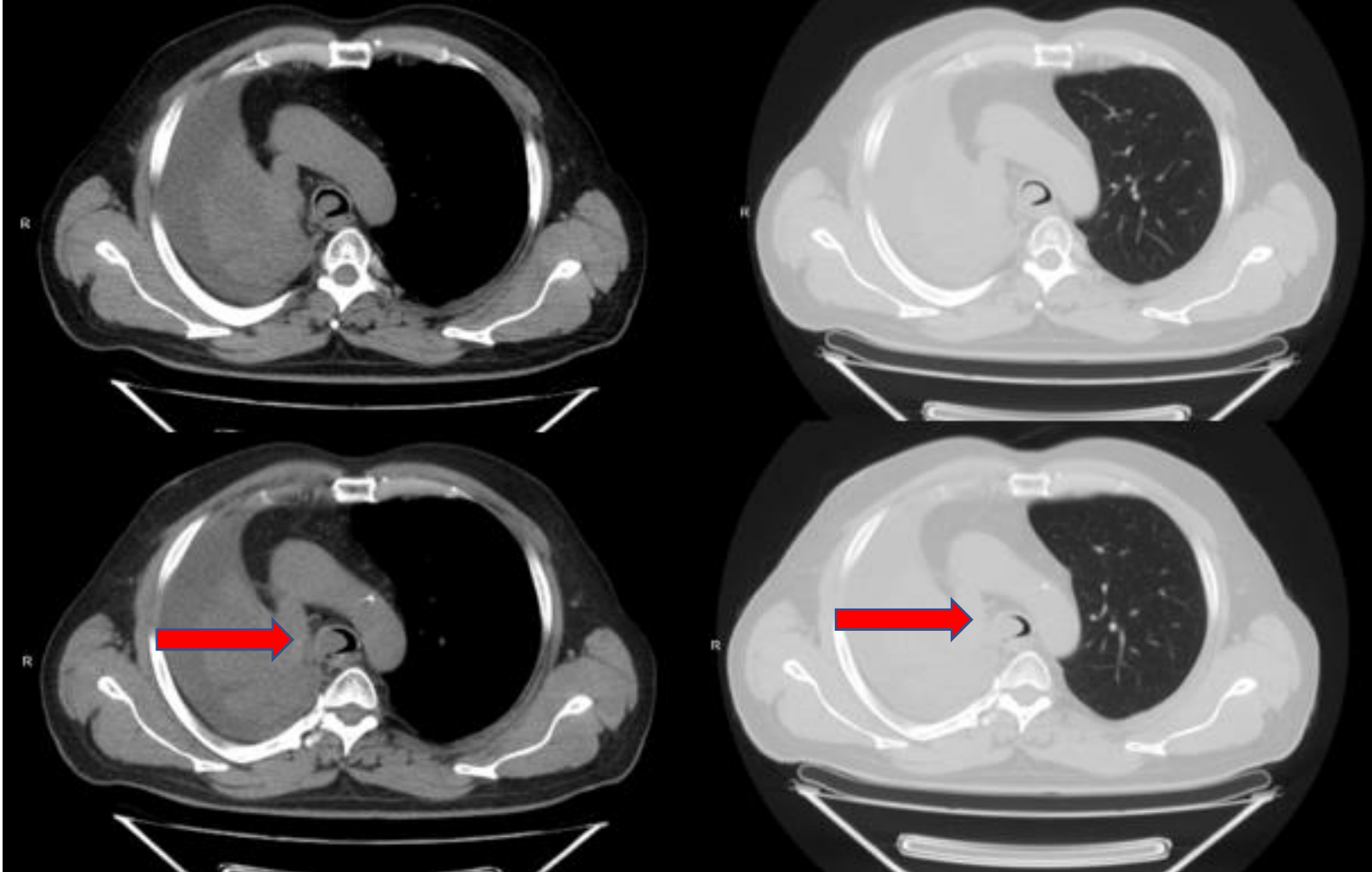
OLGU 3

Yoğun Bakım Takibinde Çekilen PA Akciğer Grafisi ve Toraks BT (Kasım 2020)



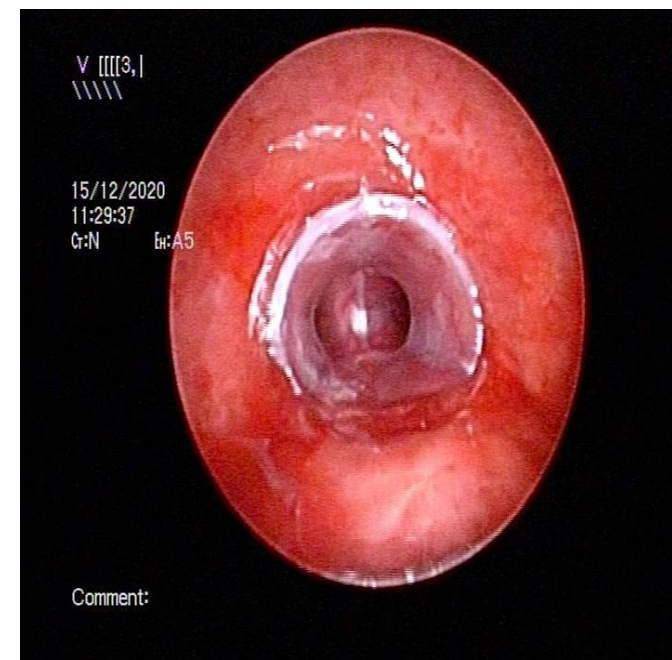
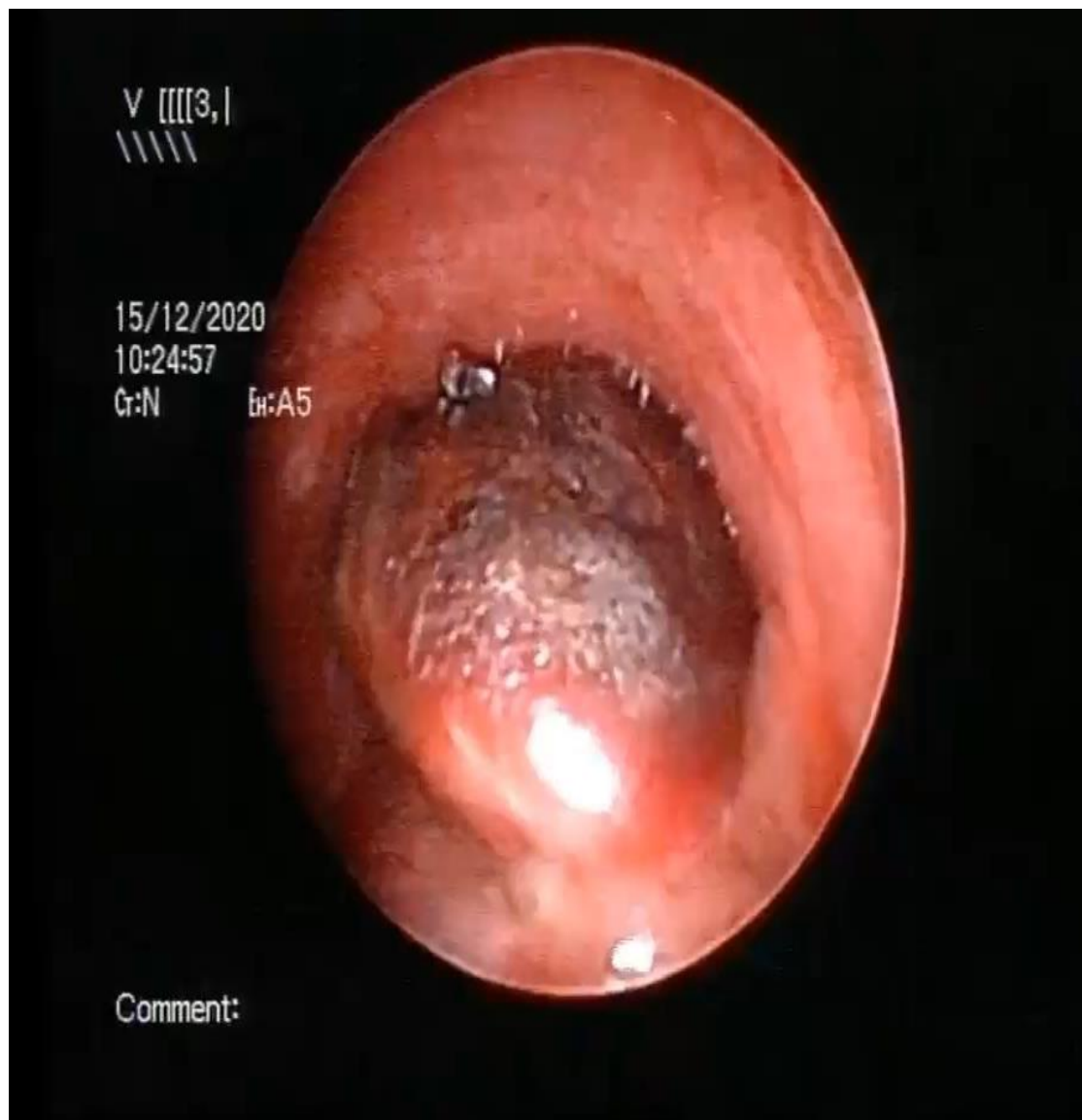
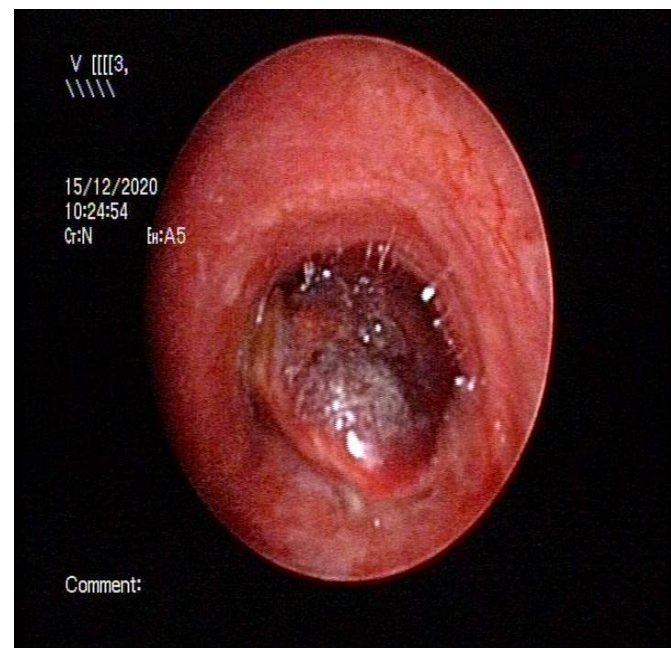
OLGU 3

Yoğun Bakım Takibinde Çekilen PA Akciğer Grafisi ve Toraks BT (Kasım 2020)

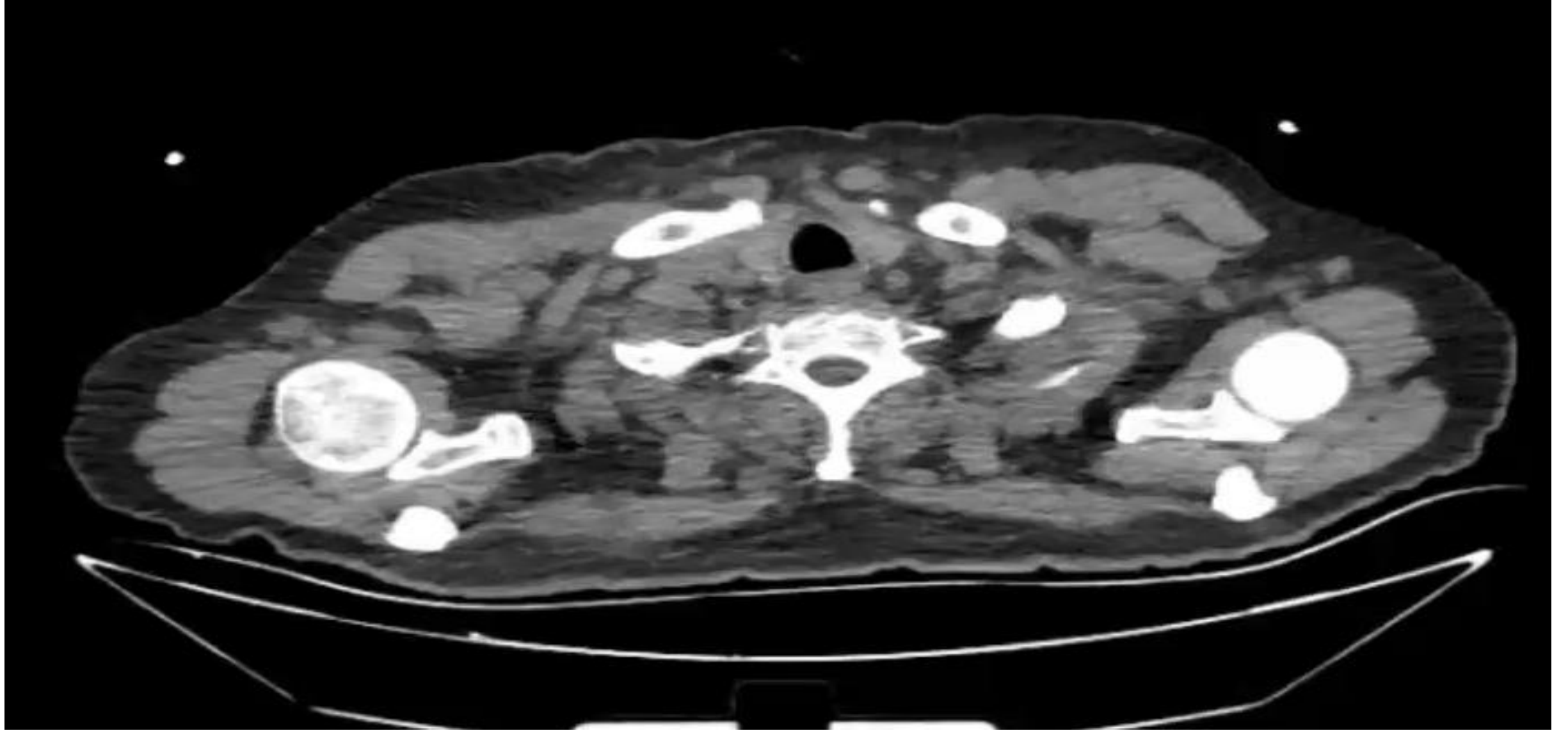


OLGU 3

RİJİD BRONKOSKOPI



OLGU 3



Ocak 2021 Toraks BT

OLGU 3

- Torasentez
- Onkoloji takibinde KT+ RT başlandı
- Şubat 2021 de yüzde ve boyunda ödem , solunum sıkıntısı ile acile başvurdu
- Vena cava superiorda bası saptanan hastaya girişimsel radyolojide vena cava'ya stent yerleştirildi

Gönderilen Materyal

PLEVRA MAYİİ

Materyallerin Alındığı Yer

PLEVRA

Materyalin Alınma Şekli :

ASPIRASYON

Klinik Ön Tanı

Akciğer Ca. KT alıyor

Makroskopi

Plevra Mayii: 4 cc hacminde prulan görünümde mayii. 2 adet lam yayıldı. PAP+ Giemsa boyandı. Hücre bloğu hazırlandı.
1BLOK/YOK

Kesit Teknikeri: Enzi Aytekin Sitoloji Teknikeri: Arif Cemre Yücel Döküm Teknikeri: Aysun Hotan Raporlayan Tıbbi Sekreter: Sunay Sarpal

TIBBİ LABORATUVAR YORUMU

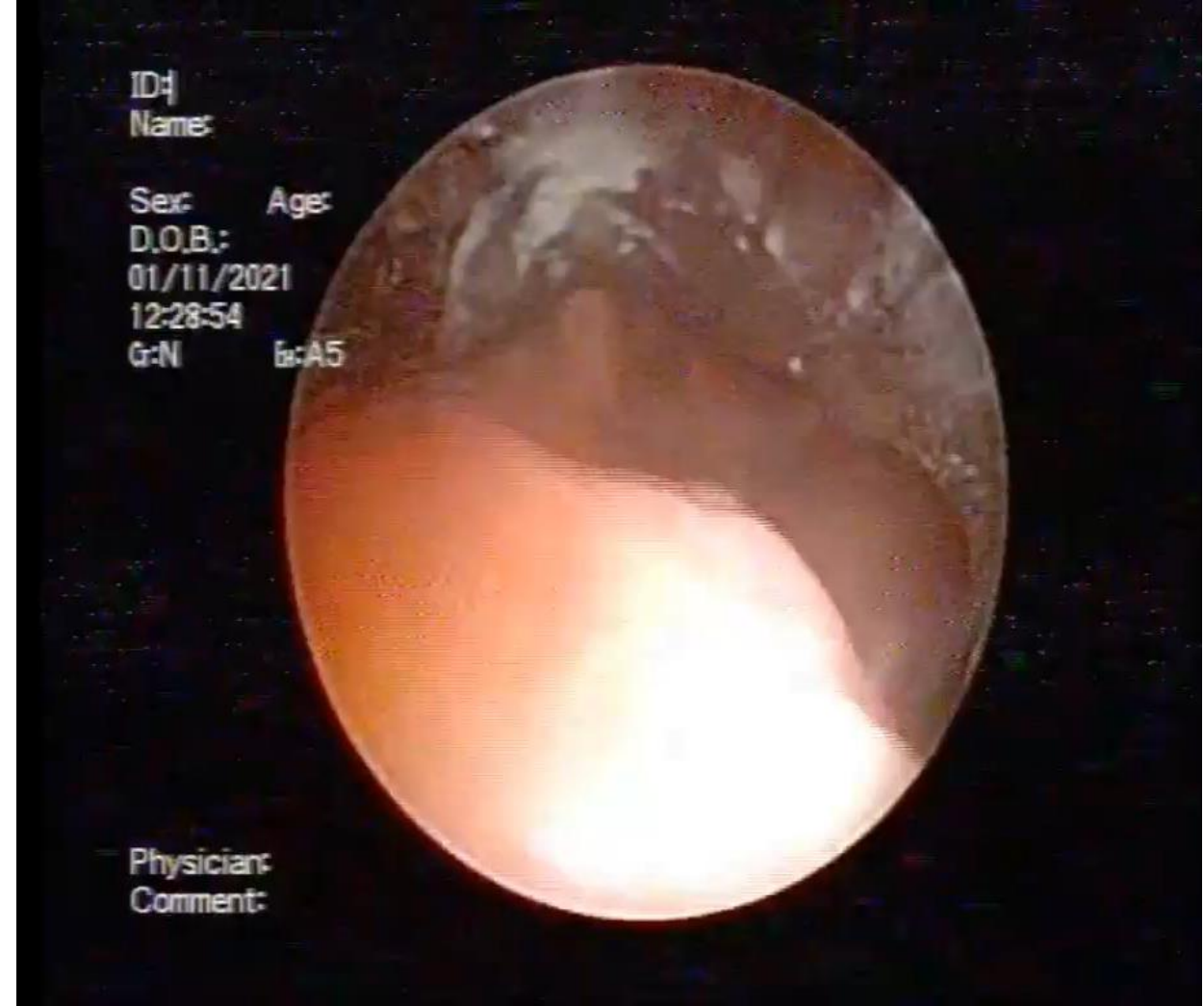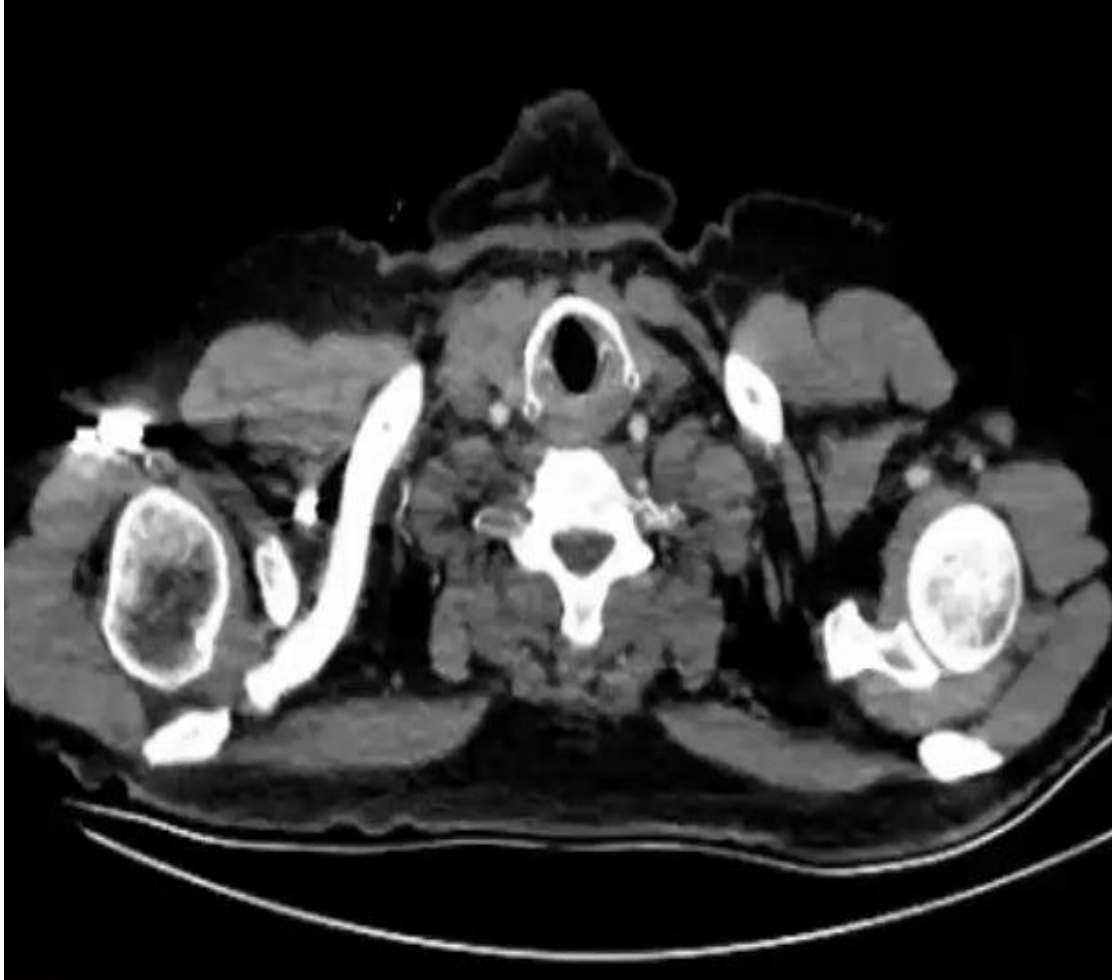NOT: Tümöral hücre görülmedi

RAPOR ÇIKIŞ TARİHİ: 18/02/2021

Histopatolojik Tanılar / Sitopatolojik Tanılar

Plevra Aspirasyon (Yayma+ Hücre Bloğu Kesitleri): Lenfositler, polimorf nüveli lökositler

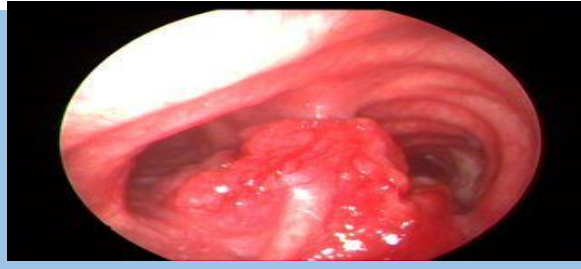
OLGU 3



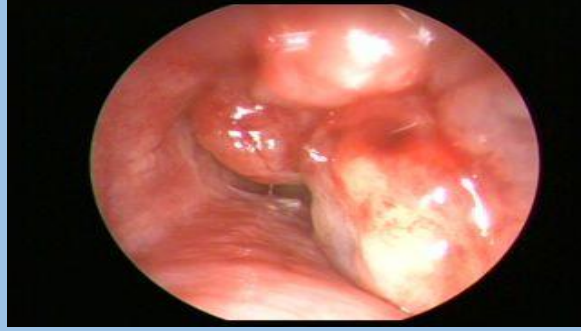
Ekim 2021 Toraks BT



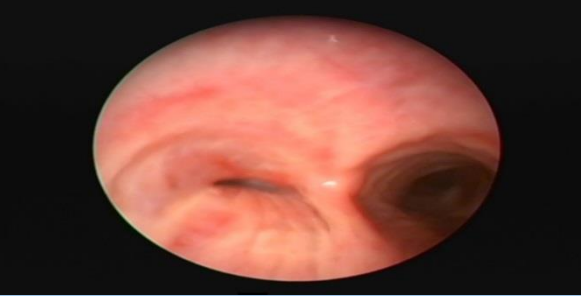
► **Ana karina tutulumu**



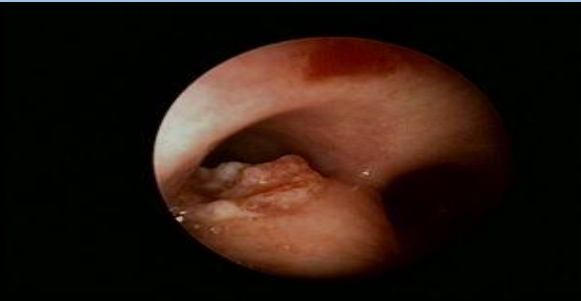► **Trakea distal veya orta hat lezyonları**



► **Ana bronşlar proksimalinde stenoz**



► **Trakeoözafegial fistül**



Airway stents: a retrospective evaluation of indications, results and complications in our 10-year experience

Mehmet Akif Özgül ¹, Erdoğan Çetinkaya ¹, Ekrem Cengiz Seyhan ¹, Demet Turan ¹, Efsun Gonca Uğur Chousein ¹, Güler Özgül ², Deniz Doğan ³

Introduction: Tracheobronchial stents (TBS) are the principal modalities in the management of central airway obstruction with intrinsic tracheobronchial pathology and extrinsic airway compression. The aim of the study is to assess the indications, surveillance management, complications, and long-term outcomes of the TBS managed by rigid bronchoscopy (RB) in our 10-year experience.

Materials and methods: The files of all patients who underwent stenting in two centers from November 2008 to September 2018 were reviewed for background data, type of disease, and indication for the placement of stents, symptoms, treatment, complications and outcome.

Result: 305 patients were stented with 342 TBS. TBS were placed in both malignant (n= 223) and benign airway diseases (n= 82). The median length of stent stay was 88 (34-280) days in patients with malignancies and 775 (228-2085) days in benign diseases. There was no stent-related mortality. Mucostasis (19%) and granulation tissue formation (17%) were the most common stentrelated complications. Benign nature of the disease, tumors metastatic to tracheobronchial tree, length of stent stay, and shape of stent were associated with the development of complications.

Conclusions: TBS offer a safe and effective therapy for patients with both benign and malign tracheobronchial pathologies.

Im: 45/196
Se: 201

A

HELVACI NURTEN
30451135754

Im: 55/196
Se: 201

A

HELVACI NURTEN
30451135754

Im: 62/196
Se: 201

A

HELVACI NURTEN
30451135754

Im: 71/196
Se: 201

A

HELVACI NURTEN
30451135754
28.12.1951 F

YEDIKULE GOG.HAST.VE GOG.CERRAHI E.A.H.
546

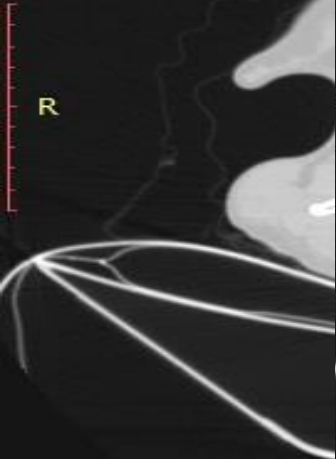
Im: 76/196
Se: 201

A

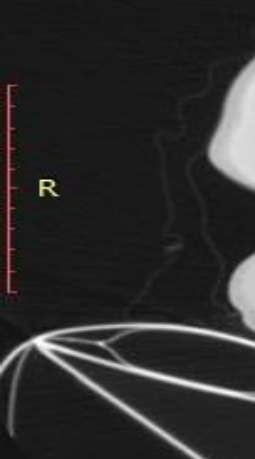
HELVACI NURTEN
30451135754
28.12.1951 F

YEDIKULE GOG.HAST.VE GOG.CERRAHI E.A.H.
546

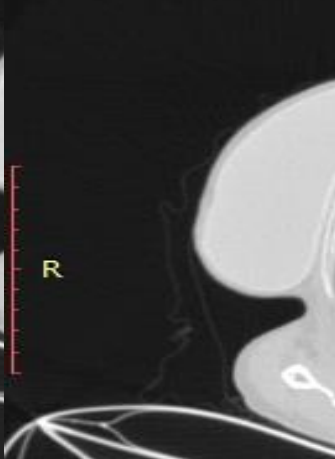
BT, Toraks, kontrastsiz | (C15.9) Ozofagus malign ne
Mediasten, iDose (4)
Mediasten




WL: -400 WW: 1500
T: 2.0mm L: -93.1mm



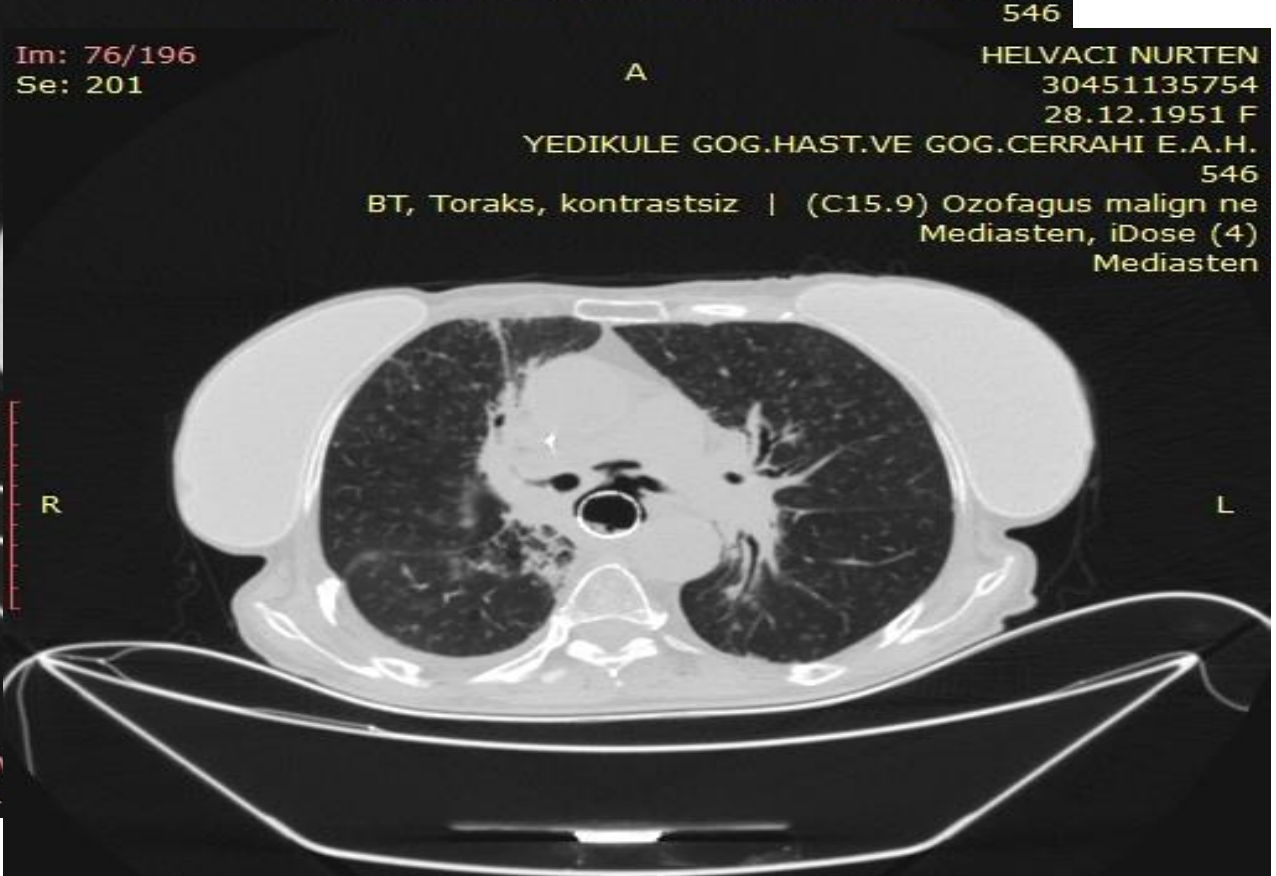WL: -400 WW:
T: 2.0mm L: -1



WL: -400 WW: 1500
T: 2.0mm L: -127.1mm



WL: -400 V
T: 2.0mm L



WL: -400 WW: 1500 [CT Lungs]
T: 2.0mm L: -155.1mm

p

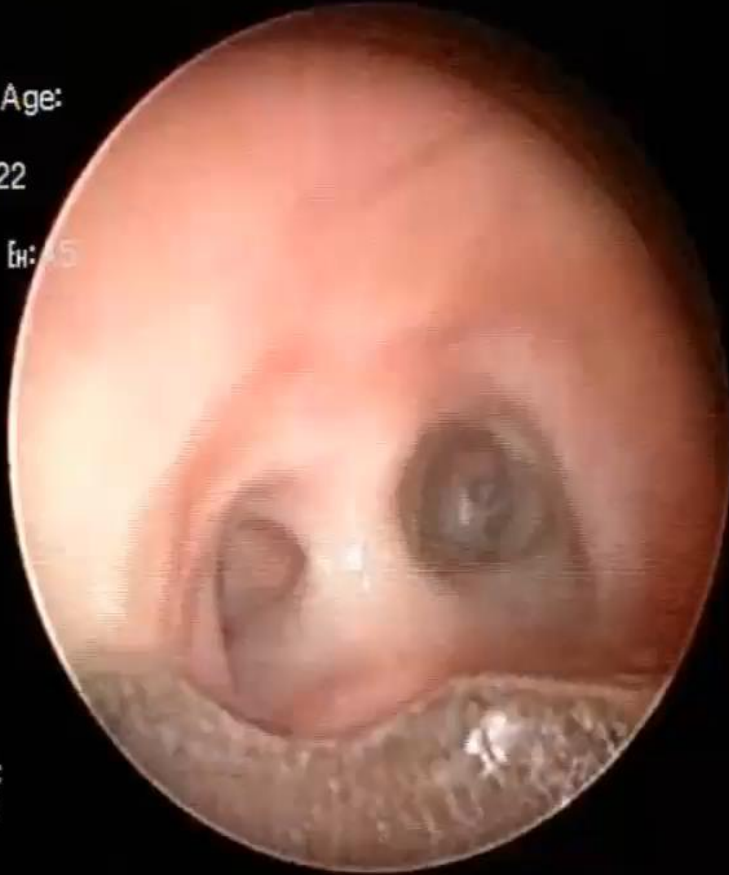182mA 100kV
08.08.2022 20:04:30

OLGU 4

Name:

Sex: Age:
D.O.B.:
09/08/2022
09:38:02
Gr:N Eri:45

Physician:
Comment:



Im: 70/189
Se: 201

A

HELVACI NURTEN

30451135754

28.12.1951 F

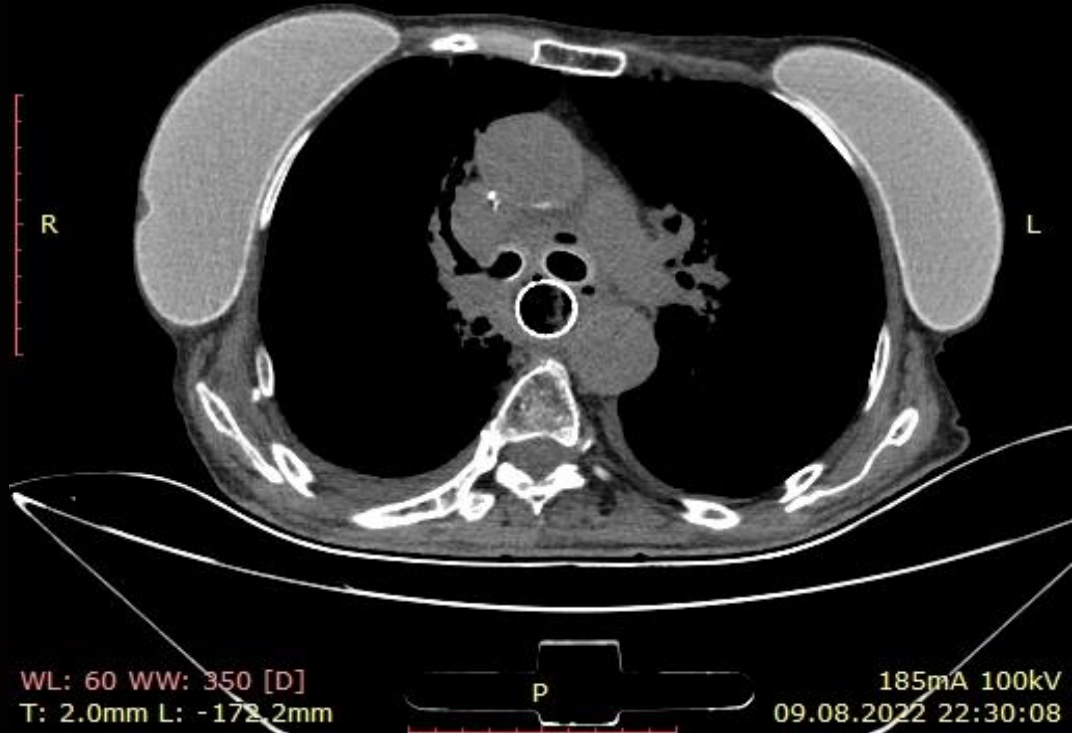YEDIKULE GOG.HAST.VE GOG.CERRAHI E.A.H.

2373

(804070) BT, Toraks, kontrastsiz | (C15.9) Ozofagus malign ne

Mediasten, iDose (4)

Mediasten

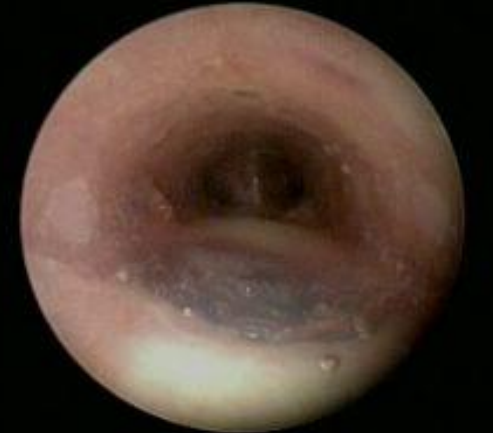
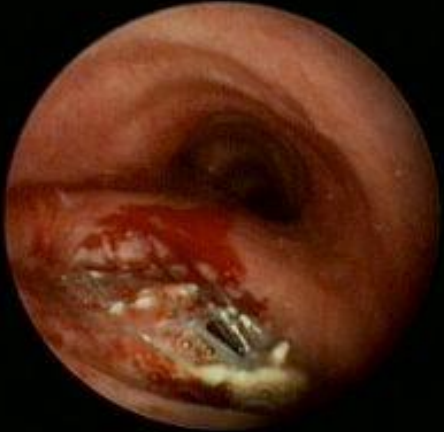
MALİGN FİSTÜL

- Özafagus fistül vakalarında aspirasyondan kaçınmak için

- Bronkoplevral fistül vakalarında hava kaçağını azaltmak için

- Mediasten fistül vakalarında mediasten enfeksiyonunu önlemek için



Use of airway stents to treat malignant tracheobronchial fistulas: Our six-year experience

Ekrem Cengiz Seyhan ¹, Demet Turan ¹, Mehmet Akif Özgül ¹, Efsun Uğur Chousein ¹,
Güler Özgül ², Erdoğan Çetinkaya ¹

Background: This study aims to investigate the indications, safety, complications, and long-term outcomes of airway stenting in the treatment of malignant tracheobronchial fistulas.

Methods: The medical records of a total of 34 patients (24 males, 10 females; mean age: 55.4+13 years; range, 23 to 76 years) with malignant tracheobronchial fistulas treated with airway stenting between February 2014 and August 2020 were retrospectively analyzed. Data including demographic features, diagnosis, symptoms, treatment, complications and outcomes were recorded.

Results: Thirty-eight airway stents were inserted in 34 patients with malignant tracheobronchial fistulas, including 19 patients with malignant tracheobronchial esophageal fistulas and 15 patients with bronchopleural fistulas. The clinical success and the technical success rates were 91% and 100%, respectively. No perioperative death or severe complications occurred. Chronic complications (>24 h) occurred in eight (23%) patients with malignant tracheobronchial fistula. Median follow-up was 3.5 (range, 1.4 to 5.5) months in patients with malignant tracheobronchial esophageal fistulas and 18 (range, 9.5 to 26.5) months in patients with bronchopleural fistulas. Mortality rates were 79% and 61%, respectively.

Conclusion: Airway stent insertion provides a secure and effective treatment for patients with malignant tracheobronchial fistulas.

STENT KOMPLİKASYON

İŞLEM SIRASINDA

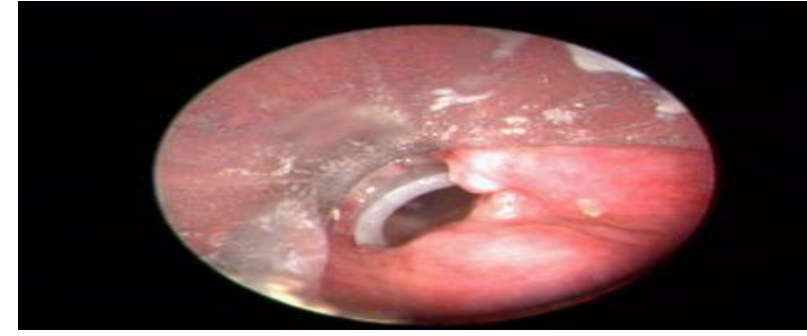
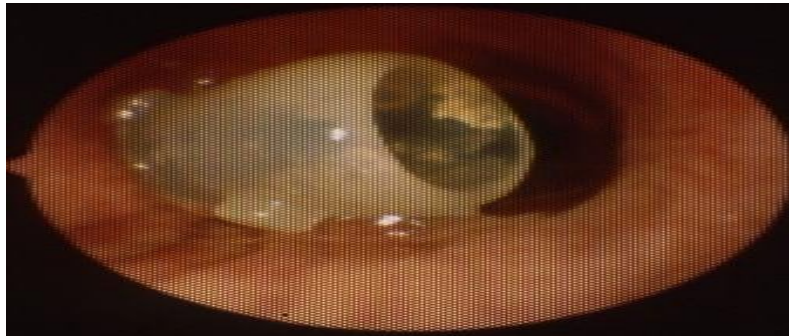
- Hava yolu obstrüksiyonu
- Malpozisyon
- Trakeobronşial perforasyon
- Mediastinal fistül
- Pnomotoraks

KISA DÖNEM

- Migrasyon
- Sekresyon retansiyonu
- Öksürük
- Perforasyon

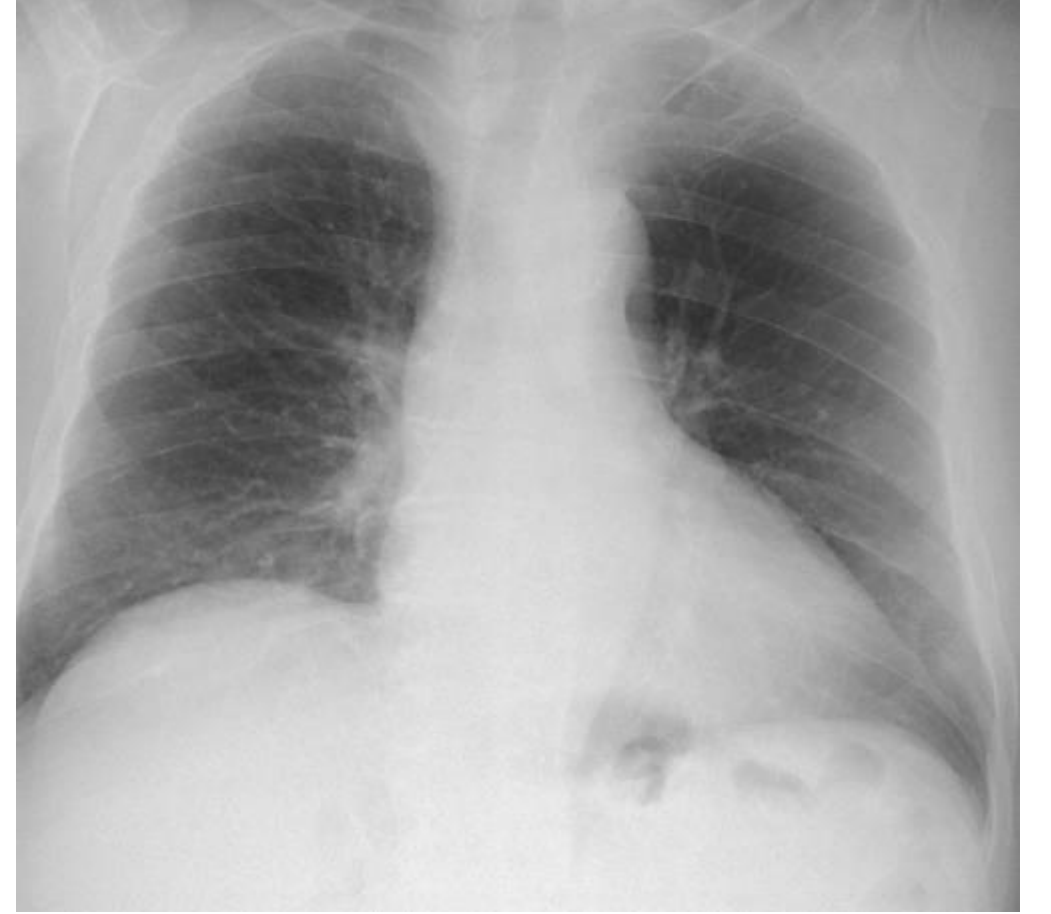UZUN DÖNEM

- Sekresyon retansiyonu
- Granulasyon
- Ağız kokusu
- Stent kırılması
- Solunum yolu enfeksiyonu



OLGU 5

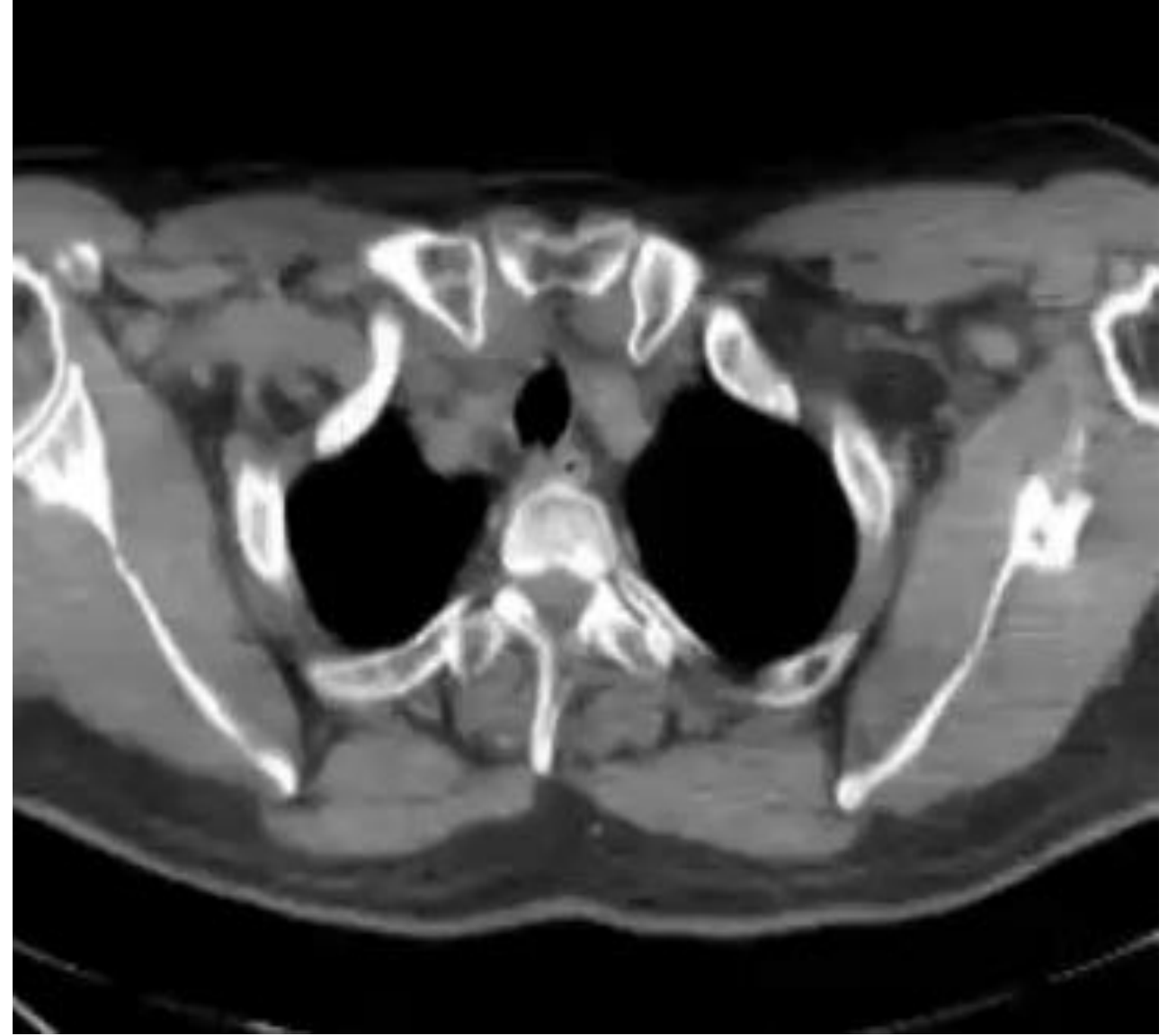
- 76 yaşımda, erkek
- Şikayeti: Nefes darlığı
- Hikayesi: Haziran 2021'de nefes darlığı başlayan hasta Van'da ileri tetkik edilirken, non-dignostik fleksibl bronkoskopik sonrası merkezimize refere edilmiş
- Özgeçmiş: HT, DM, Panik bozukluk (?)



PA AKCİĞER GRAFİSİ

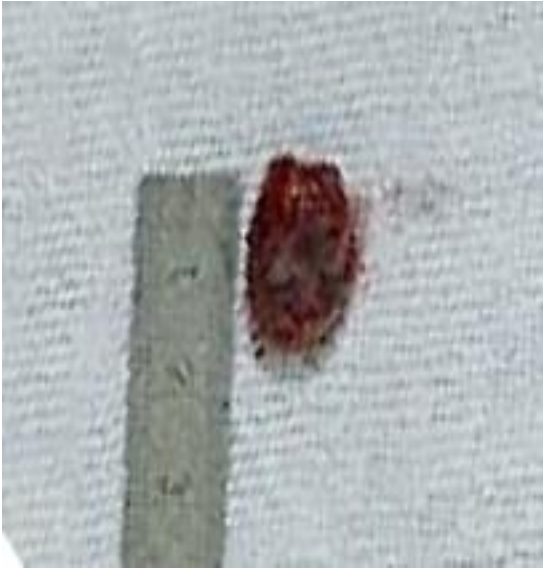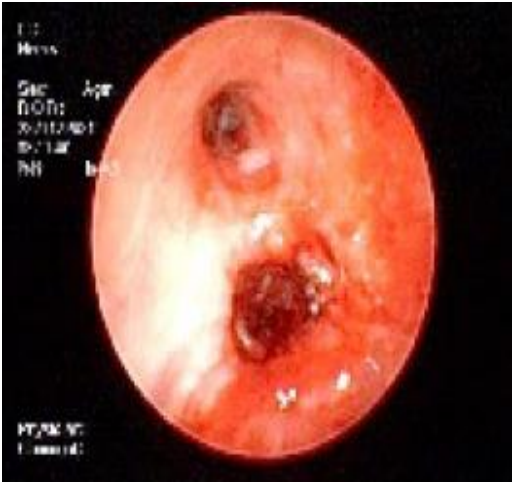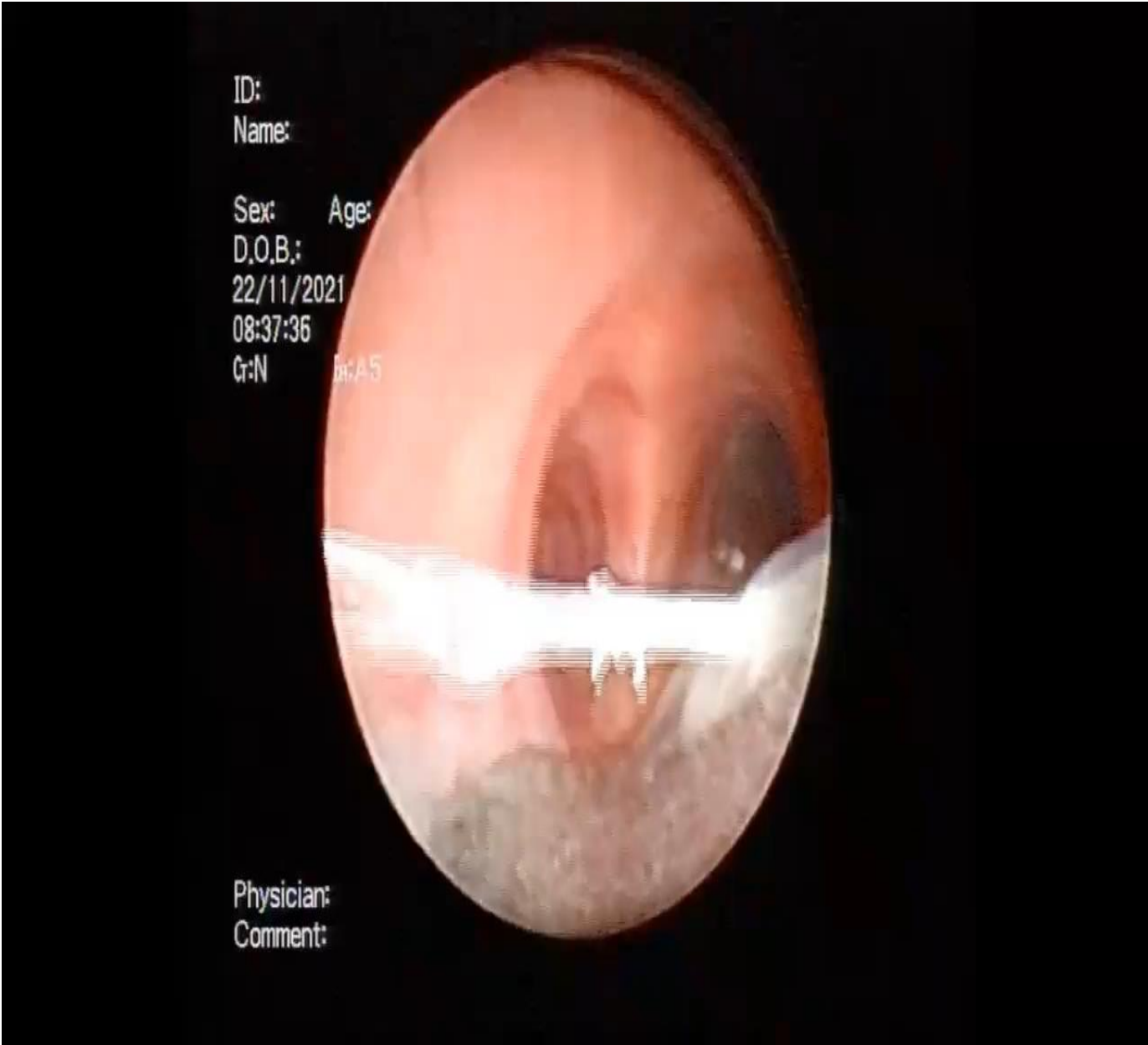
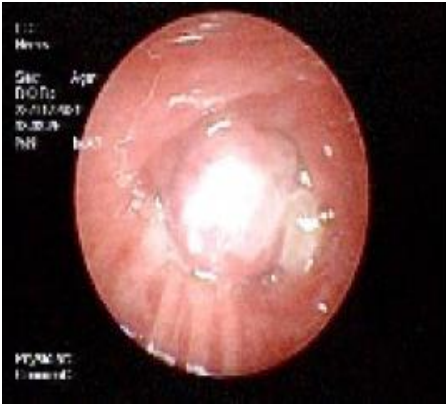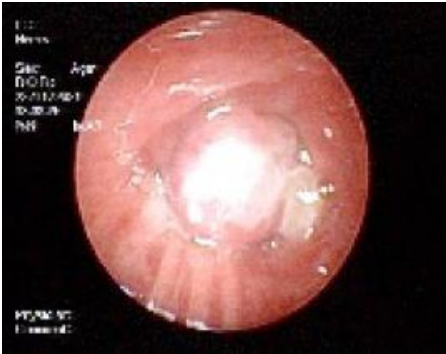
OLGU 5

- Alışkanlık: Bir özellik yok
- Fizik Muayene:
TA: 120/85 Sat: %93(oda) SDS: 22/dak
Solunum sistemi: Sol akciğerde alt alanlarda solunum sesleri kaba
- Başvuru Laboratuvar:
Tüm laboratuvar değerleri normal sınırlarda



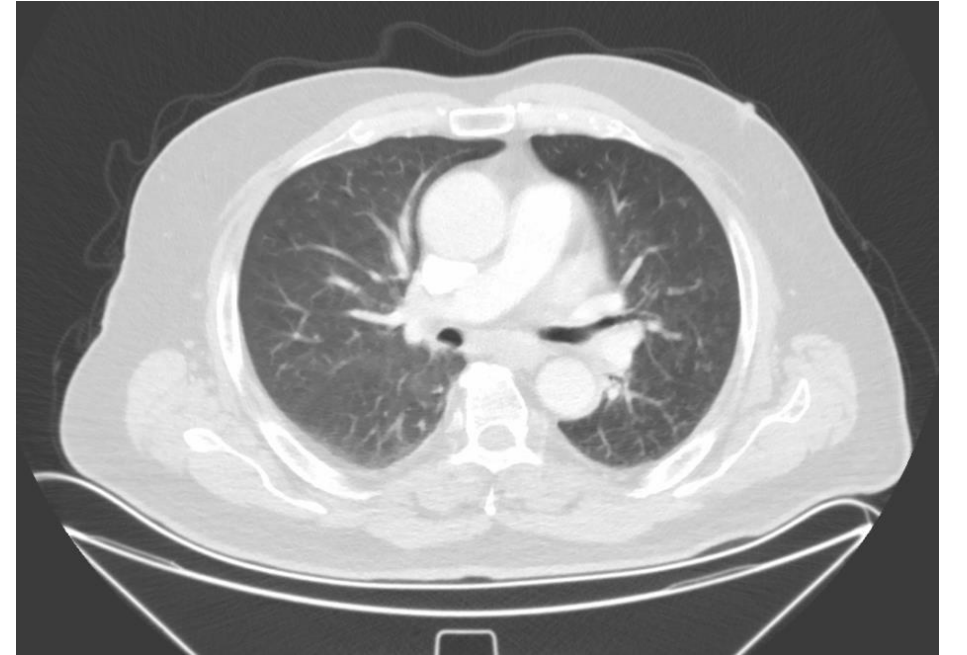
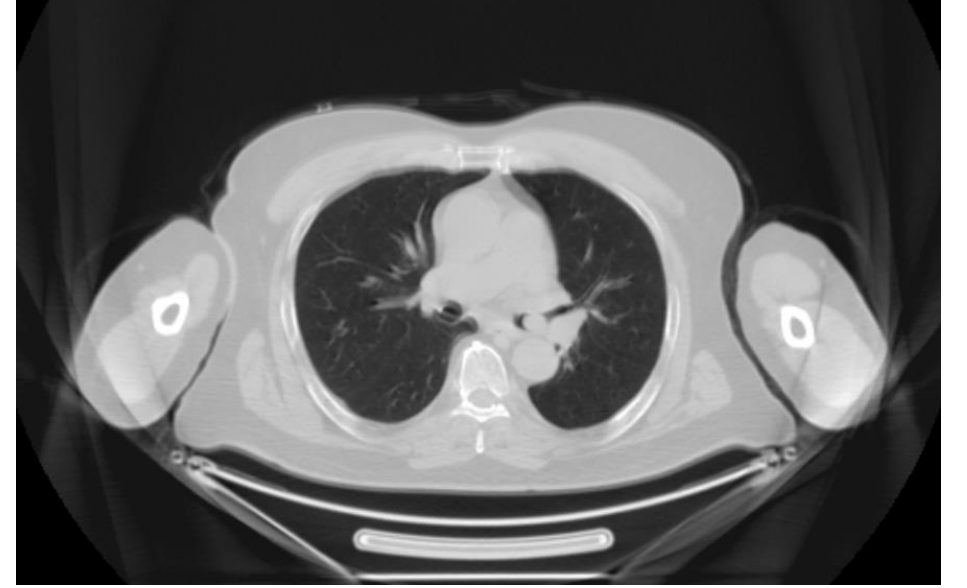
TORAKS BT

OLGU 5



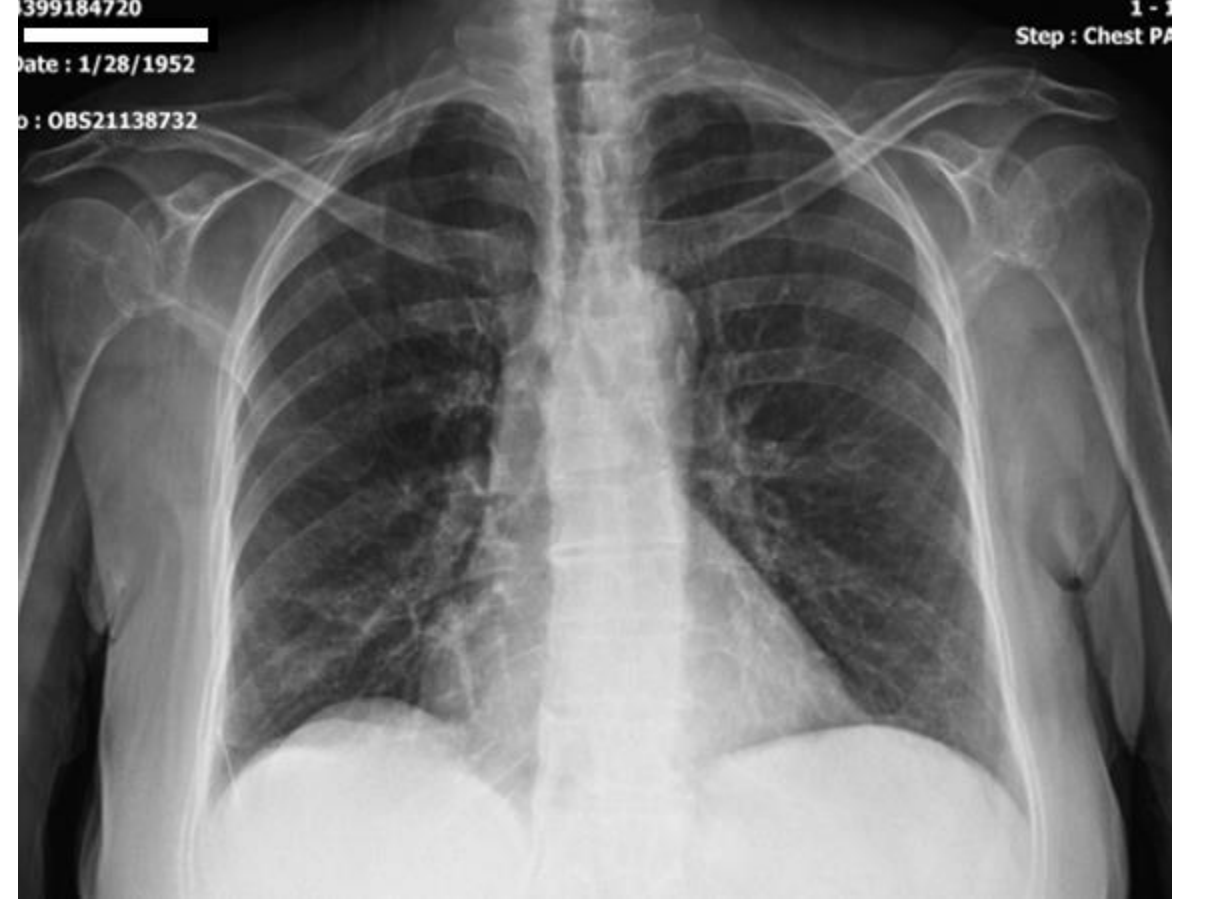OLGU 5

- Patolojisi «TİPİK KARSİNOİD TM» olarak raporlanmış
- GALYUM 68 DOTATATE PET istendi.



OLGU 6

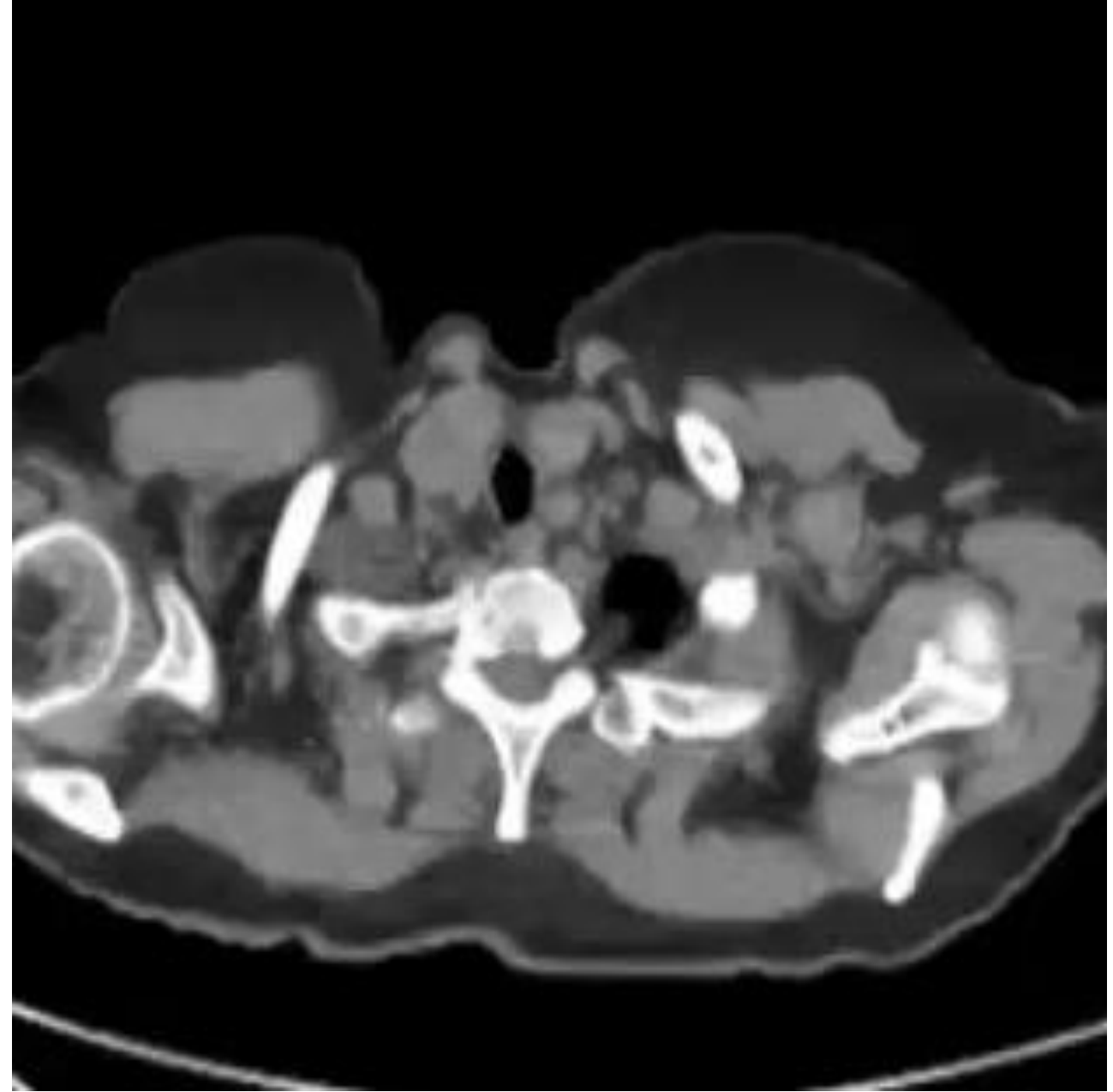
- 69 yaşında, kadın
- Şikayeti: Nefes darlığı
- Hikayesi: Nefes darlığı şikayeti ile başvurduğu Eylül 2021'de polikliniğimizde çekilen toraks BT'de sağ akciğerde izlenen kitle nedeni ile PET BT ve FOB planlanarak hasta ayaktan takipe alınmış
- Özgeçmiş: HT



PA AKCİĞER GRAFİSİ

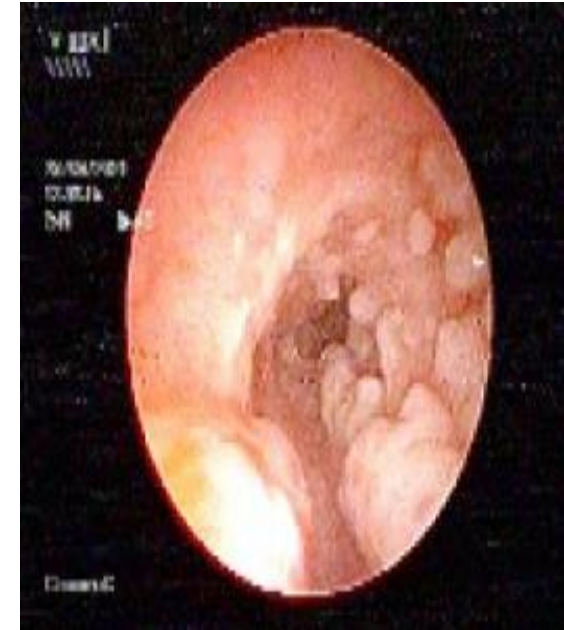
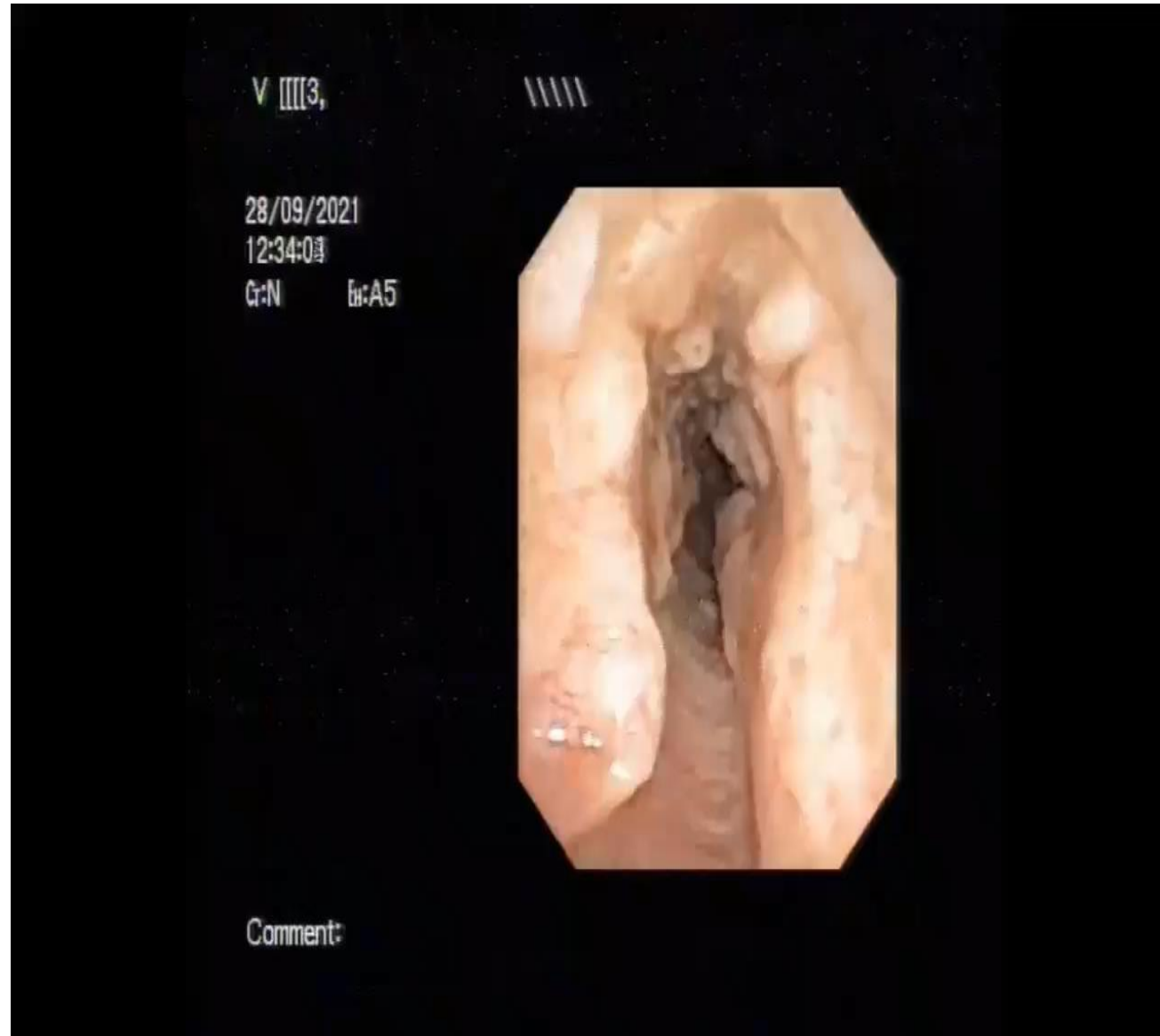
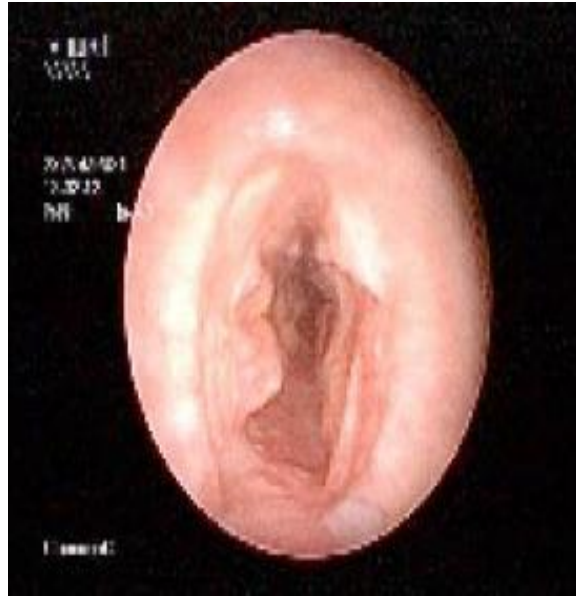OLGU 6

- Alışkanlık: Bir özellik yok
- Fizik Muayene:
TA: 140/95 Sat: %98(oda) SDS: 16/dak
Solunum sistemi: Stridor(+)
- Başvuru Laboratuvar:
Kayda değer patolojik değer yok



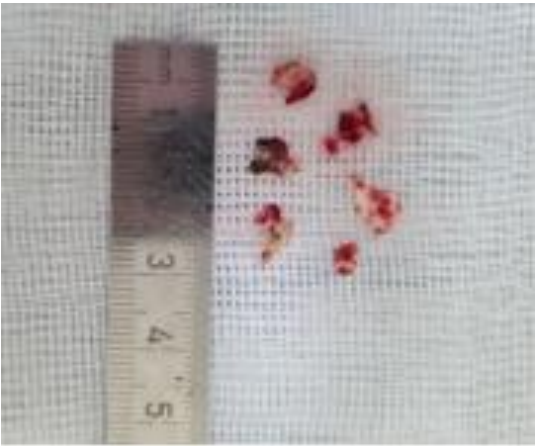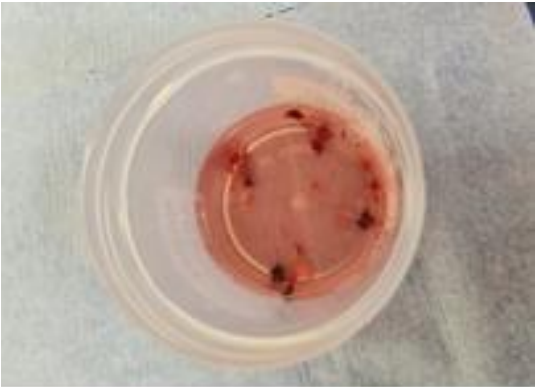
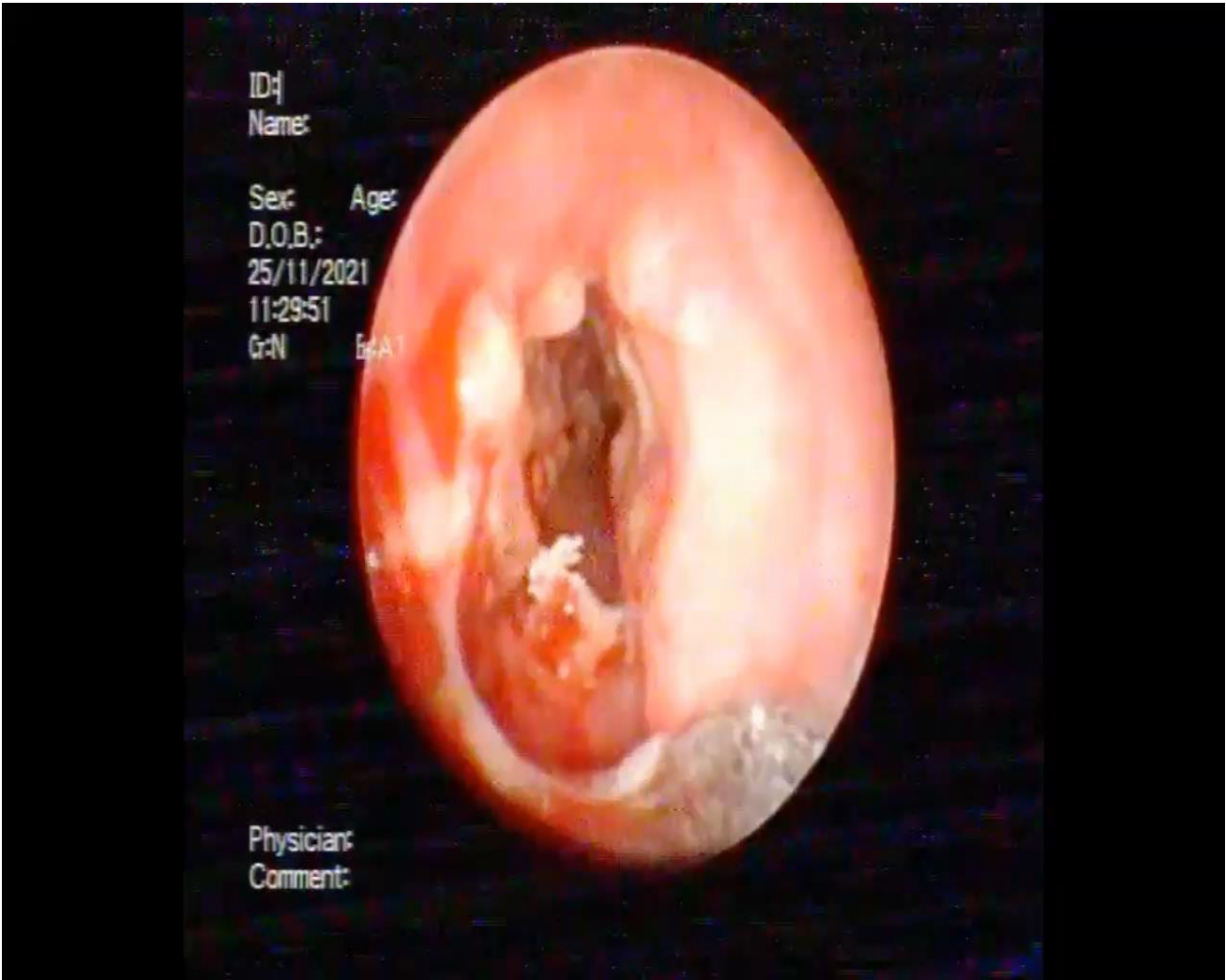
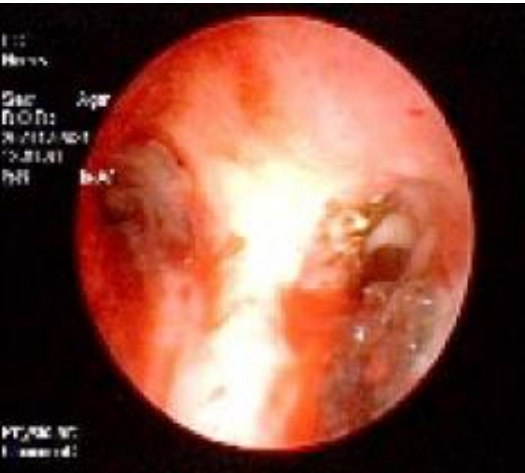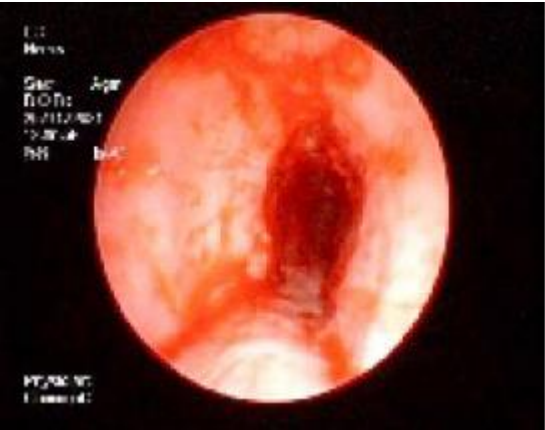OLGU 6

RİJİD BRONKOSKOPİ-1

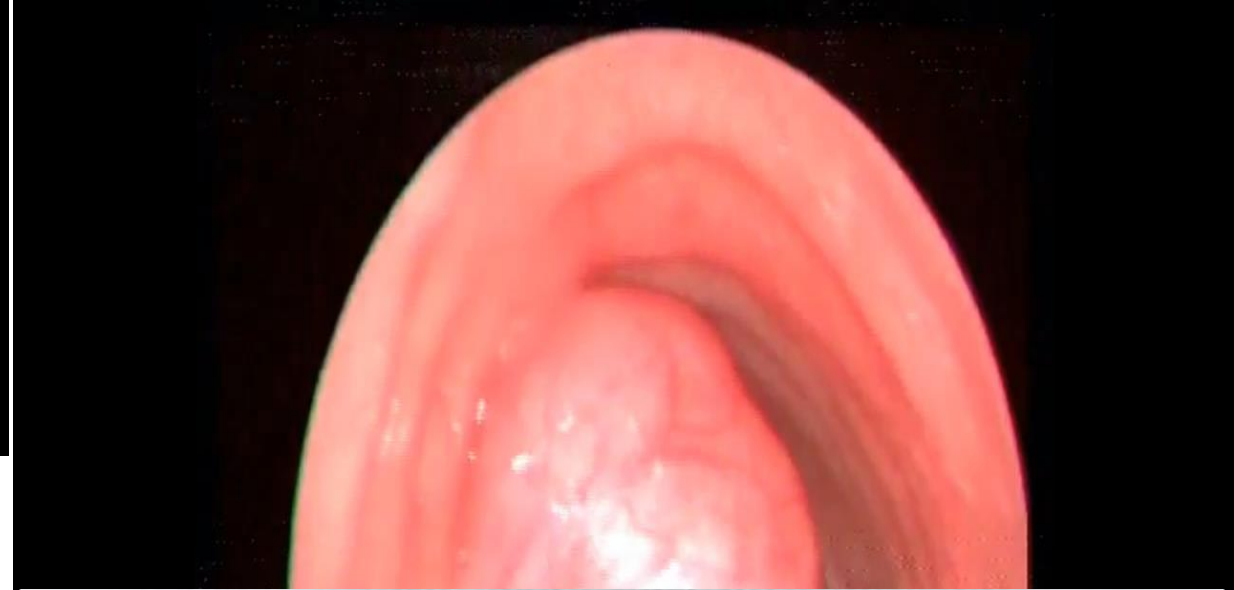
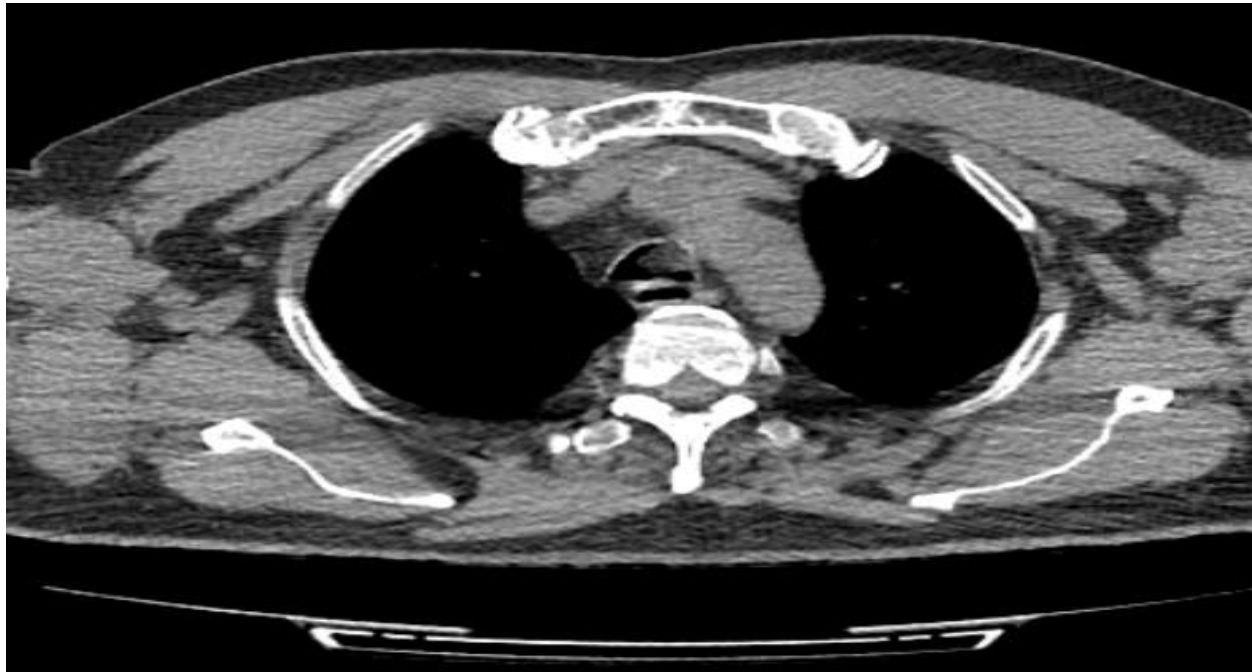
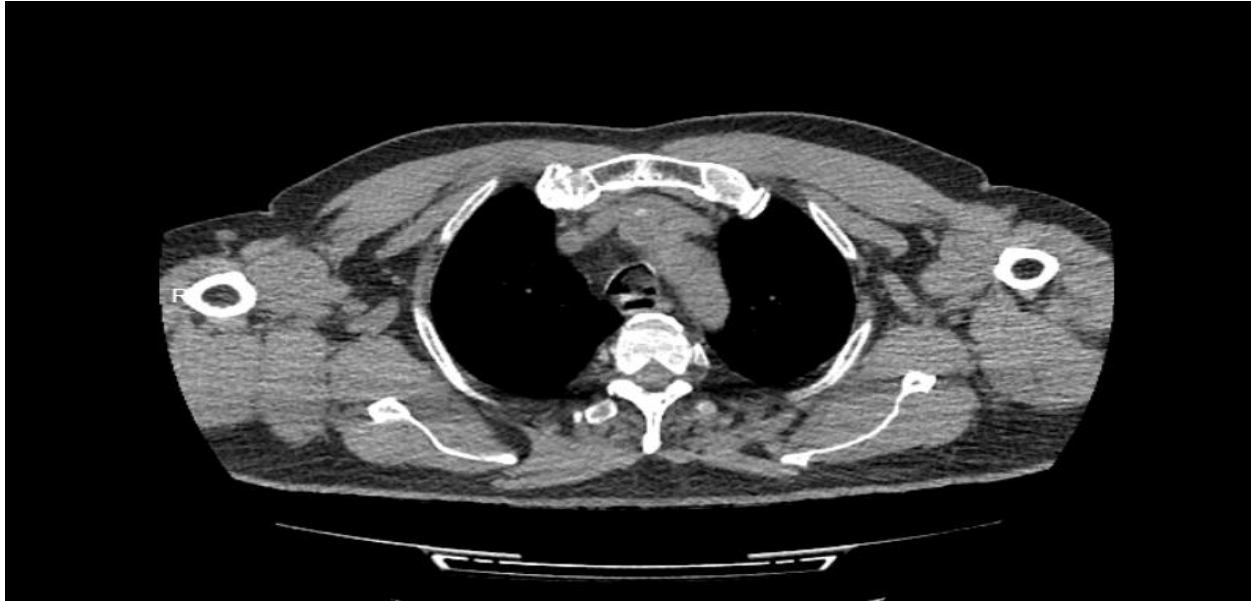
OLGU 6

RİJİD BRONKOSKOPİ-2



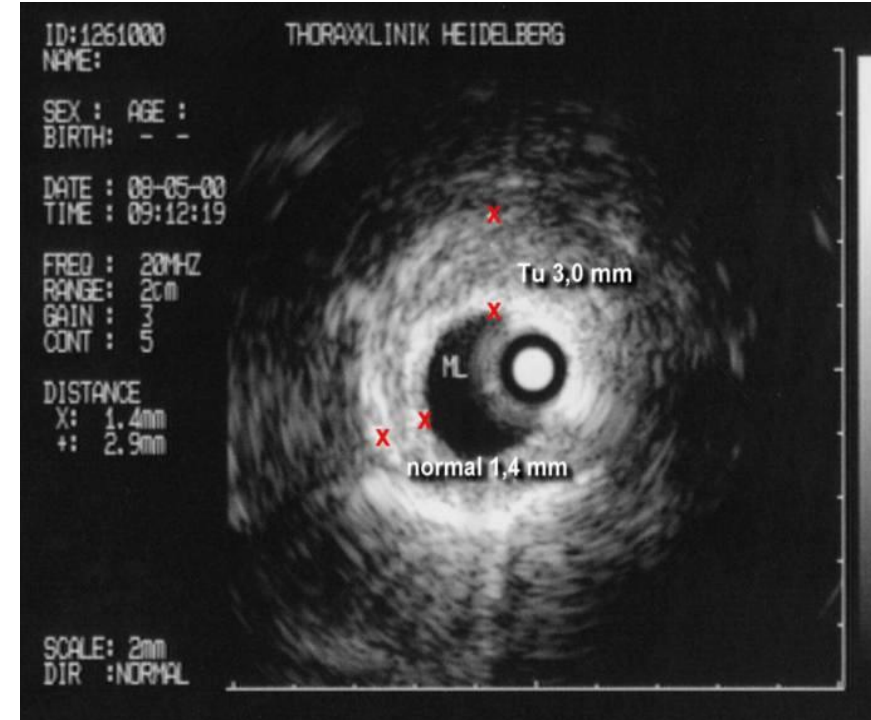
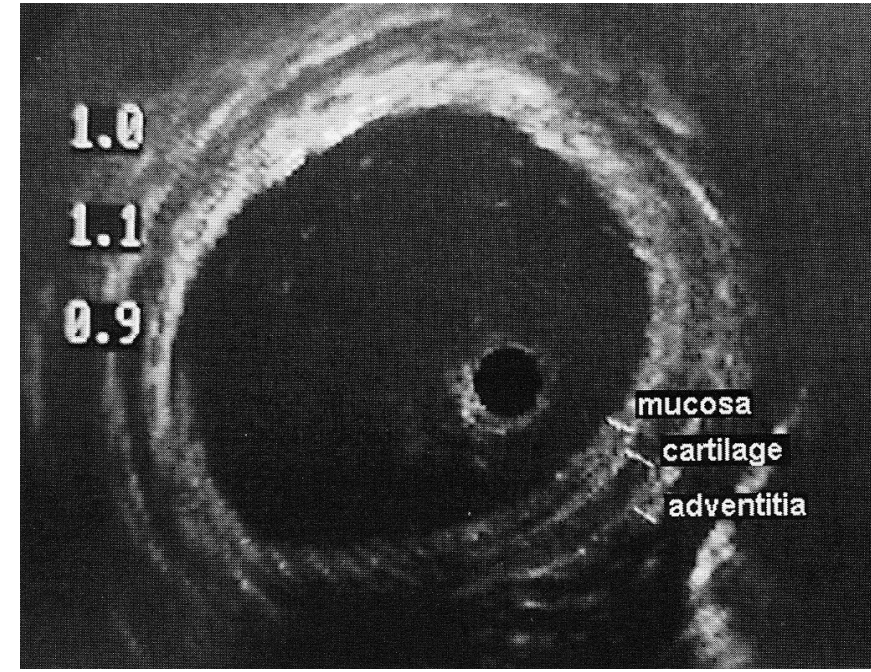
OLGU 7



BENİNG TÜMÖRLER

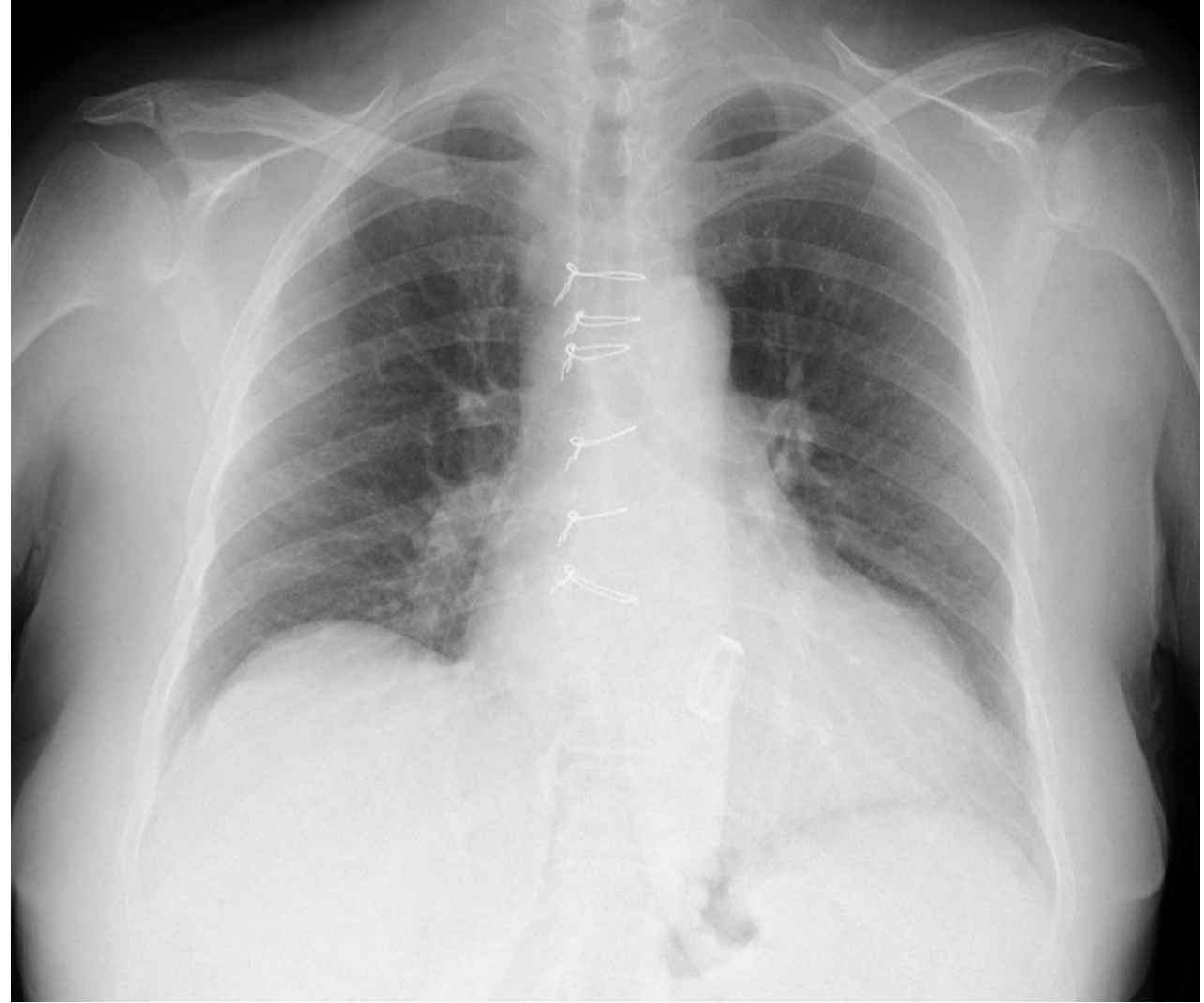Bronkoskopik tedavi

- Trakea, ana bronşlar, lob bronşları
 - Pedinküllü
 - Geniş tabanla duvara oturmayan
 - Ekstramural invazyonu olmayan
- (RADIAL PROB EBUS)
- APC, Elektrokoter snare, laser mekanik rezeksiyon
 - Rezidüel dokuya cryoterapi ile nüks düşük



OLGU 8

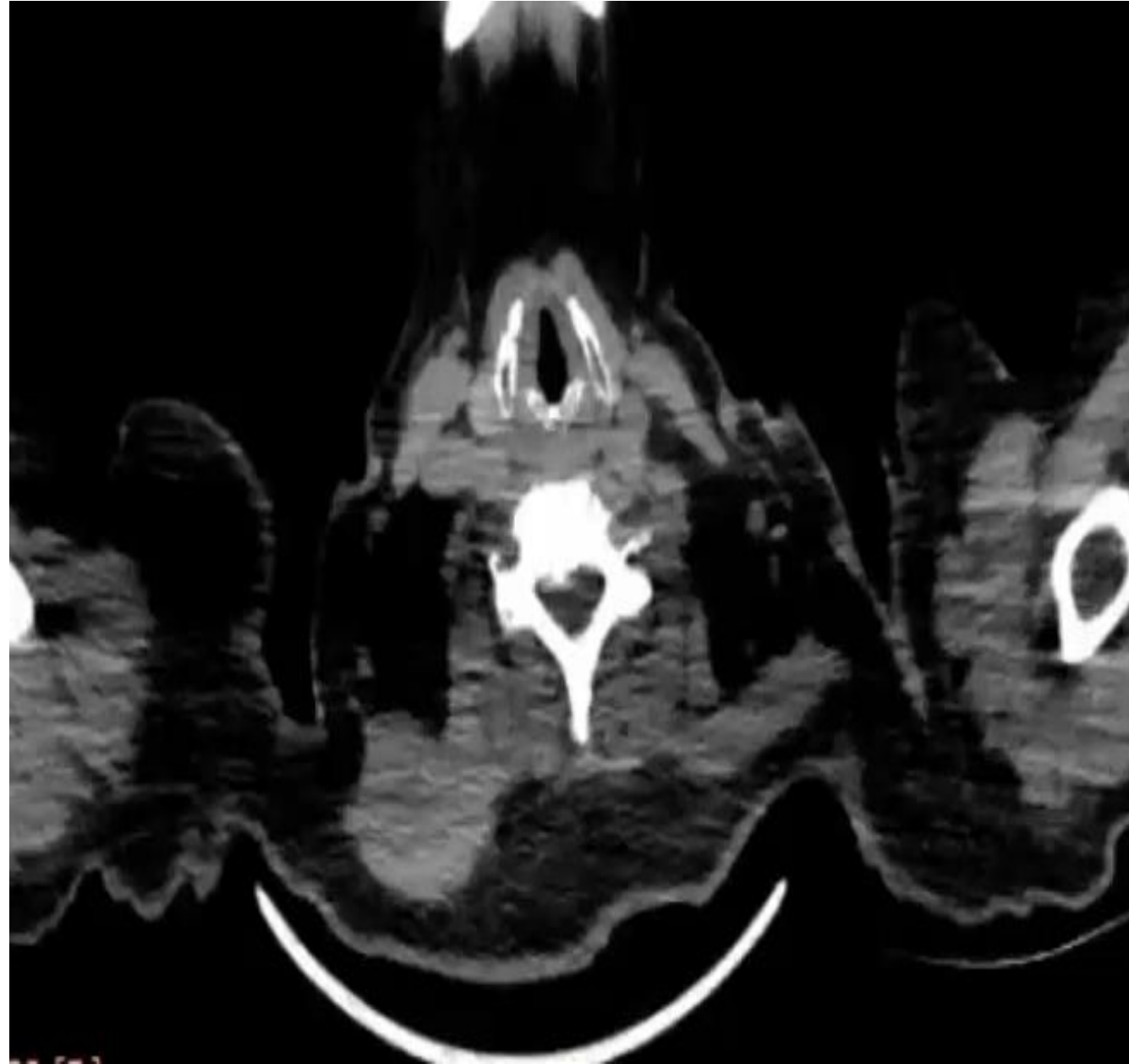
- 60 yaşımda, kadın
- Şikayeti: Nefes darlığı
- Hikayesi: Nefes darlığı nedeni ile başvurduğu poliklinikte çekilen toraks BT sonrası hasta interne edilmiş
- Özgeçmiş: DM, HT, İKH, KBY, opere MVR, Covid-19 pnömonisi nedeni ile 3 ay önce entübe halde YBÜ yatışı



PA AKCİĞER GRAFİSİ

OLGU 8

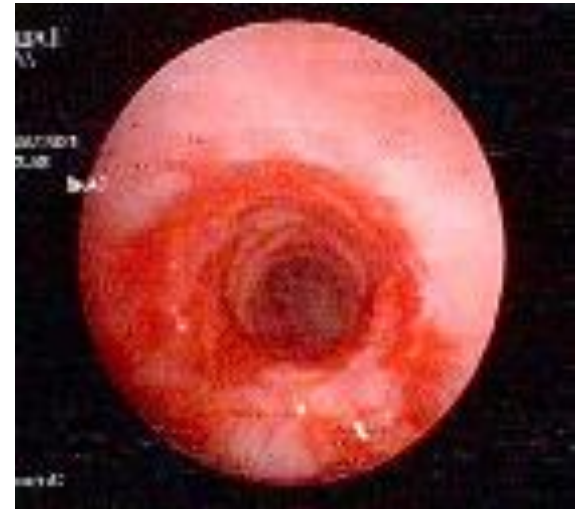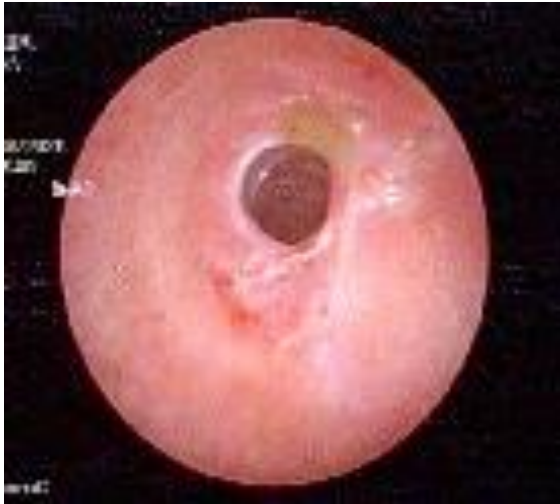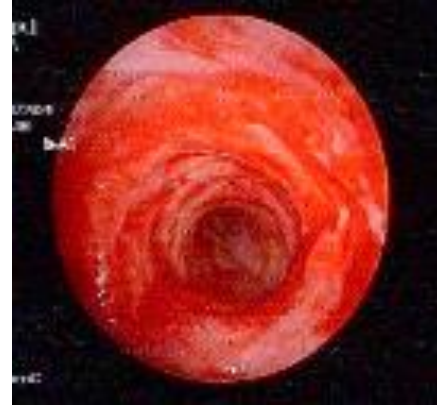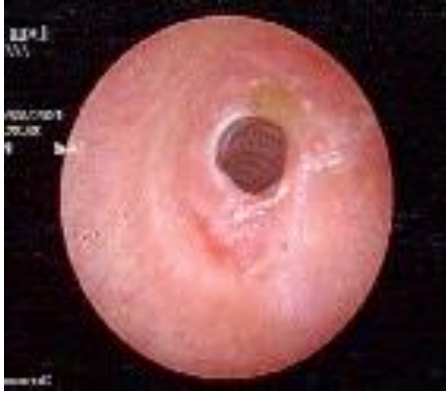- Alışkanlık: Bir özellik yok
- Fizik Muayene: TA:140/100 NDS:135/dak
Sat: %94(oda) SDS: 28/dak
- Solunum Sistemi: Bilateral solunum sesleri azalmış, alt alanlarda raller(+)
- Kardiovasküler Sistem: Taşikardik, VES(+), Bilateral pretibial ödem(++/++)



TORAKS BT

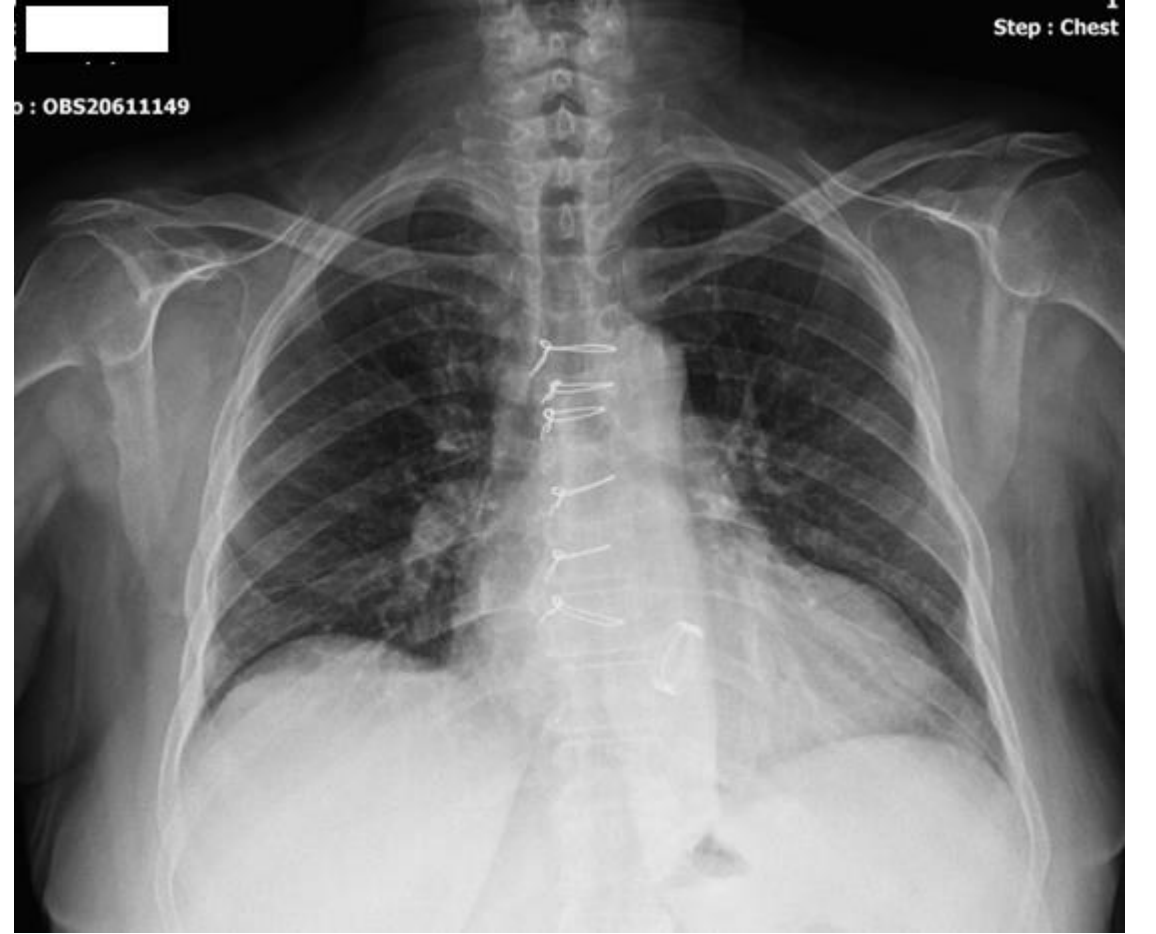OLGU 8

İLK RİJİD BRONKOSKOPİ



OLGU 8

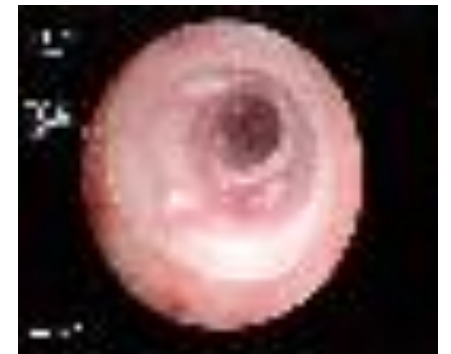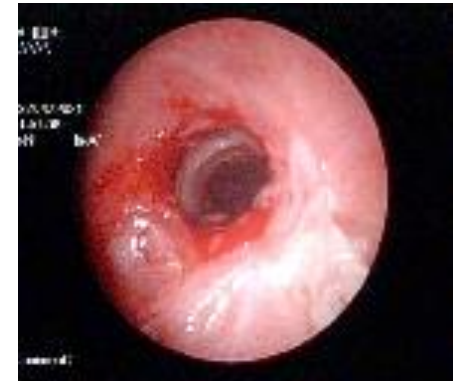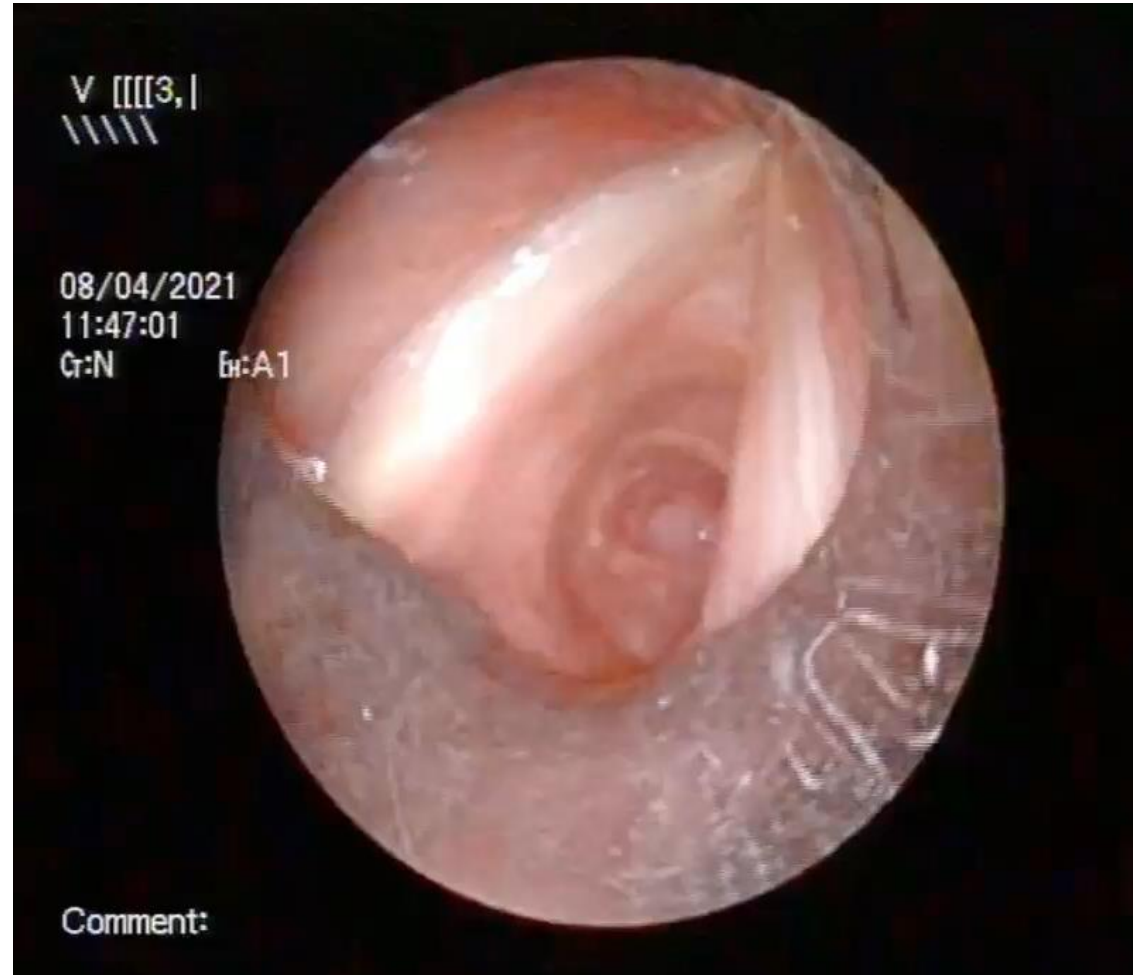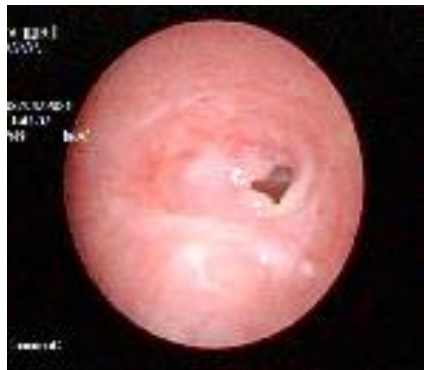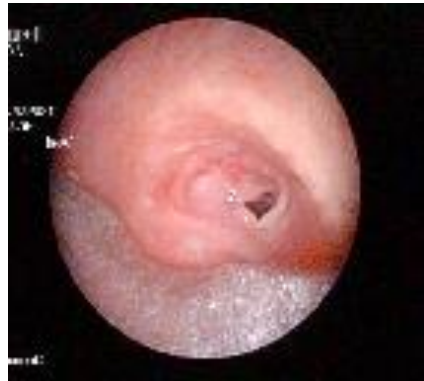- Hasta dilatasyon işleminden 1 ay sonra yine aynı semptom ile başvurdu



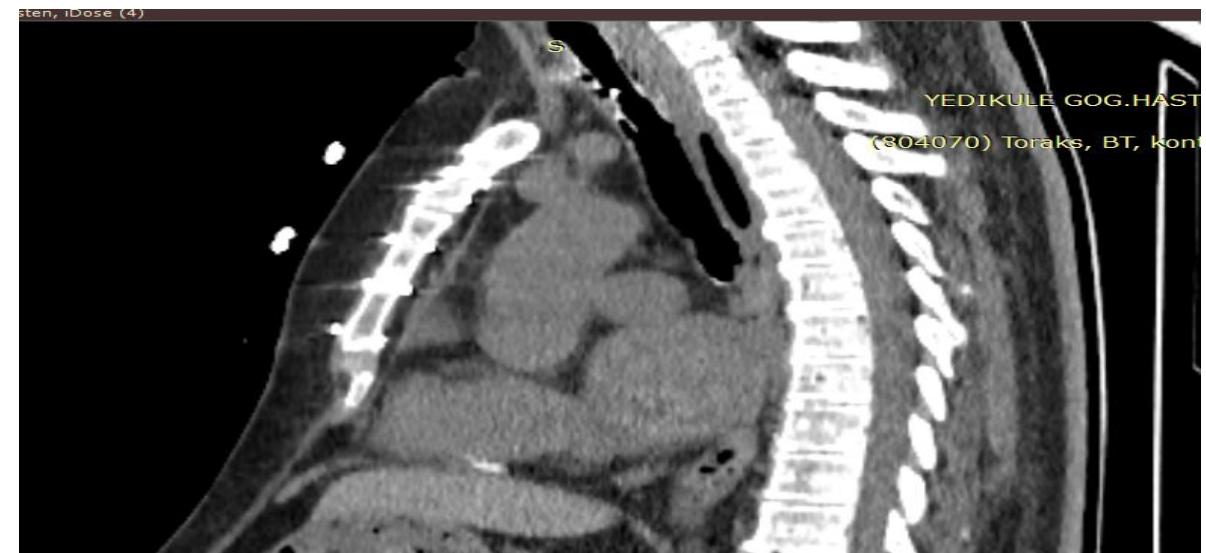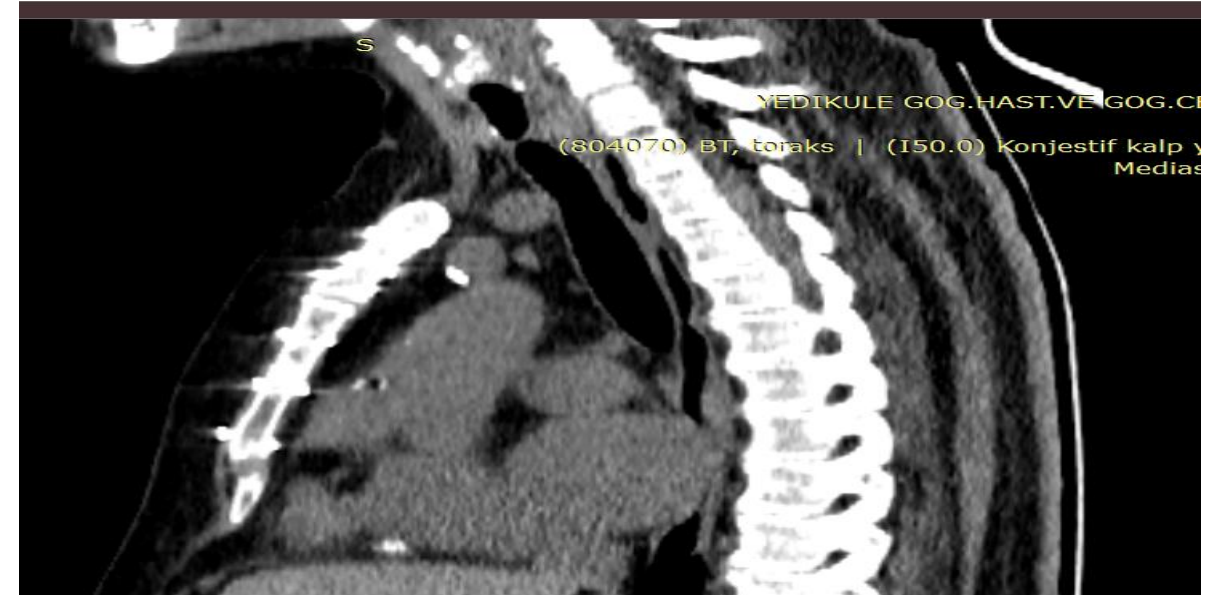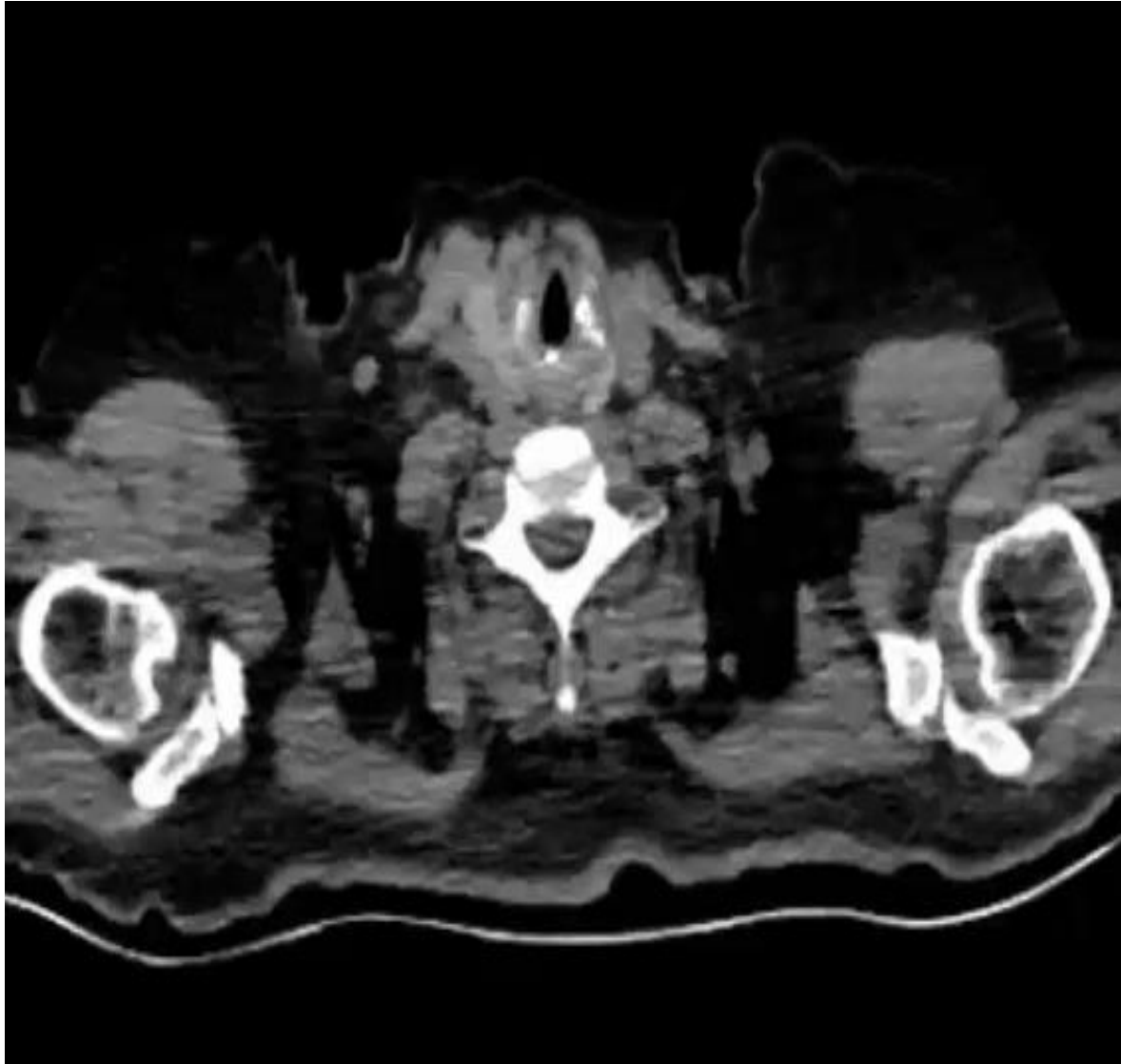
SON BAŞVURU PA AKCİĞER GRAFİSİ

SON RİJİD BRONKOSKOPİ

OLGU 8



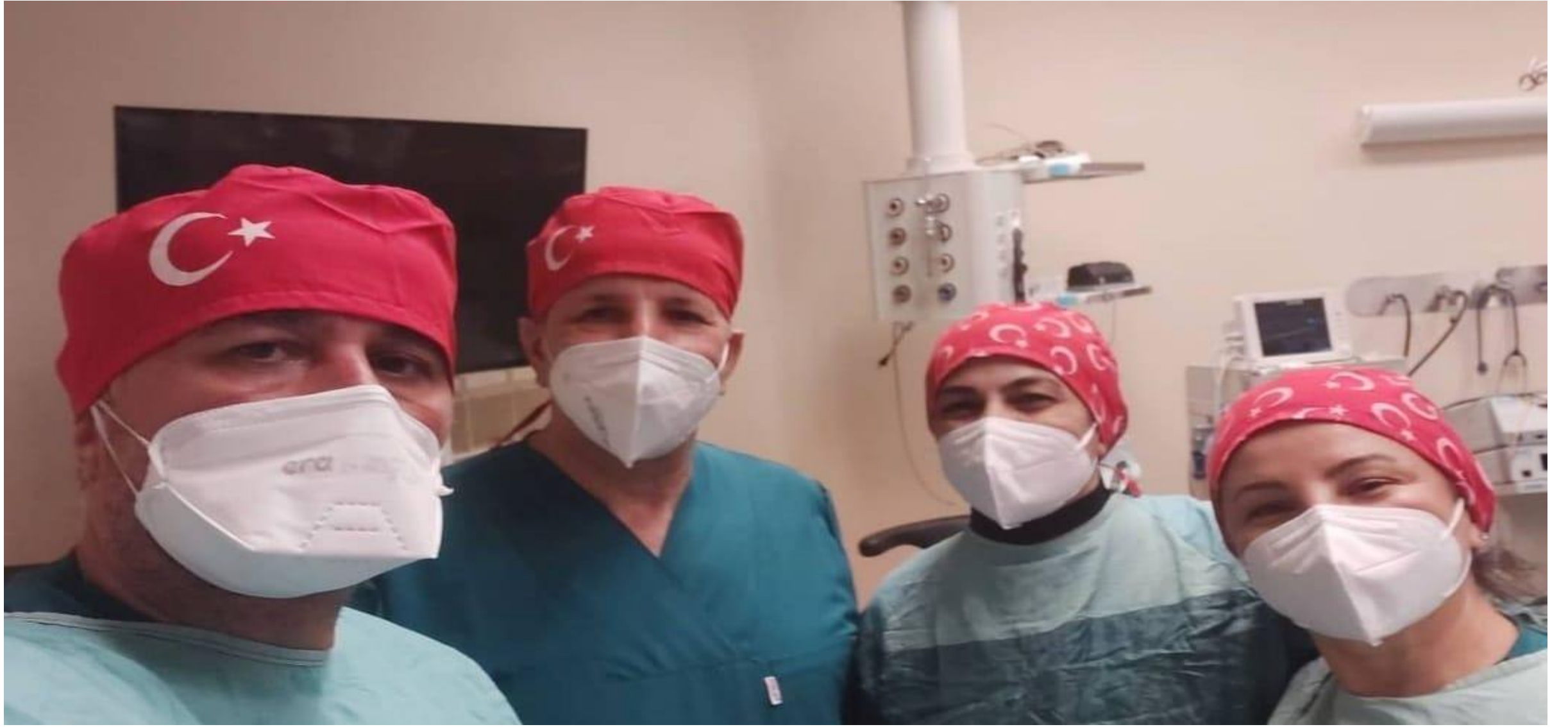OLGU 8



STENT SONRASI TORAKS BT

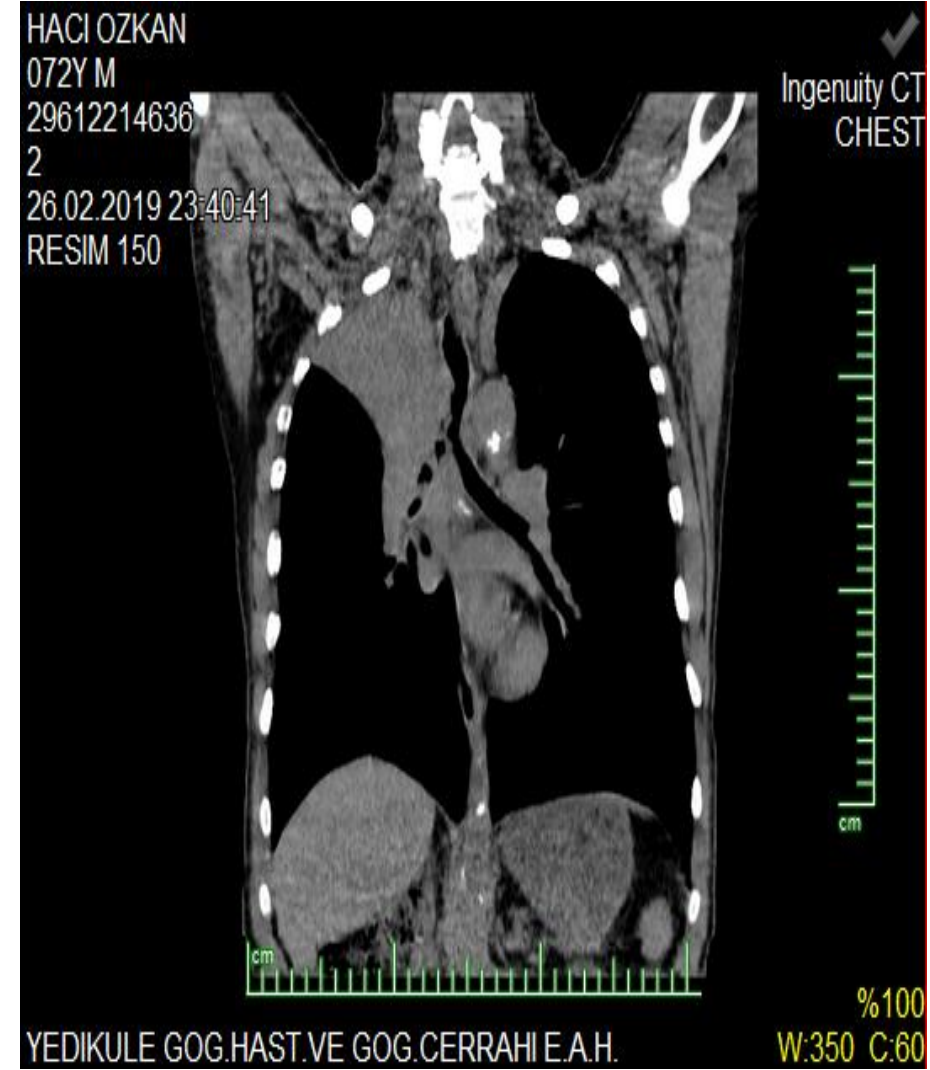
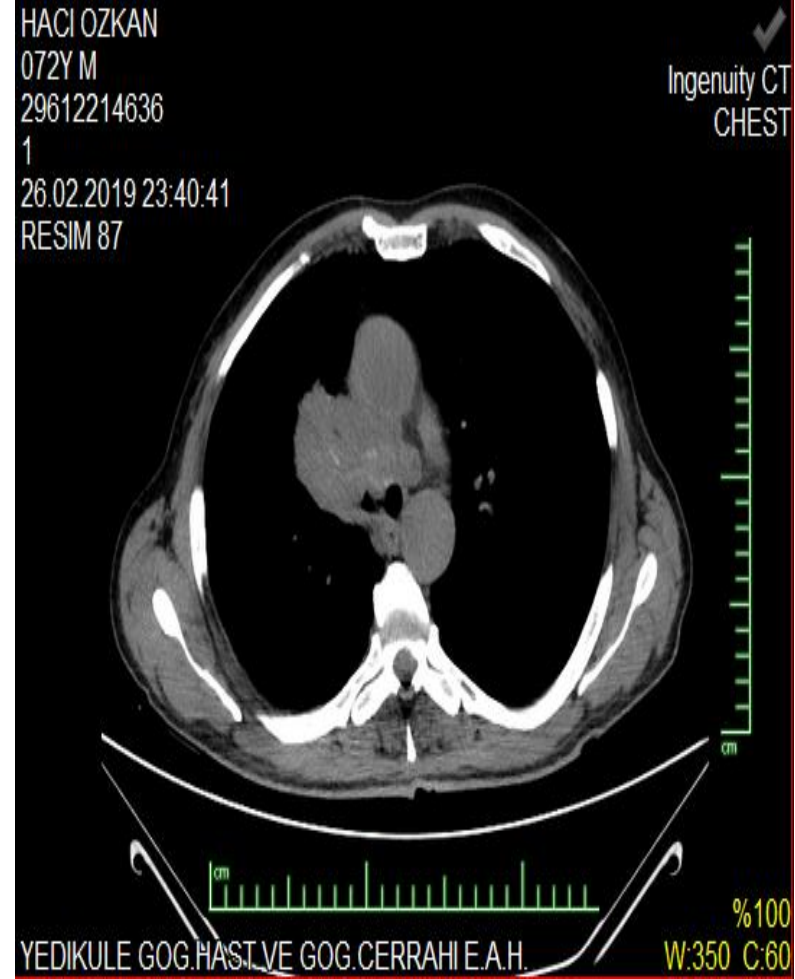
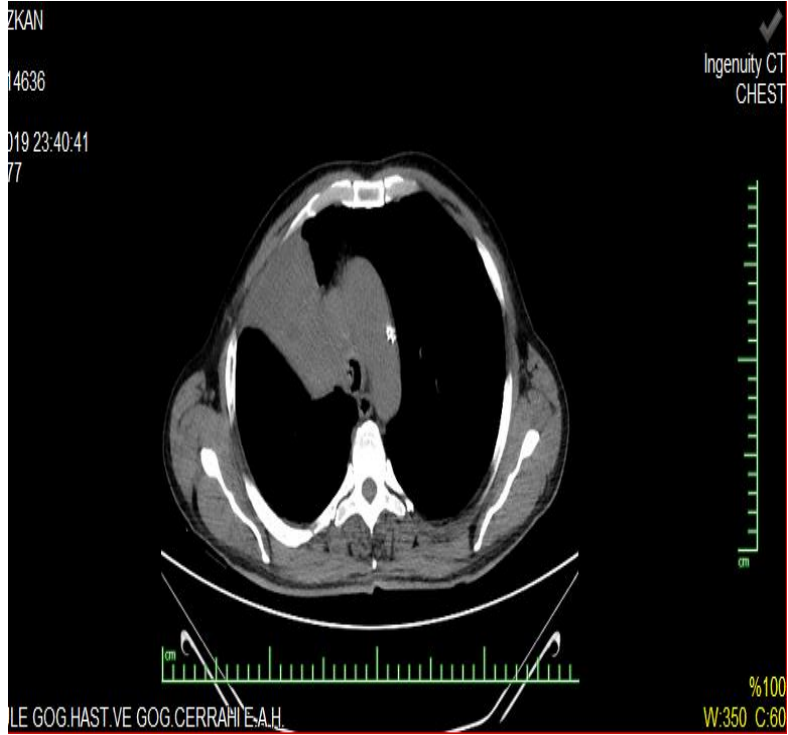
- **Masif hemoraji**
- **Endobronşial yanıklar**
- **Asfiksi**
- **Trakeal ya da bronşial perforasyon**
- **Trakeoözafegial fistül**
- **Kardiak aritmi**

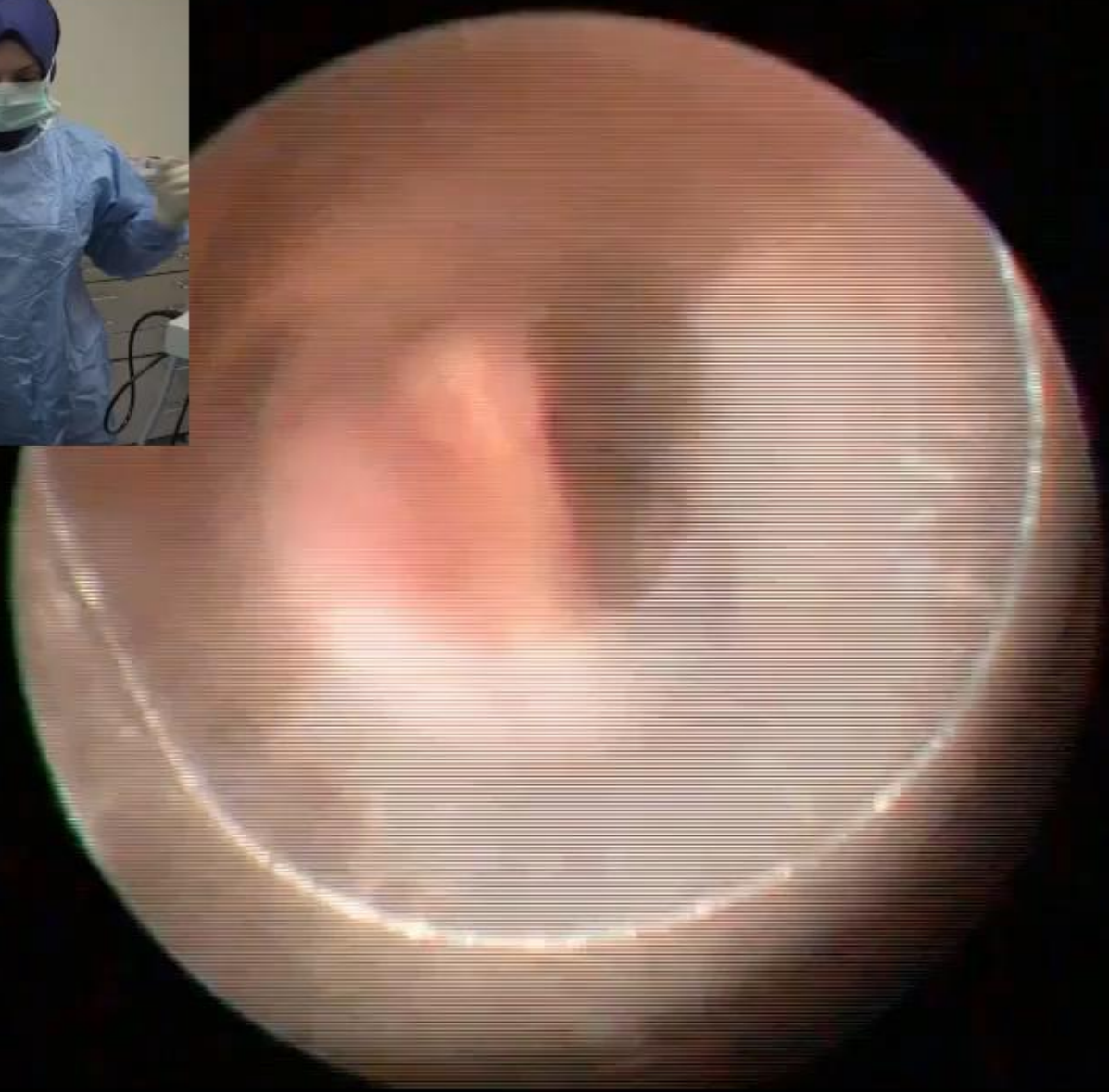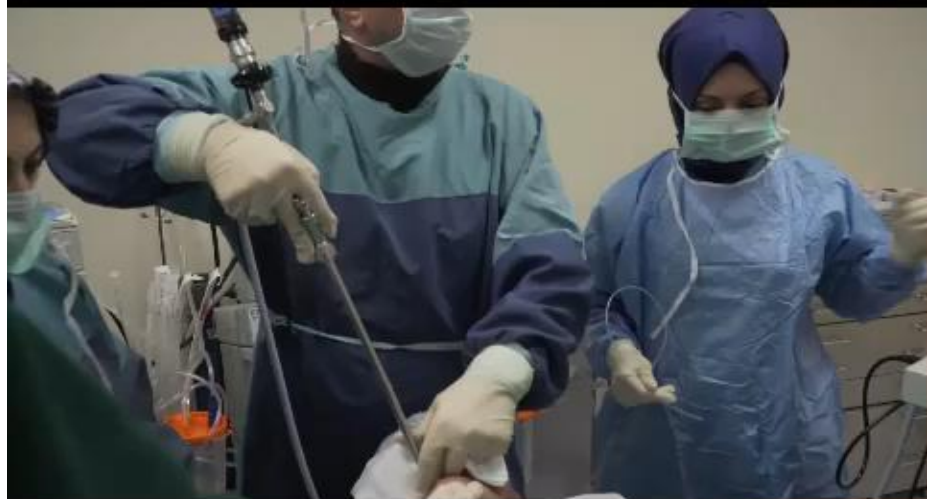- **Du Rand IA, Barber PV, Goldring J, Lewis RA, et al. British Thoracic Society guideline for advanced diagnostic and therapeutic flexible bronchoscopy in adults. Thorax 2011; 66 (3)**



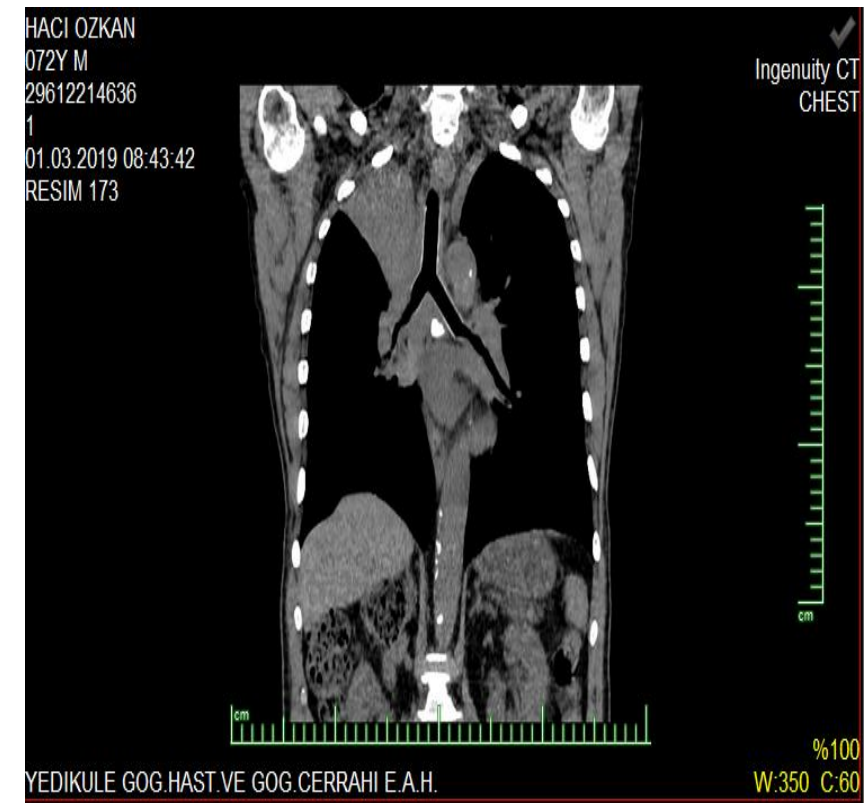
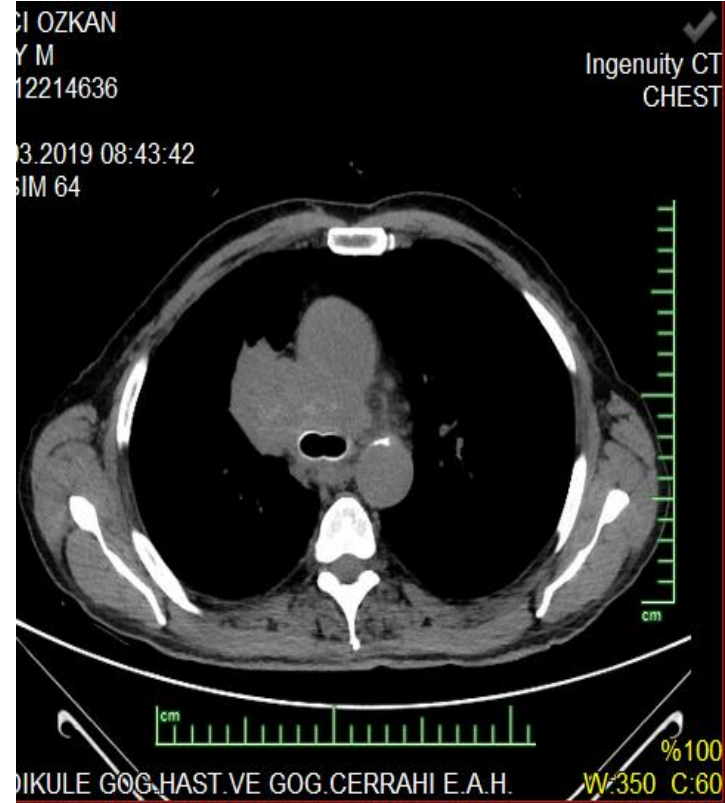
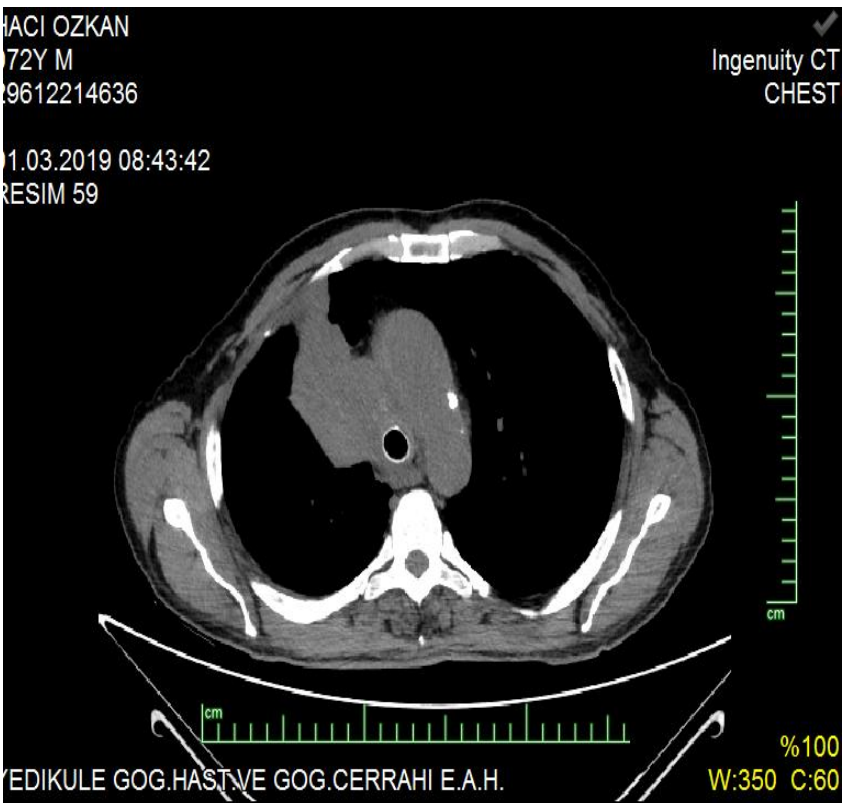
Dikkatiniz için teşekkürler...

Olgu 8





Olgu 8



PERİFERİK PULMONER LEZYONLAR



Review

Endoscopic Technologies for Peripheral Pulmonary Lesions: From Diagnosis to Therapy

Alberto Fantin ^{1,*}, Massimiliano Manera ², Vincenzo Patruno ¹ , Giulia Sartori ², Nadia Castaldo ¹ and Ernesto Crisafulli ²

Method	Advantages	Disadvantages
Ultrathin bronchoscopy	<ul style="list-style-type: none"> Affordable Easily introduced into an already-established clinical practice 	<ul style="list-style-type: none"> Operator-dependent tip stability Small working channel
RP-EBUS	<ul style="list-style-type: none"> Affordable Easily introduced into an already-established clinical practice 	<ul style="list-style-type: none"> Need to interpret artifacts No real-time guidance during sampling
Virtual navigation bronchoscopy	<ul style="list-style-type: none"> Active navigation correction according to preprocedural planning BTPNA 	<ul style="list-style-type: none"> CT-to-body divergence Absence of real-time position correction by fluoroscopy
EMN	<ul style="list-style-type: none"> Active navigation correction according to preprocedural planning Ability to associate real-time navigation correction with fluoroscopy Real-time guidance during sampling 	<ul style="list-style-type: none"> CT-to-body divergence Interference with metallic objects and other magnetic fields
Shape-sensing navigation	<ul style="list-style-type: none"> Operator-independent tip stability 	<ul style="list-style-type: none"> Expensive in terms of acquisition (at present only within robotic bronchoscopy technology)
Augmented fluoroscopy	<ul style="list-style-type: none"> Real-time navigation correction with fluoroscopy 	<ul style="list-style-type: none"> Expensive in terms of acquisition
CBCT	<ul style="list-style-type: none"> The gold standard for tool-in-lesion confirmation 	<ul style="list-style-type: none"> Expensive in terms of acquisition Non-negligible radiation exposure
Robotic bronchoscopy	<ul style="list-style-type: none"> Integration of a navigation system within an articulating catheter that can be used for multiple purposes 	<ul style="list-style-type: none"> Expensive both in terms of acquisition and consumables Technical demanding Requires general anesthesia CT-to-body divergence

RP-EBUS, radial-probe endobronchial ultrasound; BTPNA, bronchial transparenchymal nodule access; EMN, electromagnetic navigation; CBCT, cone-beam computed tomography.

Efficacy and Safety of Cone–Beam Computed Tomography–Derived Augmented Fluoroscopy Combined with Endobronchial Ultrasound in Peripheral Pulmonary Lesions

Kai-Lun Yu ¹ ², Shun-Mao Yang ³, Huan-Jang Ko ³, Hui-Yu Tsai ⁴, Jen-Chung Ko ¹, Ching-Kai Lin ⁵, Chao-Chi Ho ⁶, Jin-Yuan Shih ² ⁶

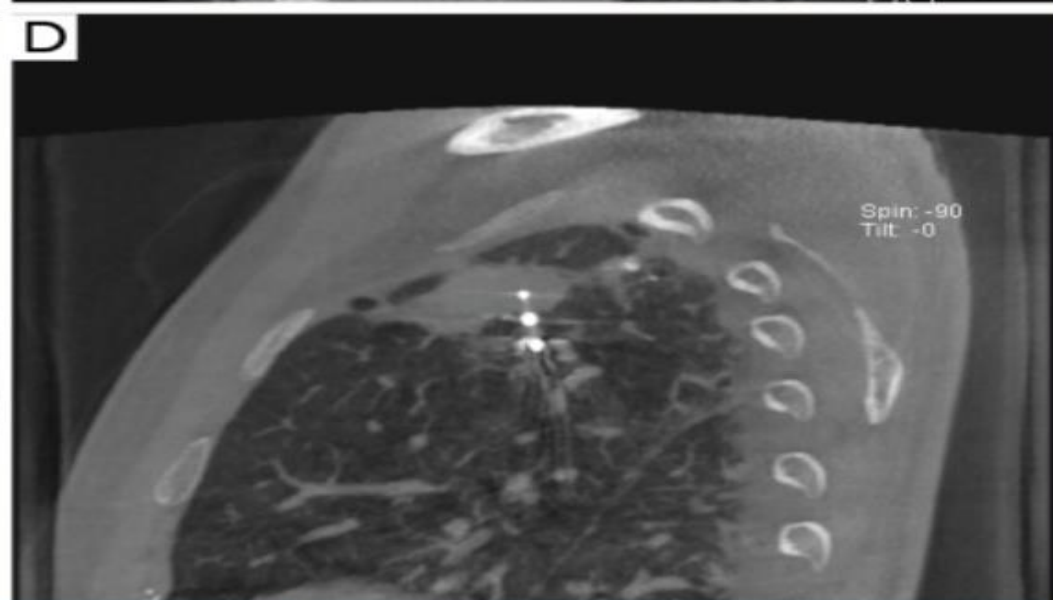
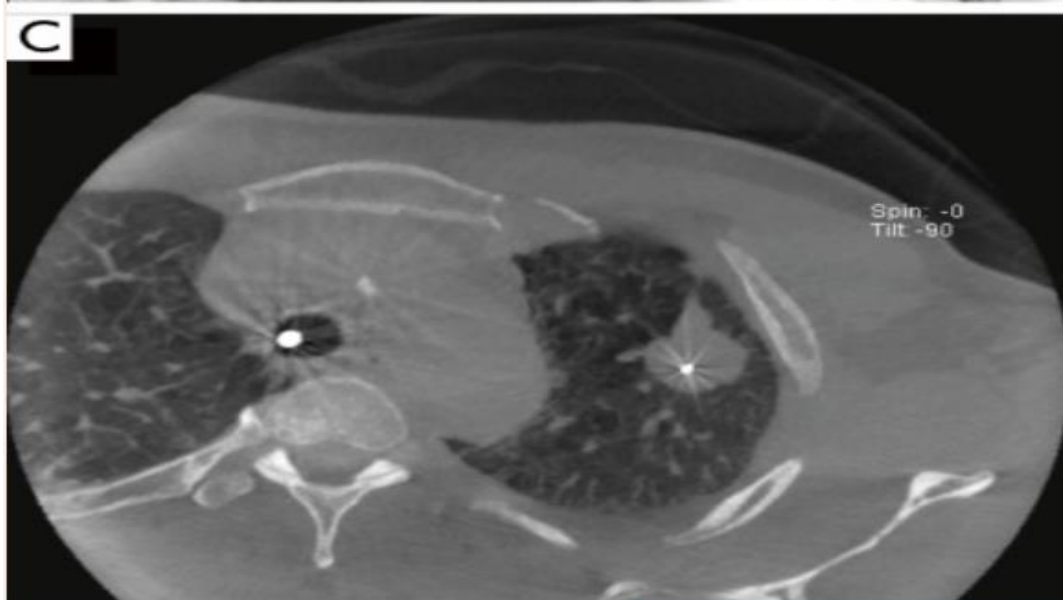
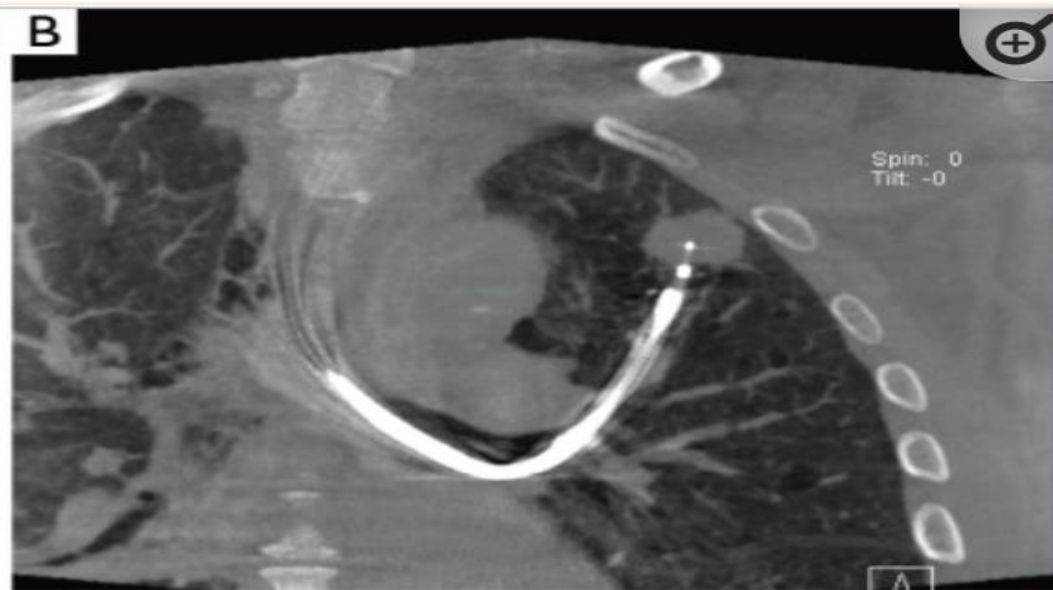
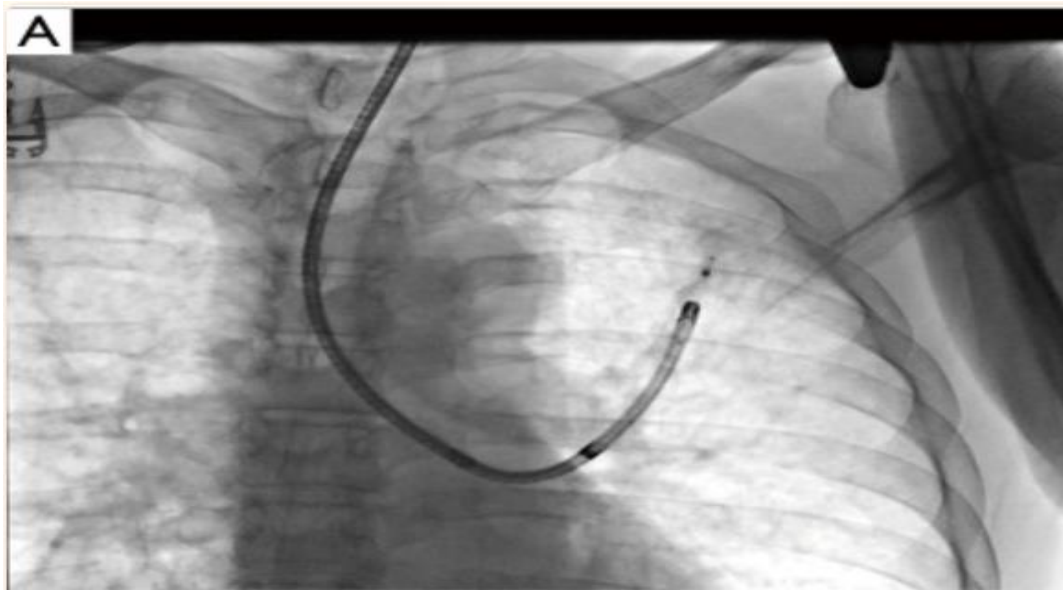Background: The diagnostic yield of peripheral pulmonary lesions (PPLs) using radial endobronchial ultrasound (EBUS) remains challenging without navigation systems. Cone-beam computed tomography-derived augmented fluoroscopy (CBCT-AF) represents a recently developed technique, and its clinical utility remains to be investigated.

Objectives: The aim of this study was to investigate the diagnostic yield of transbronchial biopsy (TBB) using a combination of CBCT-AF and radial EBUS.

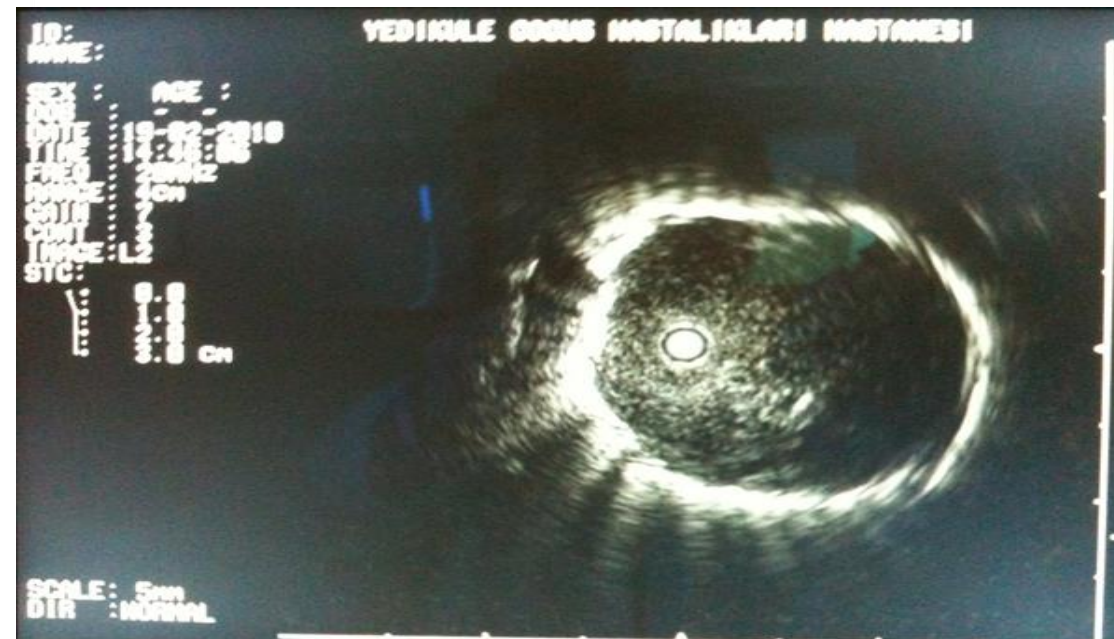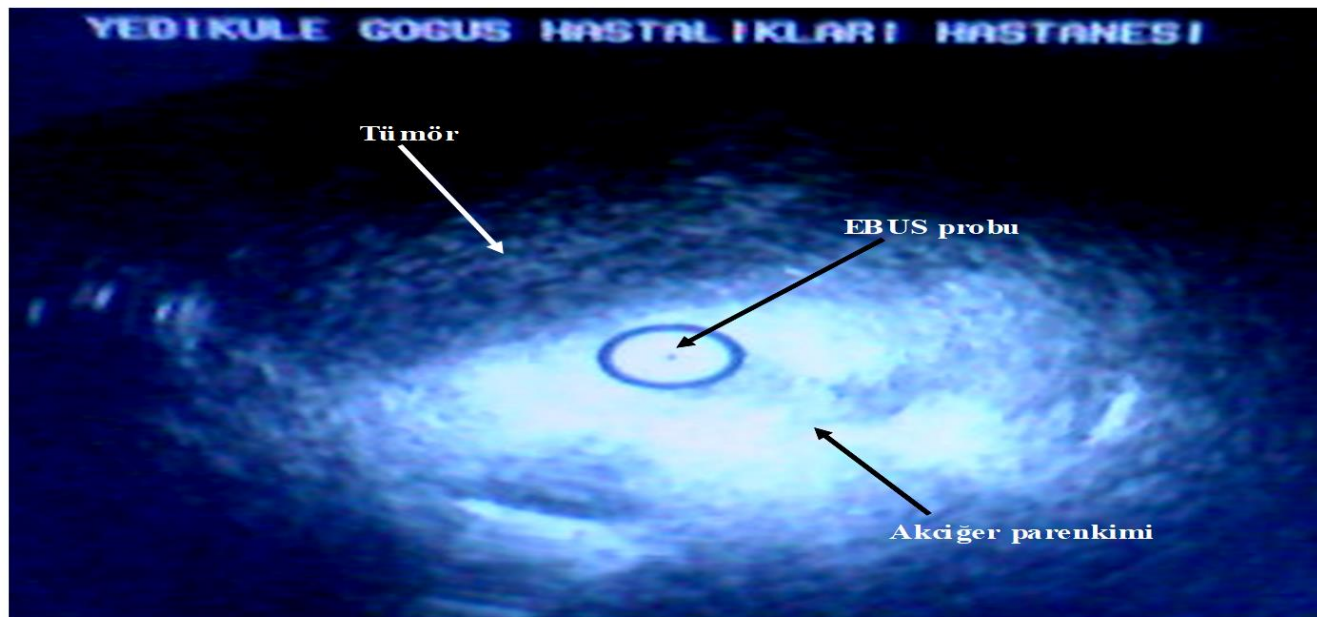
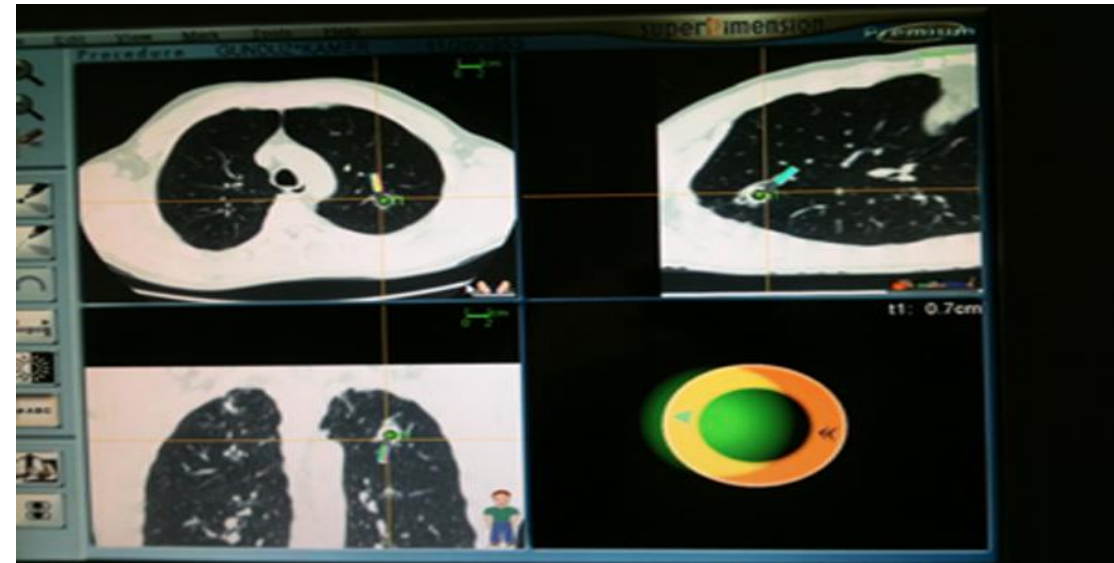
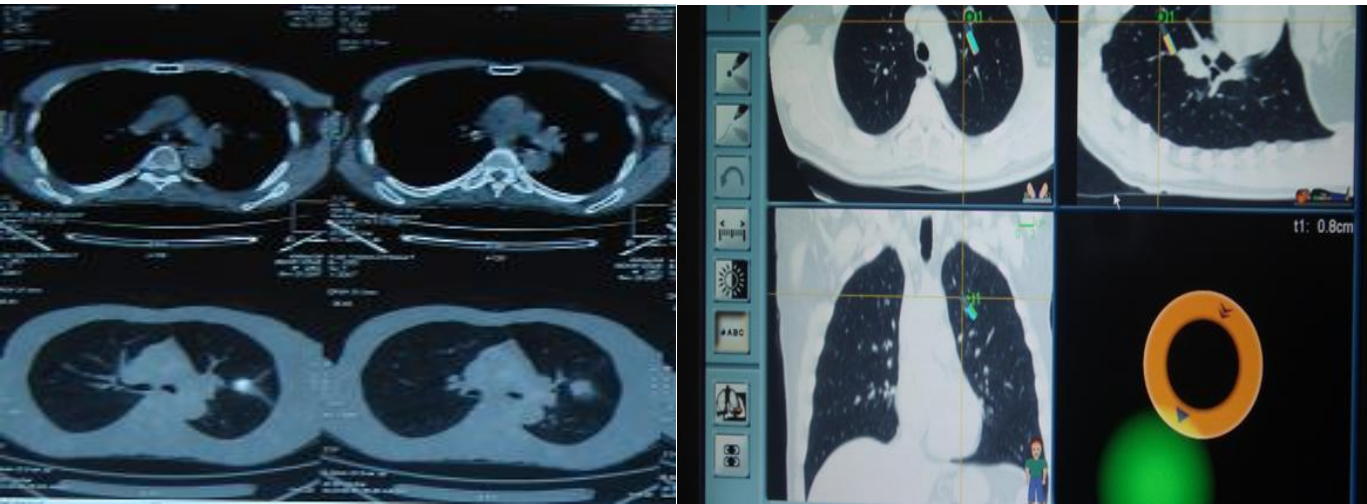
Methods: We recruited consecutive patients with PPLs who underwent radial EBUS-guided TBB, with or without AF, between October 2018 and July 2019. Following propensity score 1:1 matching, we recorded the procedure-related data and measured their efficacy and safety.

Results: While 72 patients received EBUS-plus-AF, 235 patients received EBUS only. We included 53 paired patients following propensity score matching. The median size of lesions was 2.8 and 2.9 cm in the EBUS-plus-AF group and EBUS-only group, respectively. Diagnostic yield was higher in the former group (75.5 vs. 52.8%; $p = 0.015$). The diagnostic yield for the EBUS-plus-AF group was significantly higher for lesions ≤ 30 mm (73.5 vs. 36.1%; $p = 0.002$). Moreover, there was no significant difference in the complication rates (3.8 vs. 5.7%; $p = 1.000$). Twenty-four nodules (45.3%) were invisible by fluoroscopy in the EBUS-plus-AF group. All of them were identifiable on CBCT images and successfully annotated for AF. The mean radiation dose of total procedure, CBCT, and fluoroscopy was 19.59, 16.4, and 3.17 Gy cm², respectively.

Conclusions: TBB using a combination of CBCT-AF and EBUS resulted in a satisfactory diagnostic yield and safety.



Elektromagnetik navigasyon +EBUS OLGU



ENB-Tedavi

- **Endoluminal Brakiterapi**
- 18 inoperabl periferik akciğer kanserli hasta
- ENB ile lezyona ulaşıldıktan sonra EBUS ile konfirmasyon
- Brakiterapi kateterinin yerleştirilmesi
- 9 hastada tam yanıt, 9 hastada parsiyel yanıt

Becker HD, et al: Electromagnetic navigation and endobronchial ultrasound for brachytherapy of inoperable peripheral lung cancer. Chest 2008; 134:396

Ablative technique	Ablation followed by surgical resection	Region	ClinicalTrials.gov identifier
PDT	No	United States, Canada	<u>NCT02916745</u>
PDT	Yes	United States	<u>NCT03344861</u>
PDT	No	Taiwan	<u>NCT03211078</u>
TVA	Yes	Australia	<u>NCT03198468</u>
TVA	No	Austria, Italy	<u>NCT03514329</u>
BLITT	Yes	United States	<u>NCT03707925</u>
RFA	No	China	<u>NCT03009630</u>
RFA	Yes	China	<u>NCT03272971</u>
RFA/MWA	No	China	<u>NCT02972177</u>
MWA	No	United States	<u>NCT03713099</u>
MWA	No	United Kingdom	<u>NCT03569111</u>

Bronchoscopy-Guided Cooled Radiofrequency Ablation as a Novel Intervention Therapy for Peripheral Lung Cancer

Tomonobu Koizumi ¹, Kenji Tsushima, Tsuyoshi Tanabe, Toshihiko Agatsuma, Toshiki Yokoyama, Michiko Ito, Shintaro Kanda, Takashi Kobayashi, Masanori Yasuo

Background: Our previous animal and preliminary human studies indicated that bronchoscopy-guided cooled radiofrequency ablation (RFA) for the lung is a safe and feasible procedure without major complications.

Objectives: The present study was performed to evaluate the safety, effectiveness and feasibility of computed tomography (CT)-guided bronchoscopy cooled RFA in patients with medically inoperable non-small-cell lung cancer (NSCLC).

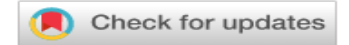Methods: Patients with pathologically diagnosed NSCLC, who had no lymph node involvement or distant metastases (T1-2aN0M0) but were not surgical candidates because of comorbidities (e.g.,

- T1 2N0M0
- 20 hasta 28 ablasyon
- PFS 35 ay
- 5 yıl sürvi %61

required hospitalization but improved with conservative treatment. There were no other adverse events in the present study.

Conclusions: CT-guided bronchoscopy cooled RFA is applicable for only highly selected subjects; however, our trial may be an alternative strategy, especially for disease local control in medically inoperable patients with stage I NSCLC.

Original Article



Transbronchial microwave ablation of lung nodules with electromagnetic navigation bronchoscopy guidance—a novel technique and initial experience with 30 cases

Joyce W. Y. Chan¹, Rainbow W. H. Lau¹, Jenny C. L. Ngai², Carita Tsoi³, Cheuk Man Chu³, Tony S. K. Mok⁴, Calvin S. H. Ng¹

- 25 hasta 30 nodül
- Ortalama 15 mm
- Yarısı bronkus sign pozitif
- 12 ay takip progresyon yok

(bronchus sign positive) in only half of them. Technical success rate was 100%, although some nodules required double ablation for adequate coverage. Mean minimal ablation margin was 5.51 mm. The mean actual ablation zone volume was –21.4% compared to predicted, likely due to significant tissue contraction ranging from 0–43%. There was no significant heat sink effect. Mean hospital stay was 1.73 days, and only 1 patient stayed for more than 3 days. Complications included pain (13.3%), pneumothorax requiring drainage (6.67%), post-ablation reaction (6.67%), pleural effusion (3.33%) and hemoptysis (3.33%). After median follow up of 12 months, none of the nodules had evidence of progression.

Conclusions: Bronchoscopic transbronchial microwave ablation is safe and feasible for treatment of malignant lung nodules. Prospective study on clinical application of this novel technique is warranted.

Novel light delivery method for performing transbronchial photodynamic therapy ablation to treat peripheral lung cancer: A pilot study

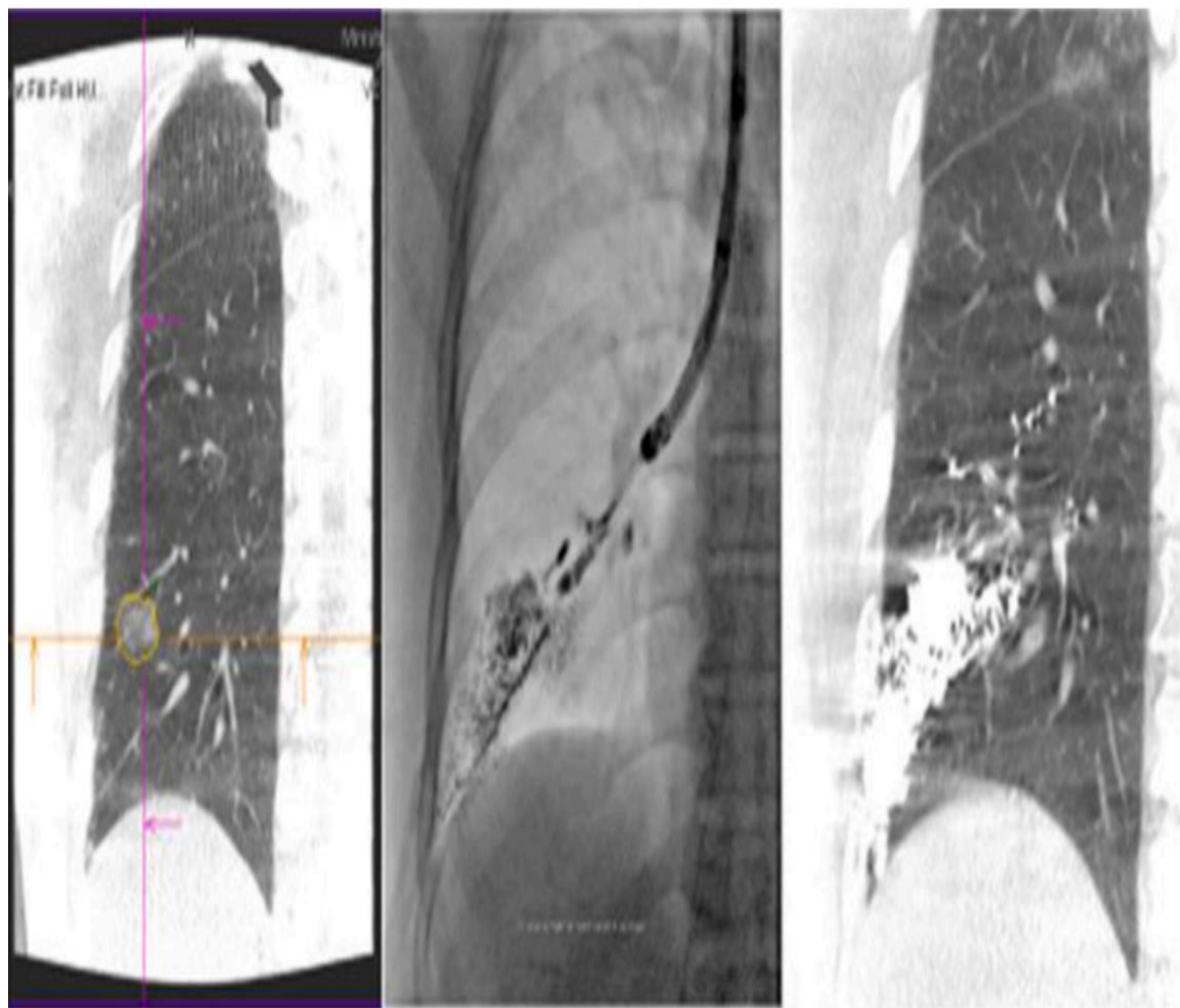
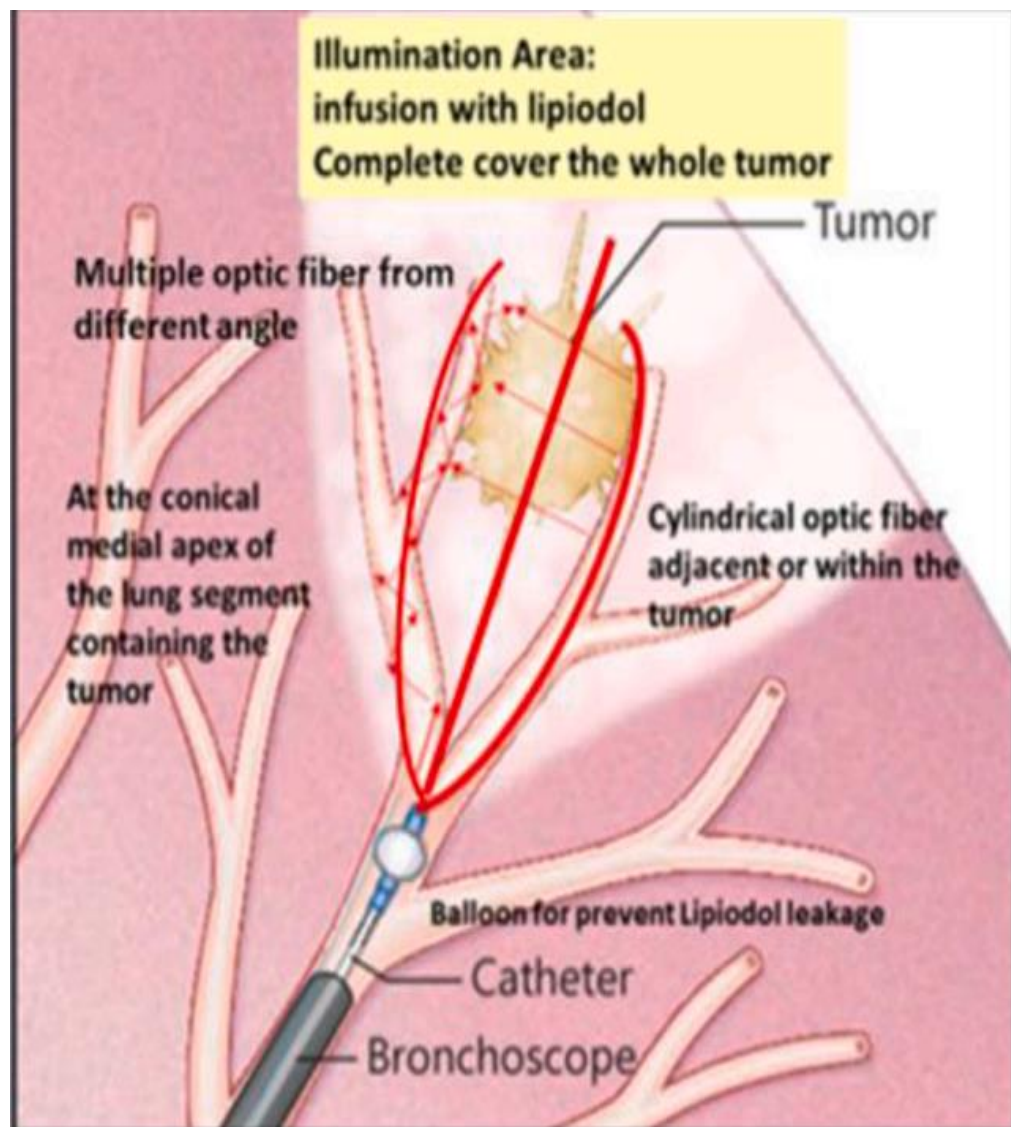
Hwailuh Chang^a, Yu-Chi Chiu^b, Shih-Wei Lee^b, Chu-Cheng Yen^c, Jih-Tung Pai^d, Cho-Yin Lee^e, Yen-Lin Wu^f, Chi-Ming Lee^f, Yei-San Hsieh^{a,*}

Background: Photodynamic therapy involves using a photosensitizer with light illumination and is recommended for treating early, centrally located lung cancers, but it is not a standard treatment for peripheral lung tumor. We previously proposed a novel light delivery method, in which lipiodol is perfused into the bronchial tree to increase the scope of illumination via the fiber effect. Herein, we attempted this novel technique under electromagnetic bronchoscope guidance in a hybrid operation room where lipiodol facilitated light diffusion, and evaluated the effectiveness and feasibility of this technique for peripheral lung cancers.

Methods: This phase 0 pilot study included three patients with peripheral lung cancers (primary tumors ≤ 20 -mm diameter). The photodynamic therapy was administered using Porfimer sodium as the photosensitizer, and an electromagnetic navigation bronchoscope in a hybrid operating room to guide the catheter to the tumor. This facilitated lipiodol infusion to encase the tumor and permit the transbronchial photodynamic therapy ablation.

Results: Administering 630 nm 200 J/cm (400mW/500sec) energy through a 3-cm cylindrical diffusing laser fiber was safe; no significant acute complications were observed. Although the treatment outcome was unsatisfactory due to the low light dose, tumor pathology in one case revealed tumor necrosis, with no significant damage to the surrounding lung tissue.

Conclusions: Novel light delivery transbronchial photodynamic therapy ablation for peripheral lung tumors is feasible and safe. Additional clinical trials may help determine the best illumination plan and light dose through multiple deliveries from multiple angles.



Review of current thermal ablation treatment for lung cancer and the potential of electrochemotherapy as a means for treatment of lung tumours

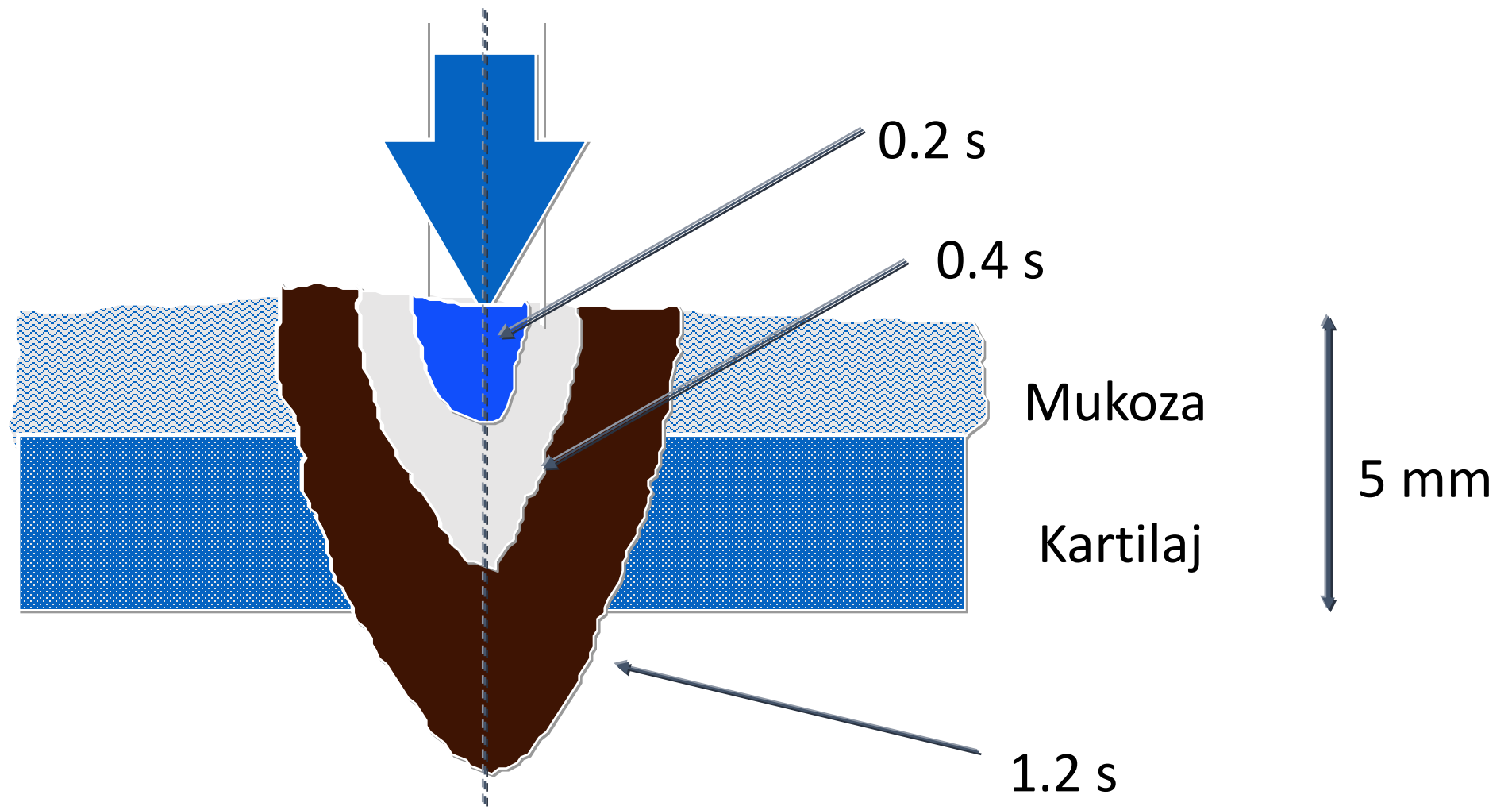
Saleem Jahangeer¹, Patrick Forde, Declan Soden, John Hinchion

Gelecekte....

(ClinicalTrials'da devam eden çalışmalar)

- **Akciğer maligniteler için doğrudan endobronşiyal ablasyon tedavileri (mikrodalga, radyofrekans, termal, lazer, kriyosprey)**
- **Primer lezyonda radyasyona duyarlılığı artırmak için doğrudan nanopartikül enjeksiyonu**
- **Kanser hücre ölümünü arttırmak için enfeksiyöz virüslerin enjeksiyonu**
- **Kemoterapi ve diğer antineoplastik ajanların tümörlere doğrudan enjeksiyonu**
- **Pre ve peri-operatif nodül işaretleme**

• İLGİNİZ VE DİKKATİNİZ İÇİN TEŞEKKÜR EDERİM



J.C Fisher 1983

PERİFERİK PULMONER LEZYONLAR

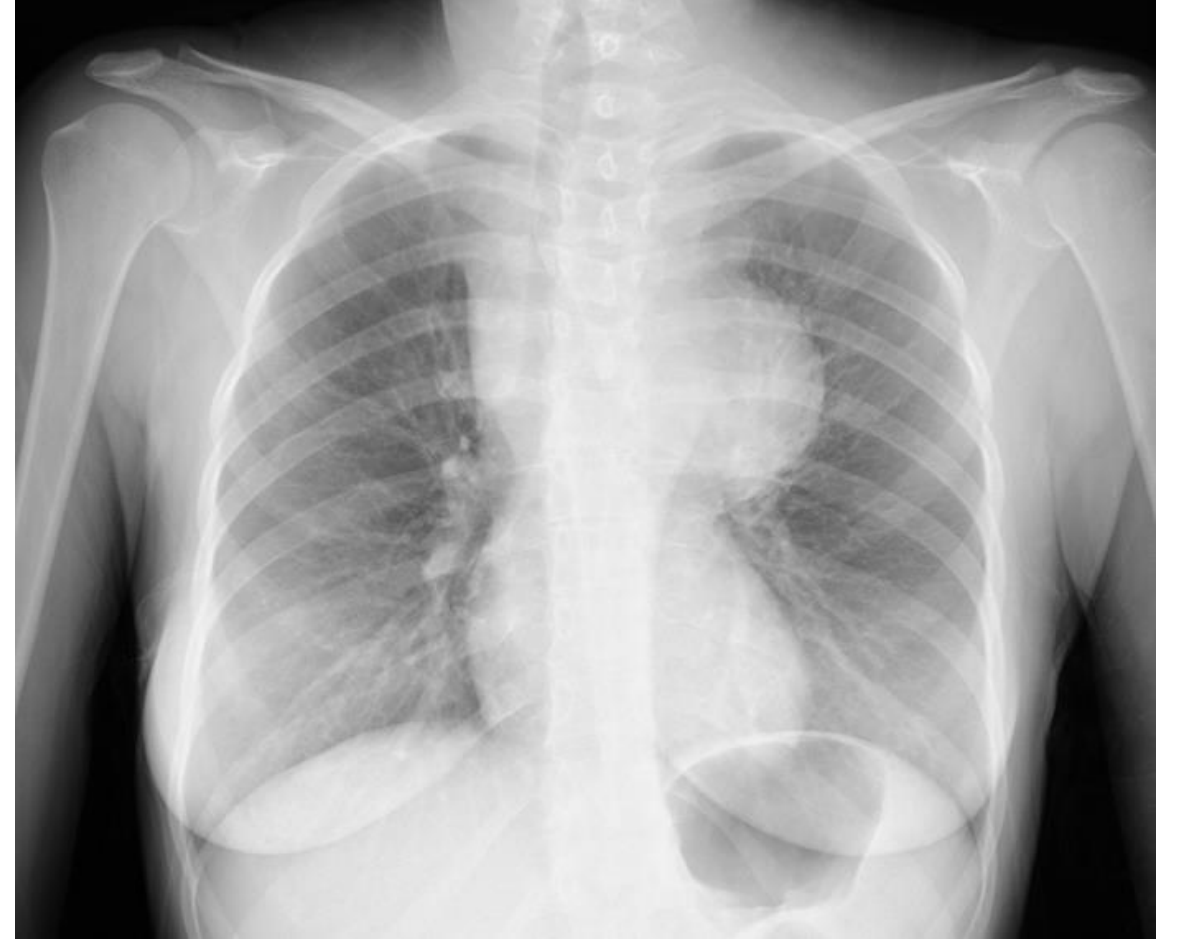- **BRONKOSKOPI**
 - *Konvansiyonel FOB*
 - *Fluoroskopi rehberliğinde TBBx*
 - *EBUS rehberliğinde TBBx*
 - *ENB rehberliğinde TBBx*
 - *Ultrathin bronkoskopi*

OLGU

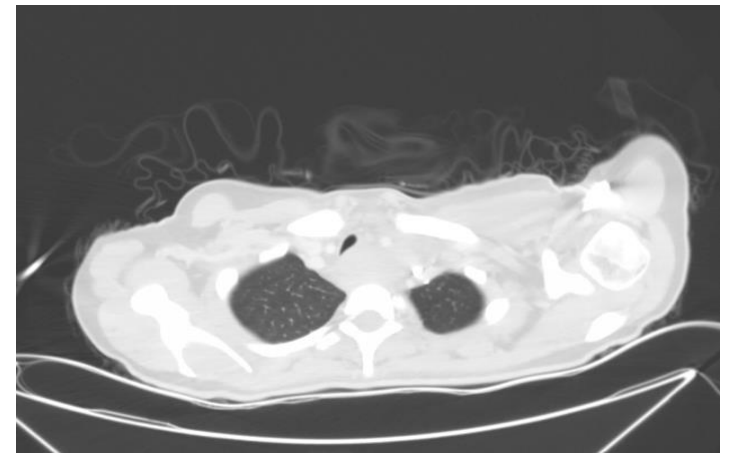
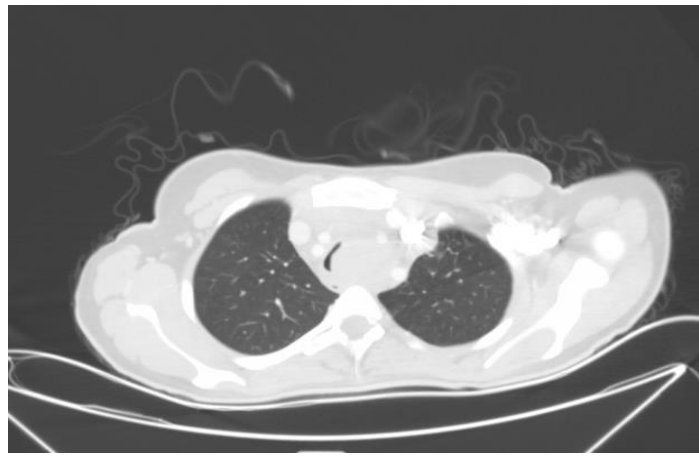
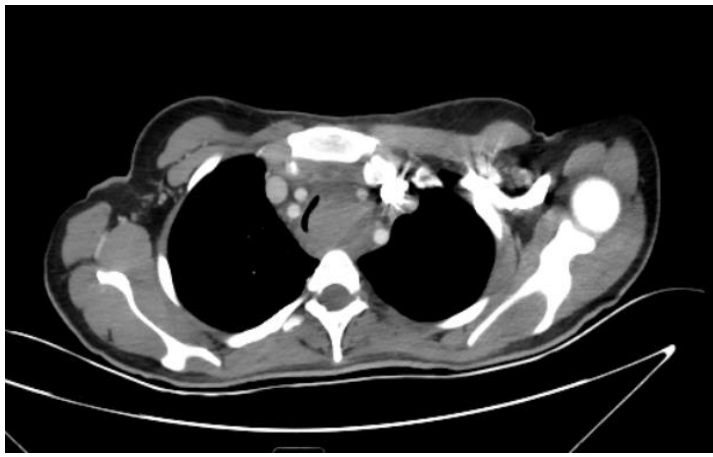
- 19 yaşında, kız
- Şikayeti: Öksürük, nefes darlığı, ses kısıklığı
- Hikayesi: 3 haftadır devam eden ses kısıklığı nedeni ile gittiği KBB hekimi tarafından servikal lenf nodu örneklenmesi planlanmış
- Ancak hasta bu süreçte ortaya çıkan ani nefes darlığı olması nedeni ile başvurduğu acilimizde interne edilmiş
- Özgeçmiş: Bir özellik yok

OLGU

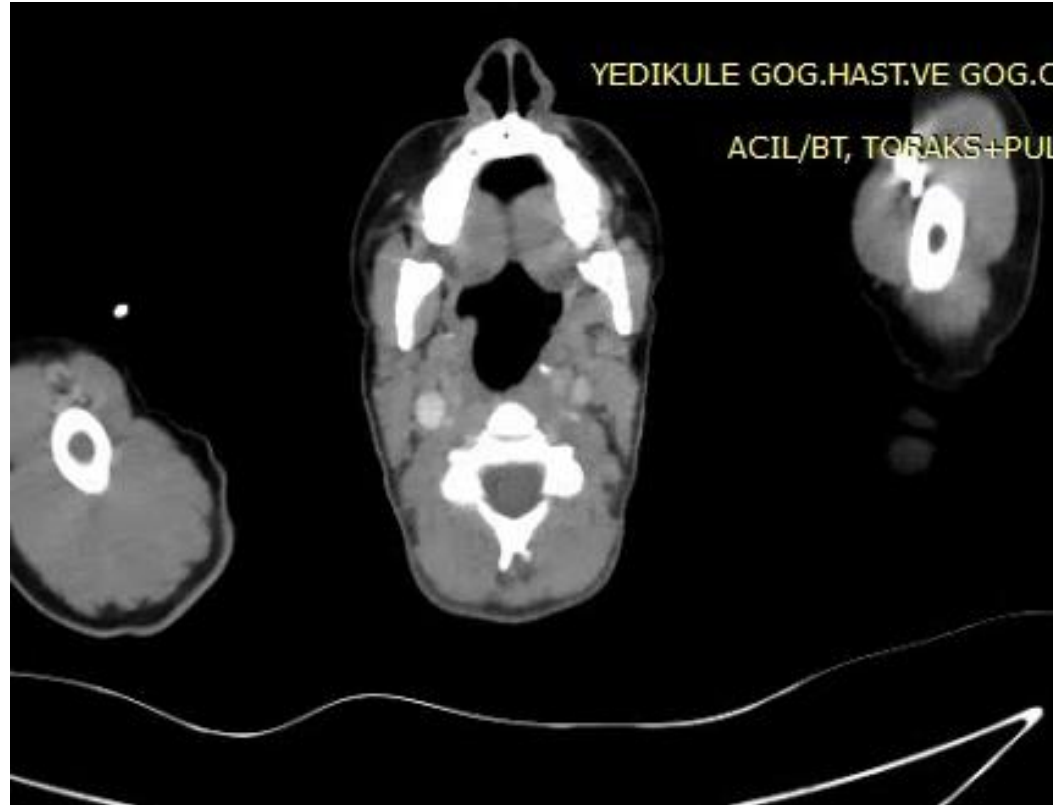- Alıřkanlık: Yok
- Bařvuru AKG: PH: 7.46 SO₂: 80
PCO₂: 27 PO₂: 56
- Hasta GBİ iin yatıřı esnasında solunum sıkıntısının artması zerine acil olarak GP nitemizde iřleme alındı, iřlem esnasında sol servikal lenf nodundan rnekleme yapıldı



PA AKCİĞER GRAFİSİ

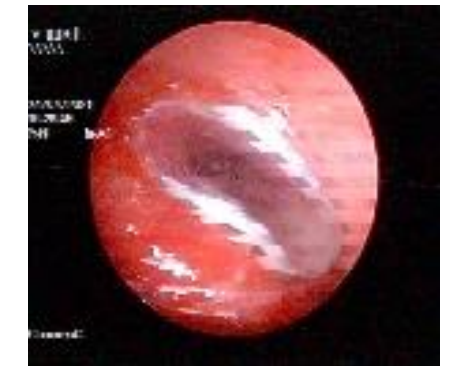
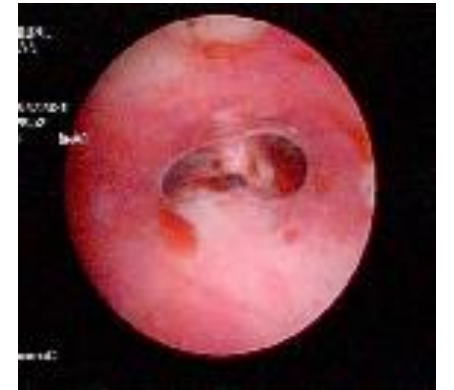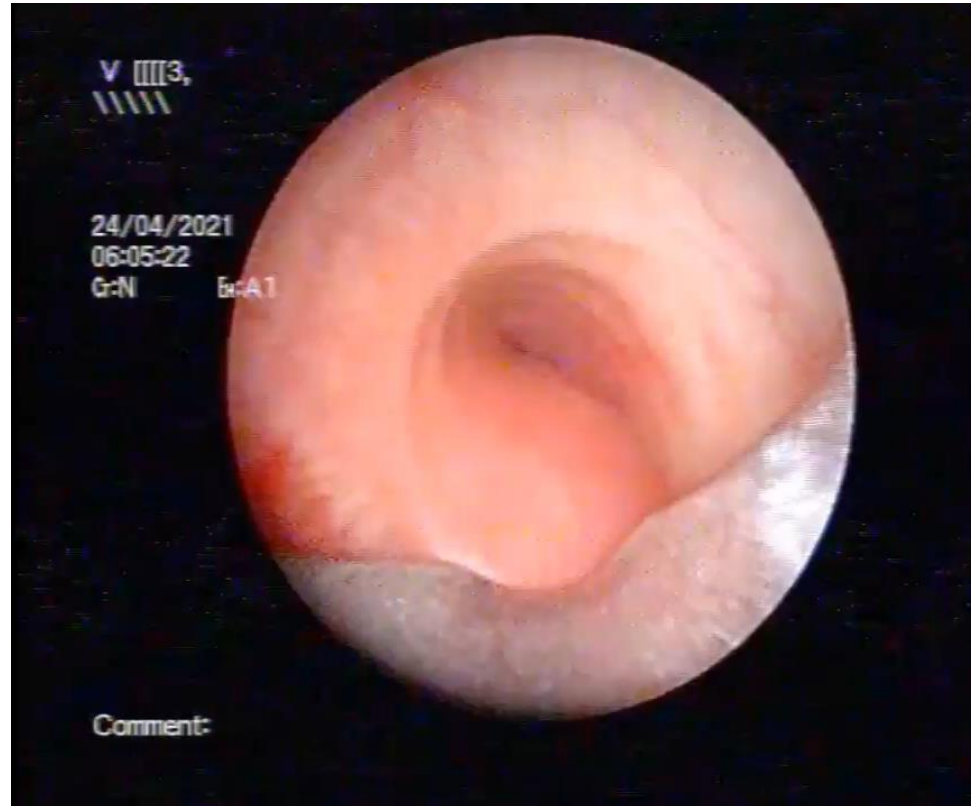

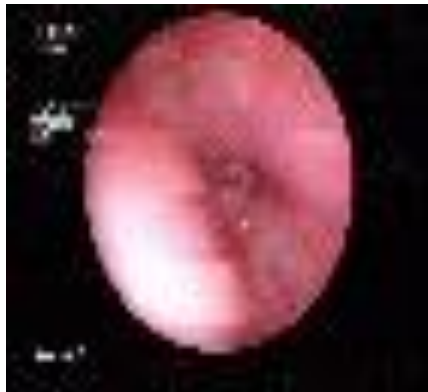
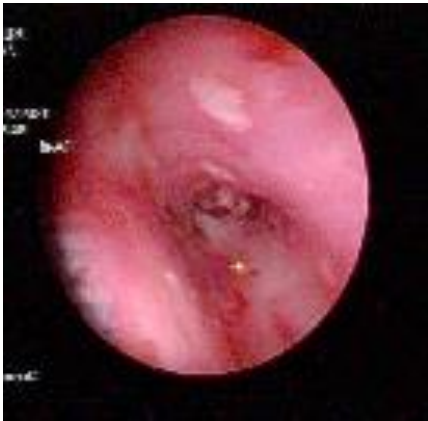TORAKS BT



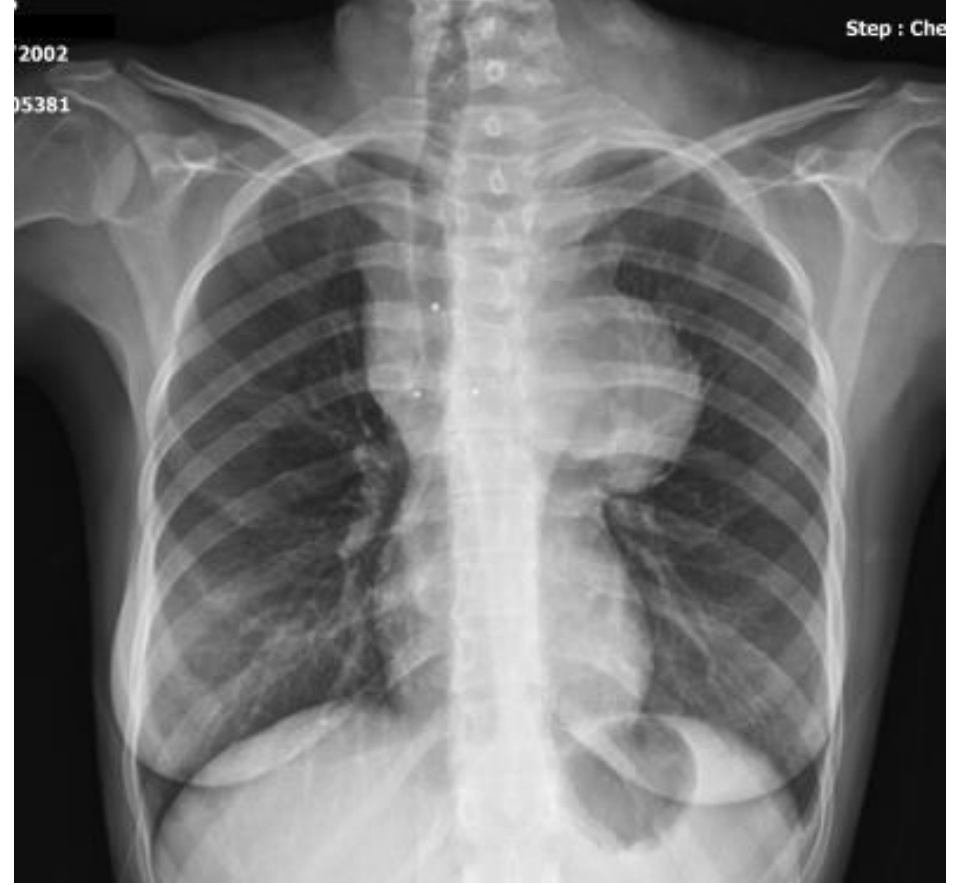
OLGU

RİJİD BRONKOSKOPİ



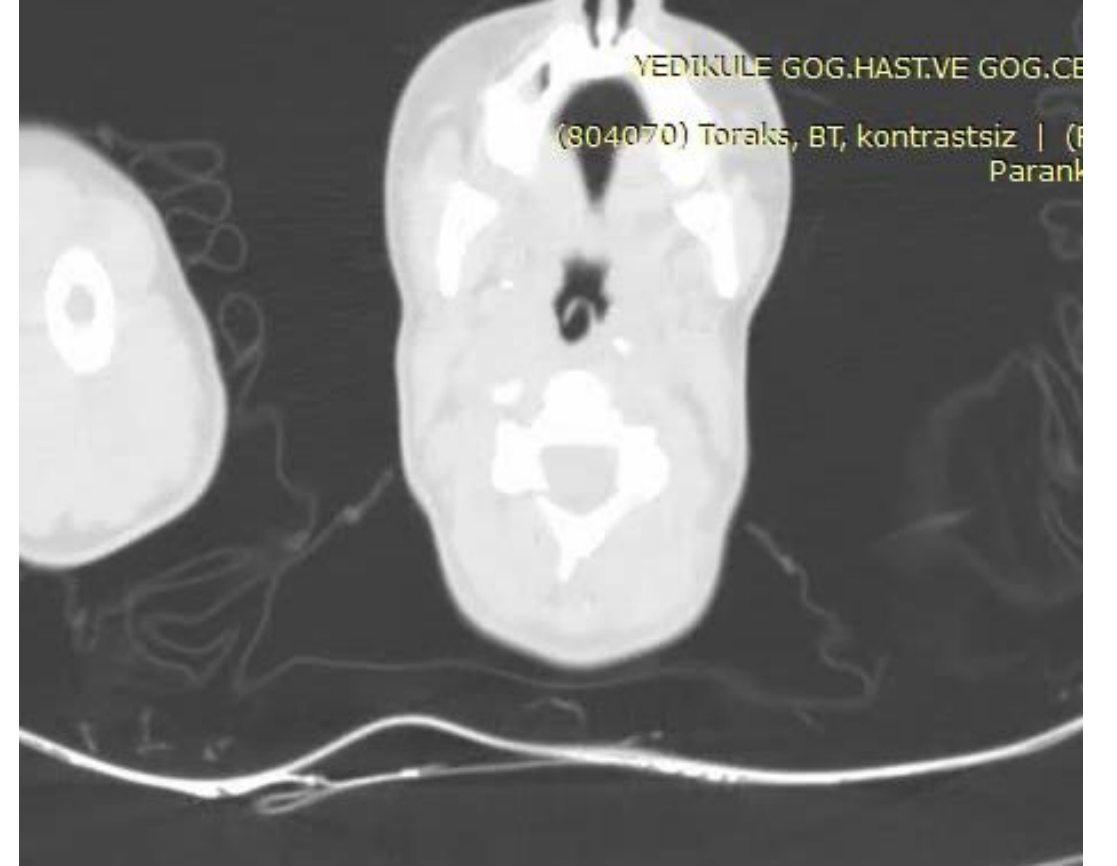
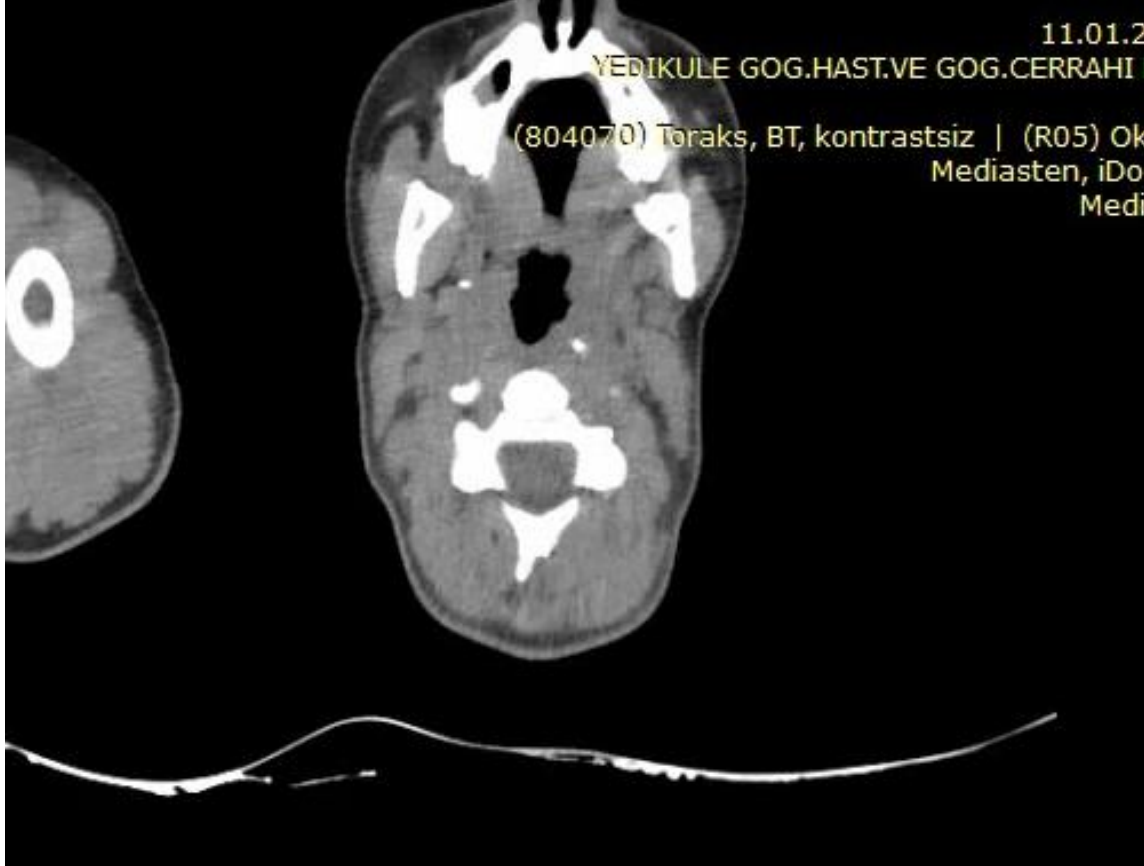
OLGU

- **TAKİP:**
- Patoloji: Hodgkin Lenfoma
- Onkolojik tedavisi : 4 kür ABVD KT
2 kür BEACOPP KT



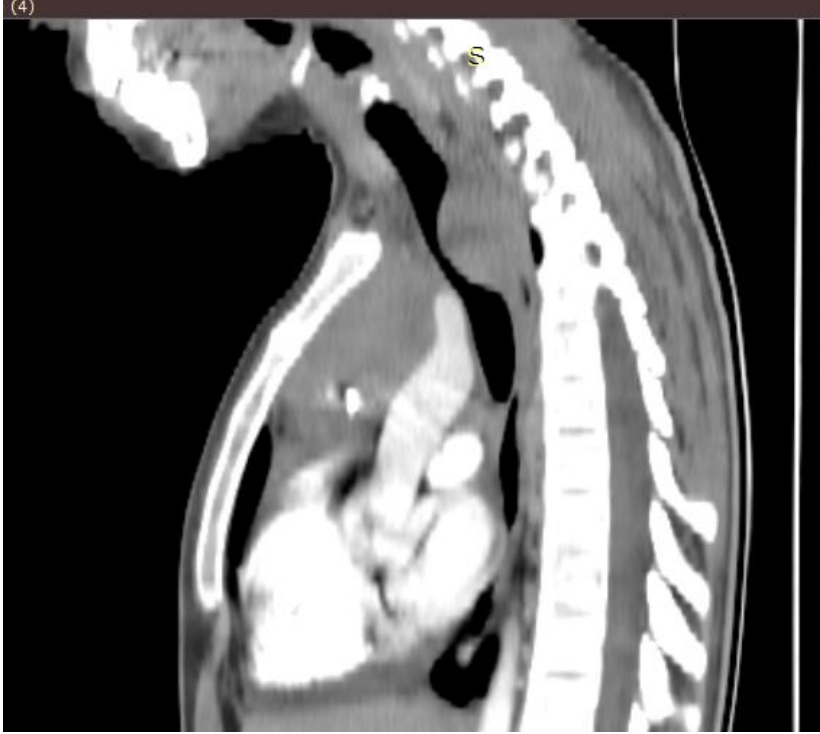İŞLEM SONRASI AKCİĞER GRAFİSİ

OLGU

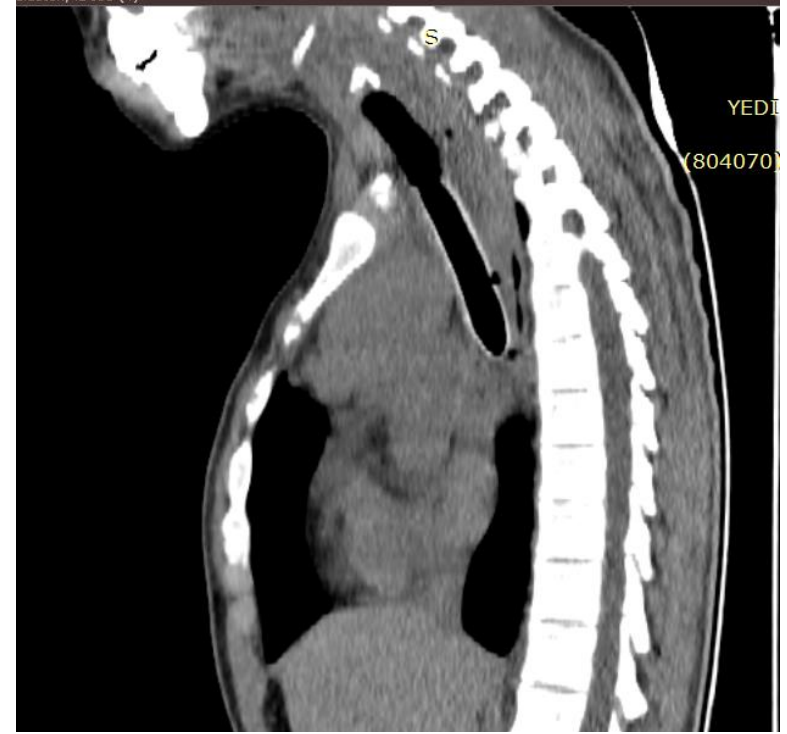


İŞLEM SONRASI TORAKS BT

OLGU

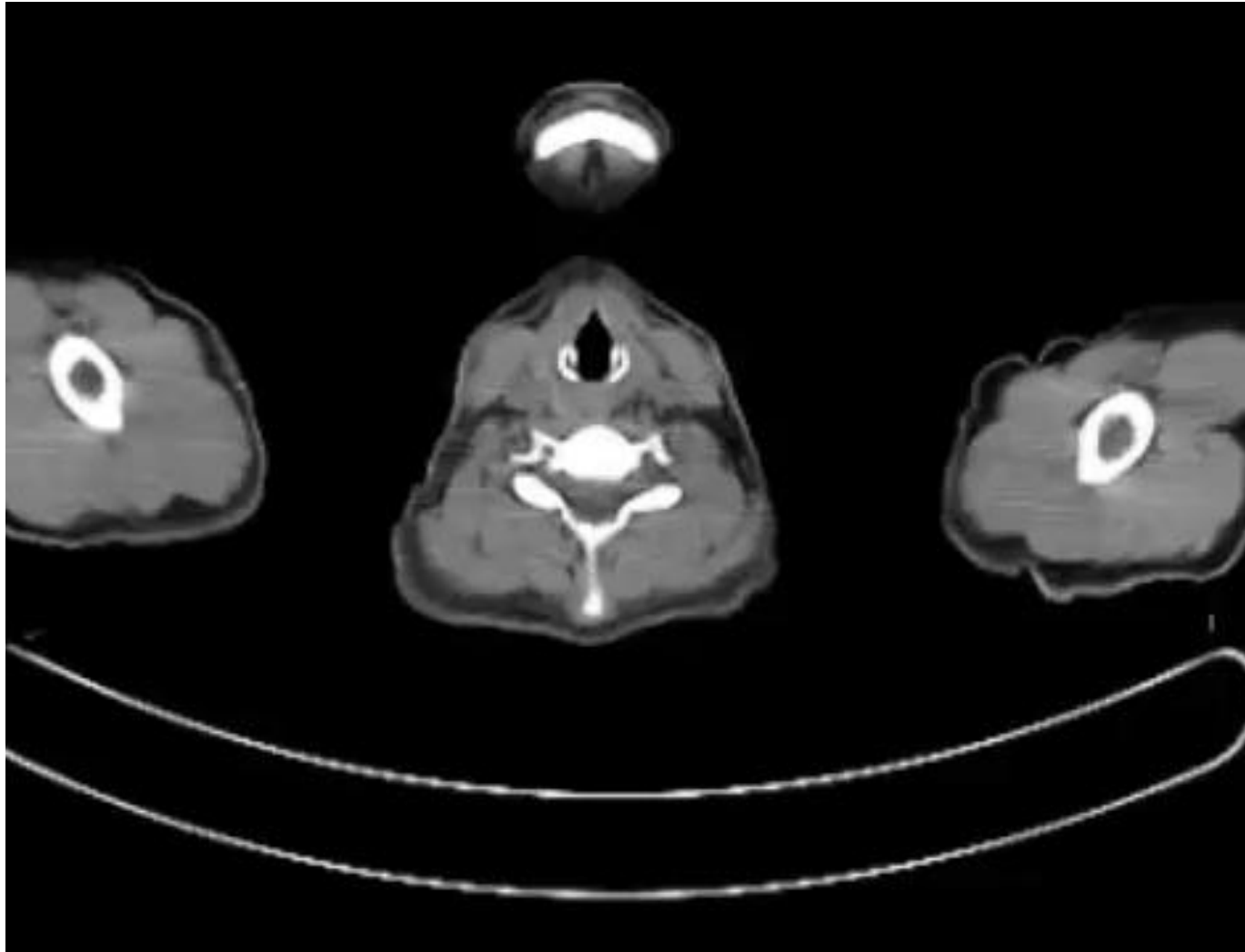


İŞLEM ÖNCESİ



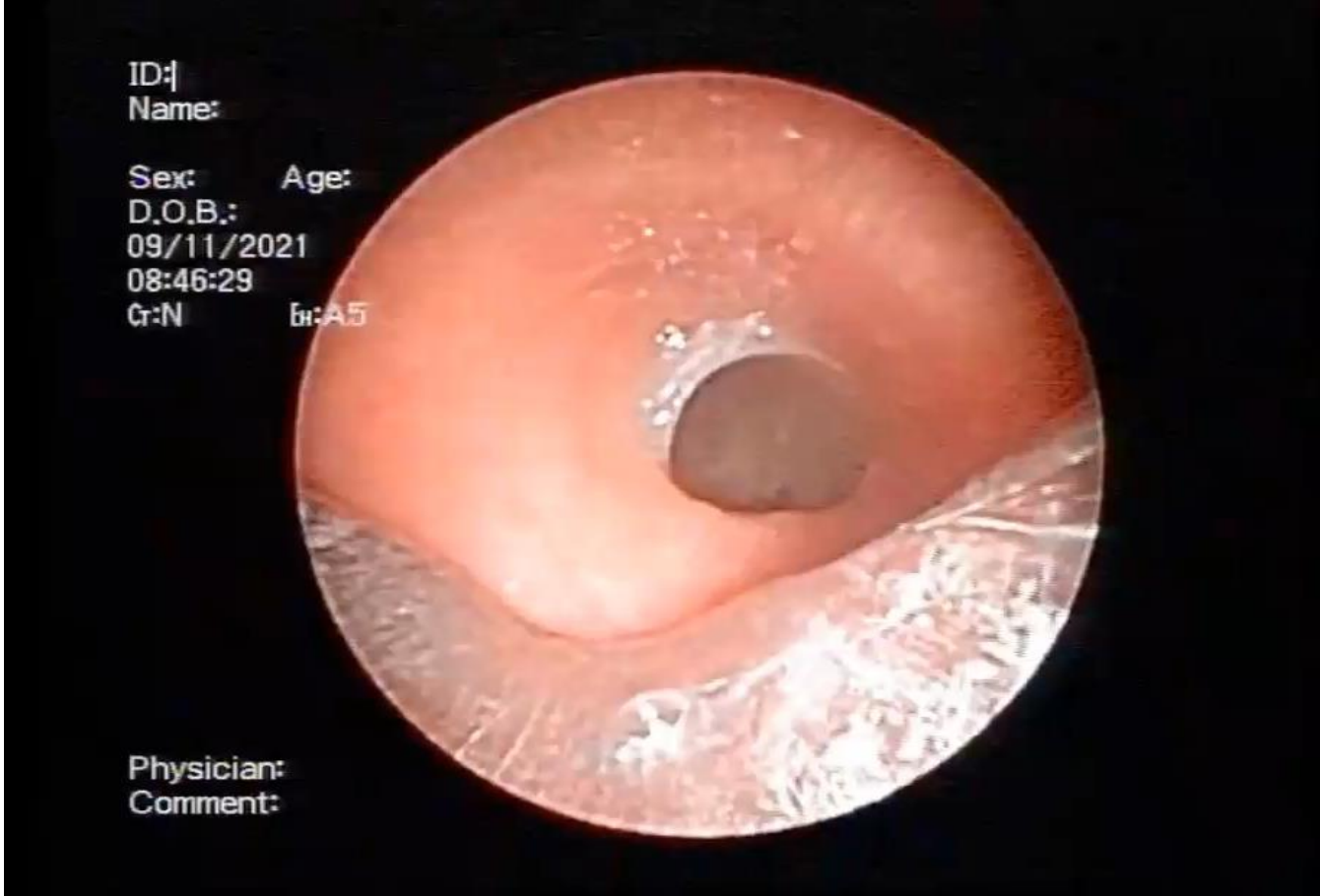
İŞLEM SONRASI

OLGU



KT SONRASI TORAKS BT

OLGU



Onkoloji tarafından RT planlanan hasta tedavisini almak üzere yönlendirildi

STENT ÇIKARMA (İLK İŞLEMDEN 6 AY SONRA)

OLGU

- 48 yaş, erkek hasta
- Şikayet: Ağızdan kan gelmesi, nefes darlığı
- Hikaye: 2015 yılında akciğer ca nedeni ile sağ pnömonektomi ve sonrasında RT almış. 6 aydır giderek artan nefes darlığı olan hastanın 1 aydır ara ara öksürmekle ağızdan kan gelmesi mevcut. EBT açısından değerlendirilmek üzere şehir dışından sevk edilen hasta interne edildi
- Özgeçmiş: Akc ca
- Alışkanlıkları: 20 paket/yıl sigara, 5 yıldır exsmoker

OLGU

- Fizik Muayene: TA: 100/60 mmHg, N: 94/dak,
SO₂: 92 (oda havası)
Genel durumu kötü
Solunum sistemi: Takipneik, sağda solunum sesleri alınamıyor
- Laboratuvar:

Hemogram

Hb: 15.7 g/dL

HCT: 45.3 %

PLT: 349 10^{e3}/uL

WBC: 10.14 10^{e3}/uL

Biyokimya

Glu: 124 mg/dl

Üre: 13 mgr/dl

Kre: 0.72 mg/dl

AST: 15 U/L

ALT: 11 U/L

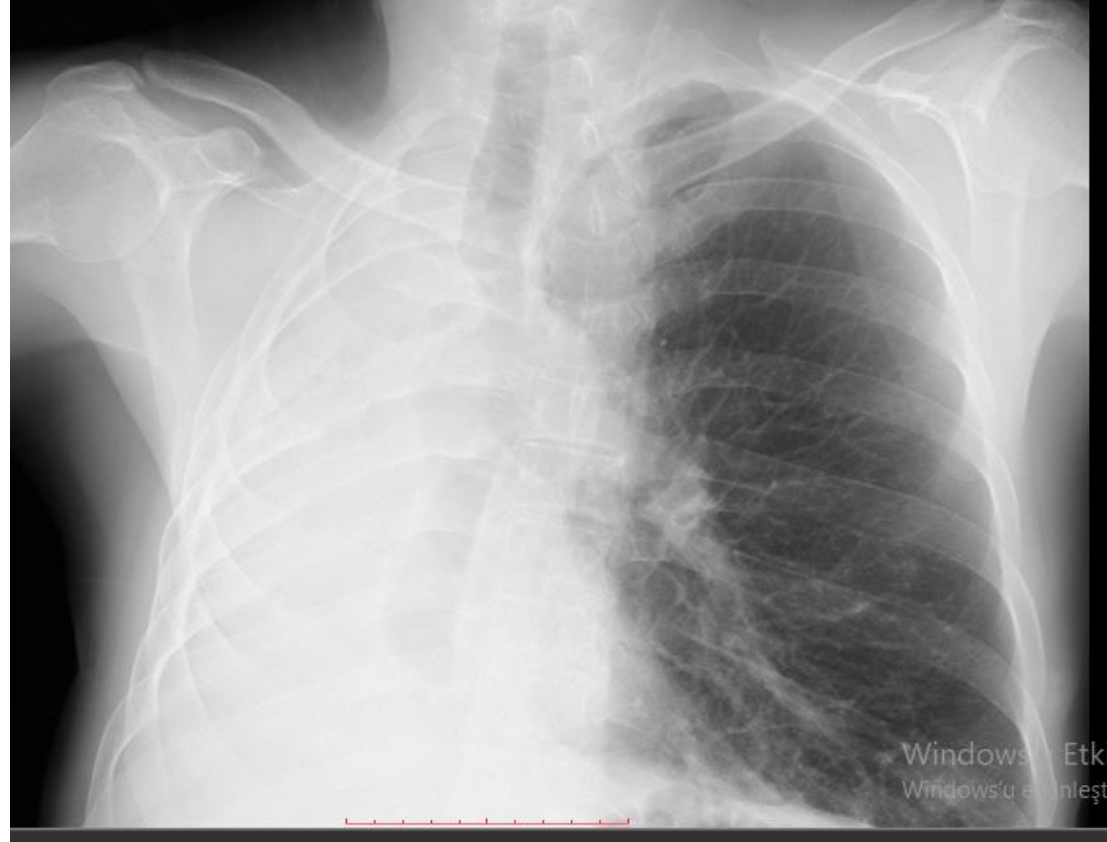Na: 137 mEq/L

K: 3.5 mmol/L

INR: 0.9

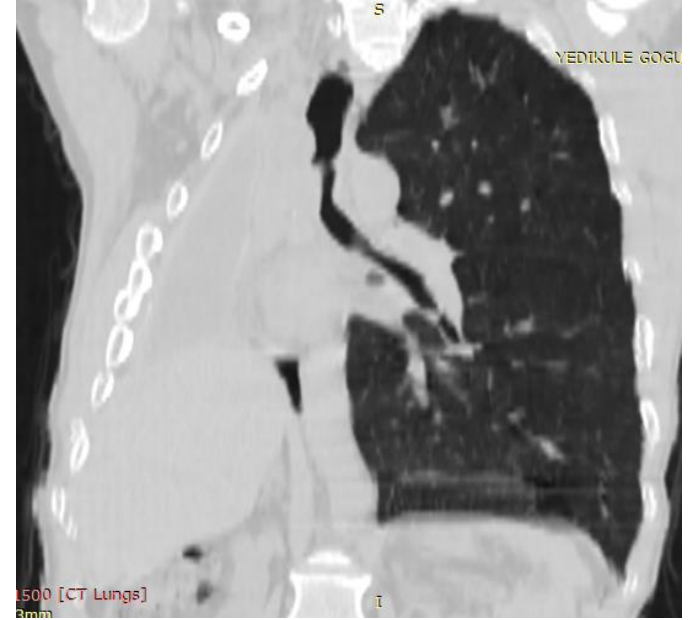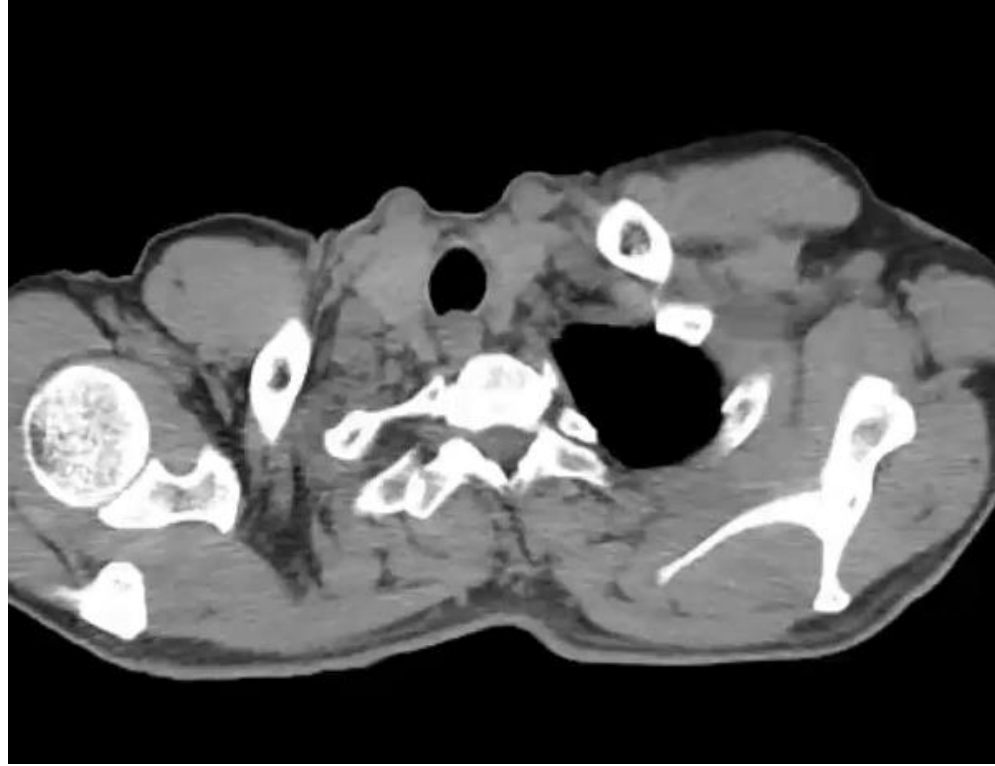
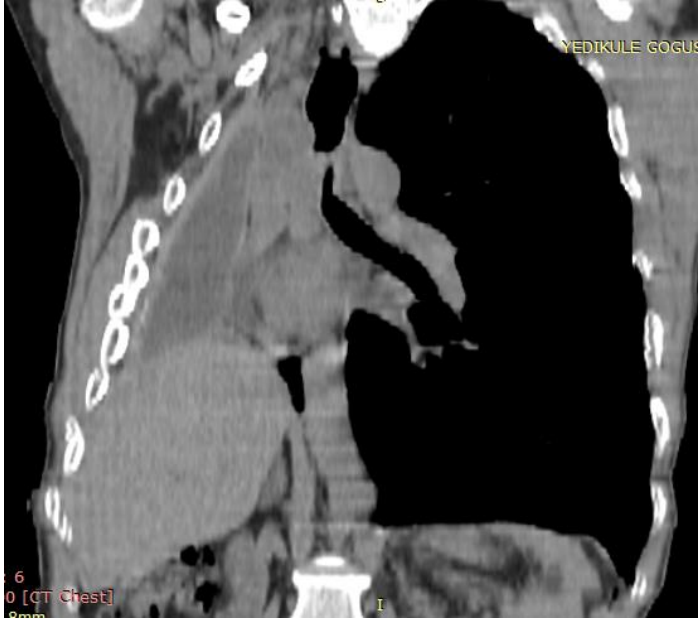CRP: 7.6 mg/L

OLGU



İşlem öncesi PA Akciğer Grafisi

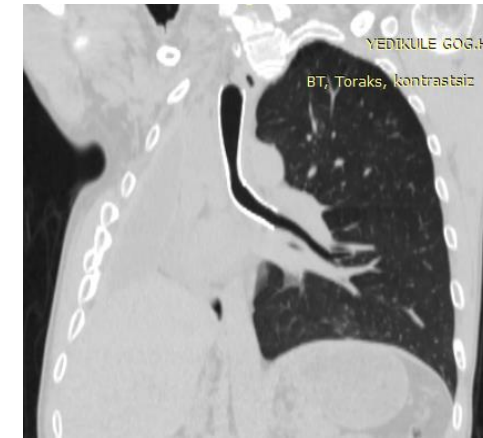
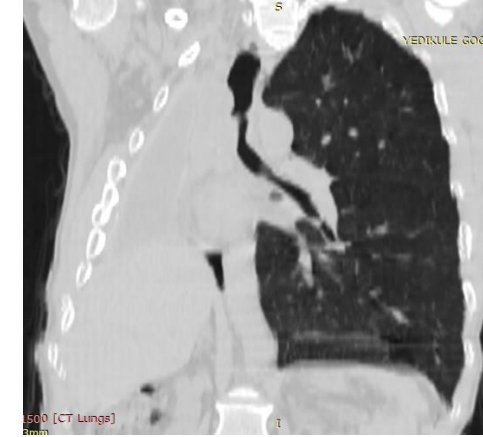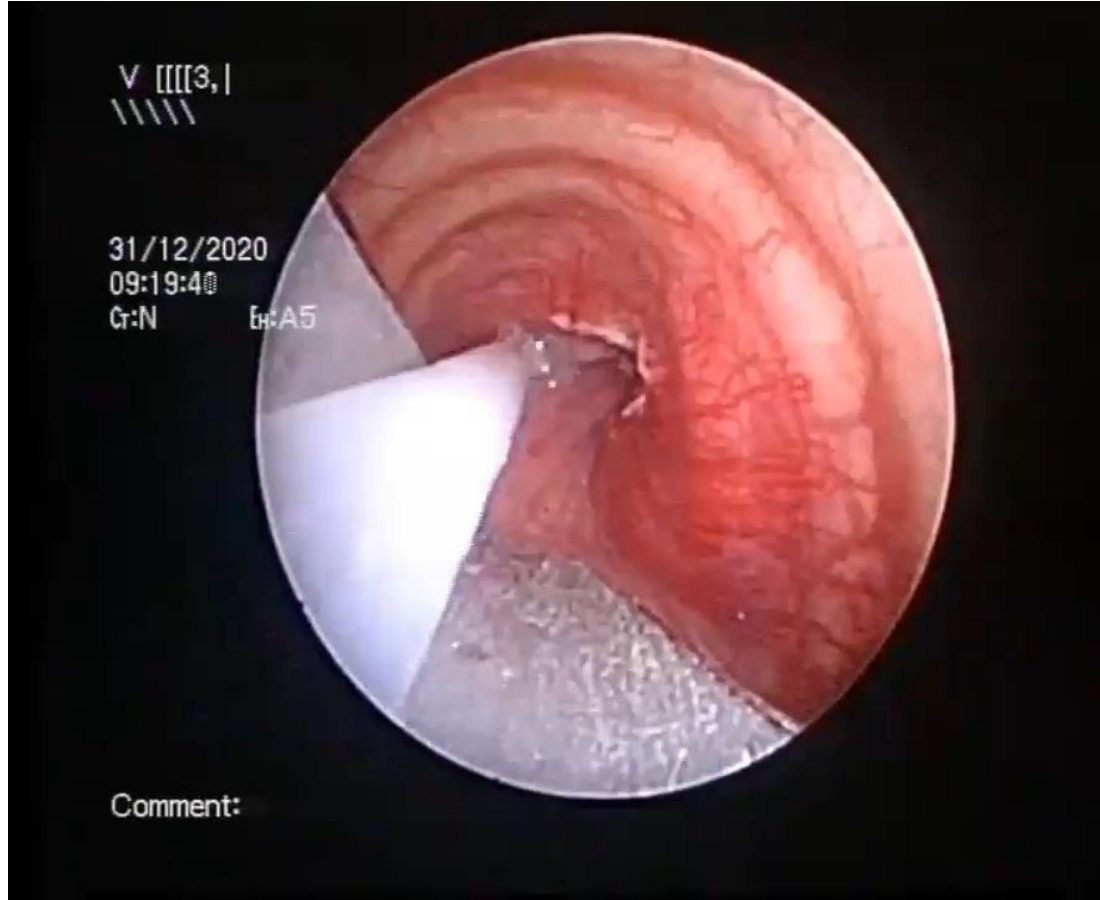
OLGU



TORAKS BT

OLGU

RİJİD BRONKOSKOPİ



OLGU

PATOLOJİ

Histopatolojik Tanılar / Sitopatolojik Tanılar

Trekea; Endobronşial Kitleden Biopsi: Küçük hücreli dışı karsinom

İmmunhistokimya Boyama Panel Sonuçları

PATOLOJİ İMMÜNOHİSTOKİMYA UYGULAMASI

MATERYAL : 8745/2020 Parafin blok
PATOLOJİK TANI : Bkz tanı.
YÖNTEM : OTOMATİZE, Ventana Bench Mark Ultra
İmmünohistokimyasal cihazı
TEKNİK : Multimer teknoloji
Ultra View Universal DAB Detection Kit
5269806-760-500
KONTROL : (+)

PRİMER ANTİKOR

Pansitokeratin Ventana
Anti-P40(BC28) Ventana
TTF-1 (8G7G3/1) Ventana

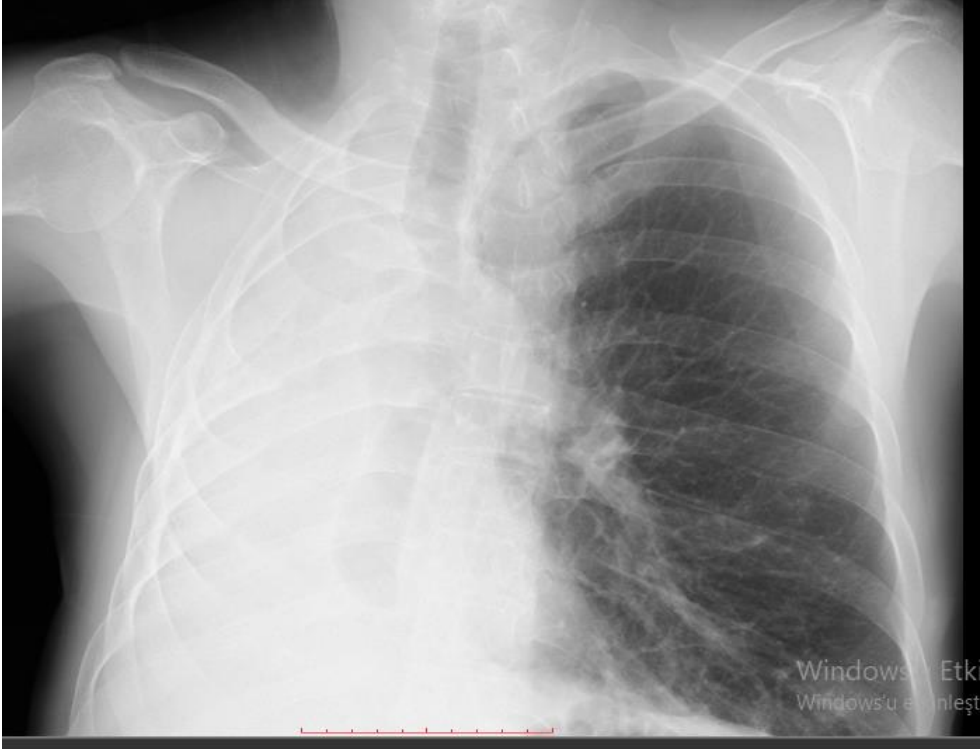İMMÜNREAKTİVİTE

Pozitif
Pozitif
Negatif

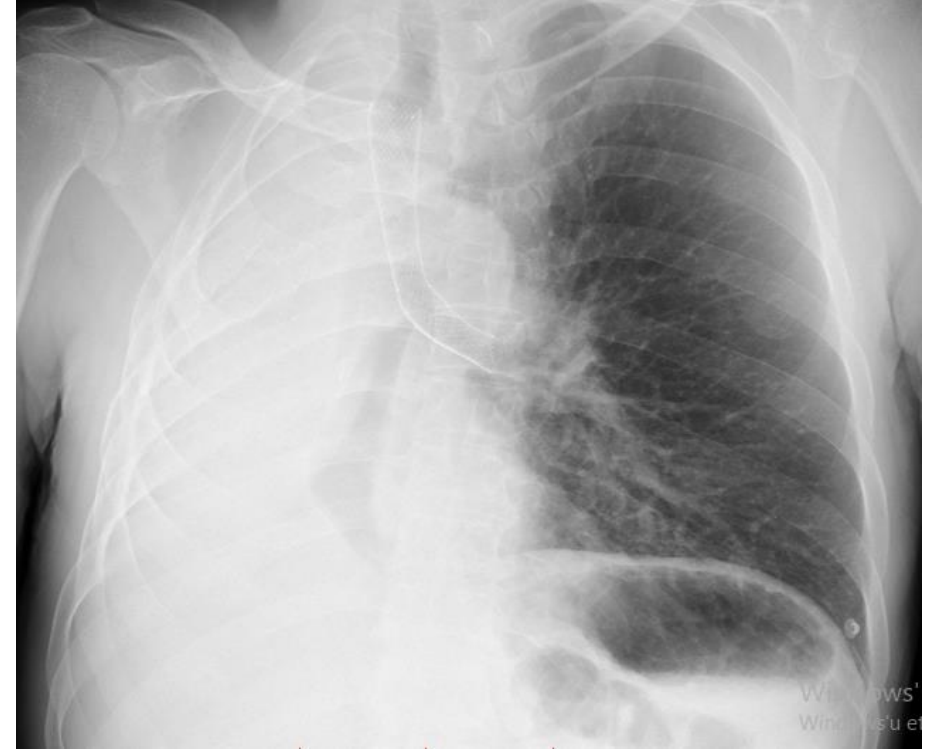Morfoloji Bilgileri

8070/3 Skuamoz hücreli karsinom, NOS,

OLGU

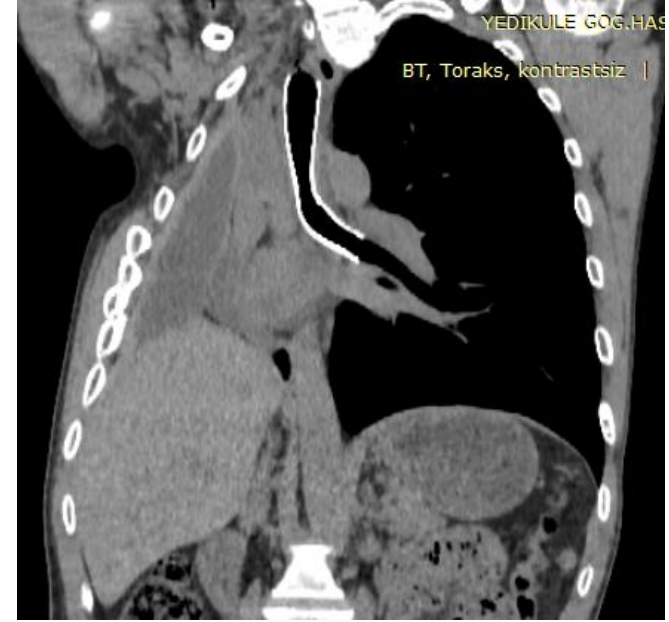
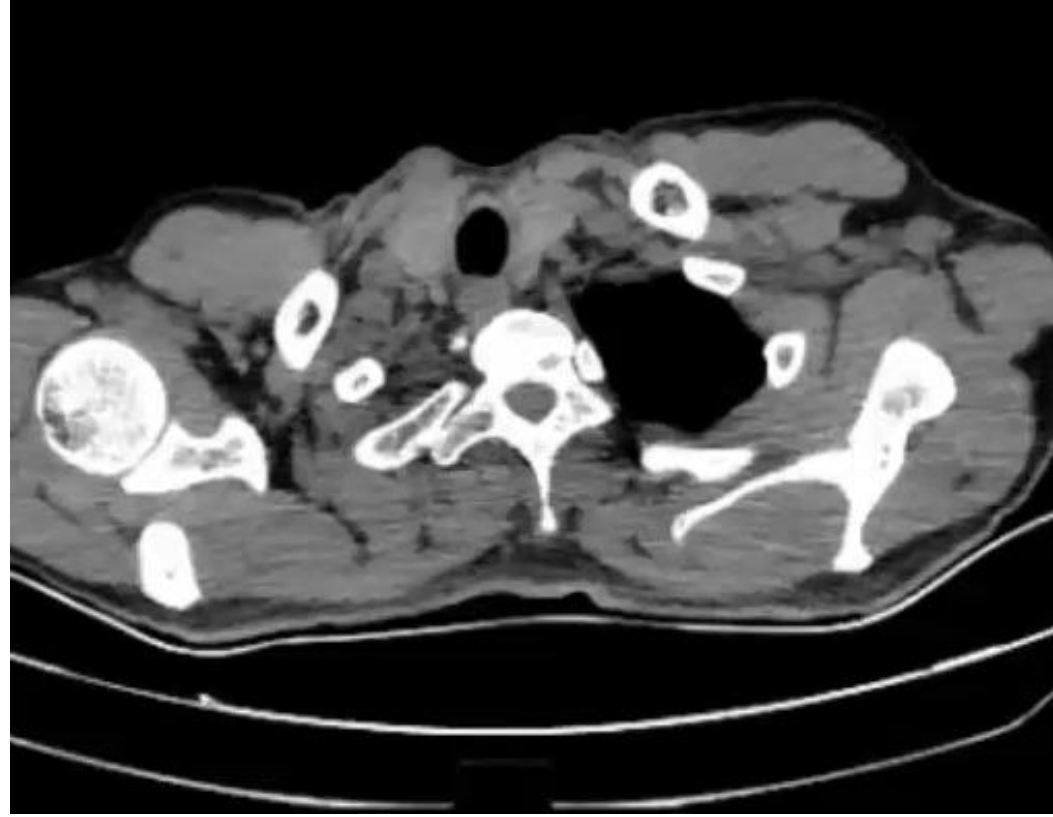
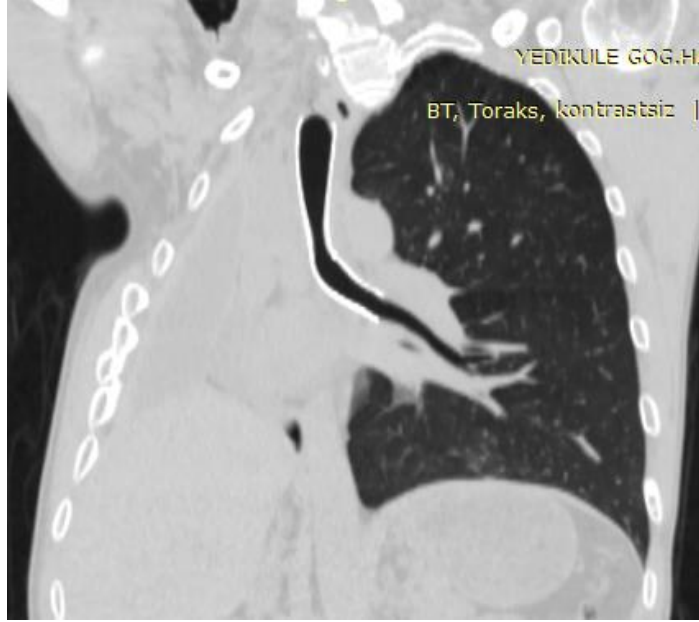

Stentleme öncesi PA Akciğer Grafisi



Stentleme sonrası PA Akciğer Grafisi

OLGU



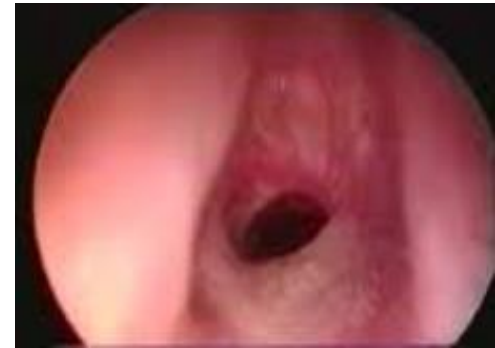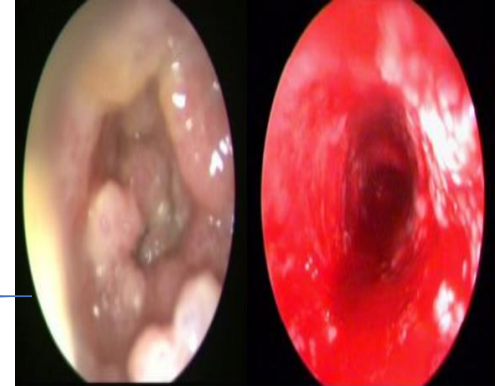
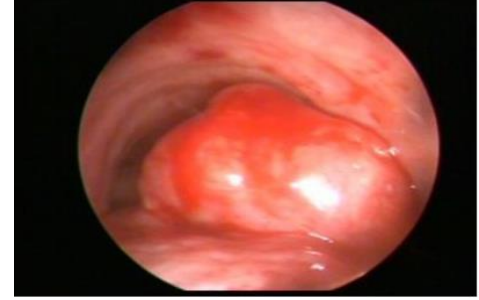
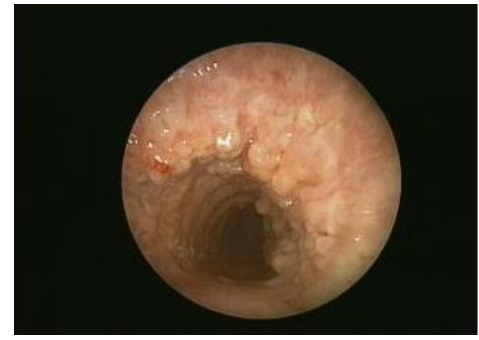Stentleme sonrası Toraks BT

NADİR NEDENLER

- Relapsing polikondrit
- Trakeaosteokondroplastika
- Trakeal amiloidoz
- Trakeal papillom
- Polianjitisli granülom (Wegener)

PM
(-)

PM
(+)

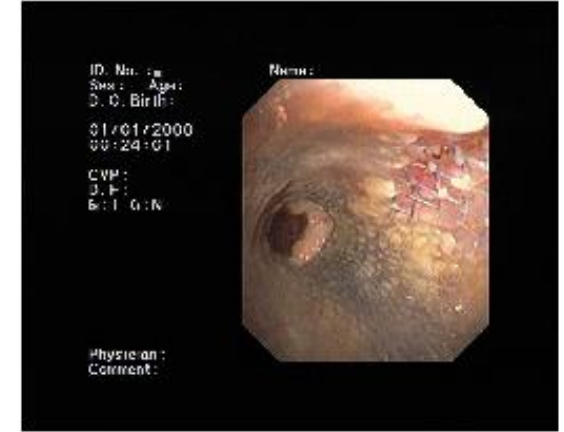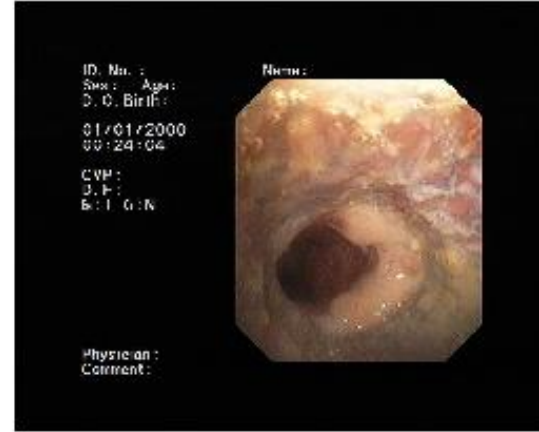
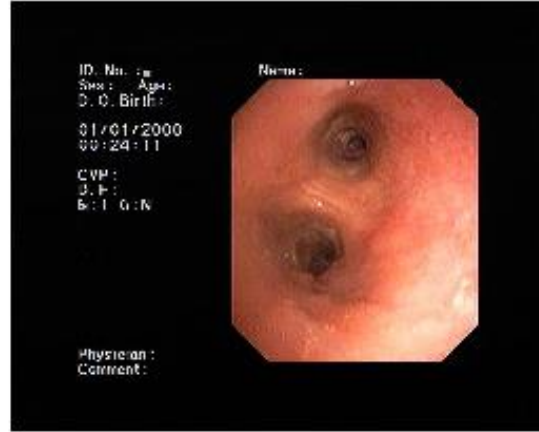
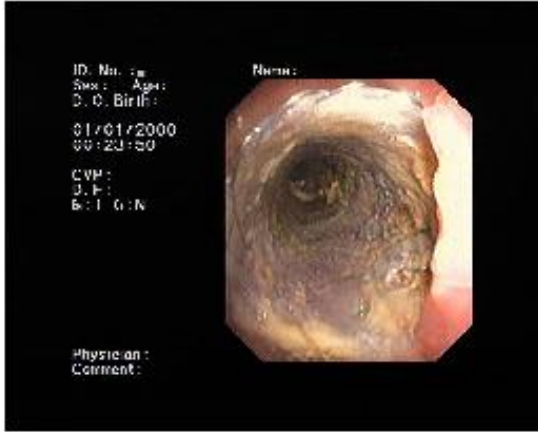

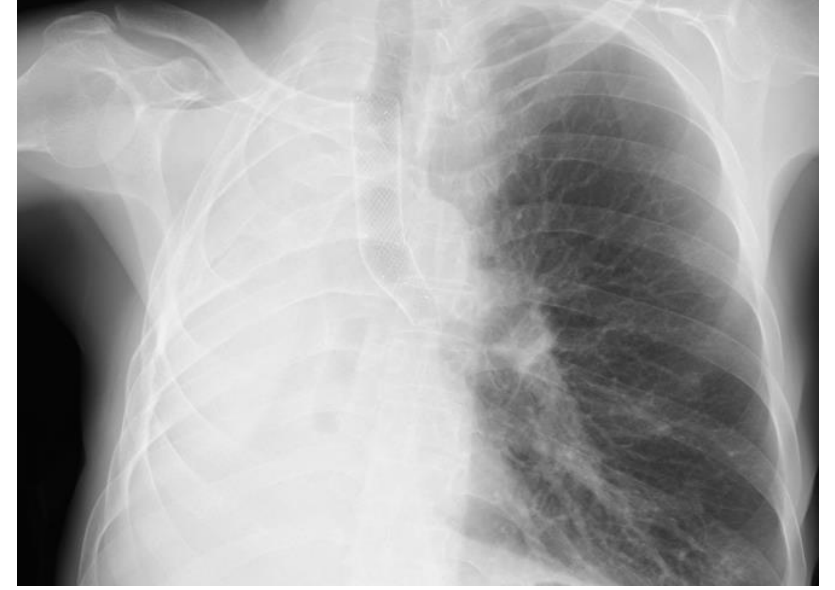
OLGU

- Hastanın genel durumu hızla düzeldi.
- Solunum sıkıntısı düzeldi
- Beslenmeye başladı, öz bakımı arttı

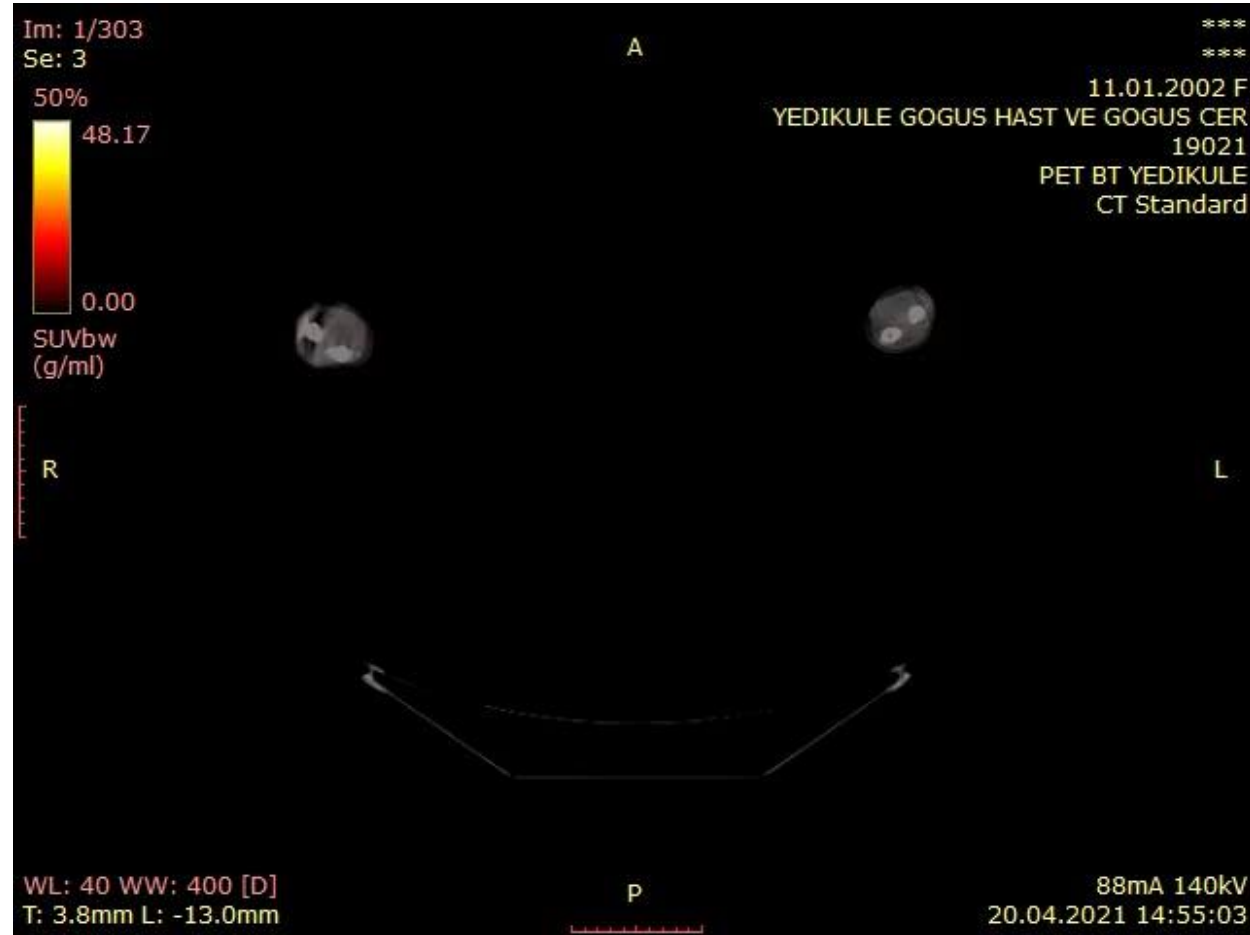ANCAK

- 4 ay sonra beslenememe ve hızlı kilo kaybı nedeni ile tekrar başvurdu. Solunumsal sıkıntısı yoktu



4 ay sonrası PA Akc grafi ve bronkoskopi görüntüleri

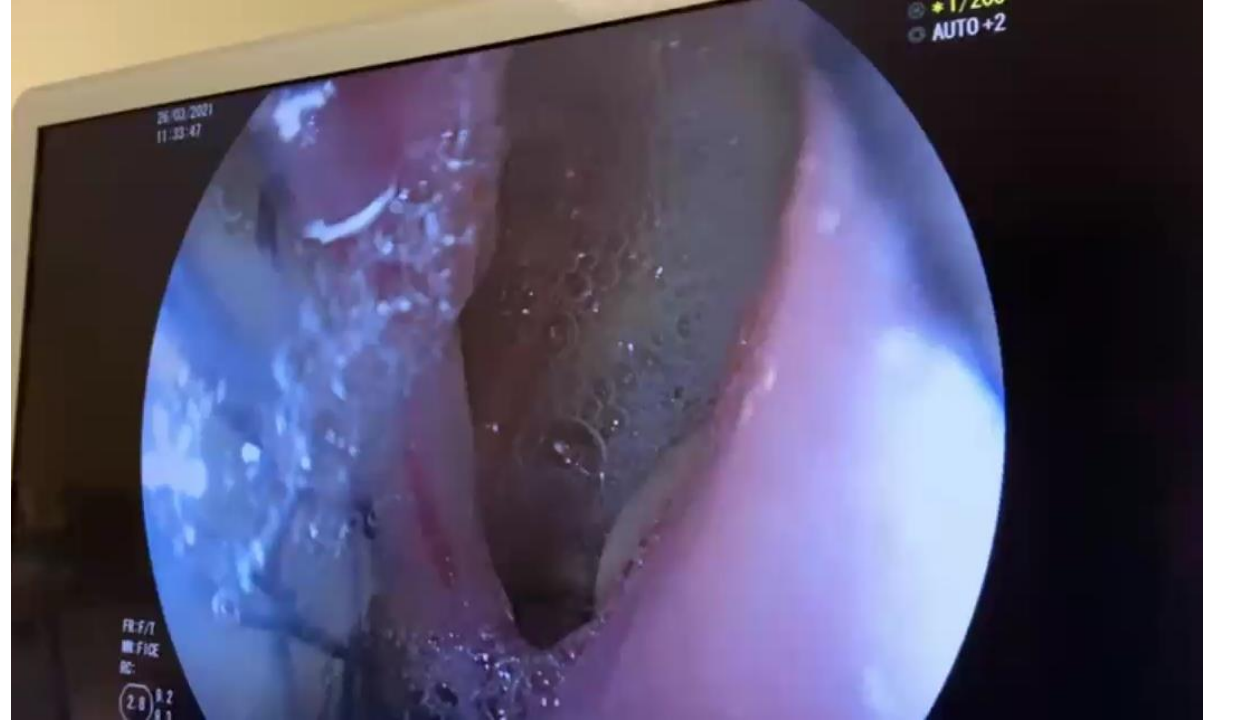OLGU 2



TÜM VÜCUT PET-BT

OLGU

- Endoskopi: Trakeadaki stentin ösefagusa girerek lümeni tam obstrükte ettiği görüldü. Darlığın distaline geçilemedi.
- Hastaya PEG açılmak üzere multidisipliner hastaneye sevk edildi



KLİNİK BULGULAR ve ANAMNEZ

Şikayetler

Öksürük
Nefes darlığı
Hemoptizi
Wheesing
Stridor



Darlığın yeri
Darlığın oranı
Darlığın uzunluğu
Hastanın kardiyopulmoner rezervi

Şikayetlerin Başlangıcı

Akut
Yavaş İlerleyici

Trakea çapı

Ön-Arka: 18 mm Lateral Çap: 23 mm

< 8 mm

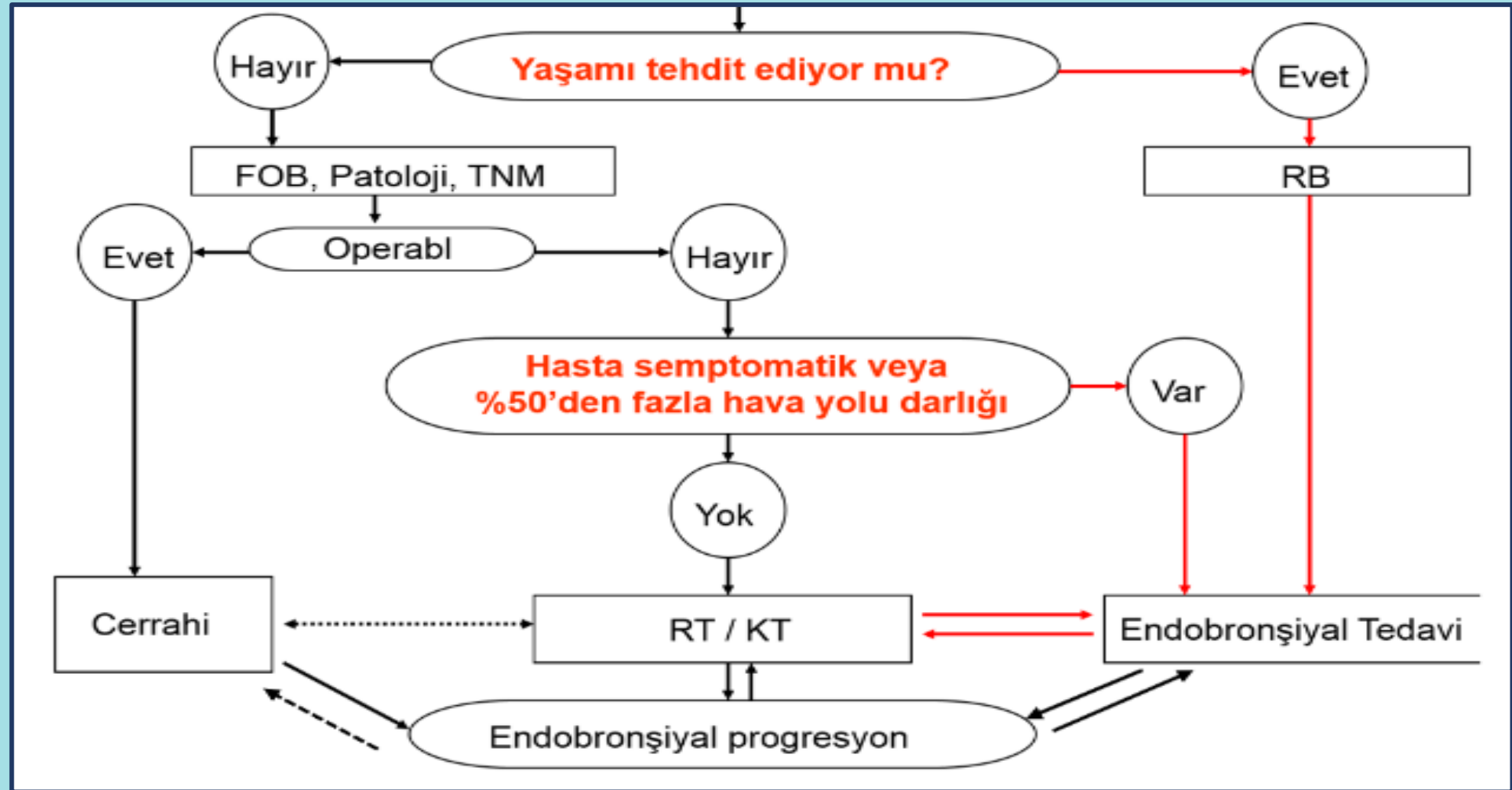


Egzersiz dispnesi

<5 mm




İstirahat dispnesi



TEDAVİ- Hava yolu açıklığını sağlamak

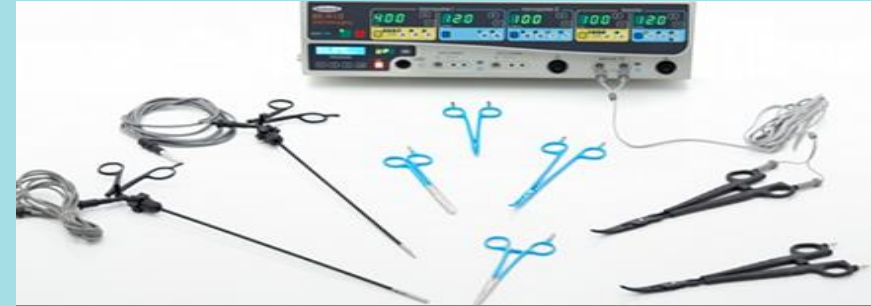
Mekanik Dilatasyon:

Rijid tüpün kendisi
Balon
Buji
Kesi
Drill



Sıcak Yöntemler:

Argon Plasma Koagülasyon
LASER
Elektrokoter



Soğuk Yöntemler:

Kriyo



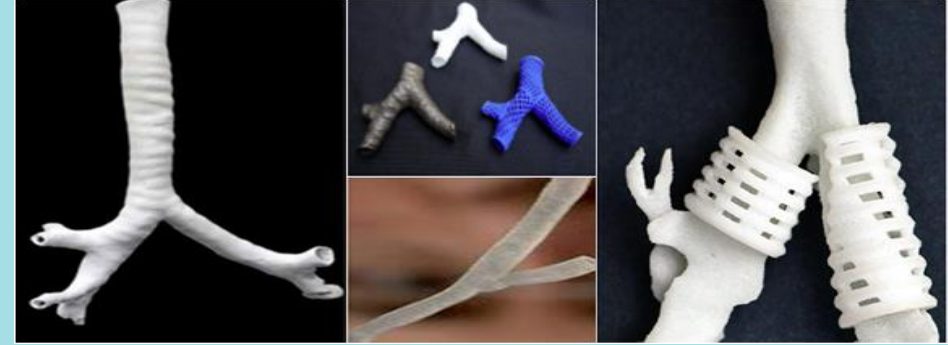TEDAVİ- Hava yolu açıklığını devam ettirme

Stentler:

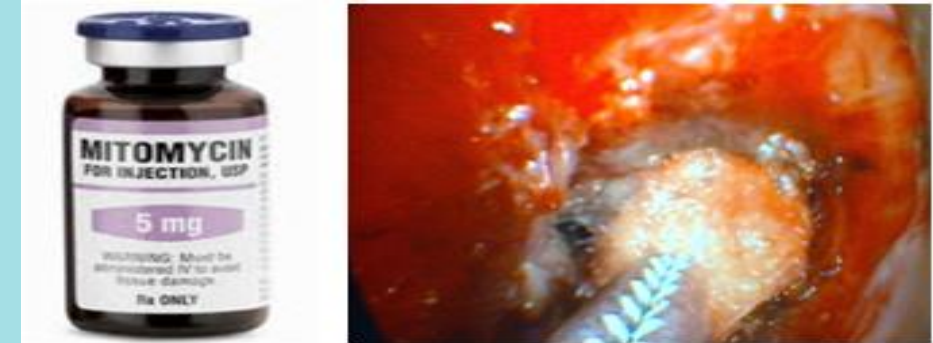
Şekil

Uzunluk

Materyal



Mitomisin- C:



Steroidler:

SANTRAL HAVA YOLU OBSTRÜKSİYONLARI

MALİGN HAVA YOLU OBSTRÜKSİYONLARI

Post-travmatik hava yolu obstrüksiyonları

Dinamik ekspiratuar darlık

Dış bası

Cerrahi sonrası

Enfeksiyonlar

İnflamatuvar havayolu hastalıkları

Benign endobronşiyal tümörler

BENİGN HAVA YOLU OBSTRÜKSİYONLARI

▪ Benign endobronşiyal tümörler

- Respiratuar papillomatozis
- Hamartom
- Leiomyom
- Lipom
- Fibrom
- Nörojenik tümör
- Pleomorfik adenom
- Onkositom
- Trakeobronkopatia osteokondroplastika

SANTRAL HAVA YOLU OBSTRÜKSİYONLARI

BENİGN HAVA YOLU OBSTRÜKSİYONLARI

MALİGN HAVA YOLU OBSTRÜKSİYONLARI

Primer Akciğer Tümörleri



Bronkojenik karsinom
Karsinoid tümör
Karsinosarkom
Pulmoner sarkom
Adenoid kistik karsinom
Mukooepidermoid karsinom

Mediastinal Tümörler



Timik karsinom
Tirois kanseri
Germ hücreli tümörler (Teratoma, vs...)

Metastatik Tümörler



Bronkojenik karsinom
Renal hücreli karsinom
Meme kanseri
Tiroid kanseri
Kolorektal karsinom
Sarkom
Melanom
Over kanseri
Uterus kanseri
Testis kanseri
Nazofarinks kanseri
Adrenal karsinom
Kronik Lenfositik Lösemi

Diğer maligniteler



Larinks kanseri
Özofagus kanseri
Lenfoma (Hodgkin ve non-Hodgkin)
Diğer tümörlere bağlı lenfadenopatiler

Girişimsel Pulmonolojide Endobronşiyal Tedavi Endikasyonları

- Tümör tedavisi
- Bening hava yolu stenozları
- Malign hava yolu stenozları
- Hemoptizi
- Bronkoskopik hacim azaltıcı tedaviler
- Yabancı cisimler

Endobronşiyal tedavi yöntemleri

➤ Sıcak yöntemler

Elektrokoter,
Argon plazma koagulasyon(APC),
Lazer

➤ Soğuk yöntemler

Kriyoterapi

➤ Rijid bronkoskopi mekanik temizleme

➤ Dilatasyon

➤ Endobronşiyal stent uygulanması

➤ Brakiterapi

➤ Fotodinamik tedavi

Endobronşiyal tedavi yöntemleri

Hızlı etki

Yavaş etki

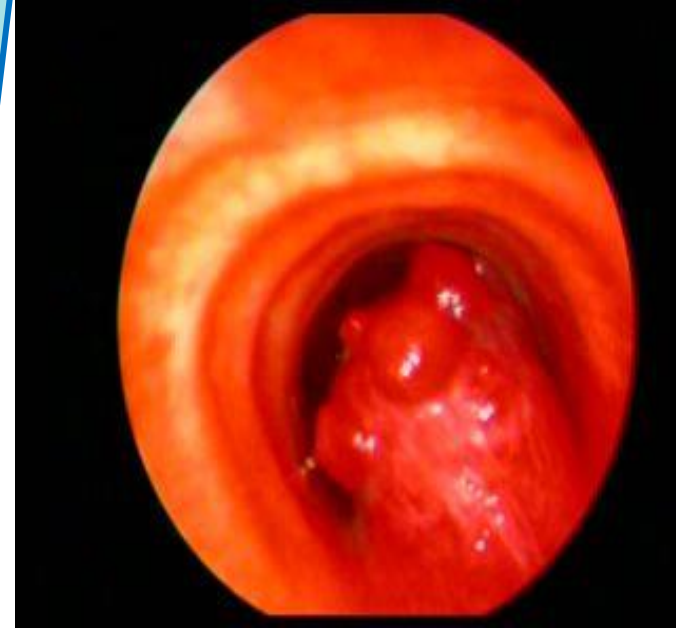Mekanik debulking

Laser, APC

Stent

PDT

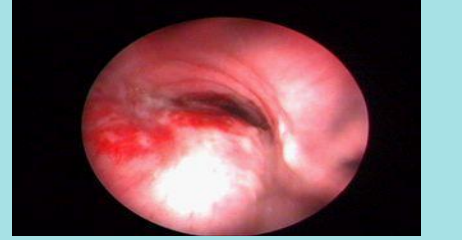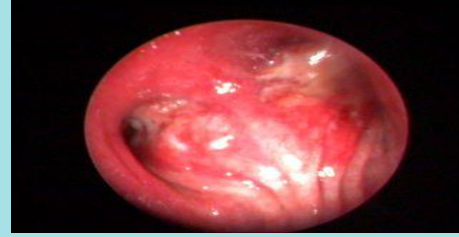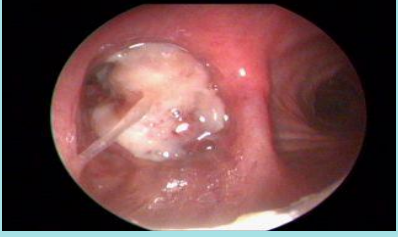Kriyoterapi



**MALİNG HAVA YOLU
OBSTRÜKSİYONU**

**ACİL
RİJİD**

**ACİL DEĞİL
FOB YA DA RİJİD**

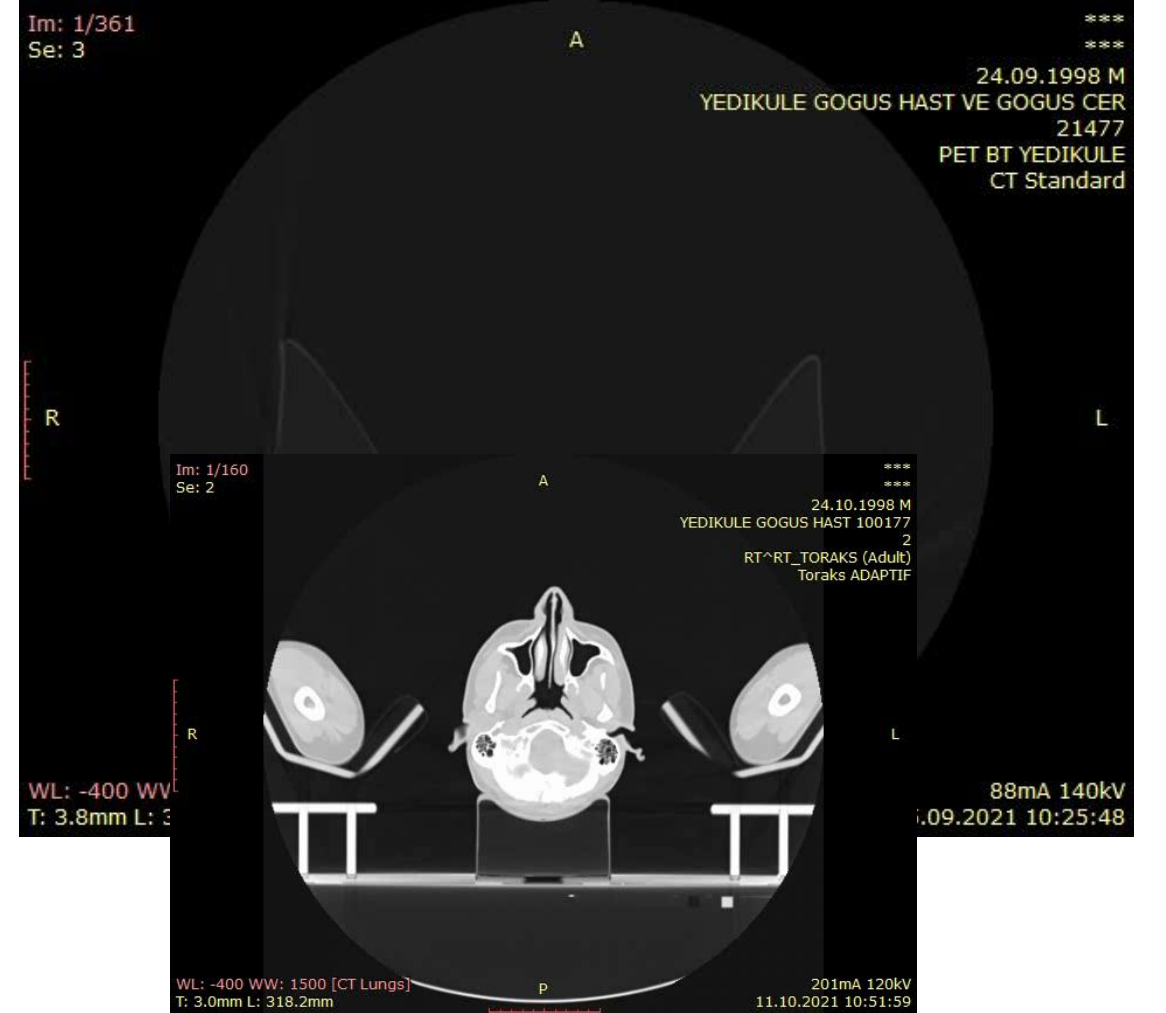


ABLATİF TEKNİKLER VE MEKANİK REZEKSİYON

STENT

OLGU 1

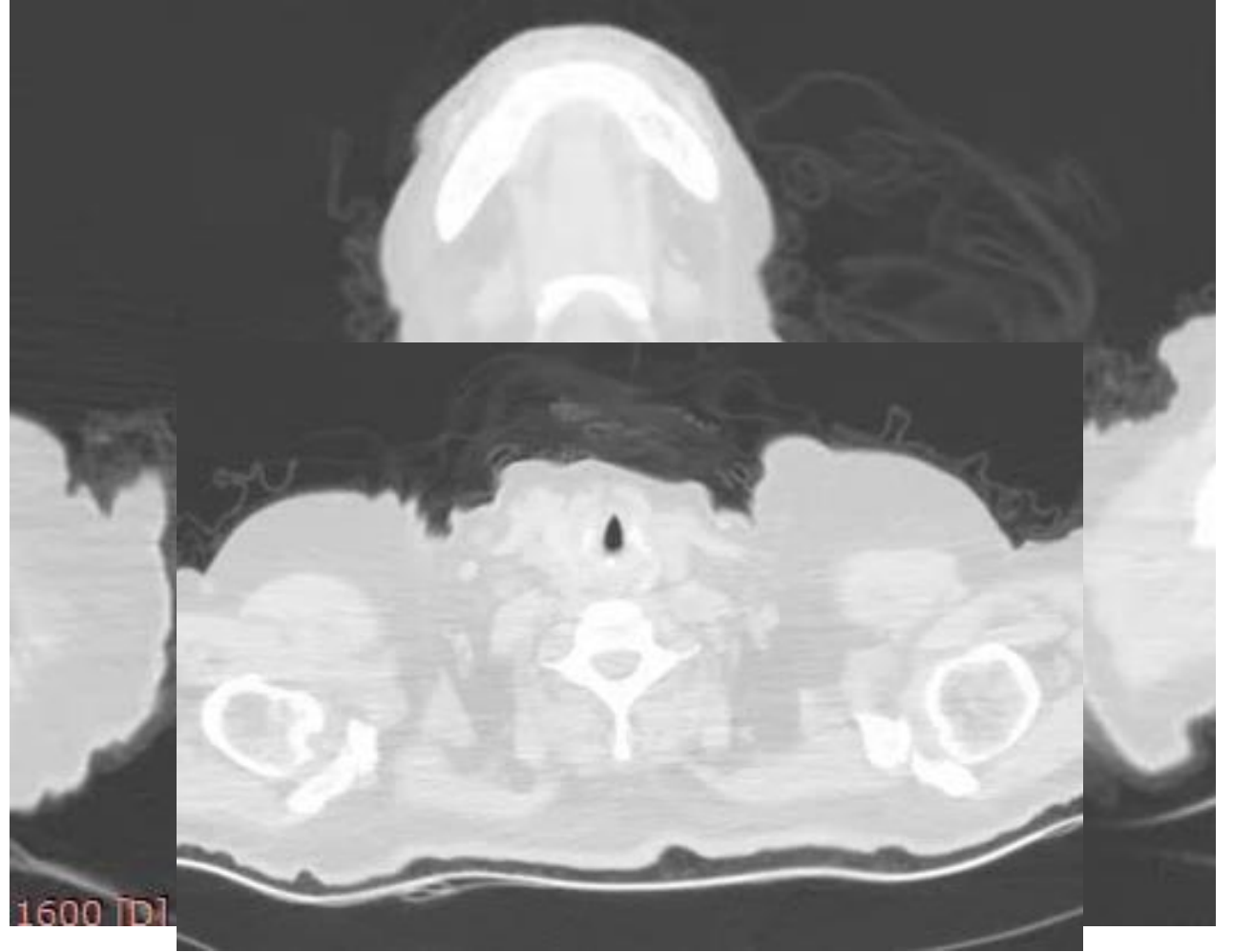
- Özgeçmiş: Ewing sarkomu (2018)
- Alışkanlık: 4p/yıl sigara, aktif içici
- Fizik muayene:
TA: 110/80 NDS: 130/dak
Sat: %94(oda) SDS: 30/dak
Solunum sistemi: Yaygın stridor(+)
- Laboratuar:
WBC: $14.39 \times 10^3/\mu\text{L}$ PLT: $579 \times 10^3/\mu\text{L}$
CRP: 132 mg/dL AST: 46 U/L ALT: 62 U/L
Potasyum: 5.3 mmol/L



TORAKS BT

OLGU 2

- Hasta anestezi ve kardioloji konsültasyonları sonrası GBI'e alındı
- İşlem sırasında göğüs cerrahisi ile de konsülte edildi



TORAKS BT

OLGU 3

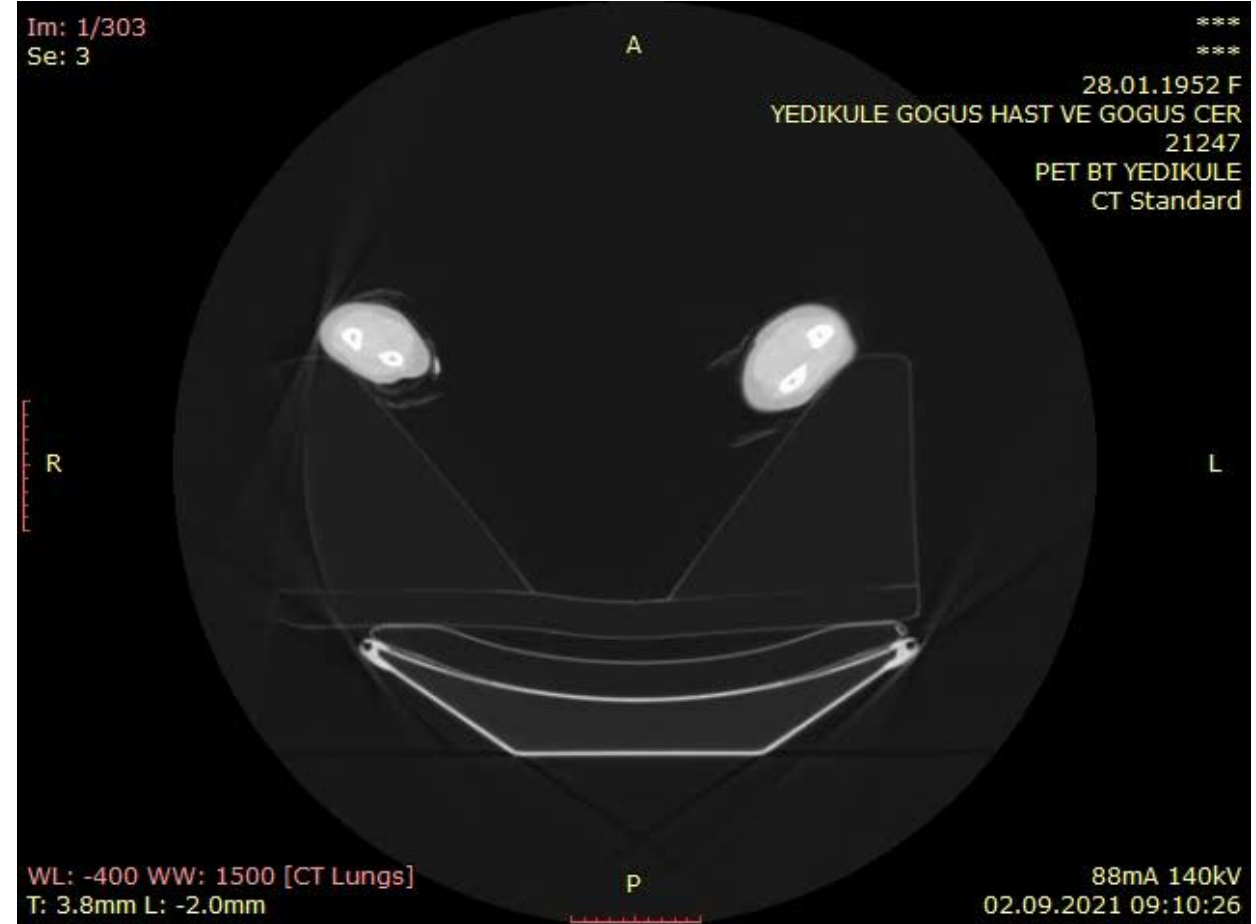
- Yoğun bakımda hastanın ventile edilememesi nedeni ile girişimsel bronkolojiden konsültasyon
- Toraks BT'si değerlendirilen hasta dış YB'dan entübe olarak işleme alındı

OLGU 3

- Rijid bronkoskopi: Vokal kordlardan 2 cm sonra lümeni % 75 oblitere eden 1.5 cm devam eden kompleks stenoz izlendi
- Stenotik alan dilate edildi
- 3 ay sonra Ekim 2021 de tekrar nefes darlığı ile başvurdu ve yine trakeada stent proksimalinde stenotik alan izlendi.

OLGU 4

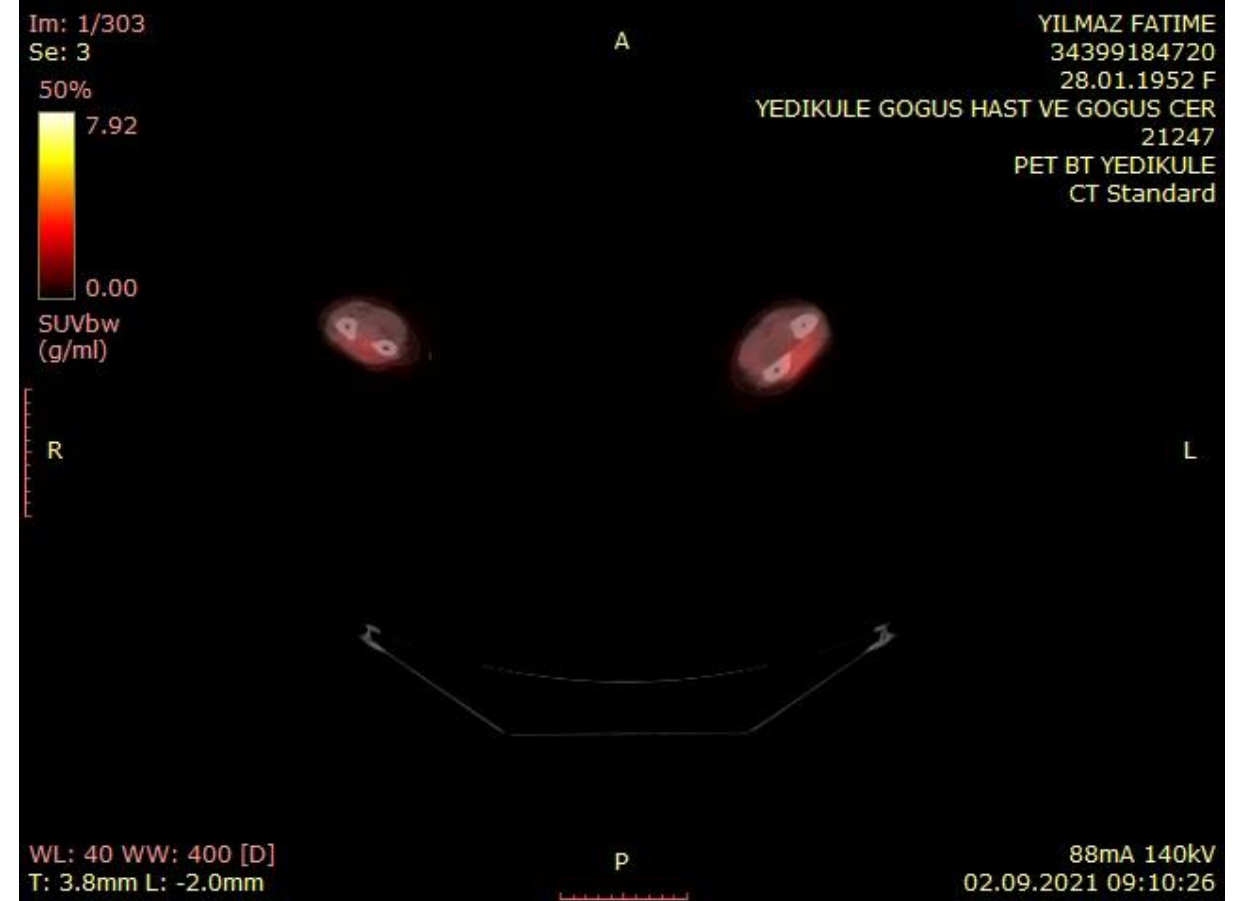
- Alışkanlık: Bir özellik yok
- Fizik Muayene:
TA: 140/95 Sat: %98(oda) SDS: 16/dak
Solunum sistemi: Stridor(+)
- Başvuru Laboratuar:
Kayda değer patolojik değer yok



TORAKS BT

OLGU 4

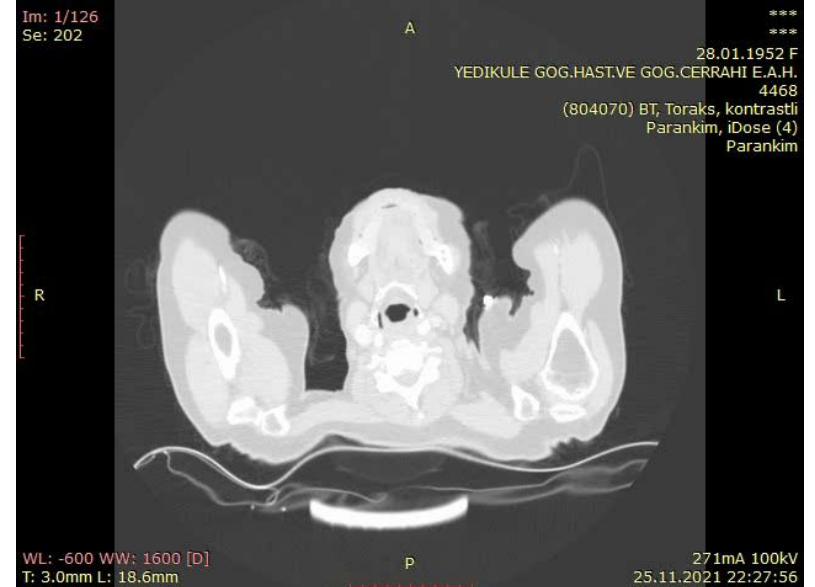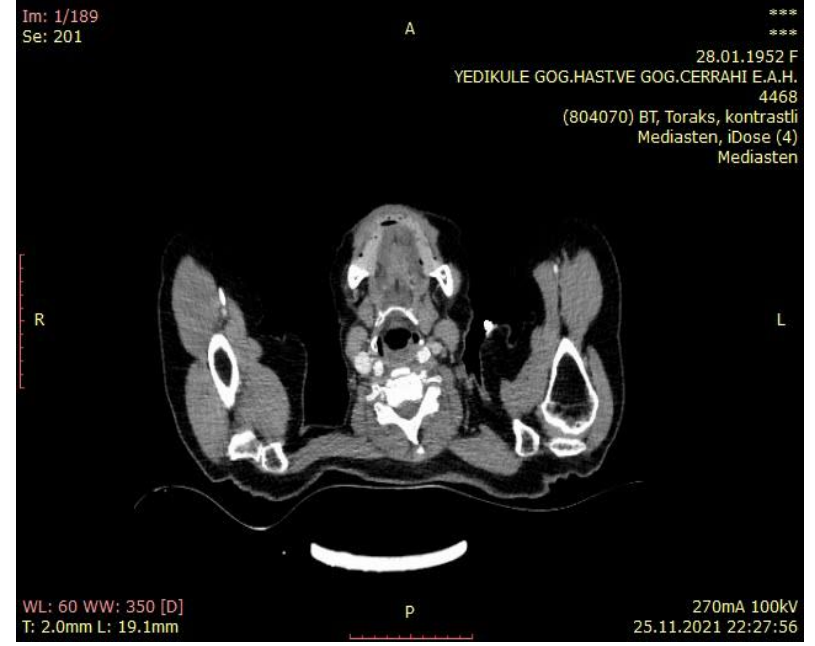
- Hastaya ayaktan yapılan FOB'de trakeadan başlayarak her iki bronşiyal sistemde çok sayıda sert nodüler lezyonlar izlenmiş ve lezyonların sert yapısı nedeni ile örneklenememiş
- İşlem esnasında girişimsel pulmonoloji ekibimizden konsültasyon istenmiş ve rijid bronkoskopi planlanmış



TÜM VÜCUT PET BT

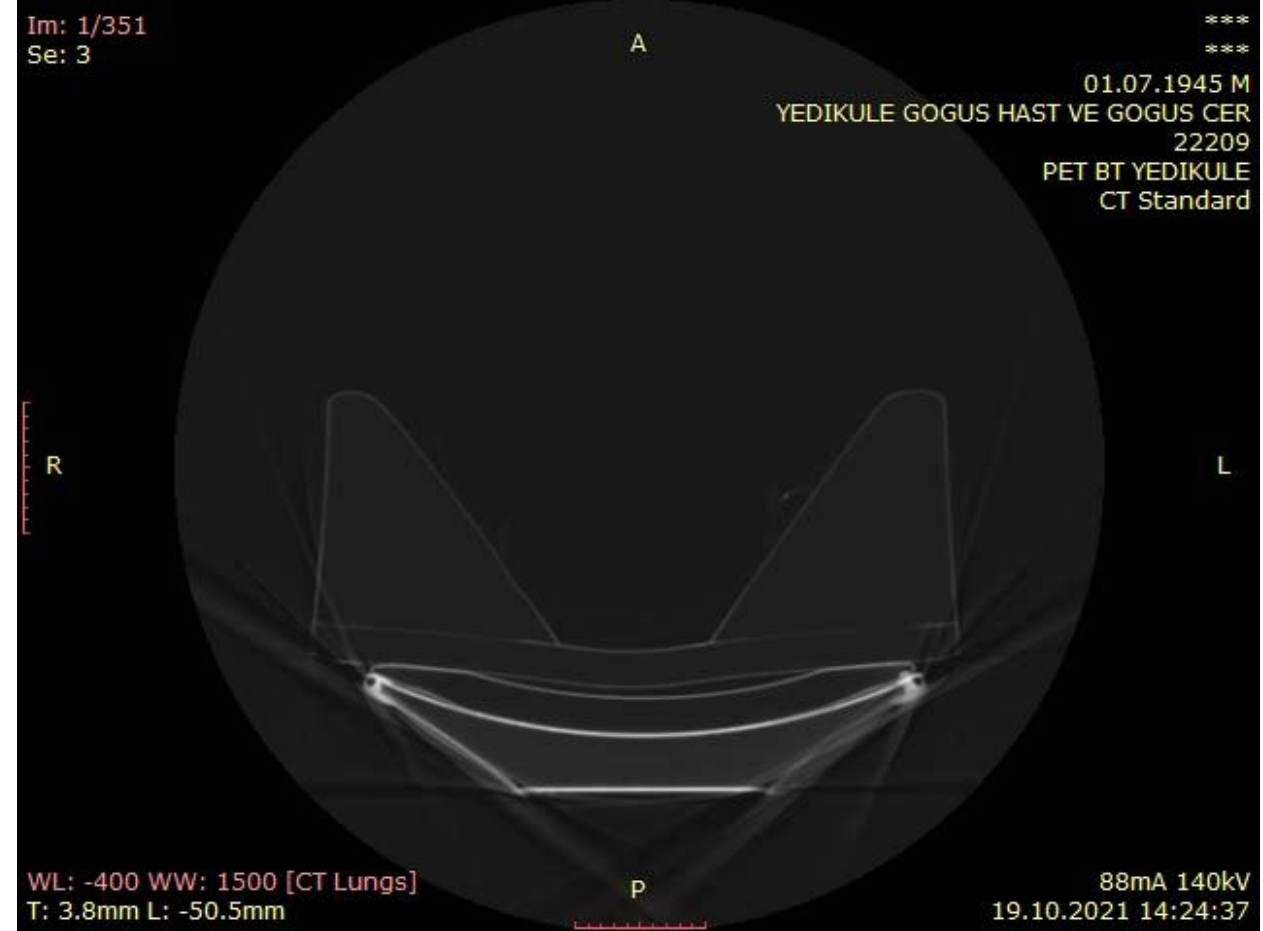OLGU 4

- Hastanın kontrollerde sağıdaki PET(+) alanının da rezolüsyona uğradığı görüldü



OLGU 5

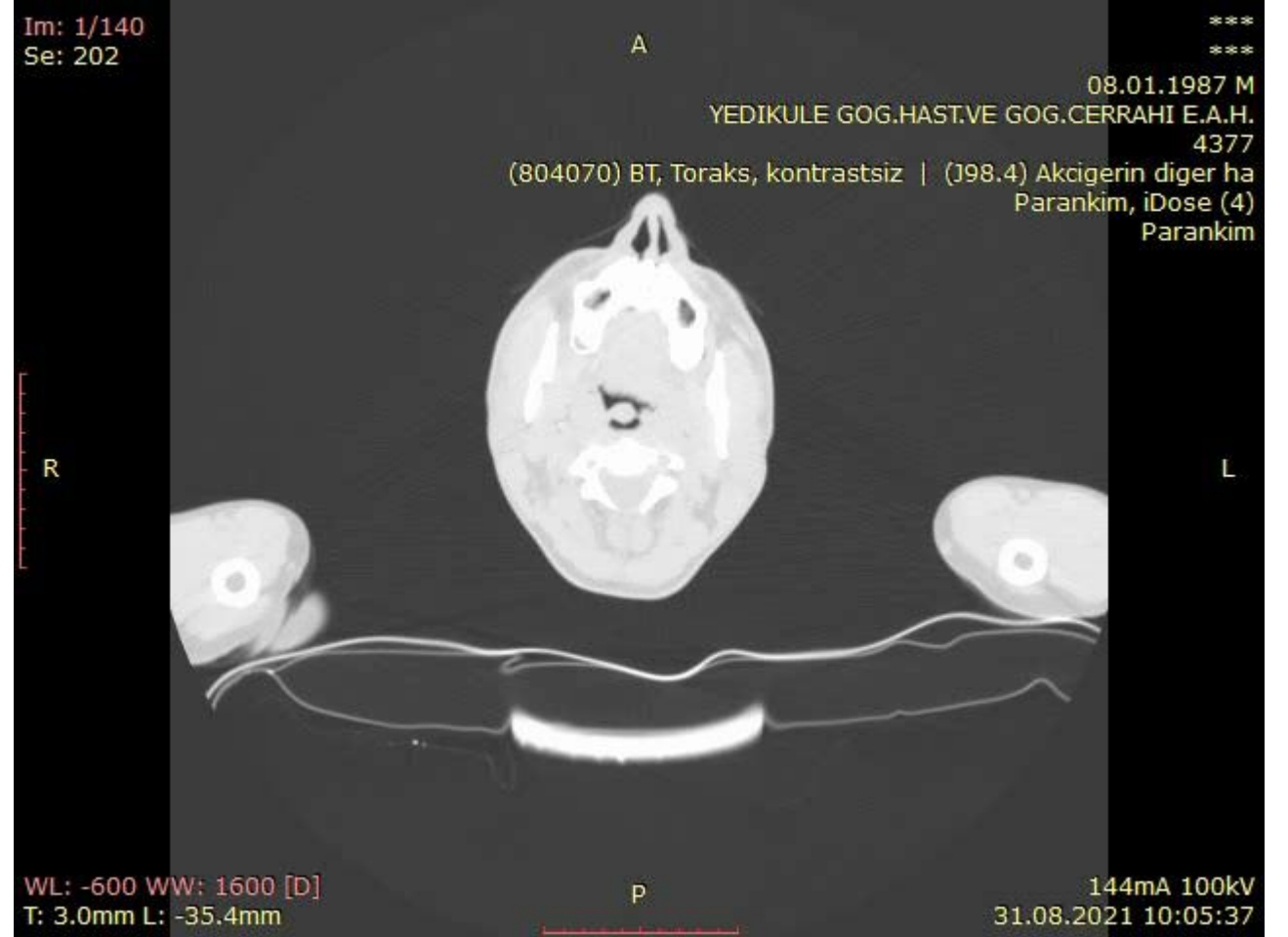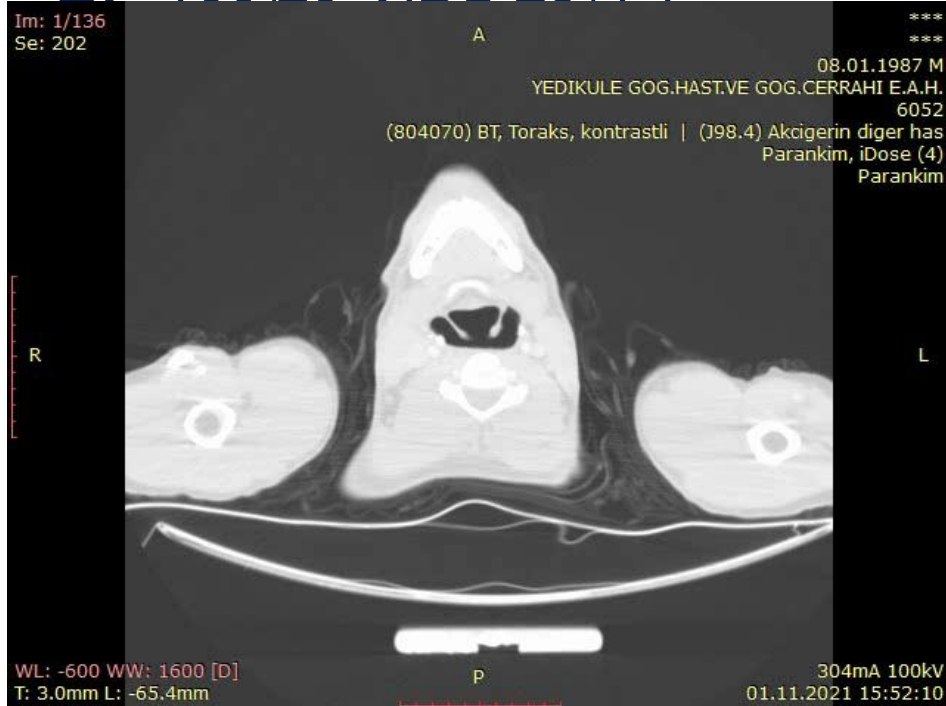- Hasta poliklinikte deęerlendirildikten sonra ayaktan yapılan fleksibl bronkoskopide sol ana bronş distalini tam olarak oblitere eden üzeri nekroze endobronşiyal lezyon görölmüş, işlem esnasında girişimsel pulmonoloji ekimizle konsülte edilerek rijid bronkoskopi planlanlanmış



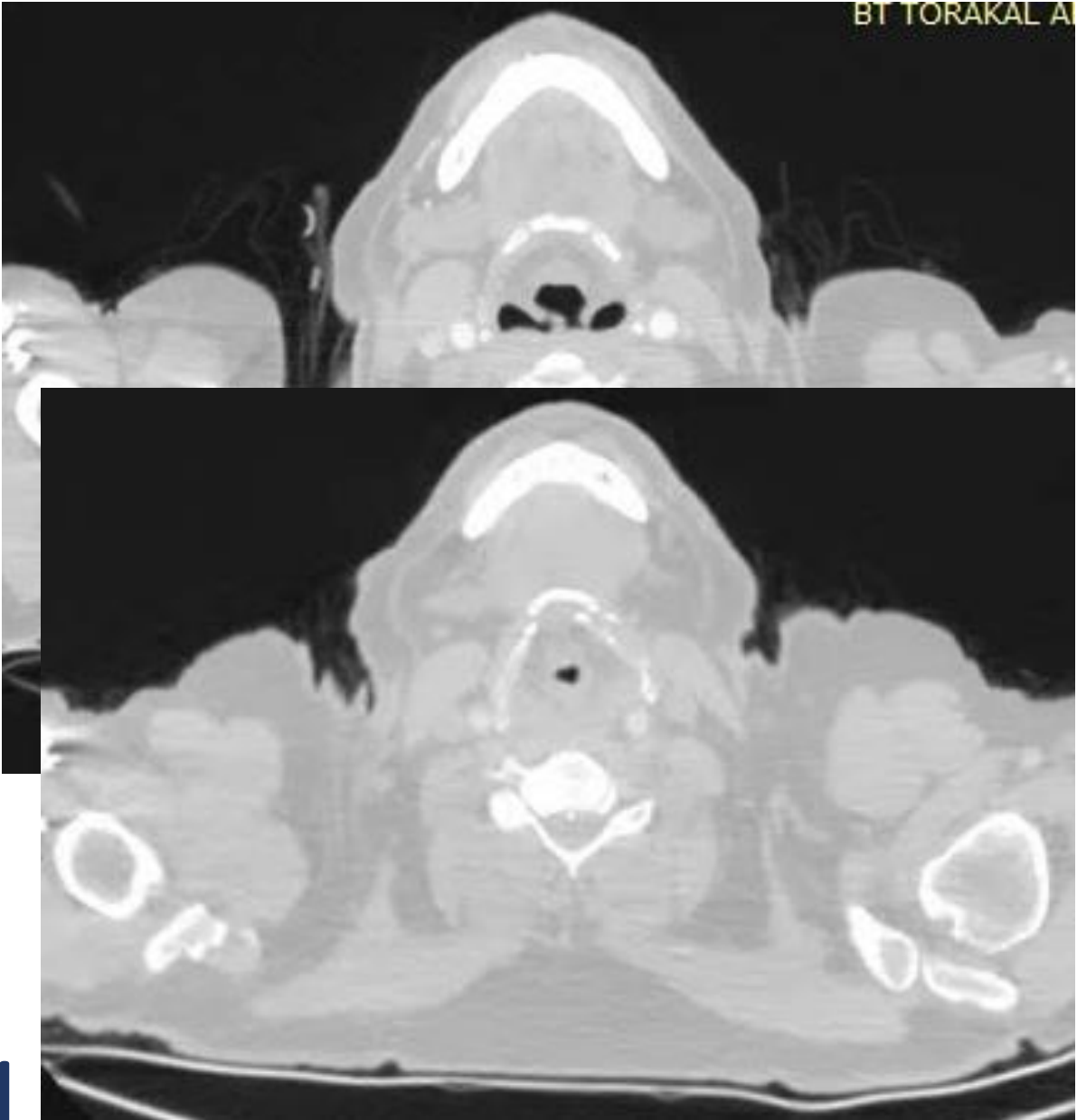
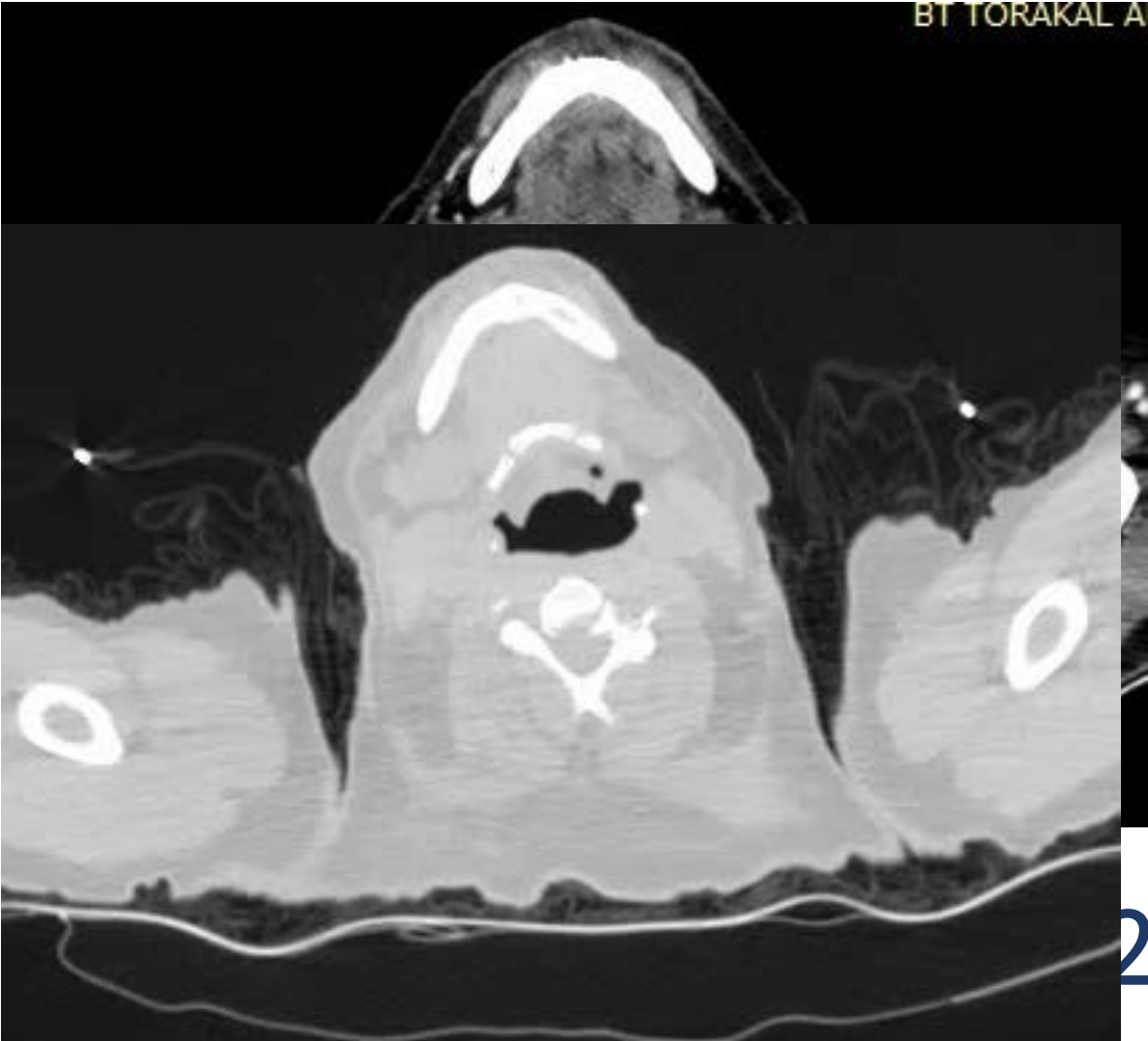
TORAKS BT

OLGU 6


- Özgeçmiş: Bir özellik yok
- Alışkanlık: Sigara: 15p/yıl, aktif içici
- Fizik Muayene:



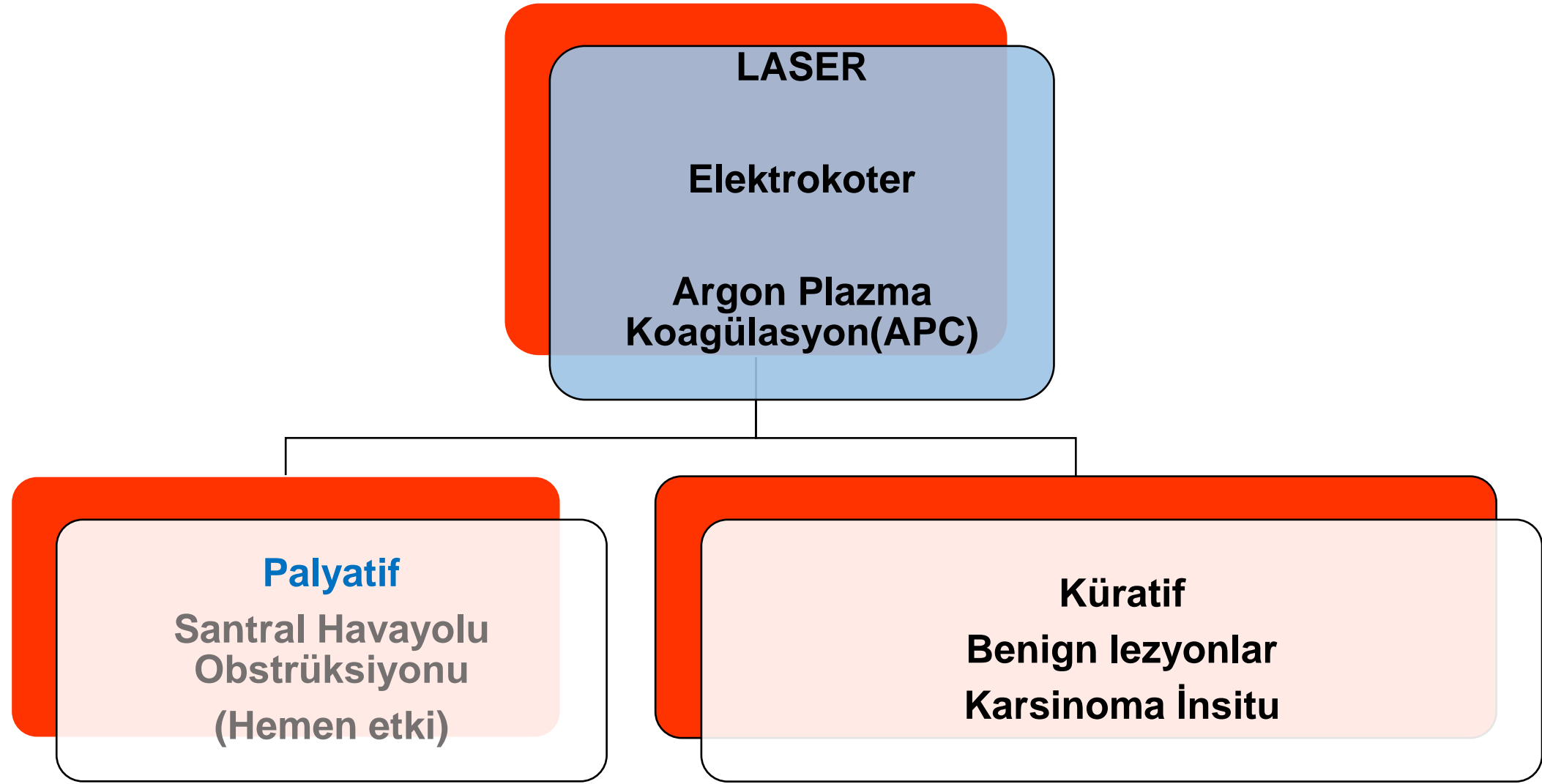
OLGU 3



NEREYE



Endobronşiyal sıcak tedavi yöntemleri



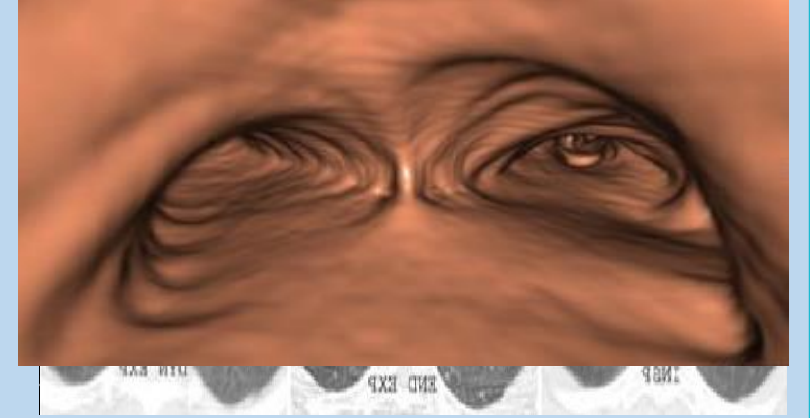
Görüntüleme Yöntemleri:

PA Akciğer Grafisi

Toraks BT

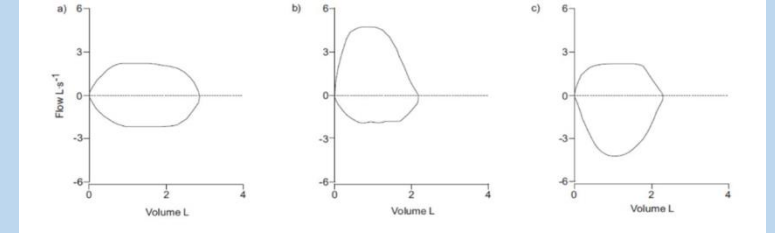
Dinamik Çekim Toraks BT
Sanal Bronkoskopi

Toraks MR



Fizyolojik Değerlendirme:

Solunum Fonksiyon Testi



Bronkoskopik Değerlendirme:

Fleksible Bronkoskopi

Rijid Bronkoskopi

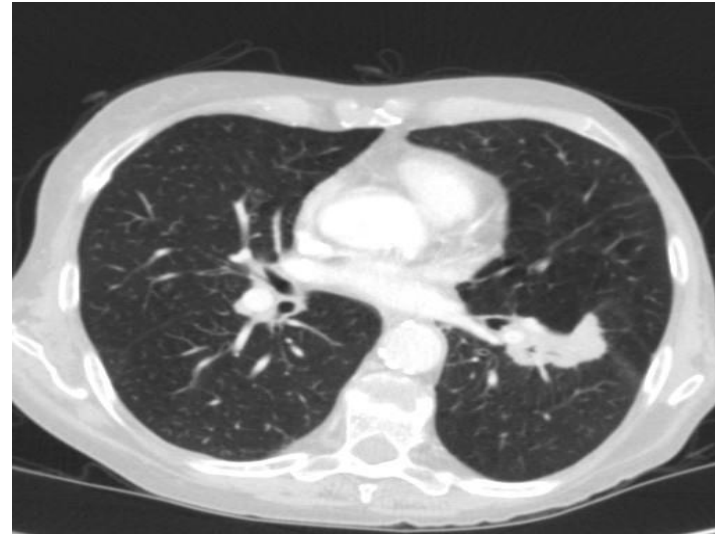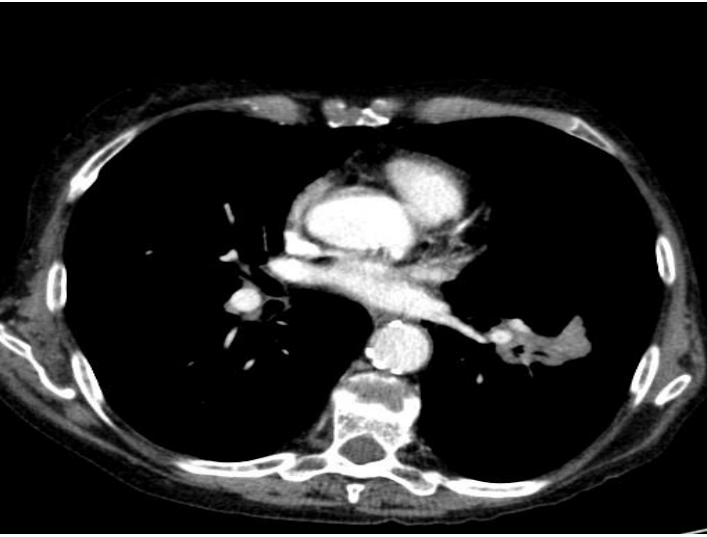


BAŞARI ŞANSINI ARTIRAN FAKTÖRLER

- ▶ Bronkoskop tümöre ulaşabilmeli
- ▶ Tümörün bronş içinde yayılımı sınırlı olmalı

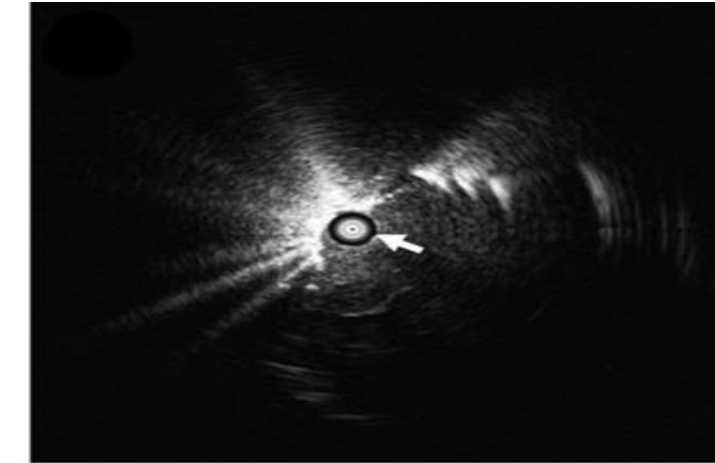
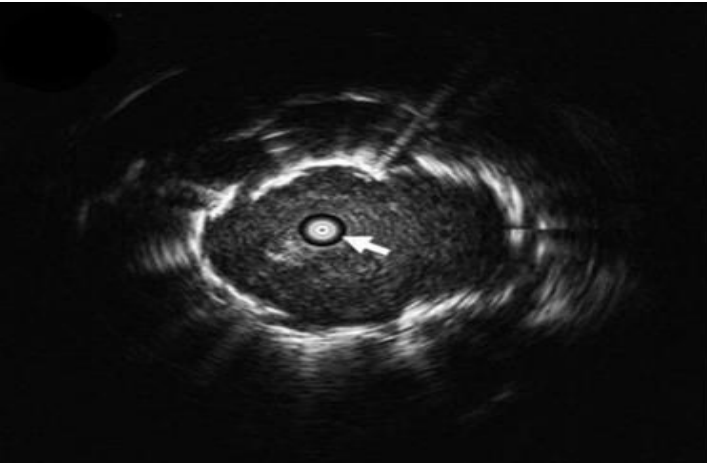
• **ACİL ŞARTLAR DEĞİL**

- ▶ Hastanın performans durumu iyi olmalı
- ▶ Elektif şartlar



Tanı başarısını etkileyen faktörler?

‘Bronkus işareti’



Tanı başarısını etkileyen faktörler?

‘Probun lezyon içindeki yeri!!’

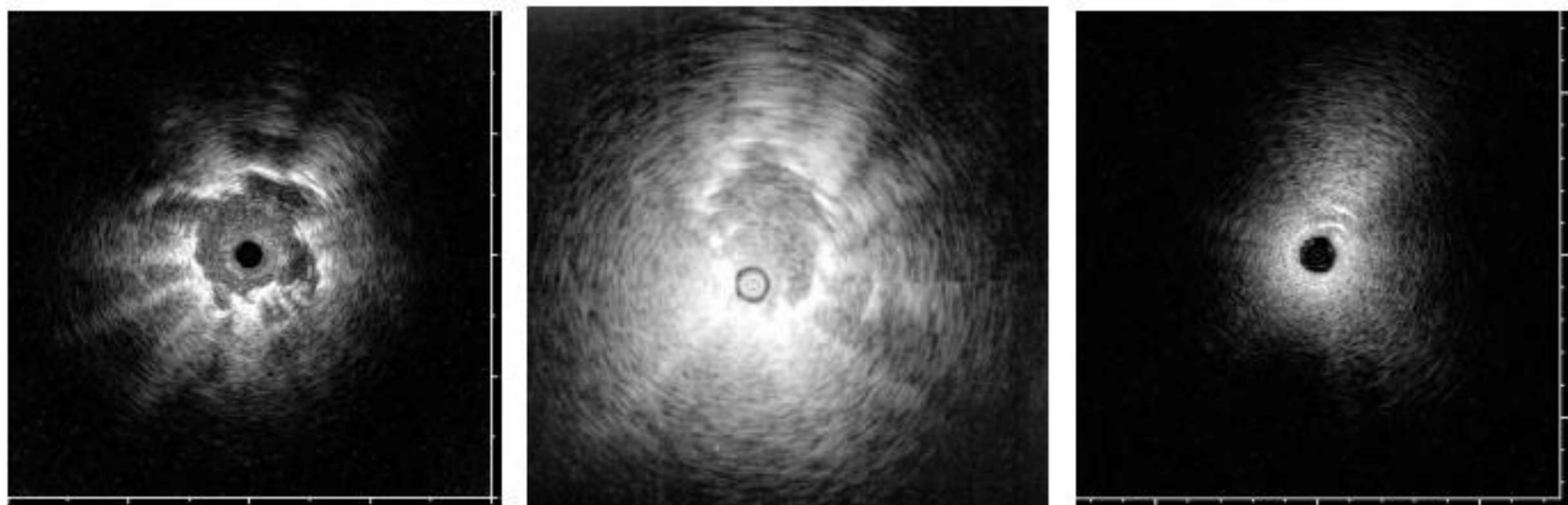


FIGURE 1. When evaluating the position of the probe against the PPLs on EBUS images, the position of the probe was divided into three patterns, as previously reported. *Left*: within the PPL; the probe was located in the bronchus inside the PPL. *Middle*: adjacent to; the probe was located in the bronchus adjacent to the PPL. *Right*: outside; the probe was located in the bronchus outside the PPL.

English dentist Charles Stent



Fig. 1. Charles Stent, 1807-1885.

STENTS IMPRESSION COMPOSITION,

FOR TAKING

Perfect Impressions of the Mouth.

CAN BE USED FOR EVERY DENTAL PURPOSE.

THE MOST RELIABLE ARTICLE IN THE MARKET.

Used by all the Leading Dentists.

TO BE HAD AT ALL DEPOTS IN THE WORLD.

4s. per lb., or 6 lbs. for 21s.

STENTS RENOVATING COMPOSITION.

Expressly made to be mixed with Discoloured Compo. making
it as Good as New. 4s. per lb.

Each box of Original Stent's Composition bears his
signature across the label.

C. Stent.

Sole Agents:

CLAUDIUS ASH & SONS,

LONDON

1, & 7, 8 and 9, UPPER STREET, GOLDEN SQUARE,
LONDON, W.

MALİGN

- Bronş, özefagus veya baş-boyun tümörleri nedeniyle dıştan bası
- Mediastinal lenf bezlerinden dolayı dıştan bası
- Malign fistül (Ör: trakeo-özefageal fistül)
- Endobronşiyal tümör

Tümör temizliğinin yetersiz oluşu, tedaviye rağmen relaps, lokal relapsın yüksek ihtimal oluşu

- İlk tanımlayan dişhekimisi C.R. Stent
- 1907: Killian metalik stent
- 1915: Brüning kauçuk stent
- 1933: Canfield gümüş stent
- 1965: Montgomery T Tüp
- 1965: Anderson Silikon stent
- 1978: Totj Nd:YAG Laser
- 1990: Dumon-Silikon Stent
- 1992: Nitinol-Stent
- 1992: Dinamik Stent

İDEAL STENT

- Kolay yerleştirilmeli
- Hava yolu dinamiklerine uyum göstermeli
- Trakea bronşa yüksek basınç uygulamamalı
- Nötral olmalı
- Migre olmamalı
- Mukostazise yol açmamalı
- Kolayca çıkarılmalı
- Ucuz olmalı

Endobronşiyal stentler

► Metal / kendiliğinden-açılabilen

► Wallstent, Ultraflex


► Silikon

► Dumon, Hood, Noppen, Montgomery, Polyflex

► Hibrid

► Rüsch Y- dinamik

► Silmet, Alveolus



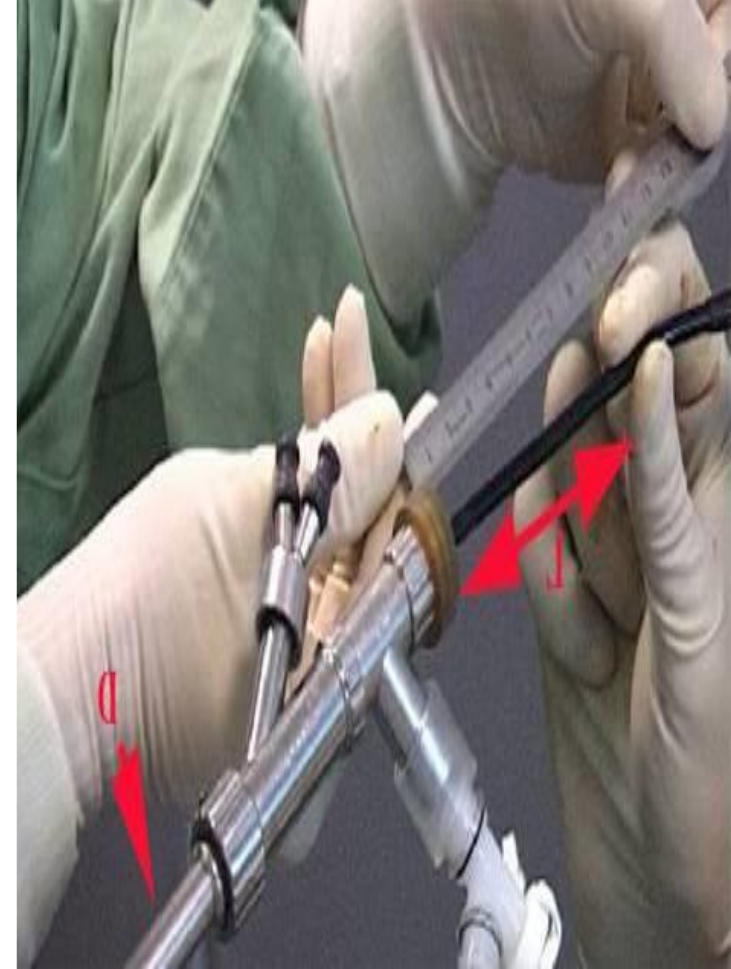STENT YERLEŐTİRİLMESİ

Güvenli ventilasyon

Dilatasyon

Güvenli yerleőtirme

Güvenli komplikasyon yönetimi



Metalik Stentler

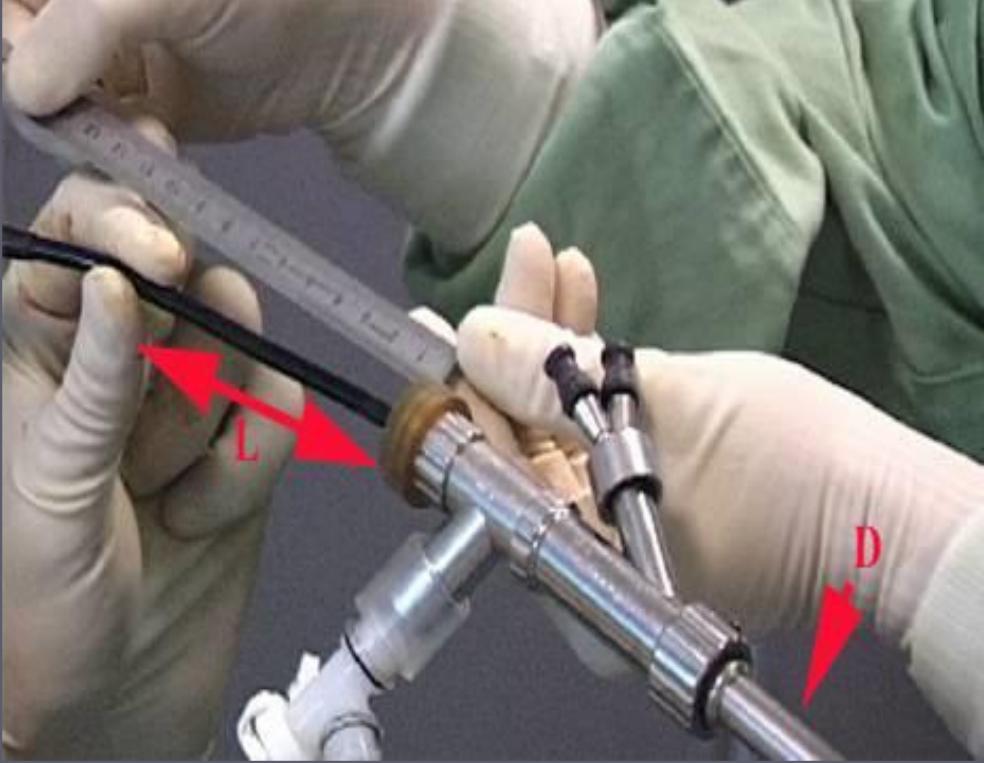


- **Hekime bağlı komplikasyonlar**

- Endikasyon doğru mu?
- Uygun stent mi?
- Migrasyon
 - Çap uygun mu?
 - Stent tipi uygun mu?
- Mukostaz
 - SF nebul (3kez/gün) önerilmemiş

- **Hasta/Hastalıkla İlişkili Komplikasyonlar**

- Migrasyon
 - Subglottik stenoz,malazi
- Obstrüksiyon
 - Kistik fibrozis,yoğun sekresyon
- Granülasyon
 - Diyabet
- Bakteriyel kolonizasyon
 - İmmün süprese hasta, transplantlı hasta,kistik fibrozis,diyabet



Uzunluk ve ap lümü

► Stenozun her bir ucundan trakeada 1 cm, bronşlarda 0.5 cm daha uzun stent seçilmeli

► BT ve endoskopi bulgularına göre

→ Timing of airway stenting ?

European Respiratory Society
Annual Congress 2013

Abstract Number: 5117
Publication Number: P3752

SPOC = Havayolu stentlemenin zamanlaması? **Silicone Prosthesis to** **Prevent Airway Obstruction** **Recurrence in Lung Cancers**

Abstract Group: 1.4. Interventional Pulmonology

Keyword 1: Lung cancer / Oncology Keyword 2: Bronchoscopy Keyword 3: Airway management

Title: Is a stent required after the initial resection of an obstructive lung cancer? The lessons of the SPOC trial, the first randomized study in interventional bronchoscopy

Prof. Dr Jean-Michel 33080 Vergnon vergnon@univ-st-etienne.fr MD ^{1,2}, Dr. Yoann 33081 Thibout yoann.thibout@chu-st-etienne.fr MD ¹, Dr. Herve 33082 Dutau Herve.DUTAU@ap-hm.fr MD ³, Dr. Michel 33083 Fabvre michel.fabvre@sat.aphp.fr MD ⁴, Dr. Laurent 33084 Cellierin laurent.cellierin@chu-nantes.fr MD ⁵, Dr. Christophe 33085 Hermant hermant.c@chu-toulouse.fr MD ⁶ and Dr. Fabrice 33088 Di Palma fabrice.dipalma@hotmail.fr ¹. ¹ Chest Diseases and Thoracic Oncology, University Hospital, Saint Etienne, France, 42055 ; ² LINA EA 4624, University Jean Monnet, Saint Etienne, France, 42000 ; ³ Thoracic Endoscopy Unit, Chest Diseases Department, North Hospital, University Hospital, Marseille, France, 13000 ; ⁴ Chest Diseases, Saint Antoine Hospital, University Hospital, Paris, France, 75000 ; ⁵ Chest Diseases, Laennec Hospital, University Hospital, Nantes, France, 44093 and ⁶ Thoracic Endoscopy Unit, Chest Diseases Department, Lapeyre Hospital, University Hospital, Toulouse, France, 31000 .

75 patients randomized (39 stent ; 36 no stent)

primary endpoint : 1 year survival without recurrence >50%

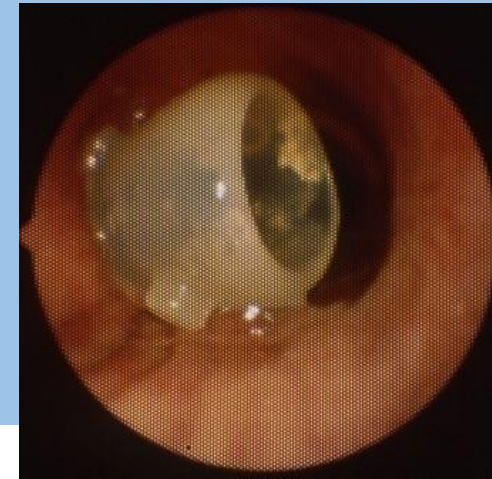Recurrence rate local obstruction strongly decreased in stent arm
Survival at 1 year : no difference.

Vergnon et al. ERS Congress 2013 Oral presentation.

MİGRASYON

- Silikon %3-13
- Metalik stent %0-17

- Küçük çaplı stent
- Dış basının düşük olduğu hastalar
 - İntrensek malign stenoz
 - Malazi



MUKOSTAZ

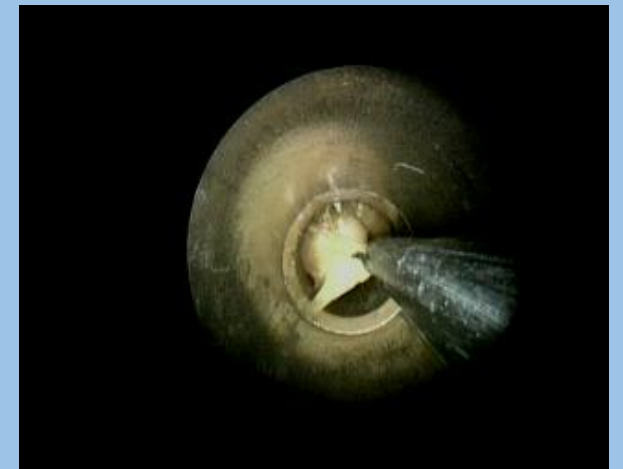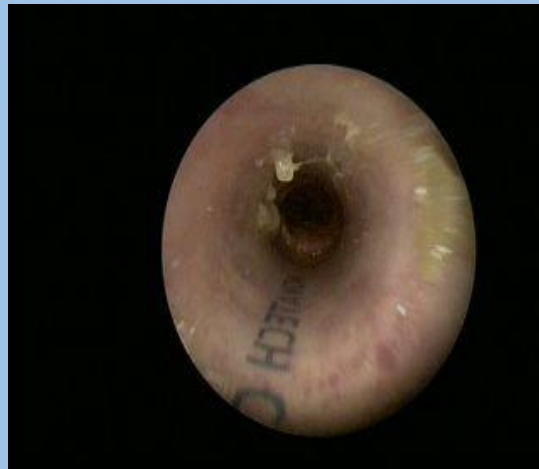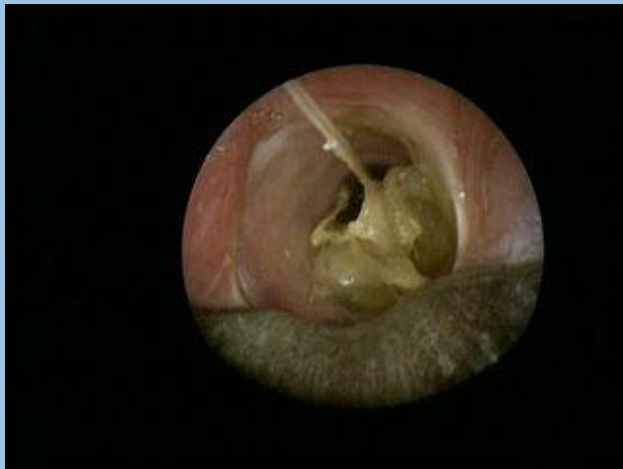-

Silikon

%6-50

Metalik stent

%18-39

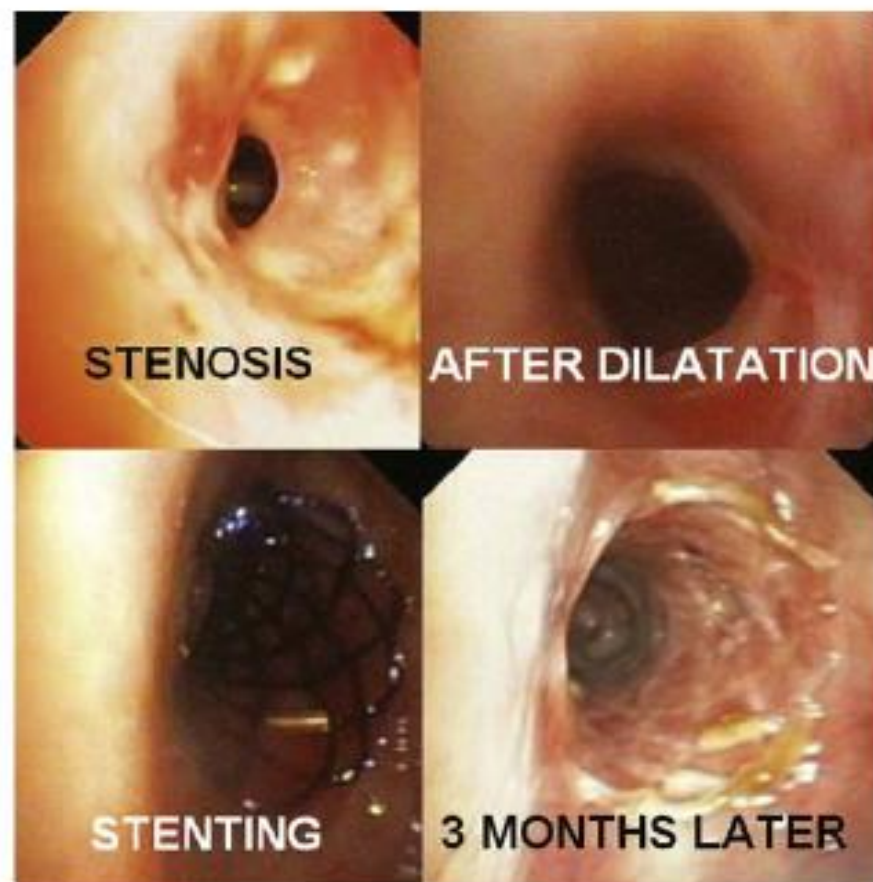

2. Jenerasyon stentlerle çözülebilecek komplikasyonlar

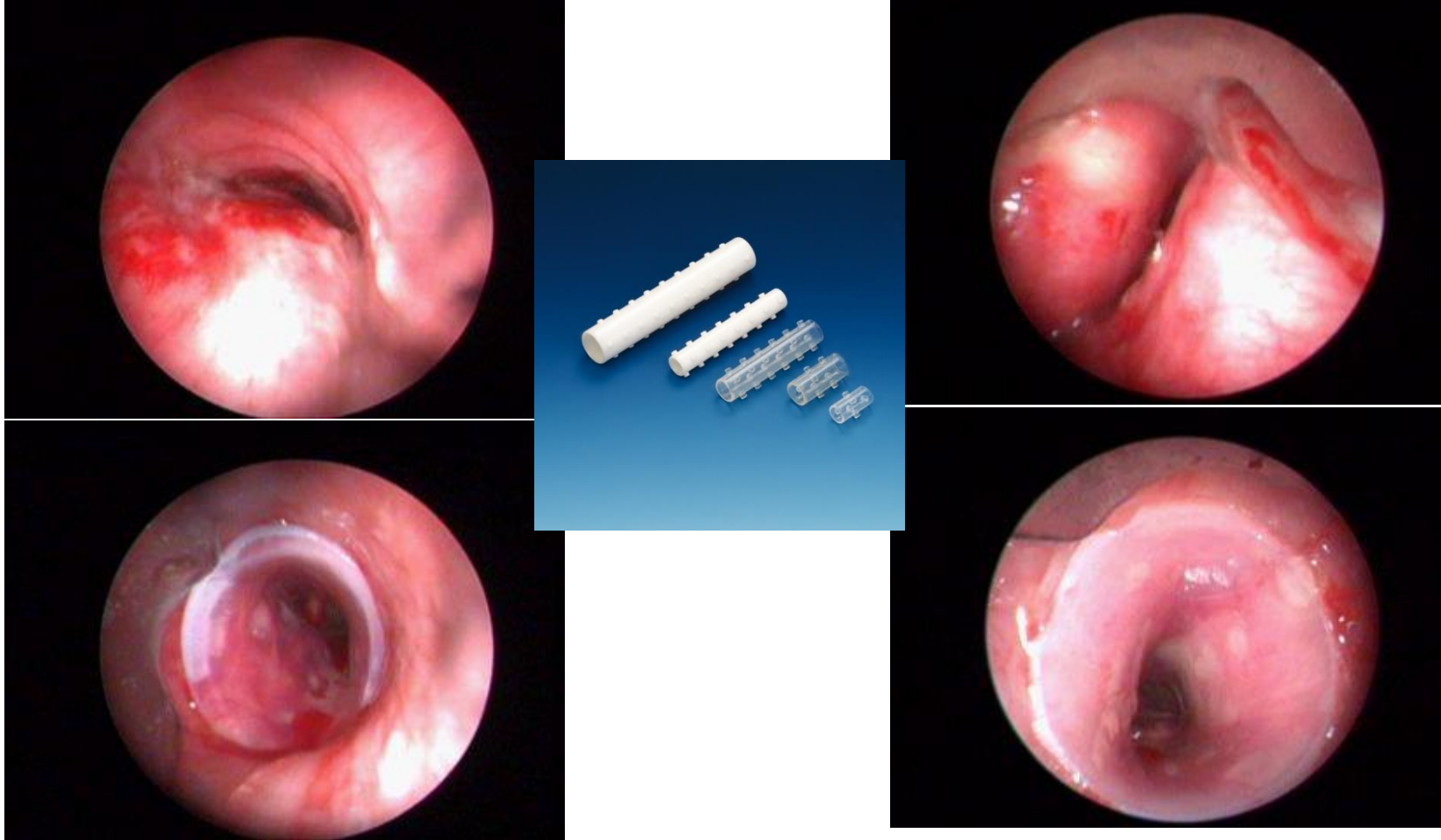
Başlıca sorunlar	İlaç salınımlı(aktiflenen)	Yeni üretim
Bakteriyel kolonizasyon	√	-
Mukostaz	√	√
Granülasyon /Re-stenoz	√	√
Migrasyon	-	√
Kompleks trakeobronşiyal anatomi	-	√
Daralan iç çap	-	√

Novel biodegradable stents in the treatment of bronchial stenosis after lung transplantation^{☆,☆☆}


Robert Lischke^a, Jiri Pozniak^a, David Vondrys^{b,*}, Martin J. Elliott^b



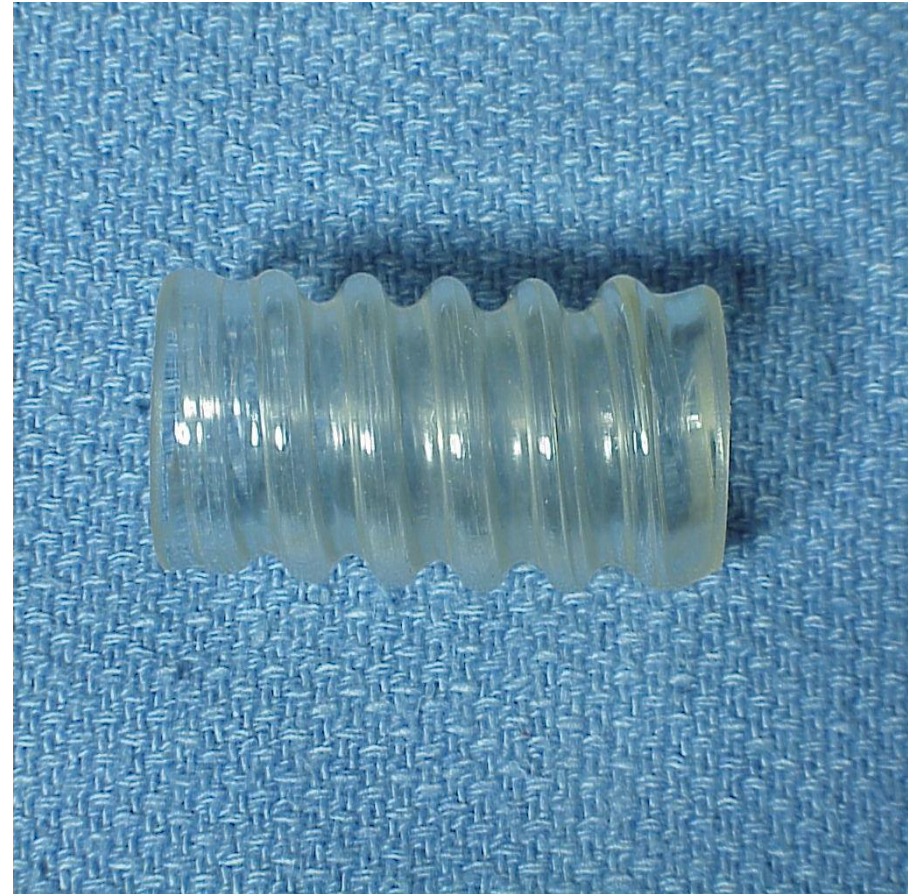
Düz silikon stent



Stenotik stent

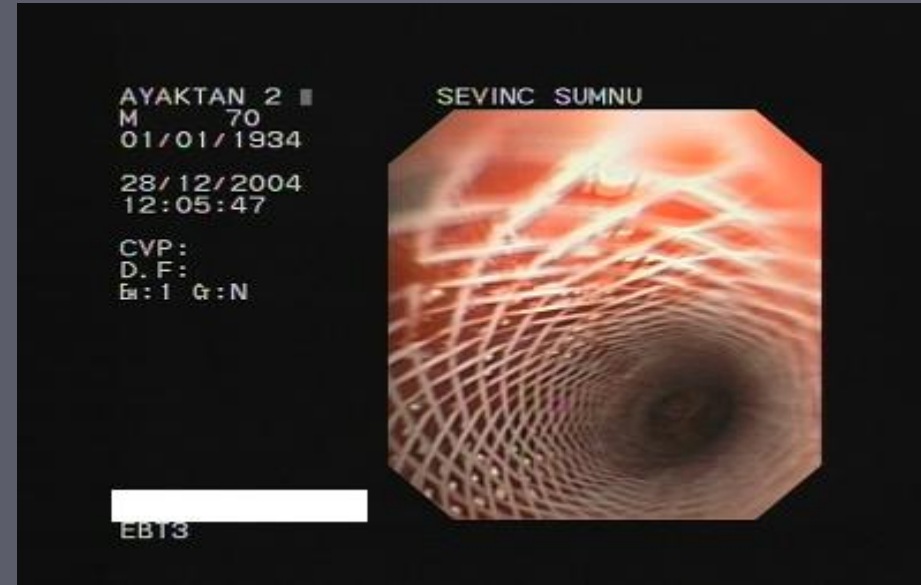
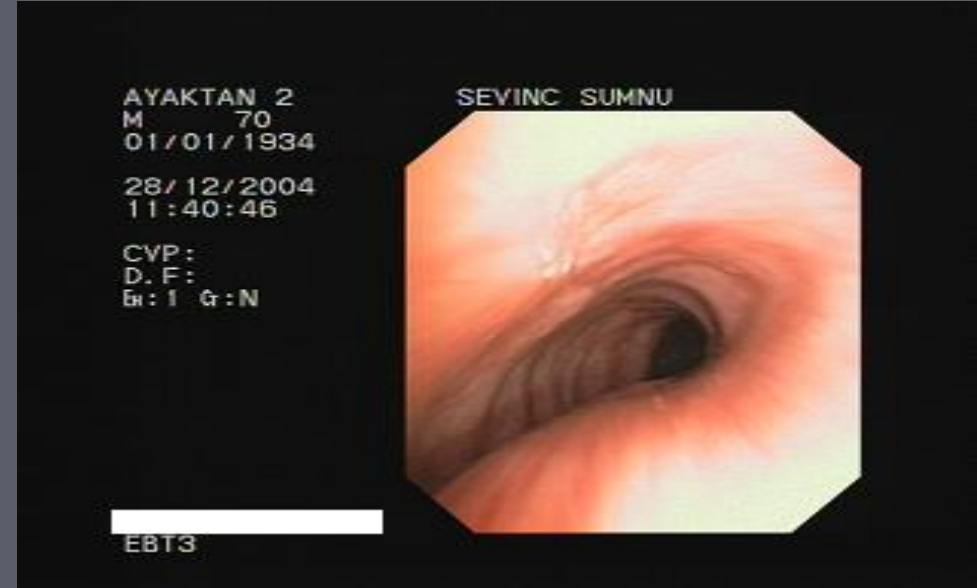
Noppen stent



Polyflex Stent

- Rijid bronkoskopi
- Aynı yükleme setiyle tekrar yüklenebilir



Hibrid Stentler

Genişleyen stent



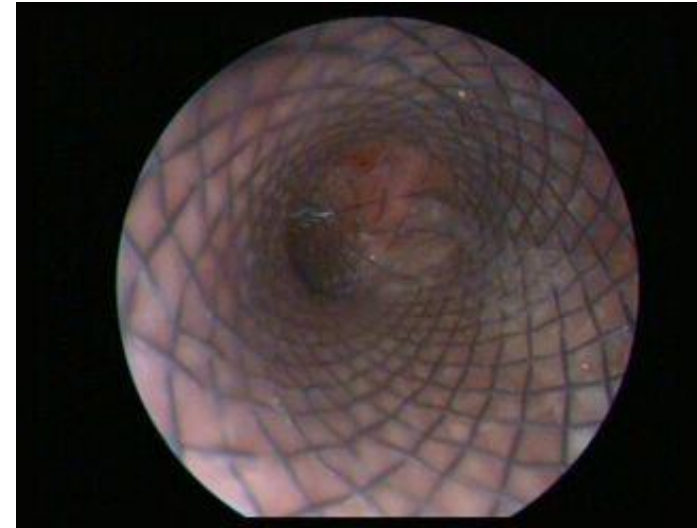
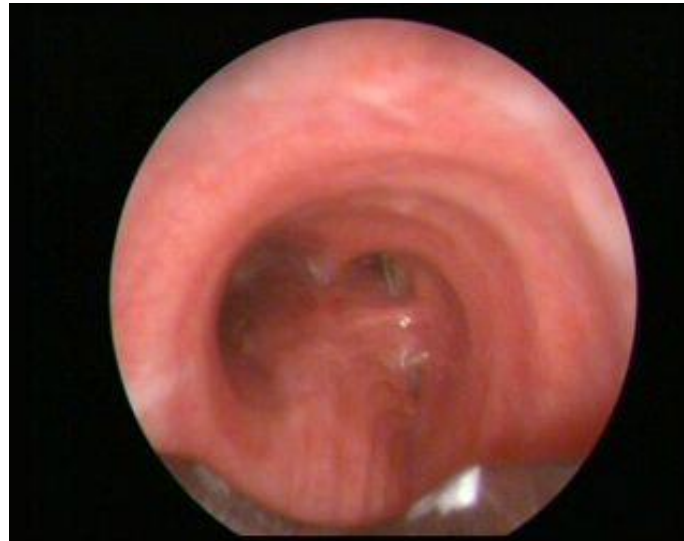Alveolus



Genişlemeyen

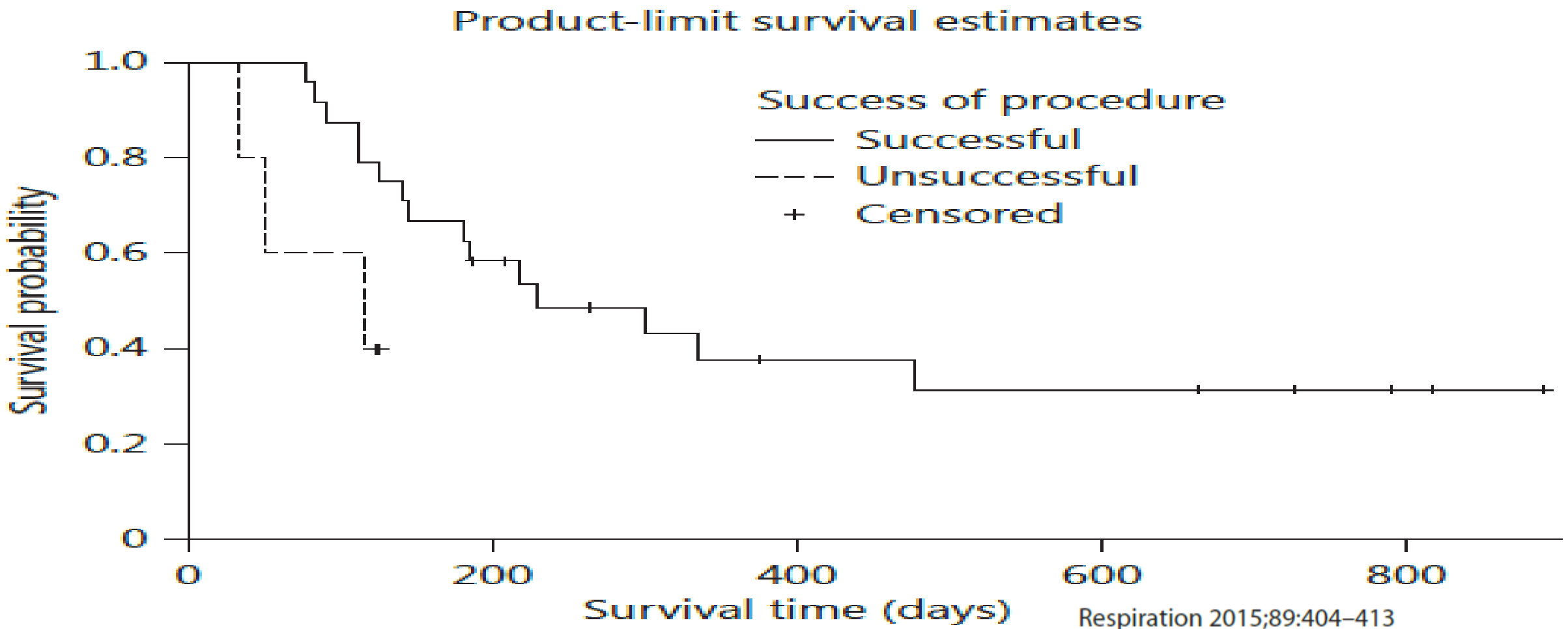


Dinamik stent, Rusch



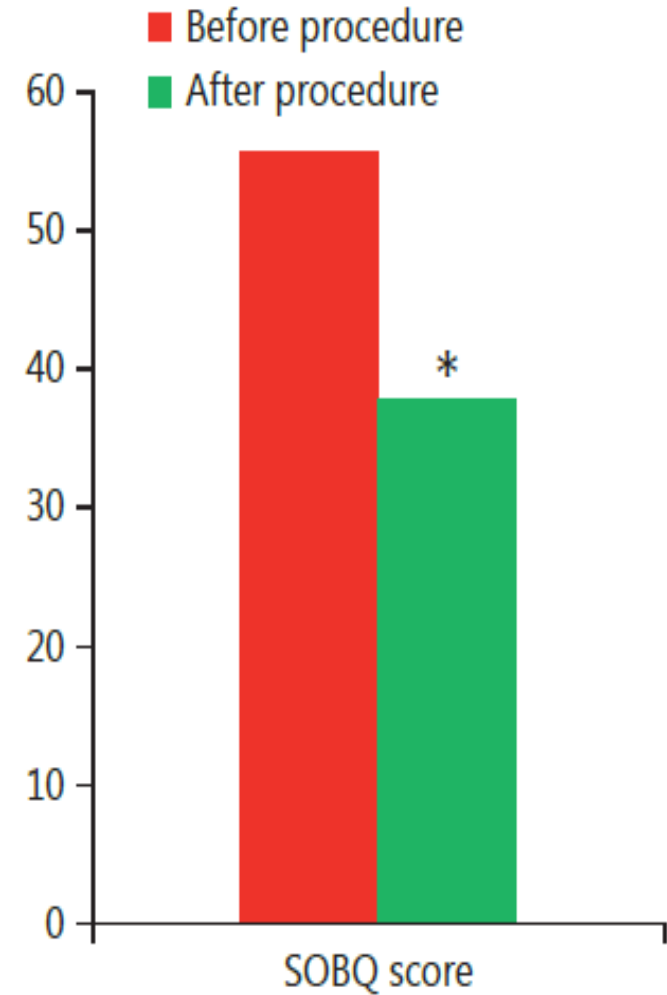
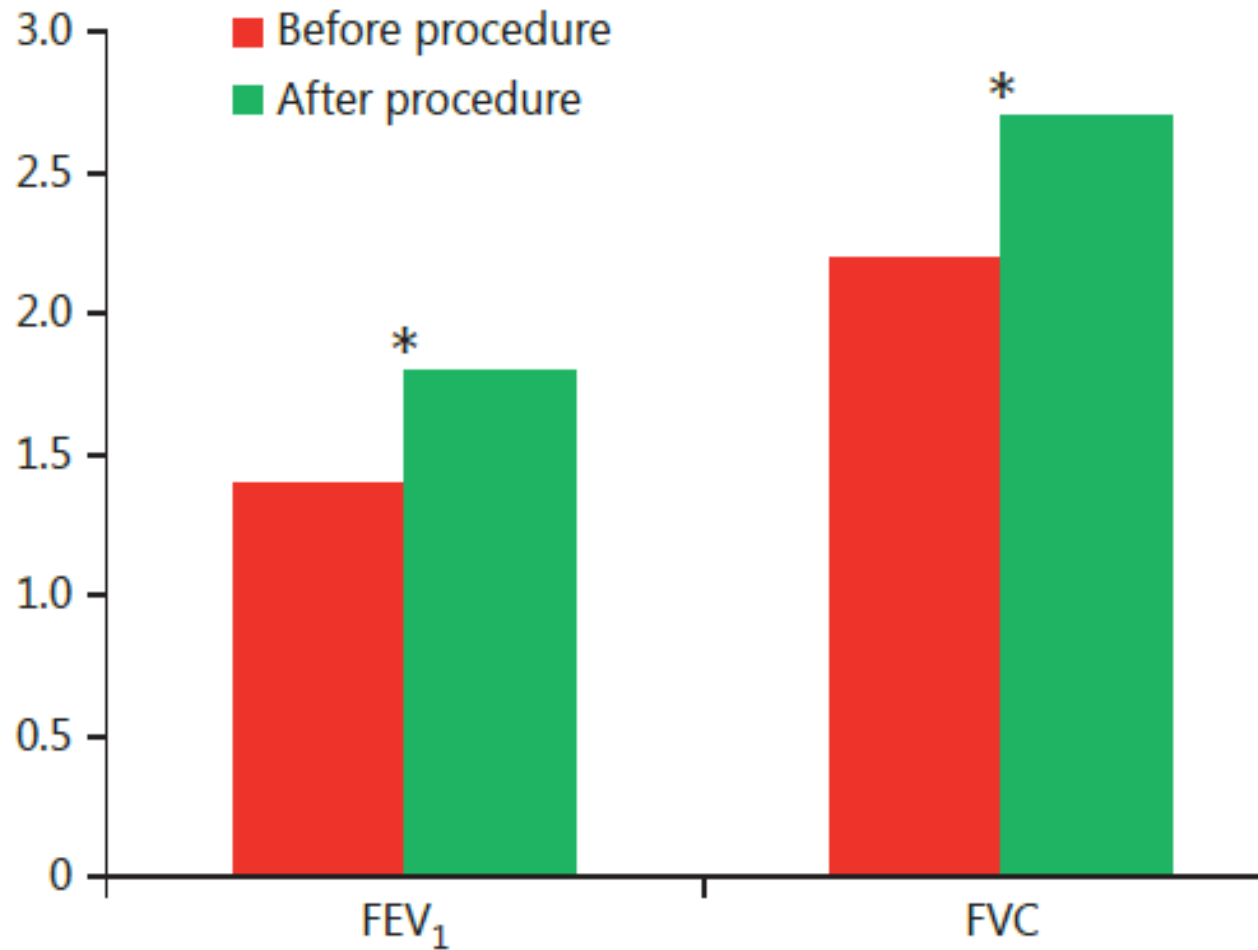
Therapeutic Bronchoscopy Improves Spirometry, Quality of Life, and Survival in Central Airway Obstruction

Kamran Mahmood^a Momen M. Wahidi^a Samantha Thomas^a
Angela Christine Argento^b Neil A. Ninan^c Emily C. Smathers^a Scott L. Shofer^a



Therapeutic Bronchoscopy Improves Spirometry, Quality of Life, and Survival in Central Airway Obstruction

Kamran Mahmood^a Momen M. Wahidi^a Samantha Thomas^a
Angela Christine Argento^b Neil A. Ninan^c Emily C. Smathers^a Scott L. Shofer^a

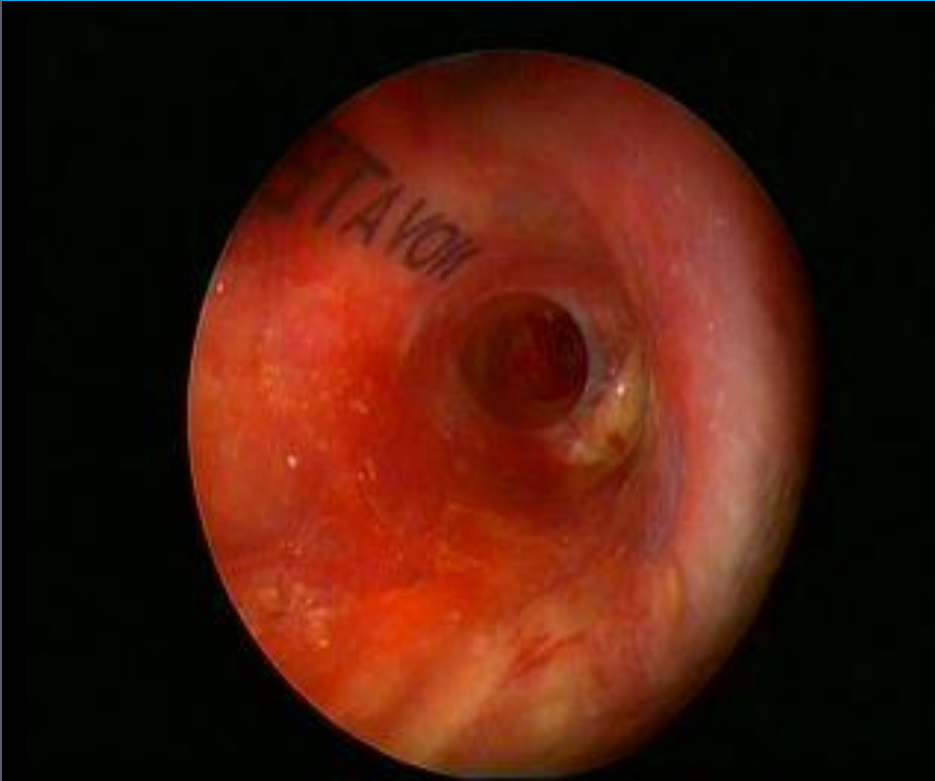

BRONŞİAL Y STENT

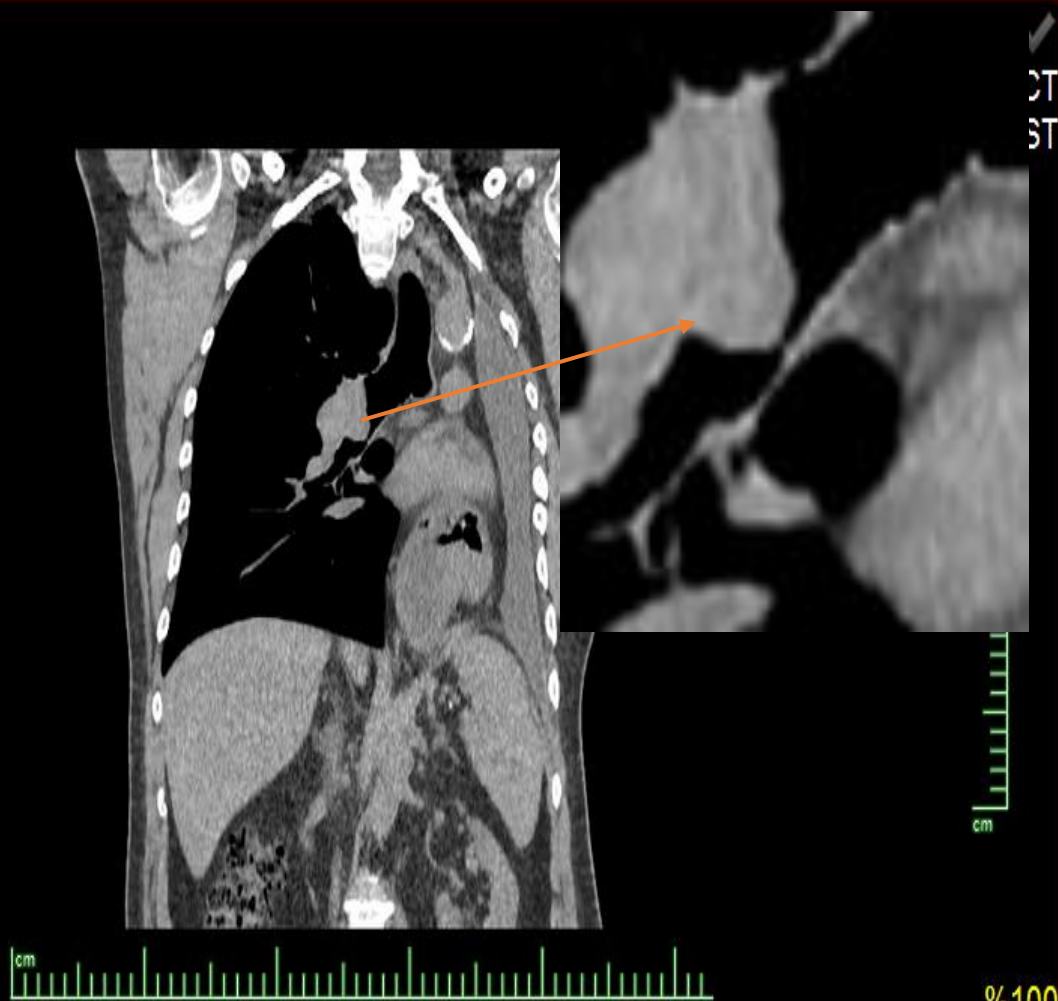Oki stent application in different indications: Six cases.

Özgül MA, Çetinkaya E, Çörtük M, Tanrıverdi E, Yıldırım BZ, Balci MK, Issaka A, Özgül G.
Clin Respir J. 2016 Jun 22. doi: 10.1111/crj.12521

- Sağ bronş sistemi
- Üst lob orifisin kapanmaması için

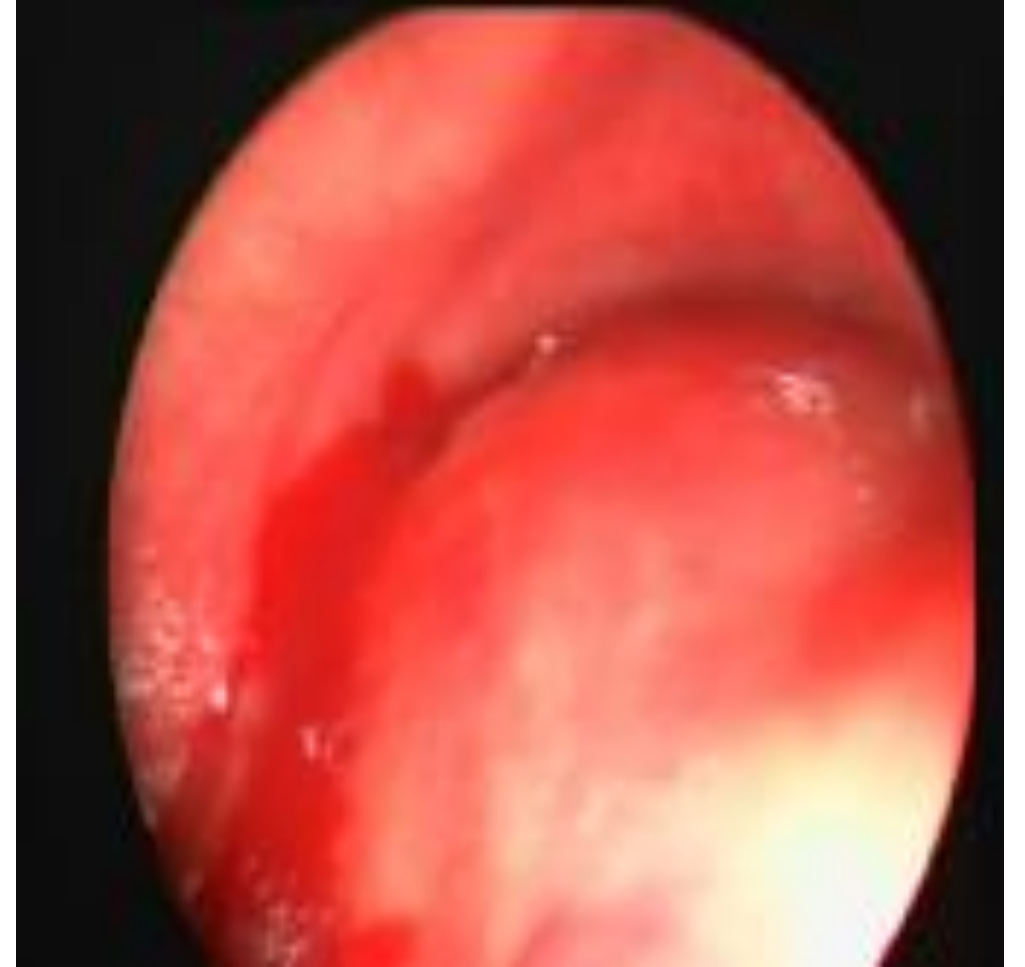


MAHMUT KACAN
062Y M
44740108244
1
04.11.2017 14:54:54
RESIM 46

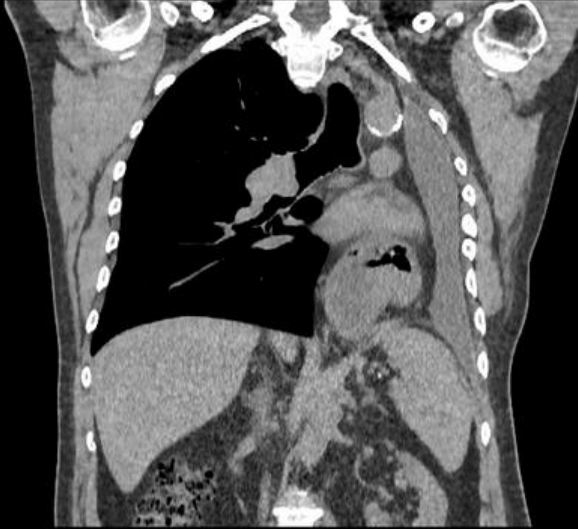

YEDIKULE GOG.HAST.VE GOG.CERRAHI E.A.H.

%100
W:404 C:3



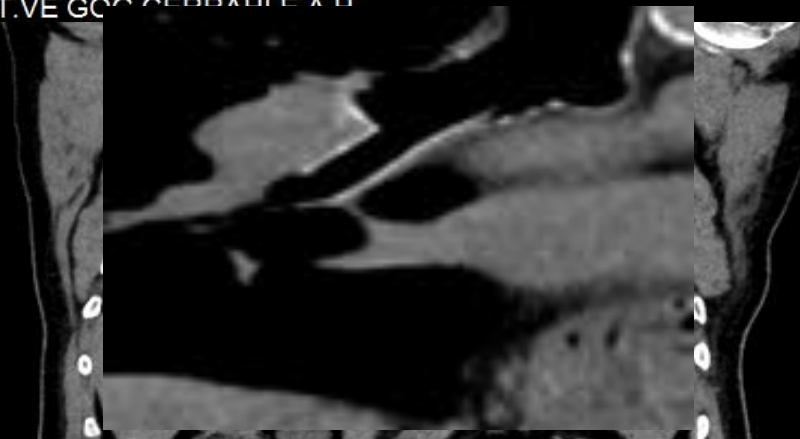
MAHMUT KACAN
062Y M
44740108244
1
04.11.2017 14:54:54
RESIM 46



Ingenuity CT
CHEST



YEDIKULE GOG.HAST.VE GOG.CERRAHI E.A.H.
RESIM 43

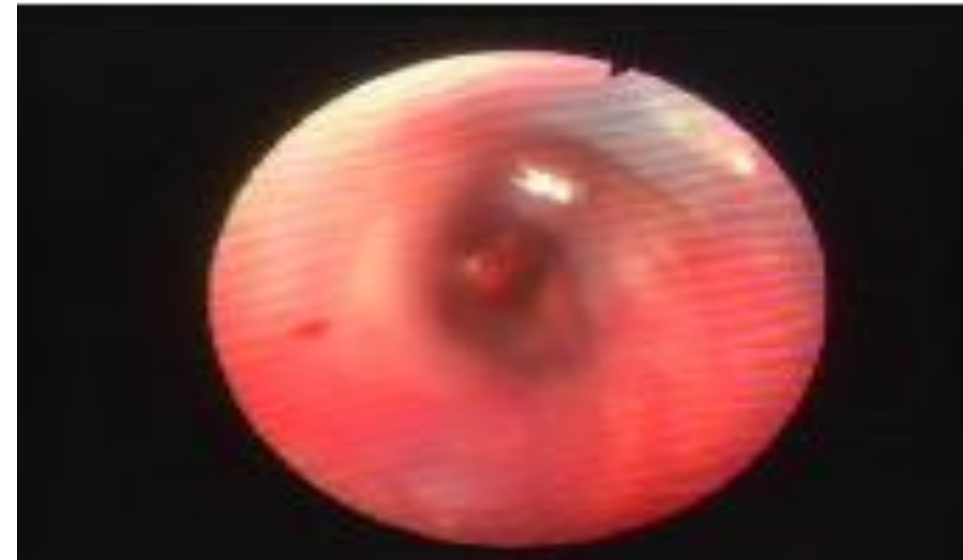
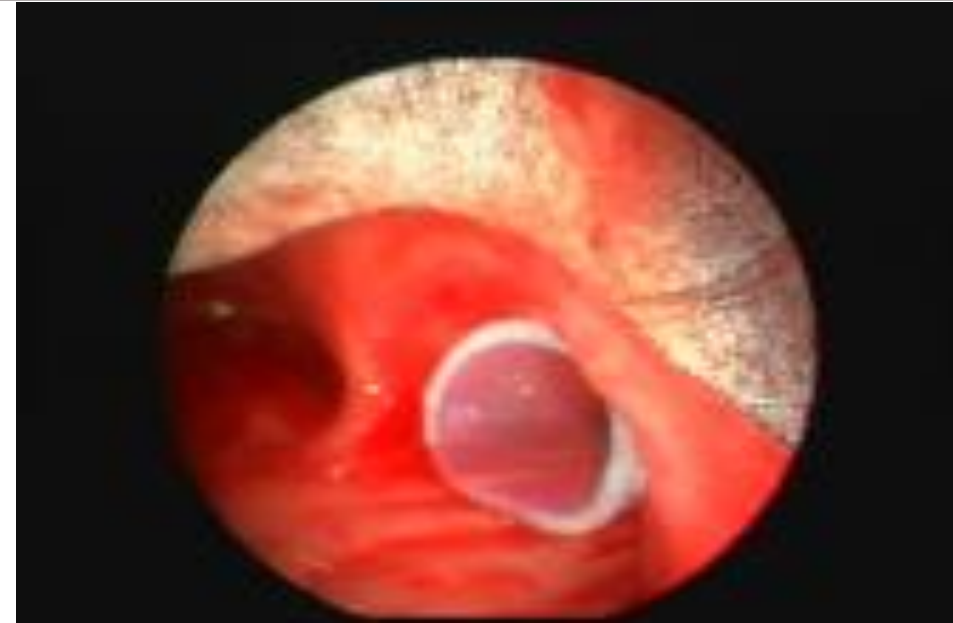

%100
W:404 C:3

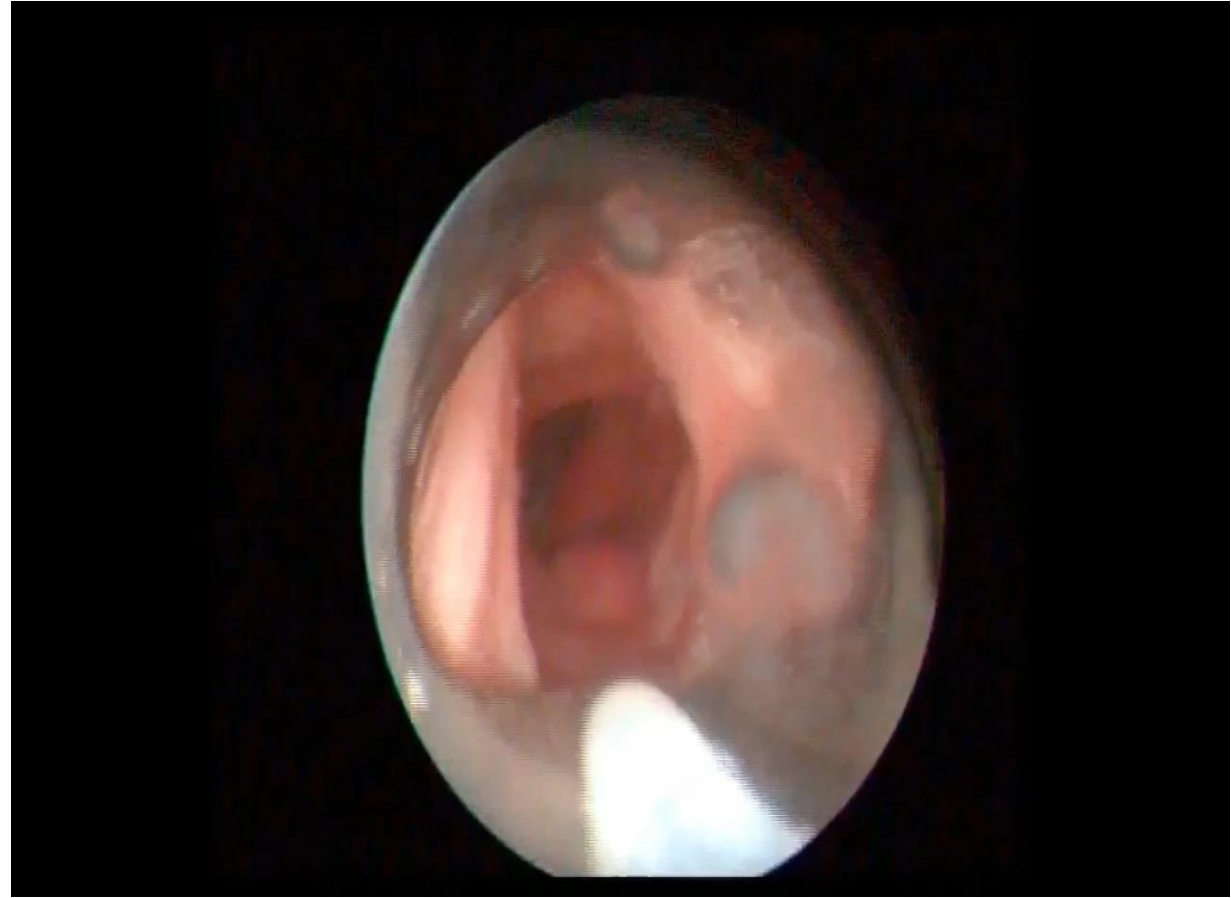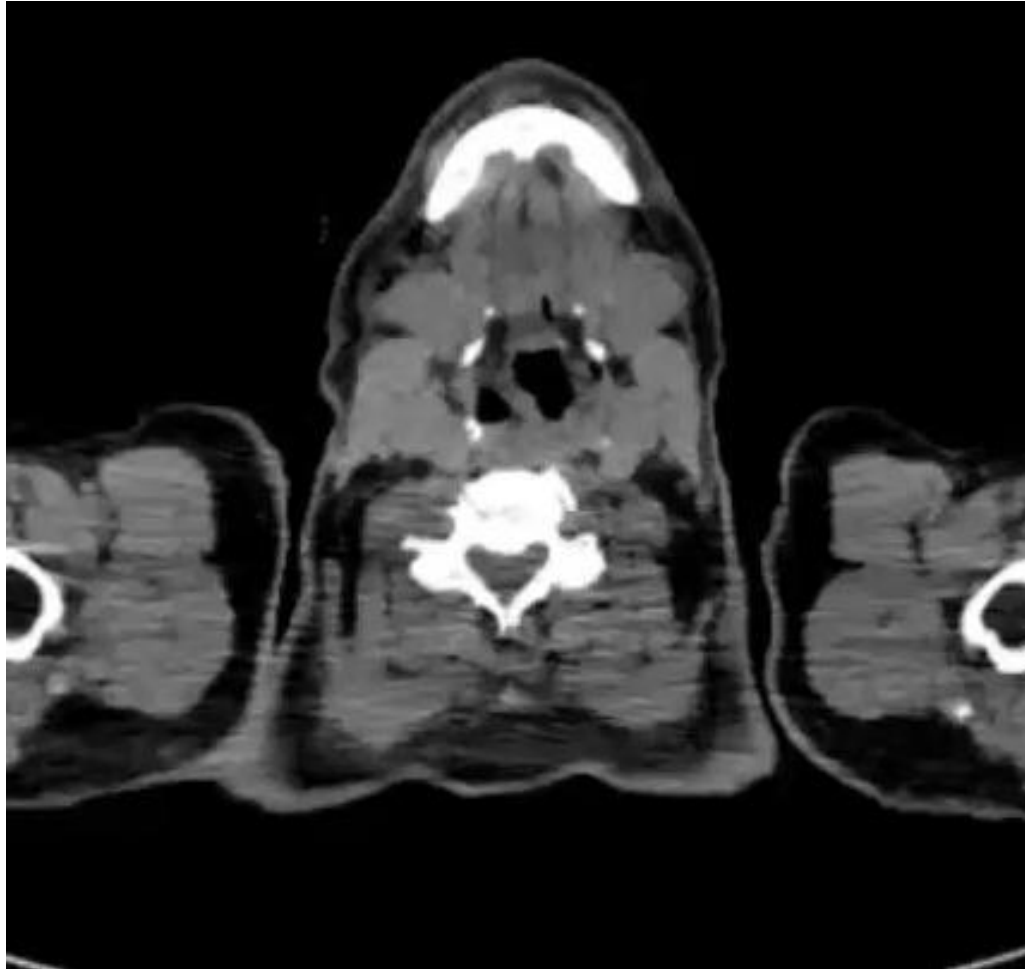


YEDIKULE GOG.HAST.VE GOG.CERRAHI E.A.H.

%100
W:350 C:60



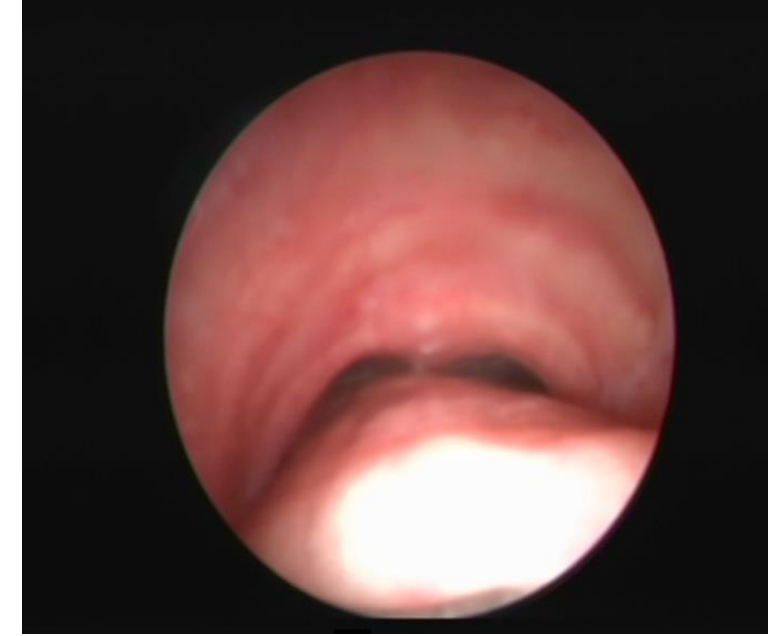
OLGU 7



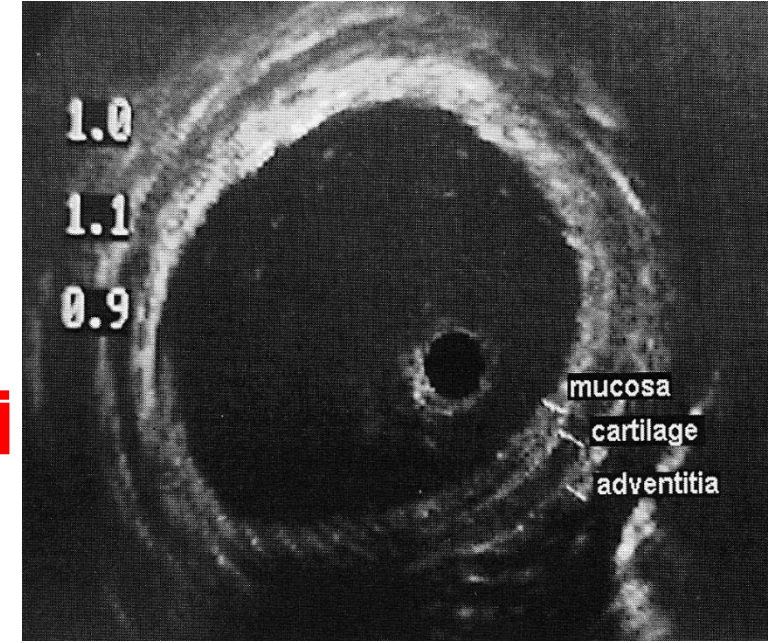Santral Havayolu Obstrüksiyonun Tanısı

► Bronkoscopi

- Havayolu mukozası ve stenoz natürü direkt gözlenebilir
- Yoğun bakım hastalarında yapılabilir.
- Ultrathin bronkoscopi
Stenoz distali



- Radial EBUS
(Trakeal invazyon ve vasküler tutulum)



► ASFİKSİ=ENTÜBASYON ve RİJİT BRONKOSKOPI

- **SANTRAL HAVA YOLU OBSTRÜKSİYONLARINDA**
- **Yeterli oksijenizasyon**
- **Yeterli ventilasyon**

Semptomlar

Dispne

Nerede,ne kadar darlık var

Stridor 8 mm egzersiz

5 mm istirahat

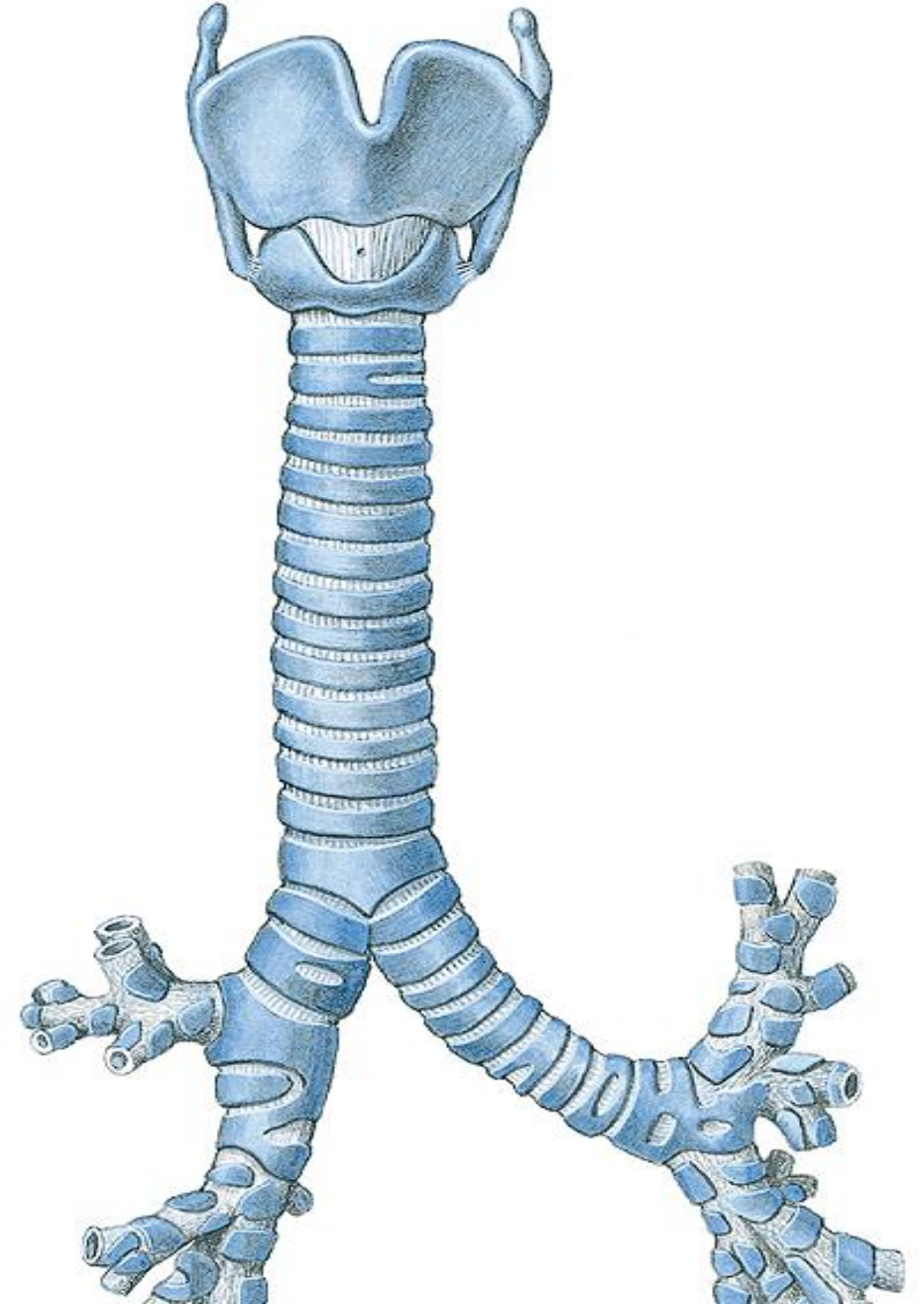
Bronkodilatöre yanıt vermeyen dispne

Ekstubasyon başarısızlığı

Öksürük

Hemoptizi

Pnömoni



Im: 47/189

Se: 201

Im: 58/189

Se: 201

Im: 67/189

Se: 201

HELVACI NURTEN

A

HELVACI NURTEN

30451135754

28.12.1951 F

YEDIKULE GOG.HAST.VE GOG.CERRAHI E.A.H.

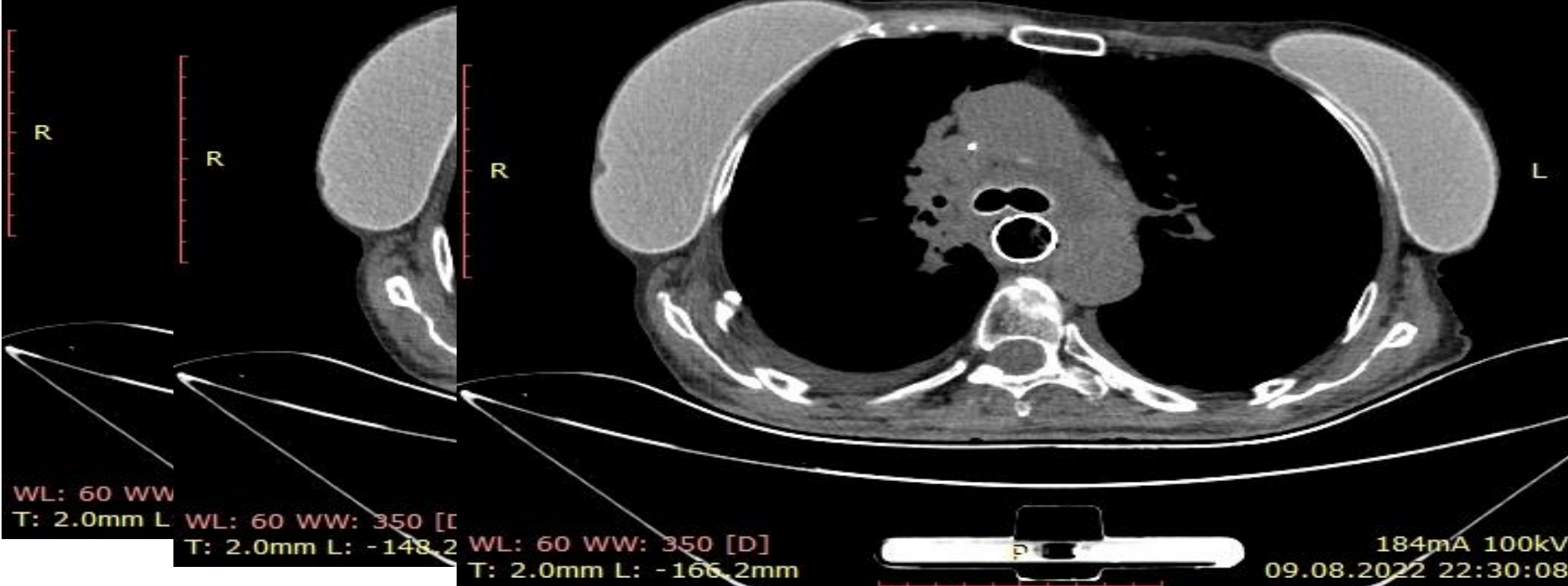
2373

(804070

(804070) BT, Toraks, kontrastsiz | (C15.9) Ozofagus malign ne

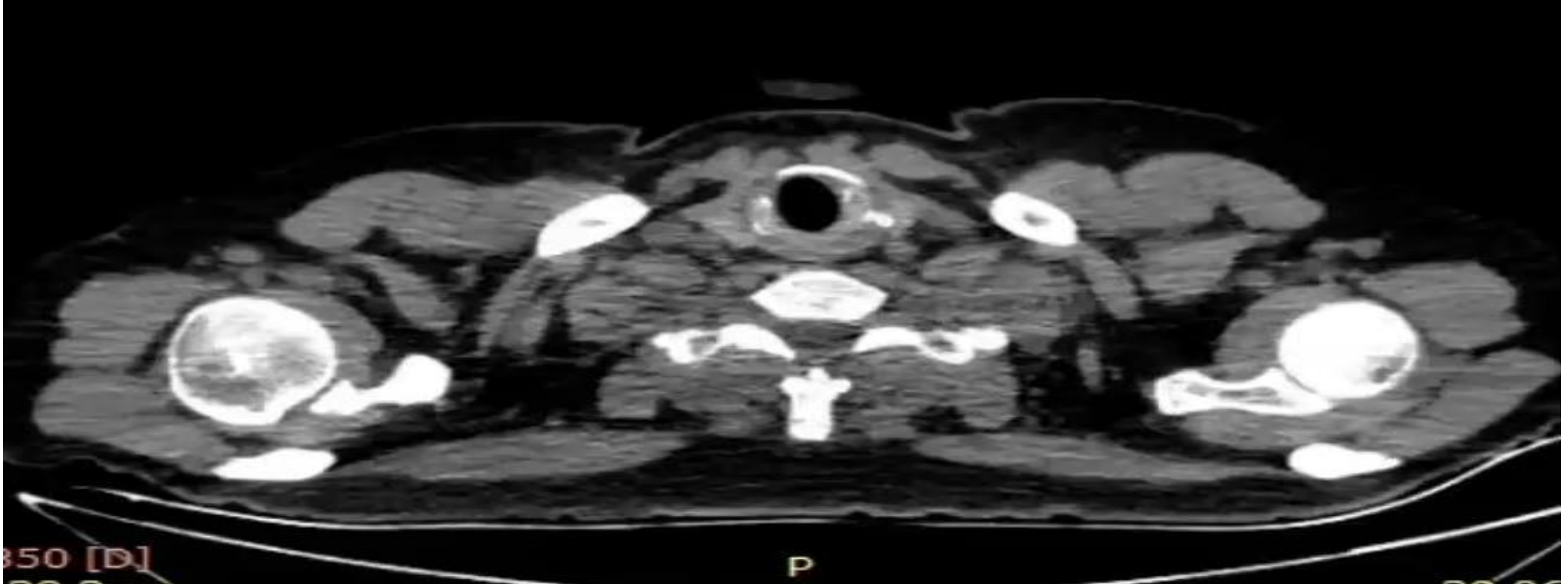
Mediasten, iDose (4)

Mediasten

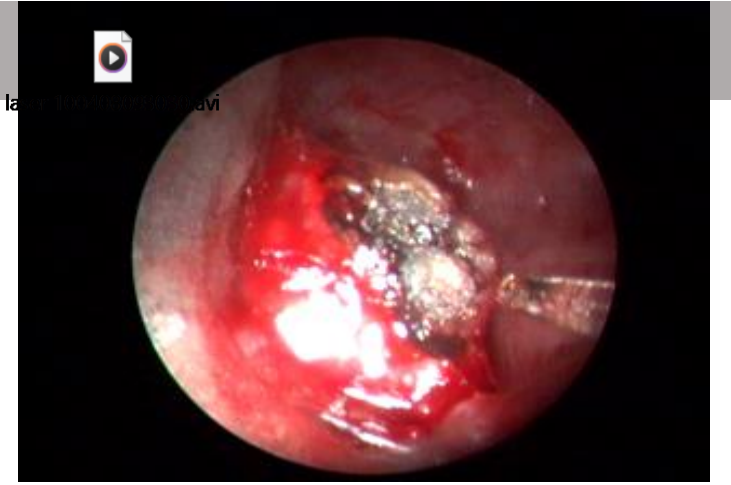
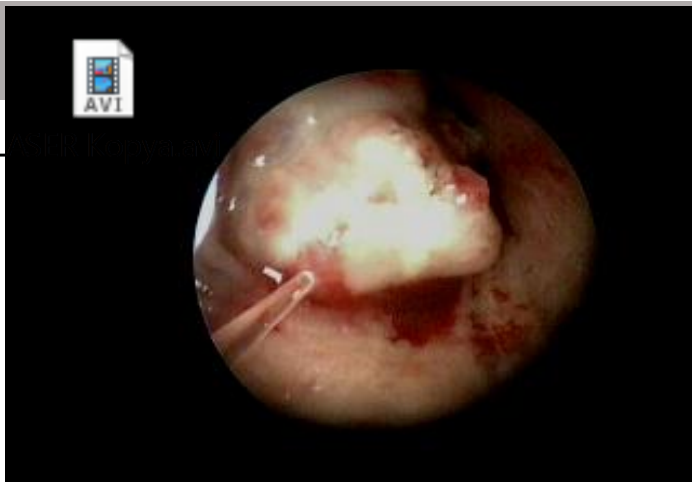
OLGU 3

- Klinik rahatlama saęlanan hastada KT –RT tedavileri tamamlandı
- Ancak Haziran 2021 de ayında tekrar nefes darlıęı nedeni ile başvurdu
- ekilen Toraks BT’de stent proksimalinde trakeada stenotik alan izlendi



LASER



- **Aynı dalga boyu ve paralel ışık**
- Dokular laser yoğun ışığını emer ve enerji büyük oranda ısı şeklinde açığa çıkar.
- **Doku ışık etkileşimi**
- Renksiz doku derin damarların koagülasyonu
- Renkli doku yüzeysel damarların koagülasyonu

METALİK STENTLER

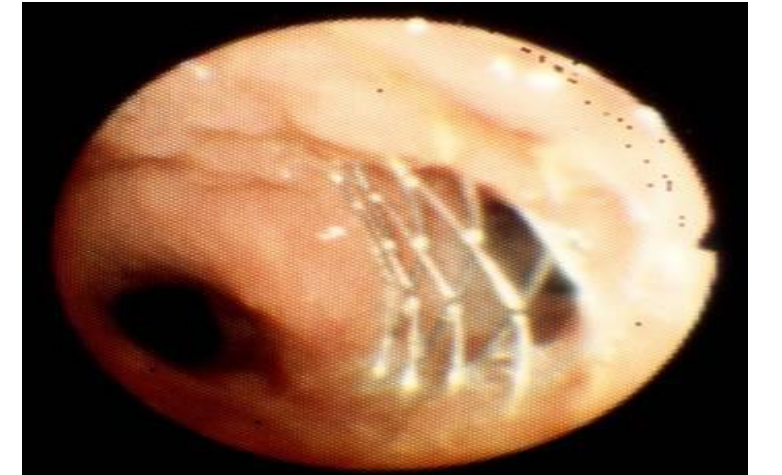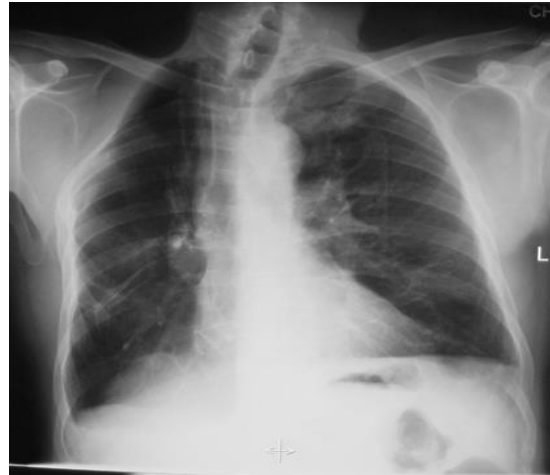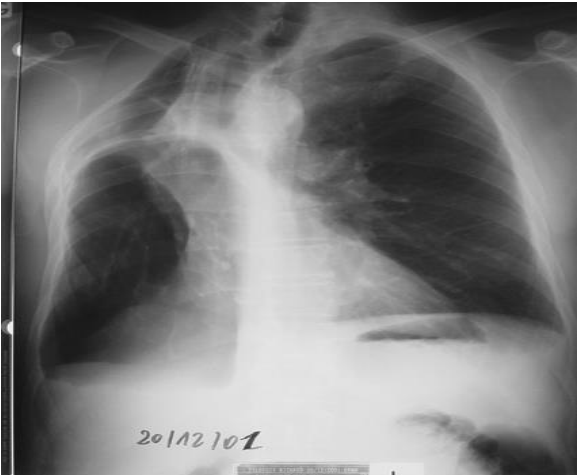Stent konacak segmentin deęişken apı varsa

Ana bronşlarda distorsiyon olan olgularda

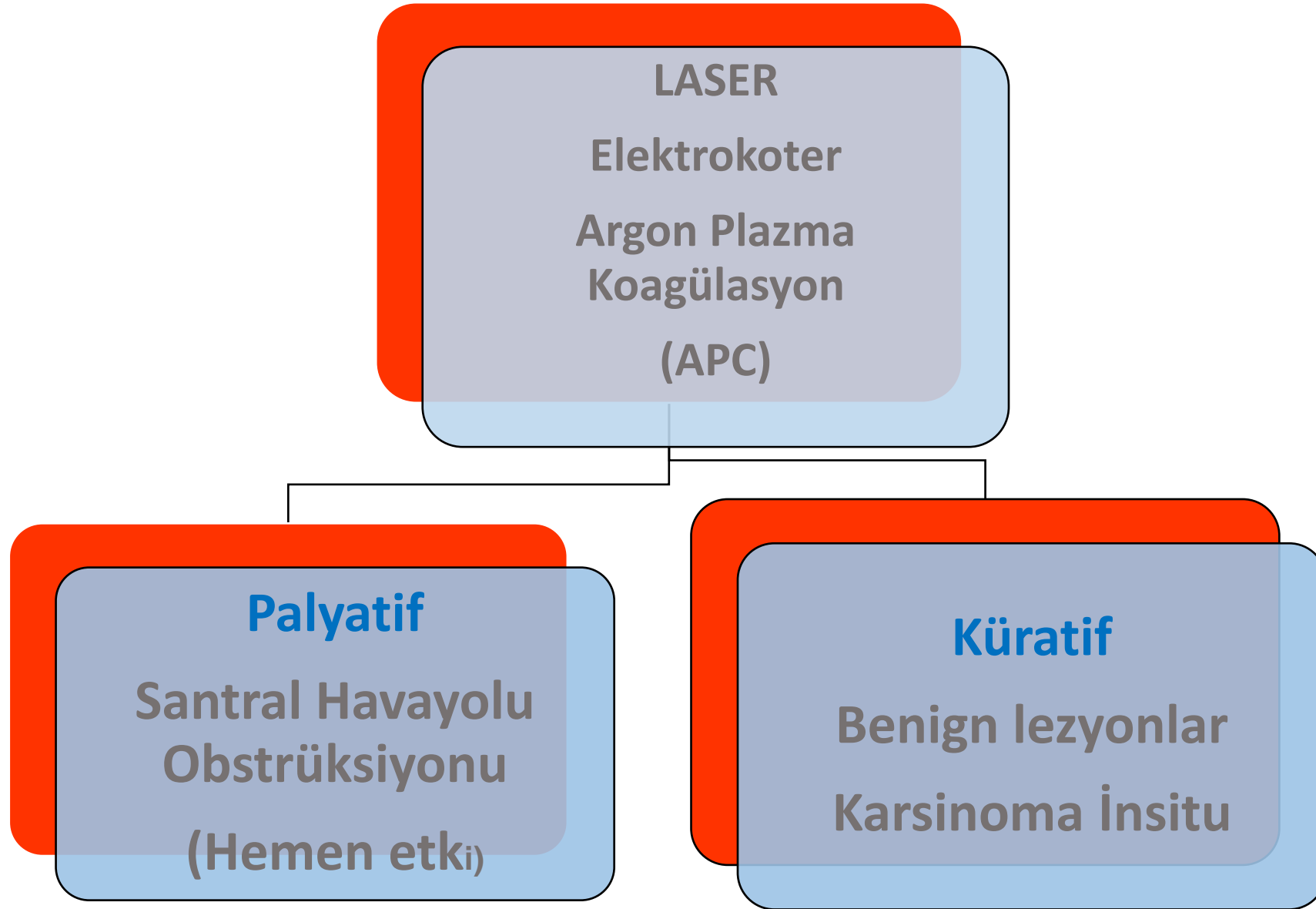
Hava yolu dinamiklerine adaptasyon

Kollateral ventilasyon için bir bronşiyal orifisi açık olarak korumak zorunda olduğunda

Segment rijid bronkoskop ile geçilemediğinde

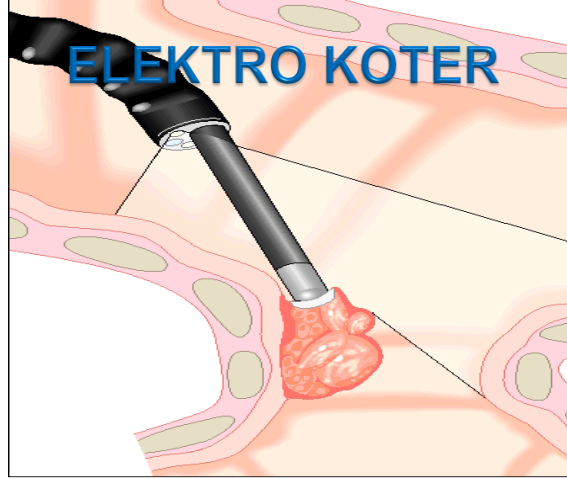


Endobronşiyal sıcak tedavi yöntemleri



ELEKTROKOTER

Koter *kontakt* (*doku teması var*)



► Yüksek frekanslı elektrik akımı

- Koagülasyon
- Kesme
- Vaporizasyon

Endobronşial lezyonların yok edilmesi

- Kanamalı lezyon koagulasyonu
- Erken evre tümör
- Hemoptizi

Semptomlar

Dispne

Nerede,ne kadar darlık var

Stridor 8 mm egzersiz

5 mm istirahat

Bronkodilatöre yanıt vermeyen dispne

Ekstubasyon başarısızlığı

Öksürük

Hemoptizi

Pnömoni

