

HRCT Patterns

(Nodular, Linear, Mosaic)

DR RECEP SAVAŞ

EGE UNIVERSITY, FACULTY OF MEDICINE, DEPT OF RADIOLOGY İZMİR

TÜRKİYƏDƏN HAMINIZA
SALAM VƏ SEVGİLƏRİMİZİ
ÇATDIRIRIQ.

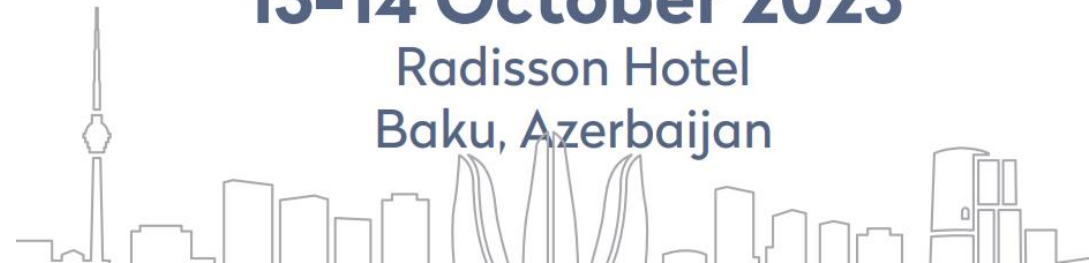

Baku

LUNG HEALTH CONFERENCE

13-14 October 2023

Radisson Hotel
Baku, Azerbaijan



ÖZET:

Bilinmesi gereken anatomik bilgi Yaklaşım yolları ve paternler

- Lineer: İnterstisyel septalar
- Nodüler: Bronşioler, parankimal ve interstisyel olaylar
- Mozaik perfüzyon.

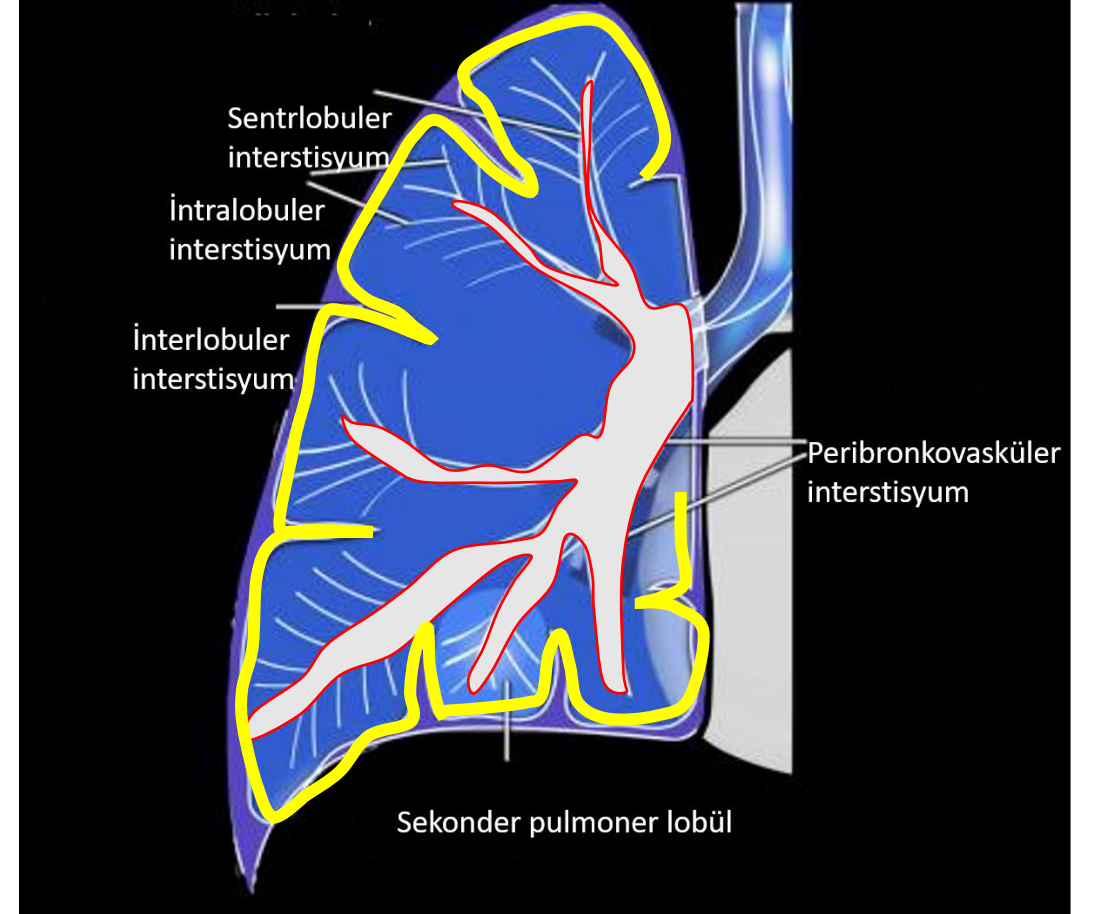
ANATOMİ:

- **İnterstisyum:** Sekonder pulmoner lobül çevresi,
Peribronkovasküler kılıf
- **Parankim:** Alveol

AKCİĞER İNTERSTİSYUMU:

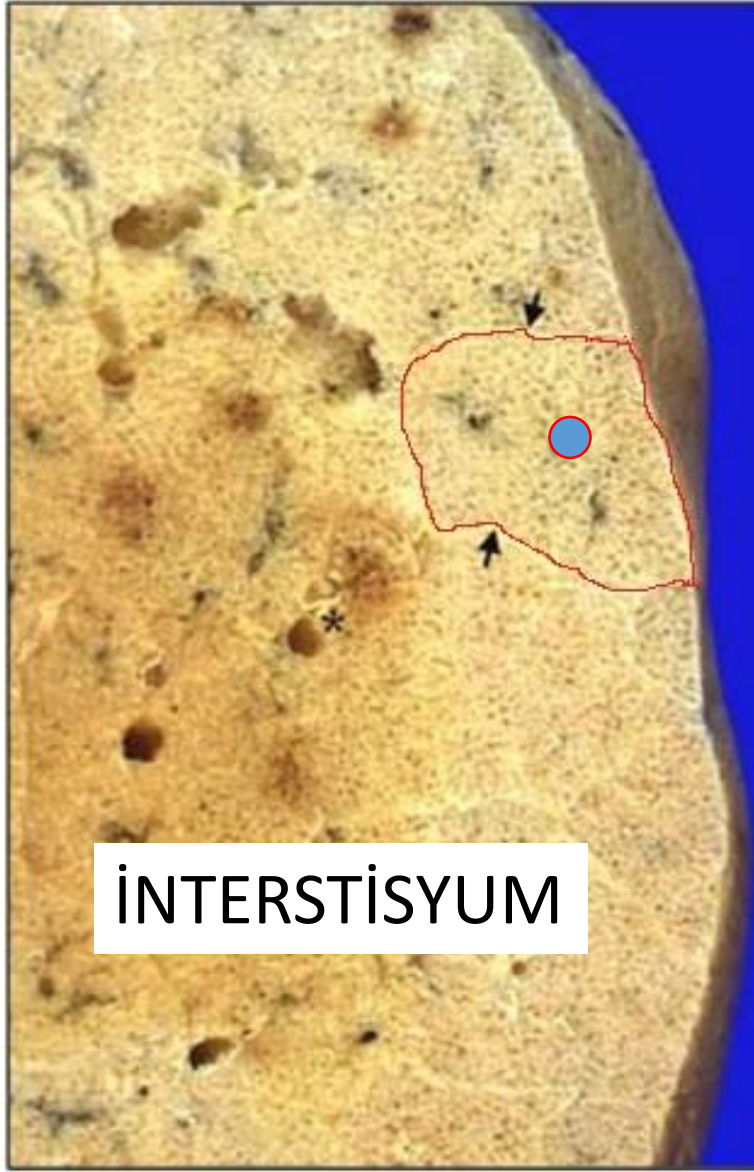
1.Aksiyel : bronkovasküler ağacı çevreleyen-sekonder pulmoner lobülün tam ortasına kadar

2.Periferik: parankimal veya plevraya yakın (sekonder pulmoner lobül çevresi)





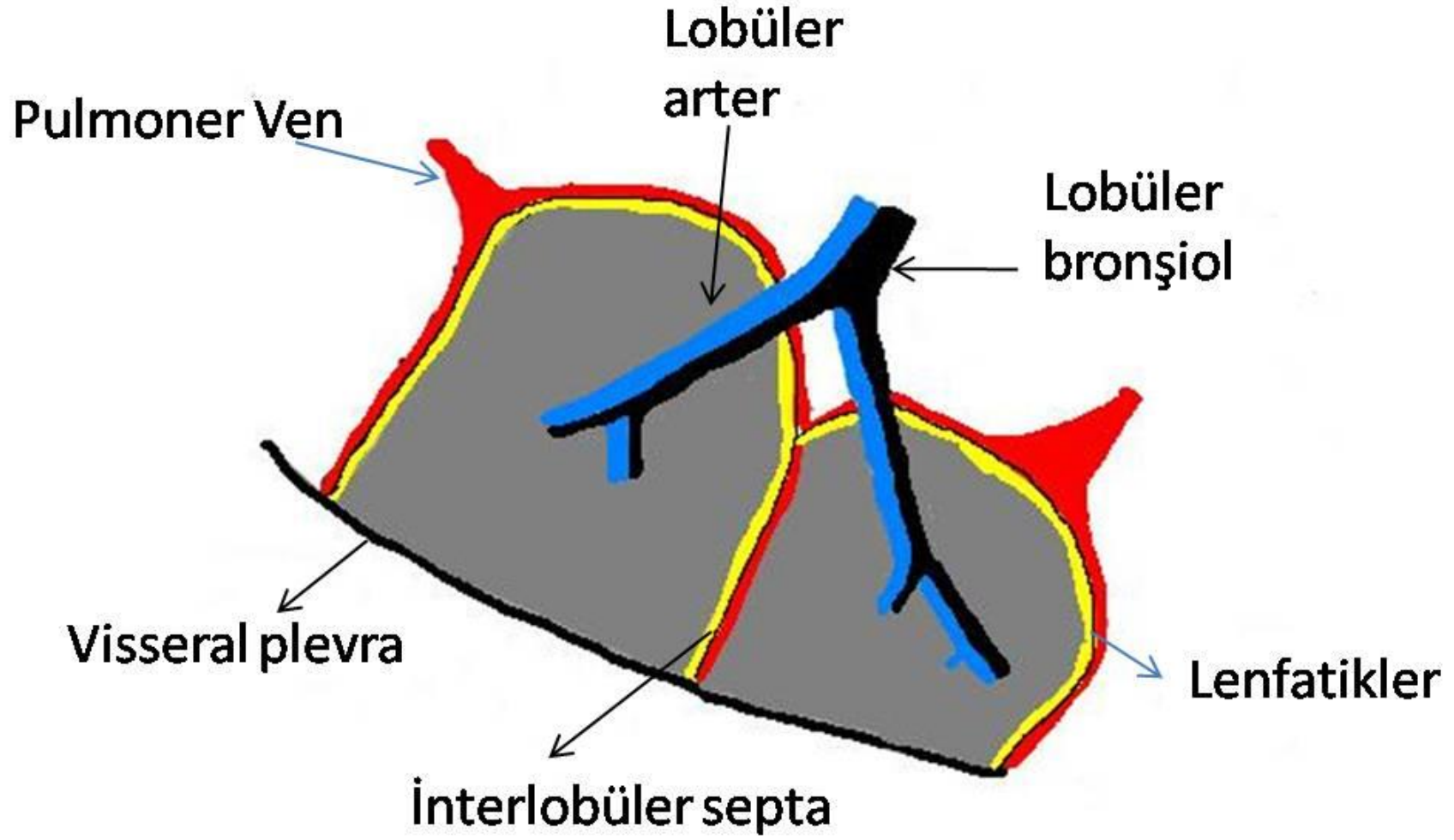


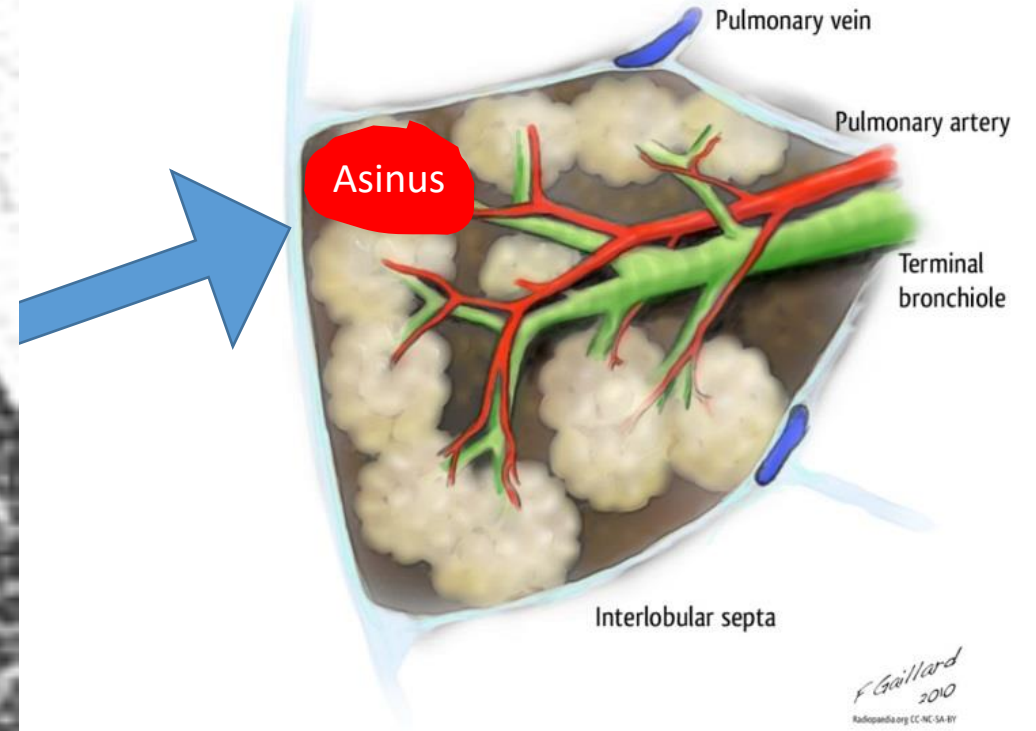
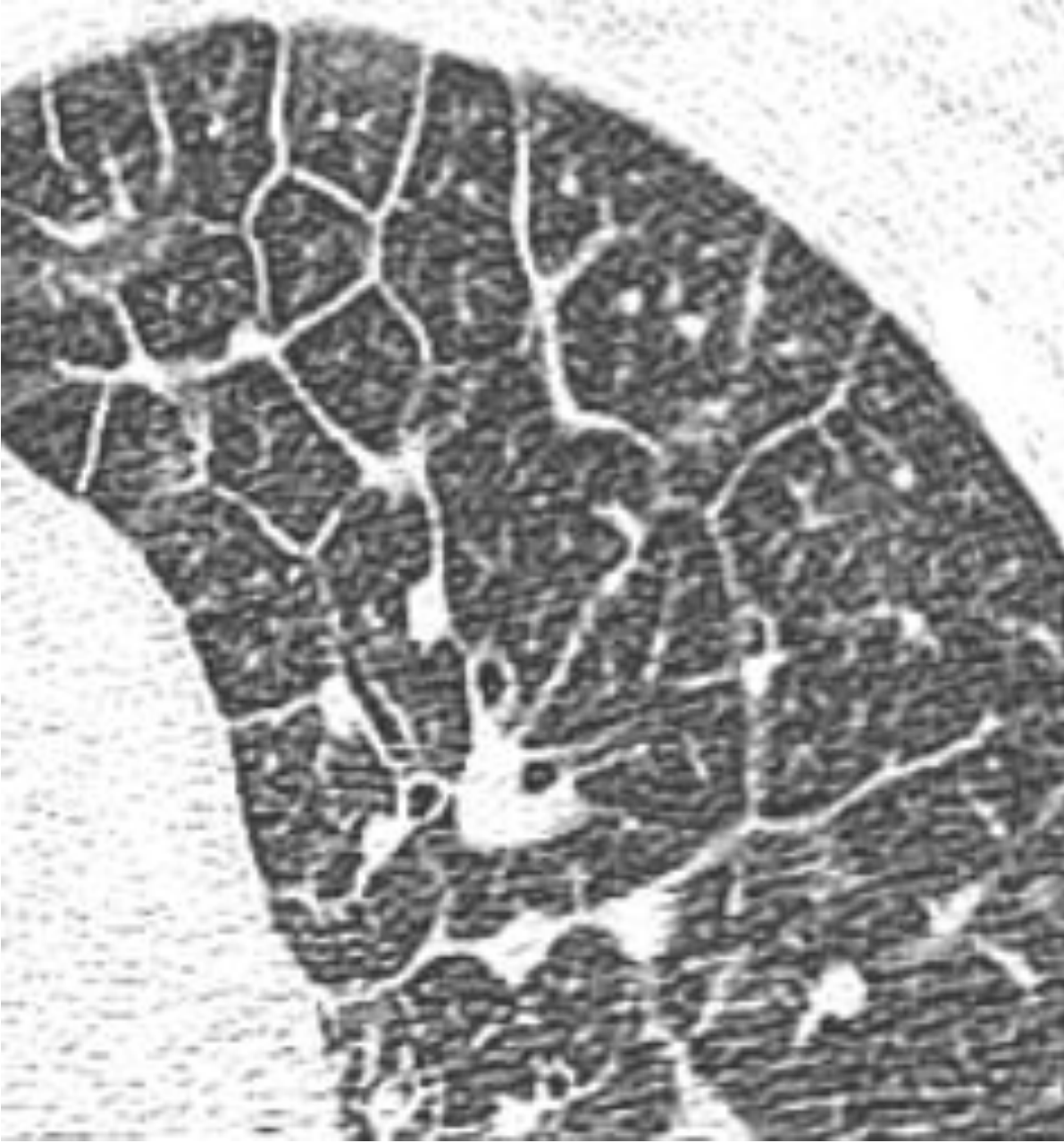


İTERSTİSYUM

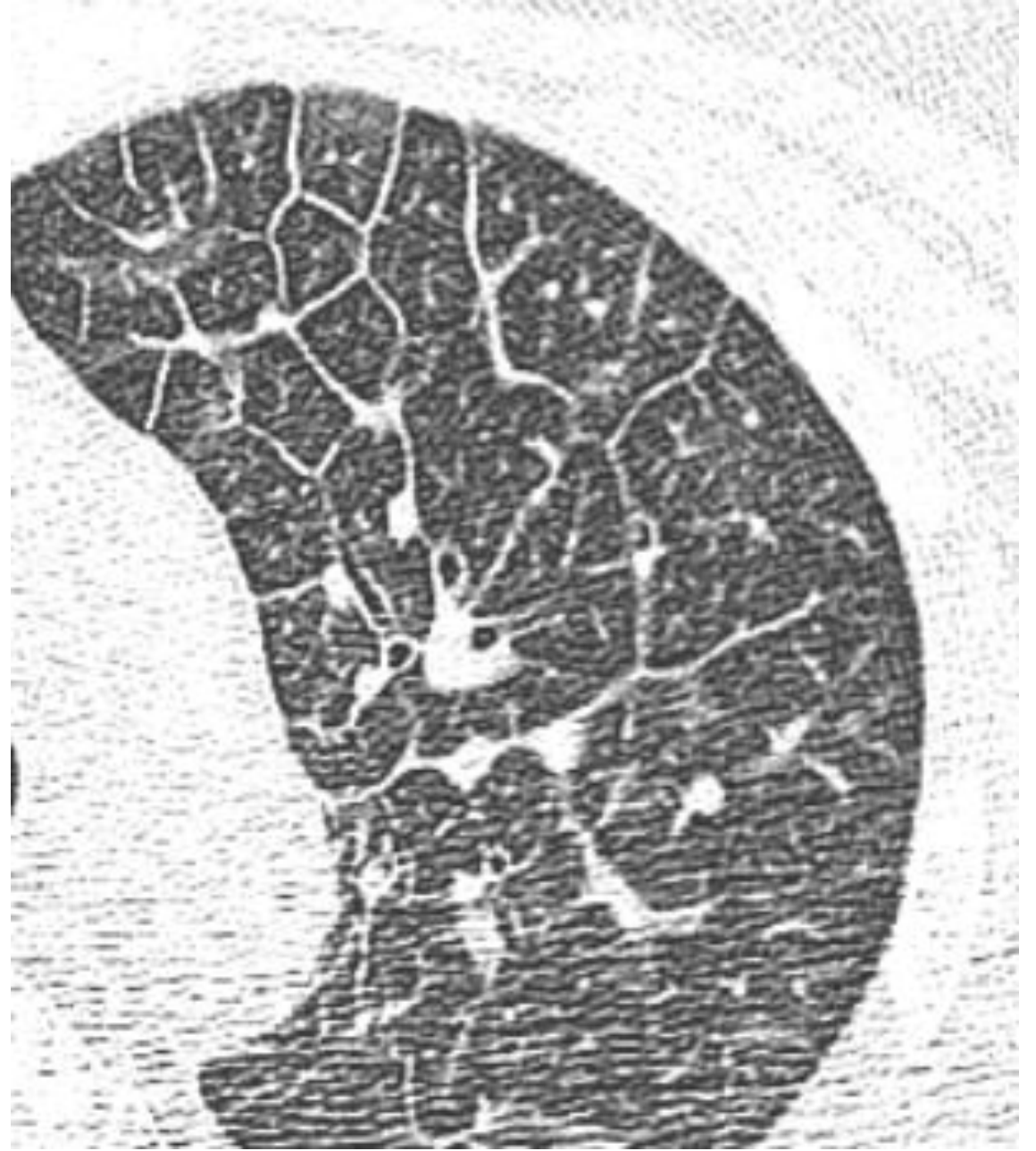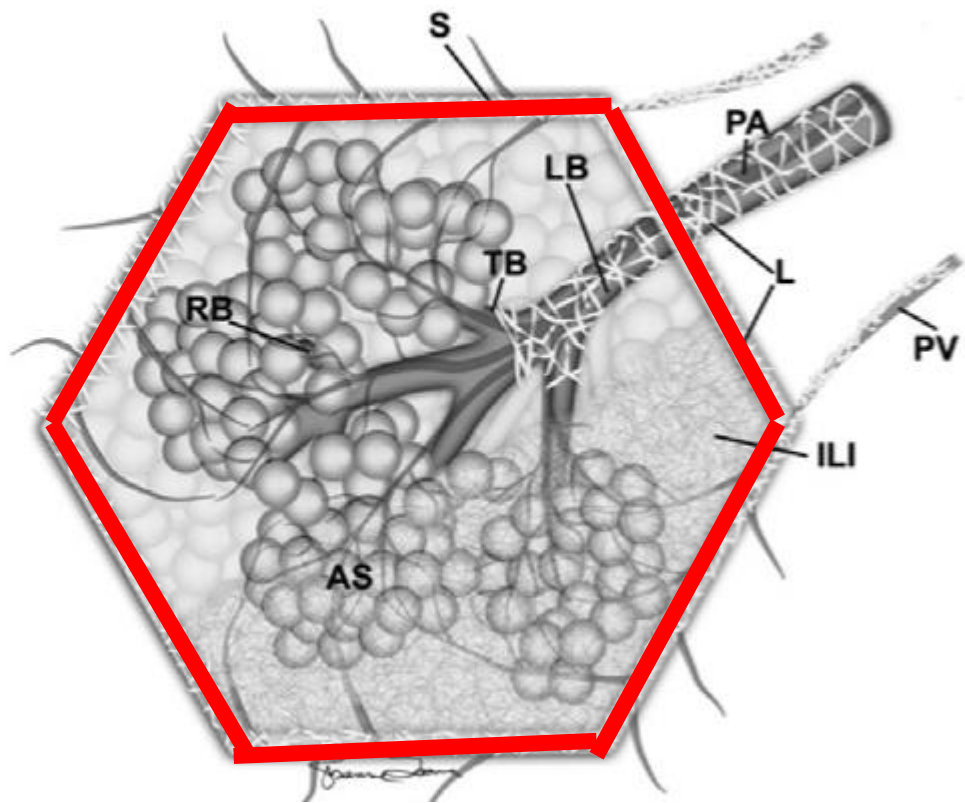


PARANKİM

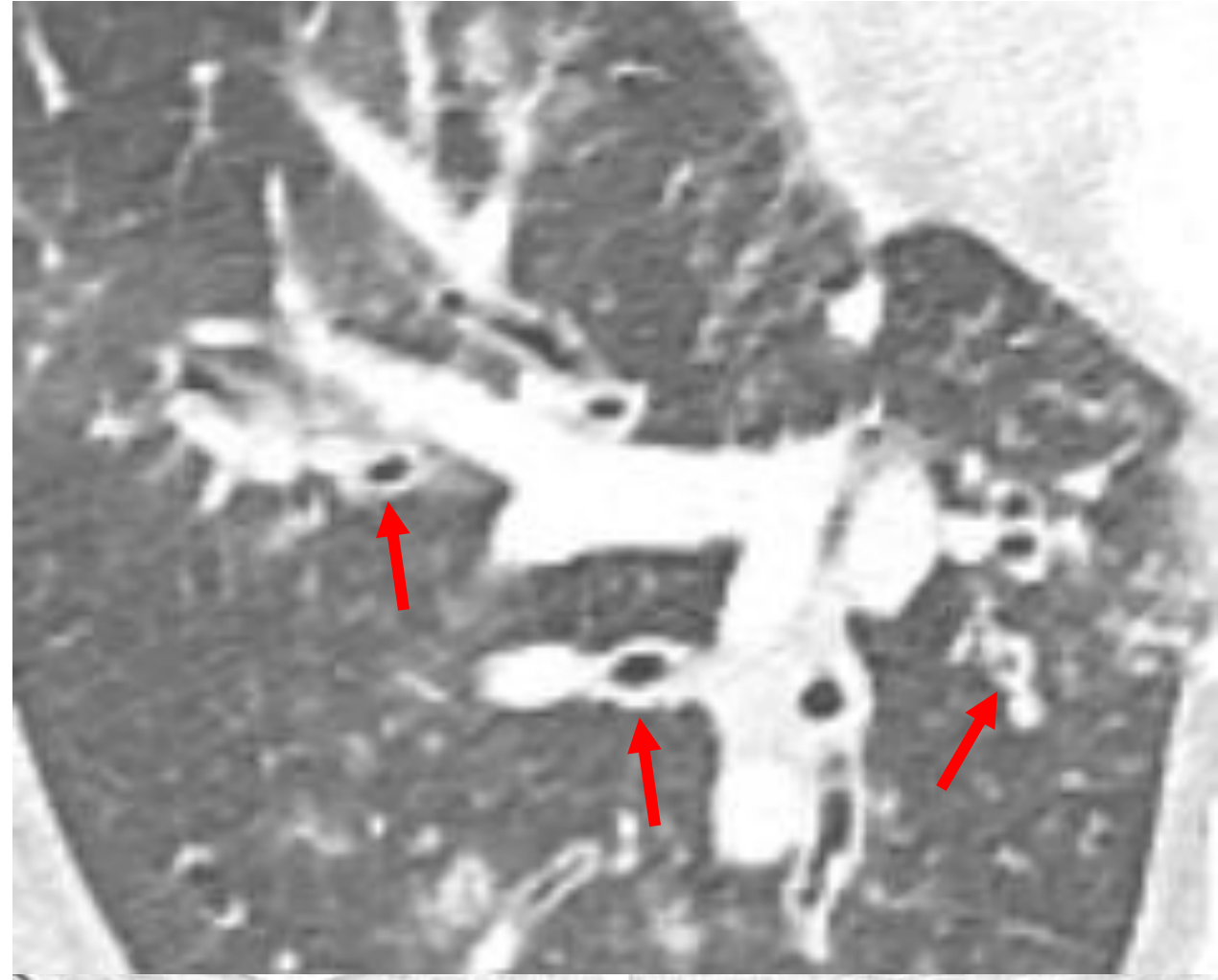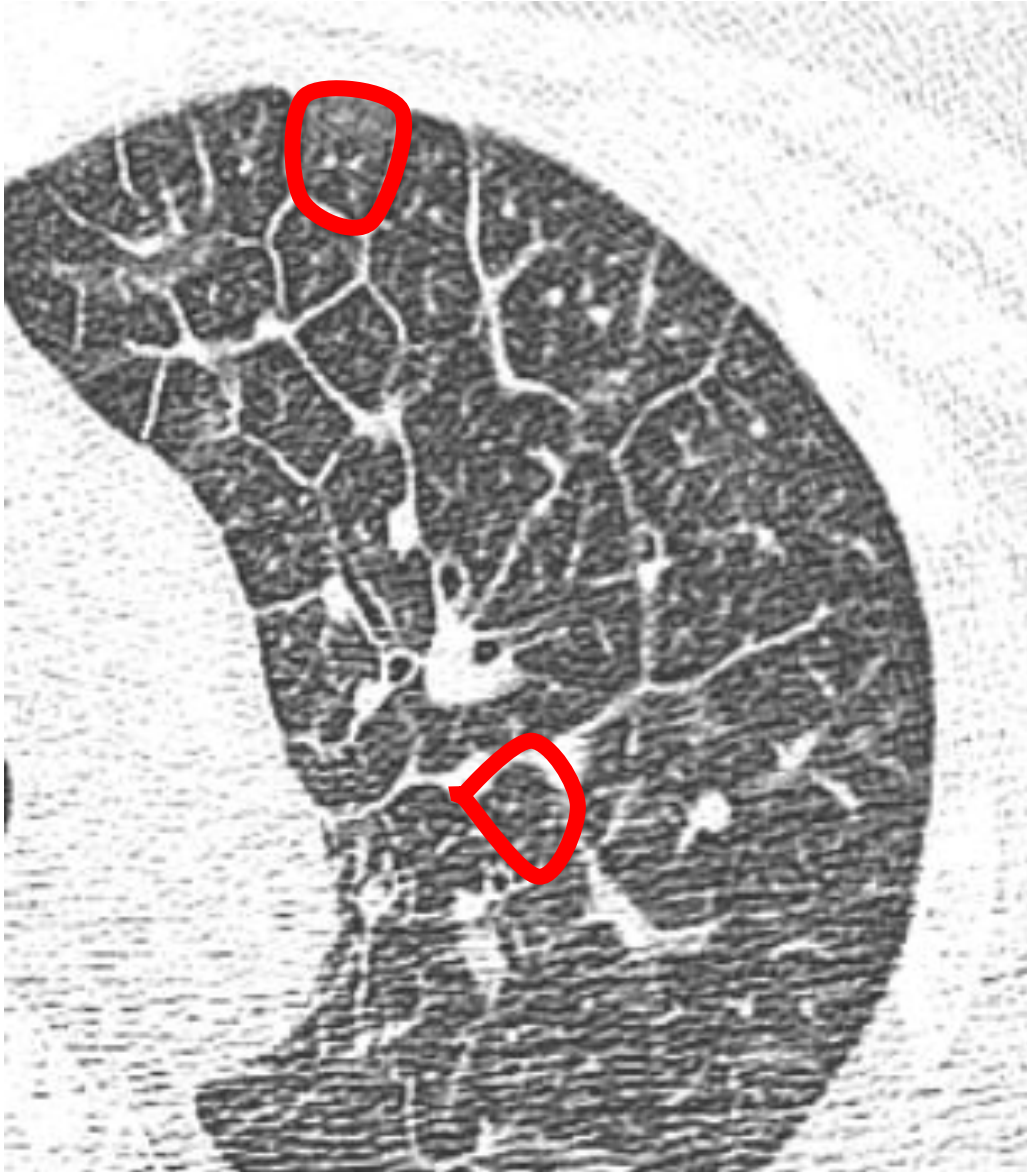


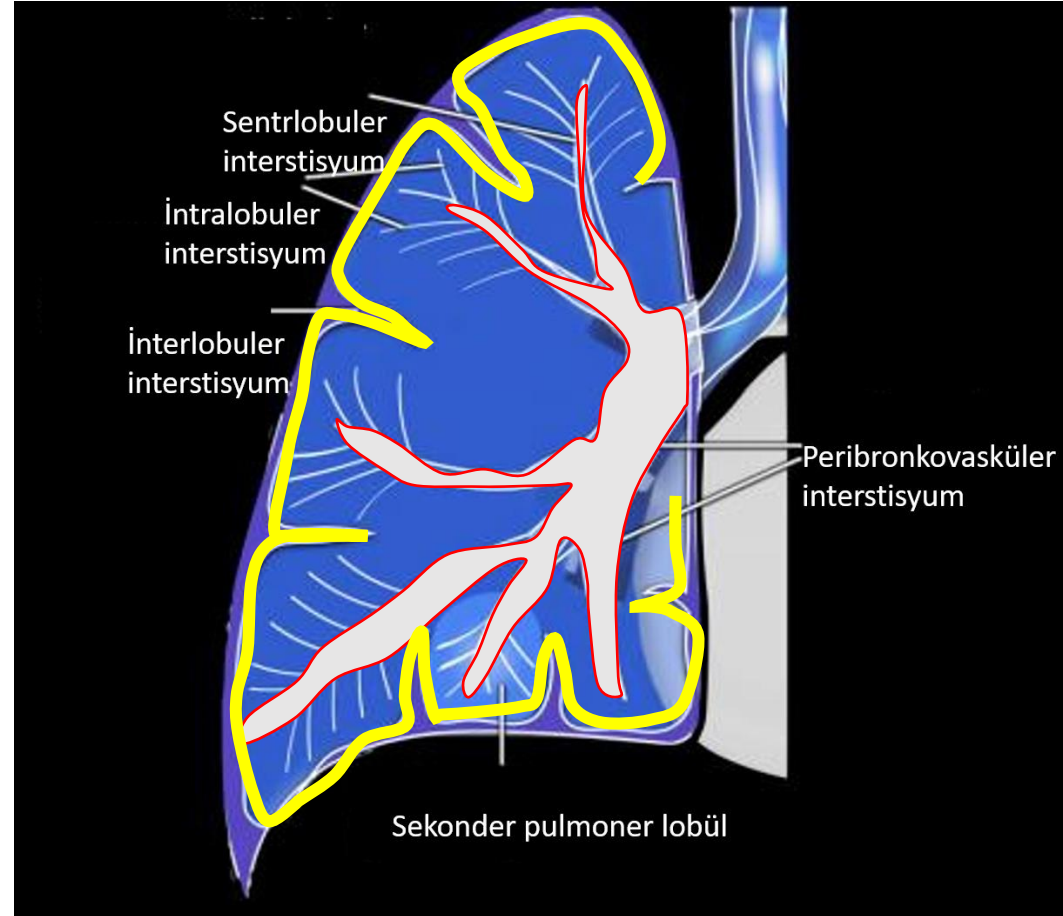


SEKONDER PULMONER LOBUL
1-2 cm çaplı

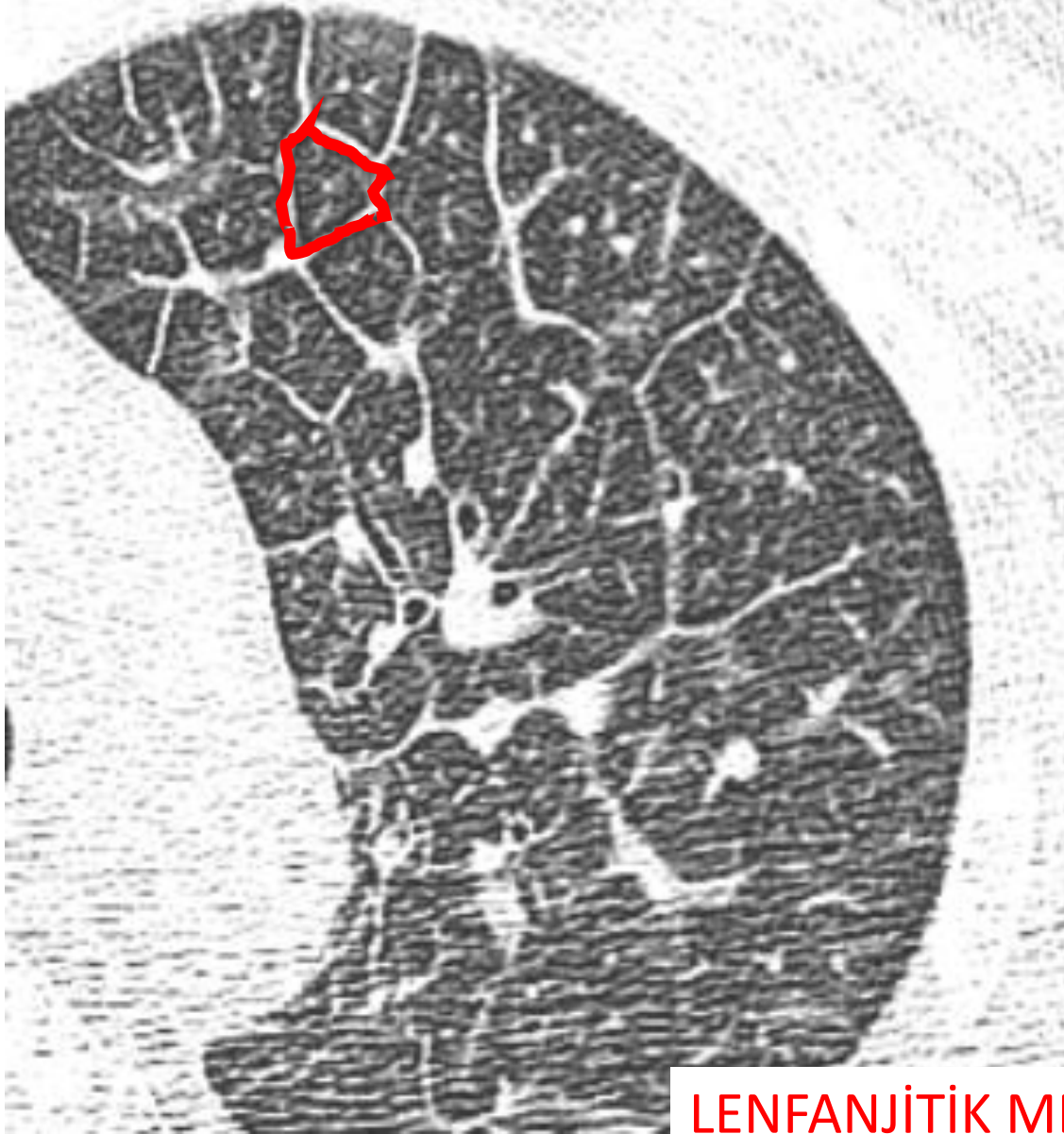


İNTERSTİSYUM





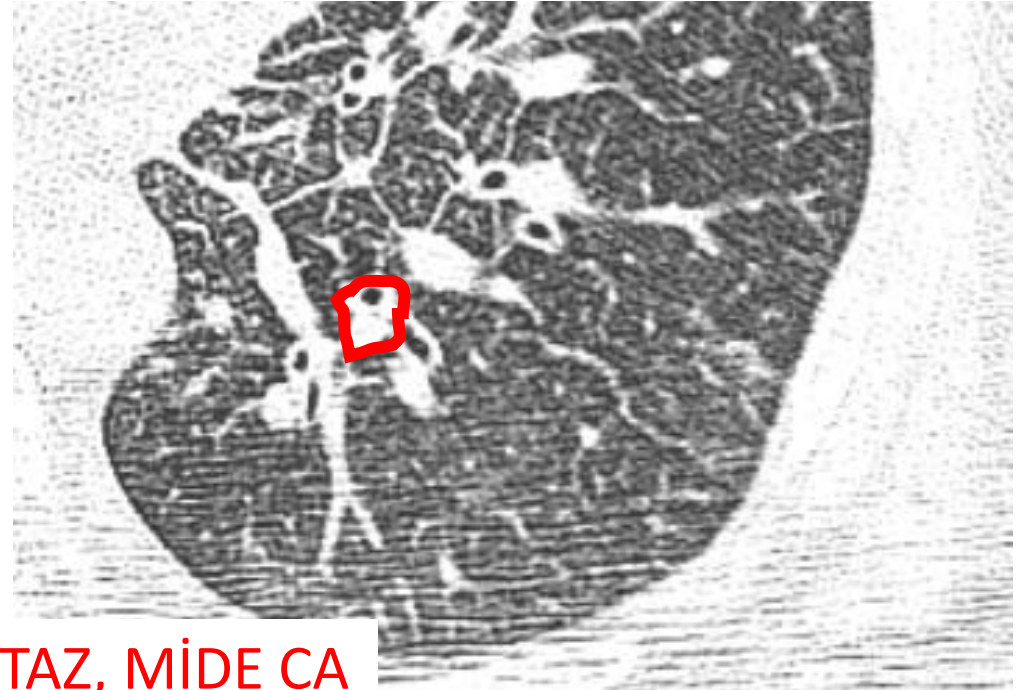İTERLOBULER SEPTAL KALINLAŞMA



LENFANJİTİK METASTAZ, MİDE CA



PERİBRONKOVASKÜLER KALINLAŞMA



ALVEOL

- Normalde BT ile görülmez.
- Alvolun etkilendiđi olaylarda karşımıza iki farklı durum ortaya çıkar:

Buzlu cam veya konsolidasyon

BAŞLICA PATERNLER :

- Buzlu cam
- Konsolidasyon

- Nodül
- Retikülasyon
- Septal kalınlaşma



NODÜLER

LİNEER

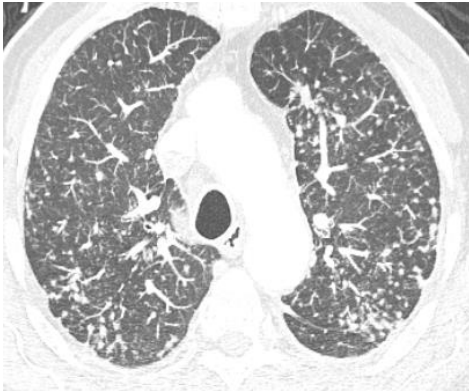NODÜL/ NODÜLER PATERN

- Akciğerde 3 cm ve daha küçük yuvarlak opasitelere nodül denir.
- Nodüler patern ise akciğerde parankimde veya interstisyumda yerleşen her iki akciğerde yaygın tutulum yapan nodülleri belirtmektedir.

NODÜLER PATERN

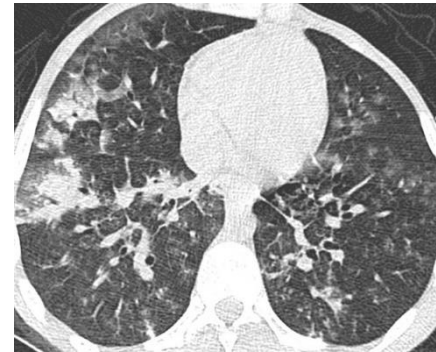İNTERSTİSYEL

- İyi sınırlı
- Sekonder pulmoner lobül ile ilişkili (içinde veya çevresinde)
- İnterstisyel hastalıklarda



HAVAYOLU

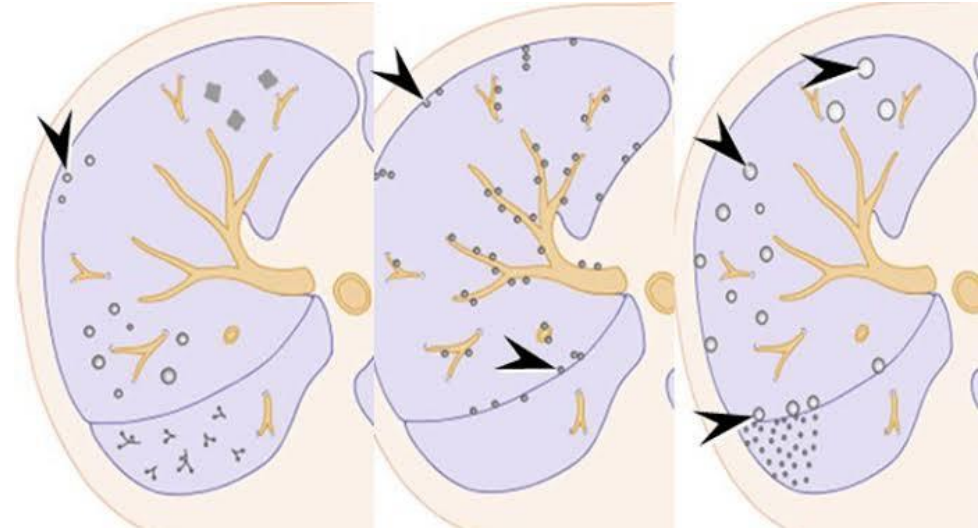
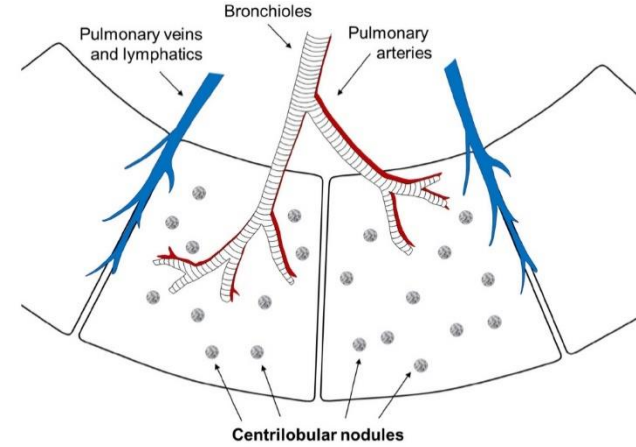
- Sınırları flu
- Tüm sekonder pulmoner lobülü dolduran
- Daha çok bronkopnömoni, pnömoni, aspirasyon,



İNTERSTİSYEL NODÜLER PATERN

Sekonder pulmoner lobülün yerleşimine göre:

- Perilenfatik
- Sentrlobüler
- Rastgele

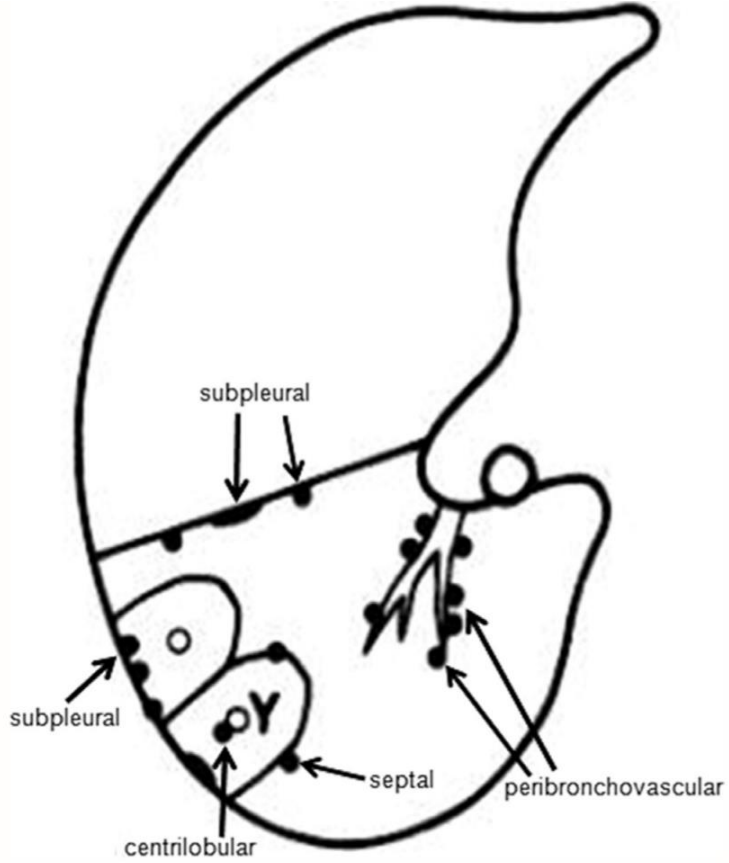


Sentrlobüler

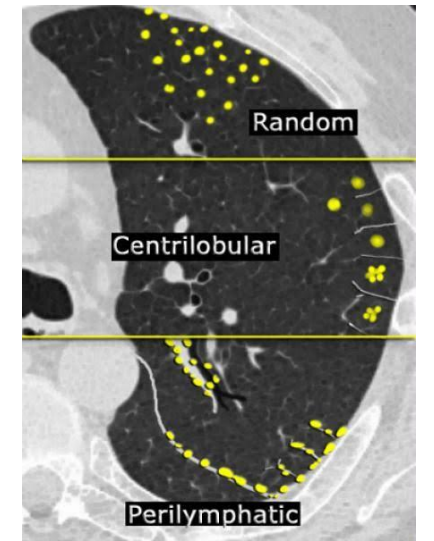
Perilenfatik

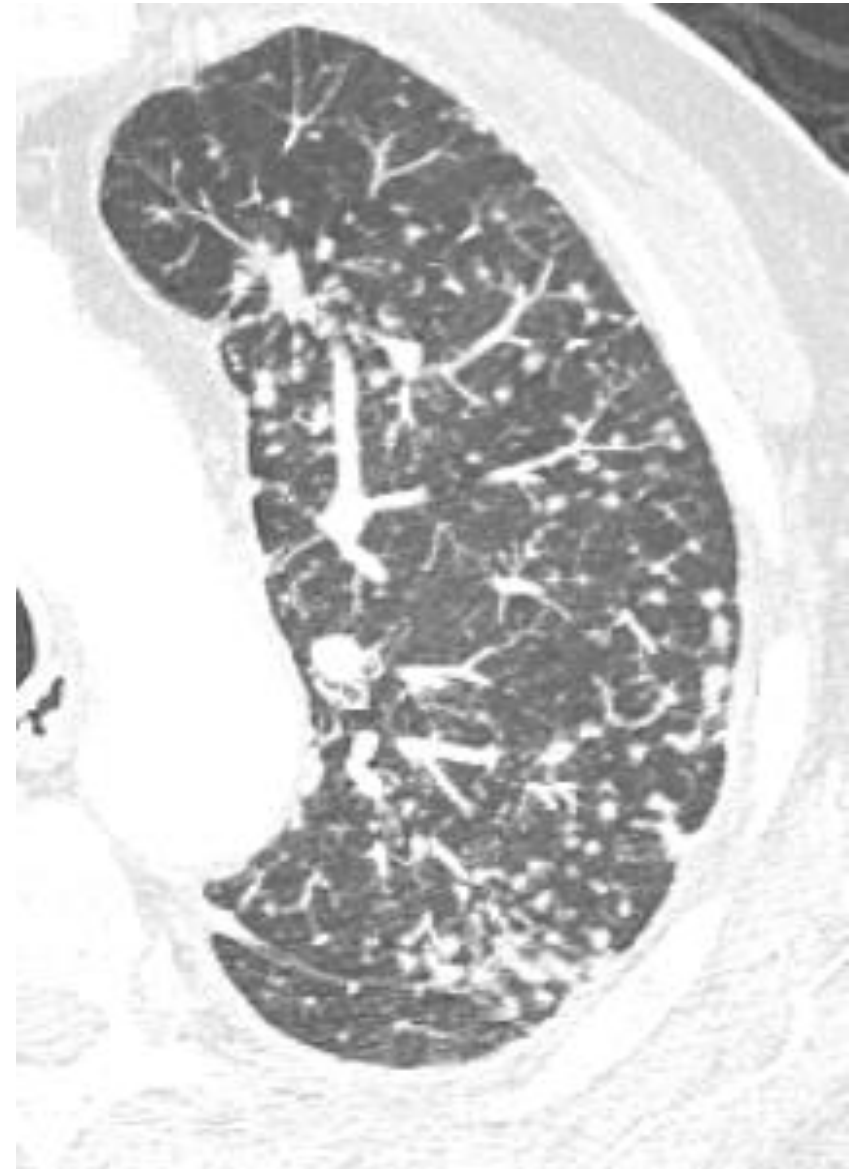
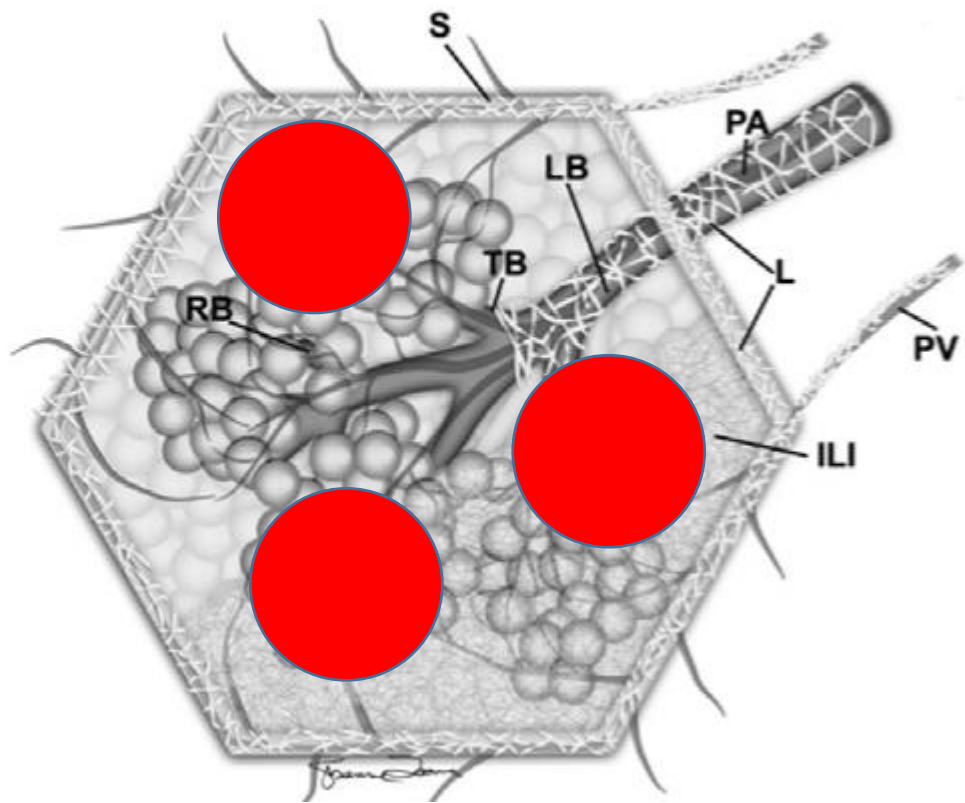
Rastgele

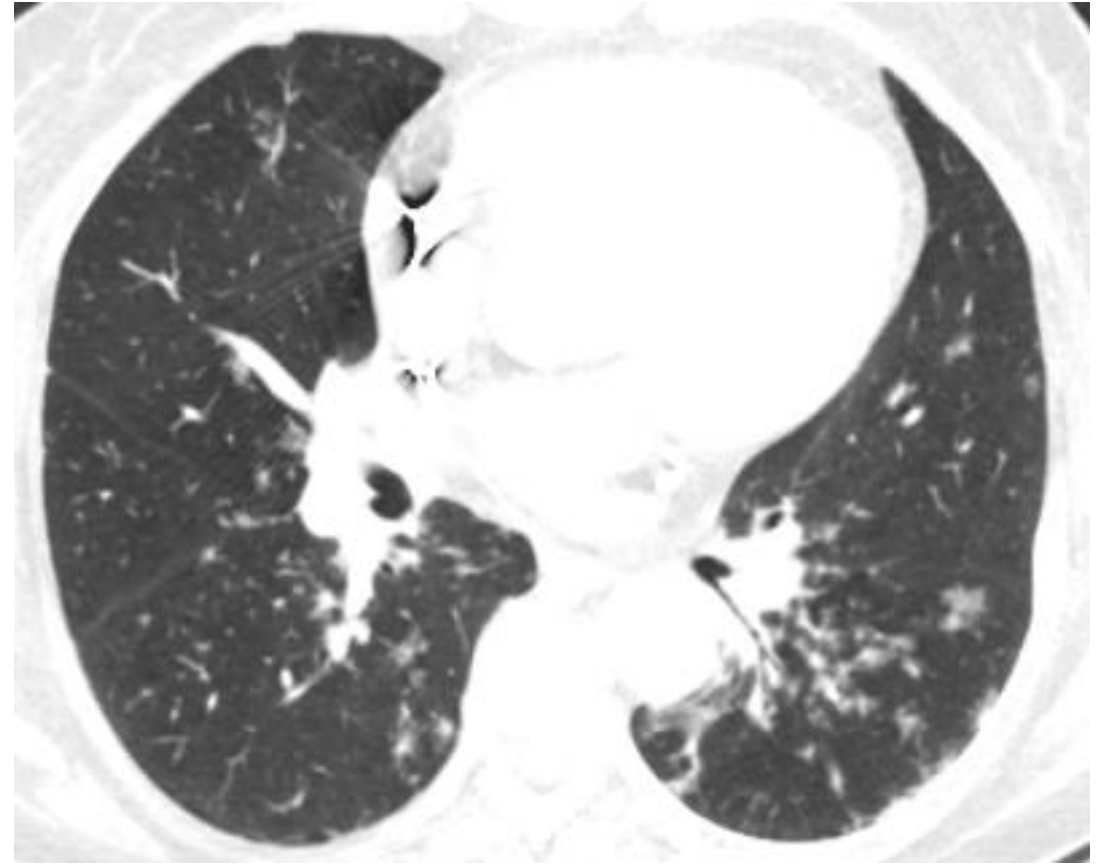
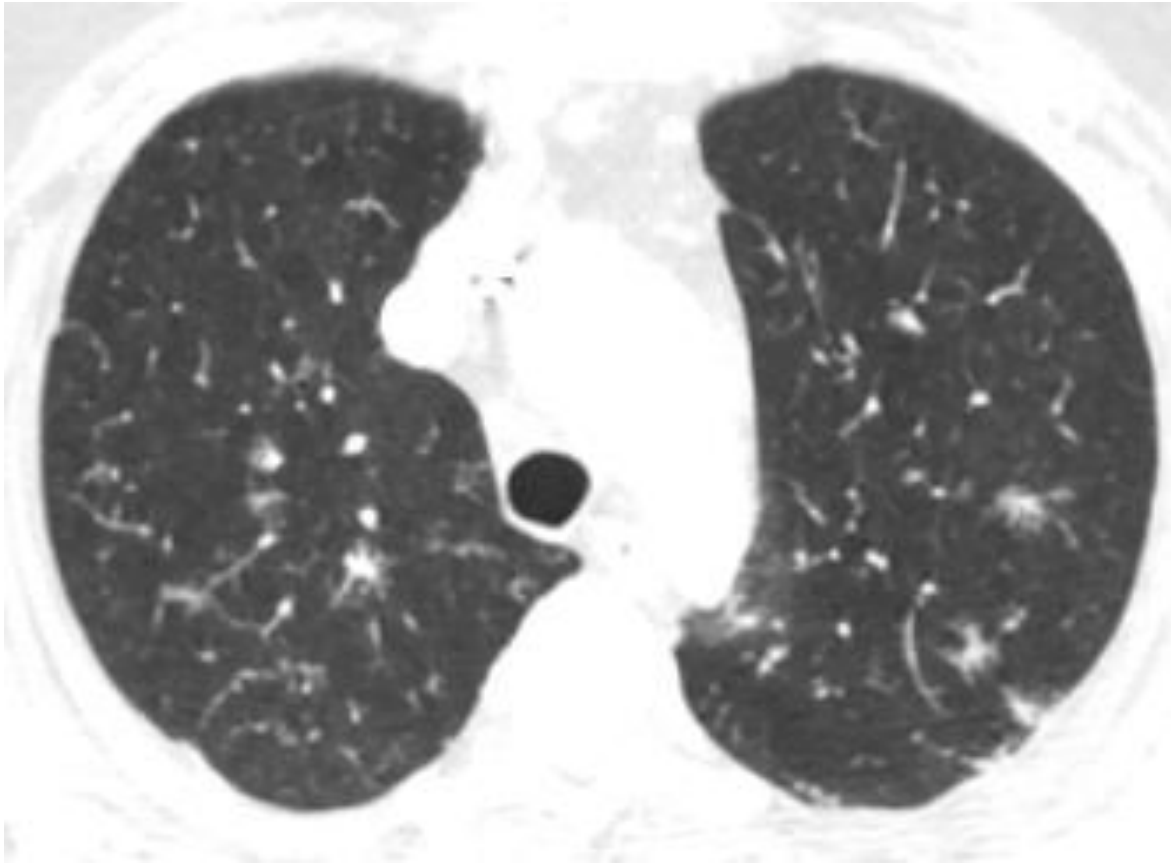
PERİLENFATİK NODÜLLER



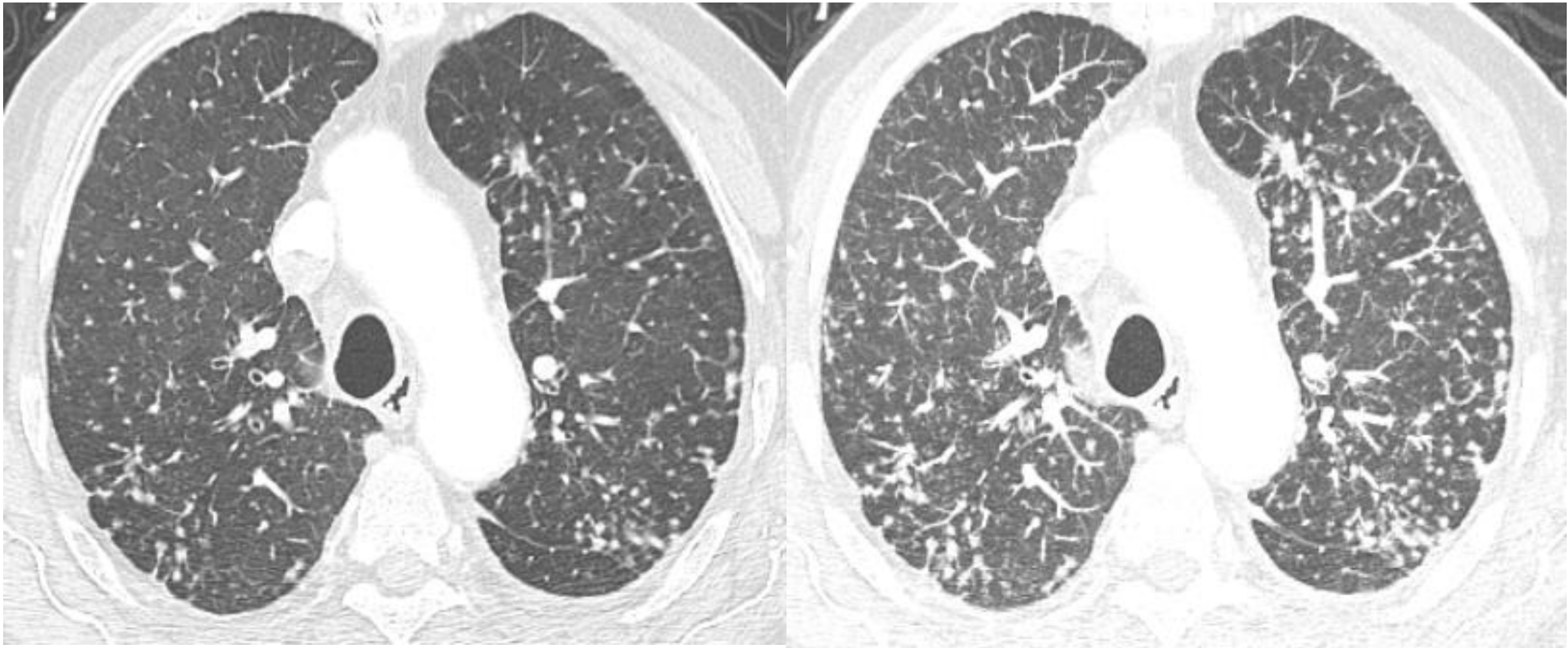
- Sarkoidoz
- Silikozis
- Kömür işçisi pnömokonyozu
- Lenfanjitik metastaz
- Nodüler amiloidozis
- LİP







SARKOIDOZIS

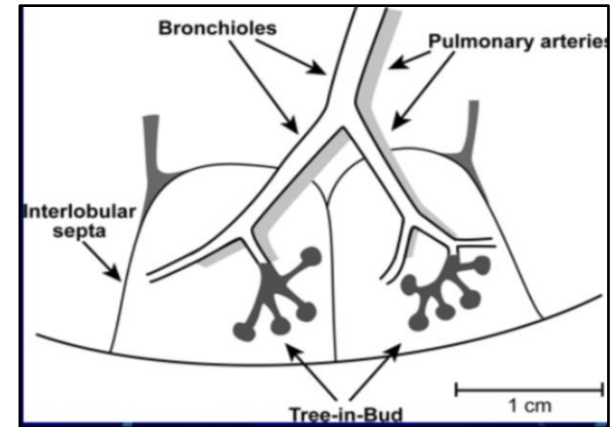
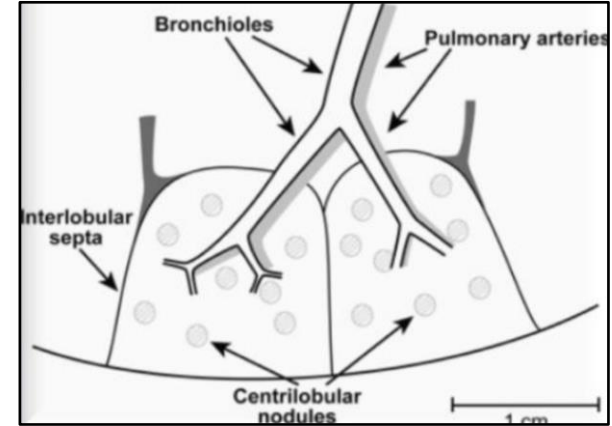


SİLİKOZİS

Sentrlobüler nodüller

- İki farklı tip:
 - Düzgün konturlu
 - Rozet şeklinde (tomurcuklanan ağaç görünümü)

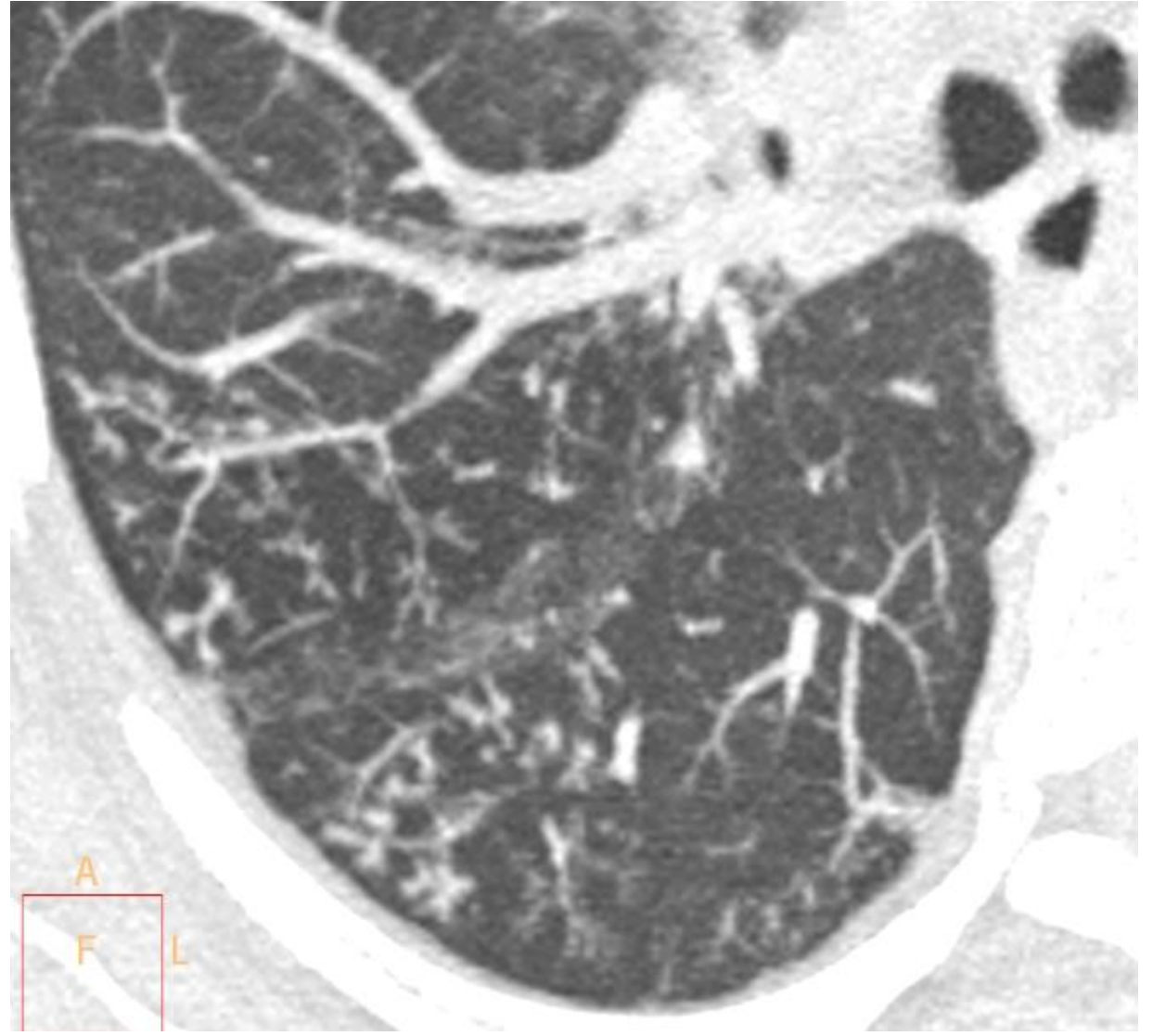
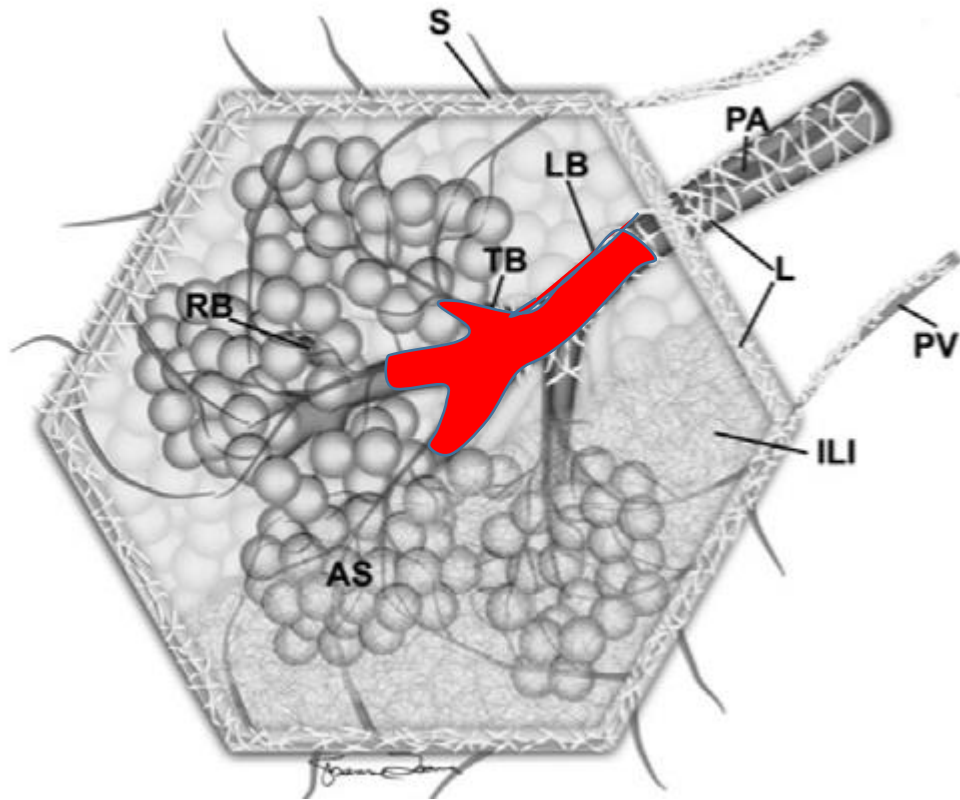
FİSSÜR, PLEVRAL YÜZEY VE İTERLOBÜLER SEPTALARDAN EN AZ 5 MM UZAKTA!

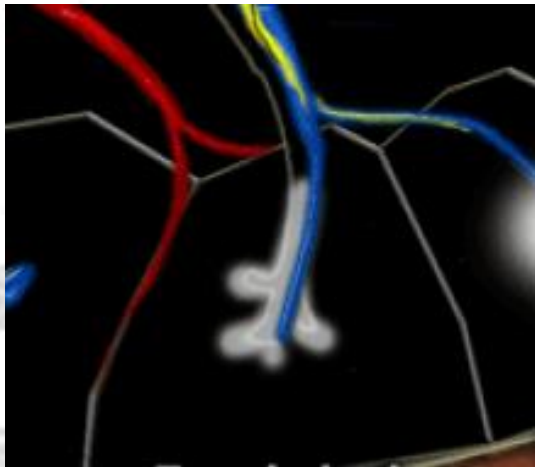
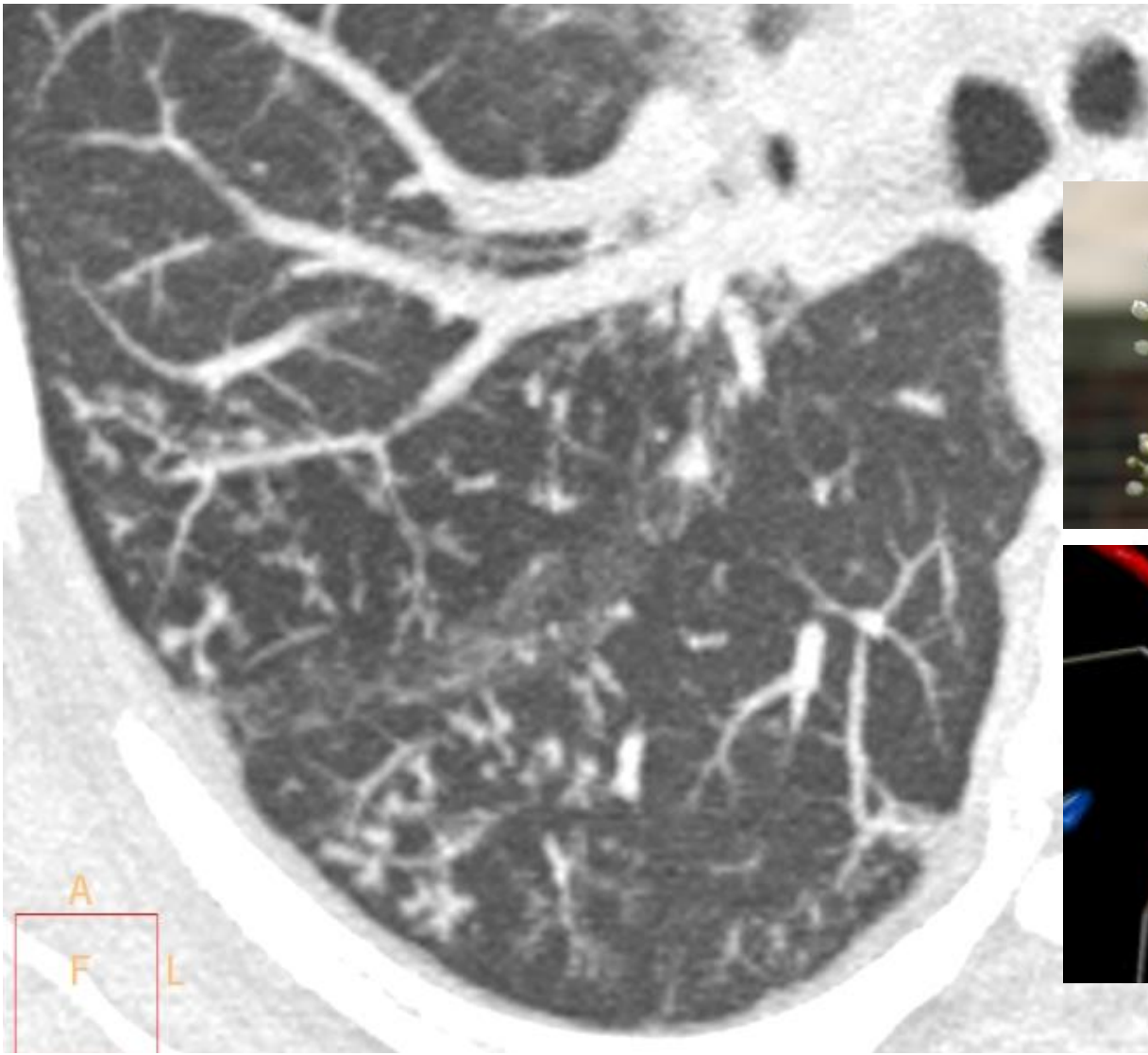


Sentrlobüler nodüller

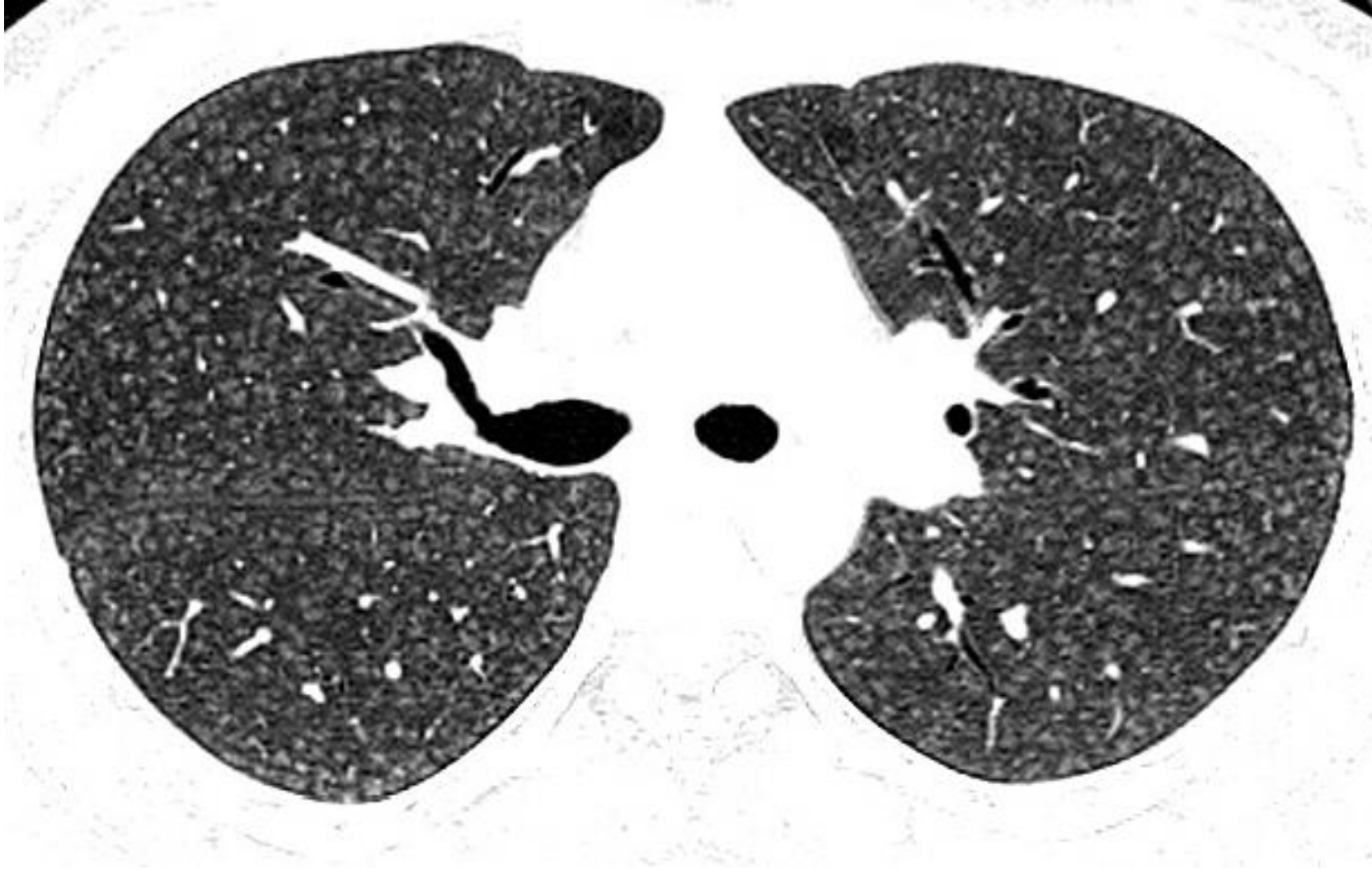- Endobronşial yayımlı enfeksiyon
- Hava yolu hastalıkları
- Panbronşiolit
- ABPA
- Hipersensitivite pnömonisi
- LHH
- OP
- Bronşiolitis obliterans
- Respiratuar bronşiolit
- Metastatik kalsifikasyon
- Trombotik mikroanjiopati

DÜZROZET ŞEKLİNDE SENTRLOBULER NODÜLLER

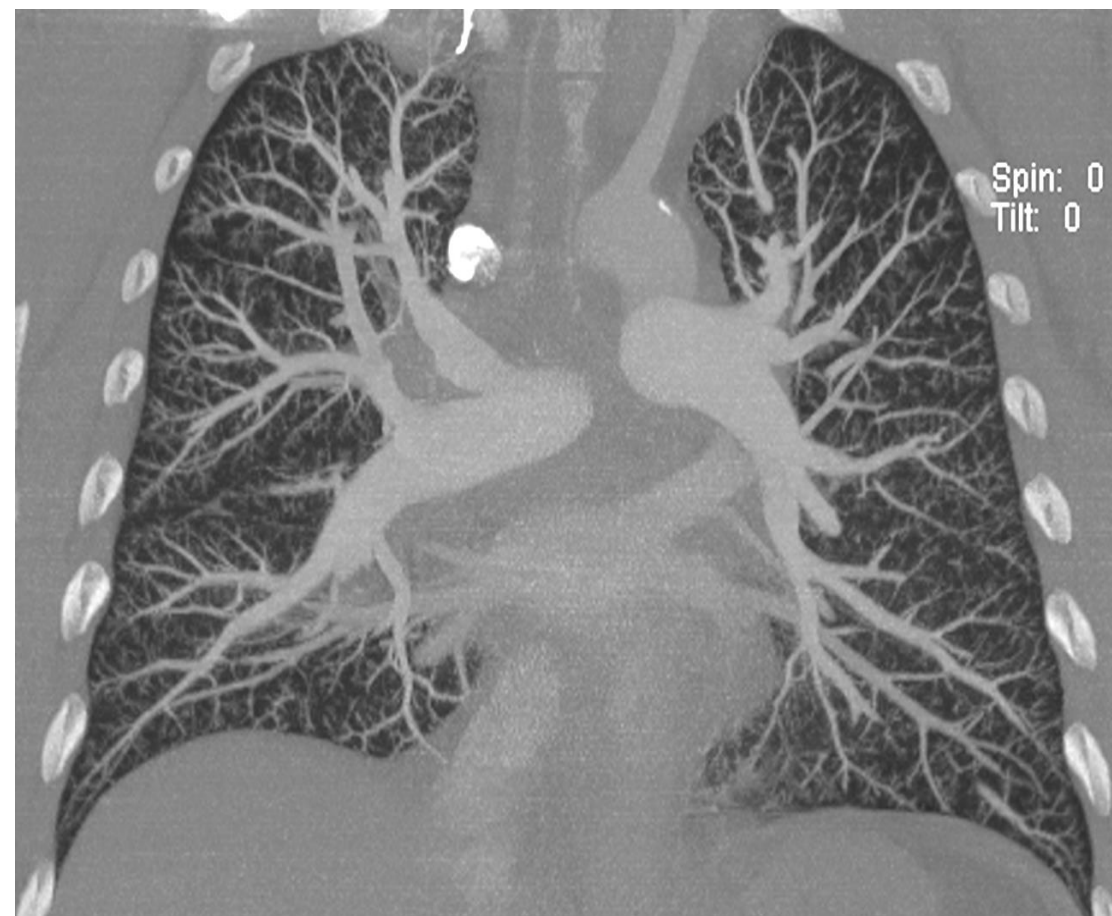
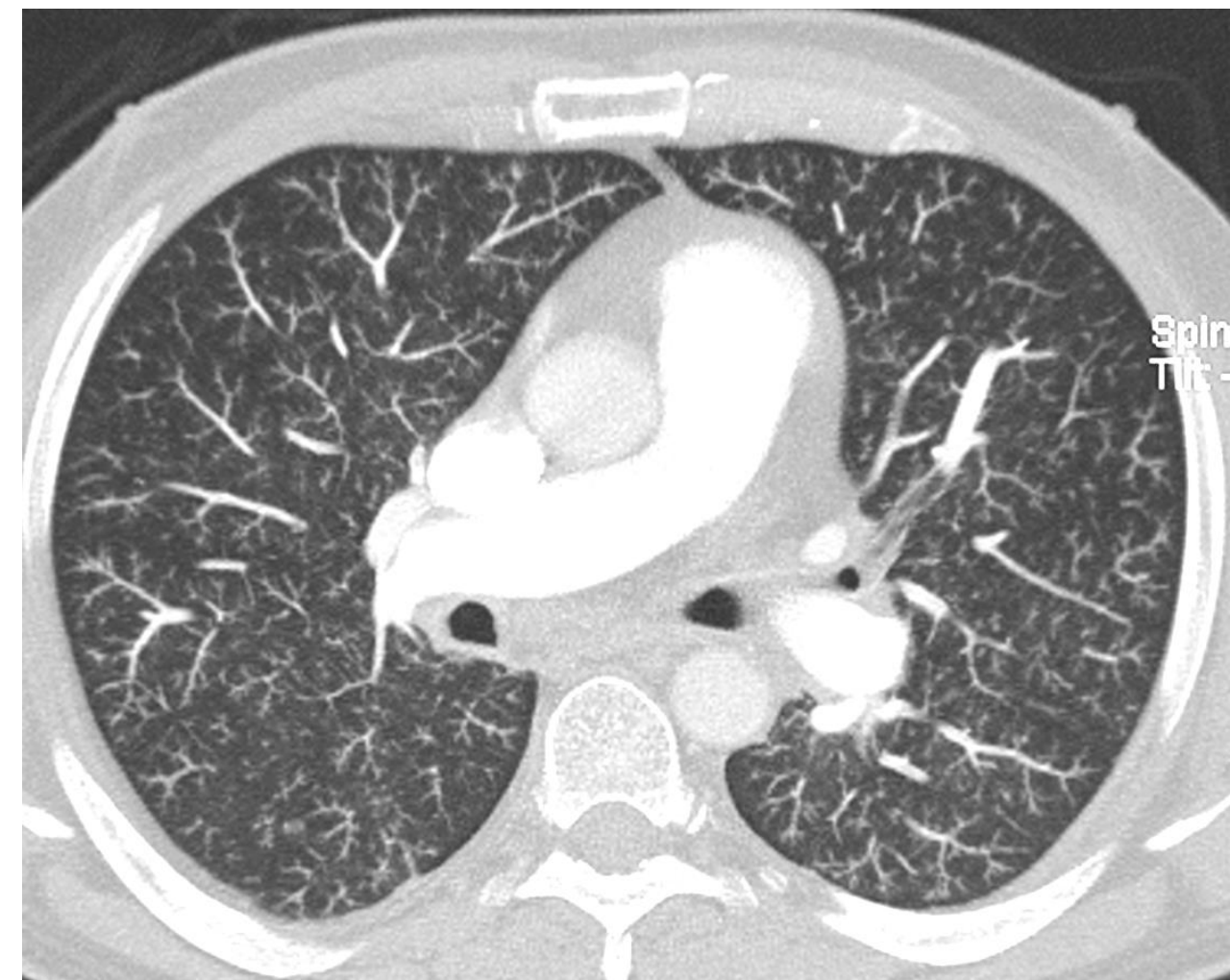




DÜZGÜN KONTURLU SENTRLOBULER NODÜLLER



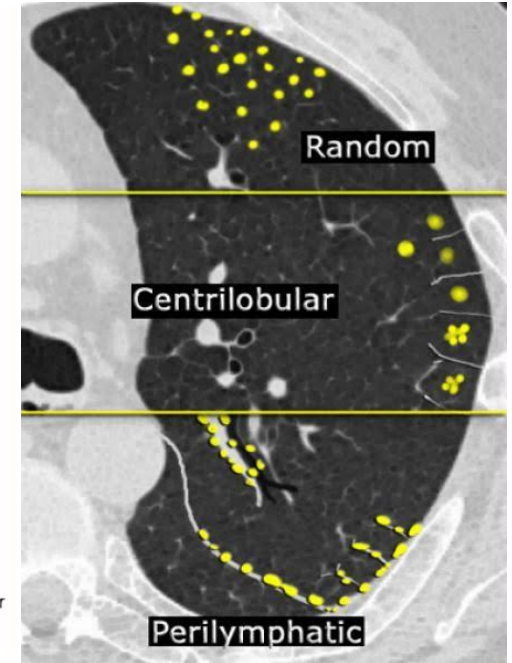
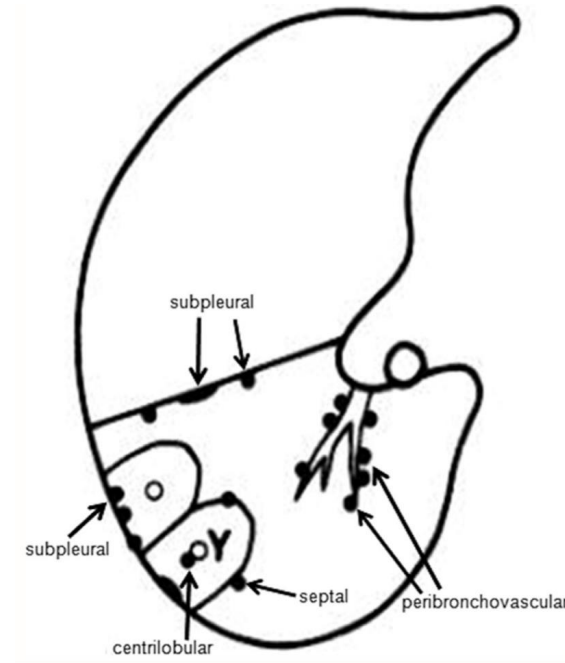
HİPERSENSİTİVİTE PNÖMONİSİ

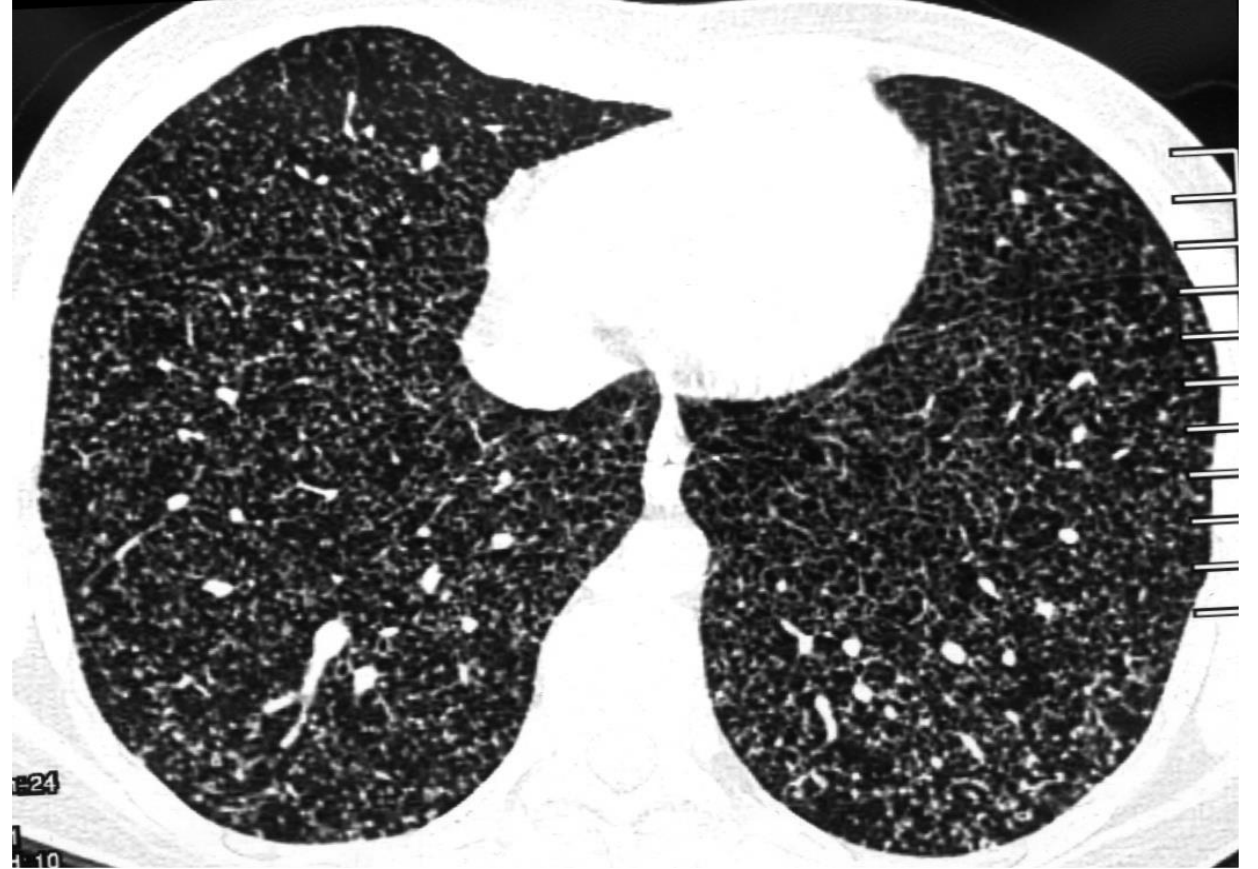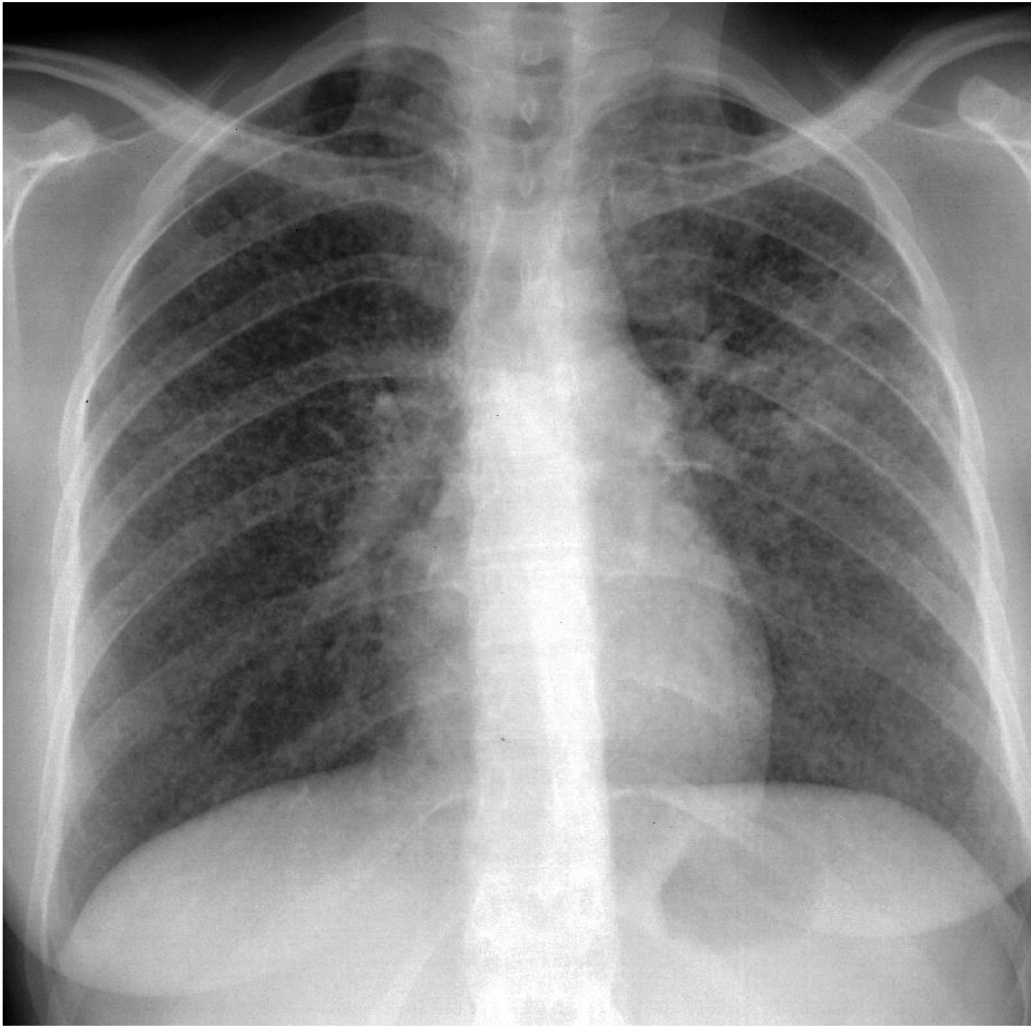


Mide ca, trombotik mikroanjiopati

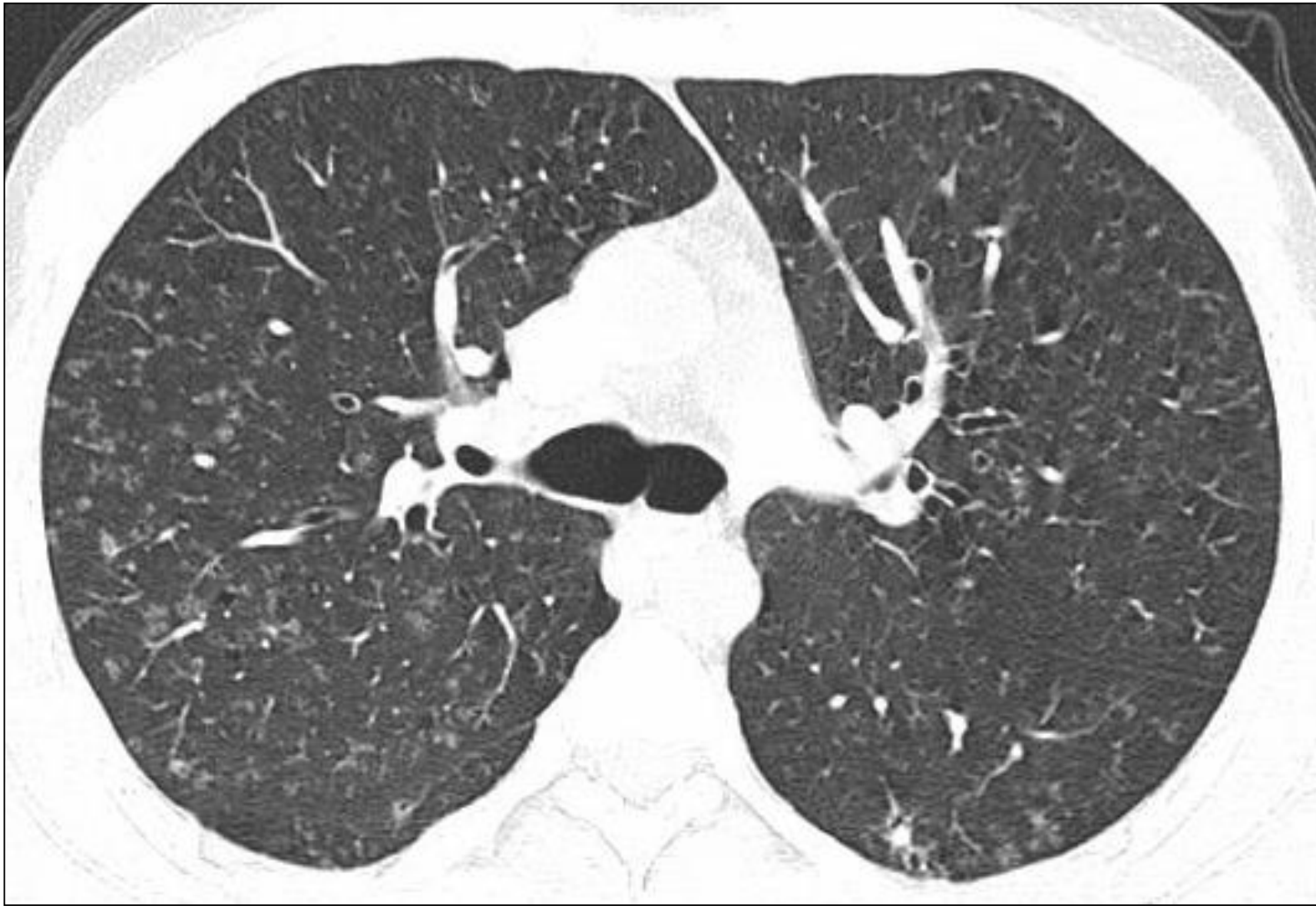Rastgele dağılımlı nodüller

- Miliyer enfeksiyon
- Hematojen metastaz
- LHH
- Sarkoidozis
- Adenokanser





MİLİYER TÜBERKÜLOZ






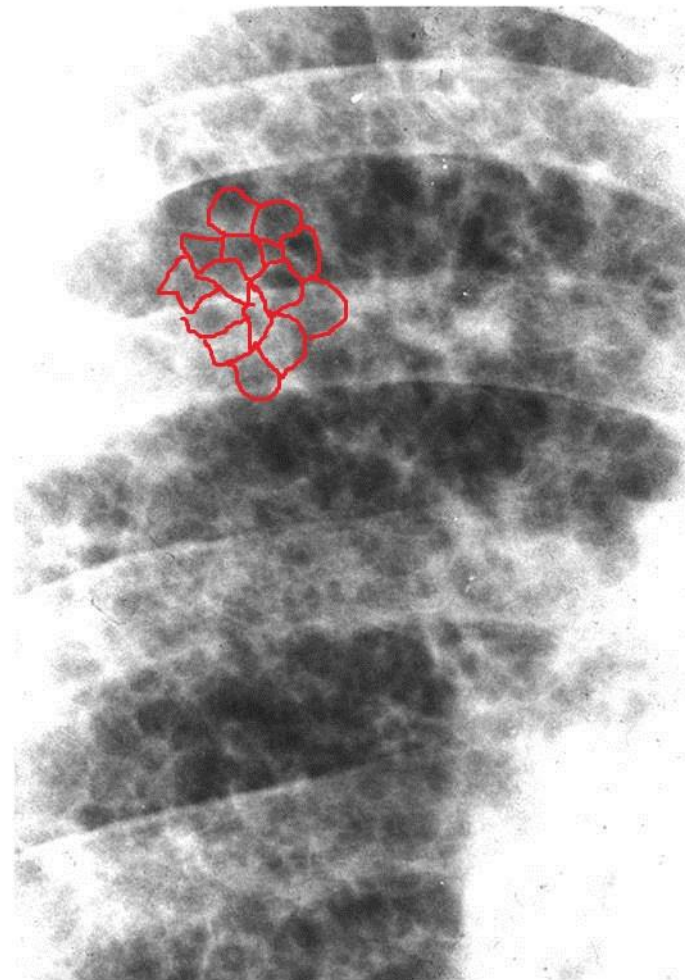
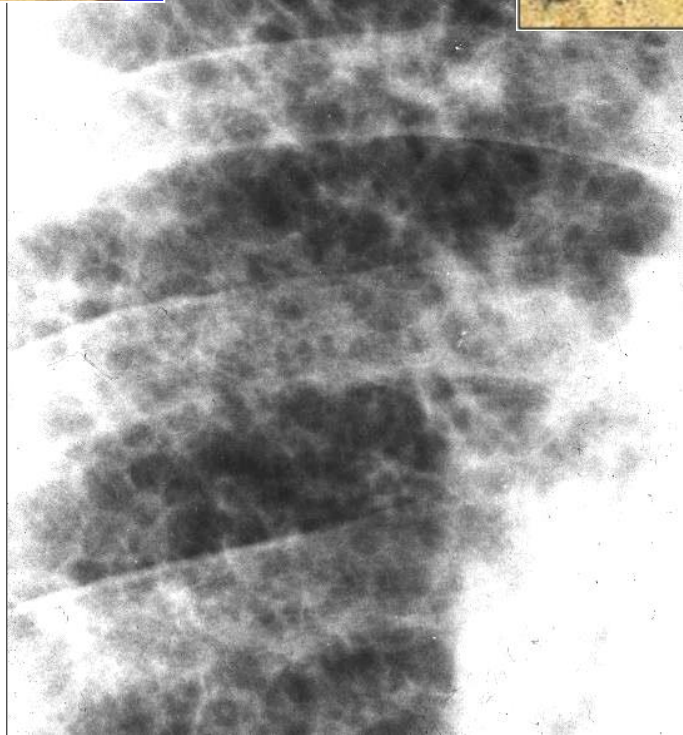
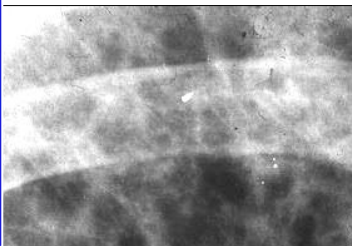

LHH

LINEER OPASİTELER

RETİKÜLASYON

- Akciğer grafisi ve BT için kullanılır.
- Aslında ağısı görünüm anlamına gelir.
- Akciğer grafisinde ve BT'de septal kalınlaşma veya fibrozisi temsil eder.

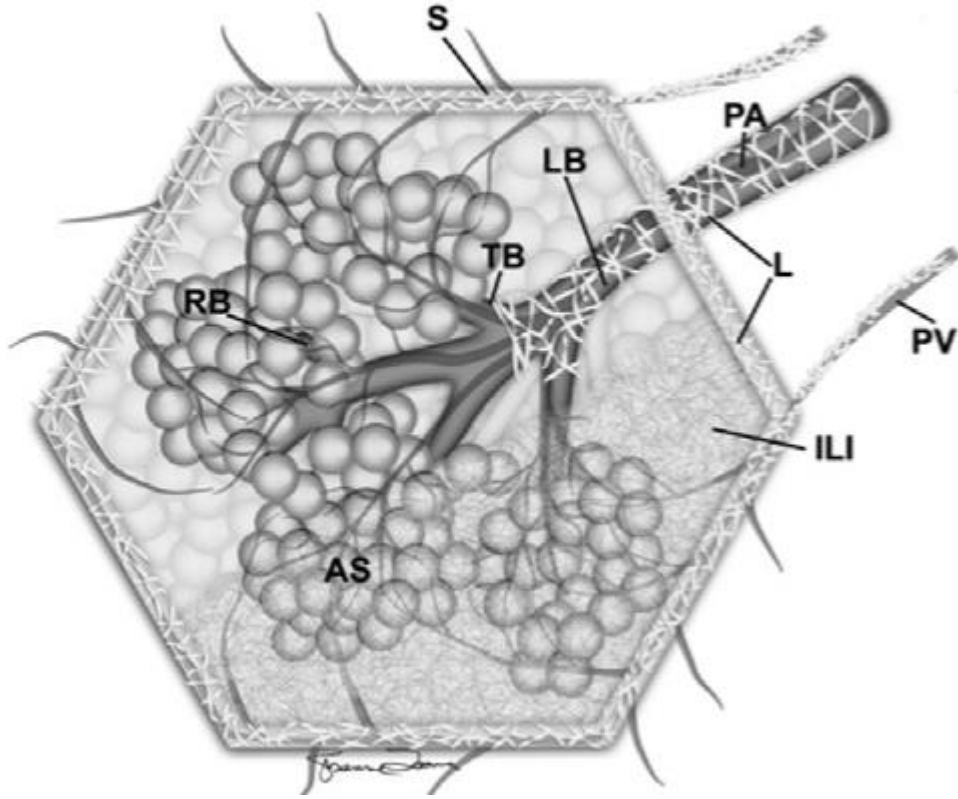




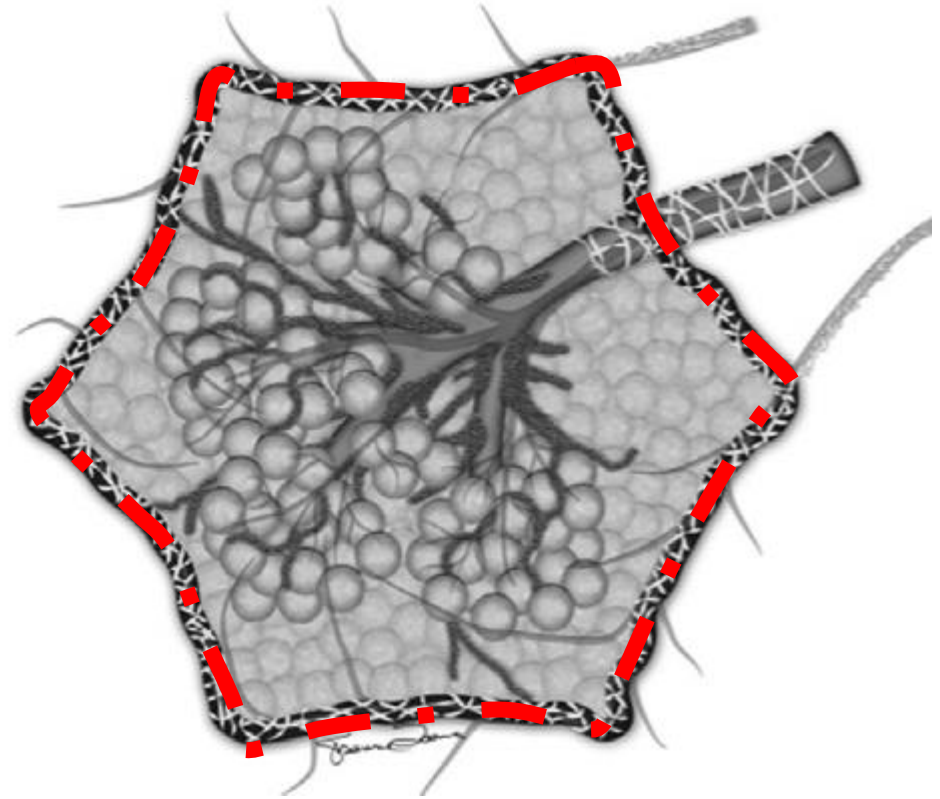
BT'DE RETİKÜLER PATERN

- YRBT'de retiküler patern = interstisyel hastalık= İnterlobüler septal düzensizlik ve kısmen kalınlaşma
- İnterlobüler septa: Bu alanda sıvı, hücre birikimi veya fibrozise bağlı
- Fibrozise bağlı interlobüler- intralobüler septal kalınlaşma

Sekonder pulmoner lobül (SPL)

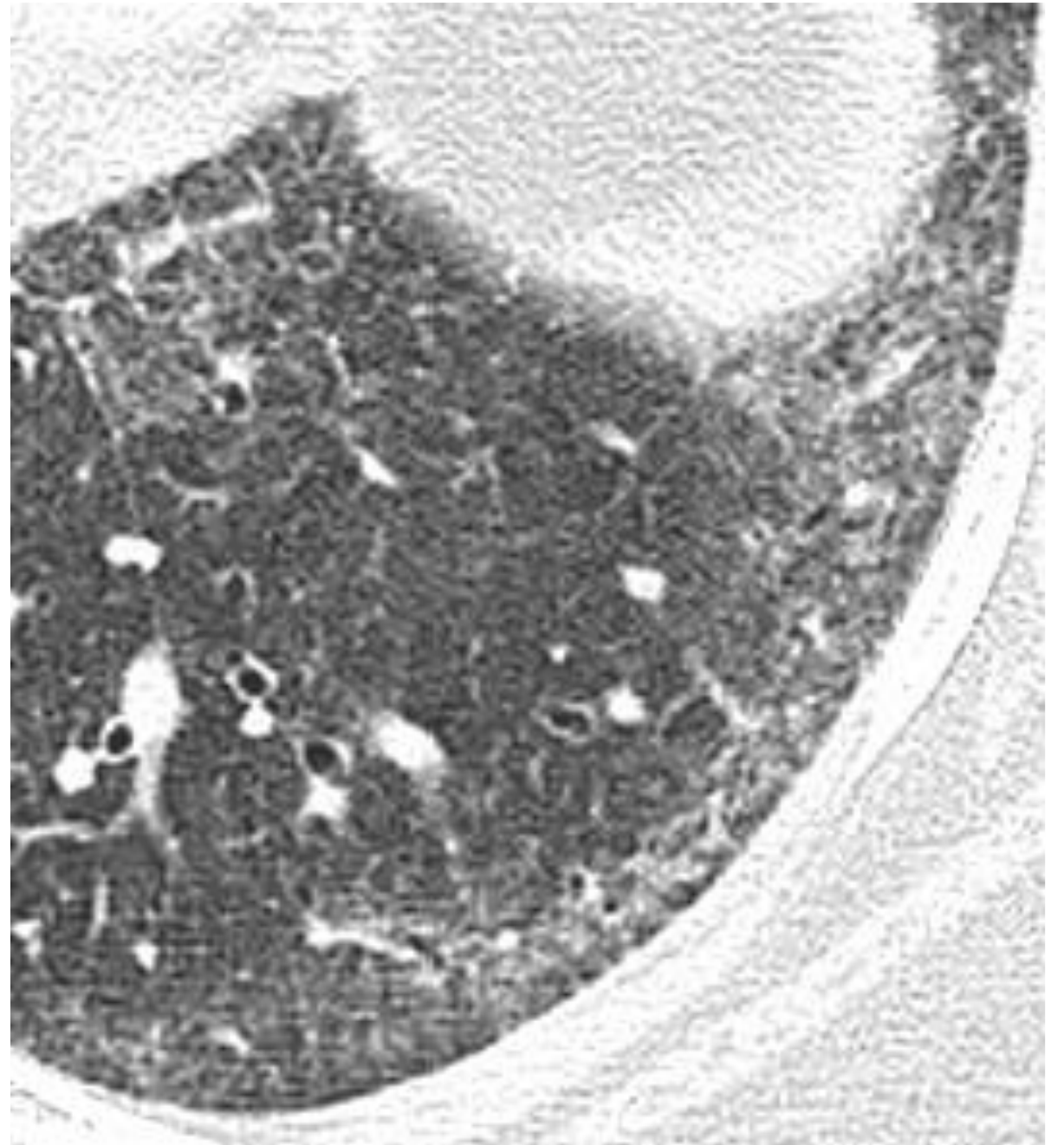
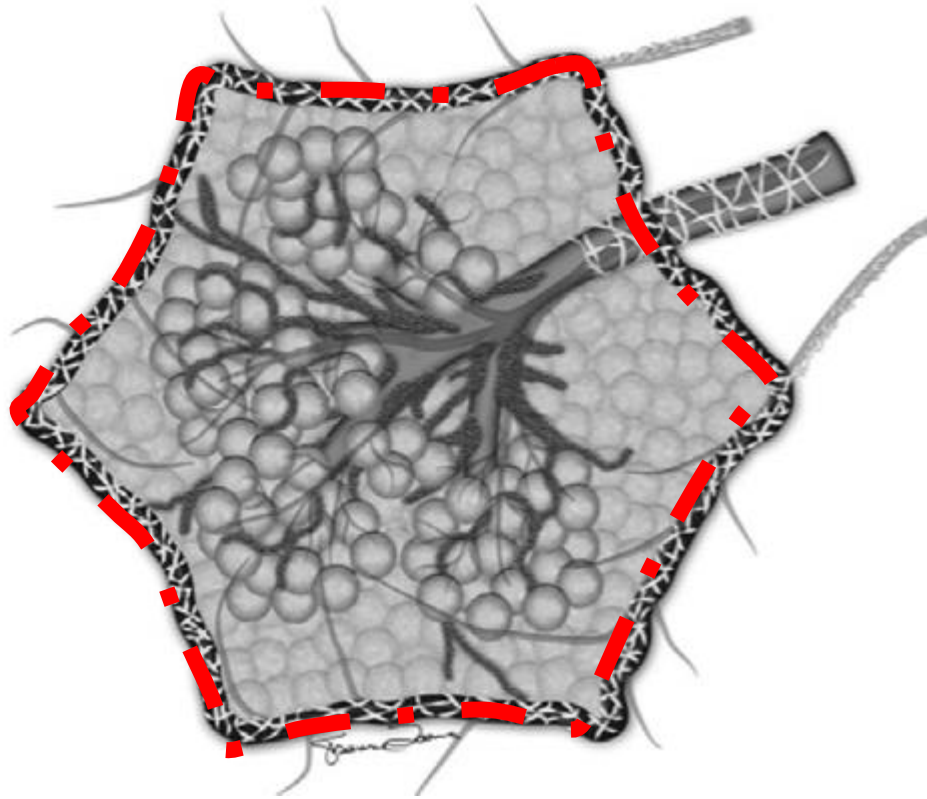


Normal



Retikülasyon

Interlobüler septumda irregülarite ve volüm kaybı



BT'DE RETİKÜLASYON NEDENLERİ:

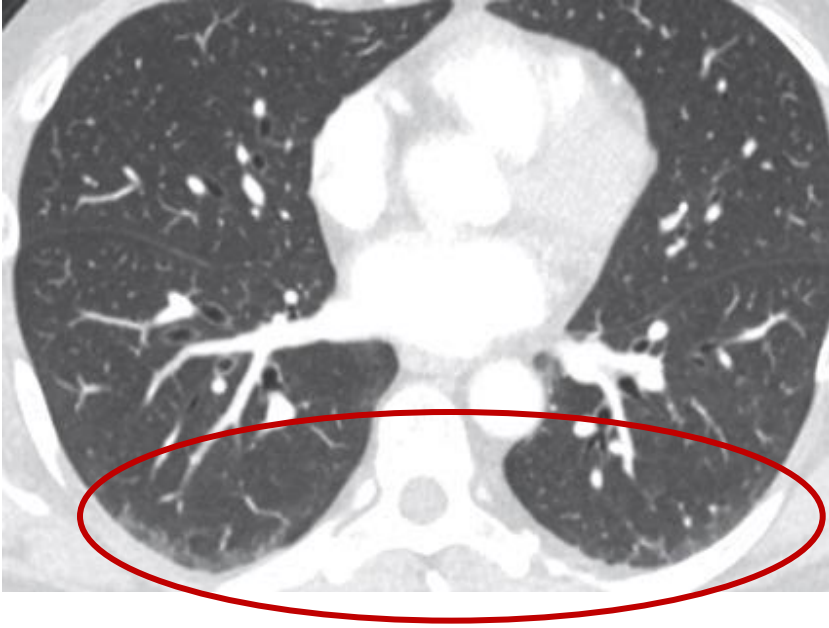AKUT

- Pulmoner ödem
- Enfeksiyonlar
- İlaç reaksiyonları

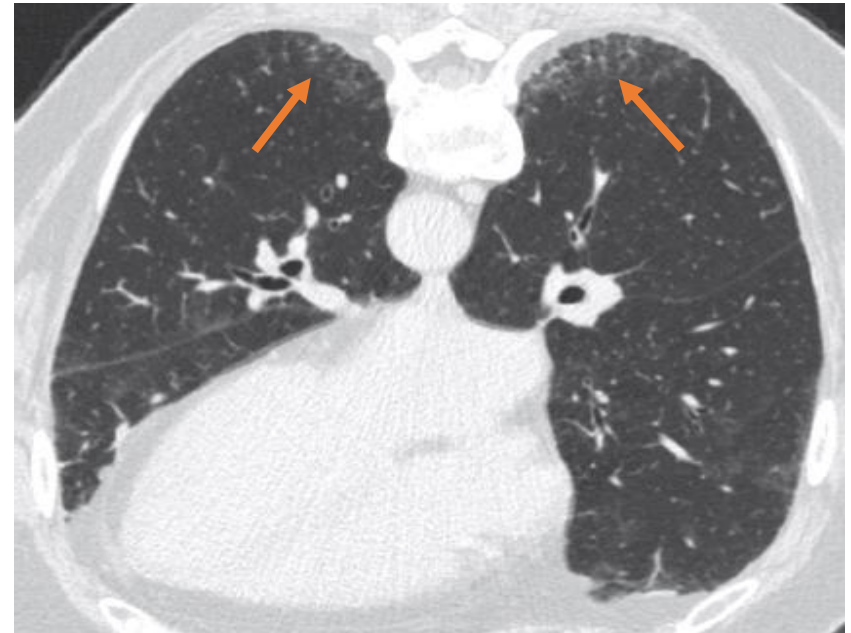
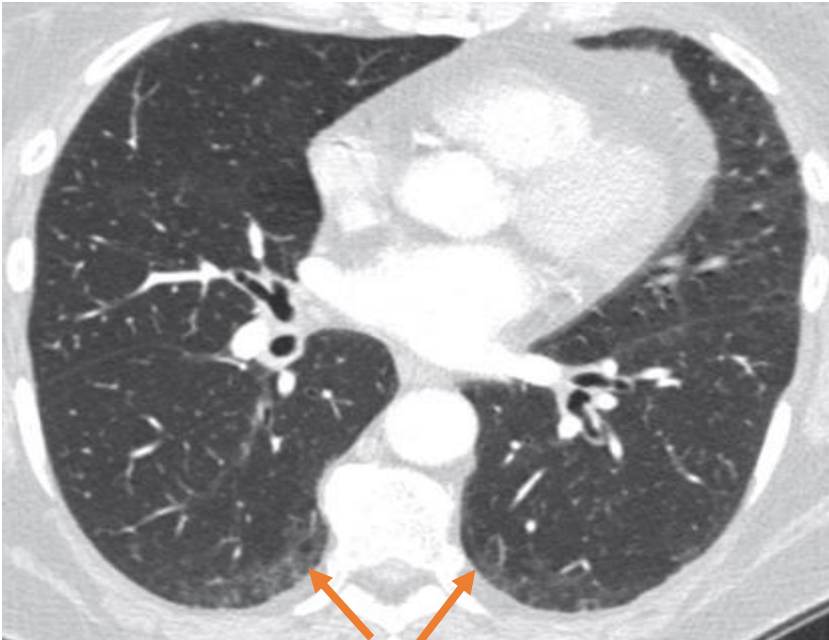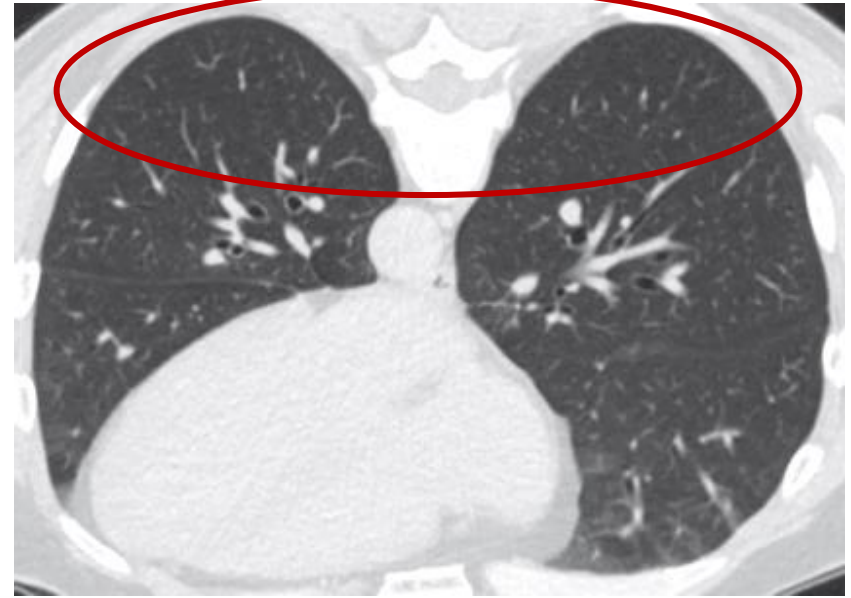
KRONİK

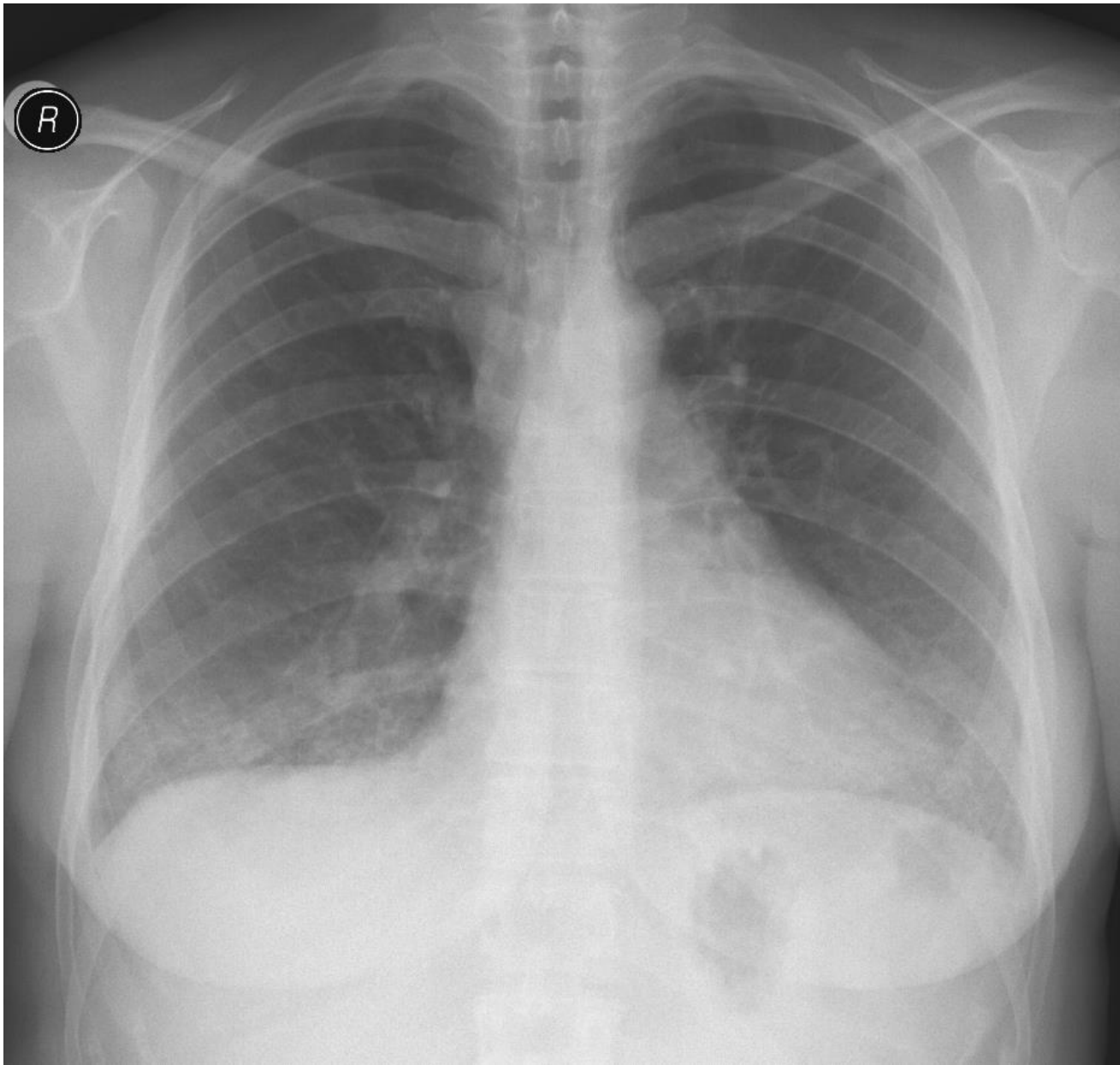
- Post-infeksiyöz skar
- Kronik interstisyel ödem
- Bağ dokusu hastalıkları
- Granülomatöz hast. (sarkoidoz vb)
- Maligniteler
- İnhalasyona bağlı hastalıklar
- İdiopatik
- ...

SUPIN

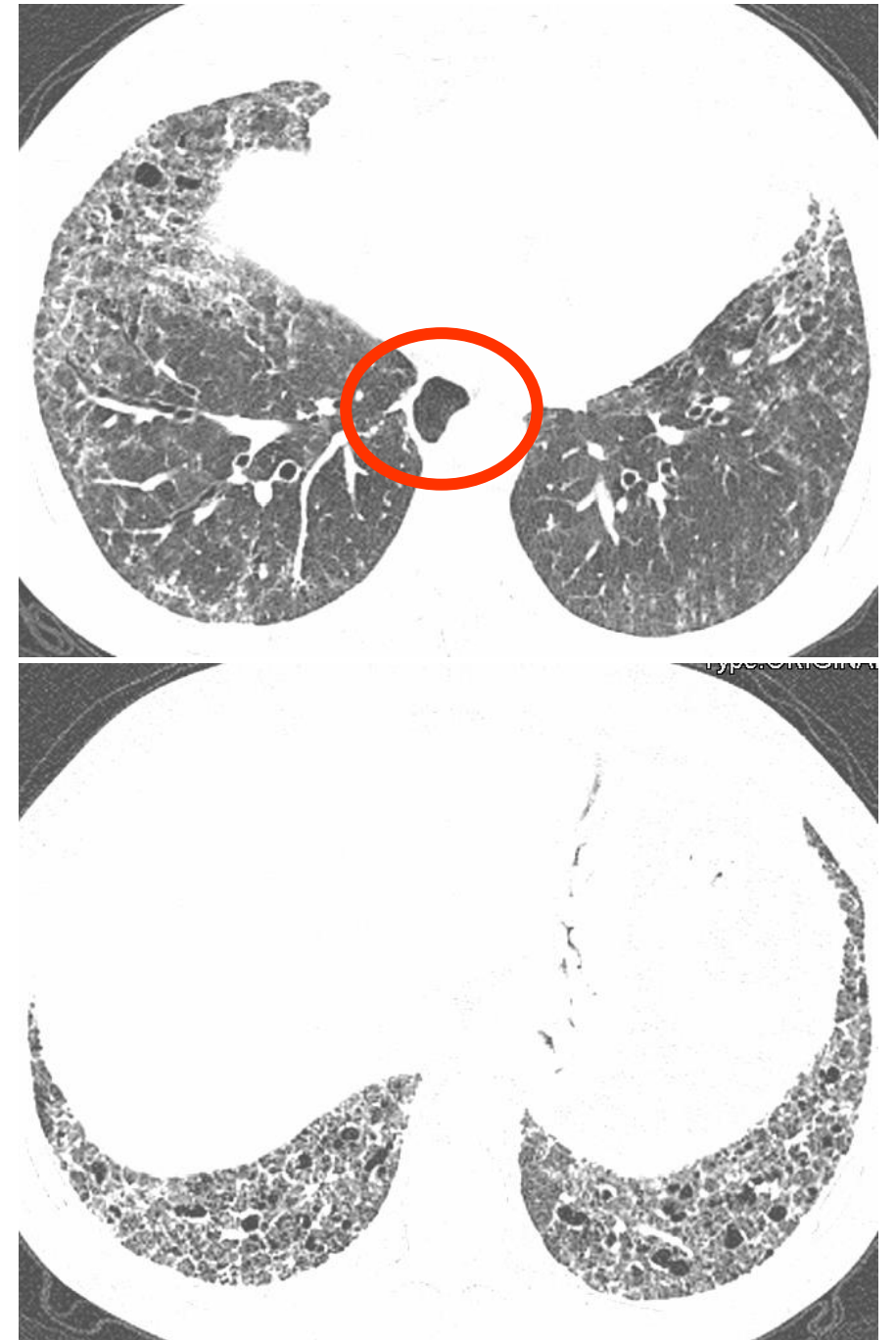

PRON





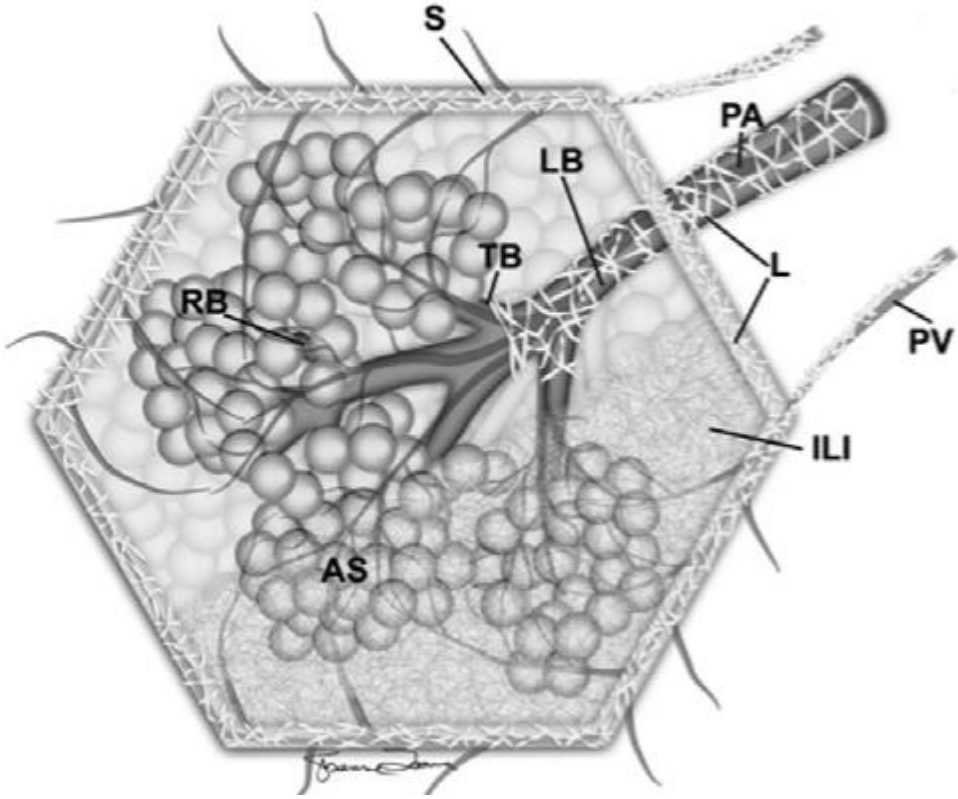
SKLERODERMA



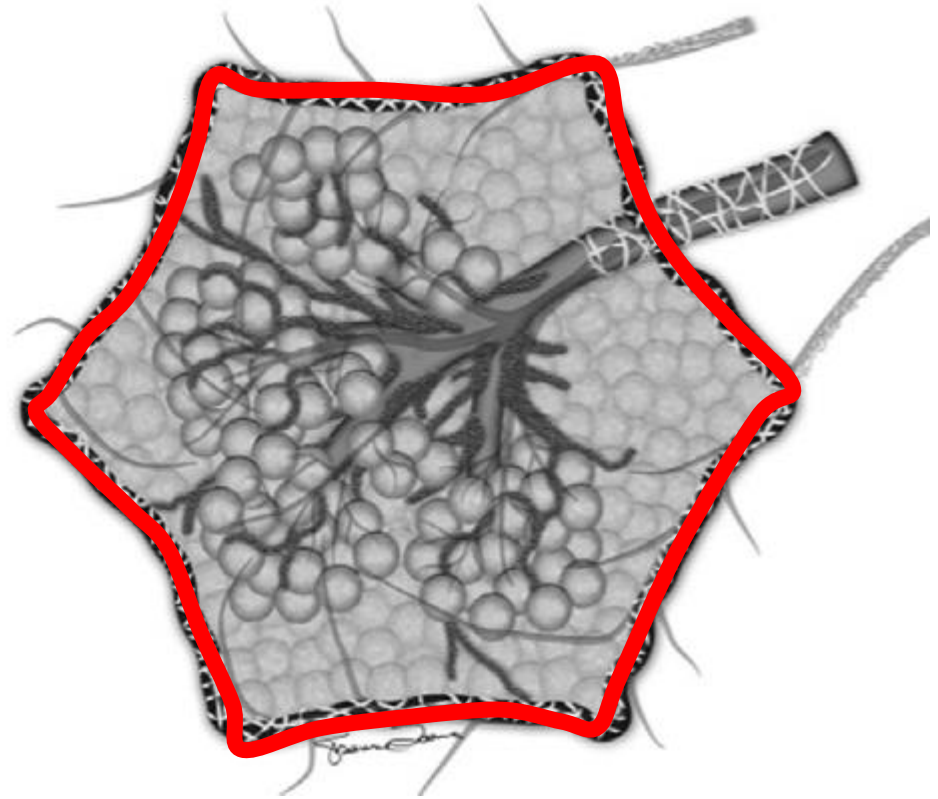
SEPTAL KALINLAŞMA

- Sekonder pulmoner lobül kalınlaşması
 - Septum içinde ise intralobüler
 - Septumun çevresi ise kalınlaşma interlobüler

Sekonder pulmoner lobül (SPL)



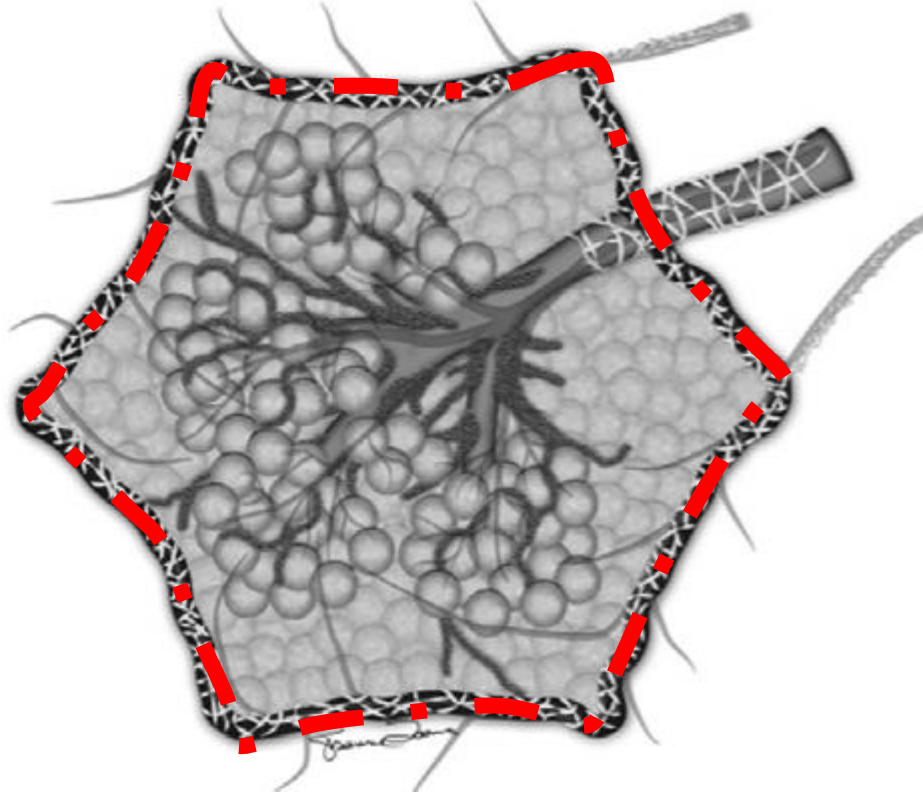
Normal



Septal kalınlaşma

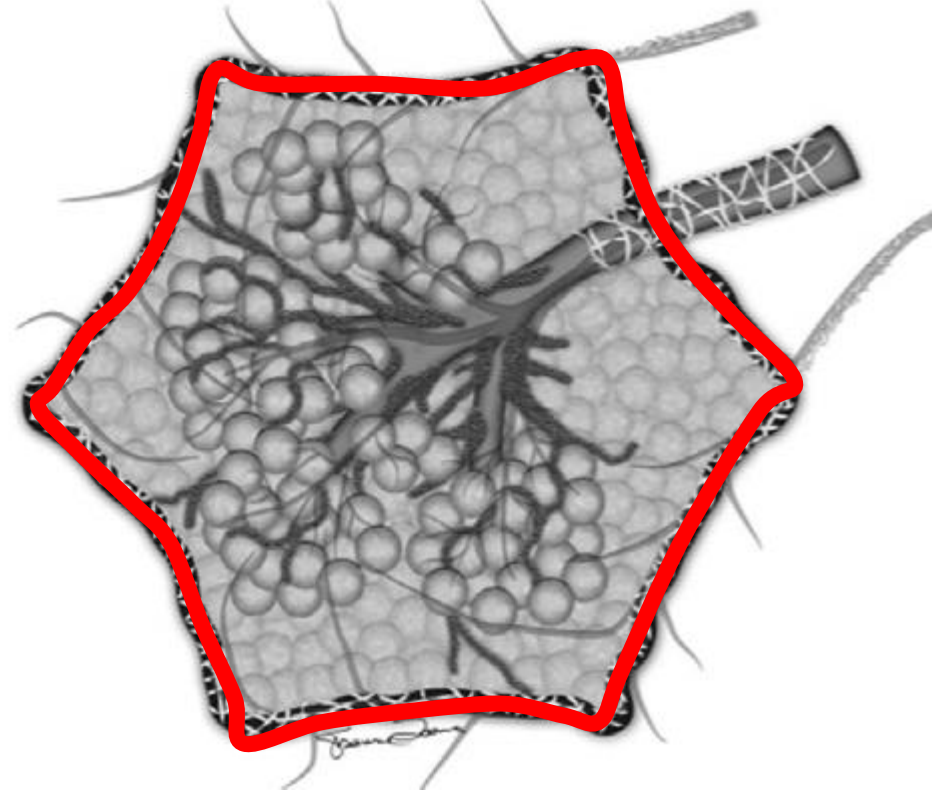
Interlobüler septumda kalınlaşma ve volüm kaybı

Sekonder pulmoner lobül (SPL)



Retikülasyon

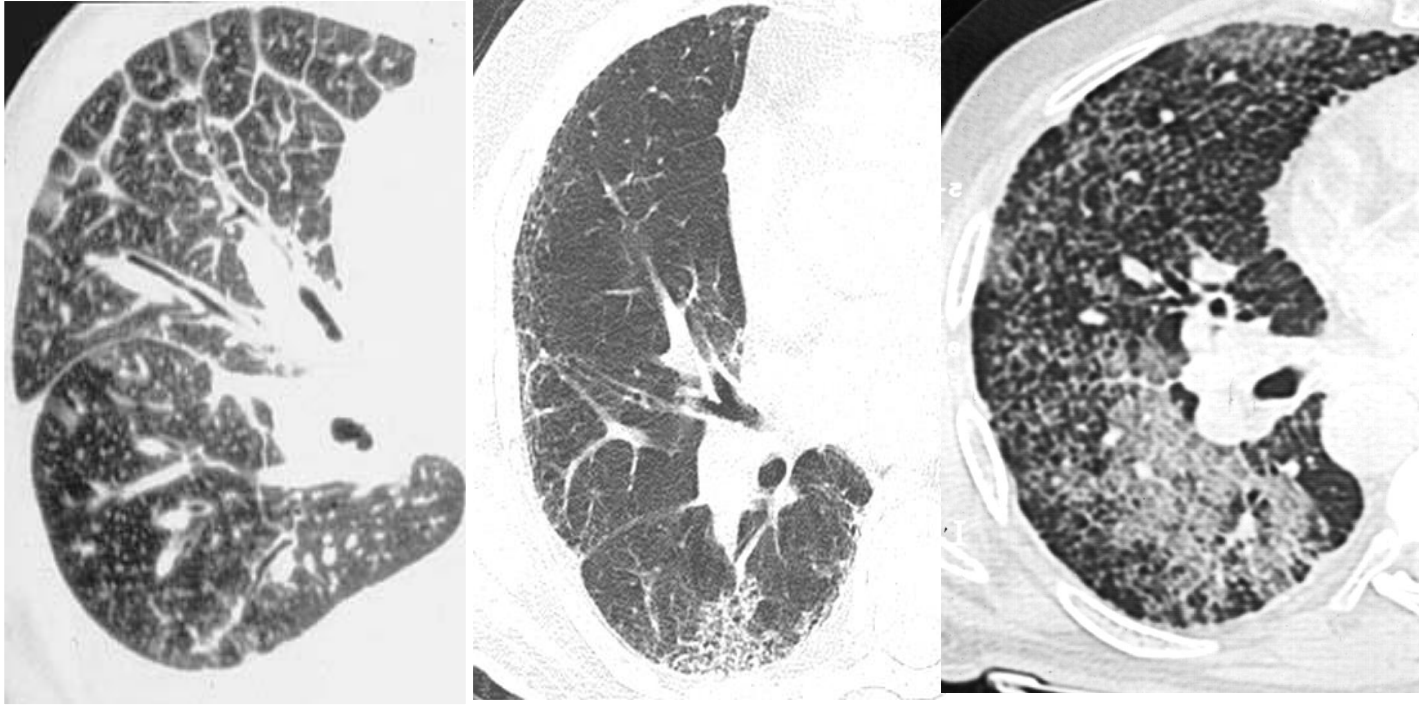
Interlobüler septumda irregülarite ve volüm kaybı



Septal kalınlaşma

Interlobüler septumda kalınlaşma ve volüm kaybı

BİLGİSAYARLI TOMOGRAFİDE



İnterlobüler
Septal kalınlaşma

İntralobüler septal
kalınlaşma

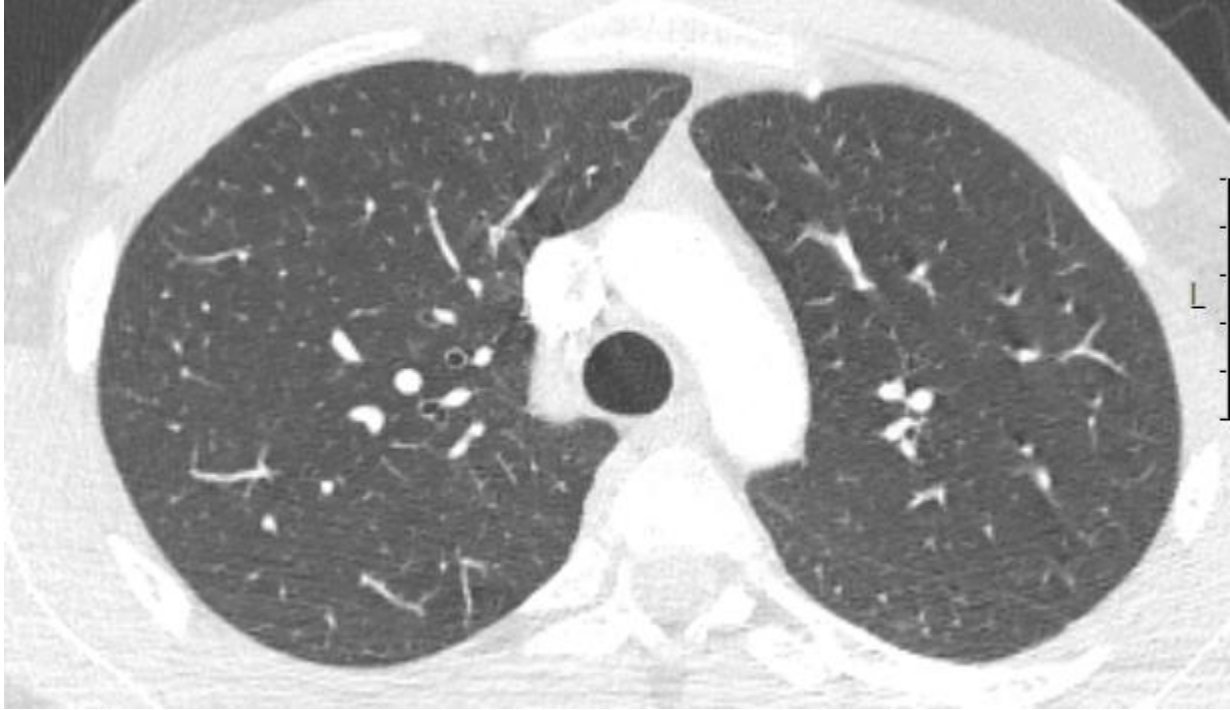
İnter ve intralobüler
septal kalınlaşma

İNTERLOBÜLER SEPTAL KALINLAŞMA

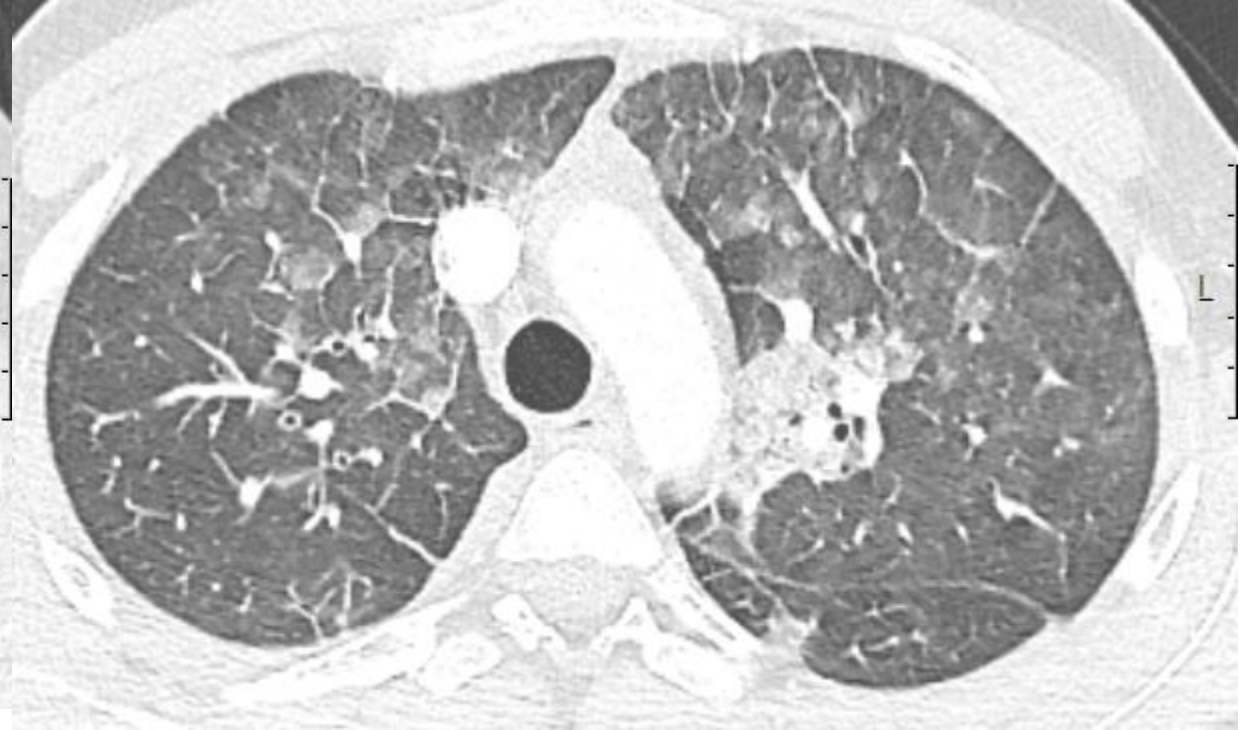
- **Düz, nodüler ve irregüler** olmak üzere üç formda incelenir.
 - **İrregüler kalınlaşma** fibrozisde
 - **Düz kalınlaşma:** Pulmoner ödem, pulmoner hemoraji , lenfoma..
 - **Nodüler kalınlaşma:** Lenfanjitik metastaz, sarkoidozis, amiloidozis..

18 Y E, AML hastası

Dispne başlamış. Fungal pnömoni? PE?)



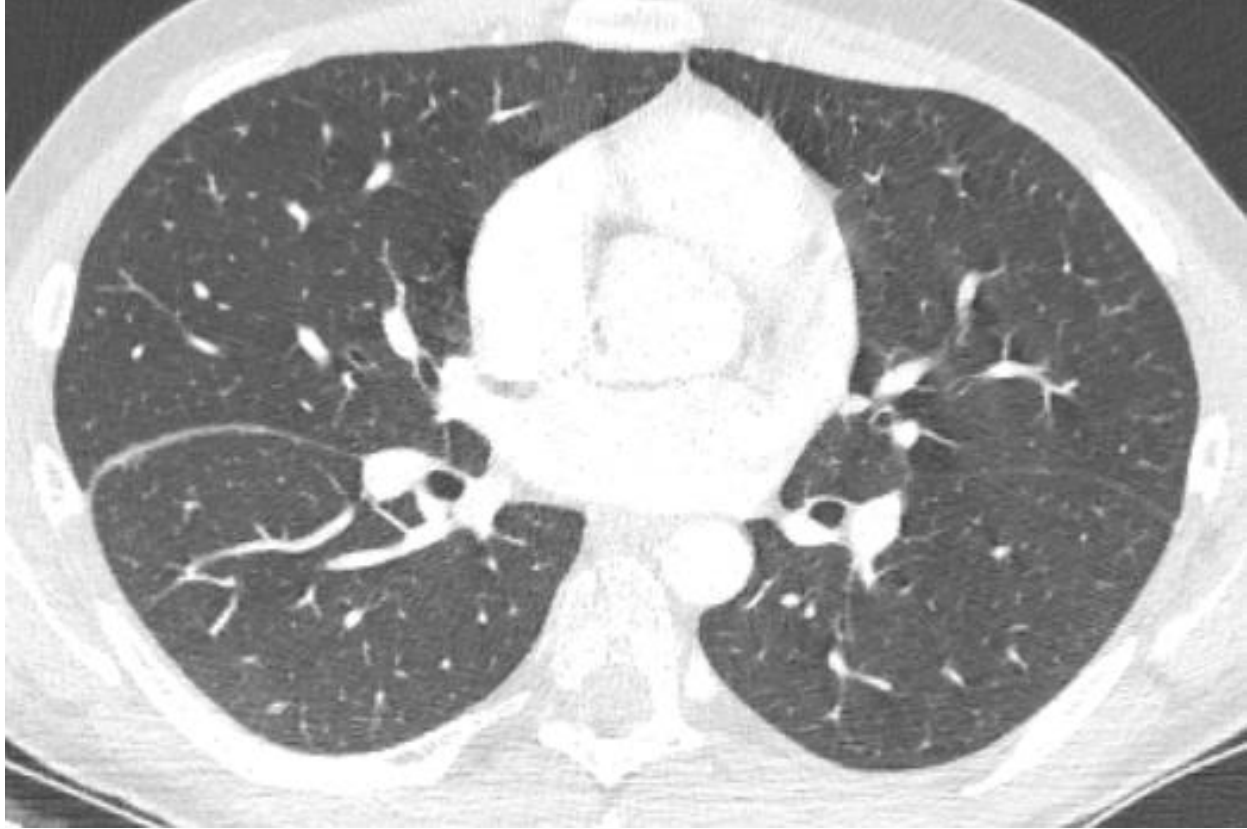10.09.2021



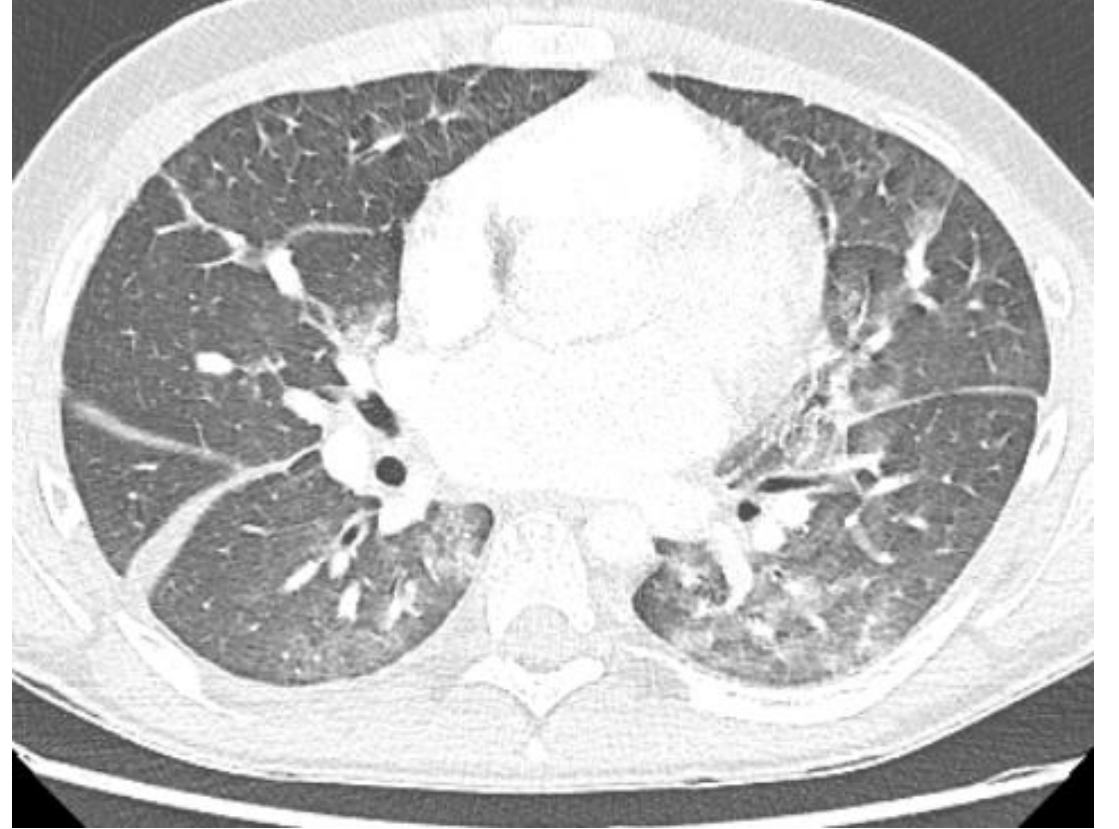17.09.2021

18 Y E, AML hastası

Dispne başlamış. Fungal pnömoni? PE?)



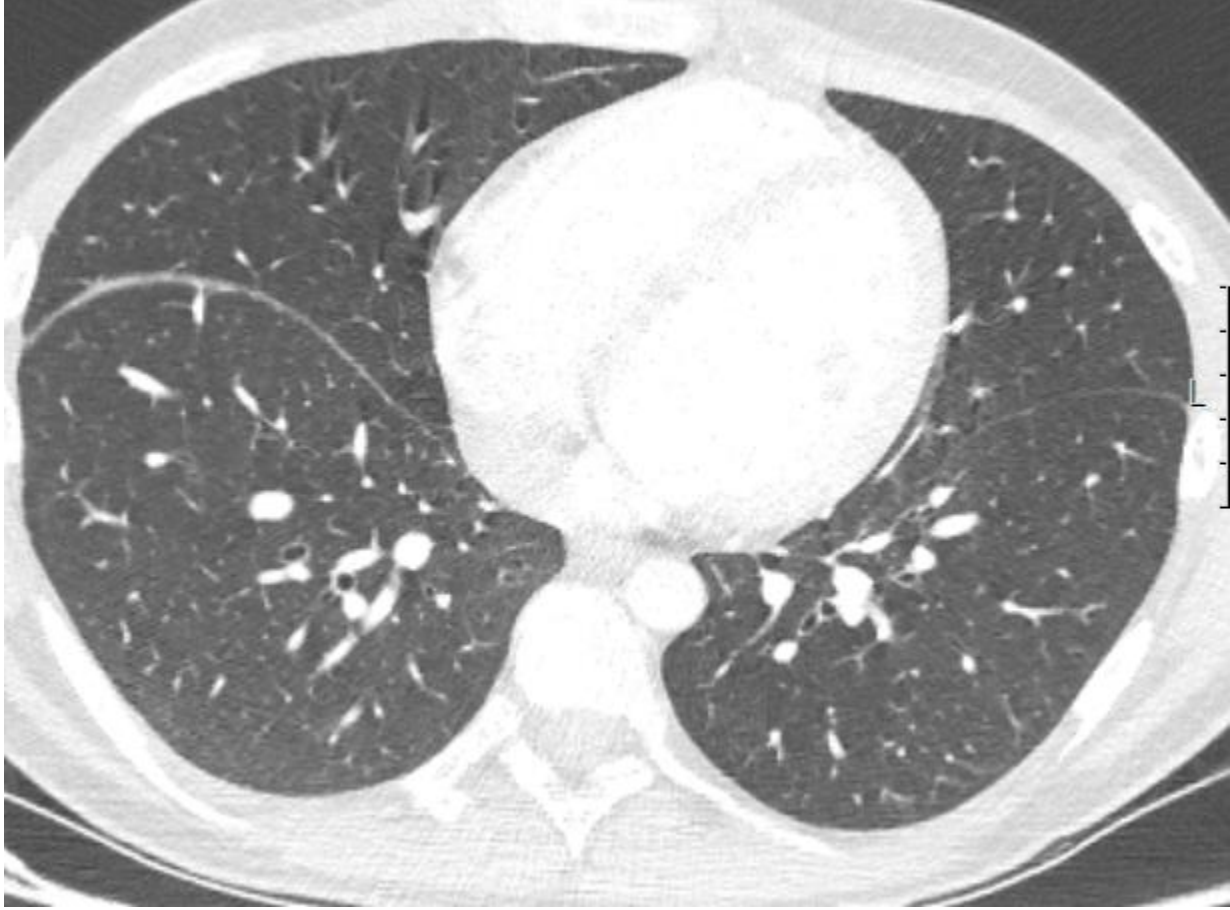
10.09.2021



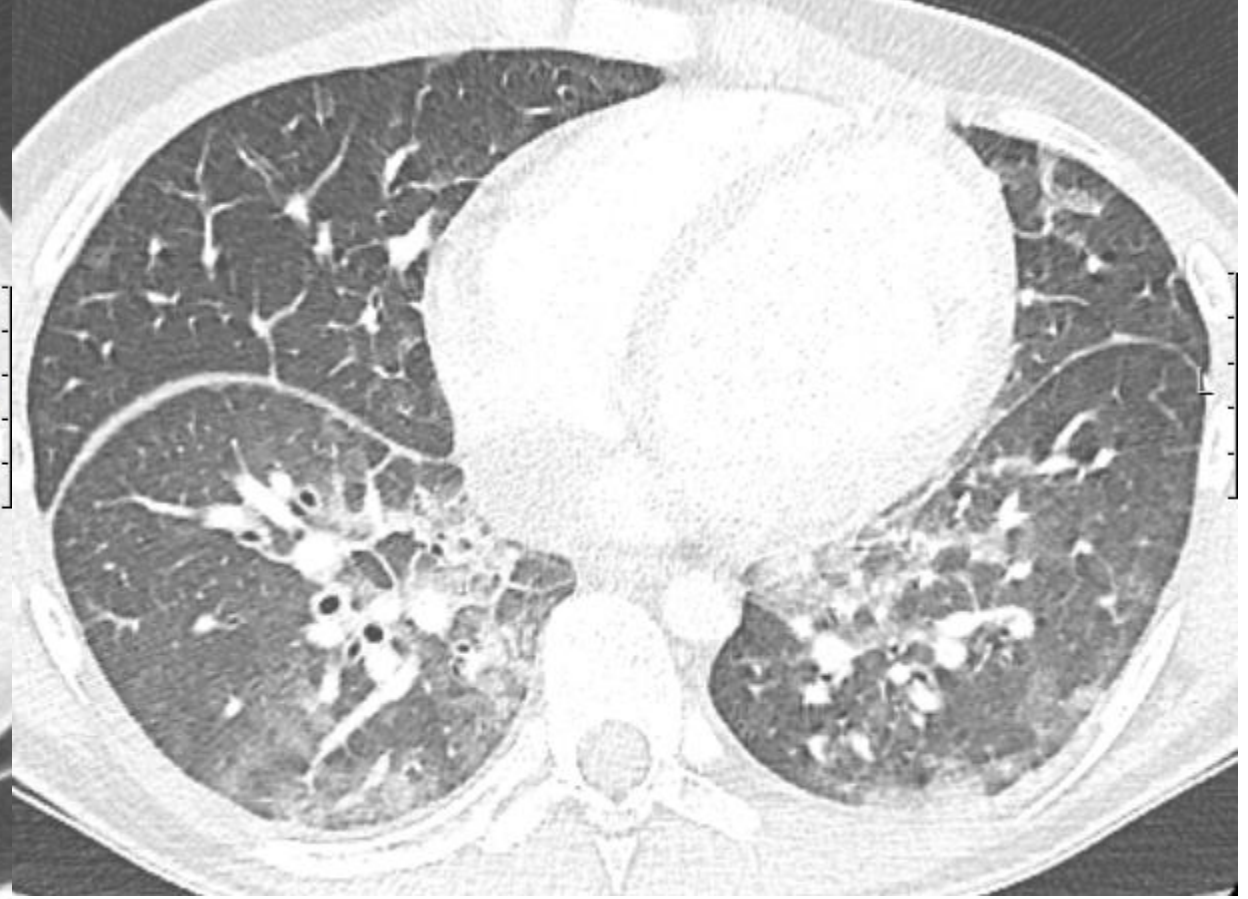17.09.2021

18 Y E, AML hastası

Dispne başlamış. Fungal pnömoni? PE?)



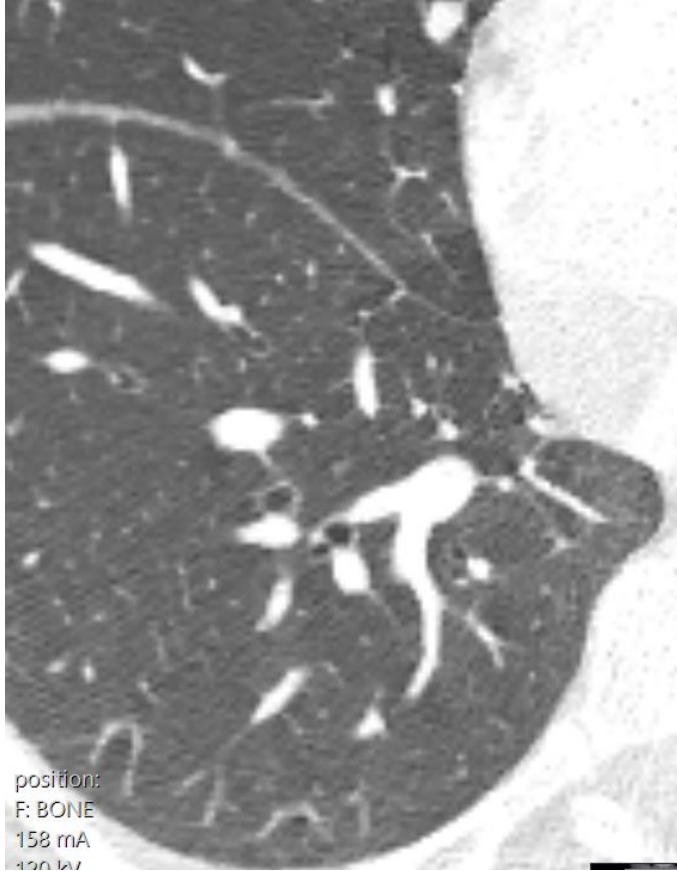
10.09.2021



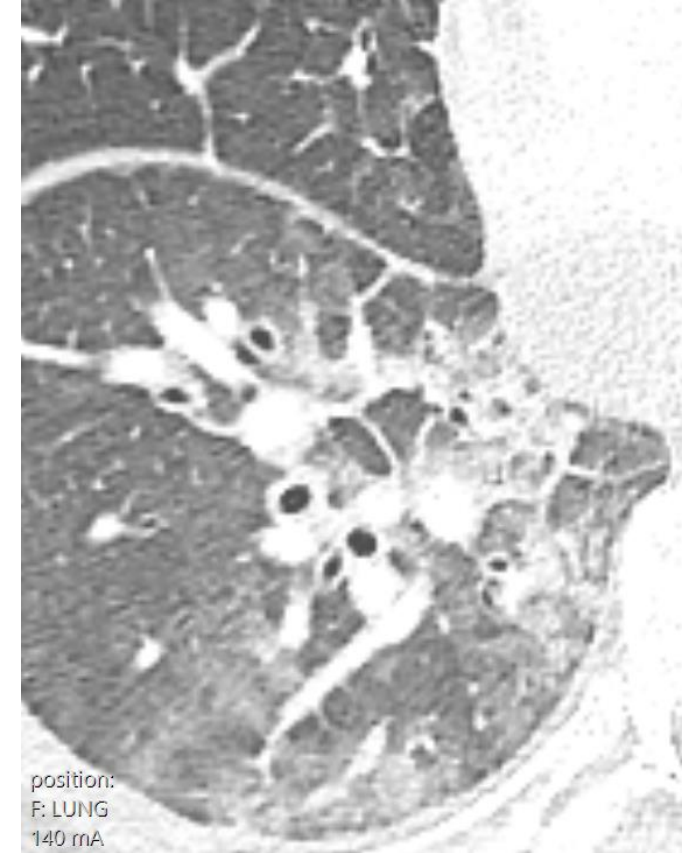
17.09.2021

18 Y E, AML hastası

Dispne başlamış. Fungal pnömoni? PE?)



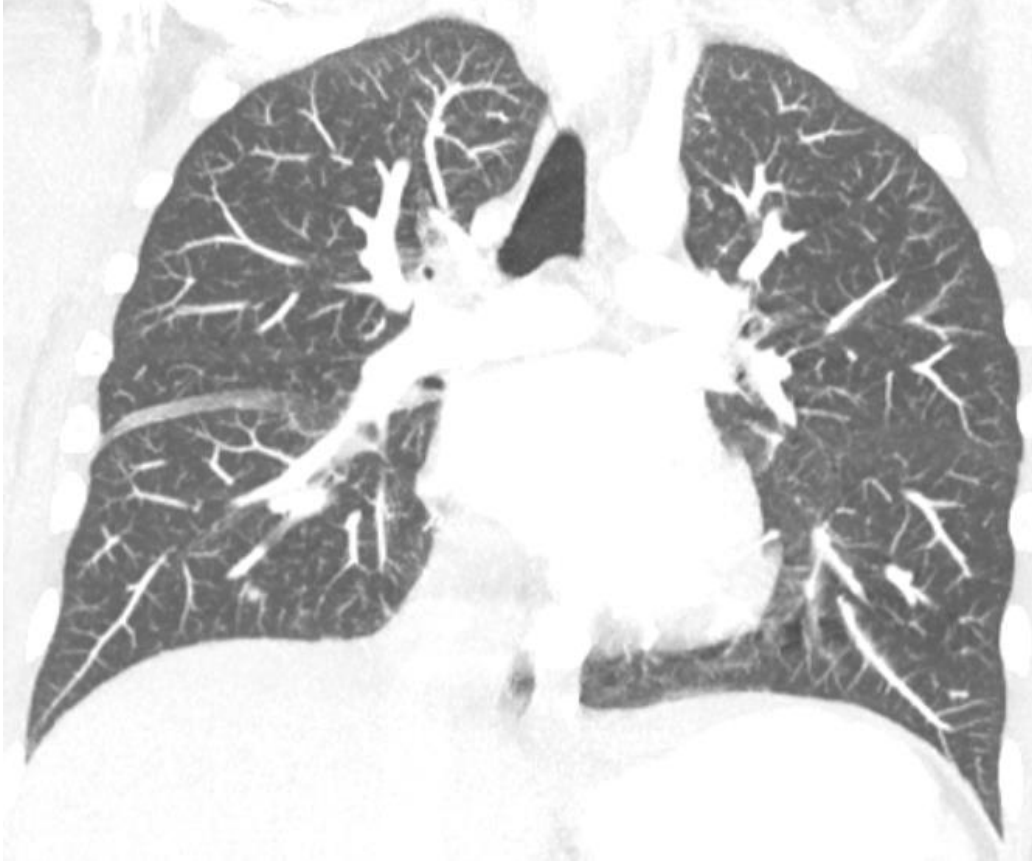10.09.2021



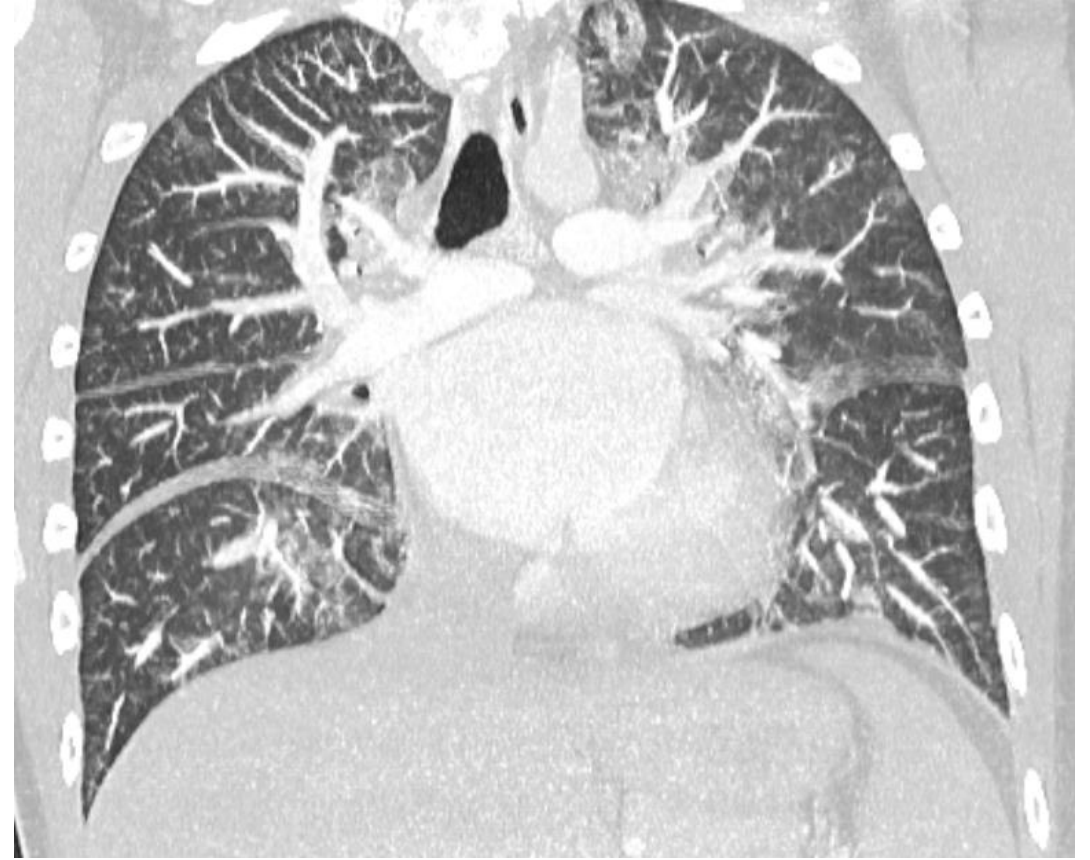
17.09.2021

18 Y E, AML hastası

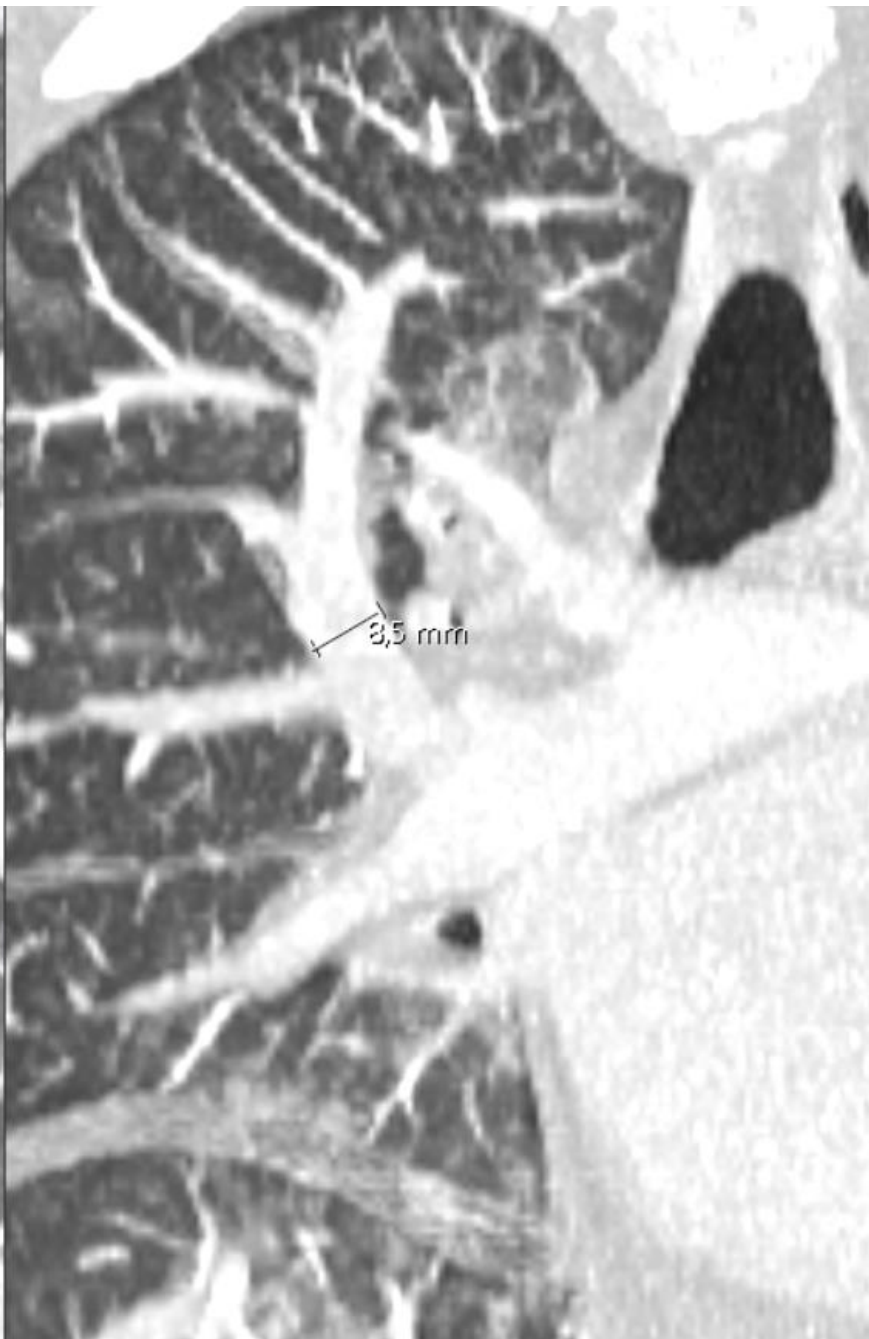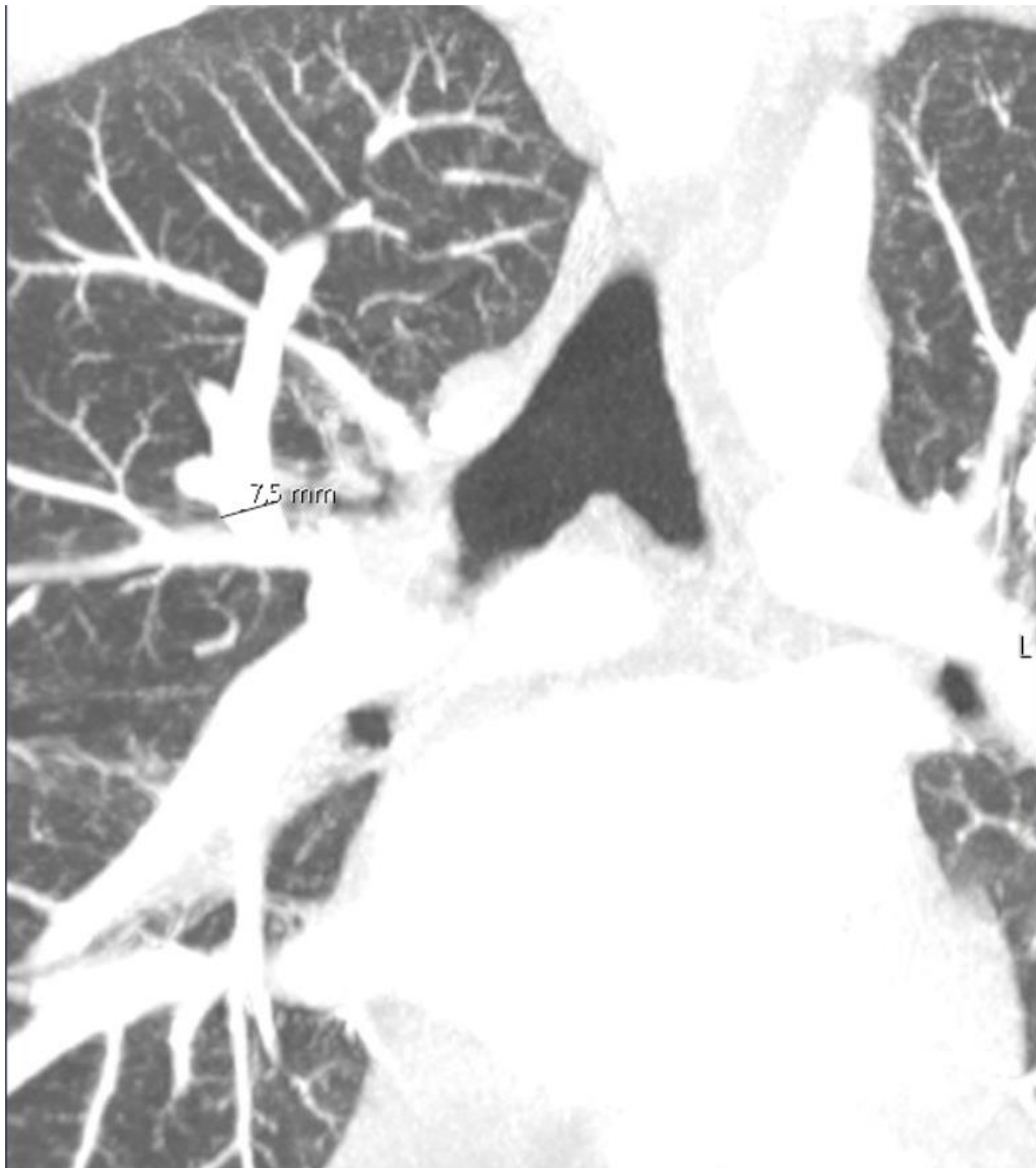
Dispne başlamış. Fungal pnömoni? PE?)

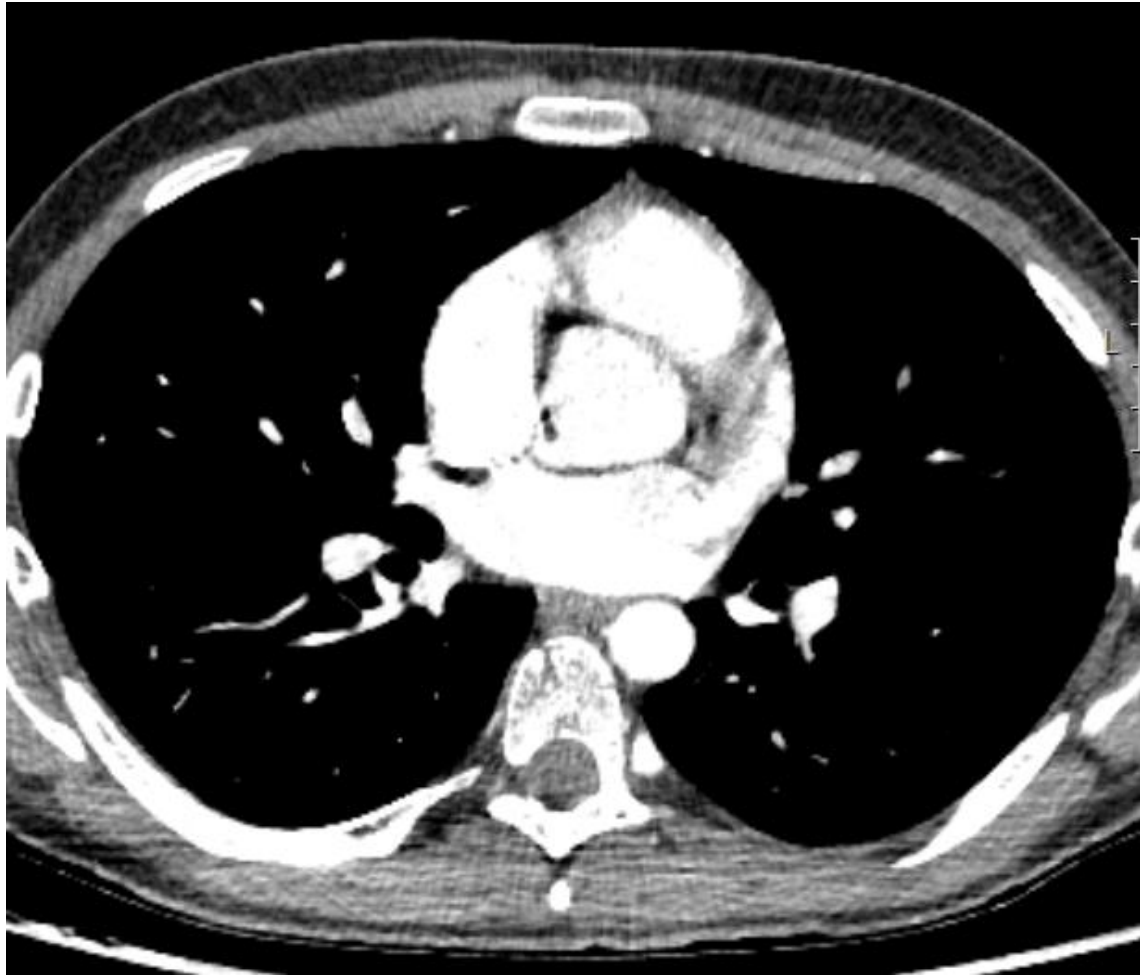


10.09.2021

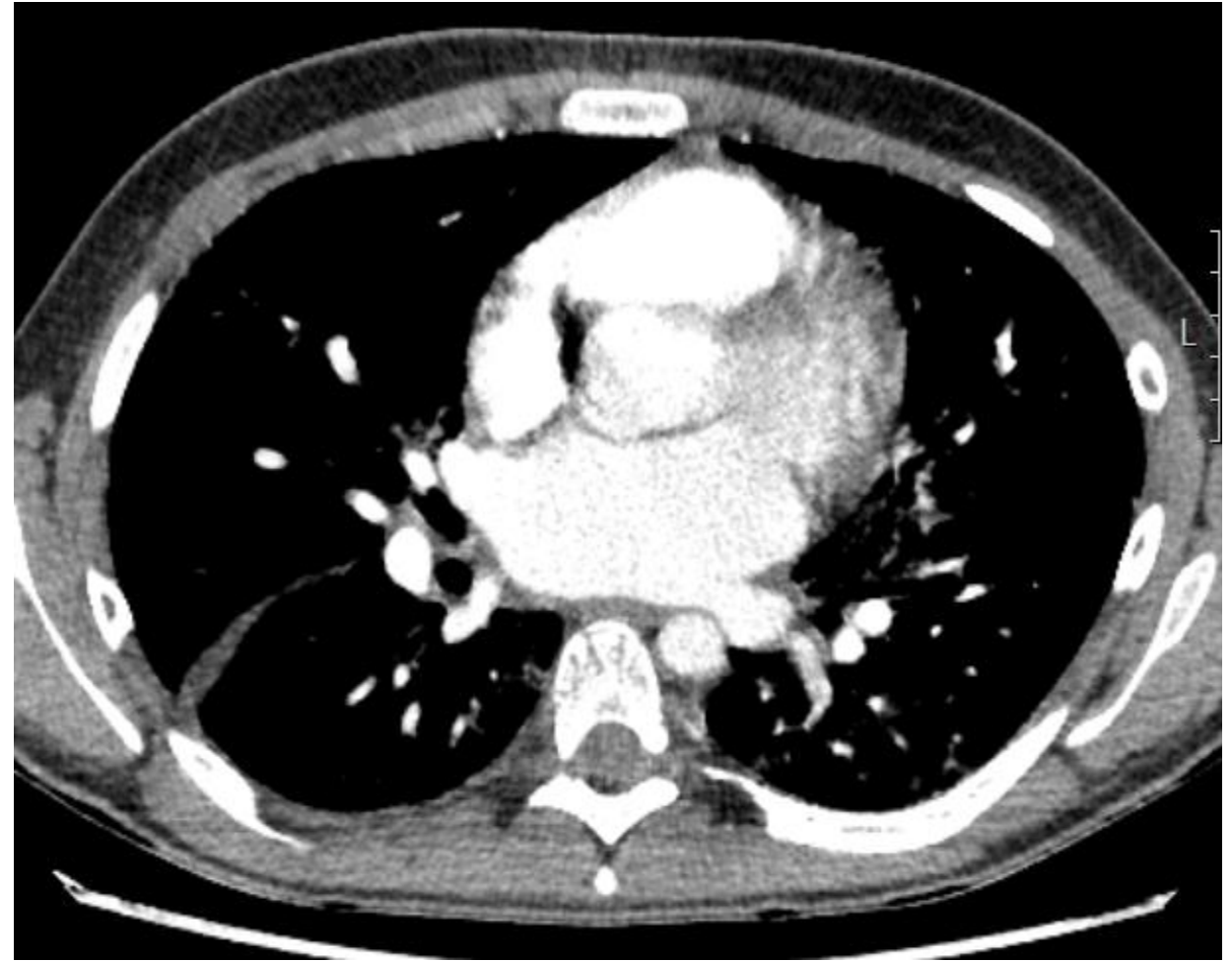


17.09.2021



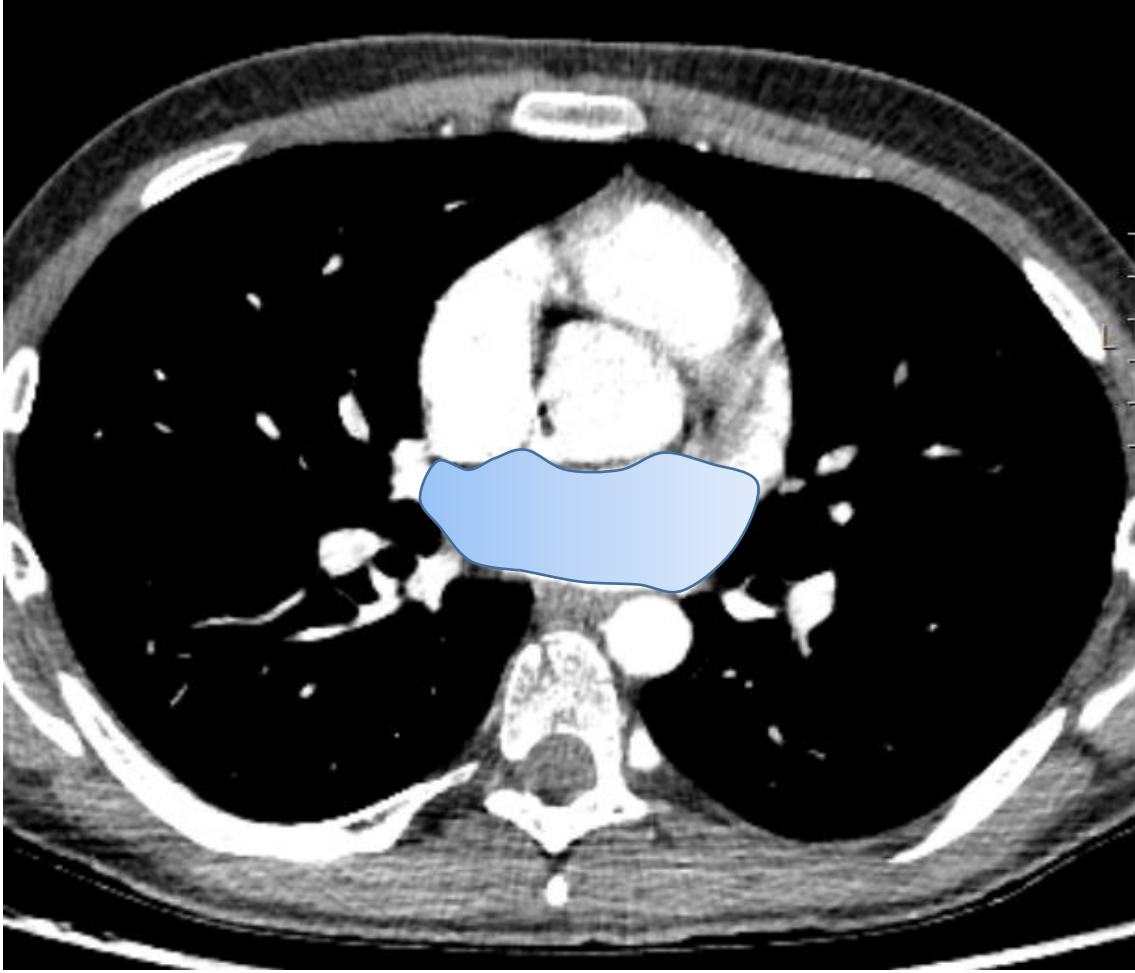


10.09.2021

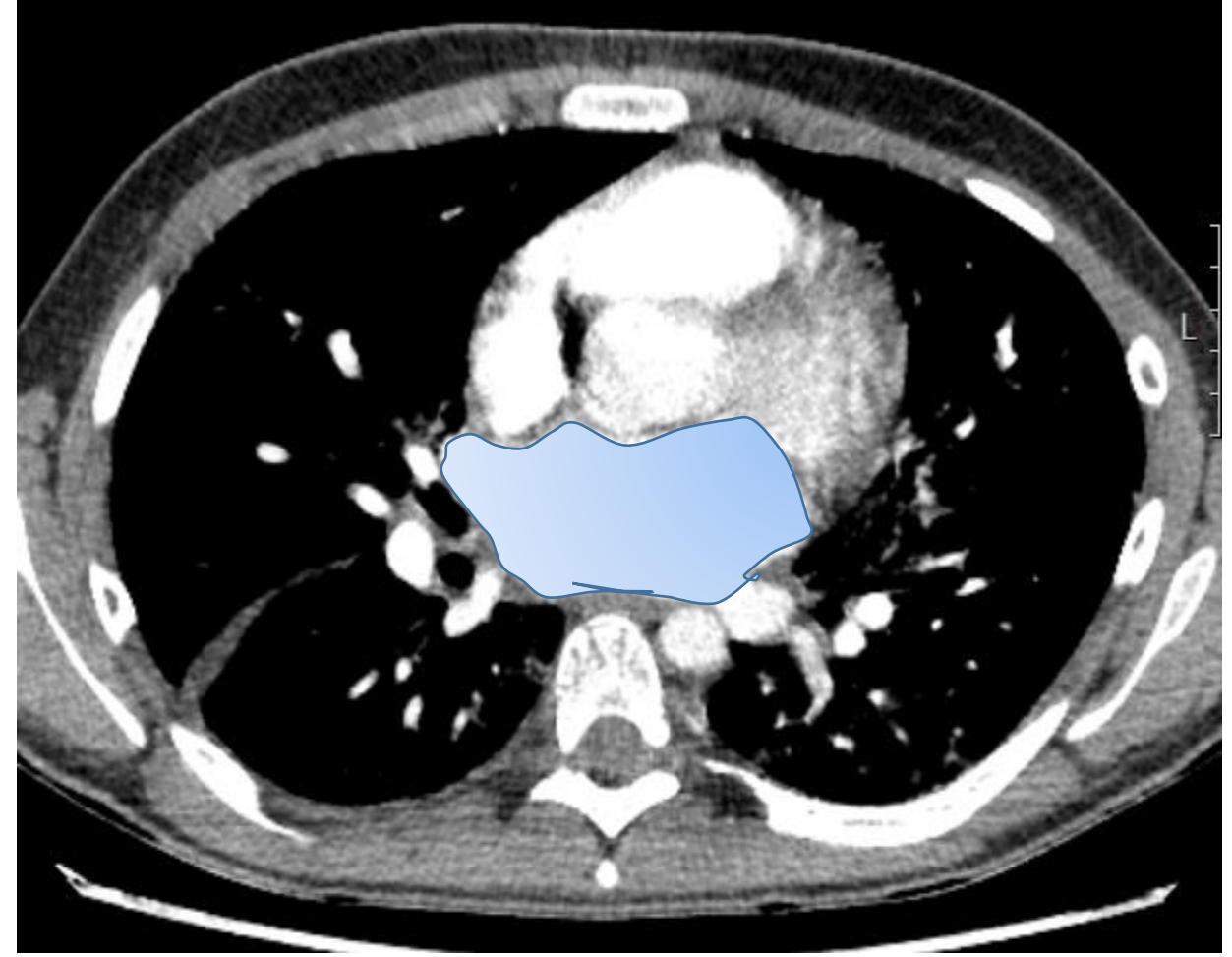


17.09.2021

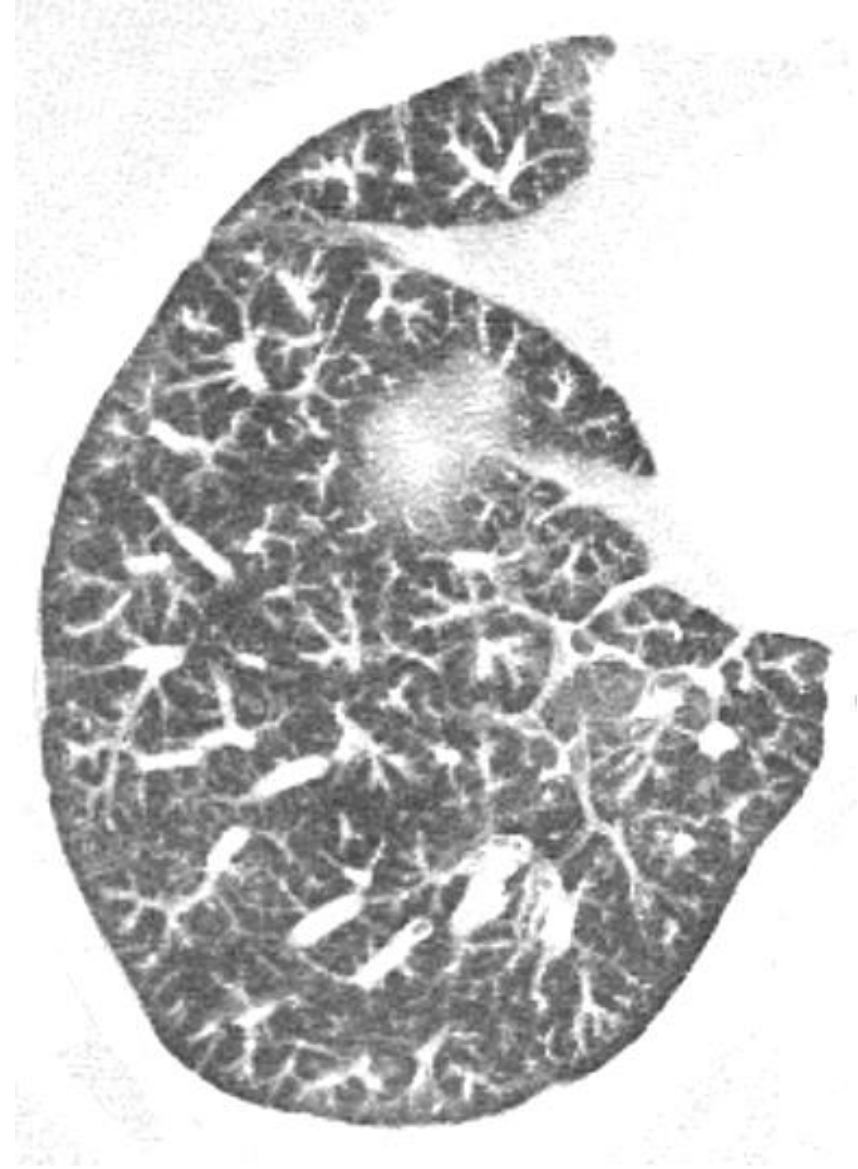
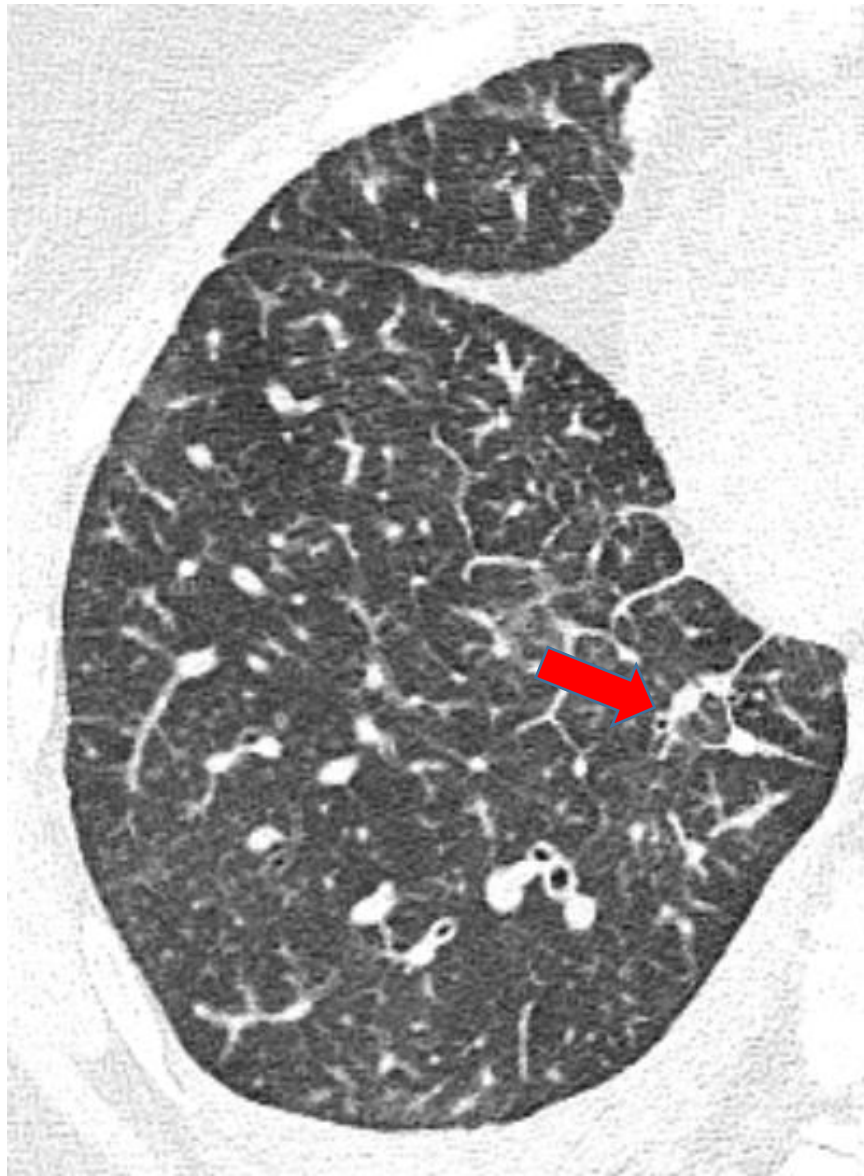Antrasiklin ilişkili akut kalp yetmezliği EF: % 25



10.09.2021

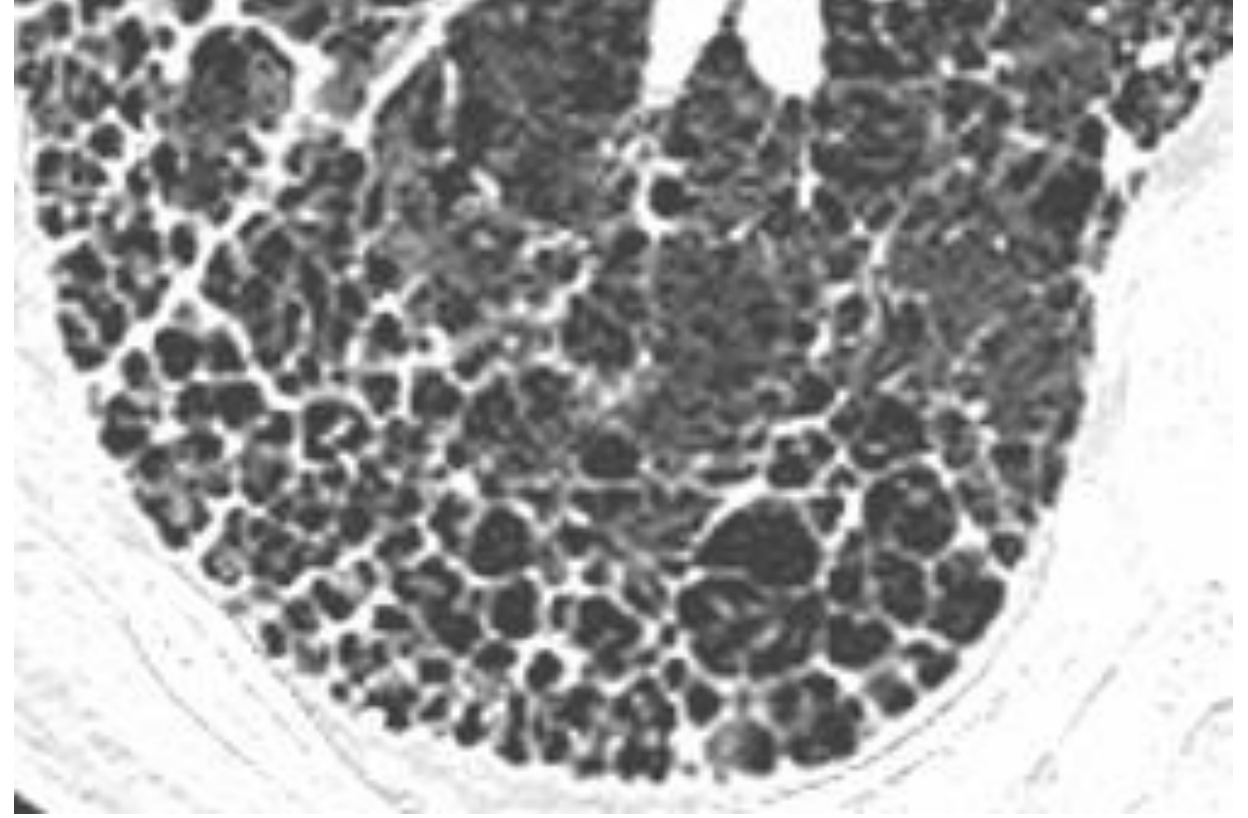
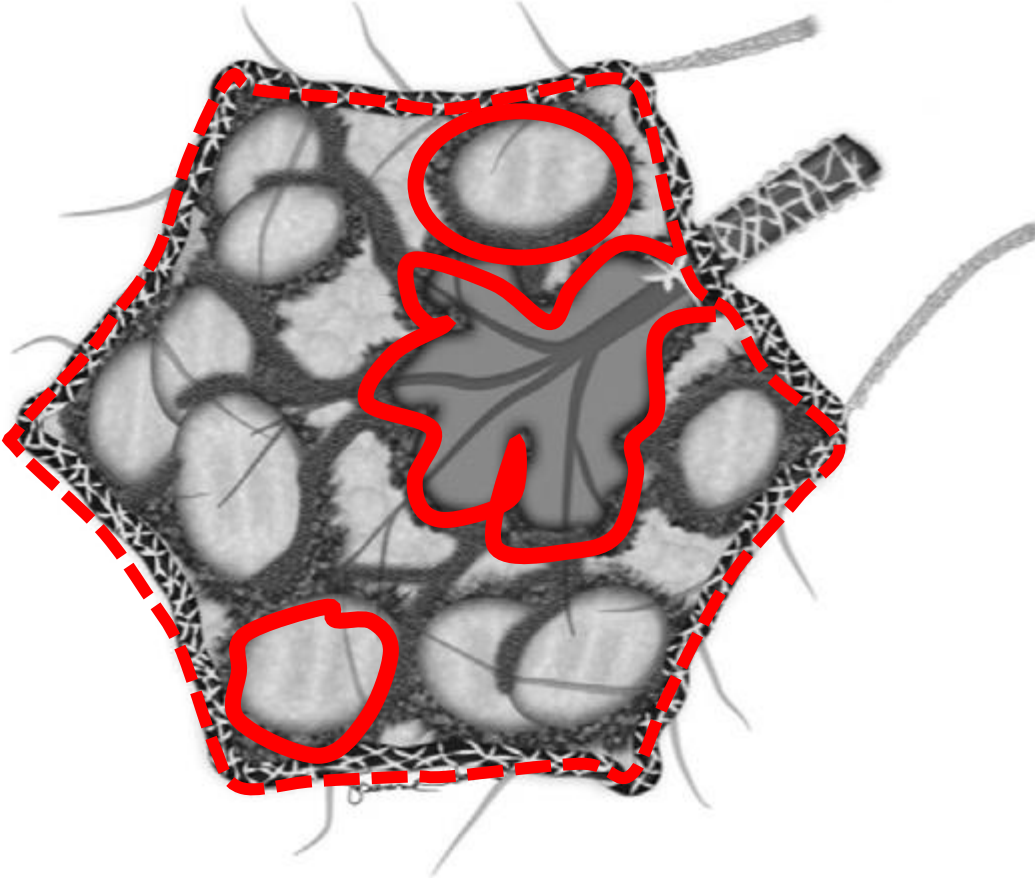


17.09.2021



LENFANJİTİK METASTAZ

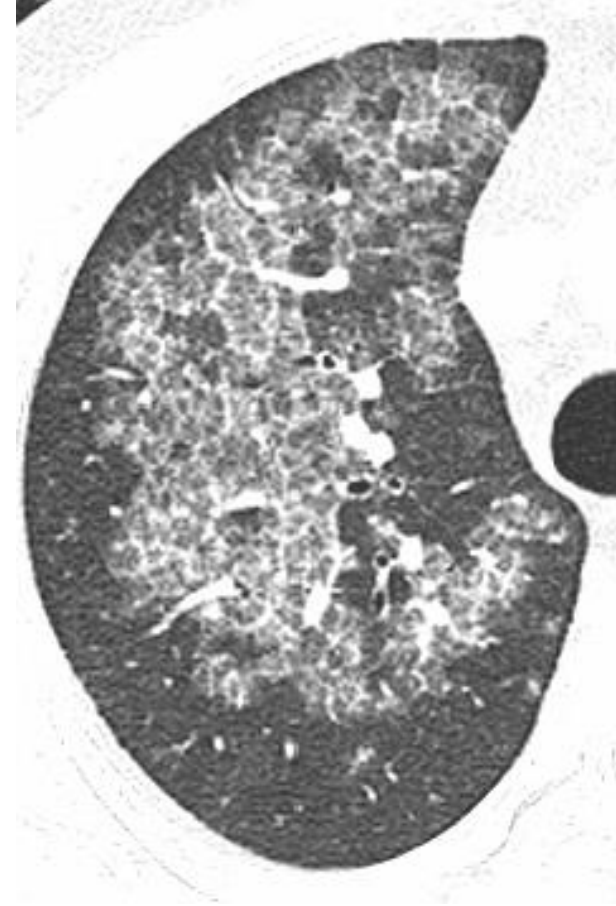
BALPETEĞİ GÖRÜNÜMÜ

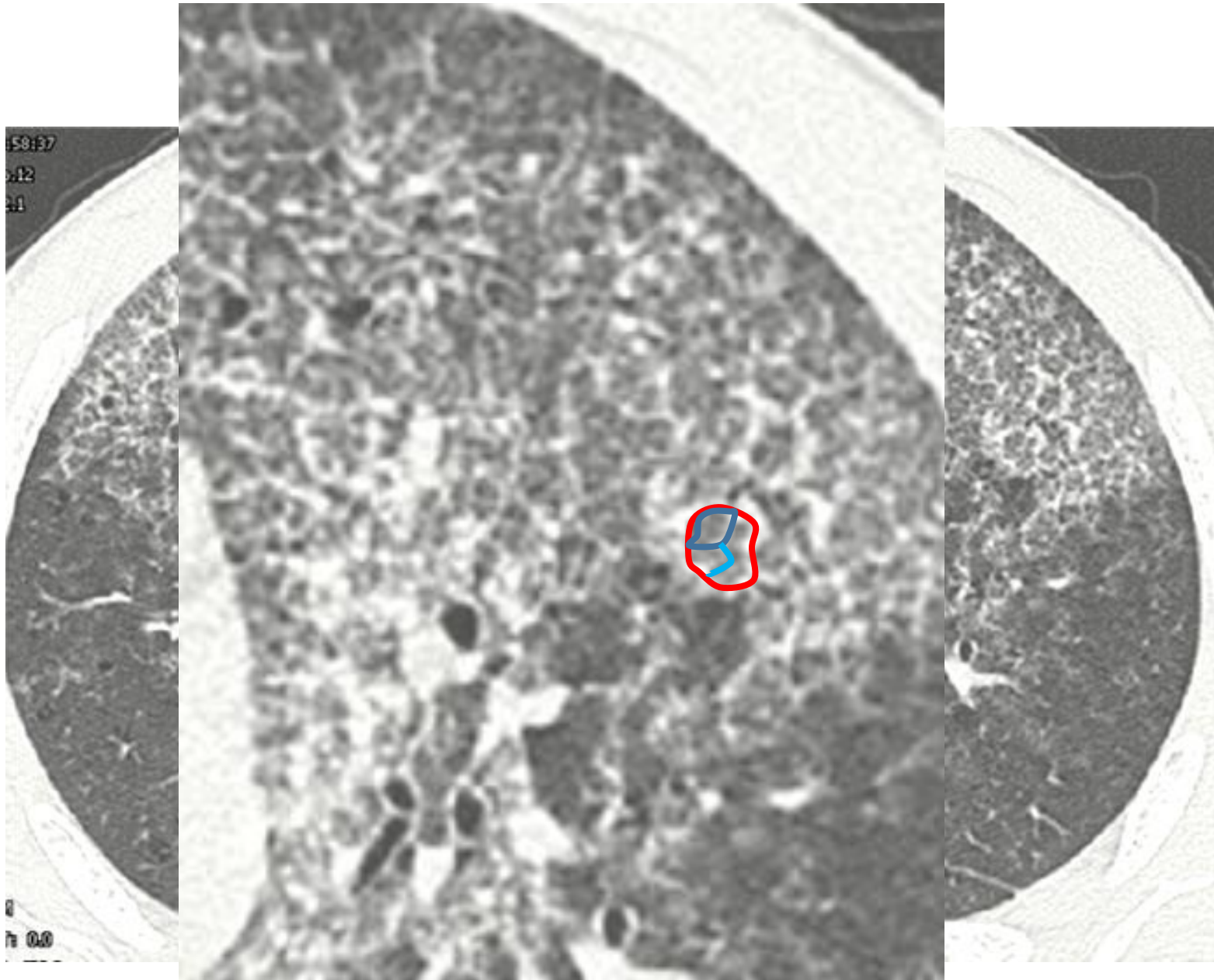


İnterlobüler septumda irregülarite ve volüm kaybı,
sentrlobüler bronşiolde dilatasyon ve kistler

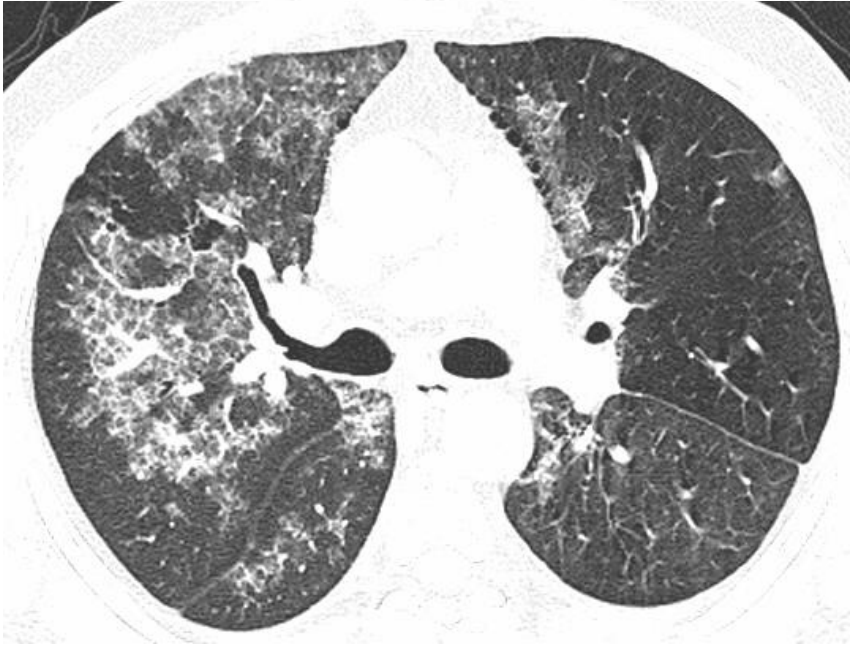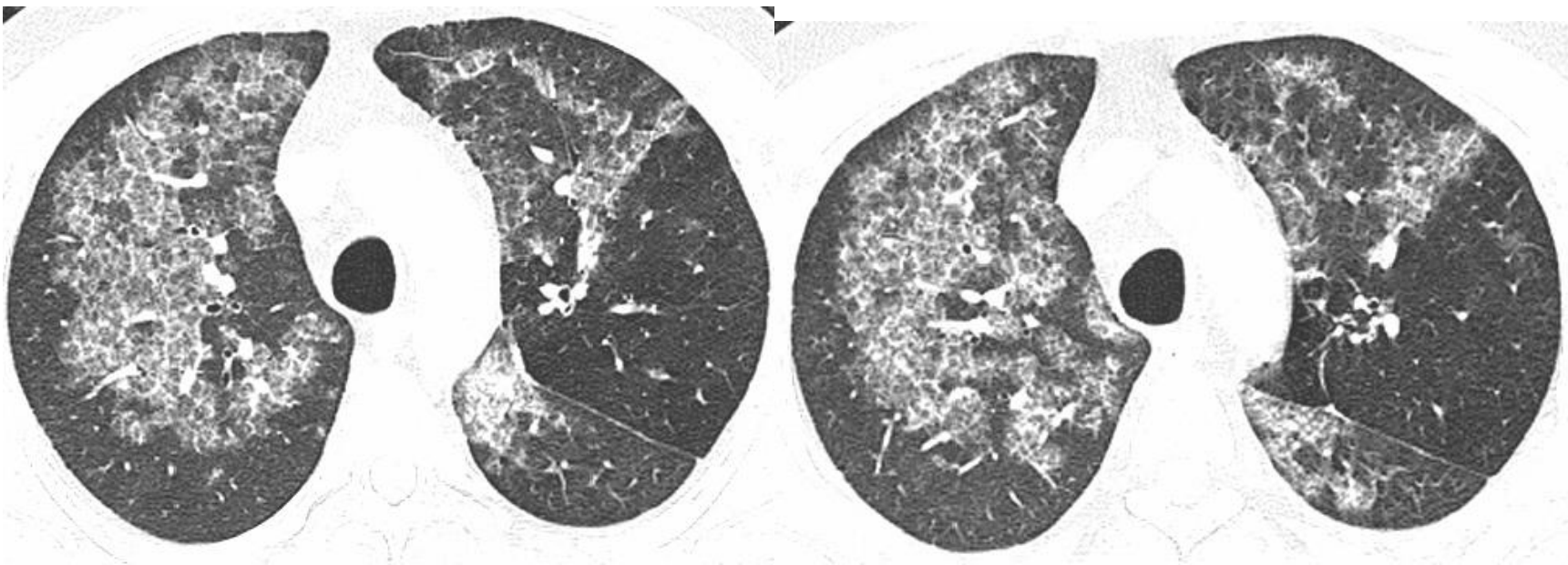
İntralobüler septal kalınlaşmalar

- Alveolar proteinozis
- Lenfanjitik met
- Ödem ve hemoraji
- UIP ve diğer interstisyel pnömoniler
- Kronik hipersensitivite pnömonisi
- Pnömoni...



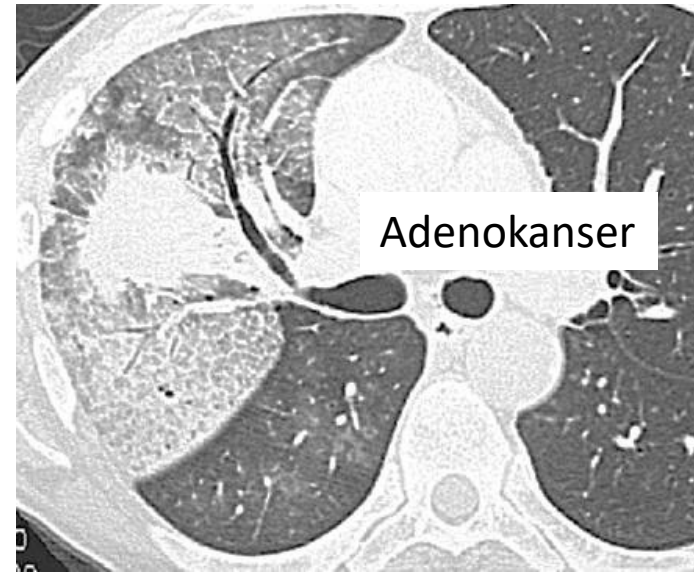
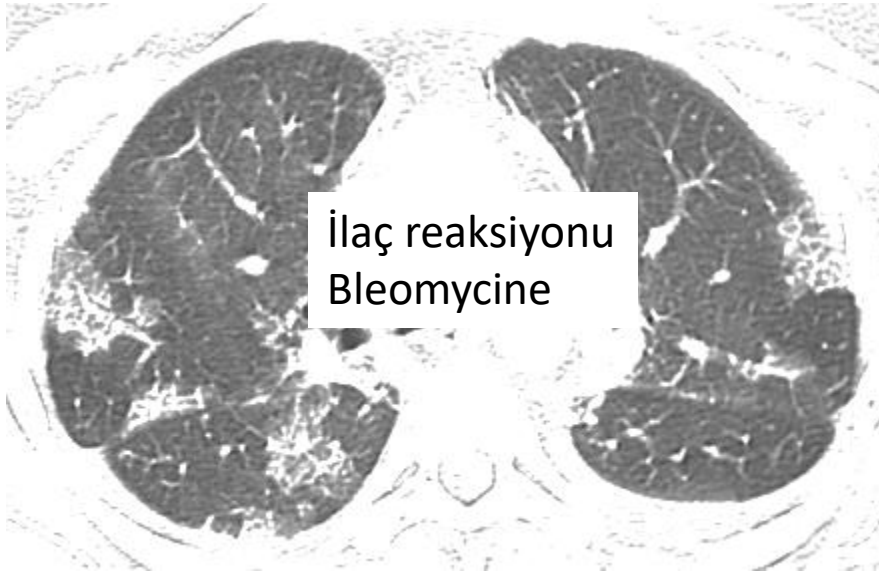
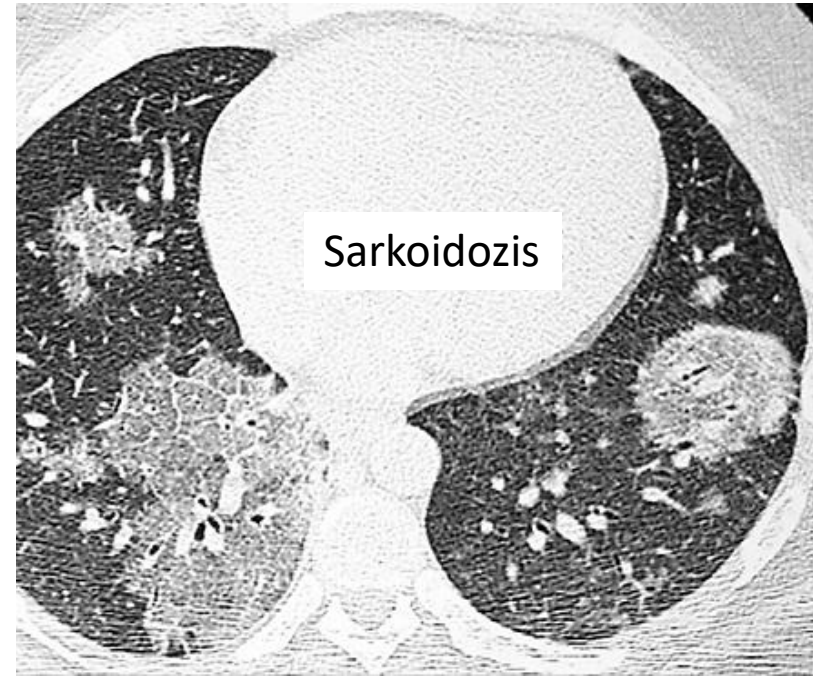
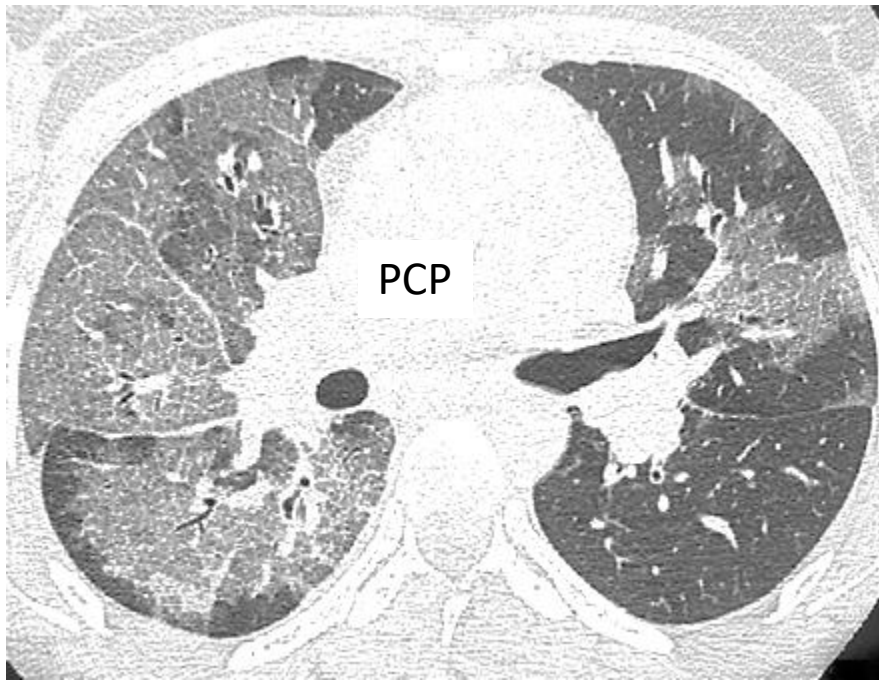


BUZLU CAM-SEPTAL KALINLAŞMA (İTER-İNTRA) BİRLİKTELİĞİ-



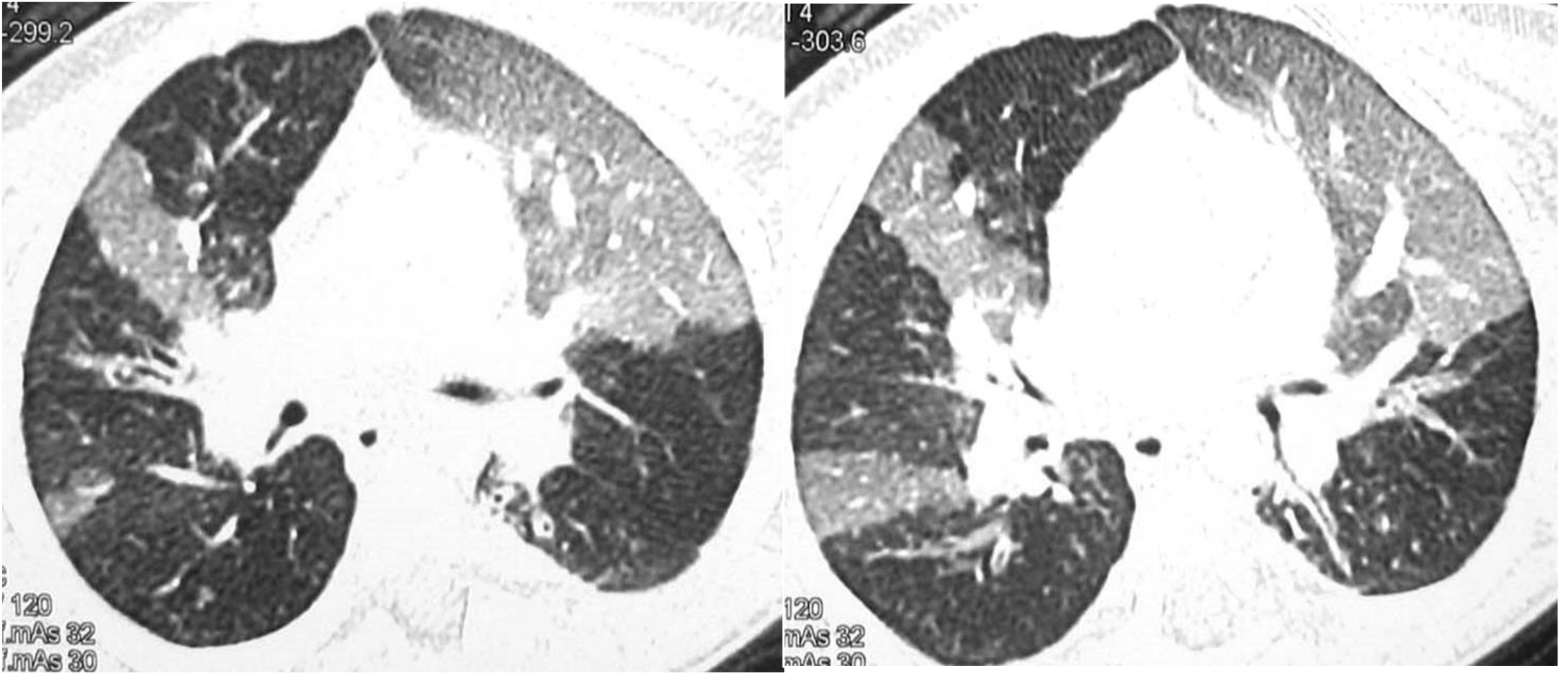
Alveoler proteinozis

(kaldırım taşı görünümü=
Buzlu cam+intralobüler
septal kalınlaşma)

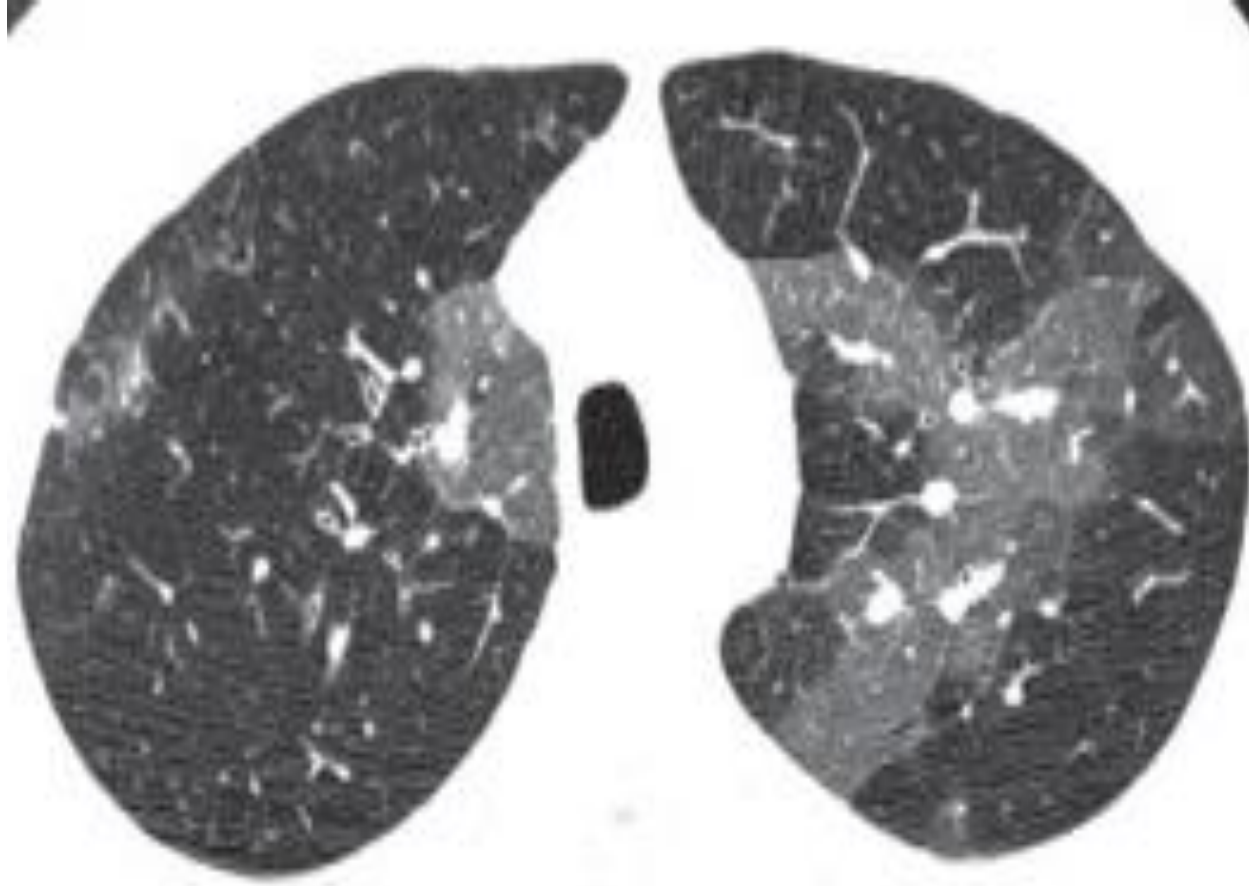


MOZAİK PERFÜZYON

- Akciğerde düşük ve normal dansite nedeniyle oluşan yamalı görünüm ve bu alanda vasküler yapıların seyrelip çapının azalması (mozaik atenuasyon, mozaik akciğer işareti gibi isimlerle anılır)
- İki nedenle oluşur:
 - A) Hava yolu daralması veya tıkanması ile (hava hapsi–hipoventilasyon–refleks vazokonstriksiyon)
 - B) Damar daralması veya tıkanması (inspiyumda düşük dansiteli alanlar ekspiyumda dansiteleri artar)



Mozaik perfüzyon



Mozaik Perfüzyon
Kr Pulmoner tromboemboli

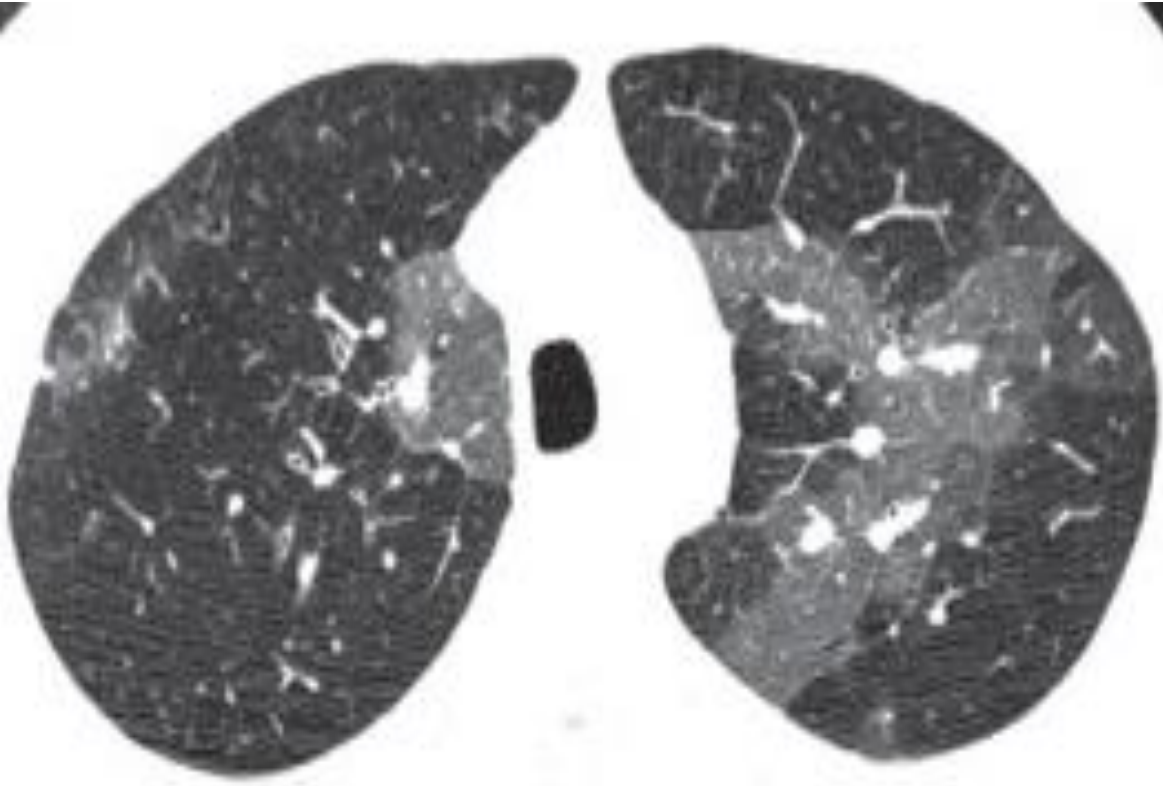
MOZAİK PERFÜZYON

HAVA YOLU HASTALIKLARI

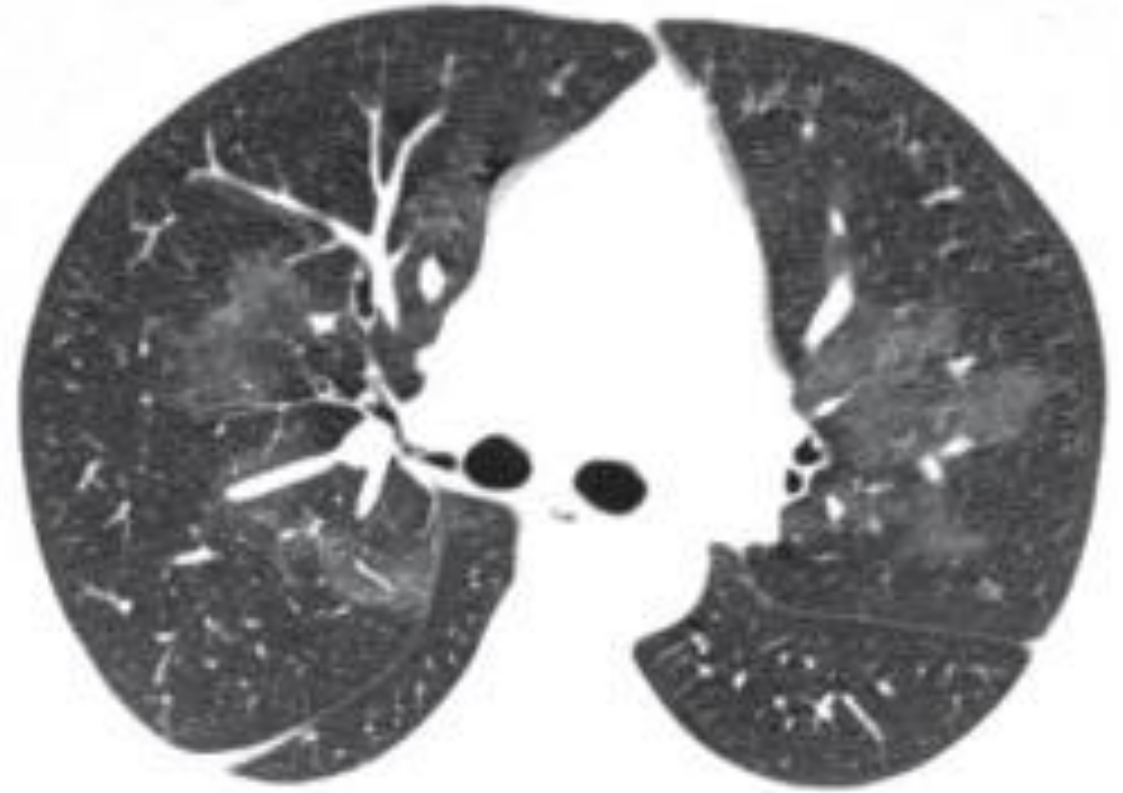
- Bronşiolitis obliterans
- Sarkoidozis
- Hipersensitiv. Pnomönisi
- AIDS
- LHH ve LAM
- Bronşioler spazm

VASKÜLER HASTALIKLAR

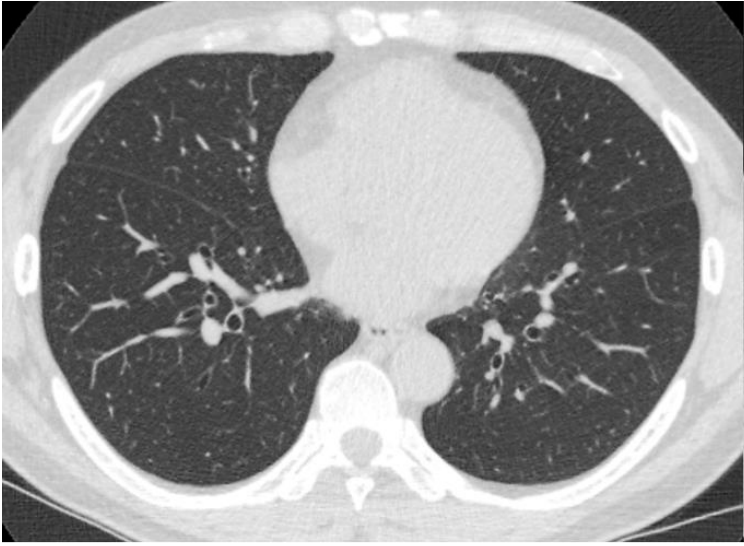
- Kronik pulmoner emboli
- Pulmoner hipertansiyon
(idiopatik veya kardiyojenik/
pulmoner nedenle)



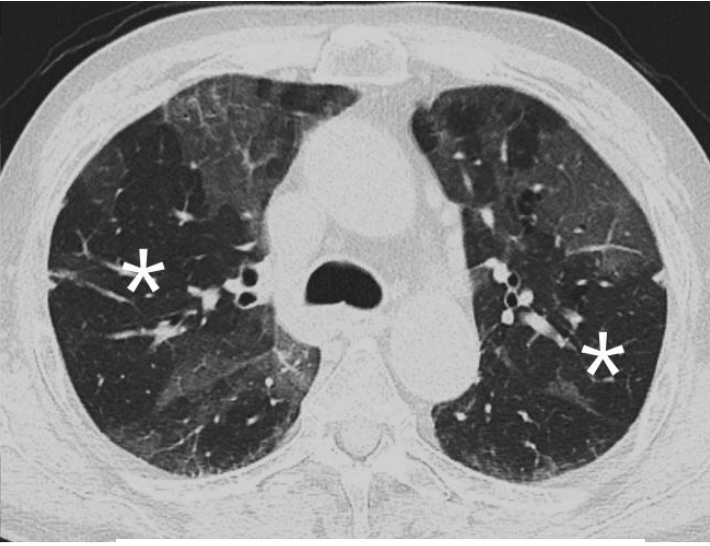

Mozaik Perfüzyon
Kr Pulmonertromboemboli



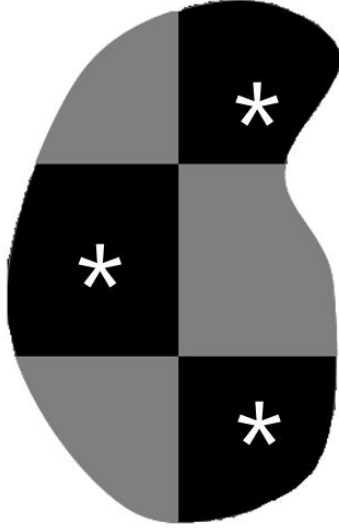
Buzlu cam
Pulmoner hemoraji



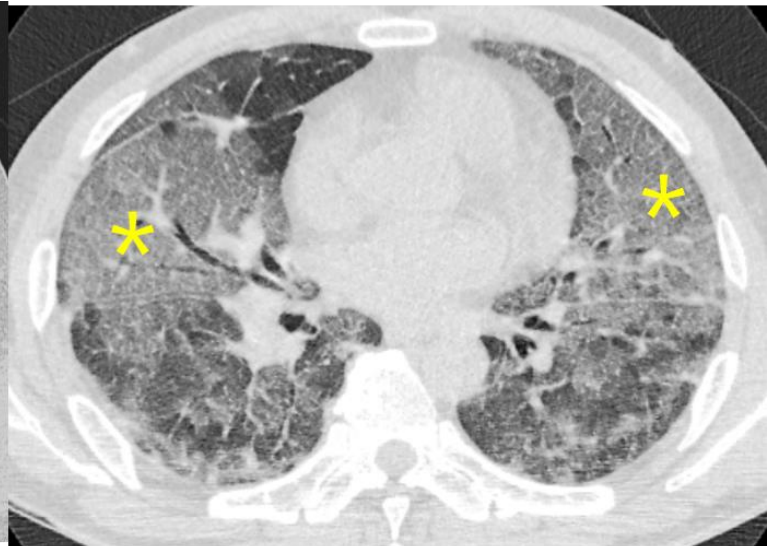
Normal akciğer




Mozaik Perfüzyon
Küçük hava yolu hastalığı



Kenarları keskin



Parankimal hastalık



SONUÇ:

- BT'de hastalıklara, öncelikle temel paternleri iyi tanımlama ile yaklaşılabilir
- Bu paternler hastanın yaşı, mesleği, cinsiyeti, mevcut hastalığı gibi klinik verilerle birleştirilir.
- Eğer sonuca gidilebiliyor ise kesin tanı; gidilemiyor ise olası / ayırıcı tanılar raporlanır.