

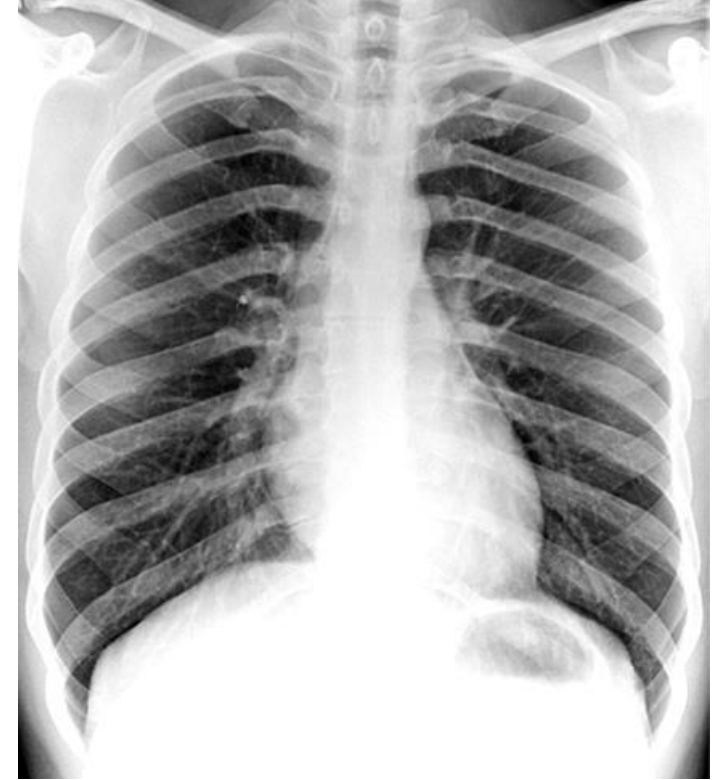AKCİĞER GRAFİSİ

Dr Recep SAVAŞ

Ege Üniversitesi Tıp Fakültesi Radyoloji AD, İzmir

Bakılacaklar için kontrol listesi

- Hastanın kimlik bilgileri (ad, yaş, cinsiyet)
- Filmin çekim tarihi
- Çekim pozisyonu (sağ, sol işareti vb)
- Hastanın pozisyonu (ayakta, yatarak, yan,vb)
- TEKNİK olarak filmi değerlendirme
- SİSTEMATİK yorumlama



Akciğer Radyogramında 5 Renk mevcut

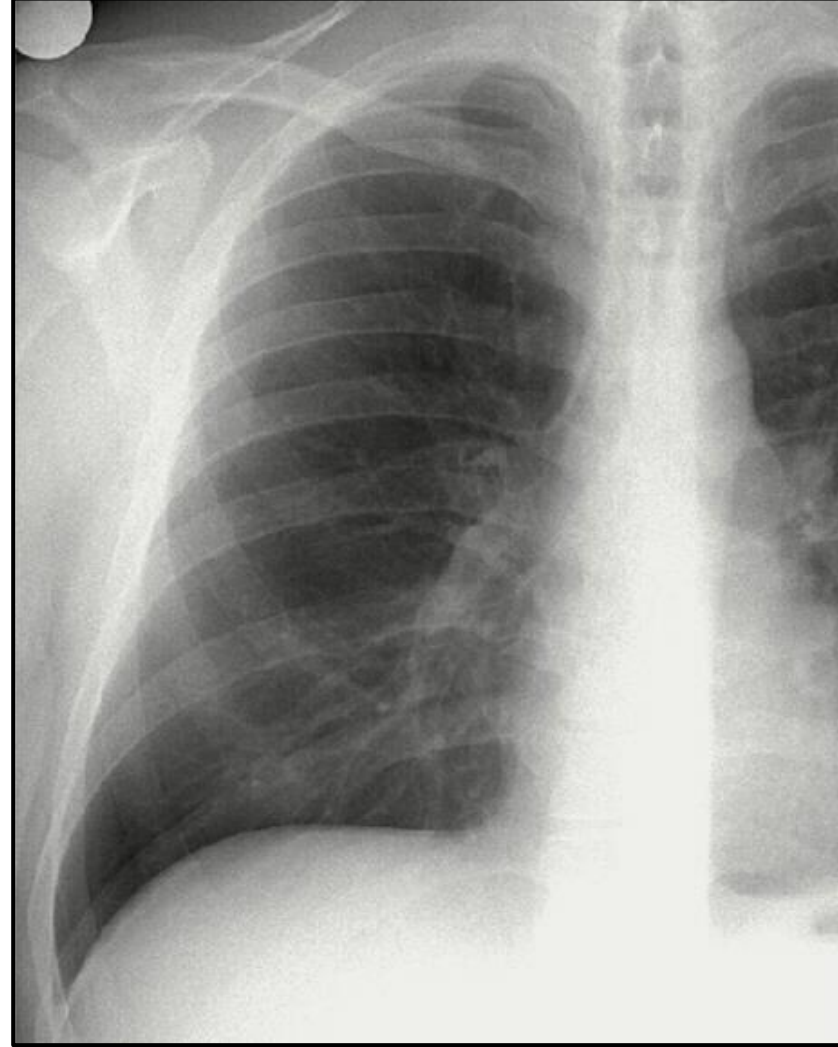
Metalik dansite

Kemik dansitesi

Su dansitesi

Yağ dansitesi

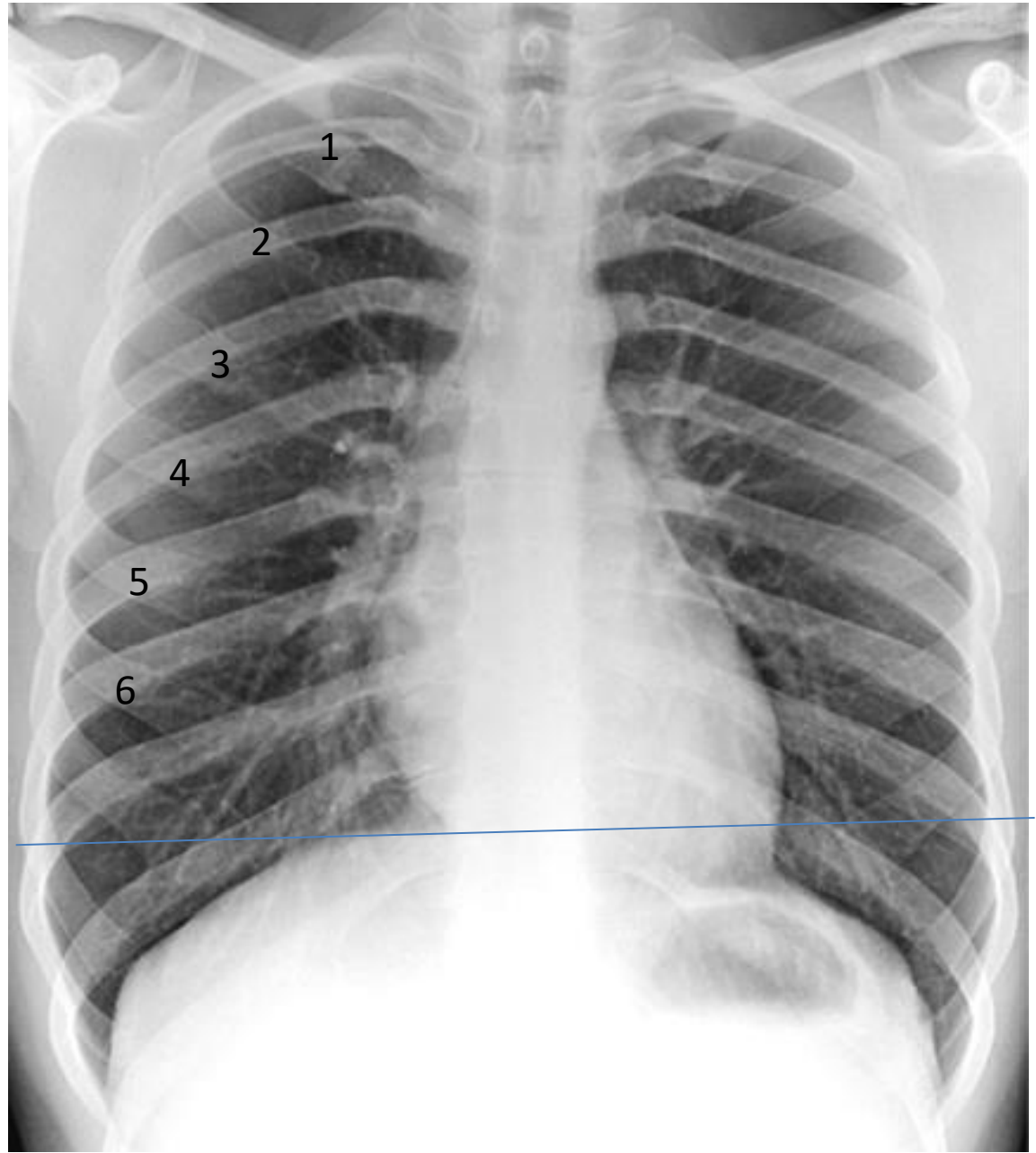
Hava Dansitesi

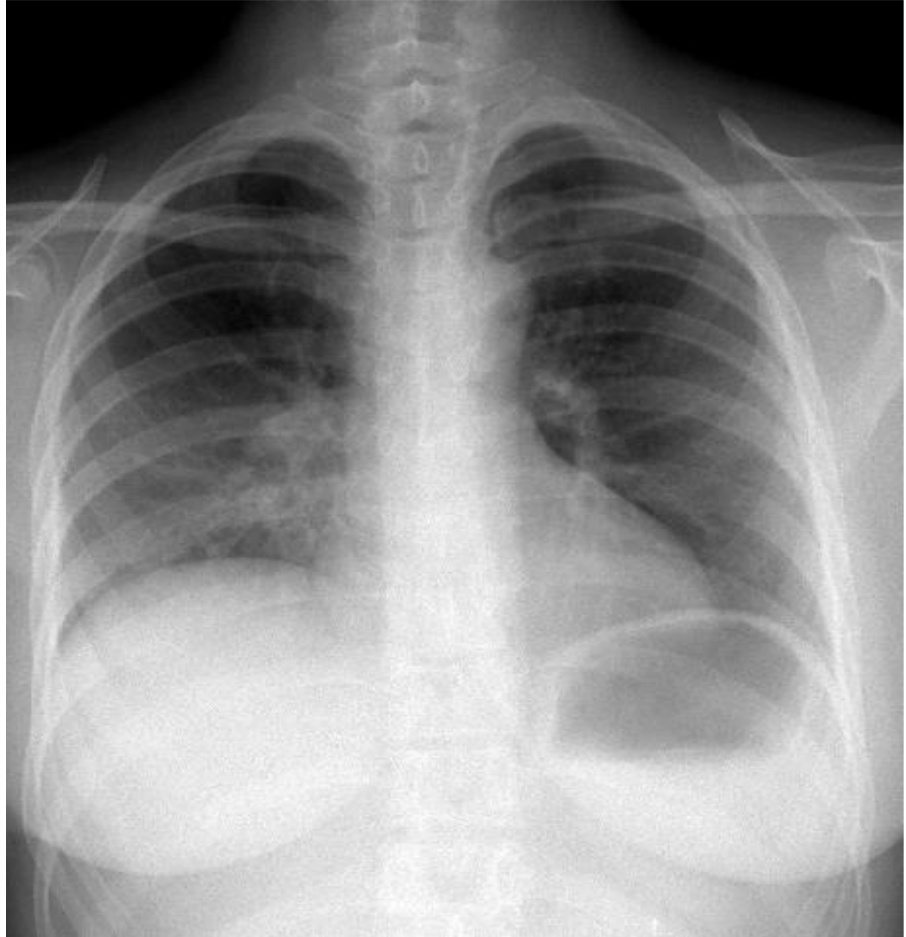
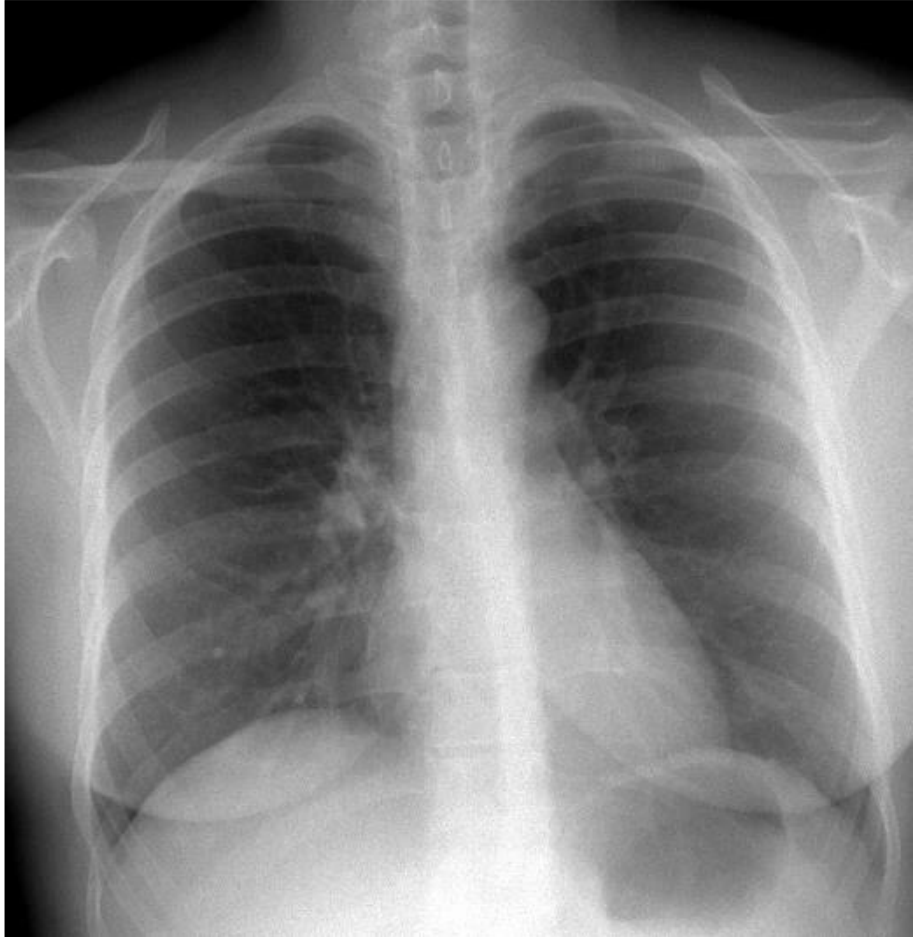


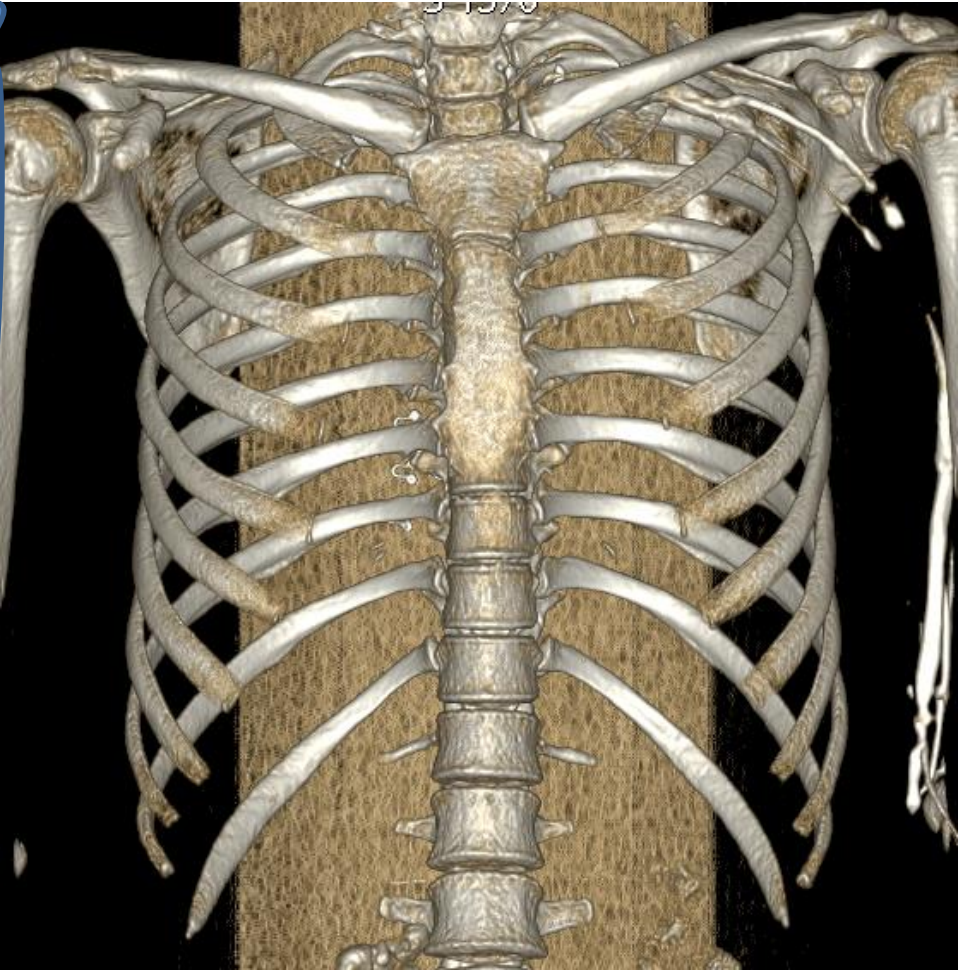
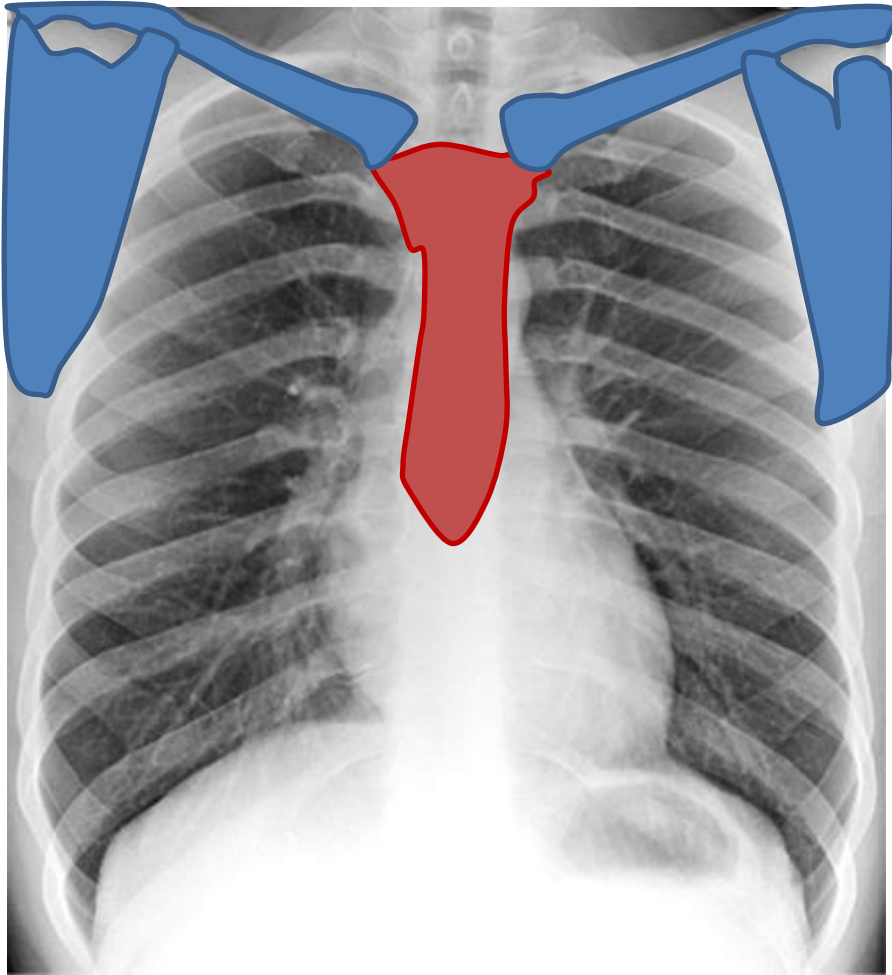
FİLMİN TEKNİK OLARAK DEĞERLENDİRİLMESİ:

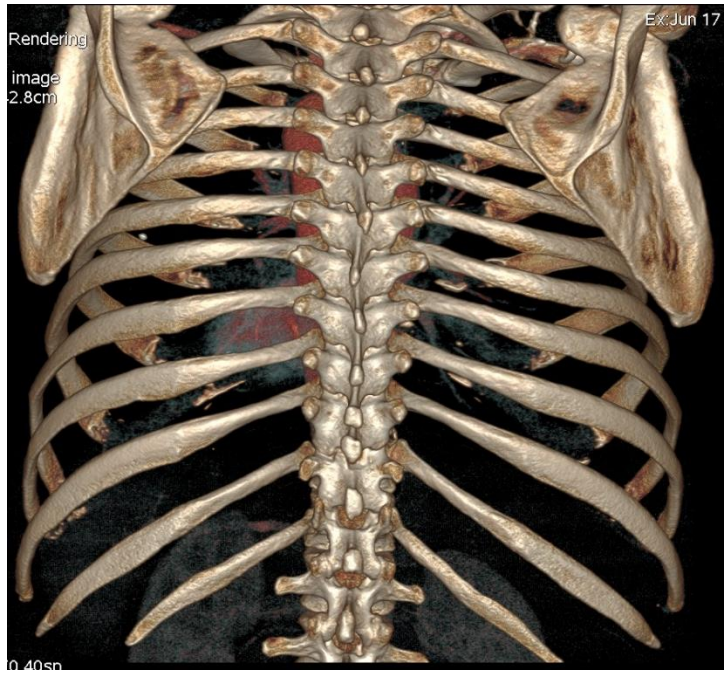
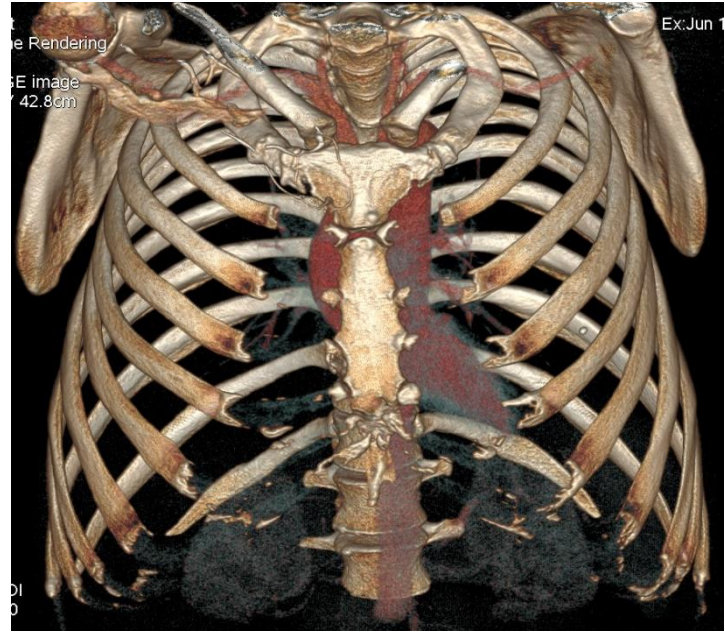
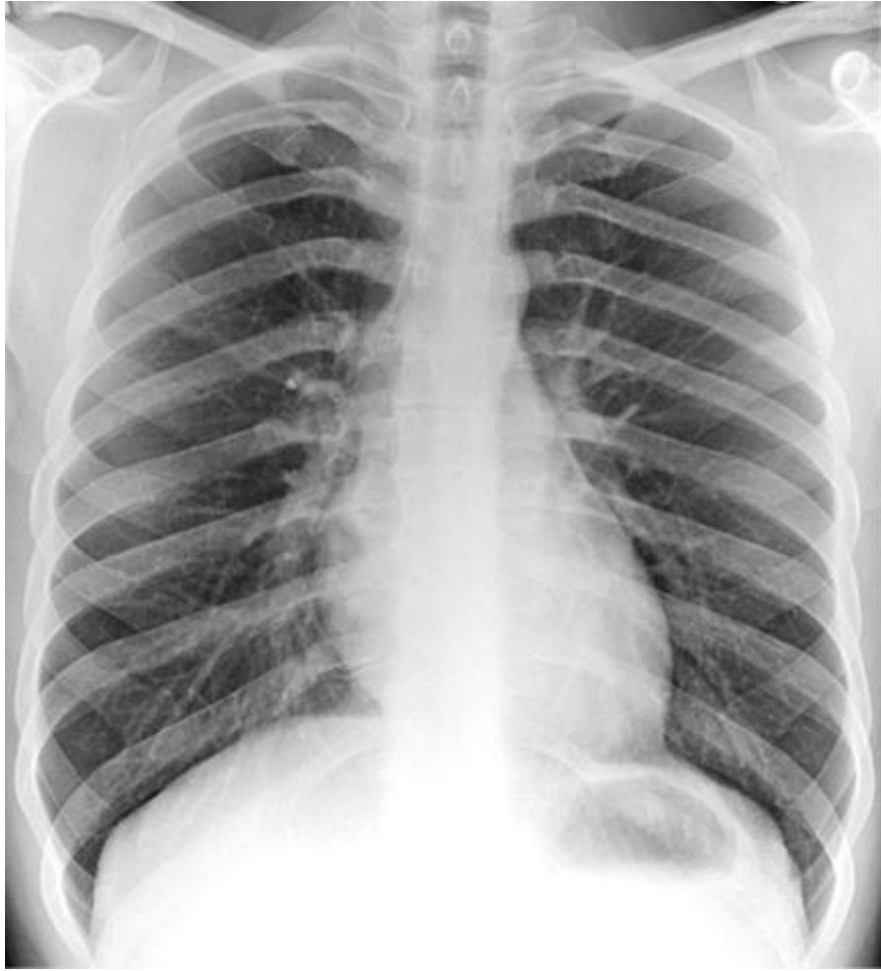KALİTE KONTROL

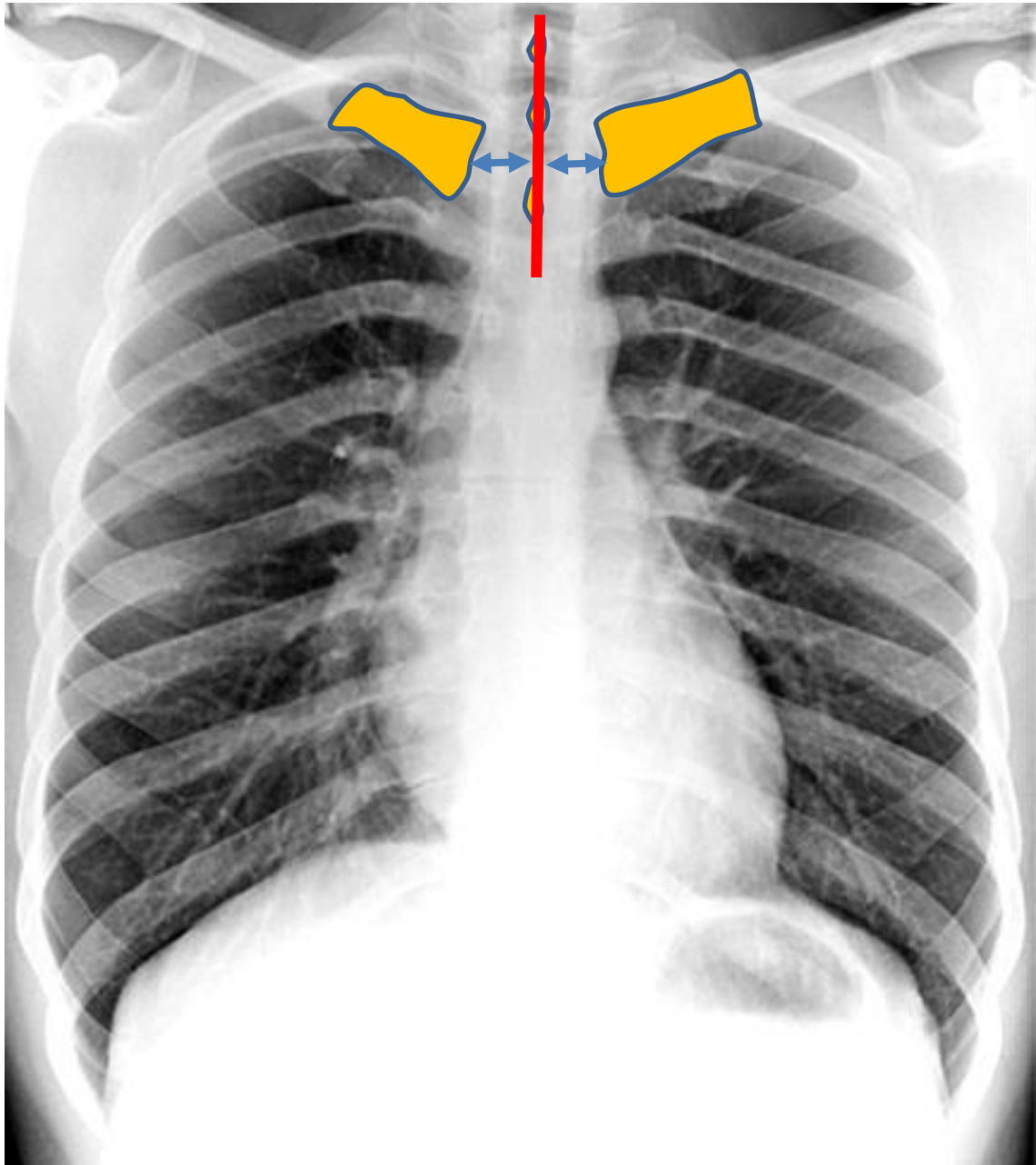
- Grafinin kapsamı
- Hastanın pozisyonu
- Dansite
- İnciriyum

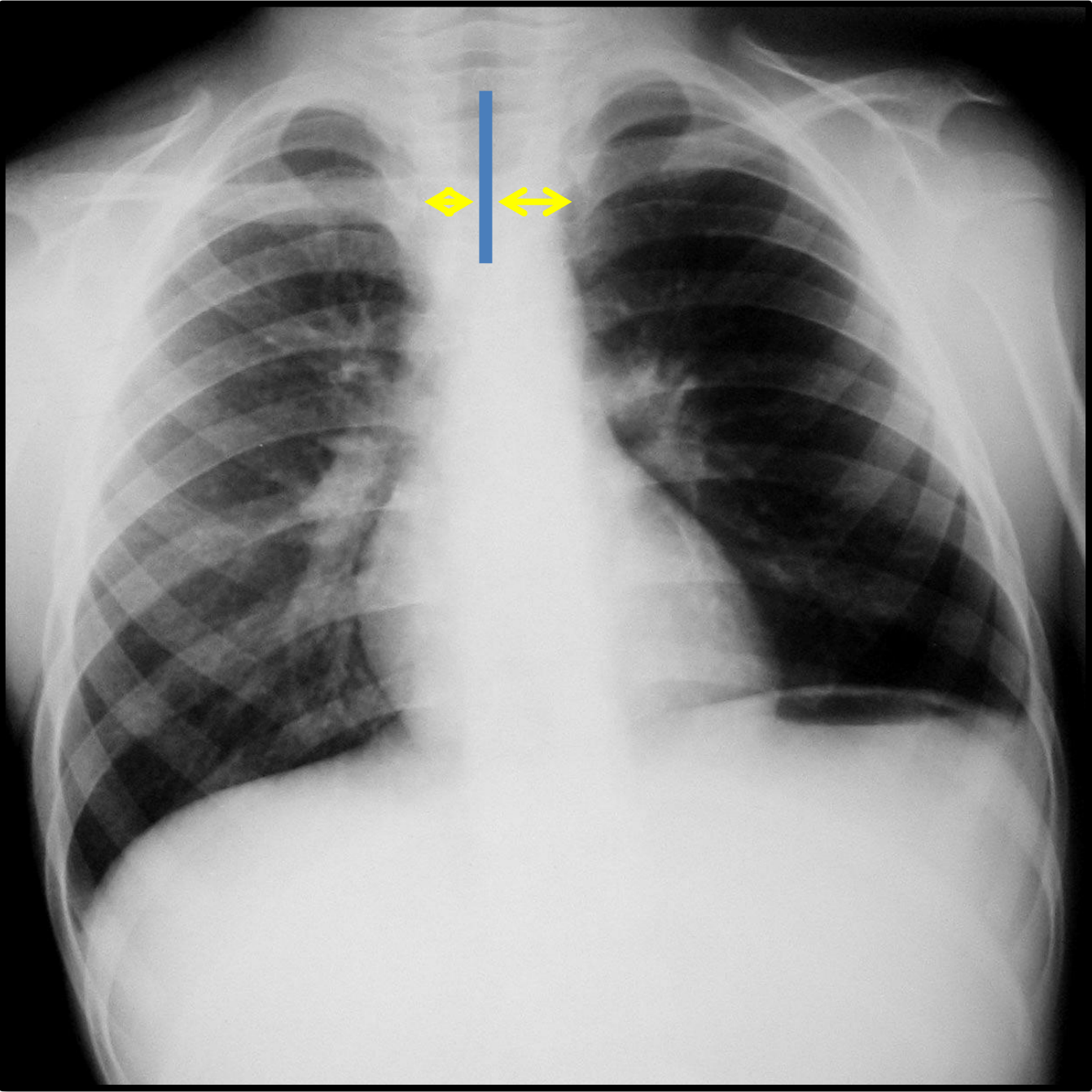




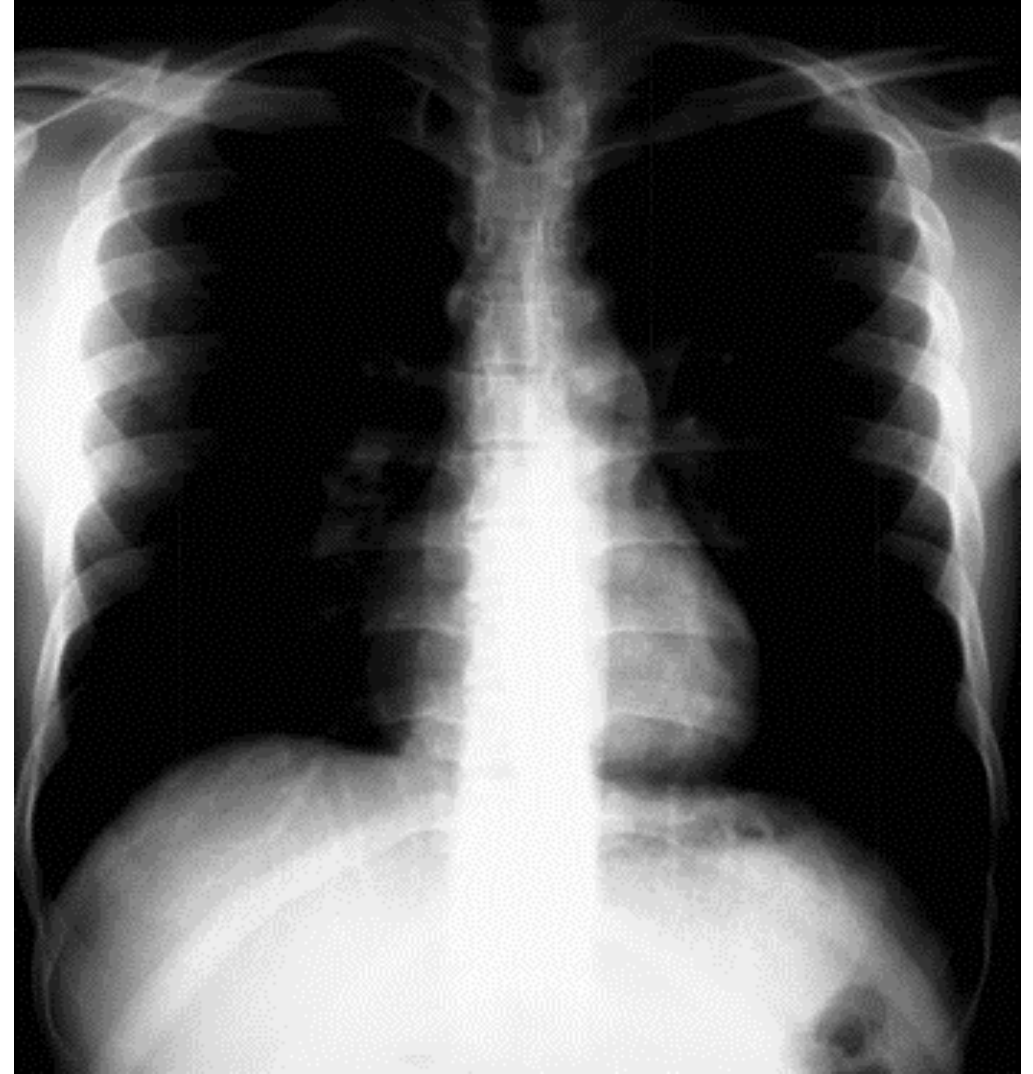
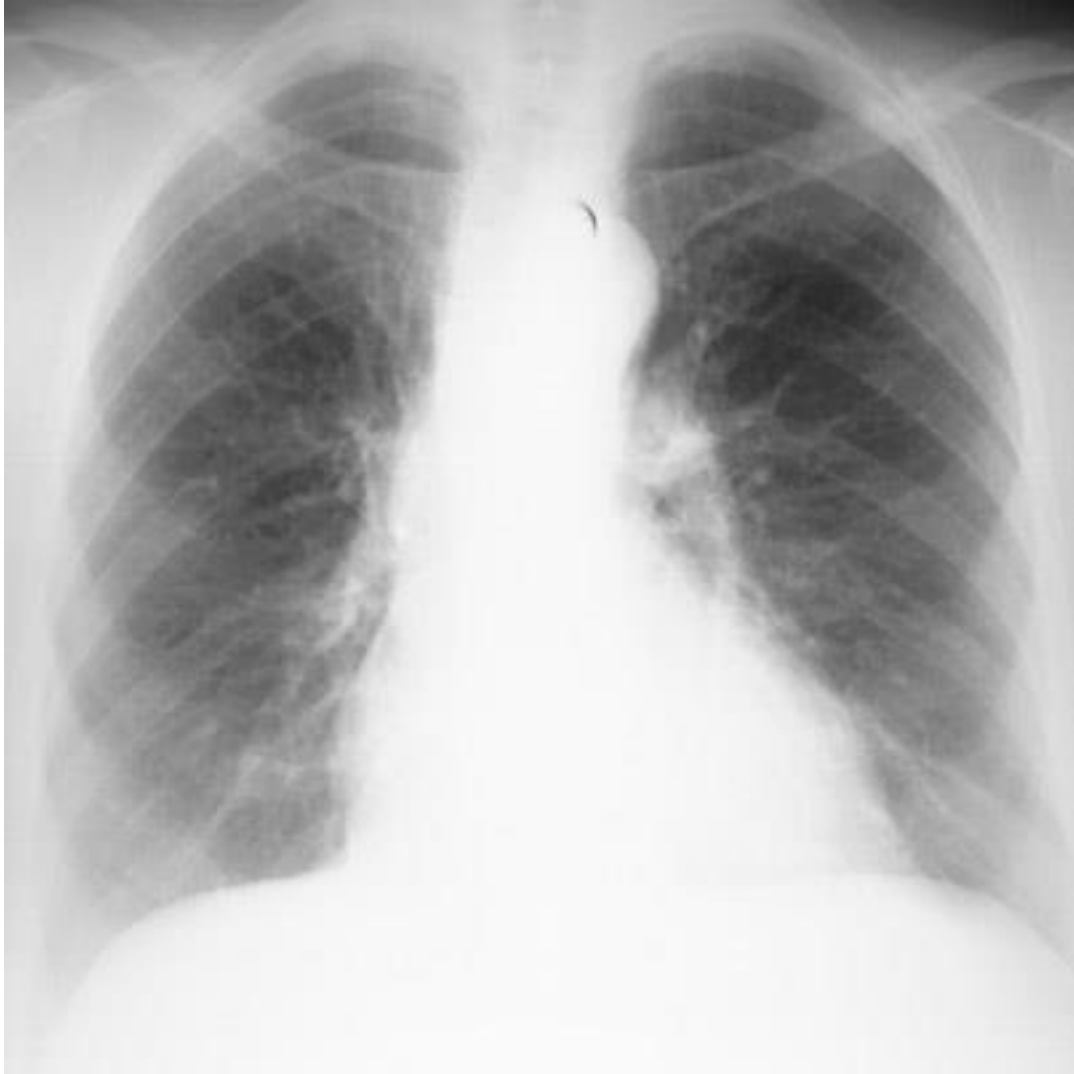

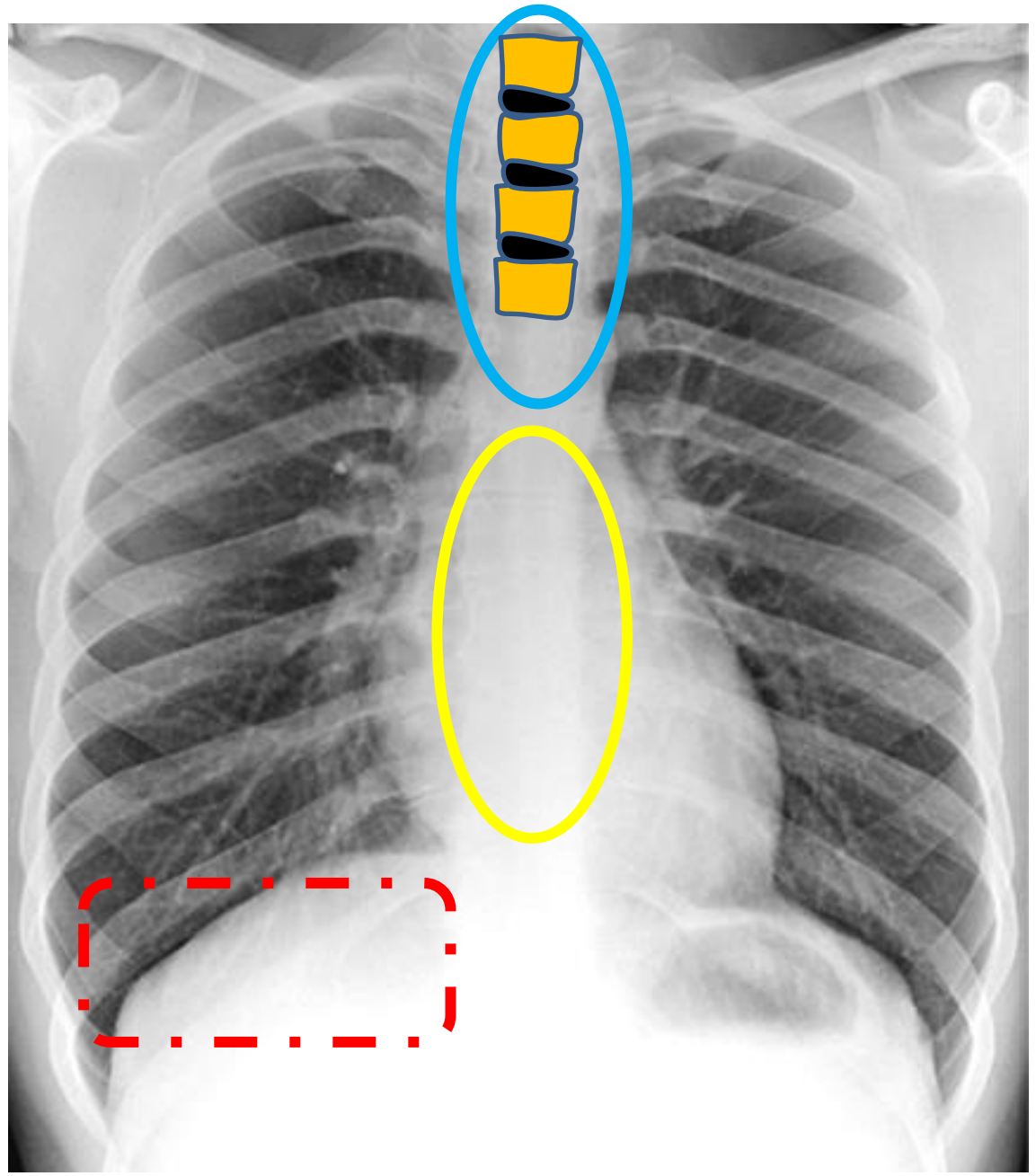






Doz kontrolü







Filmi Yorumlama

- Subjektif görüntüler oluşturarak gerçek dansiteyi görmeyebiliriz.

YALANCI Akciğer nodülü
Kavitasyon



Burada beyaz çizgisiz üçgen siyah çizgili üçgen üzerine süperpoze oluyor diye yorumlanabilir.
Aslında olay 3 tane çizgi şeklinde V ve 3 tane daire şeklinde V'den oluşmaktadır



Kısa çizgilerden oluşan bu görüntüde çoğu kişi çizgiler arasında küçük yuvarlak opasiteler oluşturabilir.

SAKLI ALANLAR (Kör noktalar)





Sistemik bakı ile

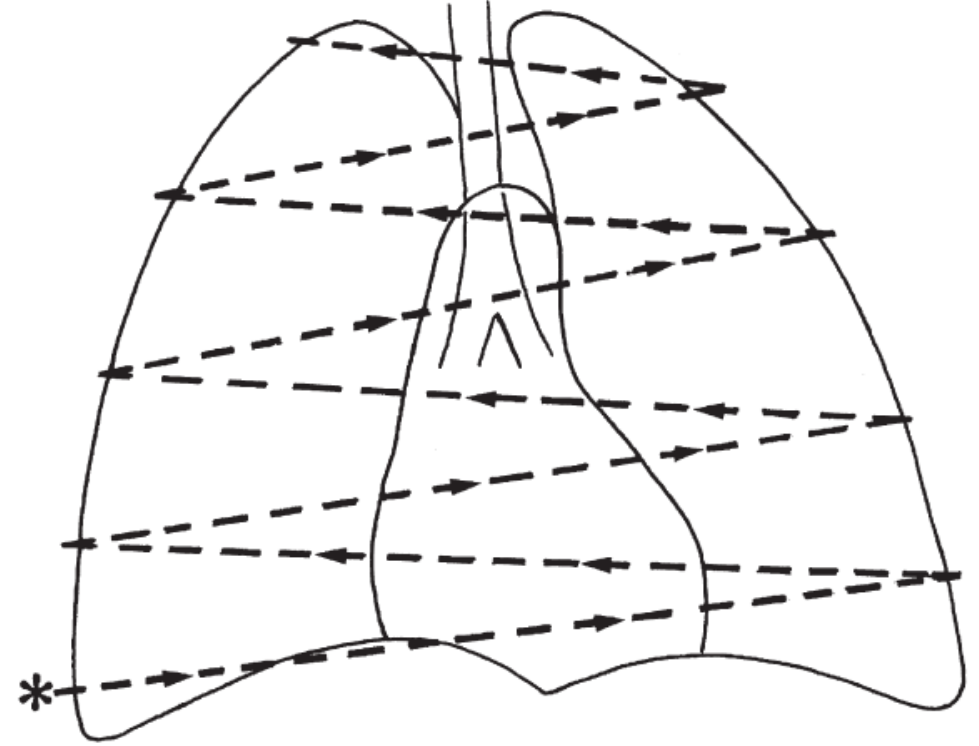
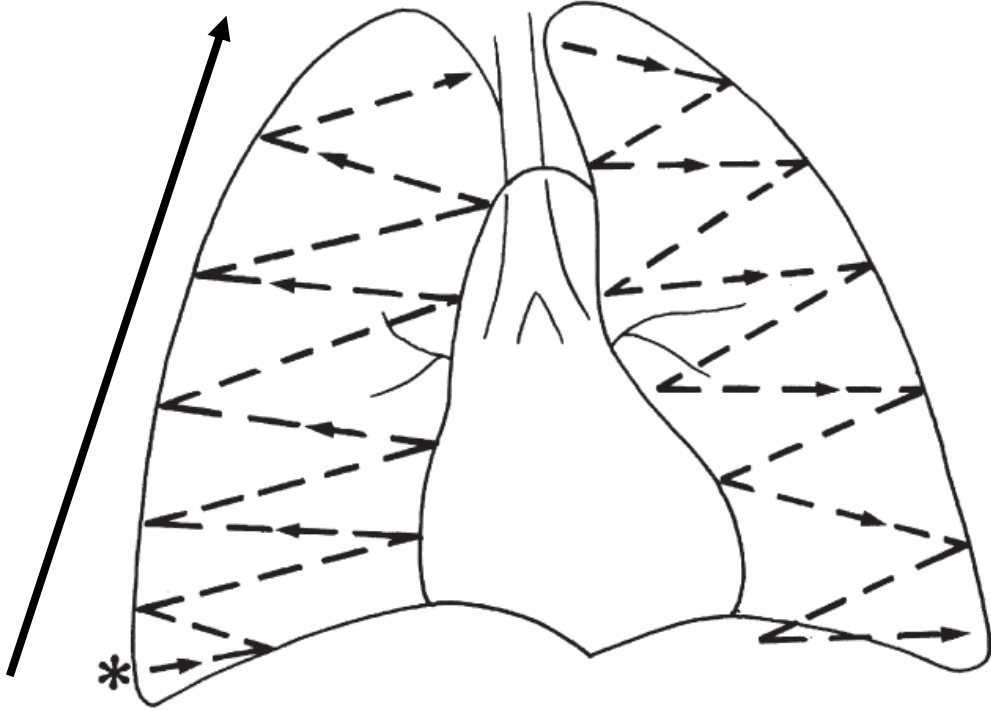
- Trakea, sağ paratrakeal çizgi
- Ana bronşlar
- Kalp ve mediasten
- Hiluslar
- Parankim alanları ve özellikle saklı alanlar (akciğerin apeksleri ve bazaller)
- Plevral boşluk, diyafram
- Kemik ve yumuşak dokular

NELER GÖRÜLEBİLİR?

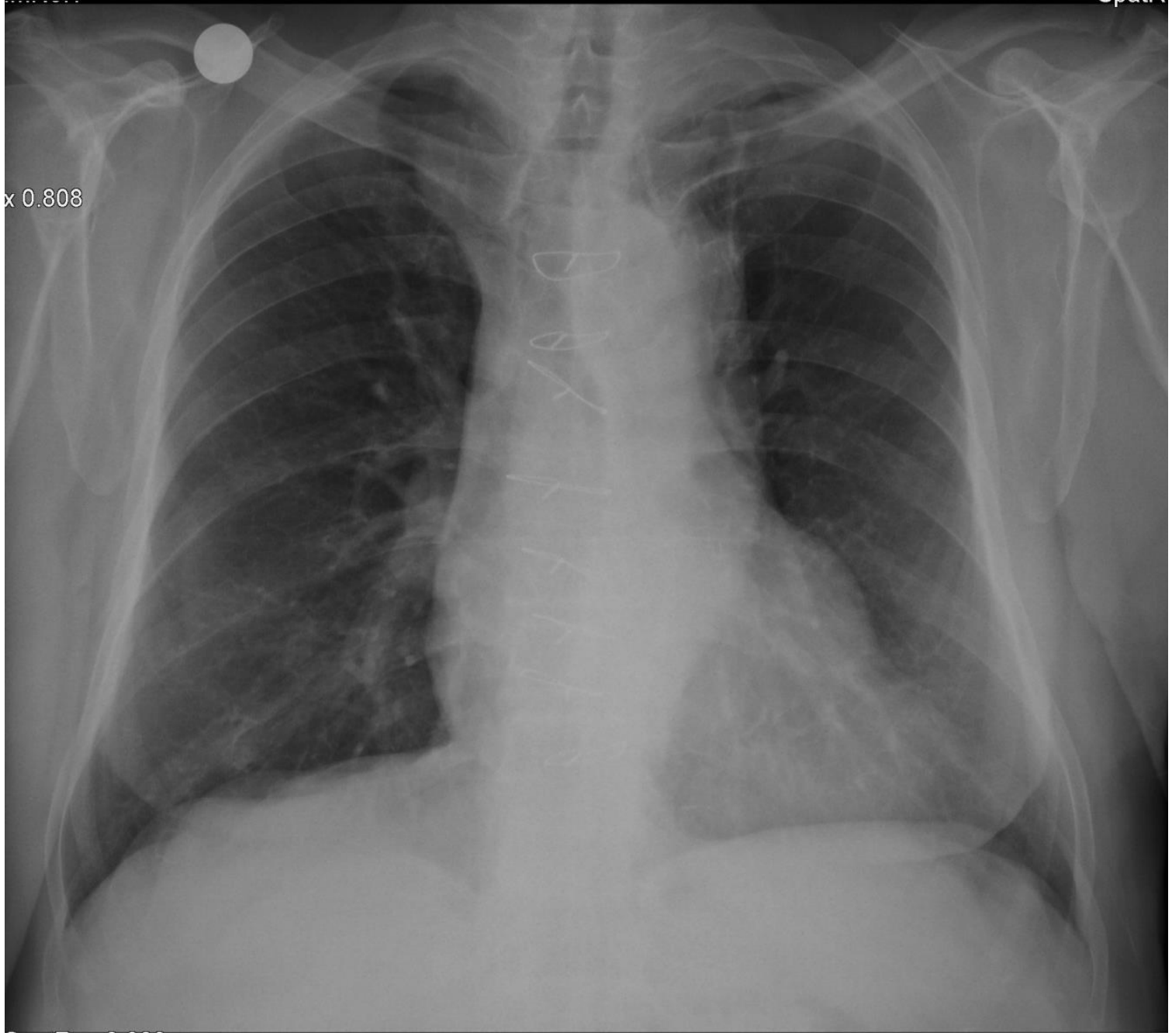
- Pnömoni
- Plevral sıvı / hava (pnömotoraks)
- Nodül veya kitle (genelde 1 cm den büyük ise)
- Atelektazi
- Kalsifik odaklar
- Kalp büyümesi
- Göğüs duvarını tutan lezyonlar (kırık, tümör vb)
- İndirekt bulgular ile diğer lezyonlar

NELER GÖRÜLEMEZ?

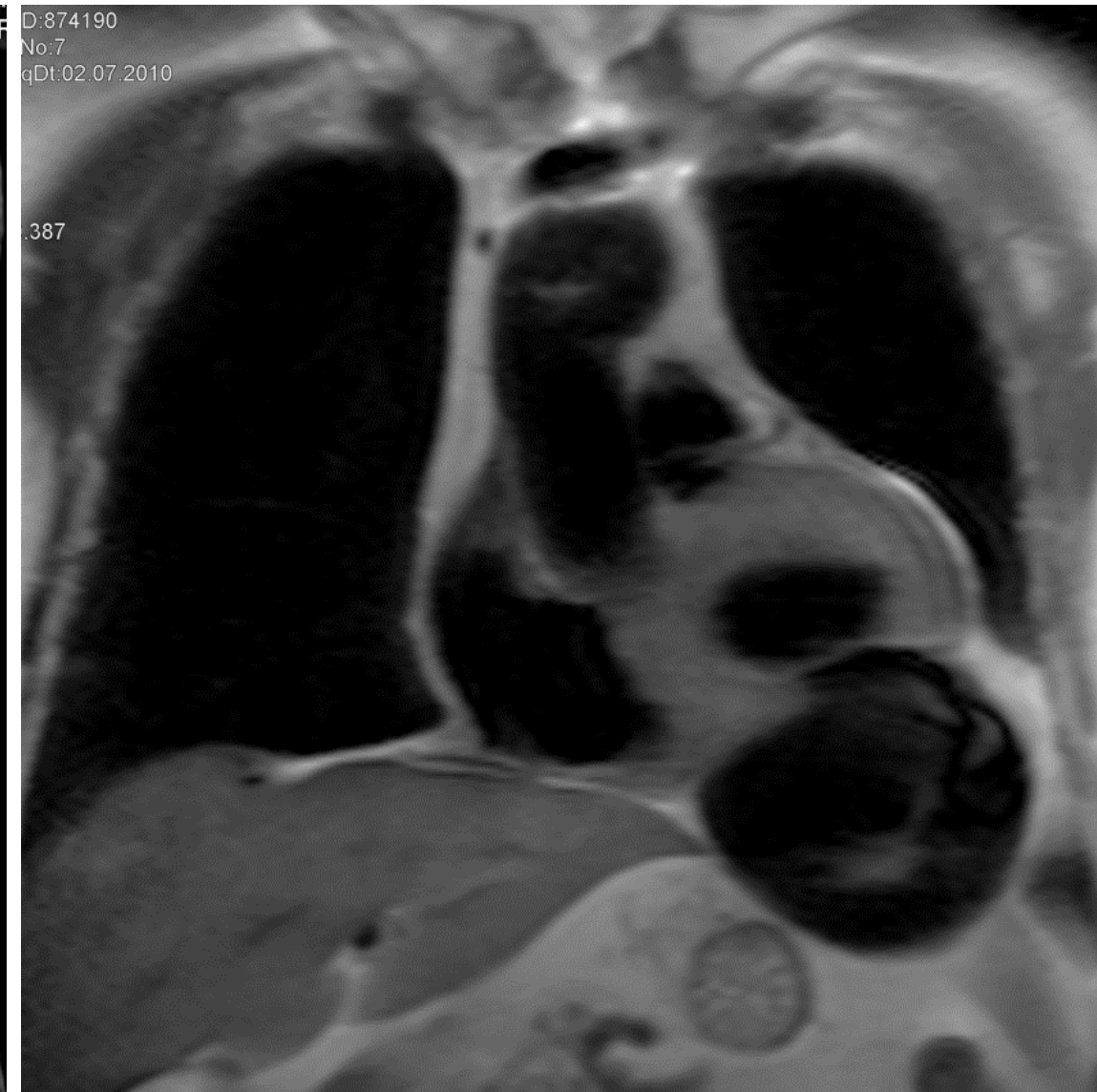
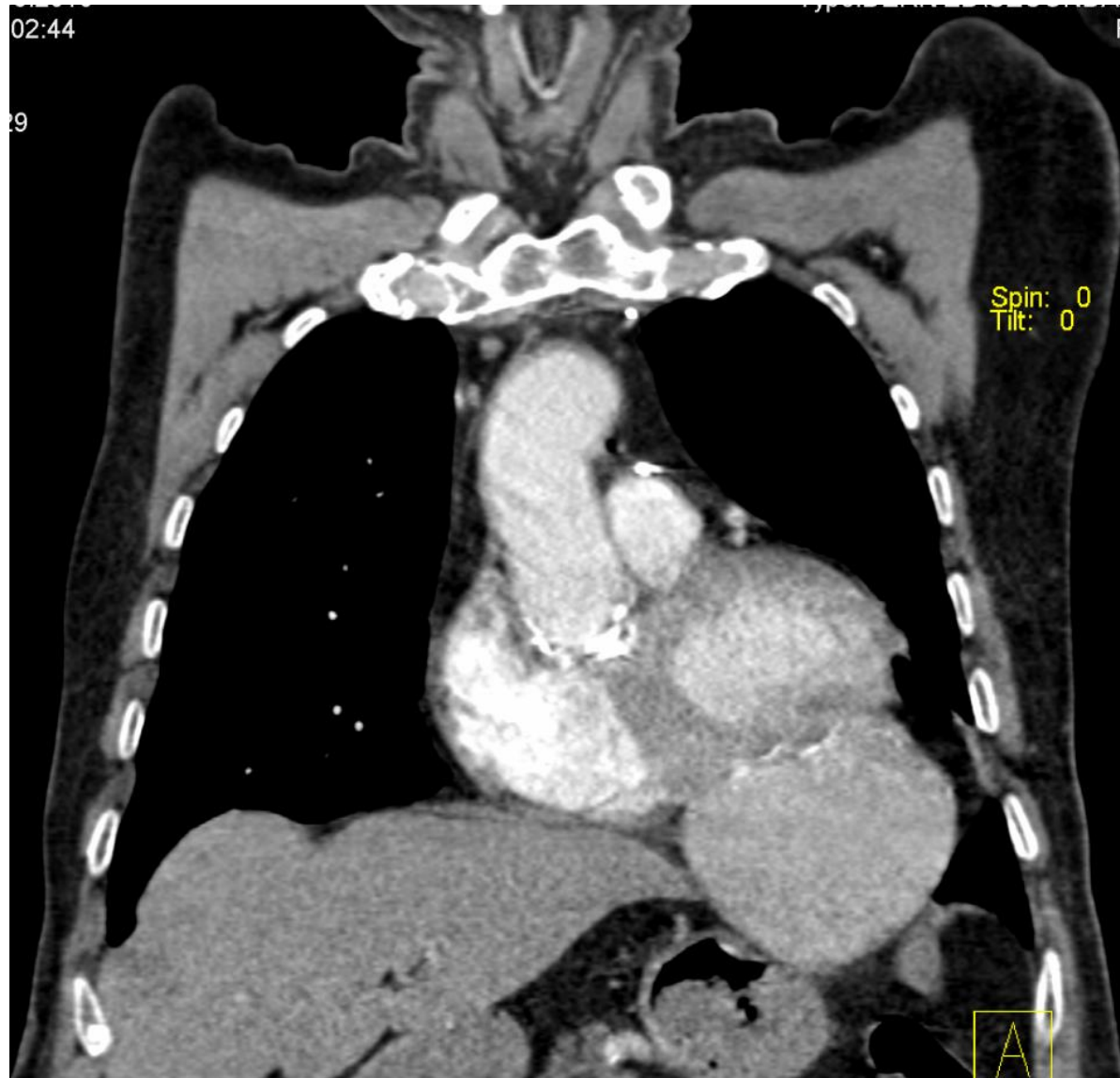
- Küçük lezyonlar (milimetrik)
- Pulmoner emboli, diseksiyon gibi damar içi veya kalp içi lezyonlar
- Dansitesi çok düşük olan lezyonlar
- Küçük pnömotoraks, az miktarda plevral sıvı
- Anatomik olarak değişiklik oluşturmayan ama organın iç yapısında bozukluğa neden olmuş her tür hastalık (dansite değişikliği yapmamış)



Önerilen bakma tarzı

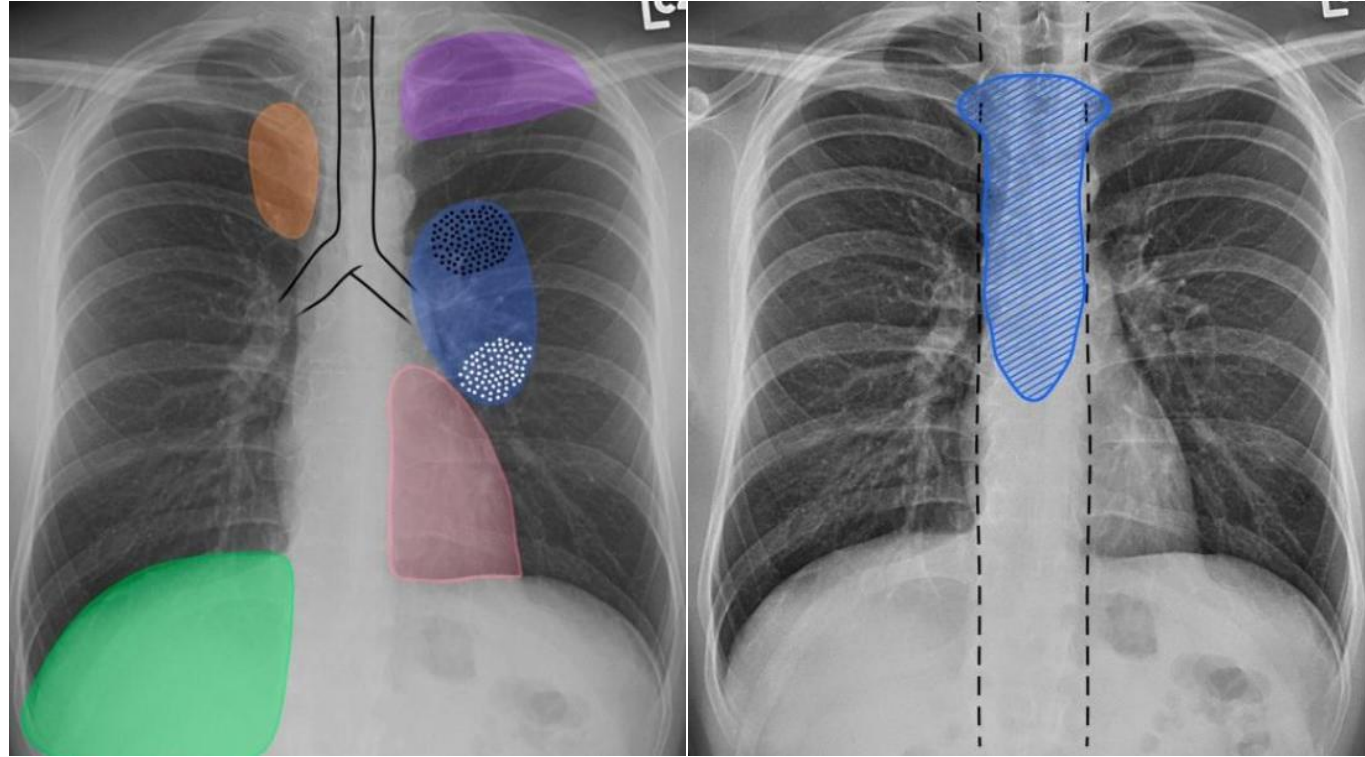


x 0.808



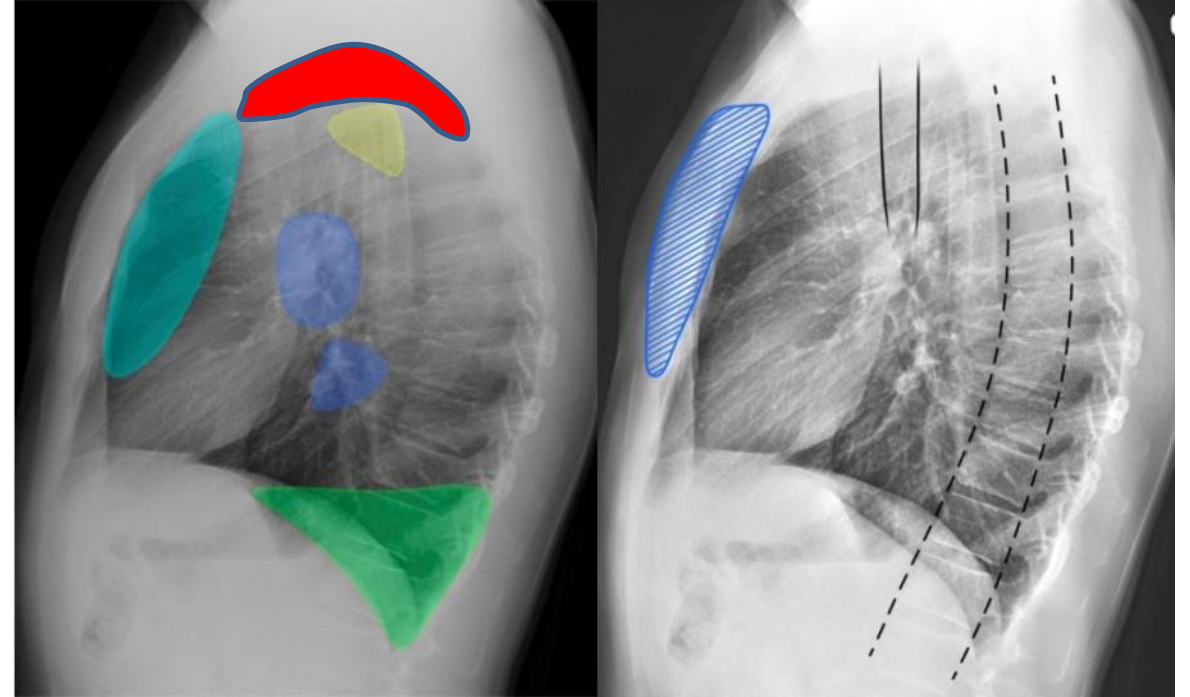
PA AKCİĞER GRAFİSİ İÇİN KÖR NOKTALAR:

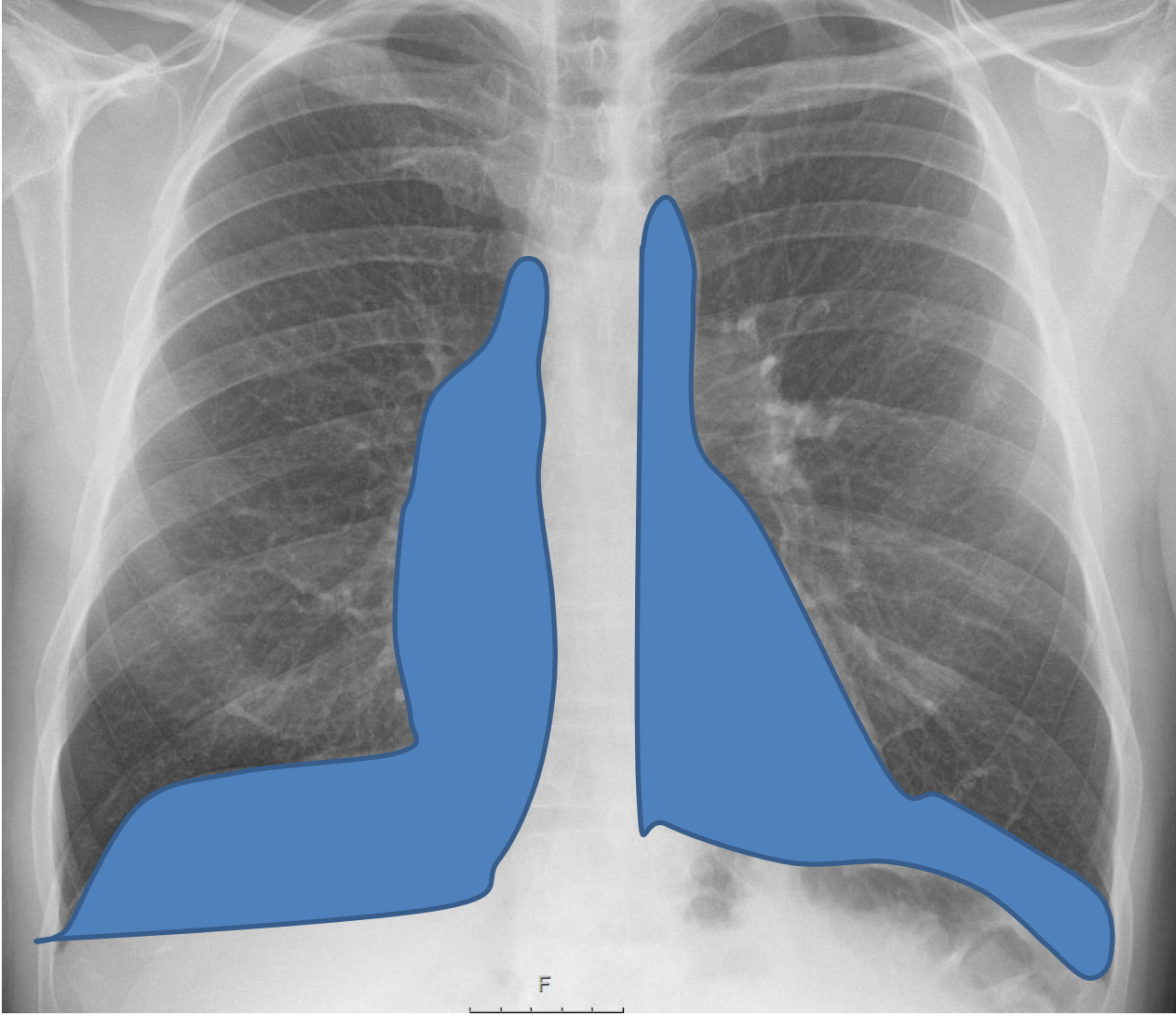
- Akciğerin apeksleri
- Sternal/Retrosternal bölge
- Mediasten/özellikle retrokardiyak bölge
- Parahiler alan
- Akciğerin bazalleri
- Göğüs duvarı



LATERAL AKCİĞER GRAFİSİ İÇİN KÖR NOKTALAR:

- Akciğerin apeksleri
- Retrosternal alan
- Hiluslar
- İnfrahiler bölge
- Posterior kostofrenik sulkus
- Göğüs duvarı ve kemik yapılar





Akciğer volümünün ortalama % 26.4 ü kardiyak, mediastinal ve subdiyafragmatik yapılar tarafından kapatılır.

AKCİĞERİN

ELEMENTER/ TEMEL LEZYONLARI

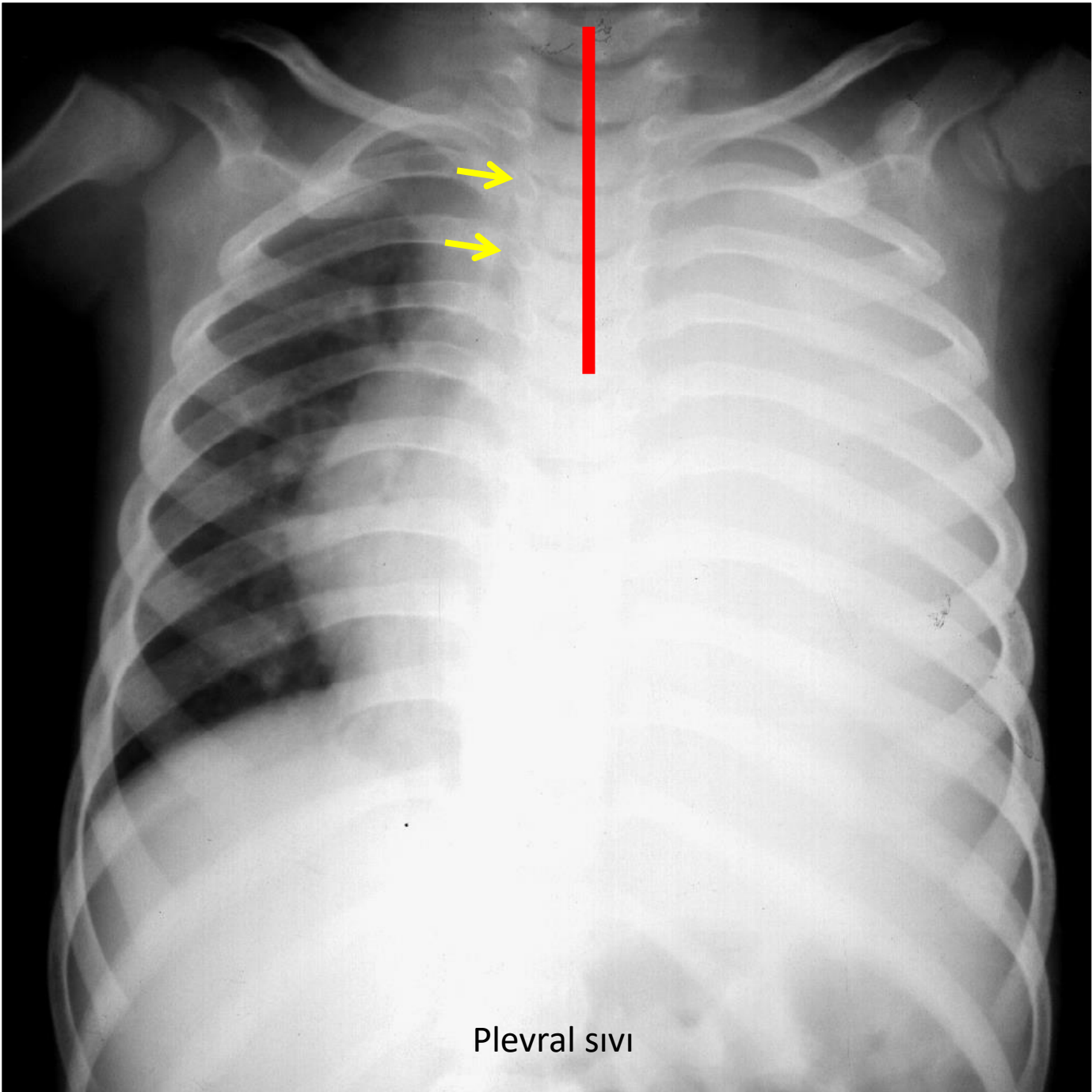
- Opak akciğer
- Konsolidasyon
- Atelektazi
- Nodül/kitle (tek veya çoklu)
- Miliyer/Lineer/retiküler dansite artışı
- Yüksek dansiteli (kalsifik/ossifik) lezyonlar
- Hiperlusen akciğer
- Kistik /kaviter lezyonlar

AKCİĞERİN

ELEMENTER/ TEMEL LEZYONLARI

- Opak akciğer
- Konsolidasyon
- Atelektazi
- Nodül/kitle (tek veya çoklu)
- Miliyer/Lineer/retiküler dansite artışı
- Yüksek dansiteli (kalsifik/ossifik) lezyonlar
- Hiperlusen akciğer
- Kistik /kaviter lezyonlar

OPAK AKCIĚER (Tek hemitoraks)



Plevral sıvı

OPAK AKCİĞER

- Trakea orta hatta

- Konsolidasyon

- Ödem /ARDS

- Plevral kitle

- Göğüs duvarı lezyonu

- Trakea opak tarafa çekilmiş

- Pnöminektomi

- Kollaps

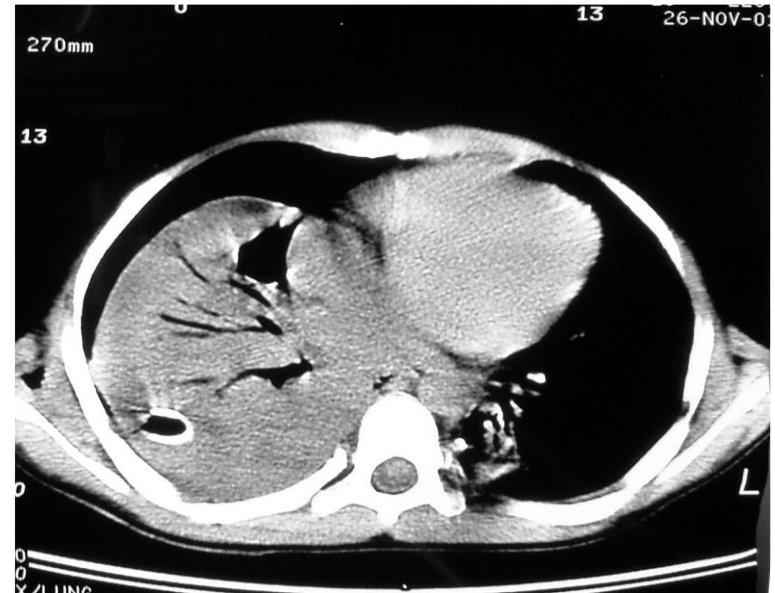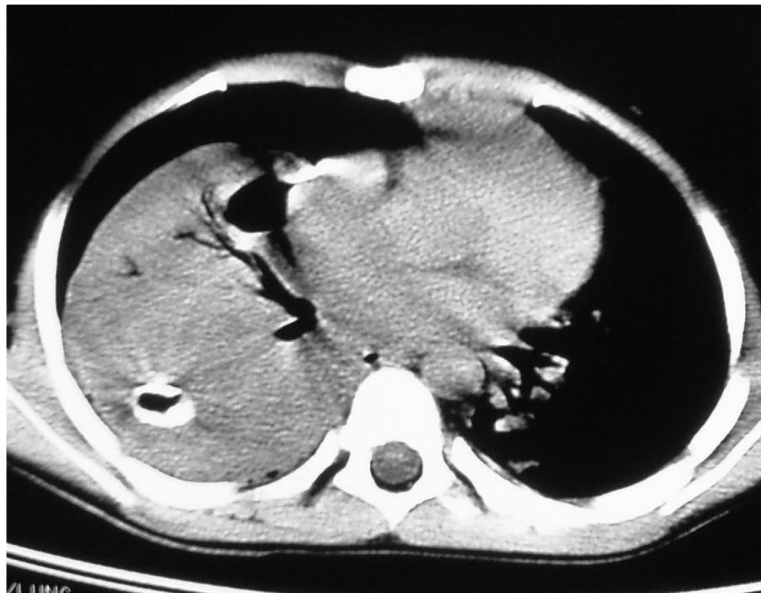
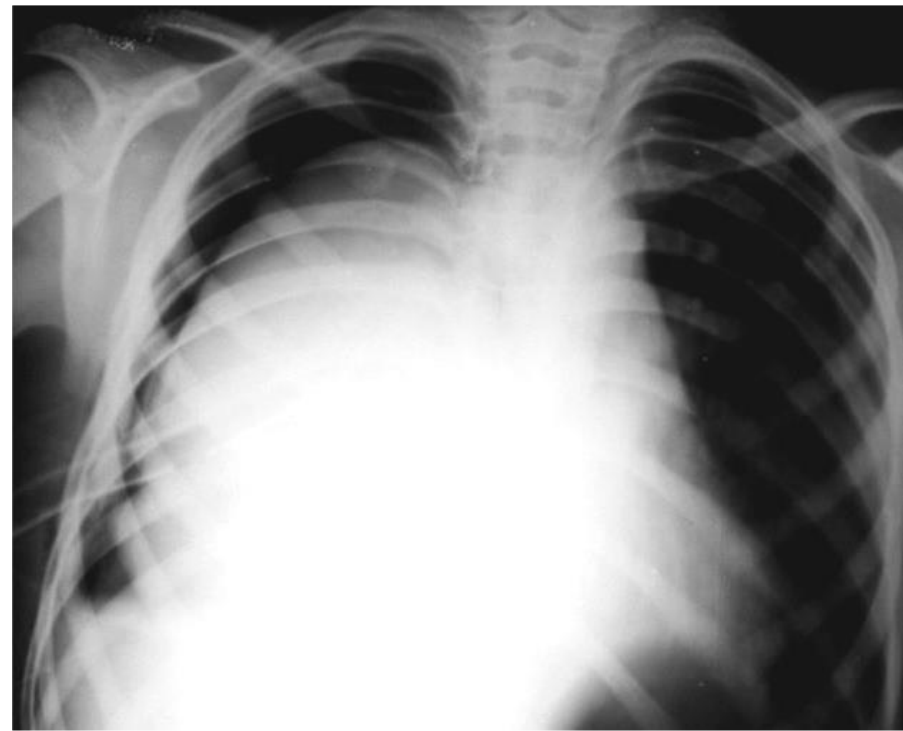
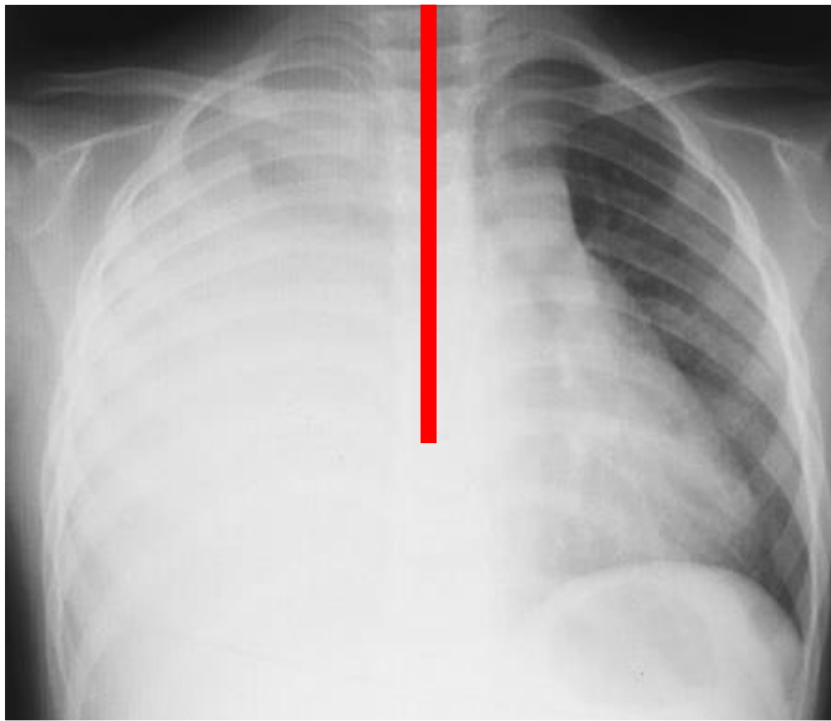
- Pulmoner agenezi, hipoplazi

- Trakea karşı tarafa itilmiş

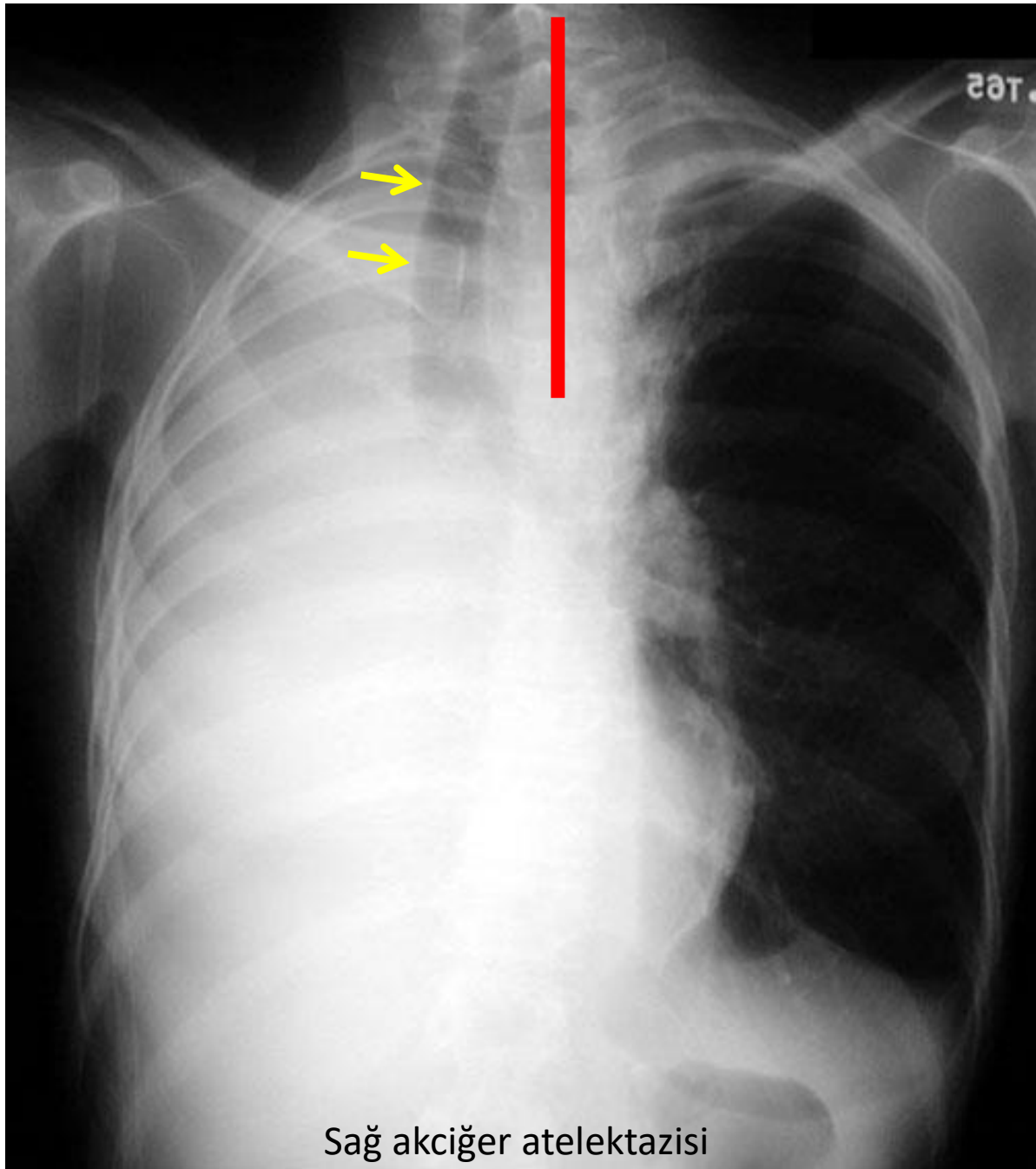
- Plevral efüzyon

- Büyük akciğer kitlesi

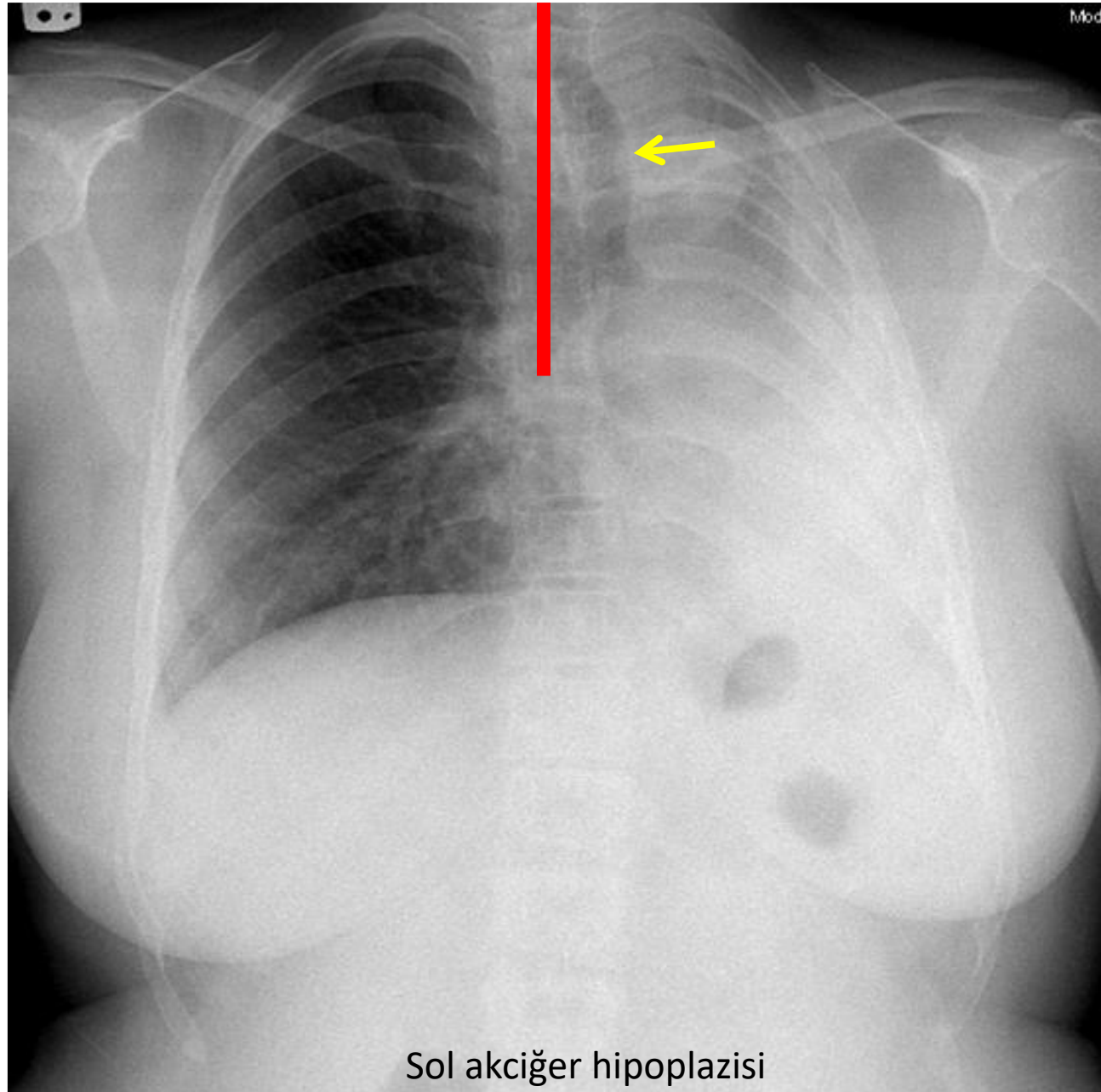
- Diyafram hernisi



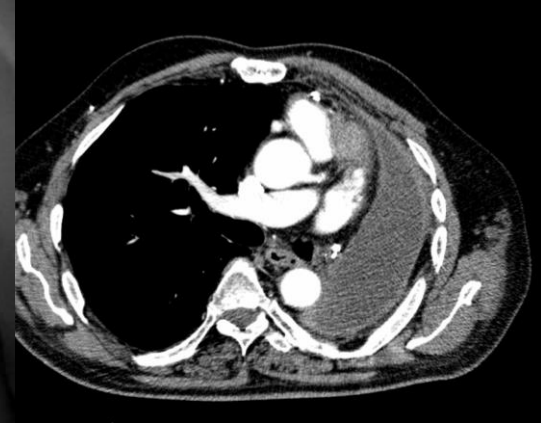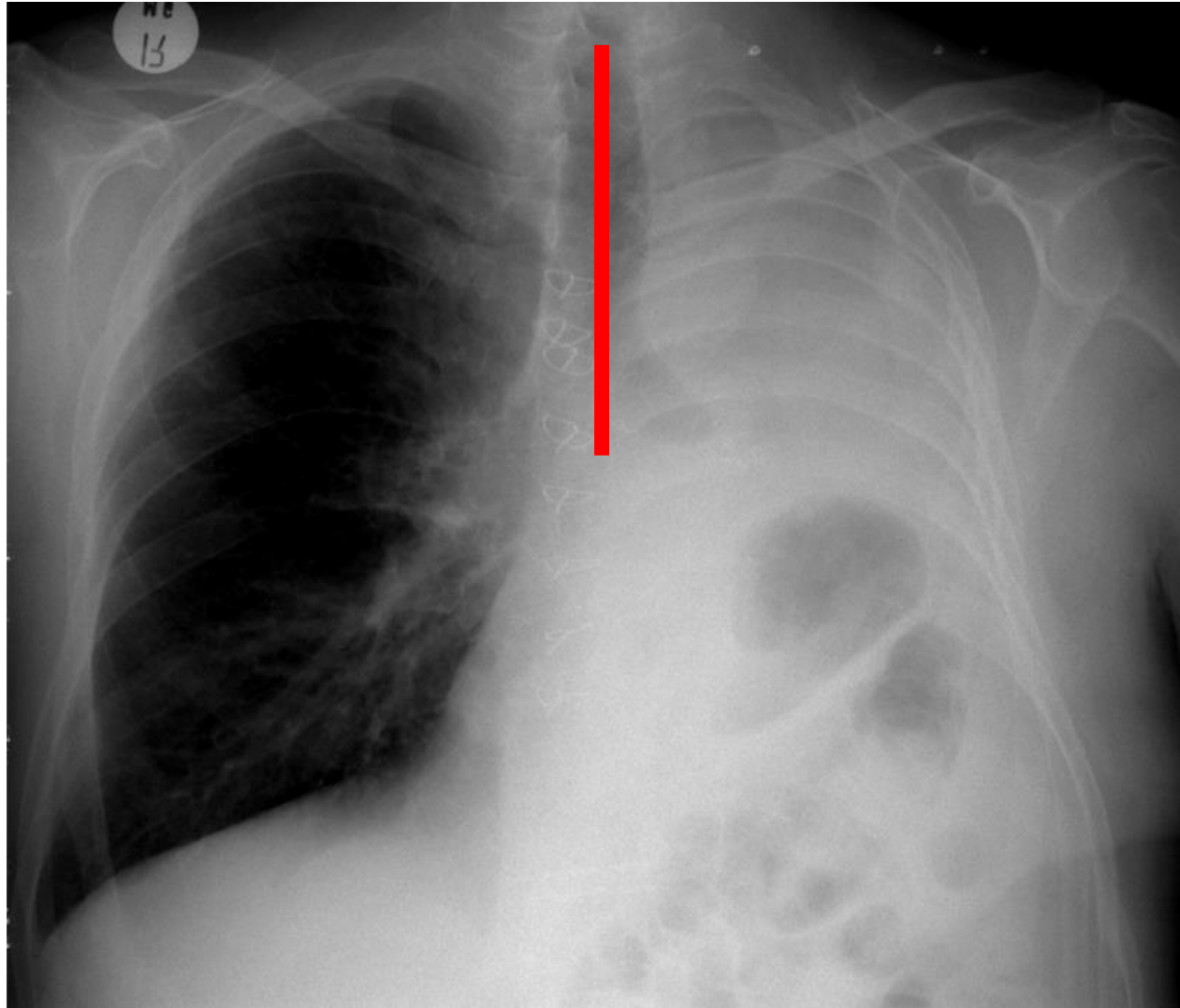
Pnömoni



Sağ akciğer atelektazisi

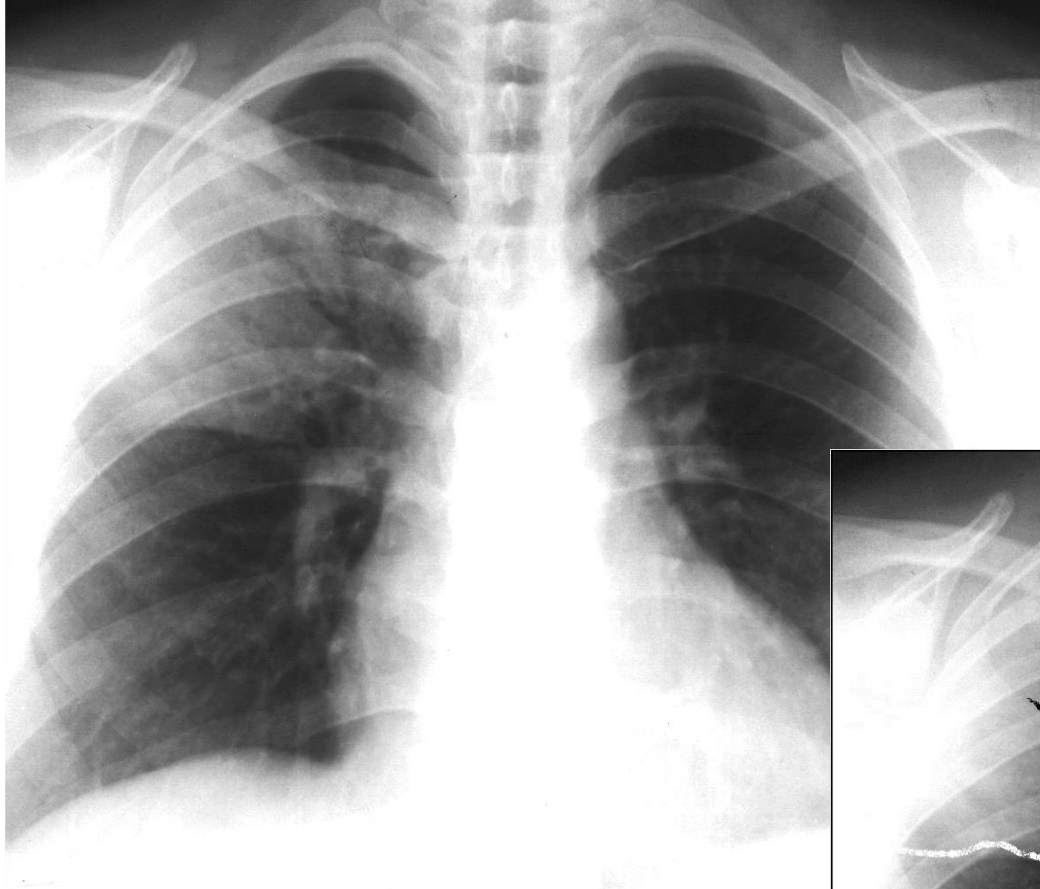


Sol akciğer hipoplazisi

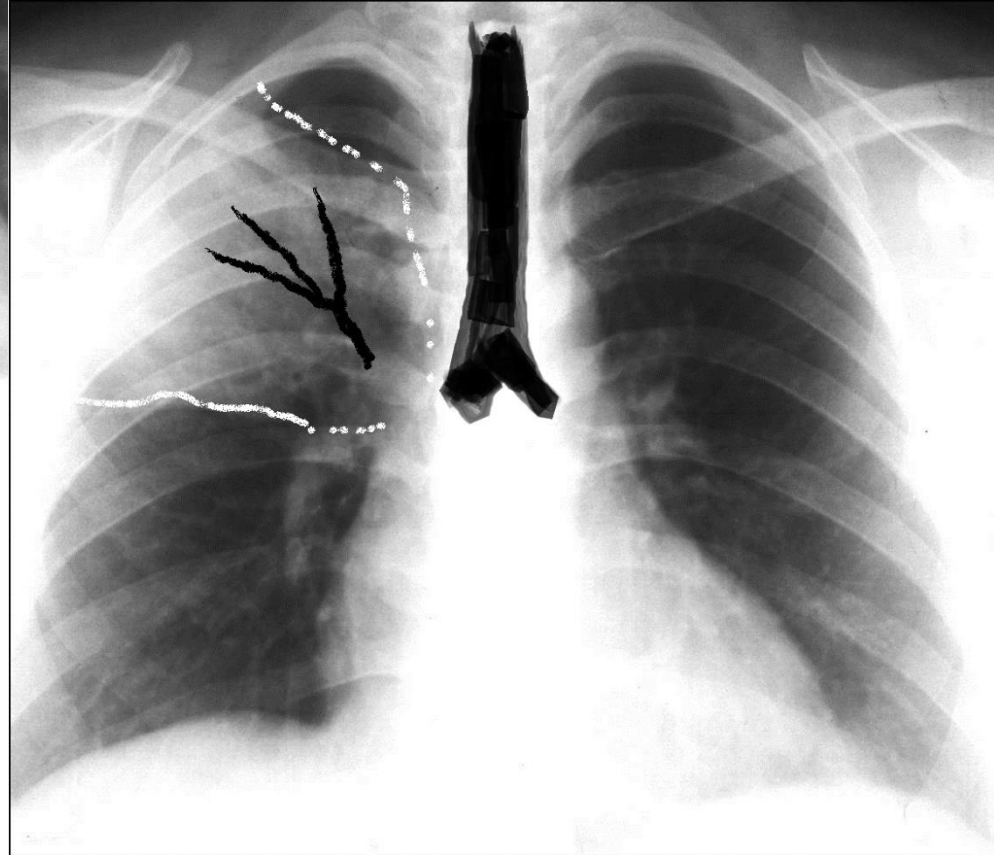


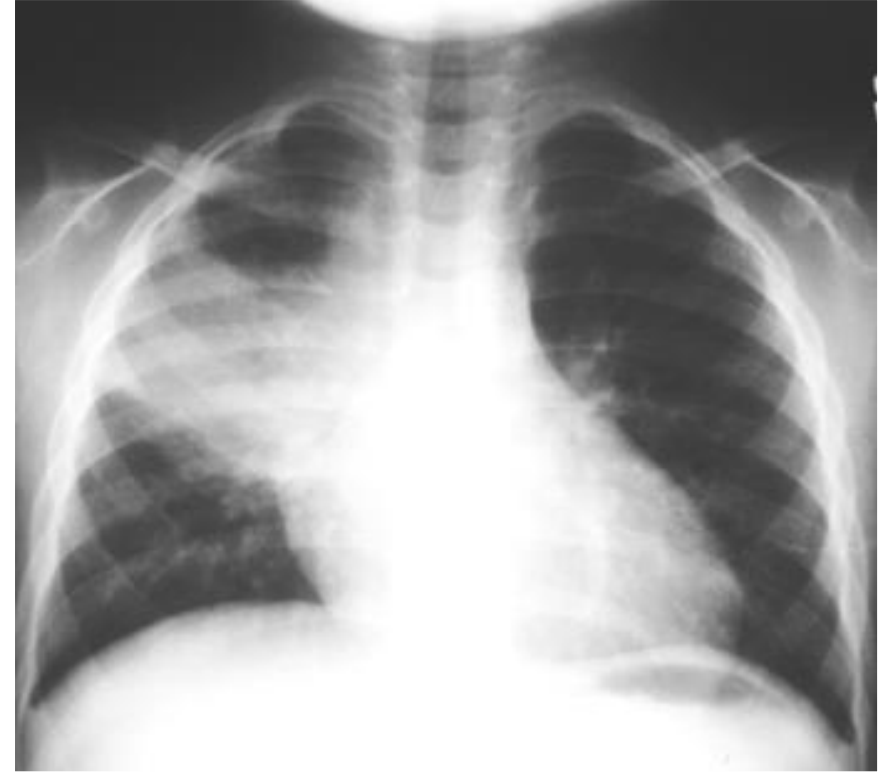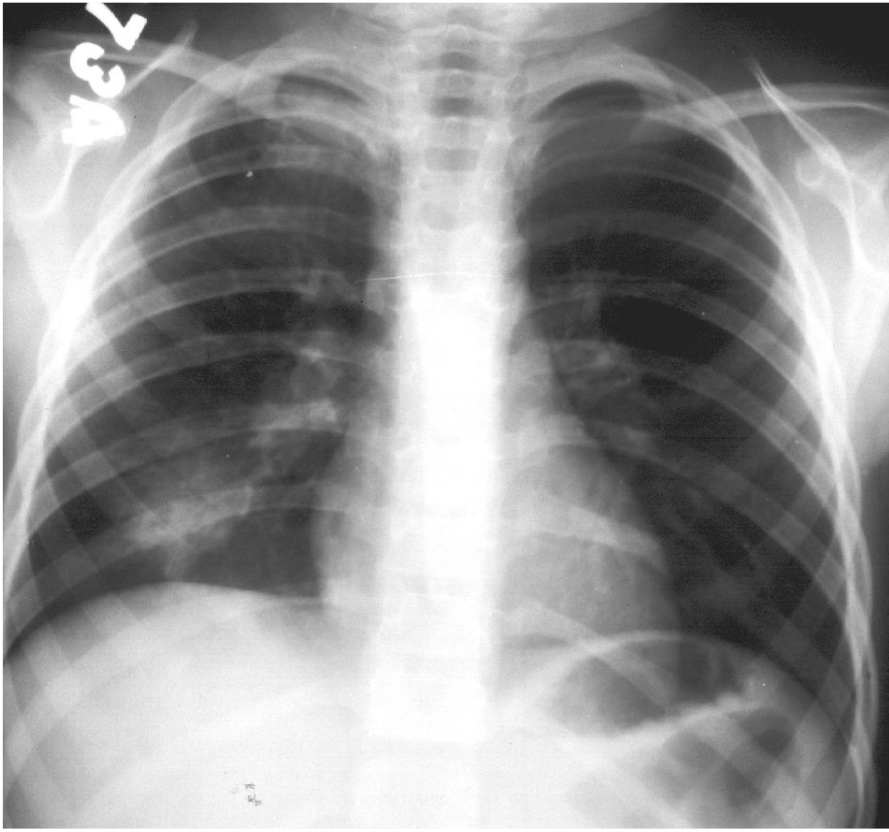
Pnömonektomi

KONSOLIDASYON

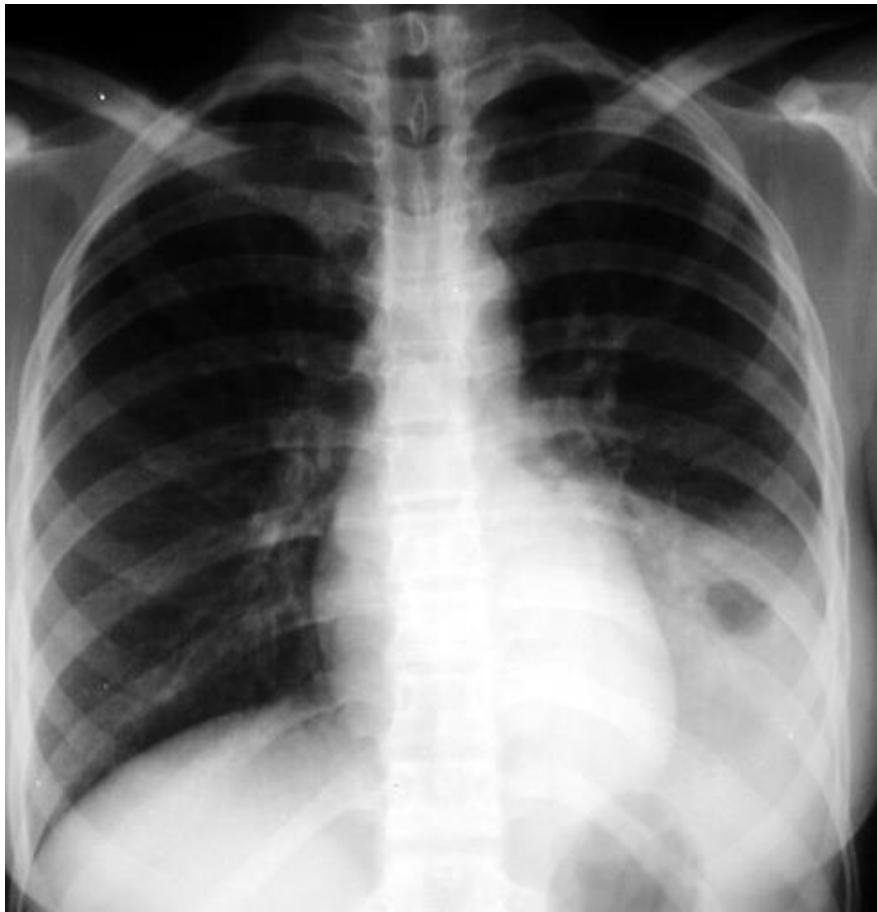

Hava bronkogramı
LOBER PNÖMONİ

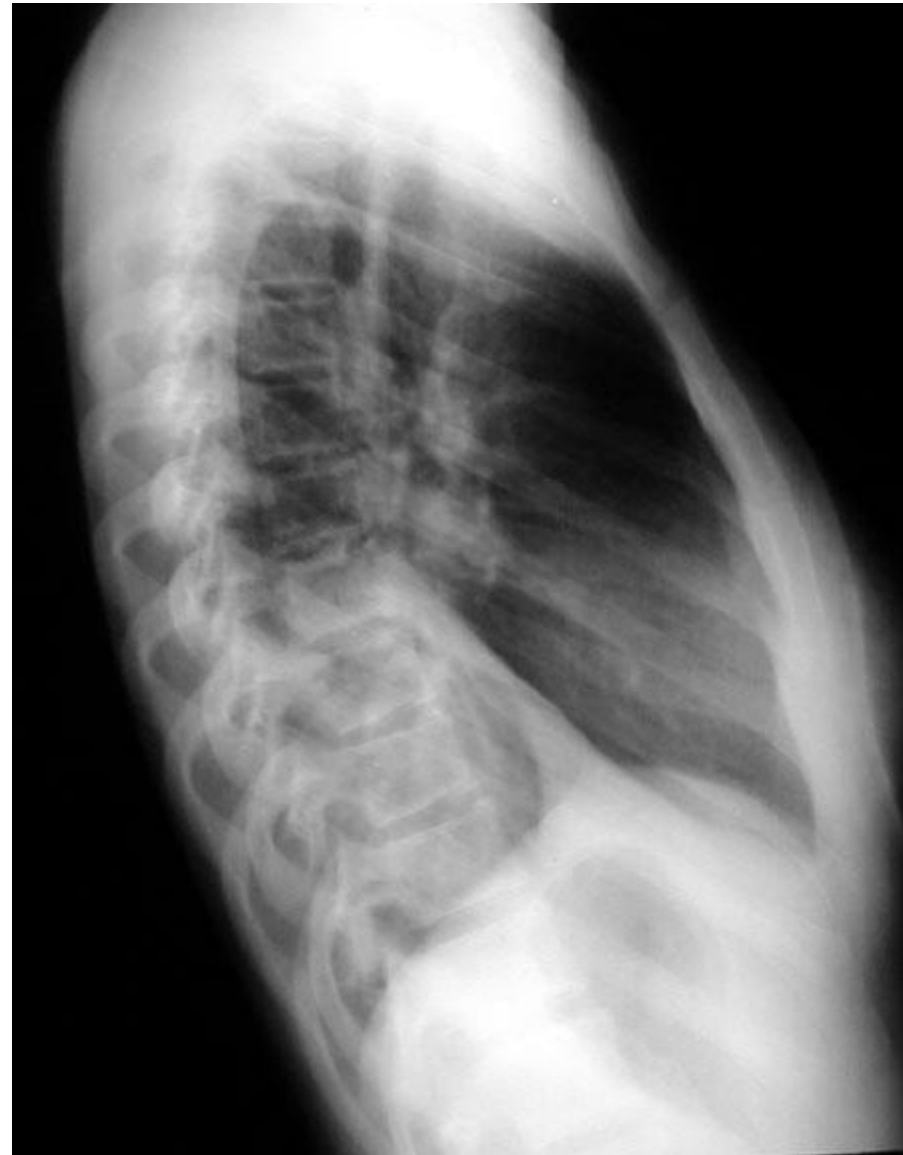



Değişik pnömoni örnekleri

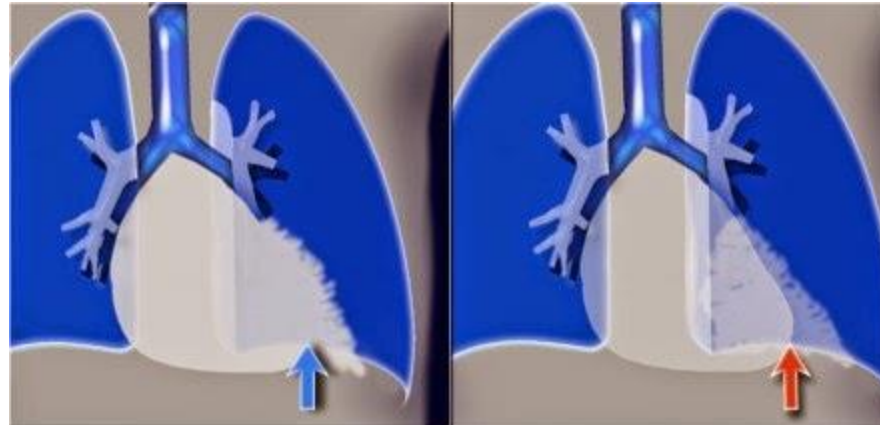


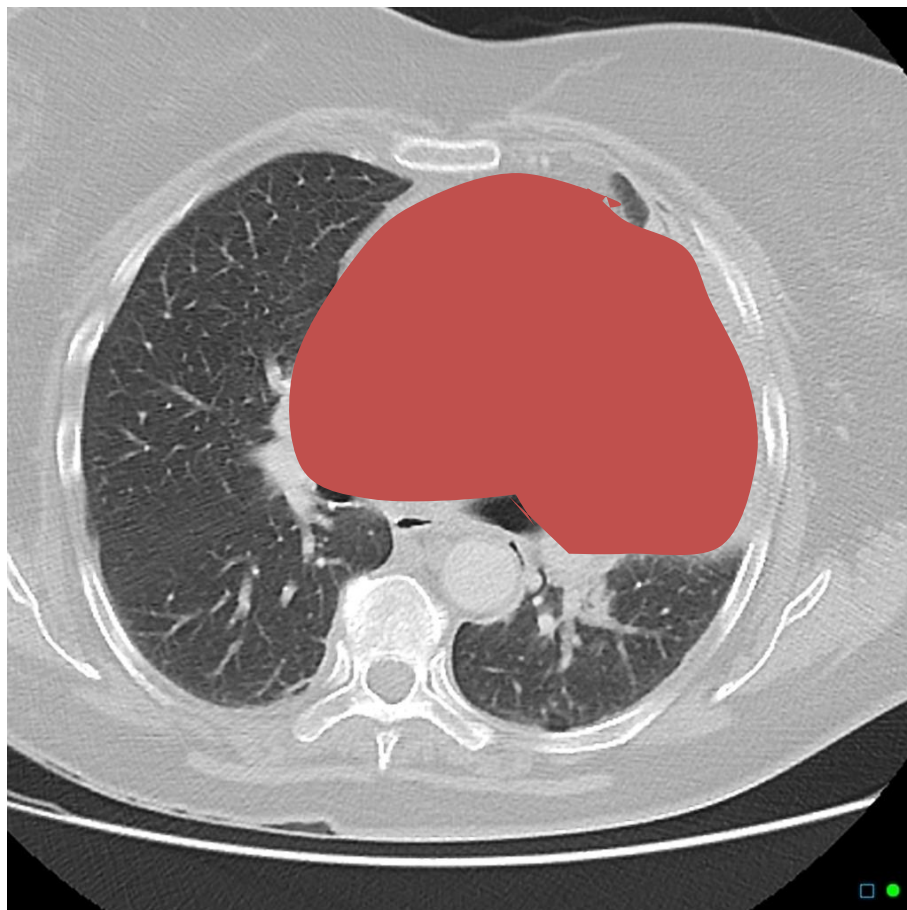
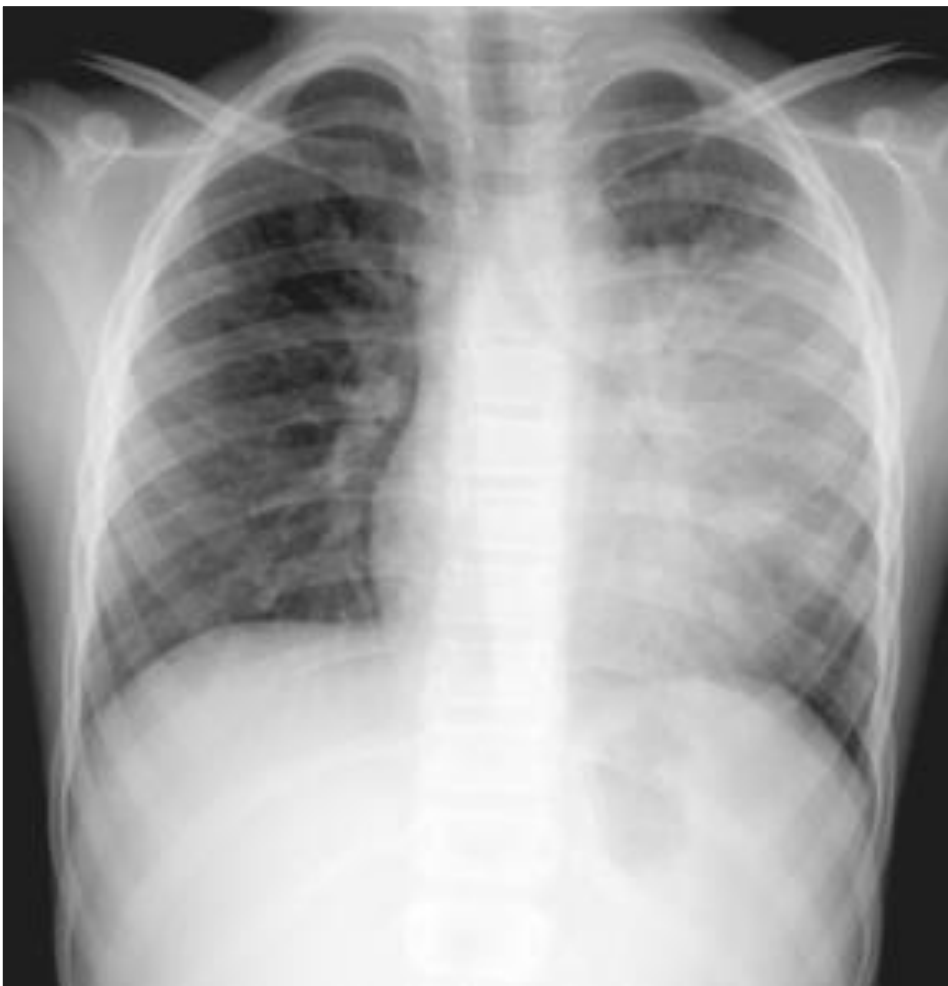Nekrotik pnömoni

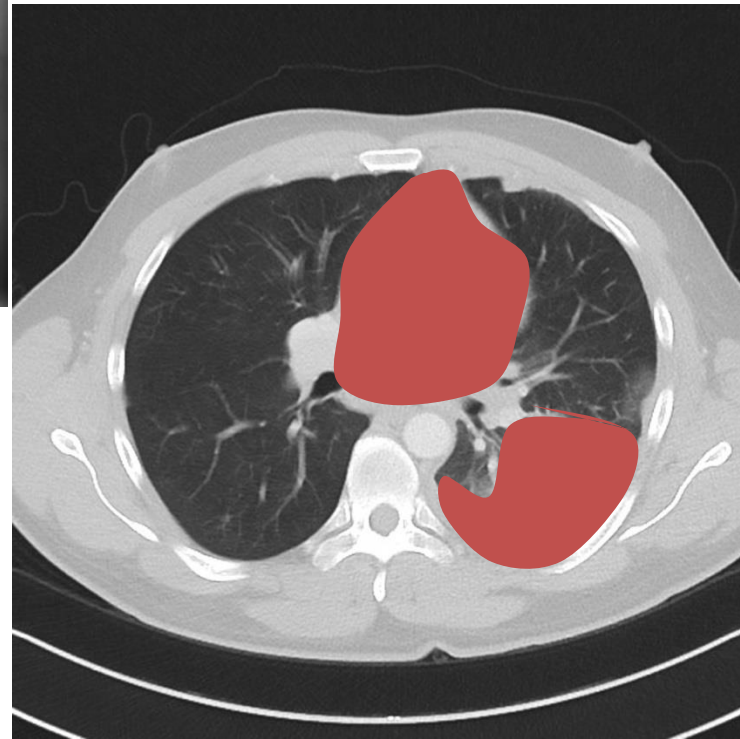
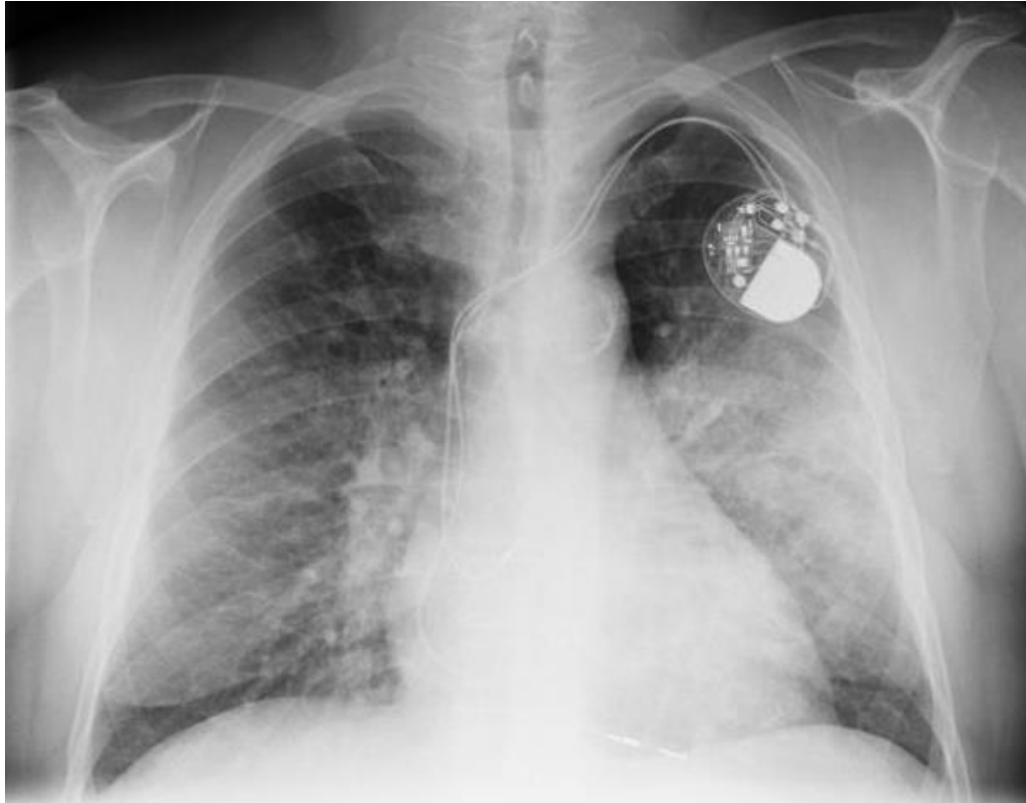


SİLÜET İŞARETİ

- Toraks boşluğunda birbirine komşu iki oluşum aynı radyografik dansitede ise birbirlerinin konturlarını siler, komşu değiller ise konturlarını silmez.

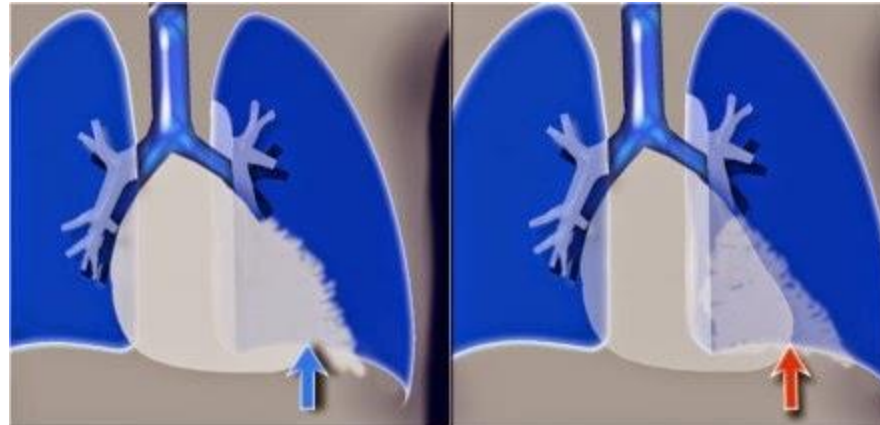


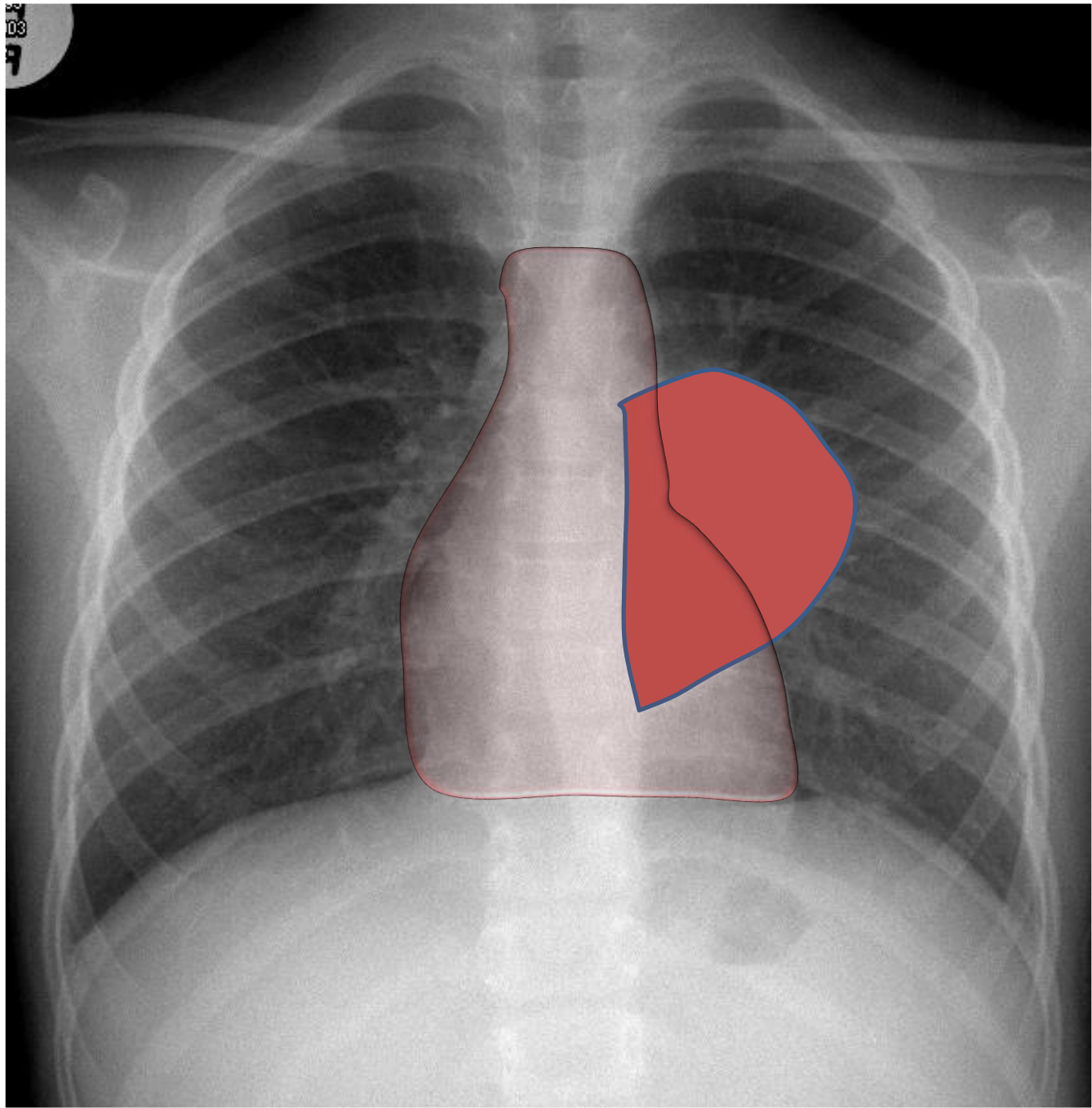


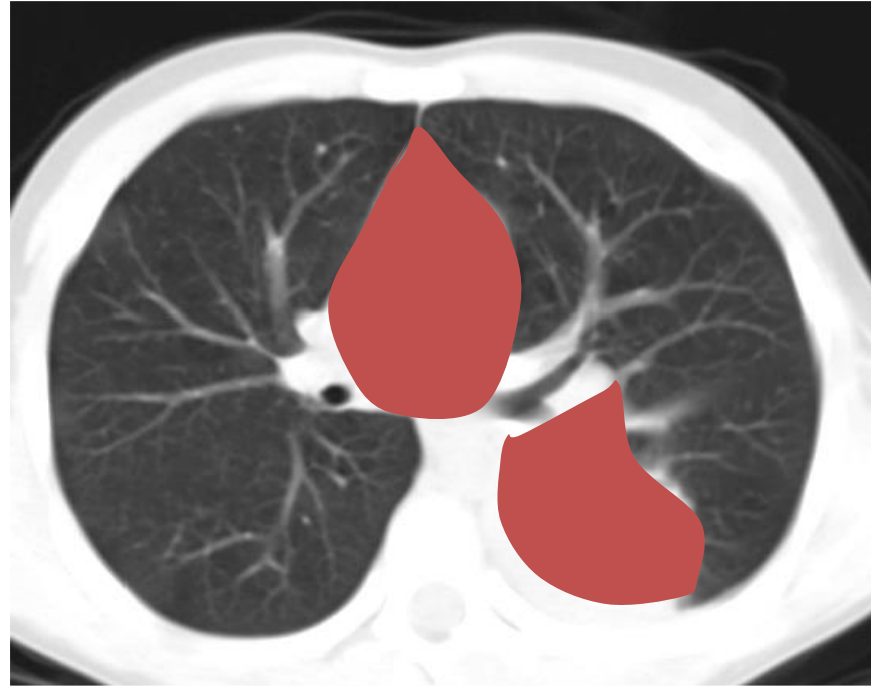
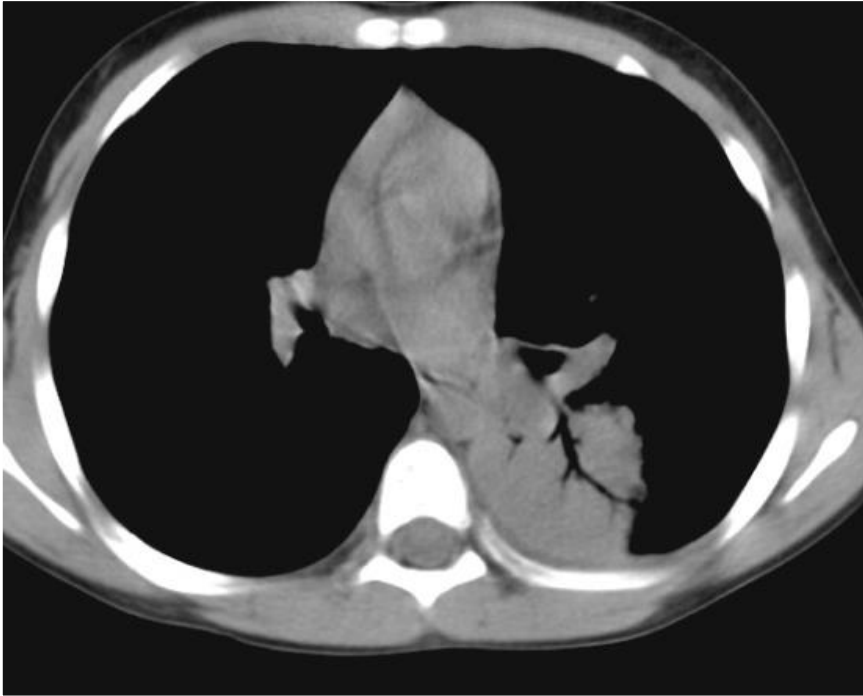

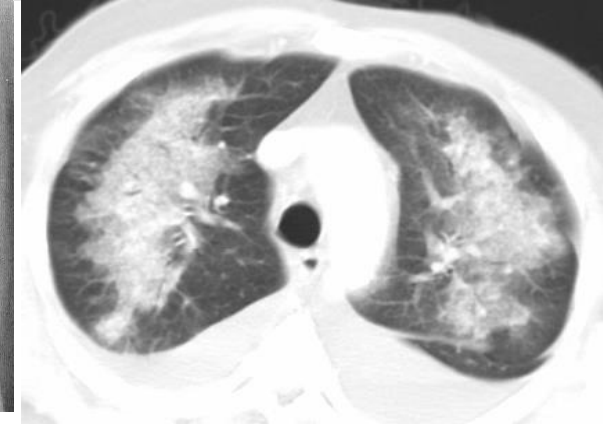
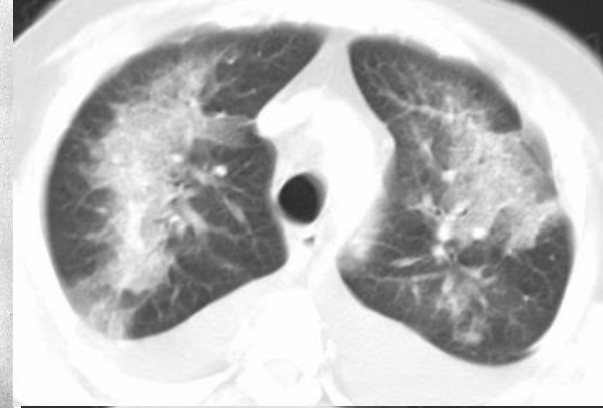
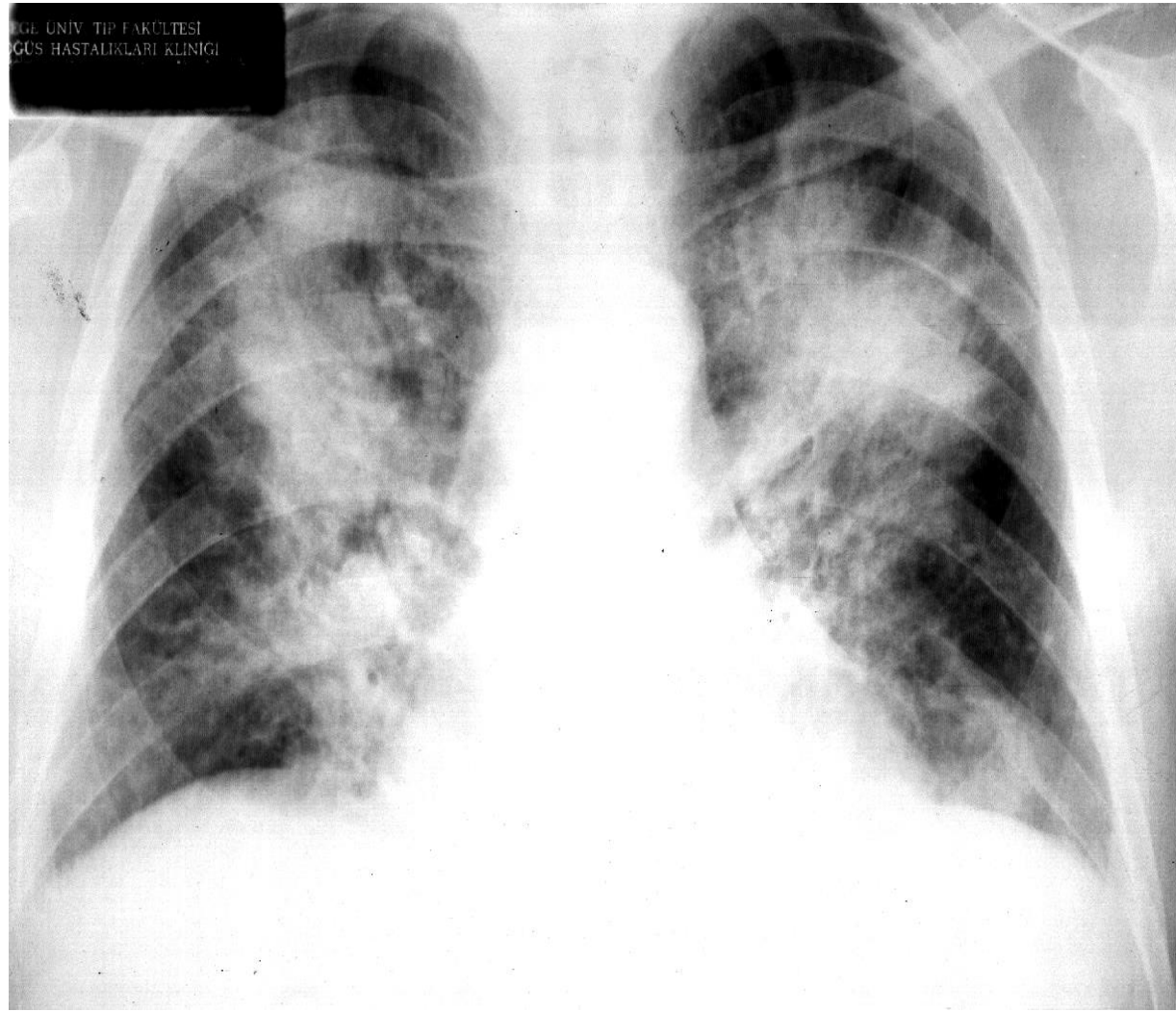
SİLÜET İŞARETİ

- Toraks boşluğunda birbirine komşu iki oluşum aynı radyografik dansitede ise birbirlerinin konturlarını siler, komşu değiller ise konturlarını silmez.

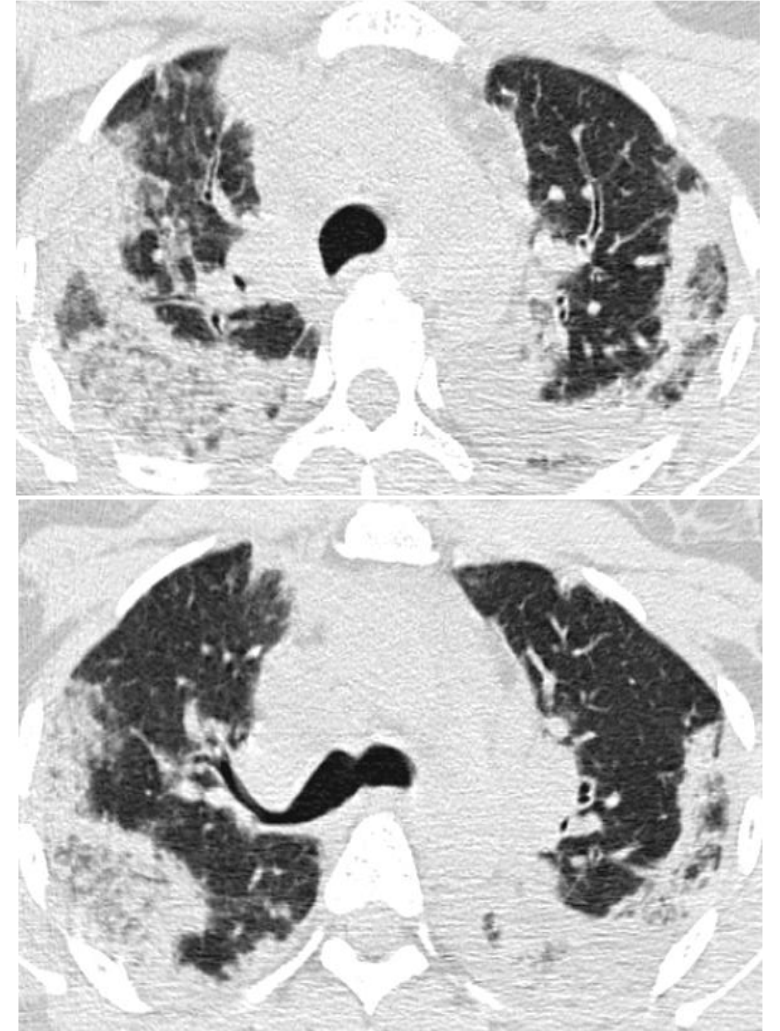
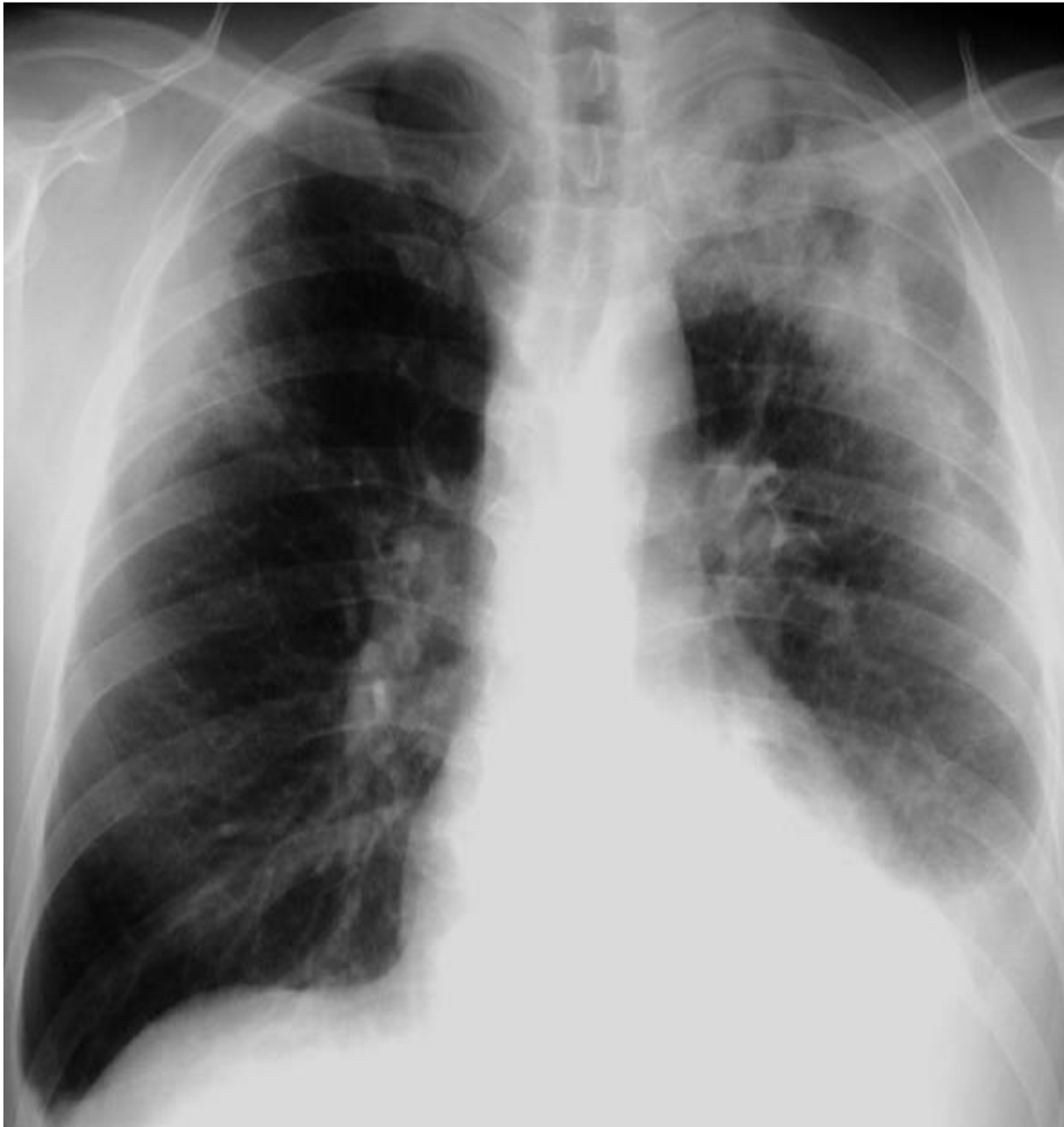







Pulmoner ödem



KRONİK EOZİNOFİLİK PNÖMONİ

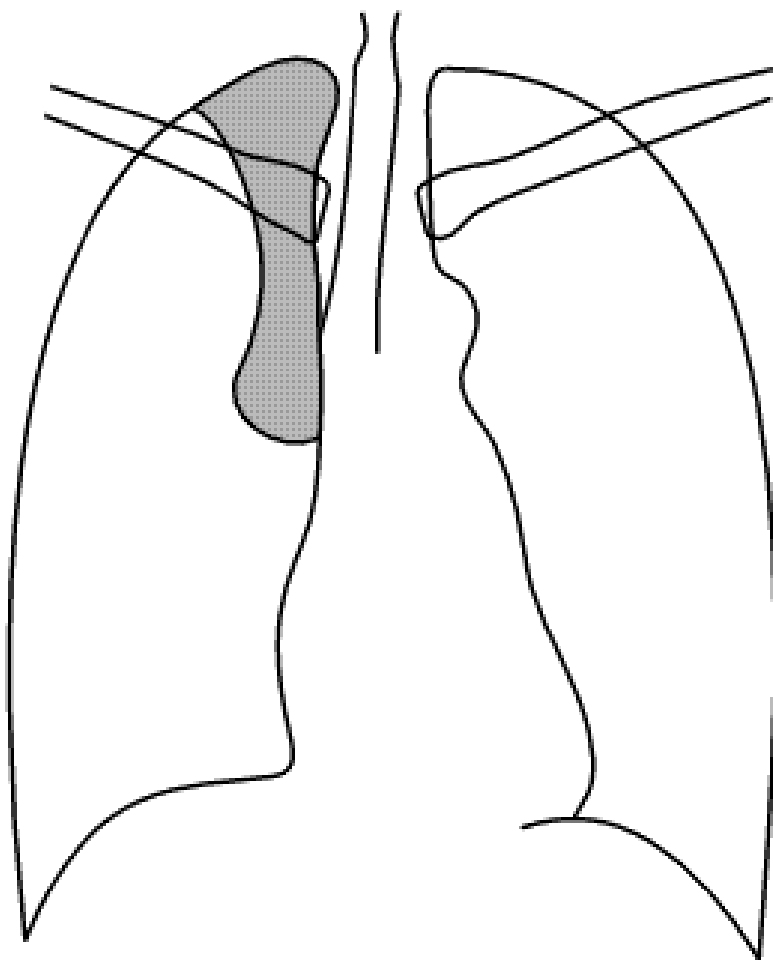
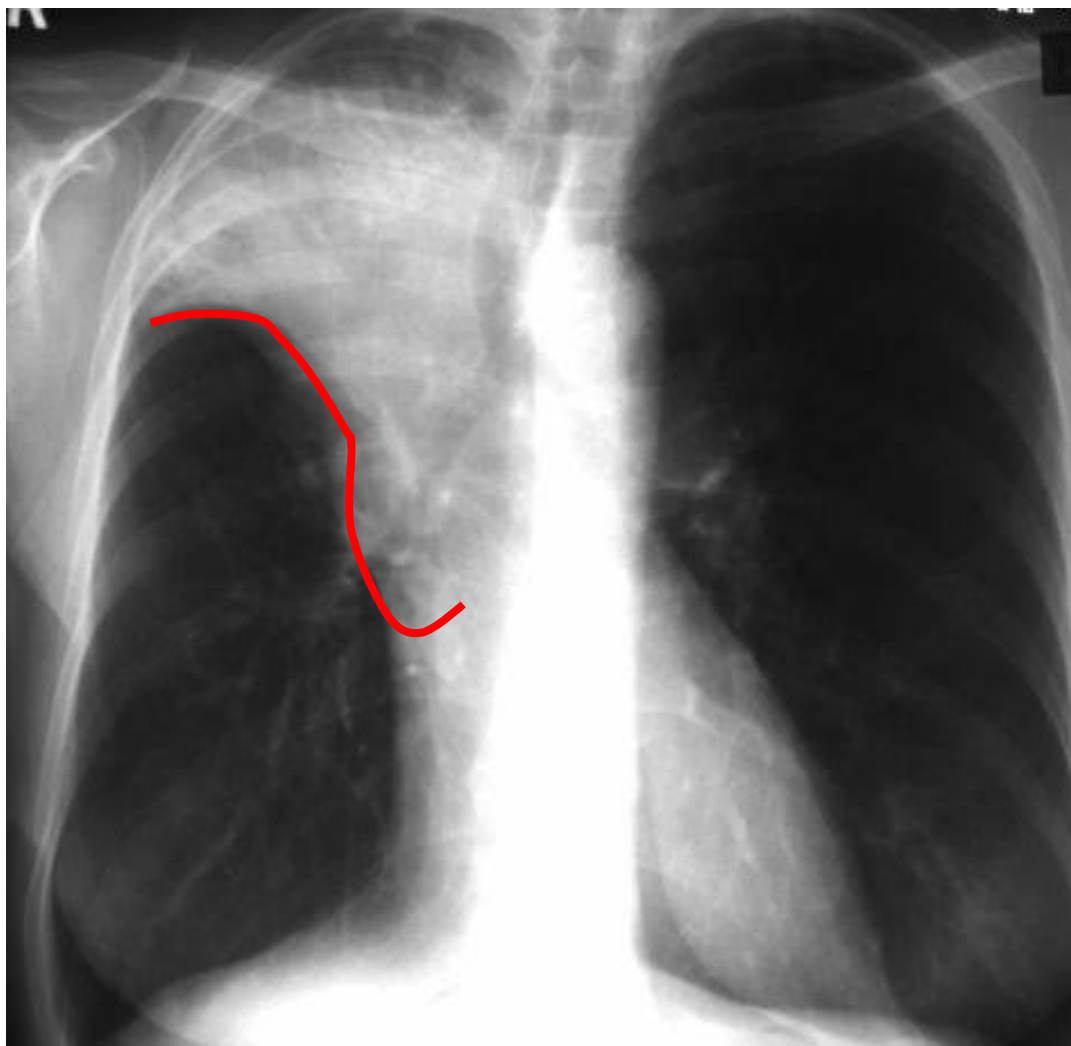
ATELEKTAZI

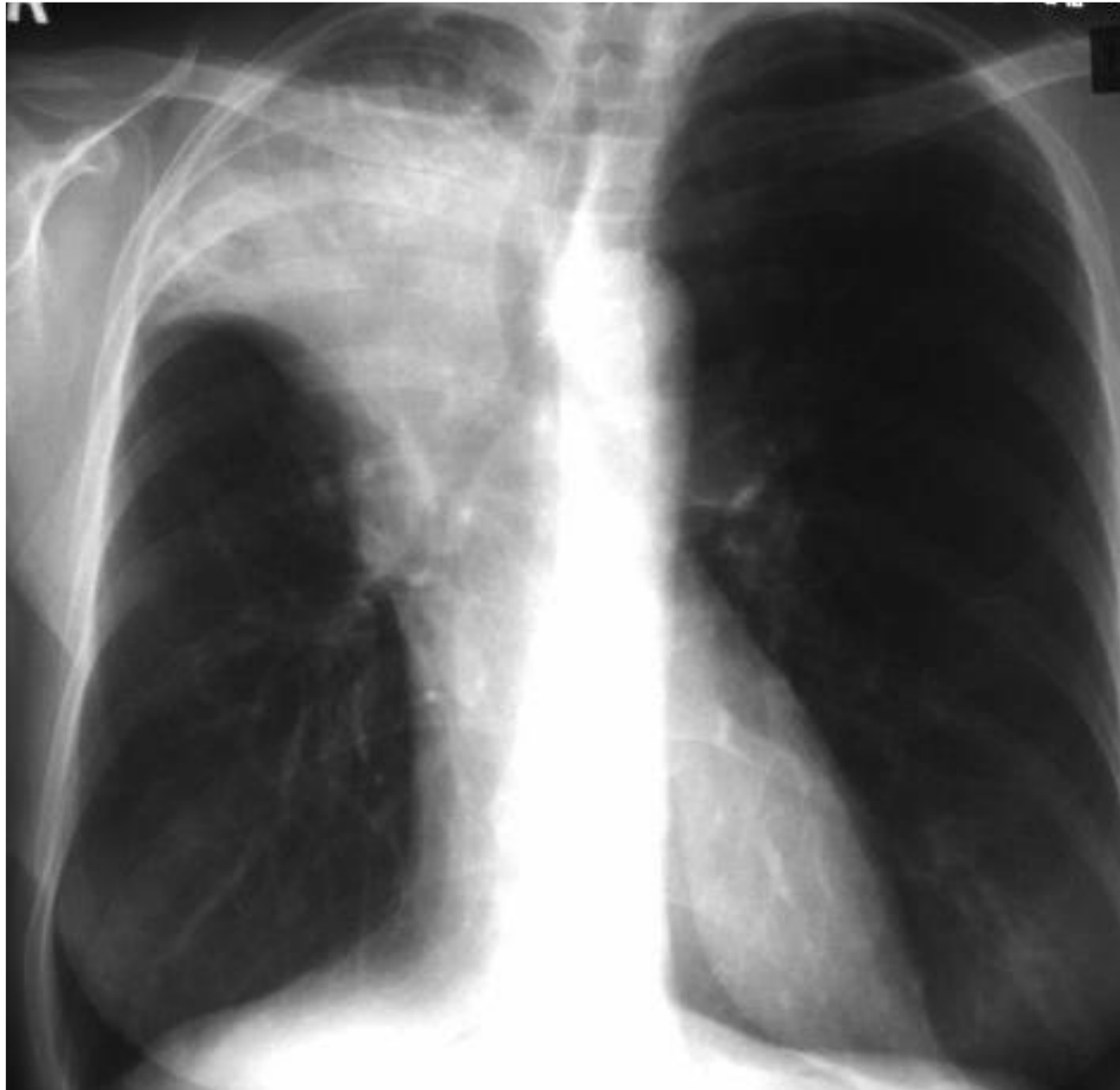DİREK BULGULAR

- İnterlobar fissürlerde yer deęiřtirme
- Bronkovasküler iřaretlerin birbirine yaklaşması
- Artmış akcięer opasitesi

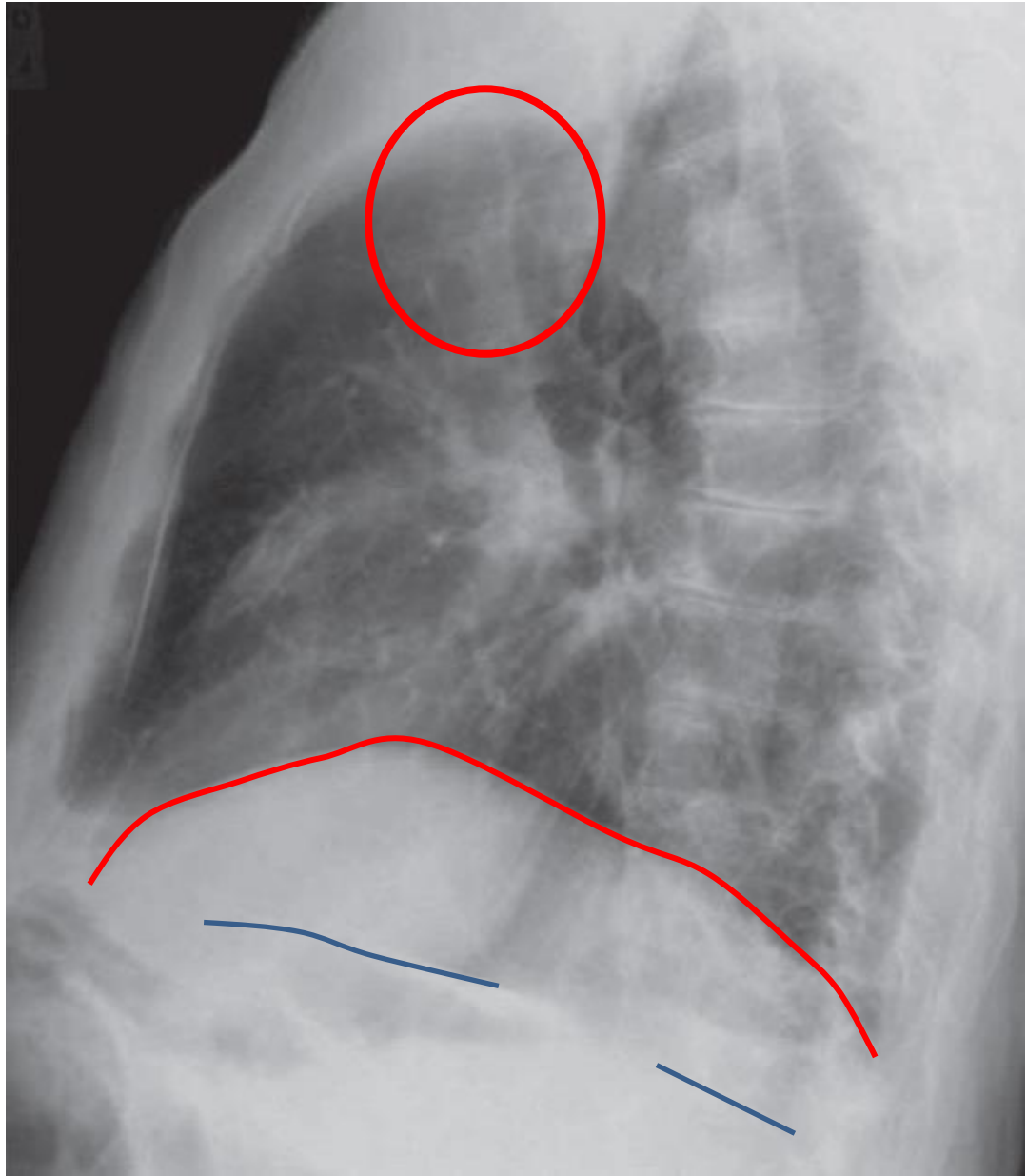
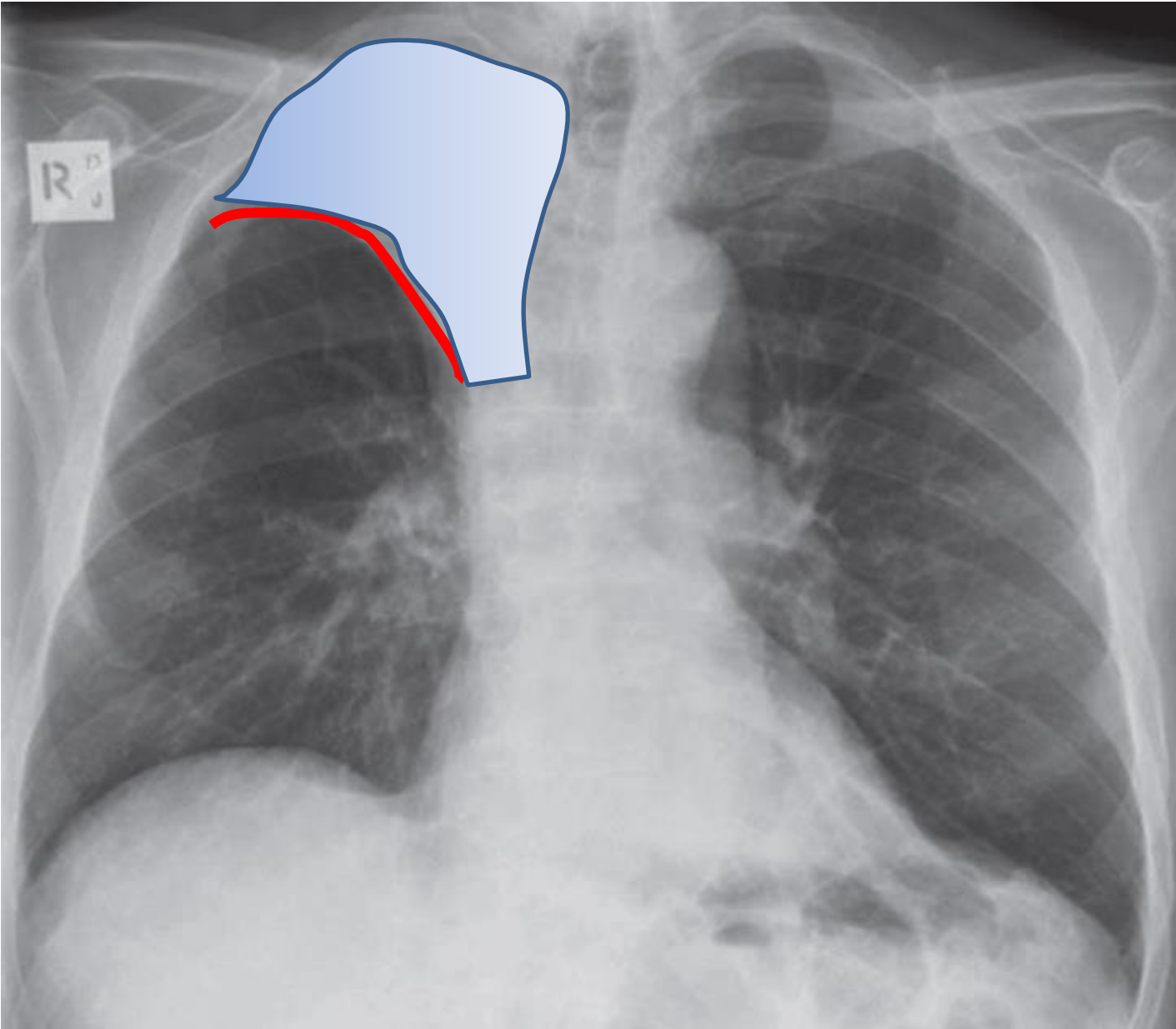
İNDİREK BULGULAR

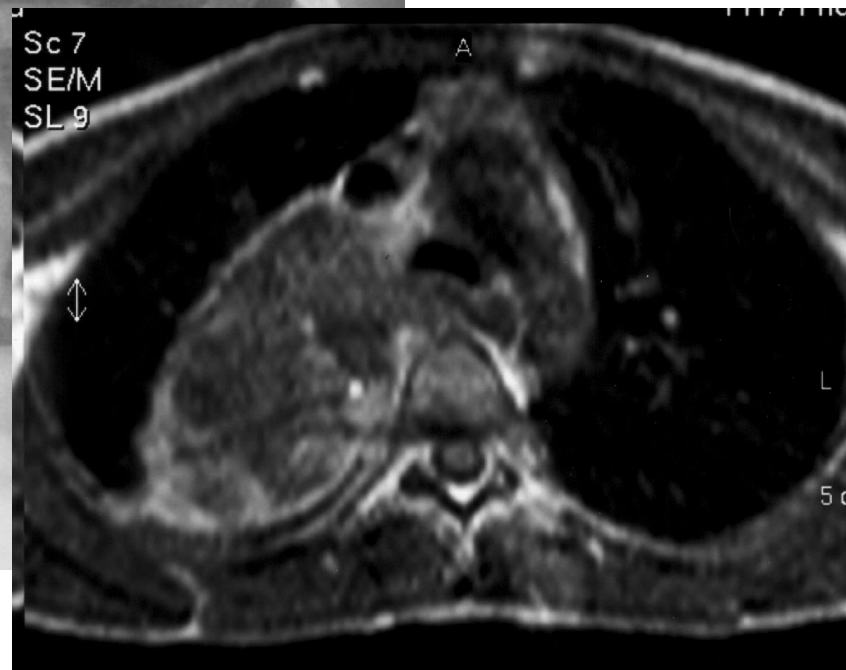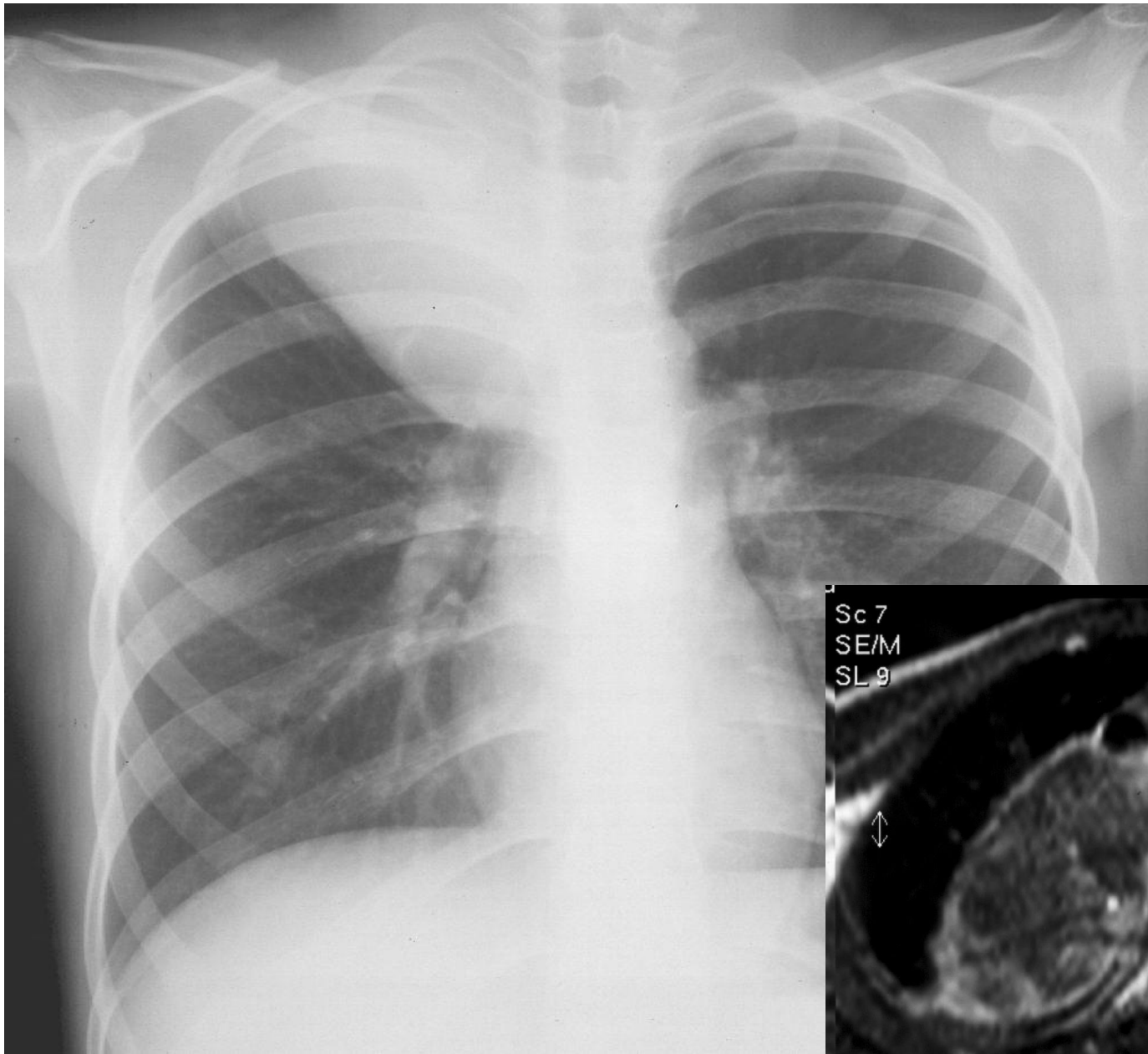
- Hiler yer deęiřtirme
- Mediastinal řift /trakeal çekilme
- Diyafragma yükselmesi
- Kostaların birbirine yaklaşması
- Komřu akcięerde kompanzatuvar hiperinflasyon
- Hava bronkogramı



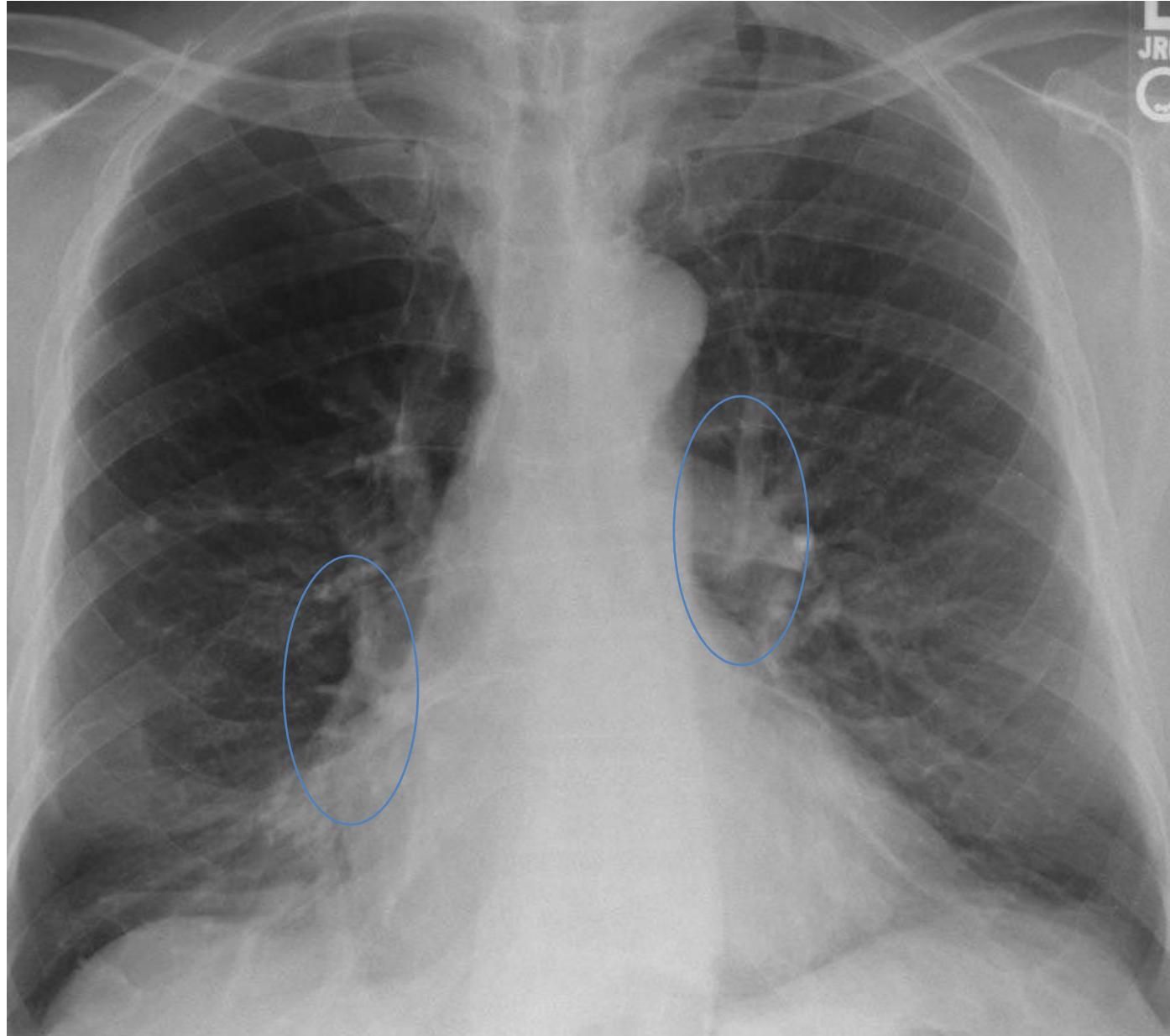


Sol üst lob atelektazisi /Golden'in S işareti

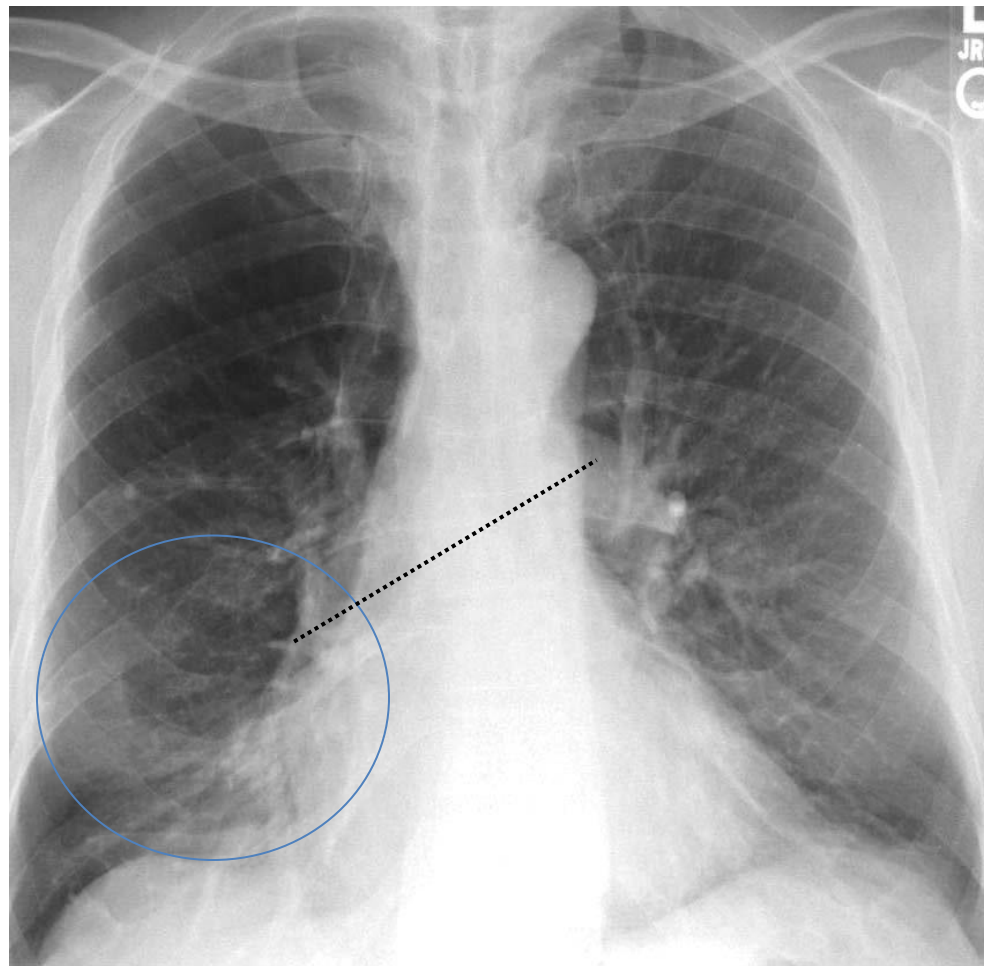
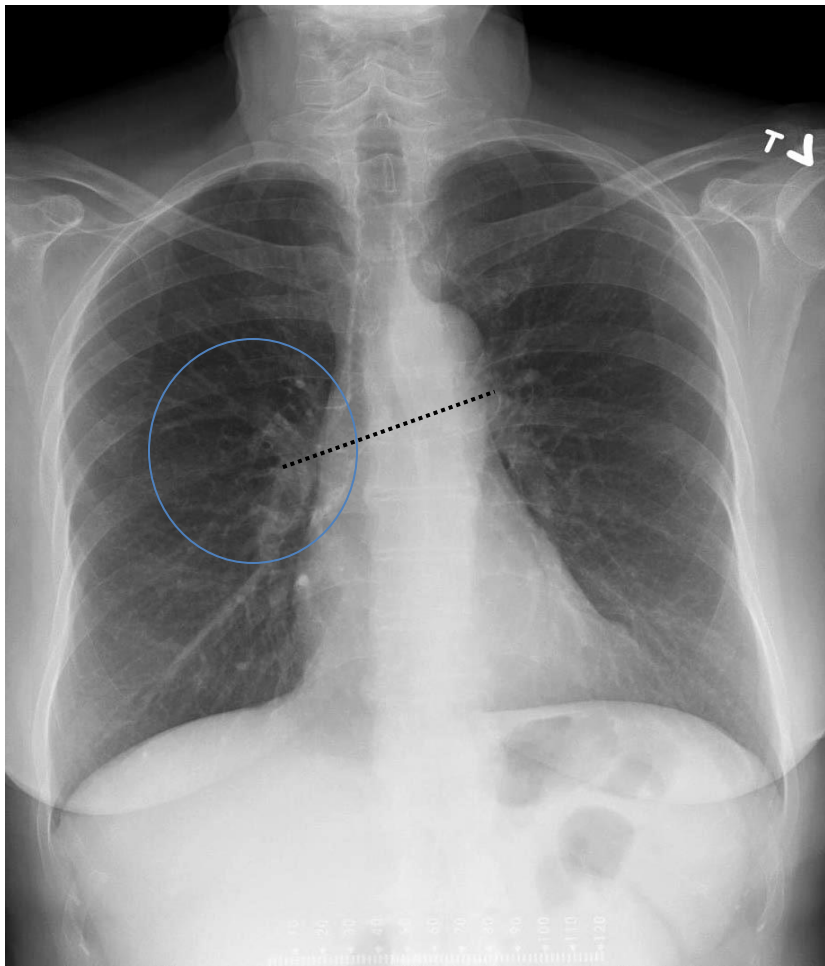




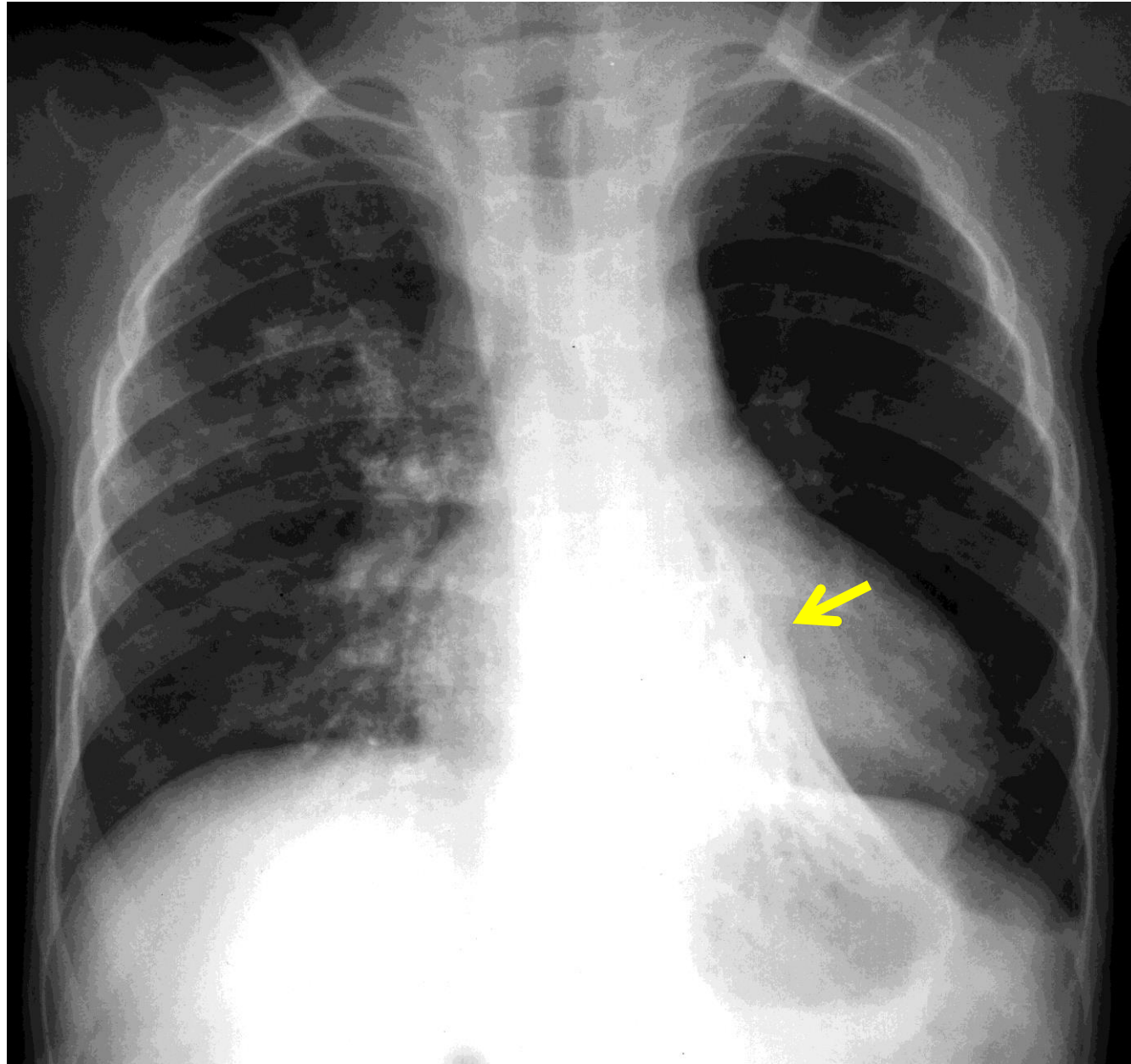
Sağ paramediastinal kitle



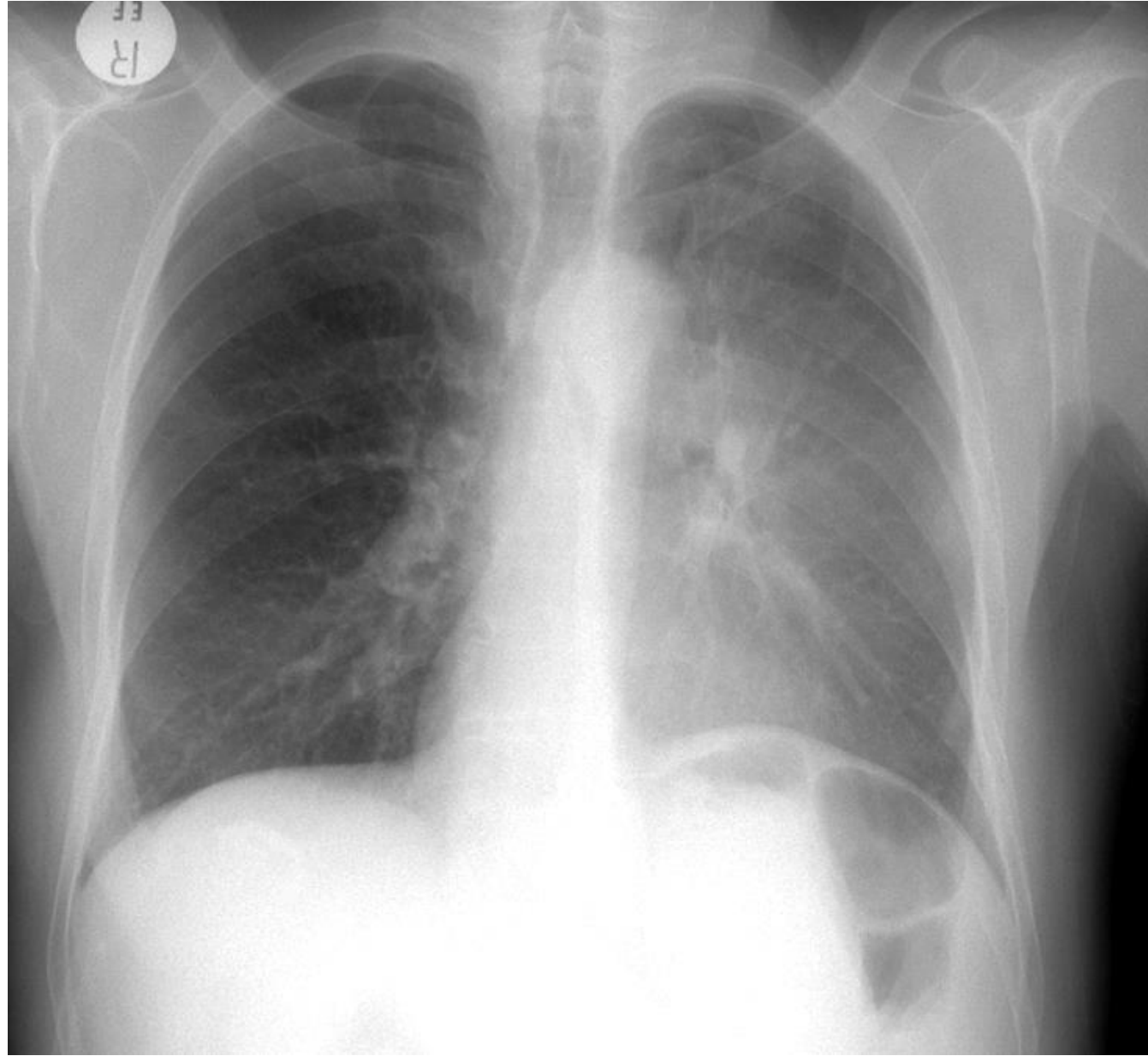
Hilus / sađda belirgin daha ařađıda: sađ alt lob atelettazisi


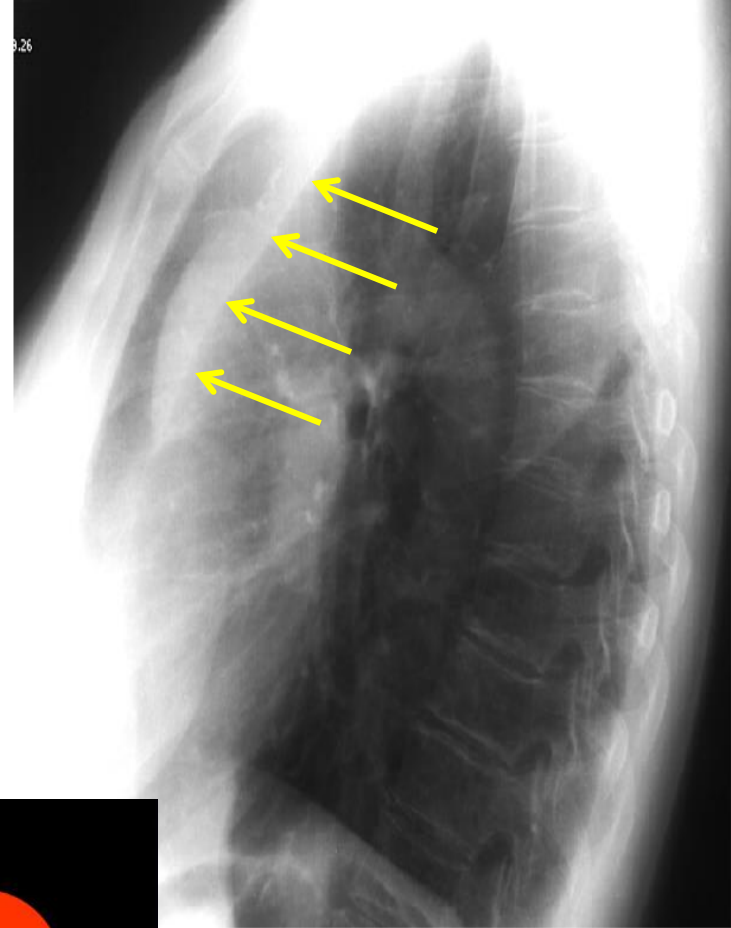
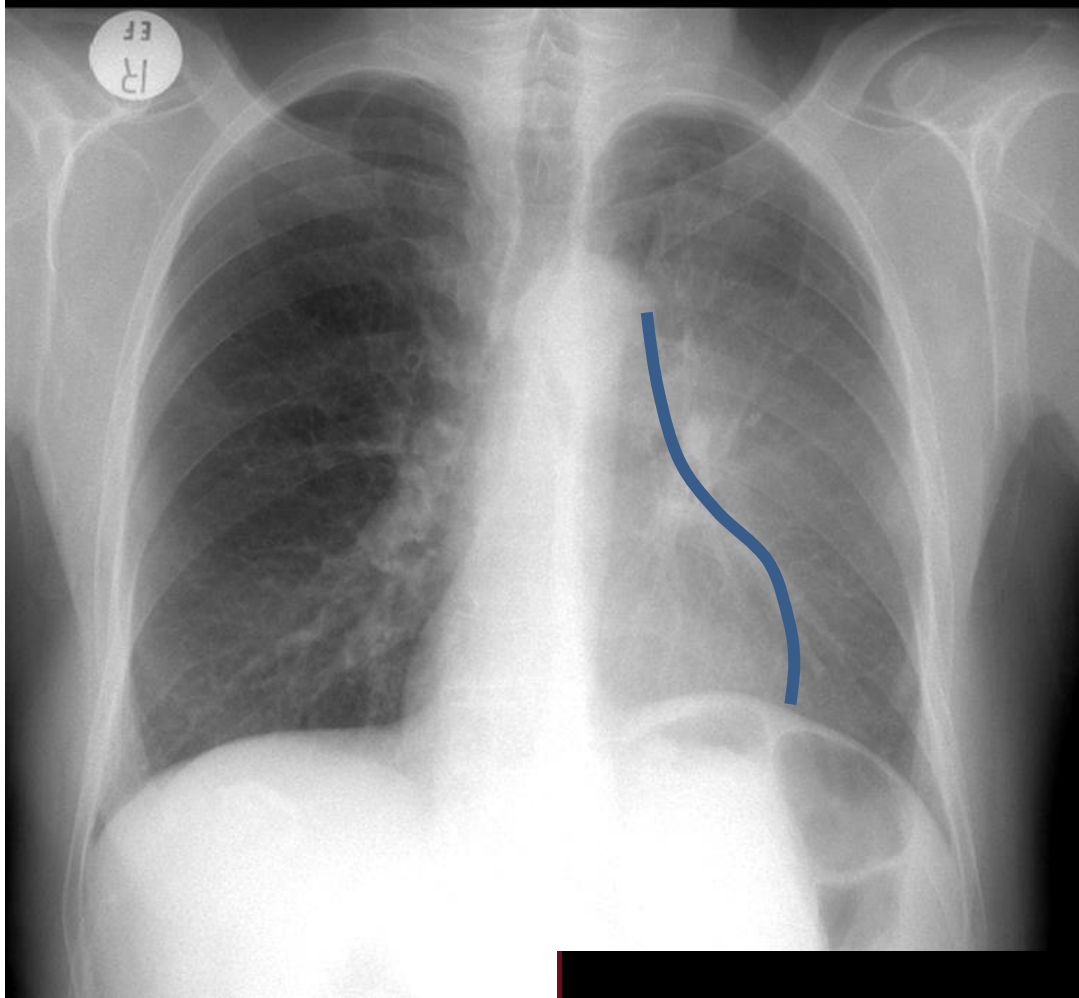


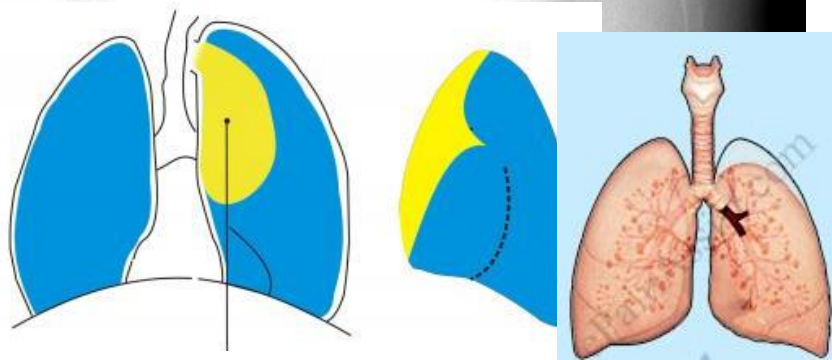
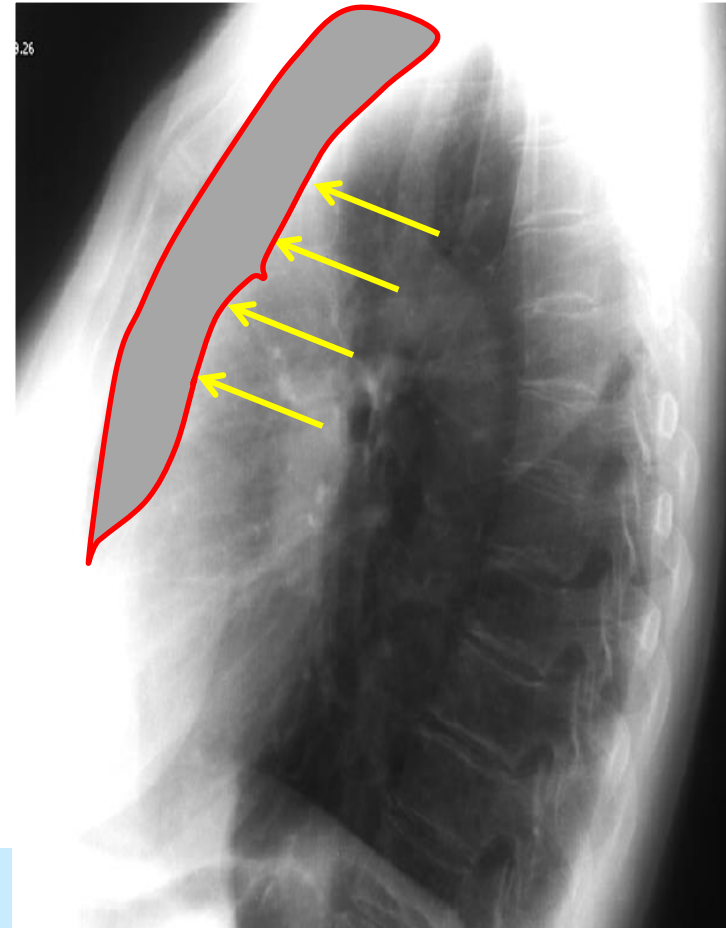
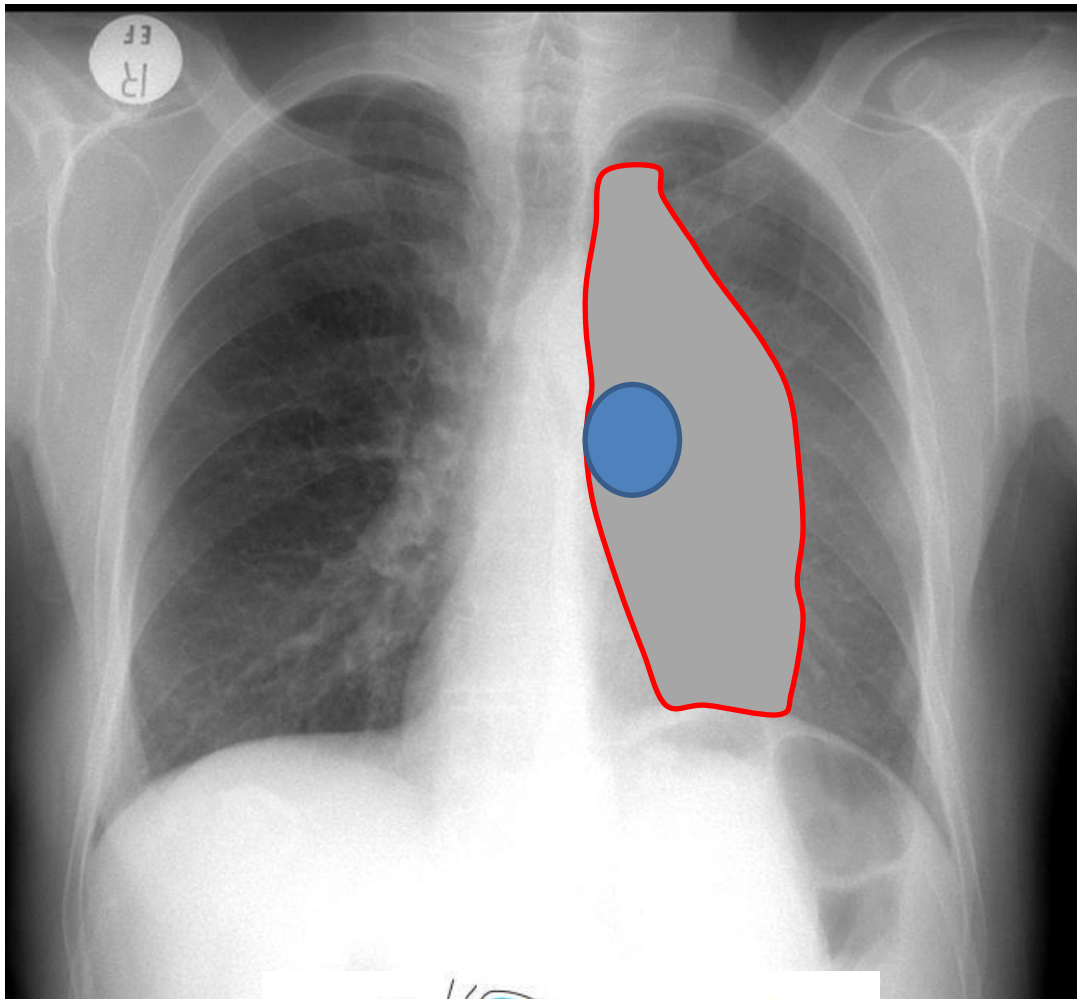
Normal hilus

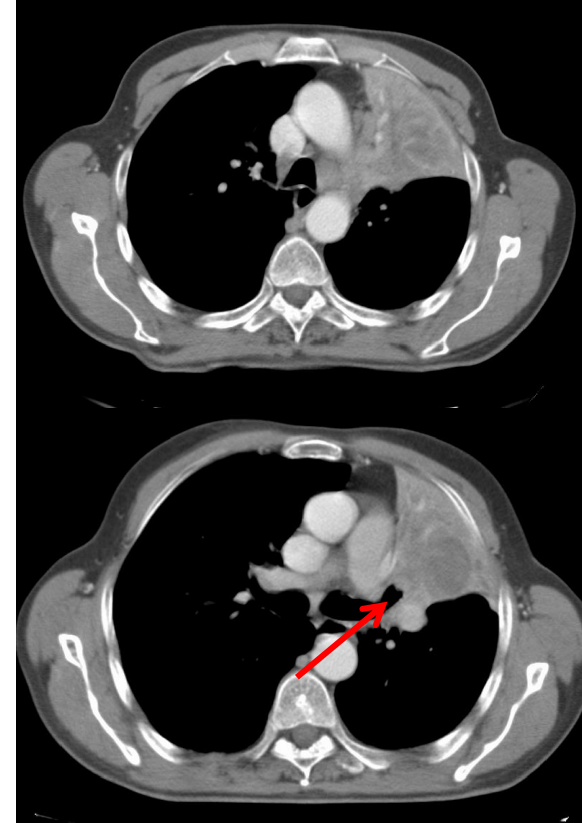
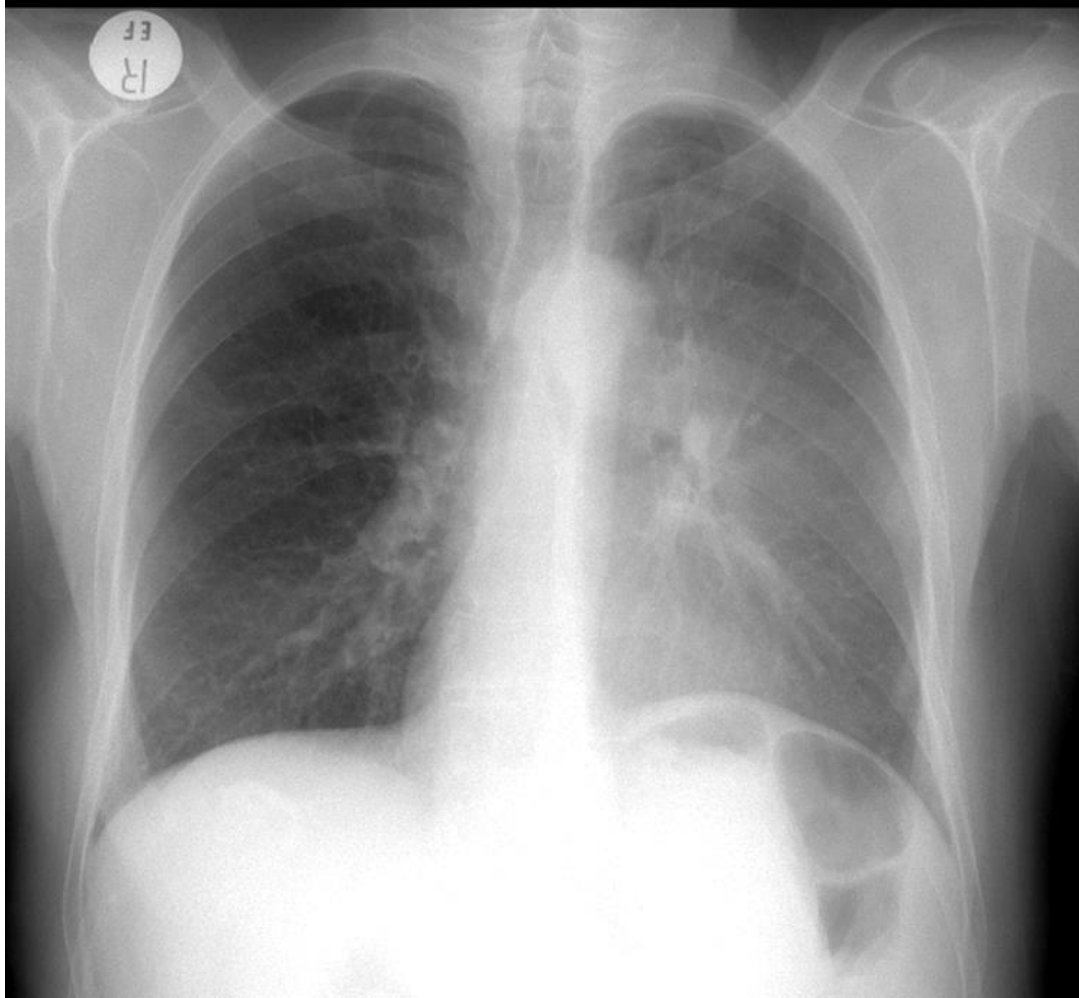


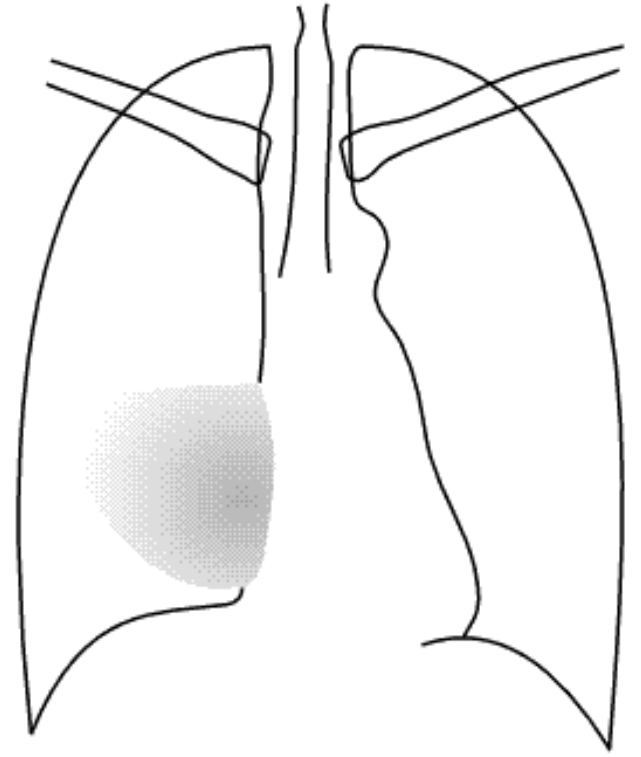
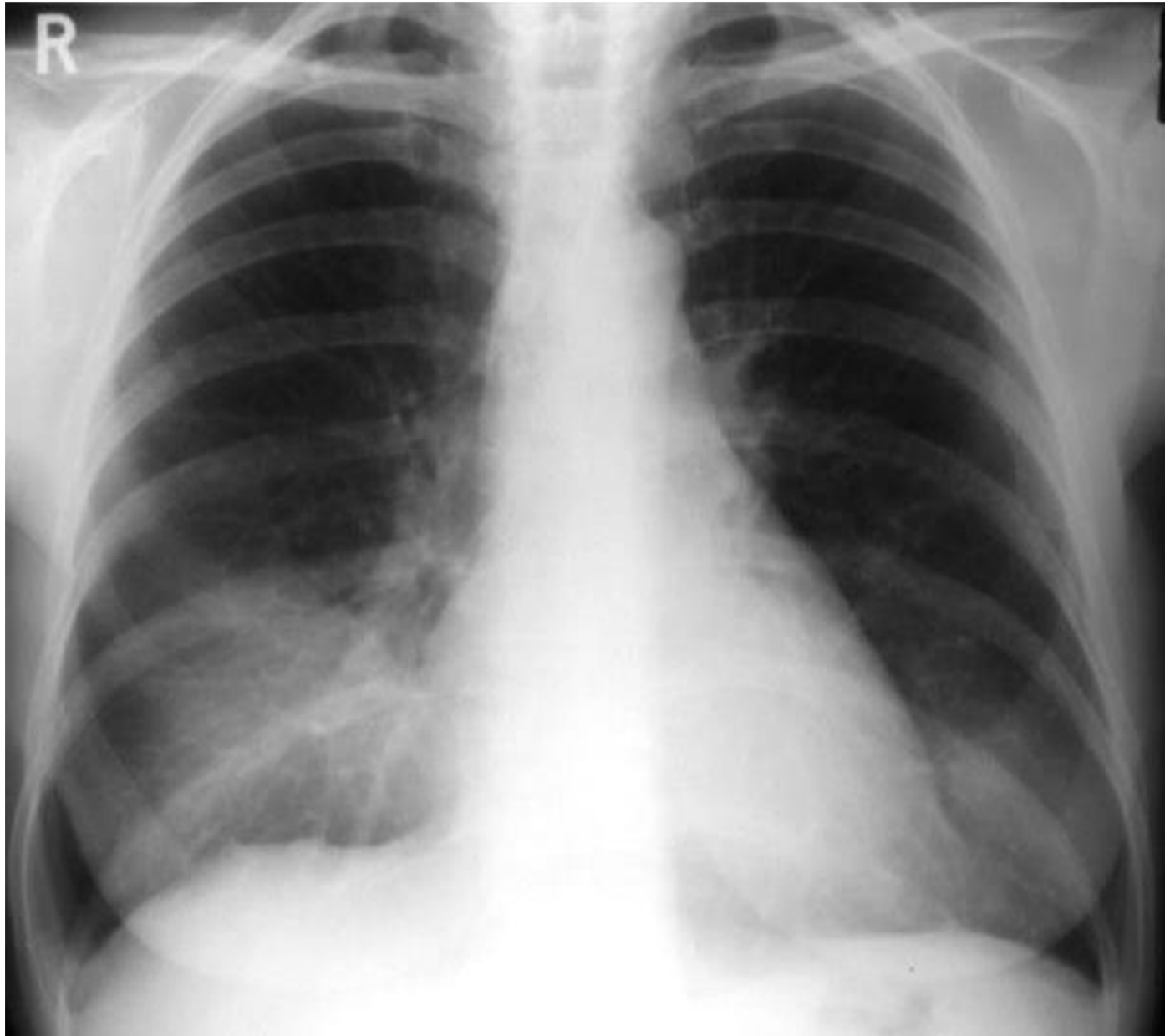
Sol alt lob atelektazisi

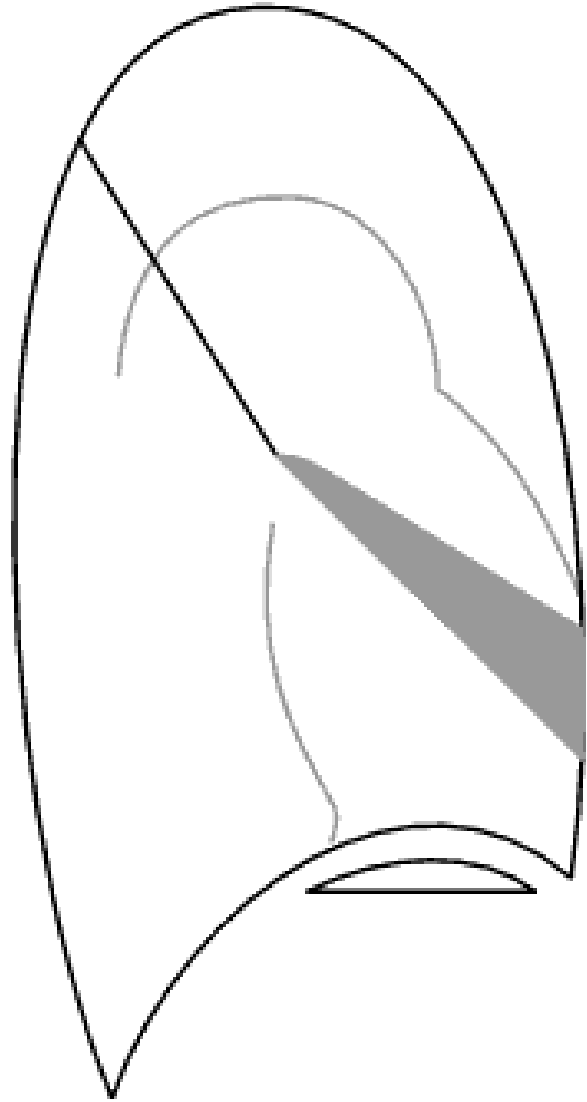
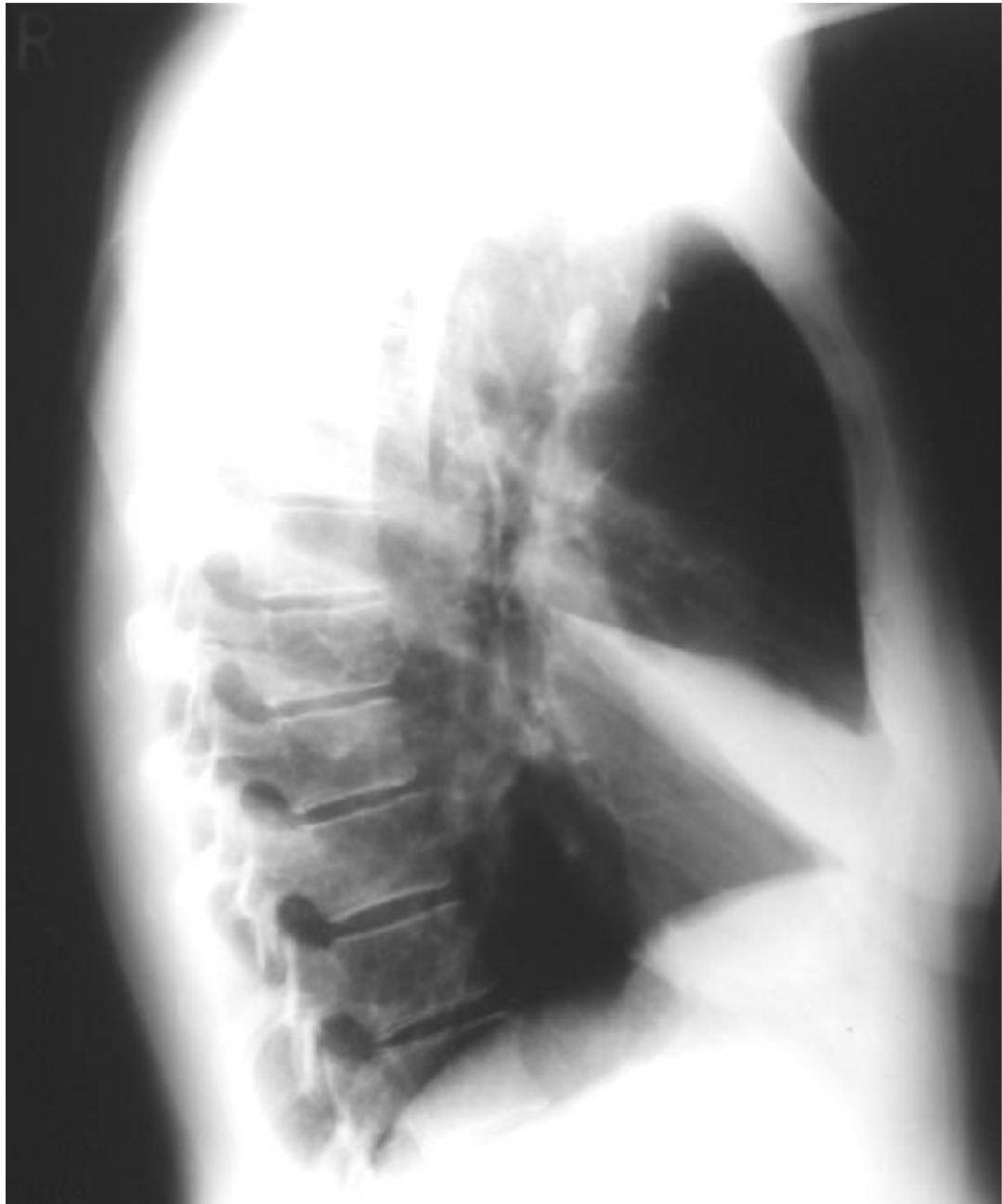

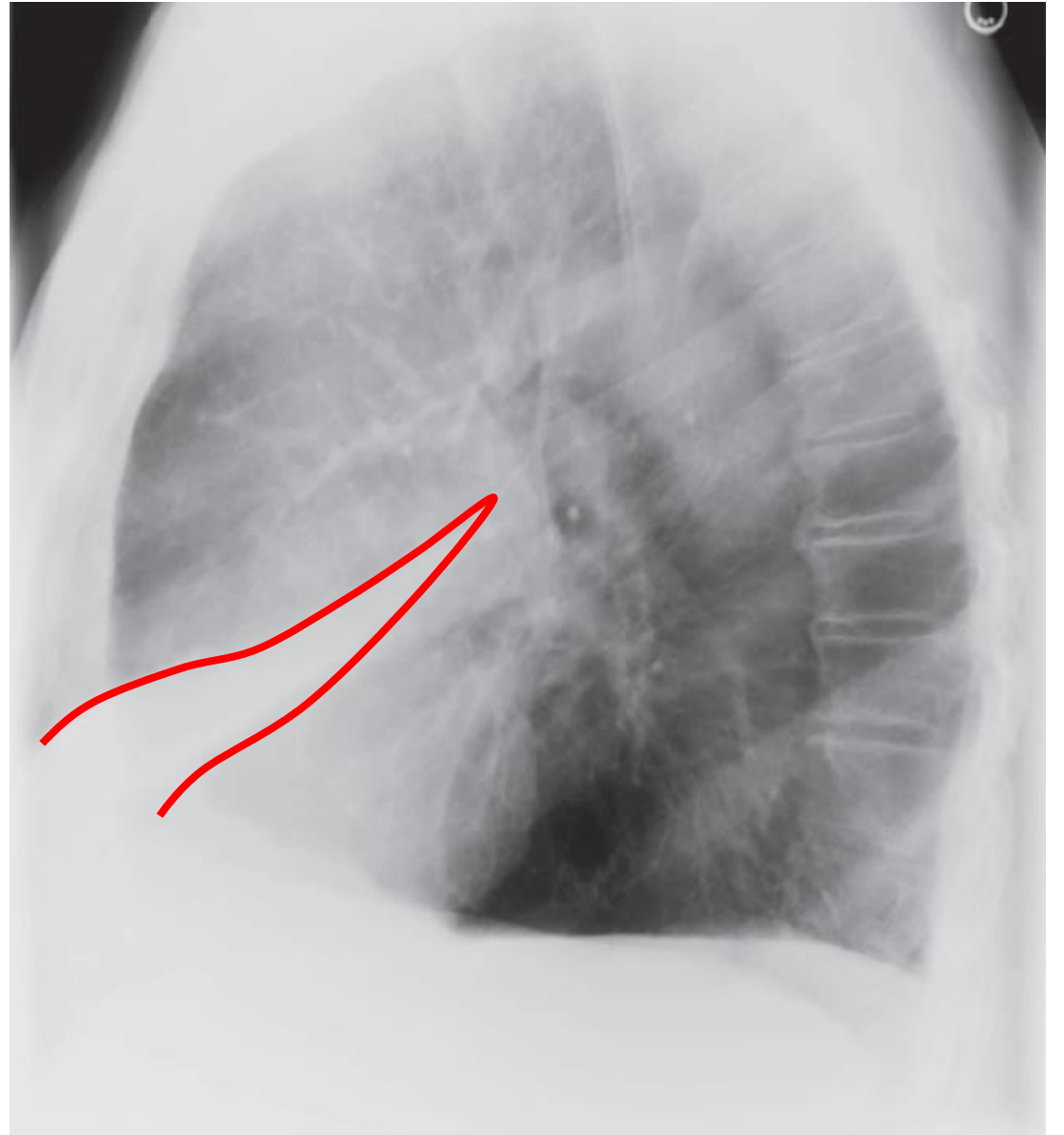
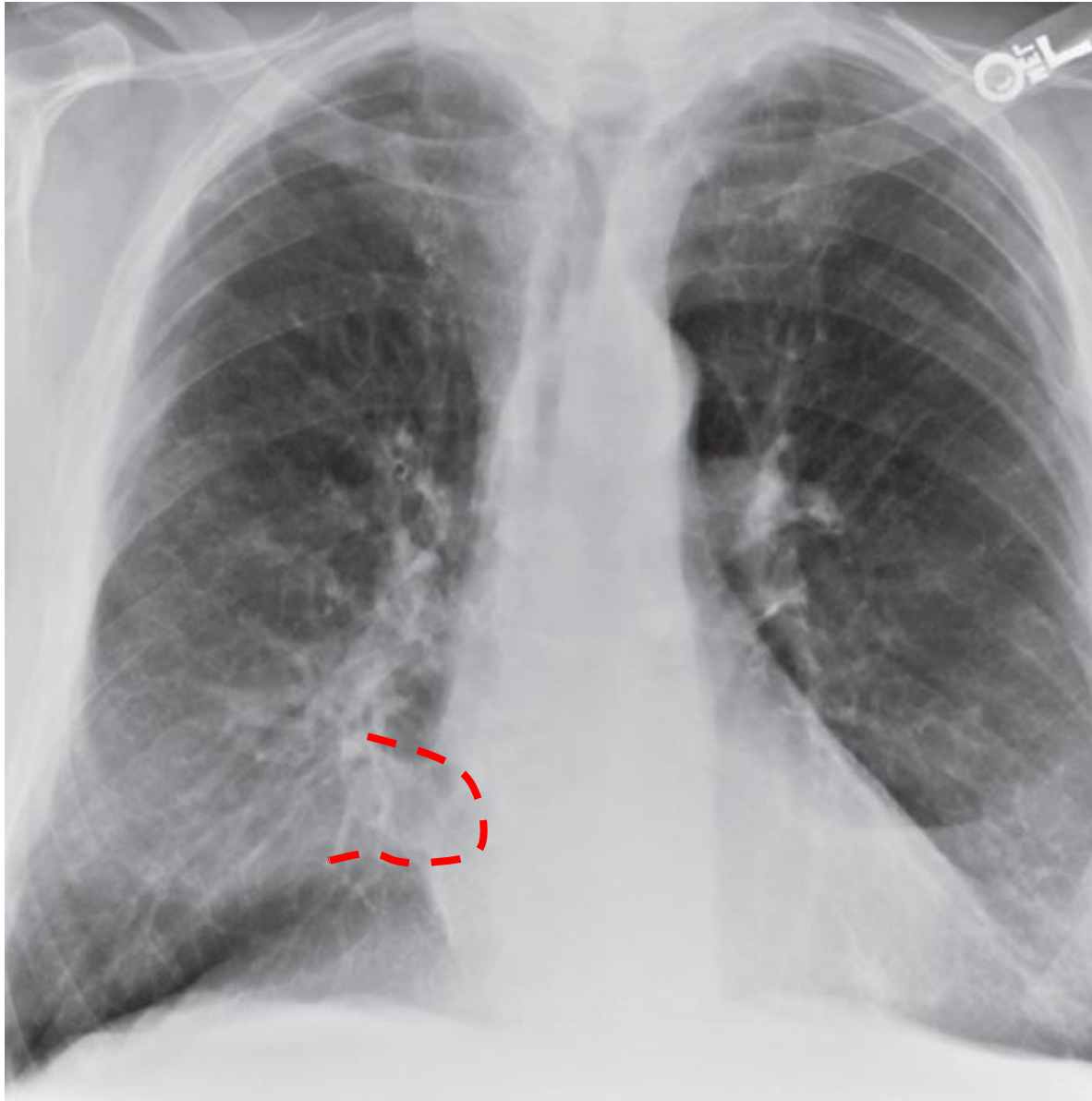


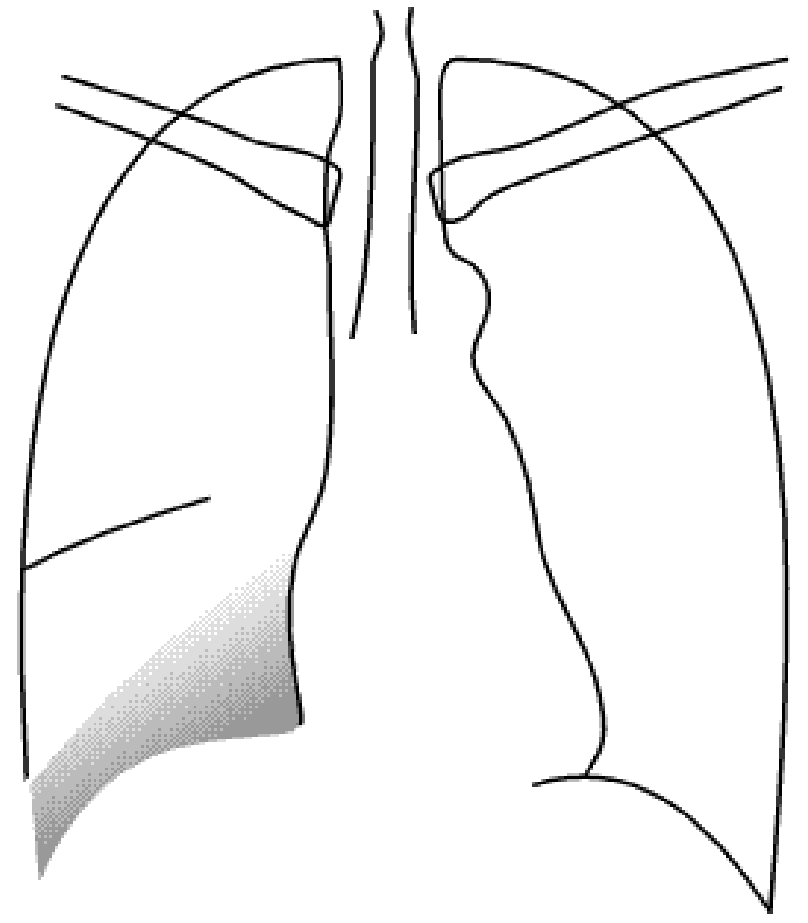

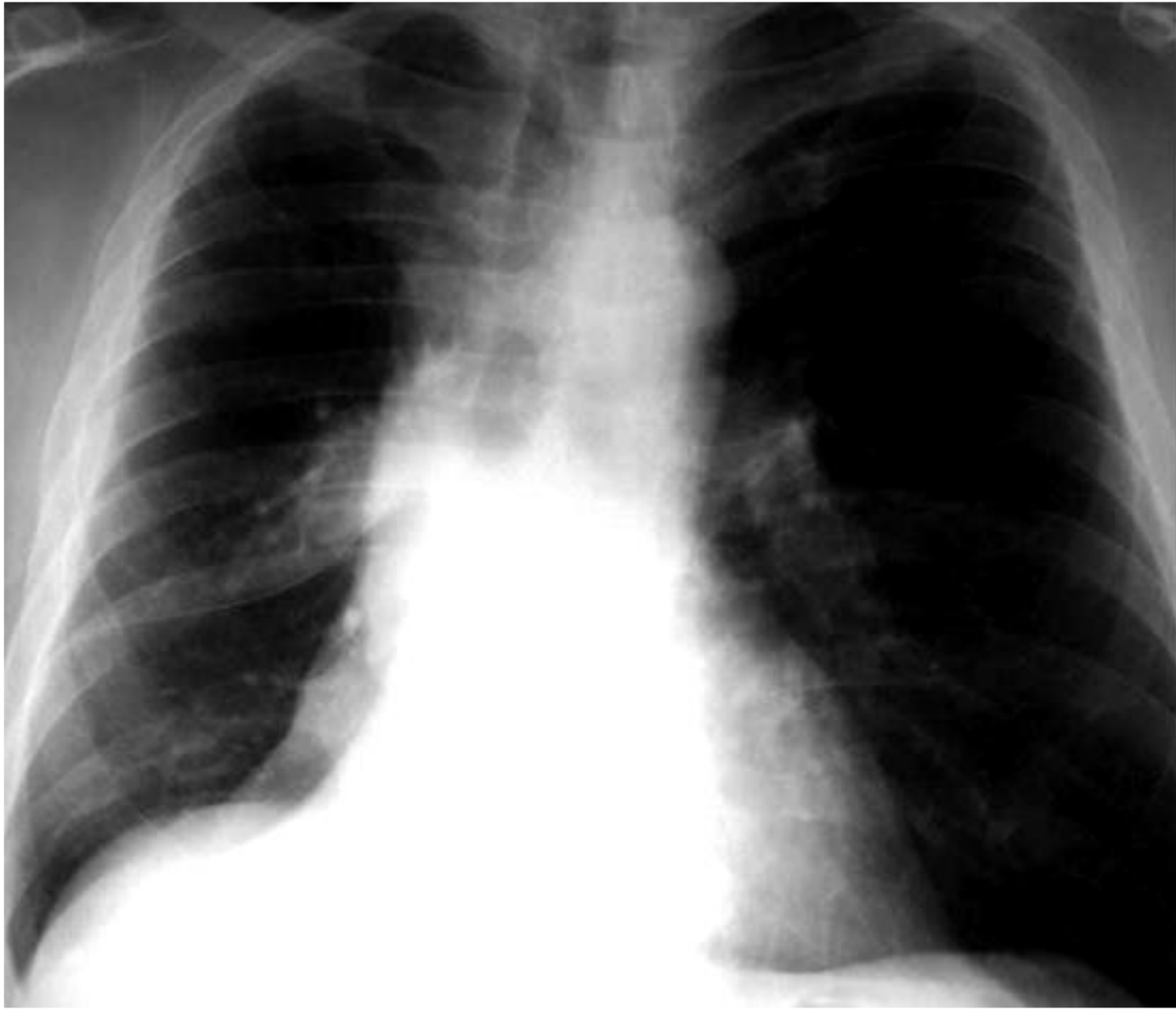
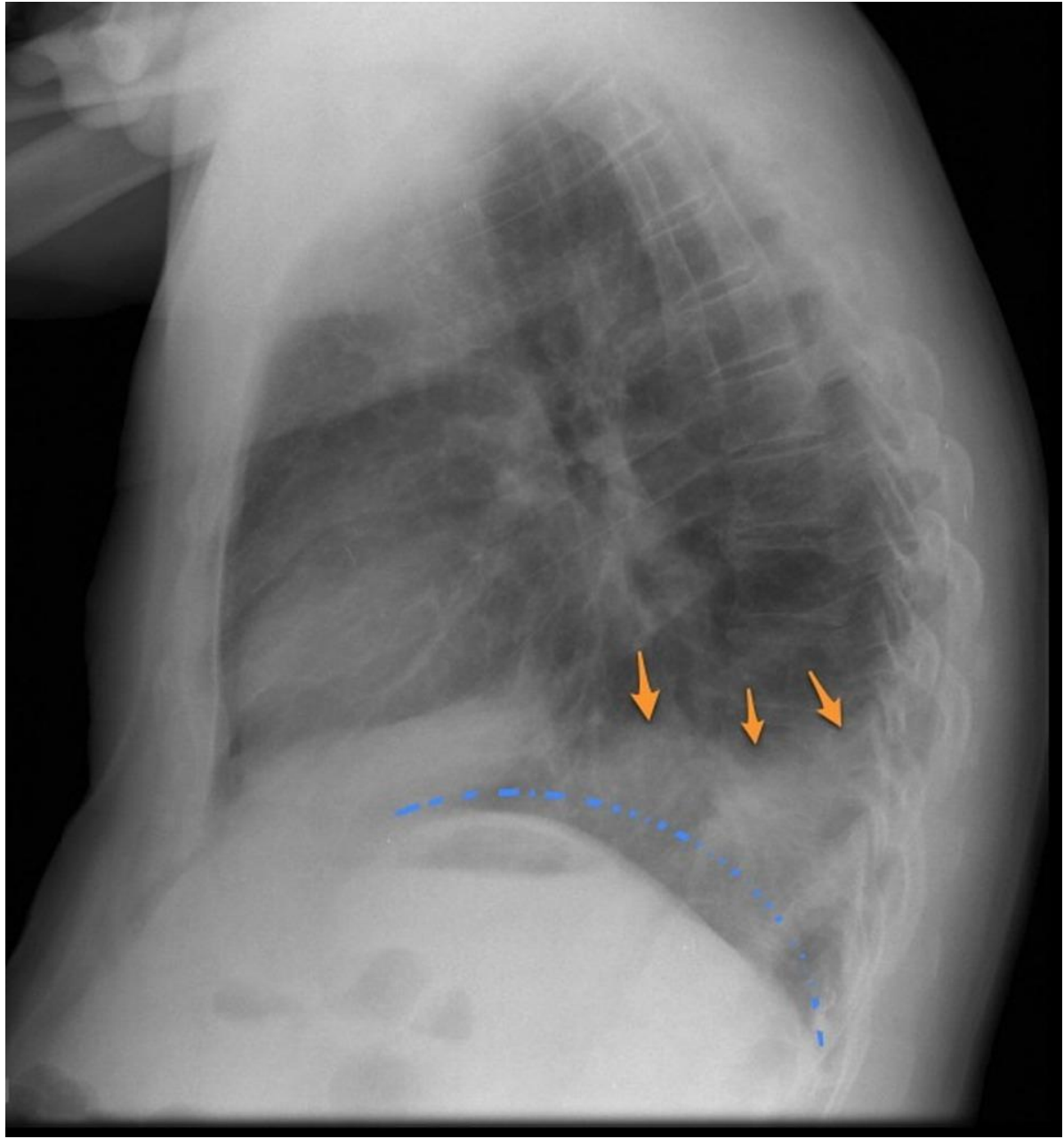
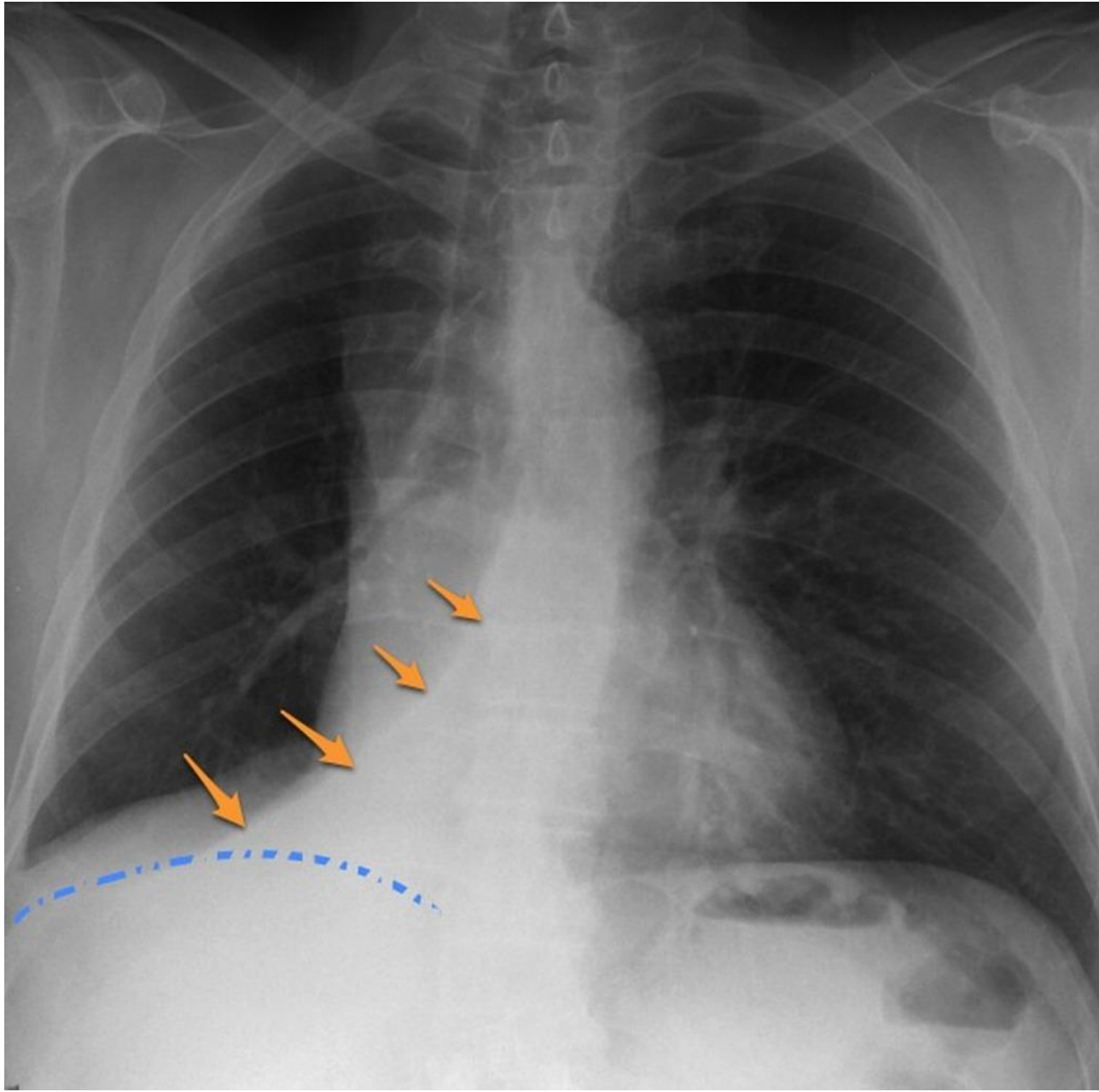




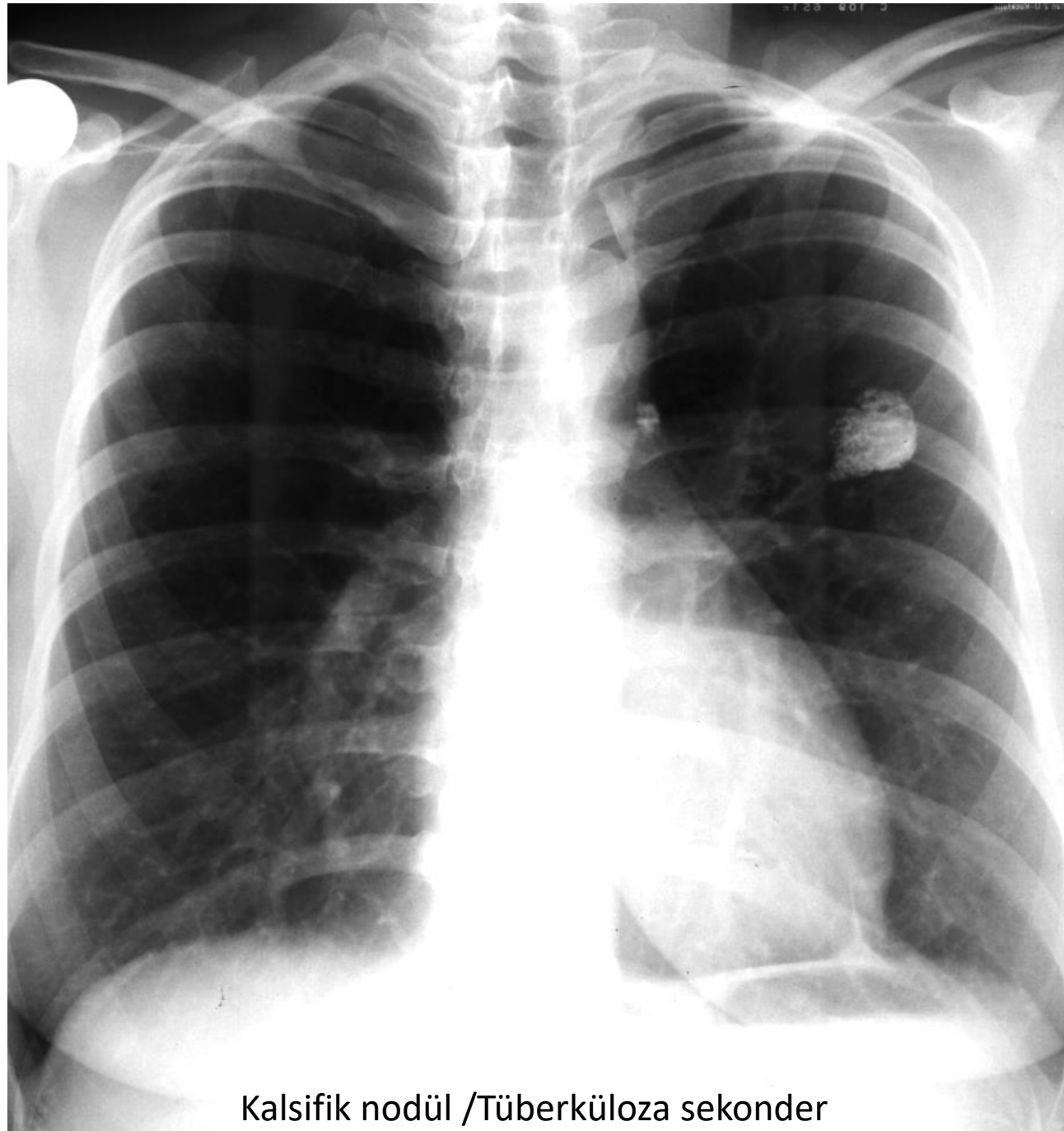




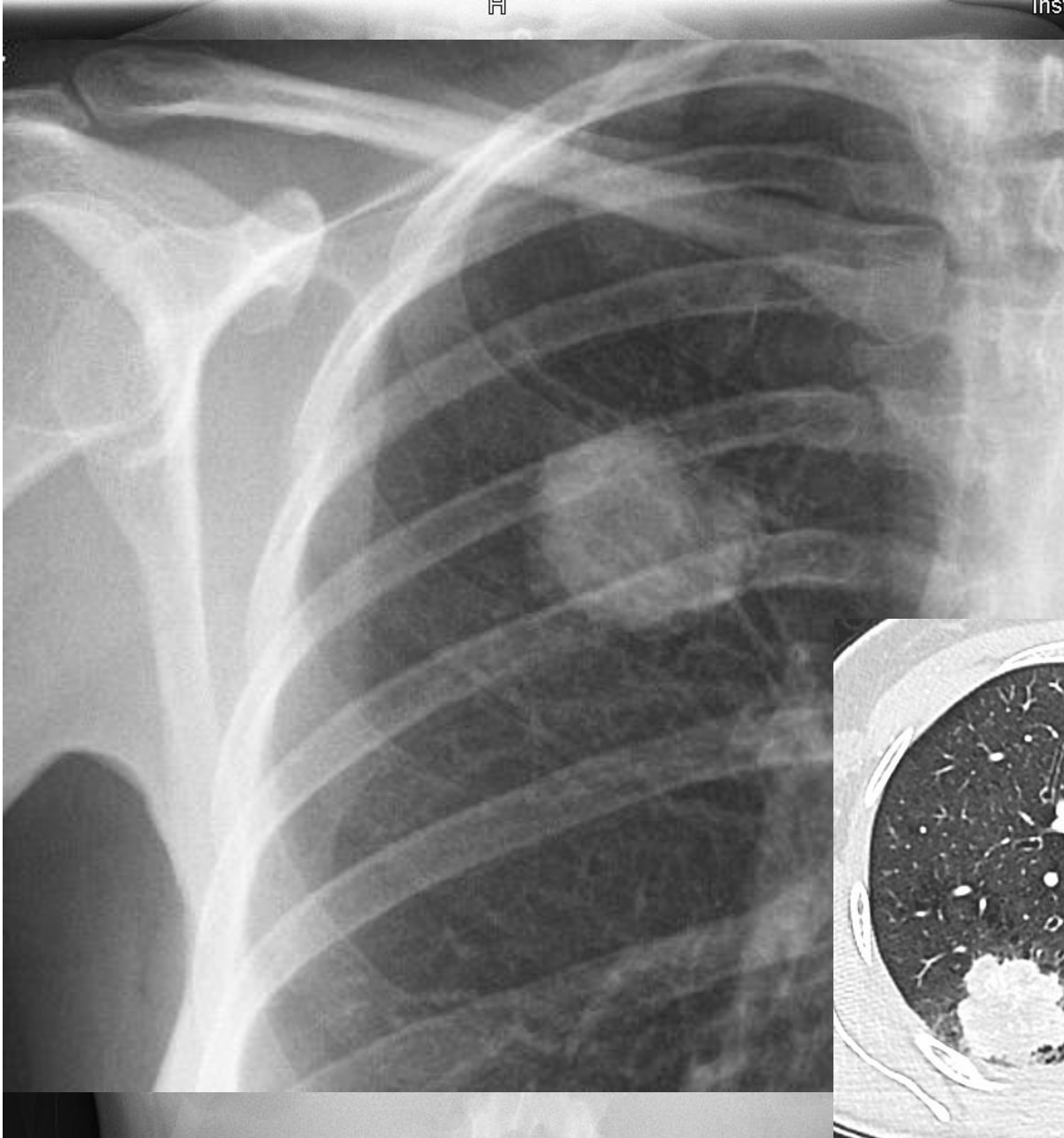




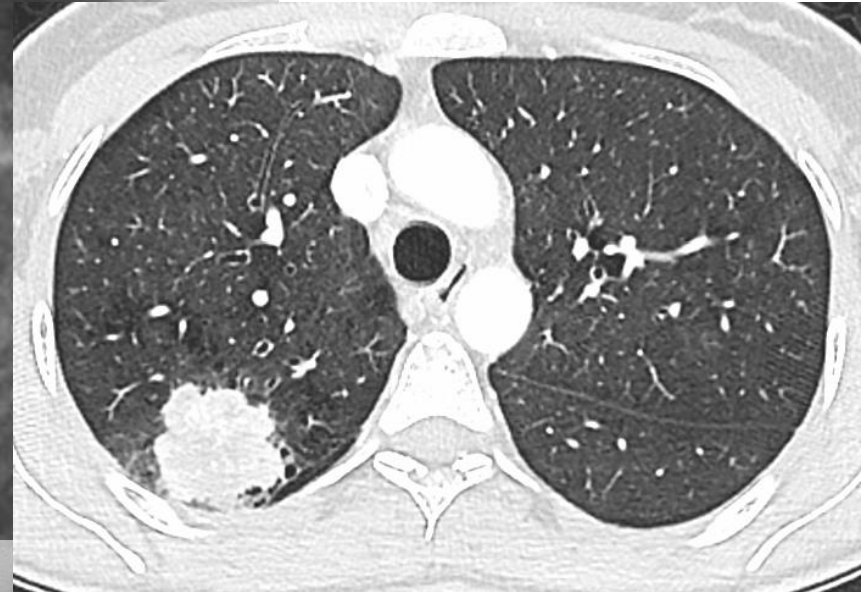
NODÜL / KİTLE
(Tek, çoklu)

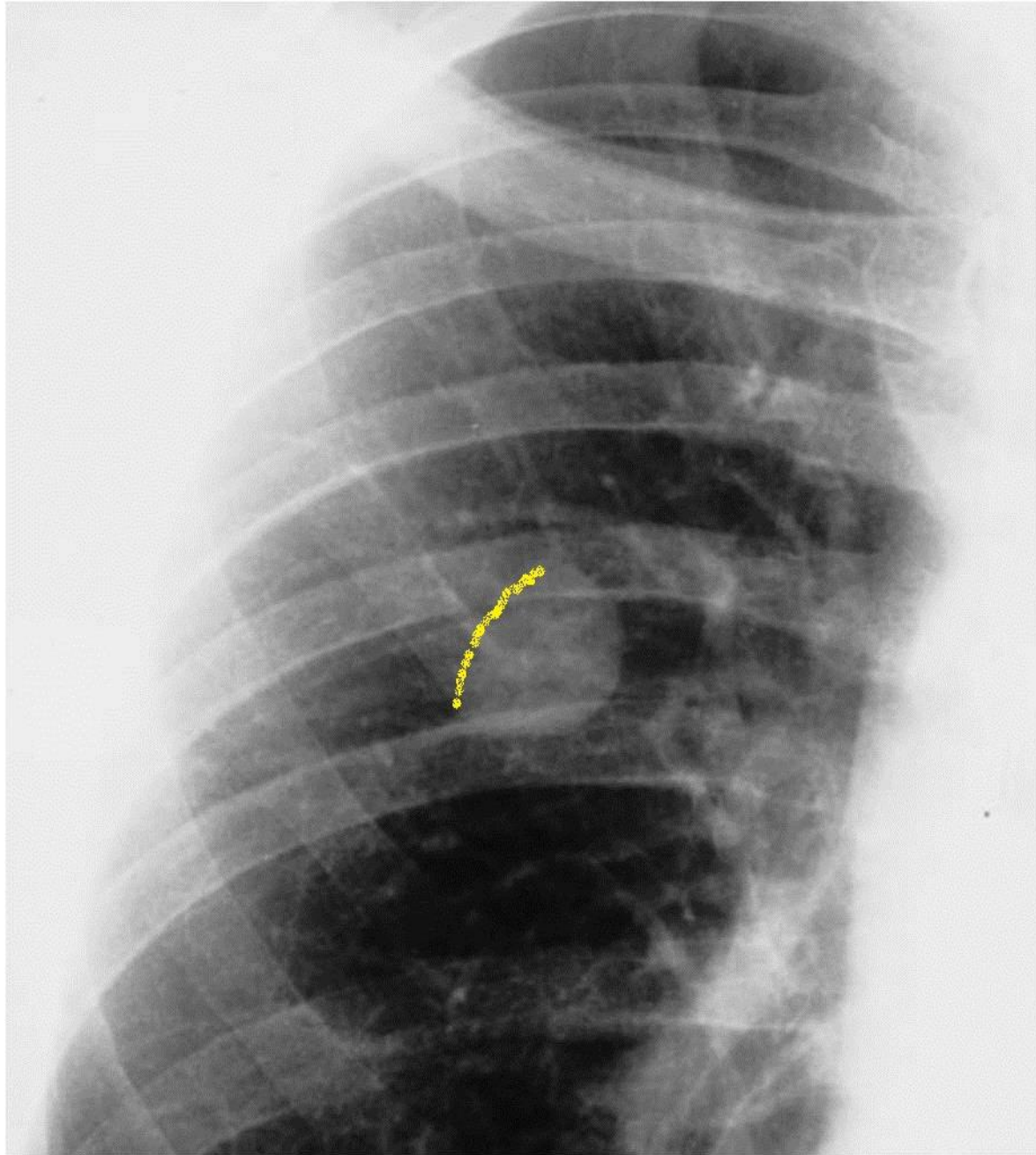


Kalsifik nodül /Tüberküloza sekonder



Malign nodül
Adenokanser





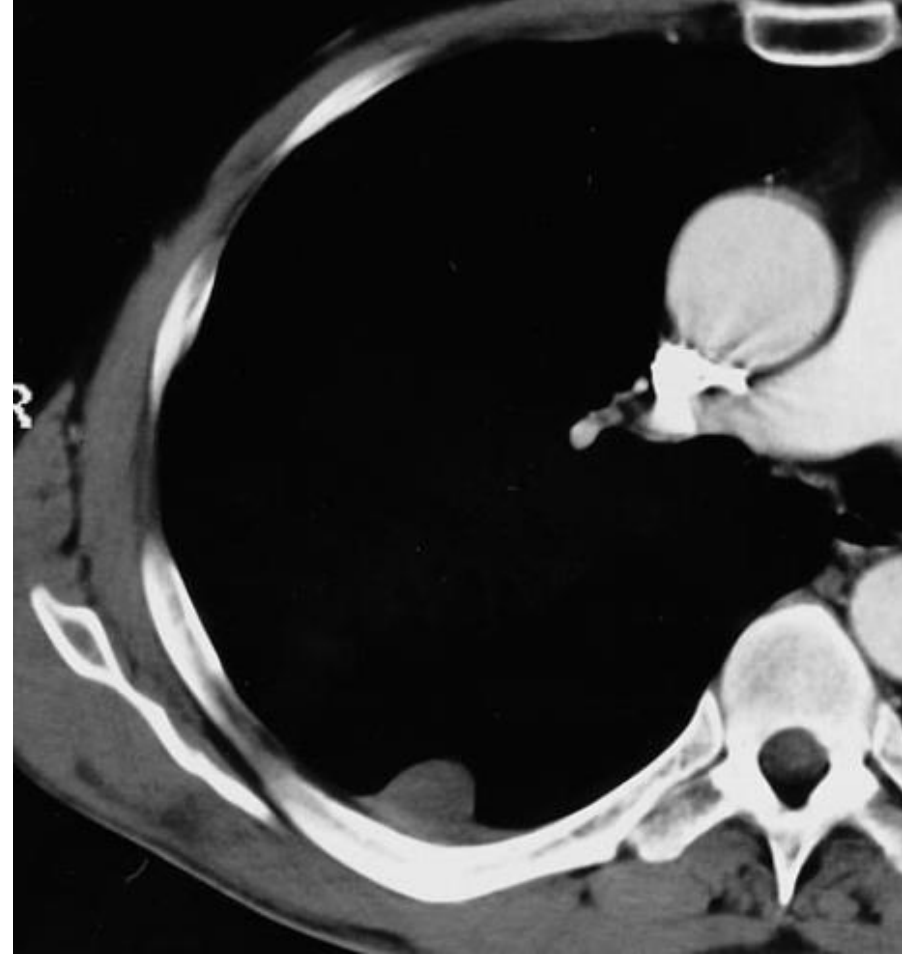
Tam olmayan kenar işareti (Incomplete border)

Parankimal olmayan
lezyonlarda;

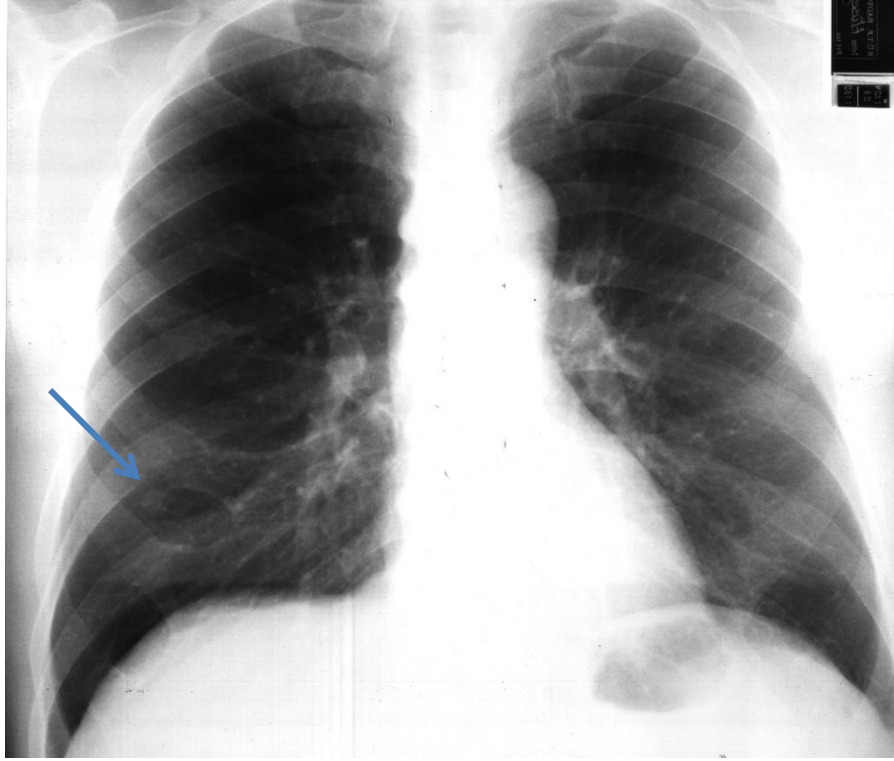
*düzgün kontur ve

*konturu net seçilemeyen alan
birlikte izlenebilir.

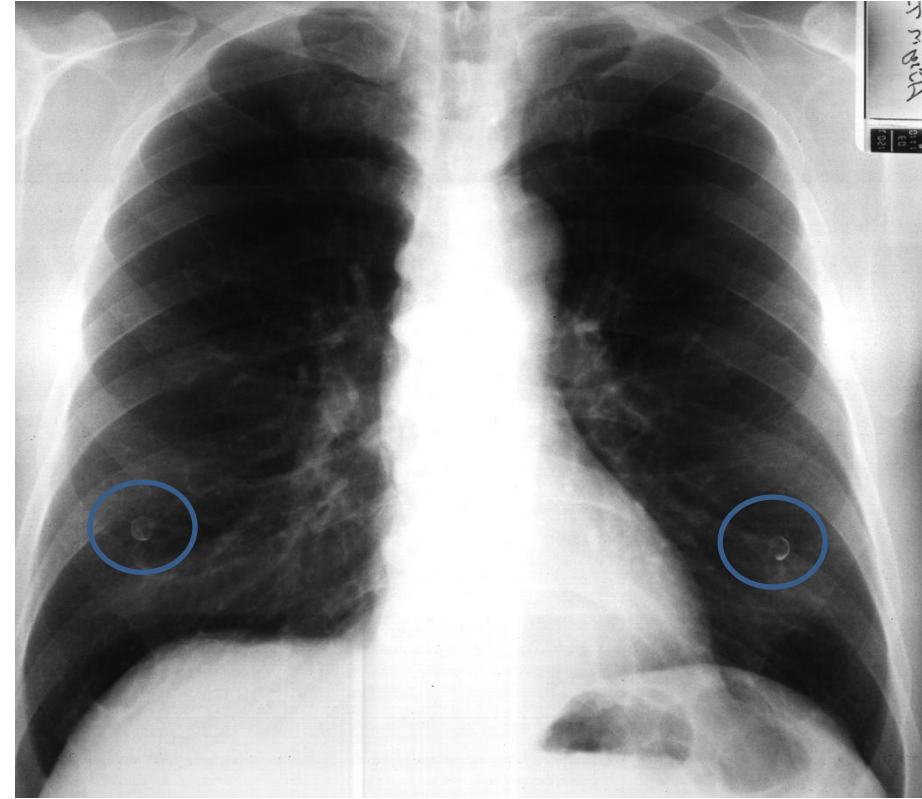
Böyle lezyonlar için, **tam
olmayan kenar işareti söz
konusudur ve ekstraparankimal
olduğunu gösterir**

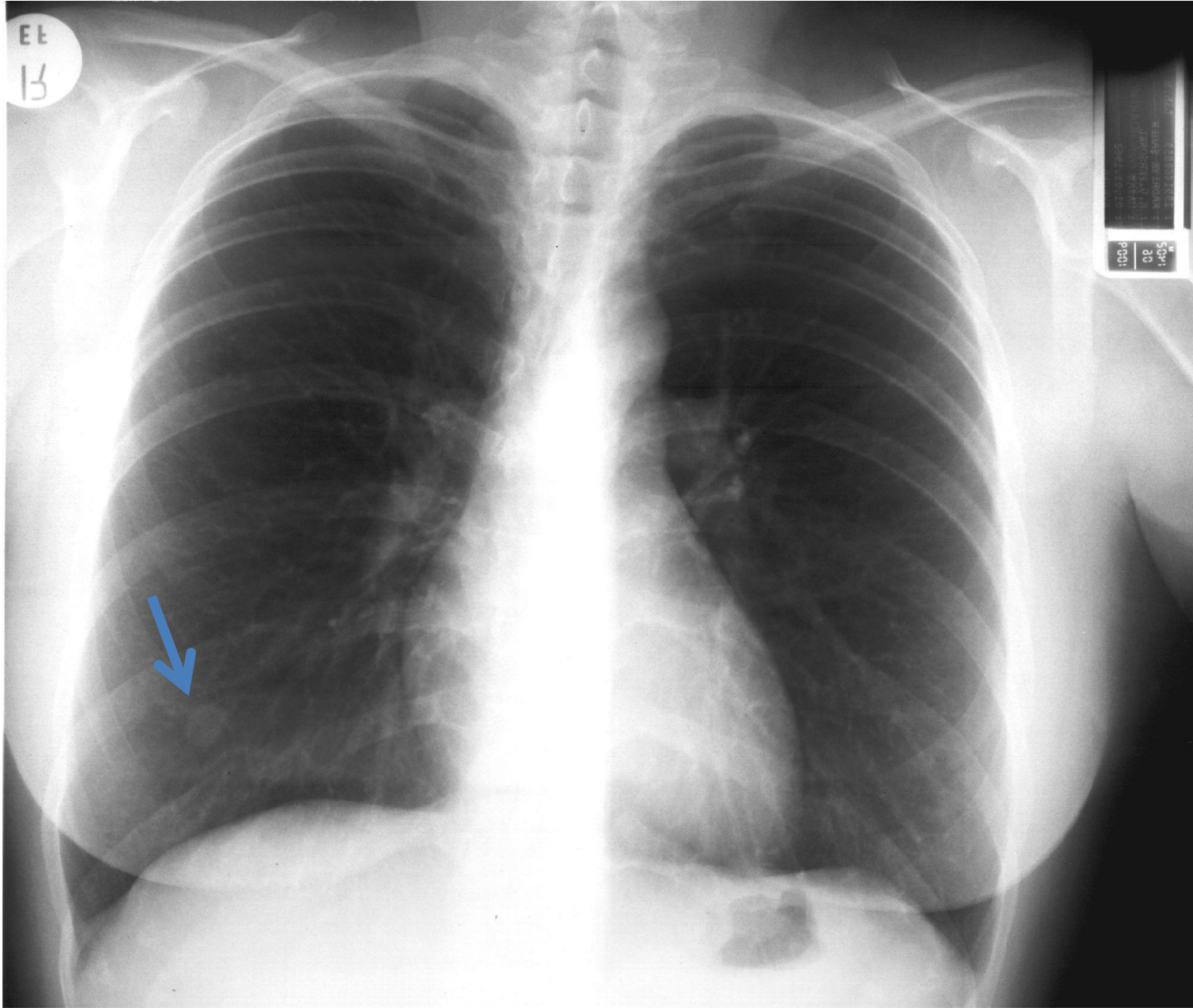


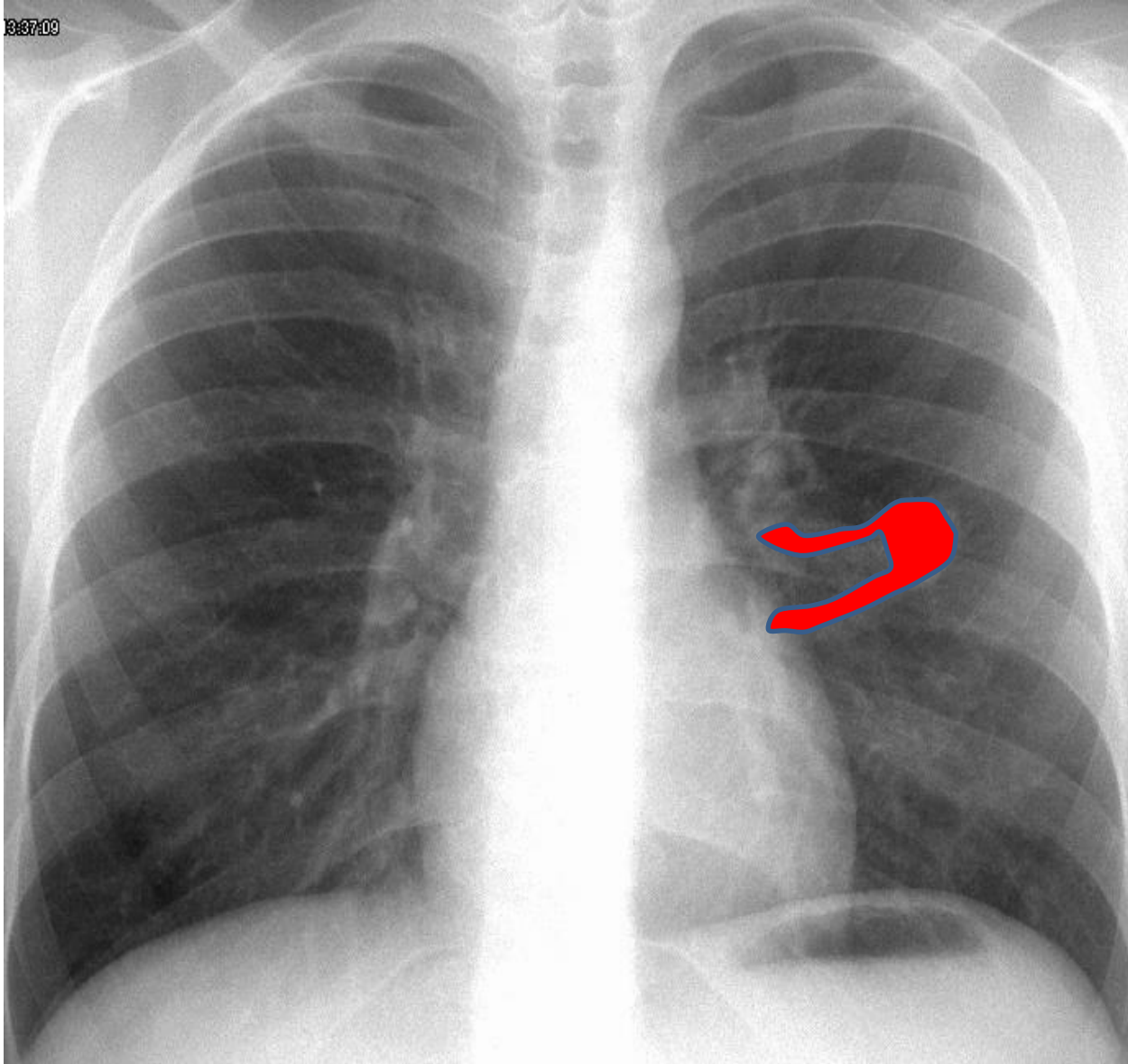
SCHWANNOM



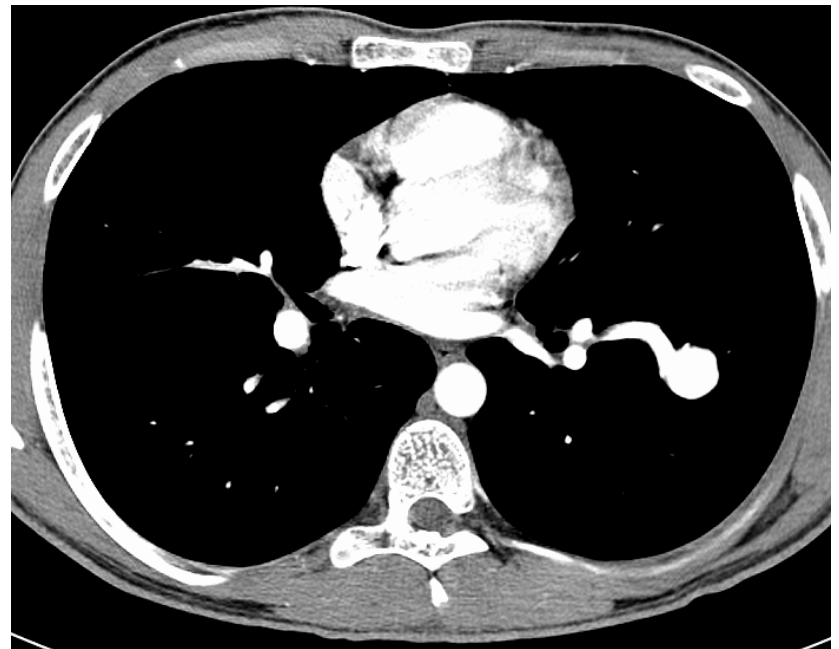YALANCI NODÜL
MEME BAŞI





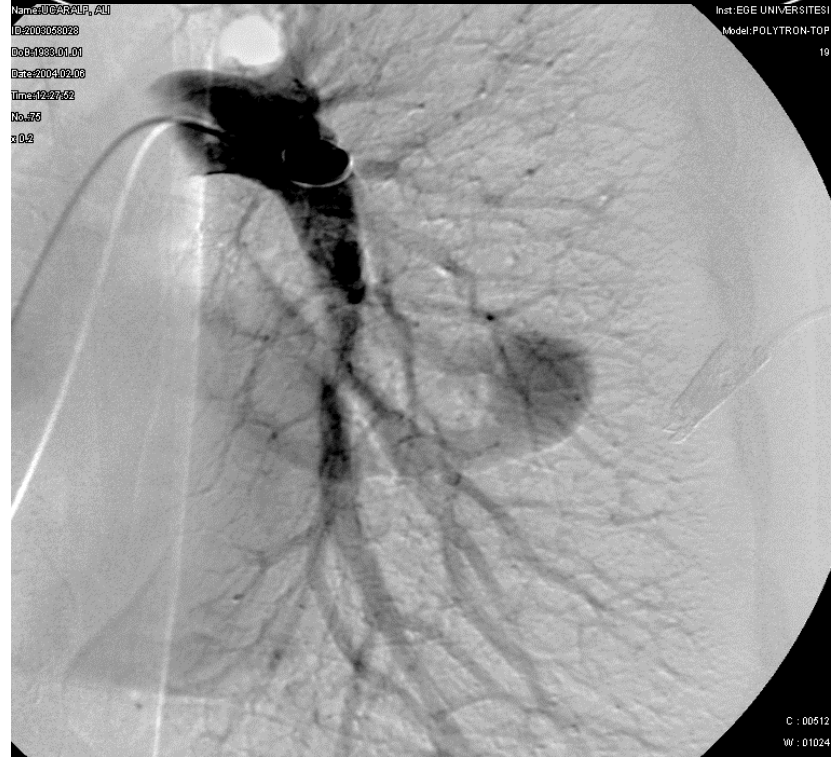

AVM

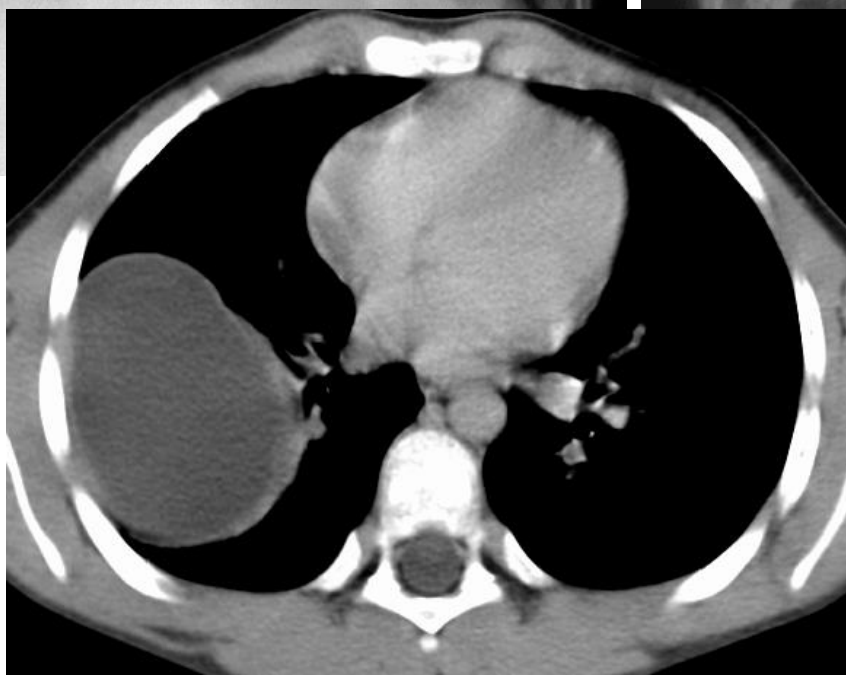
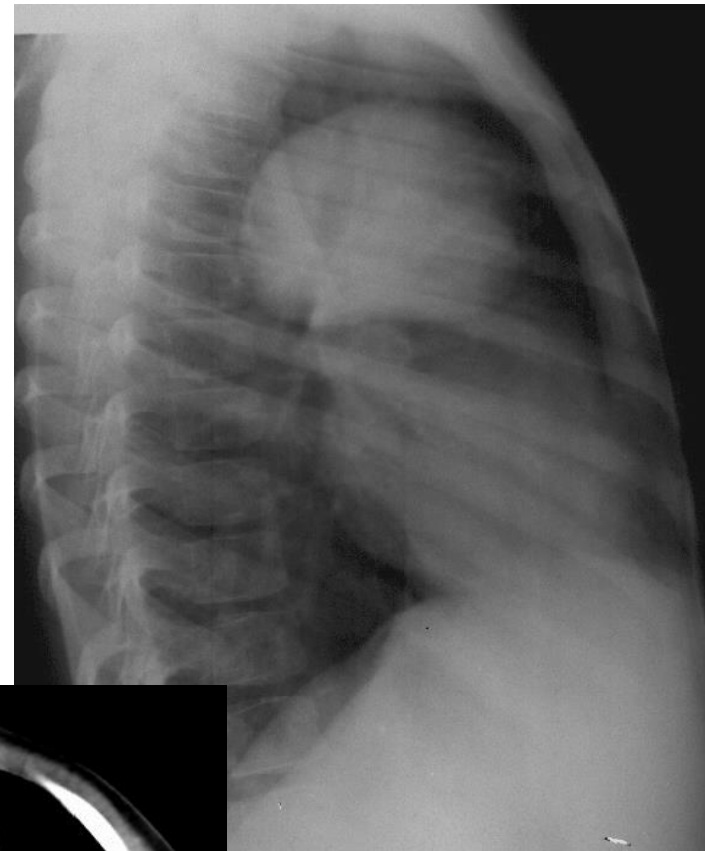
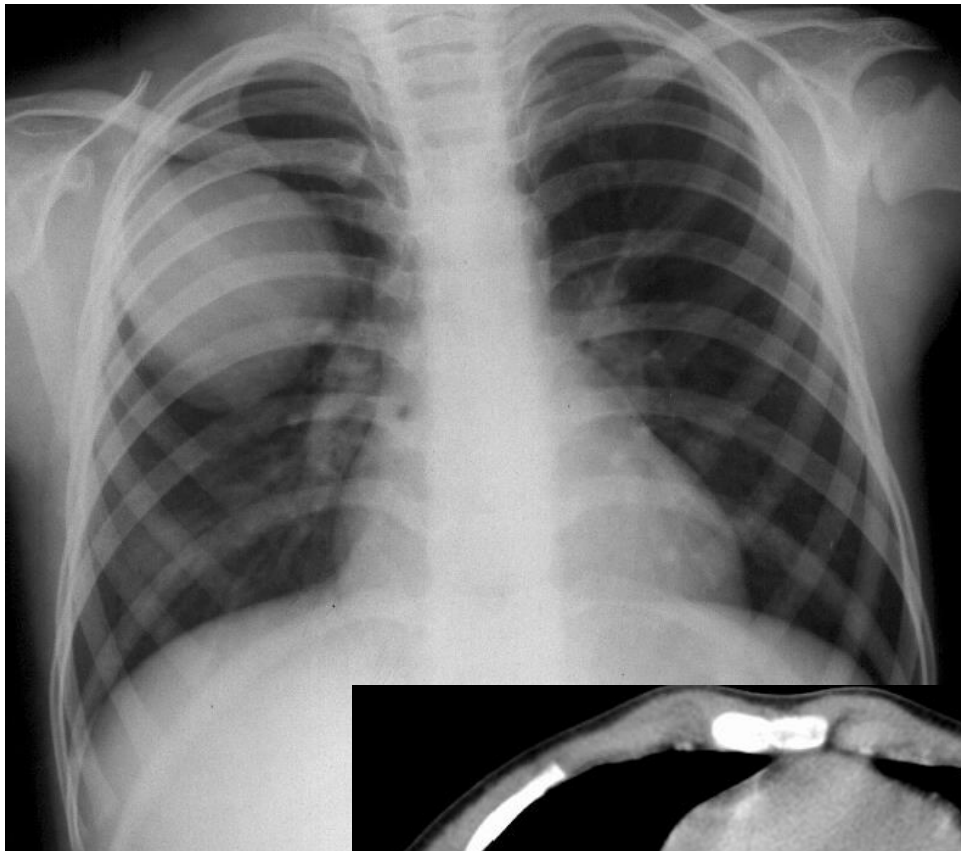


Name: TUGANAP, Ali
ID: 20055023
DoB: 1993.01.01
Date: 2024.02.08
Time: 12:27:52
No.: 55
x0.2

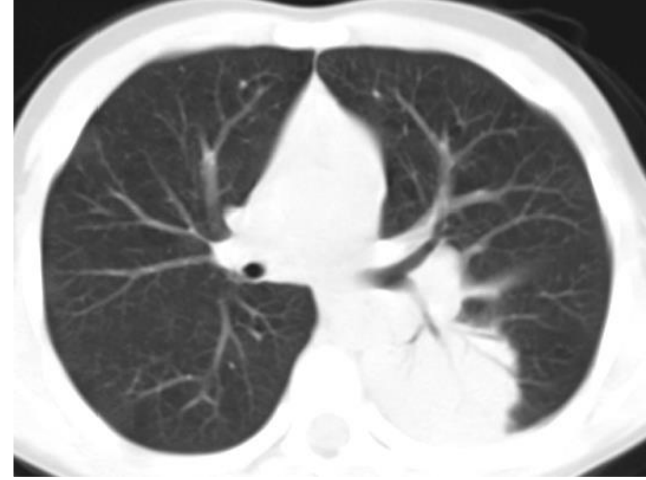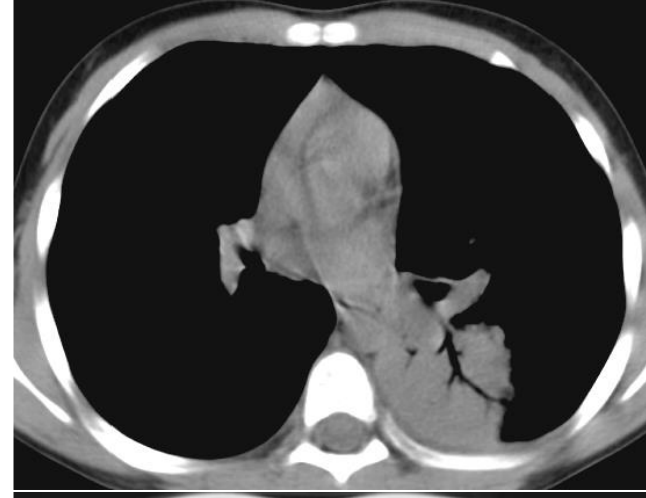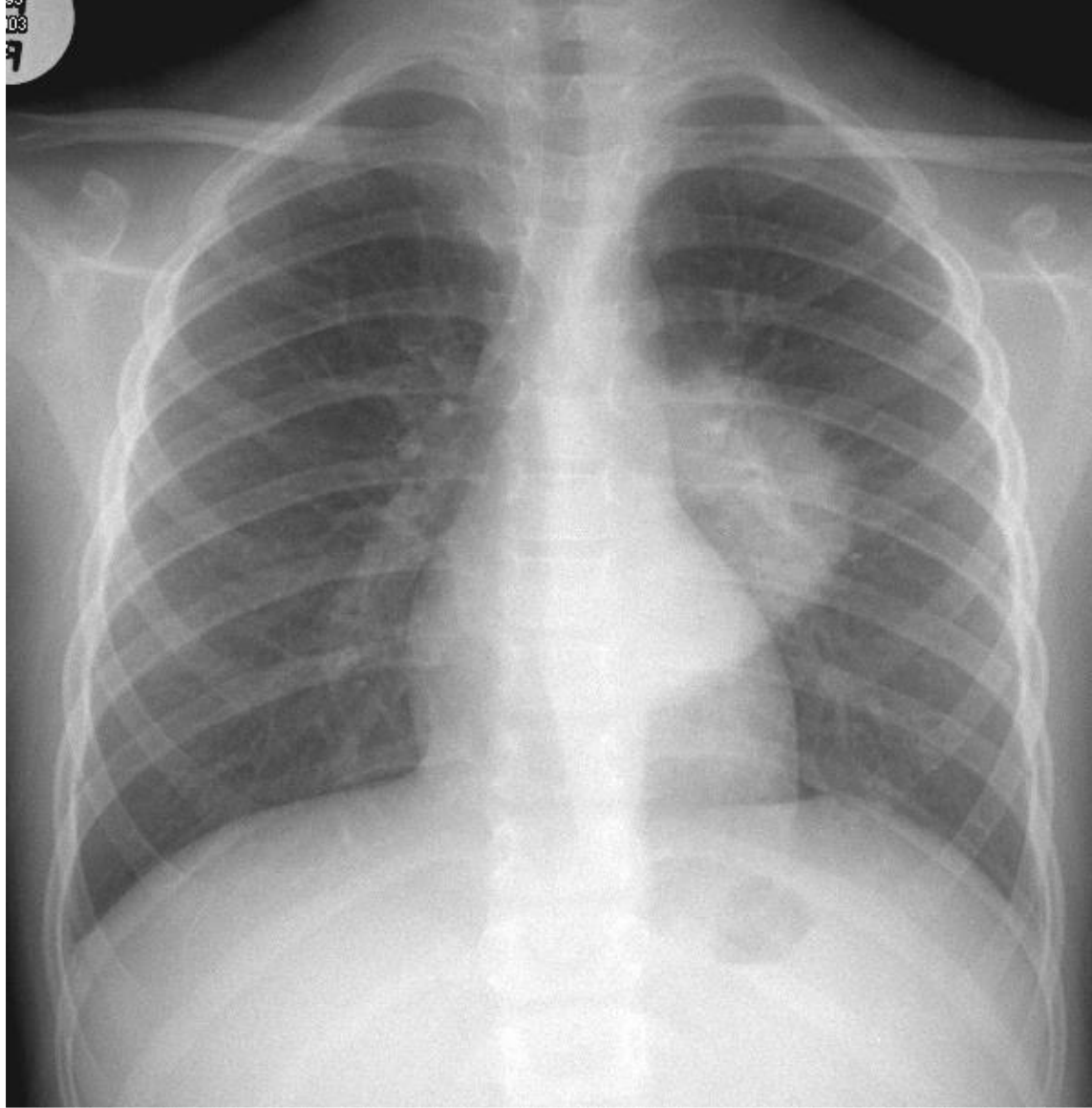
Inst: EGE UNIVERSITESI
Model: POLYTRON-TOP
19



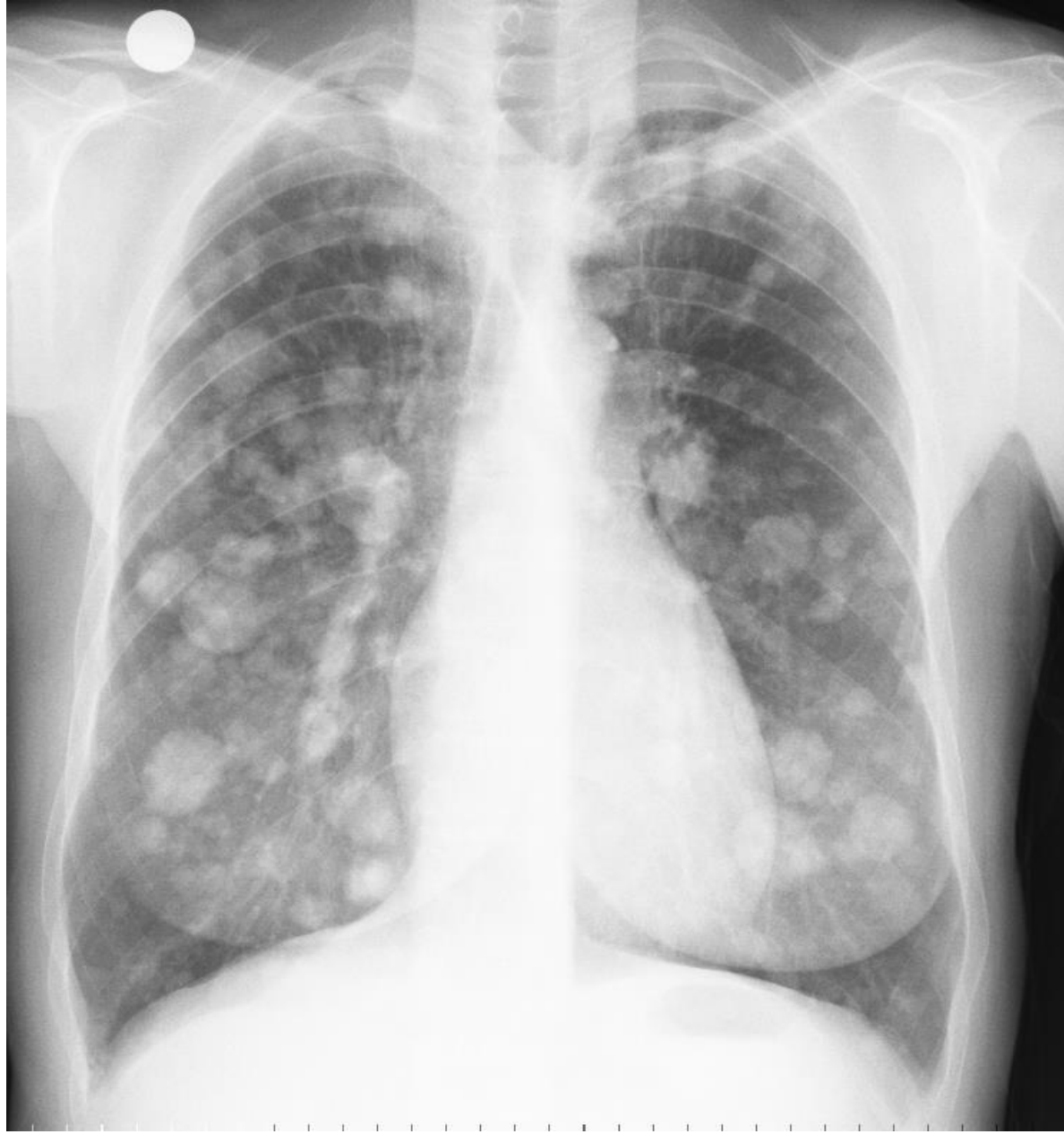C - 00512
W - 01024



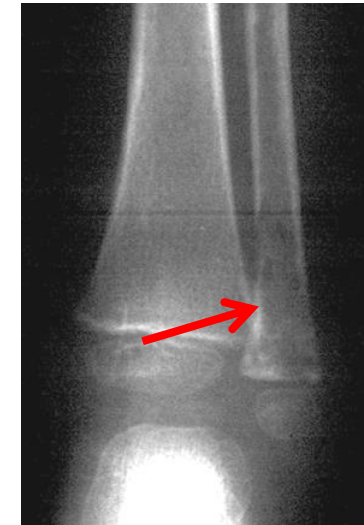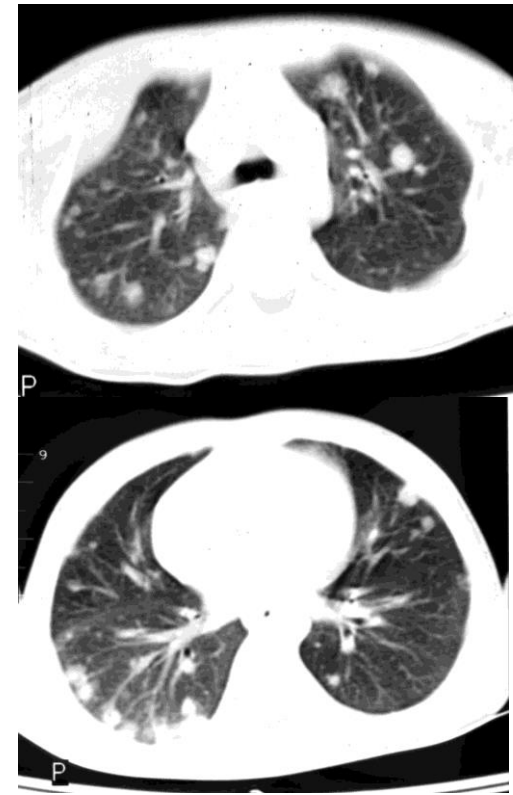
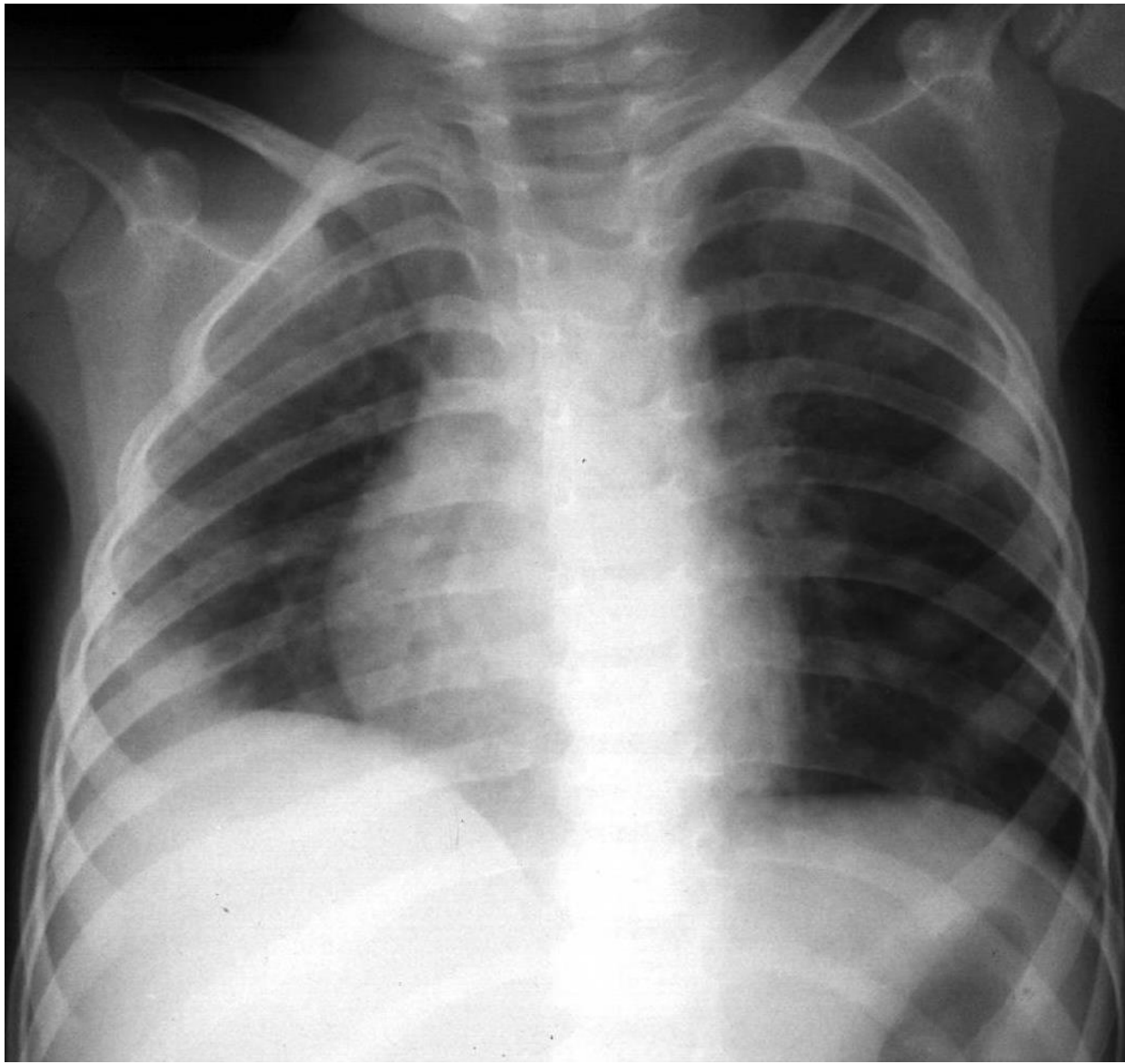
Kist hidatik



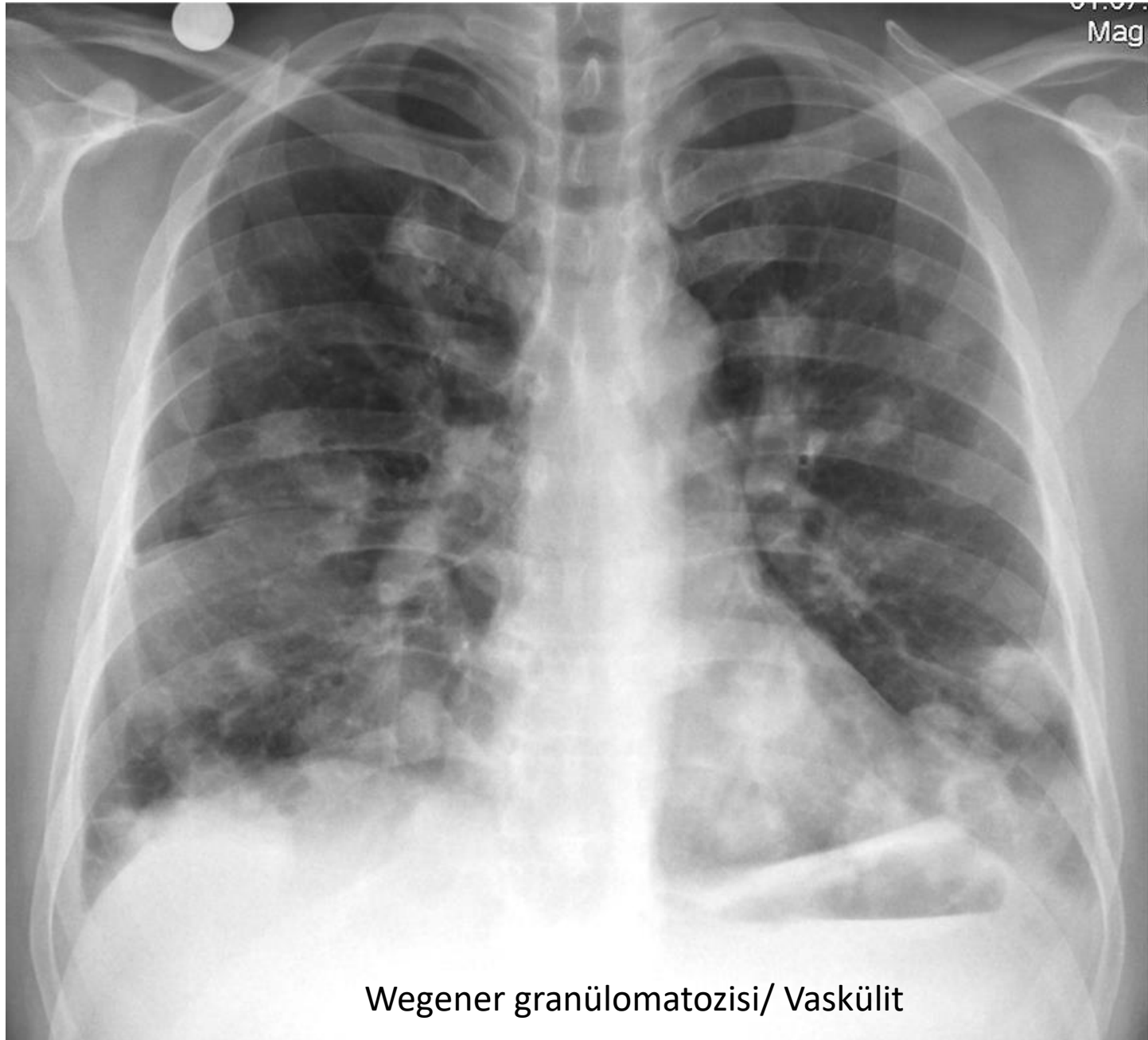Yuvarlak pnömoni



Akciğer metastazi

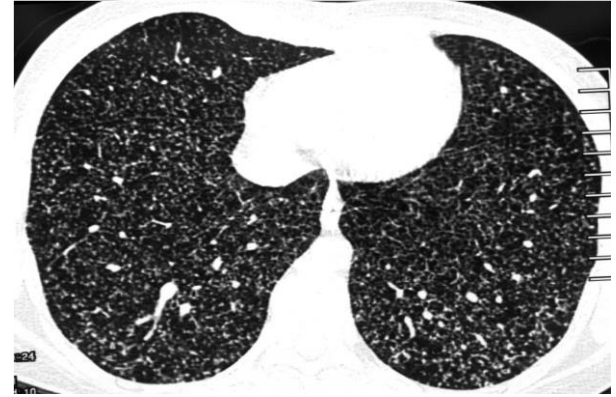
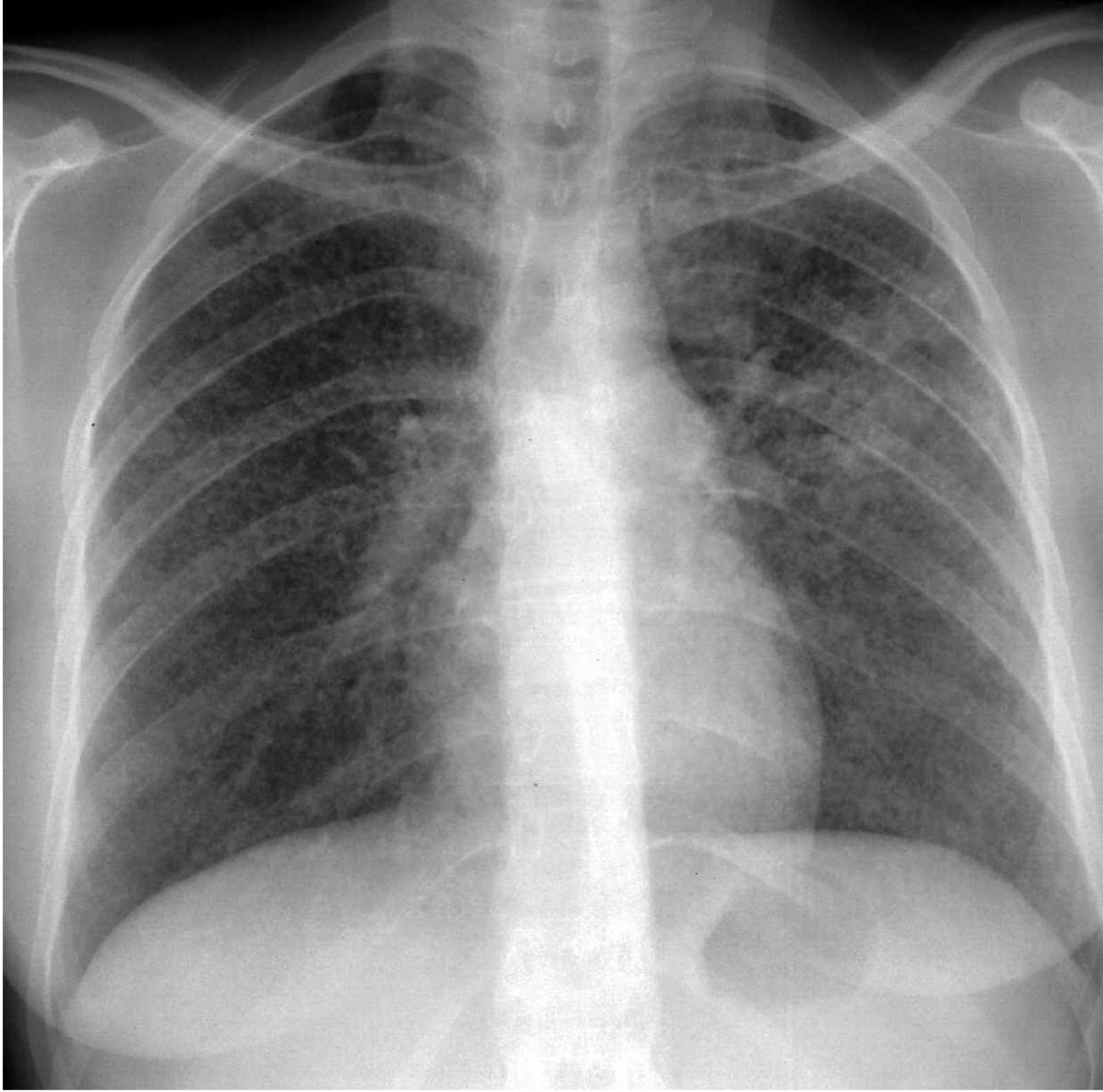


Septik emboli /osteomyelite baęlı

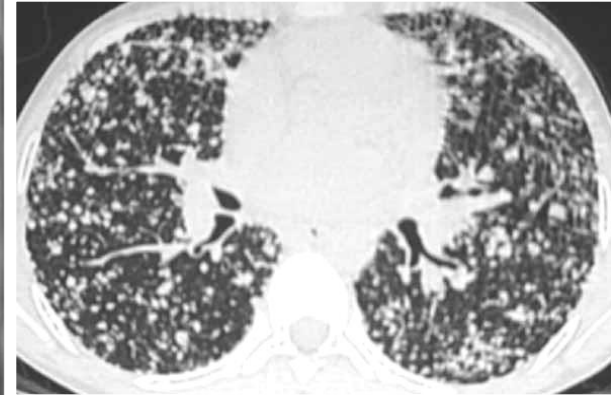
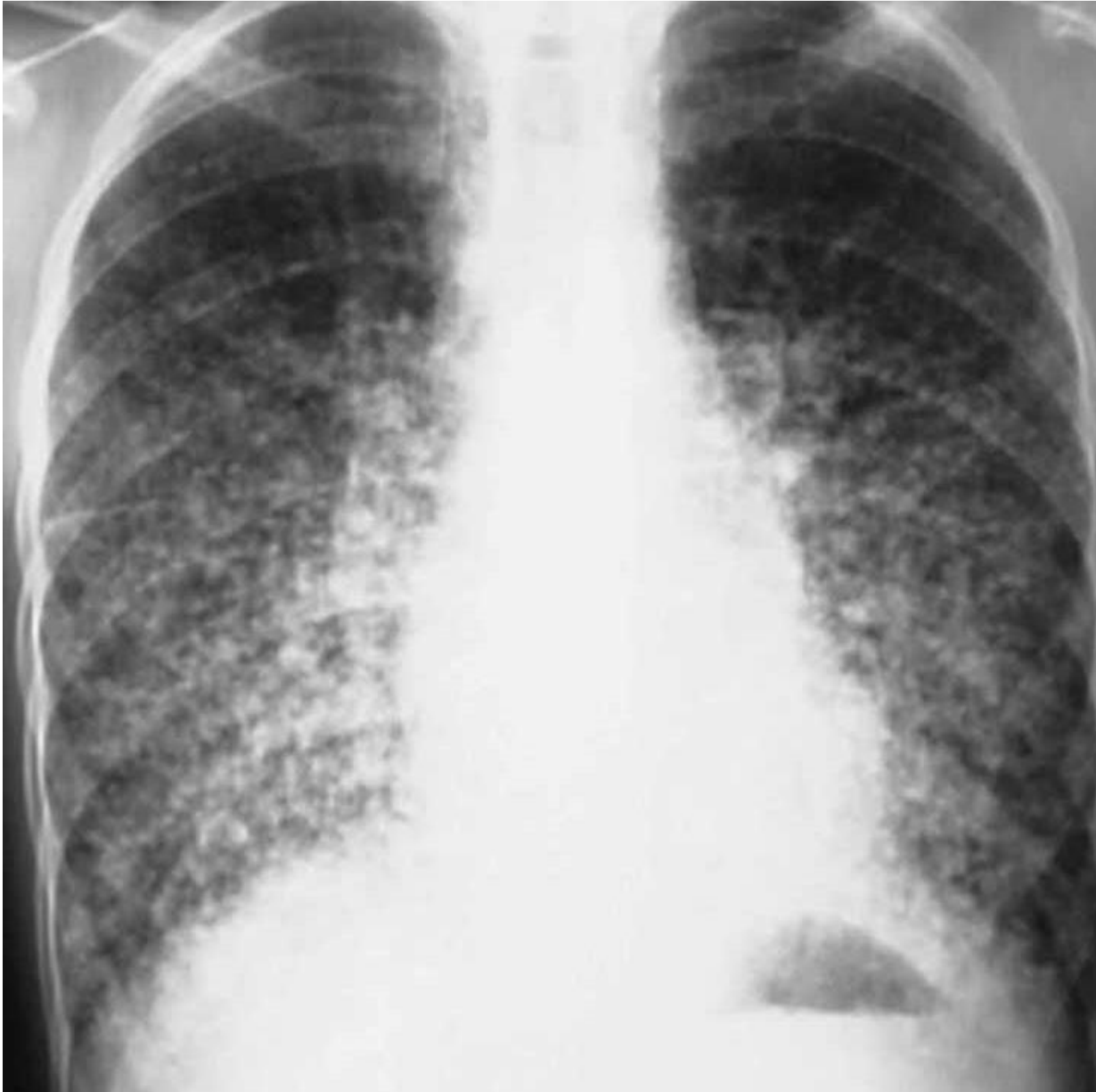

Wegener granülomatozisi/ Vaskülit

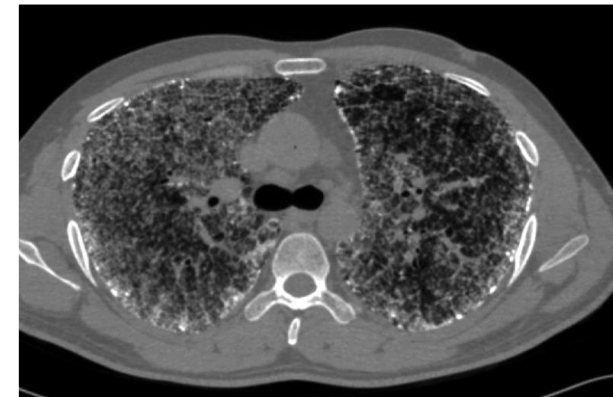
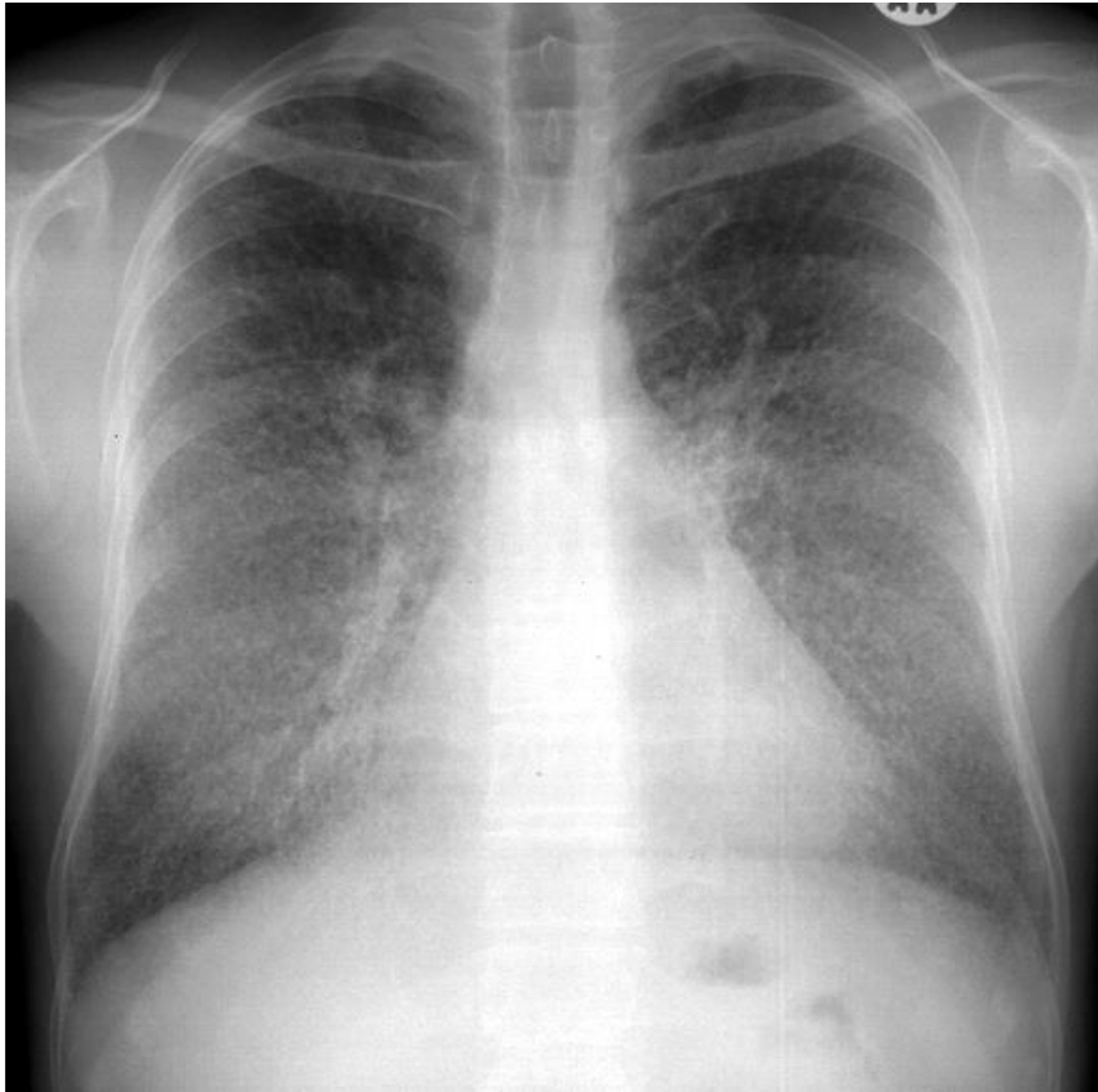MİLYER/ LİNEER/ RETİKÜLER DENSİTE ARTIŞI



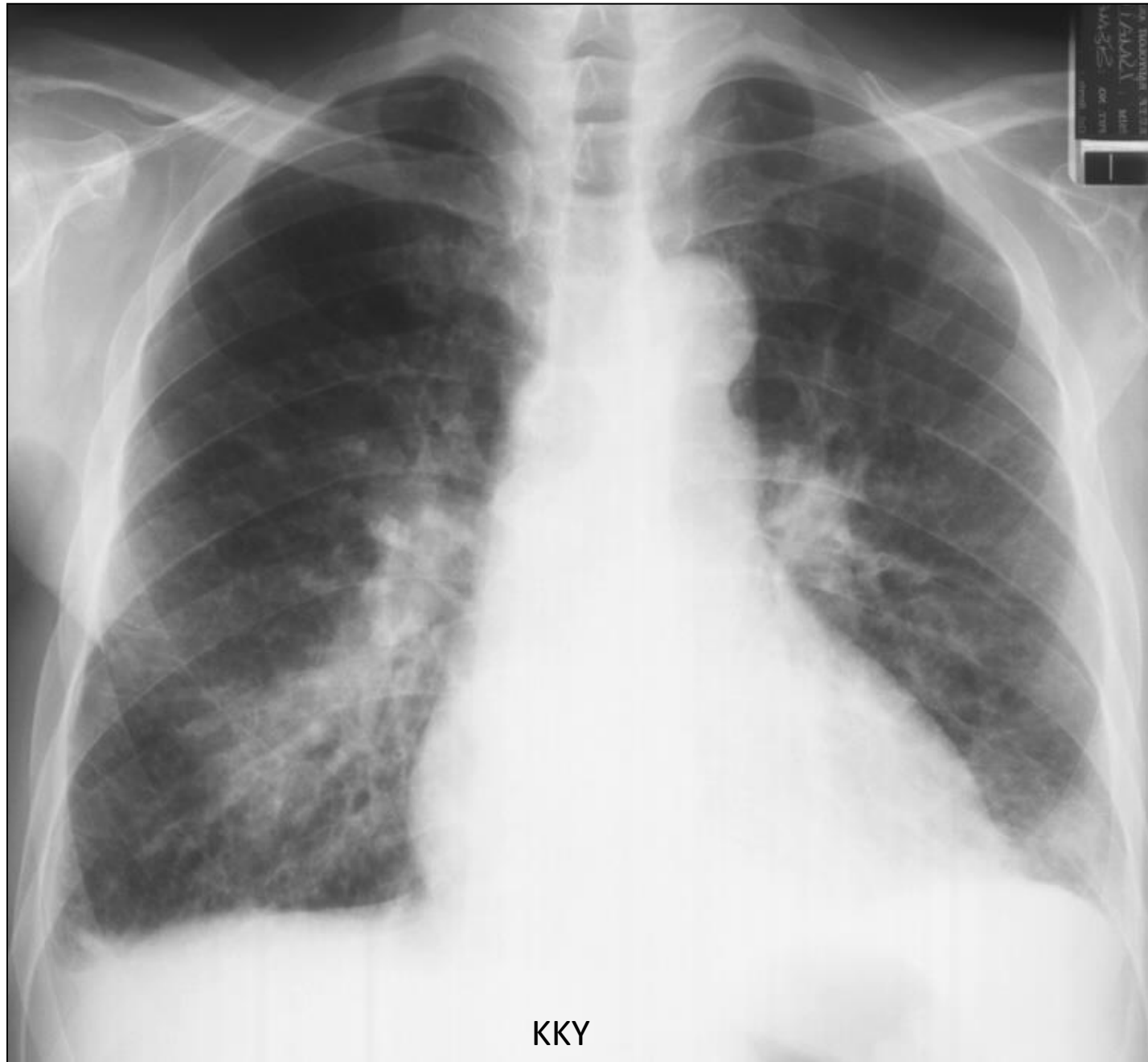Miliyer tüberküloz



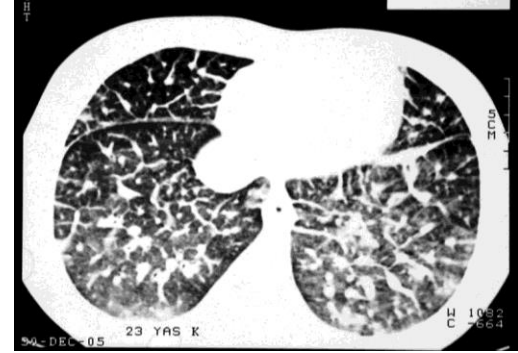
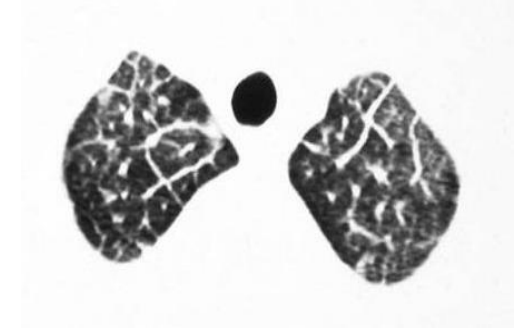
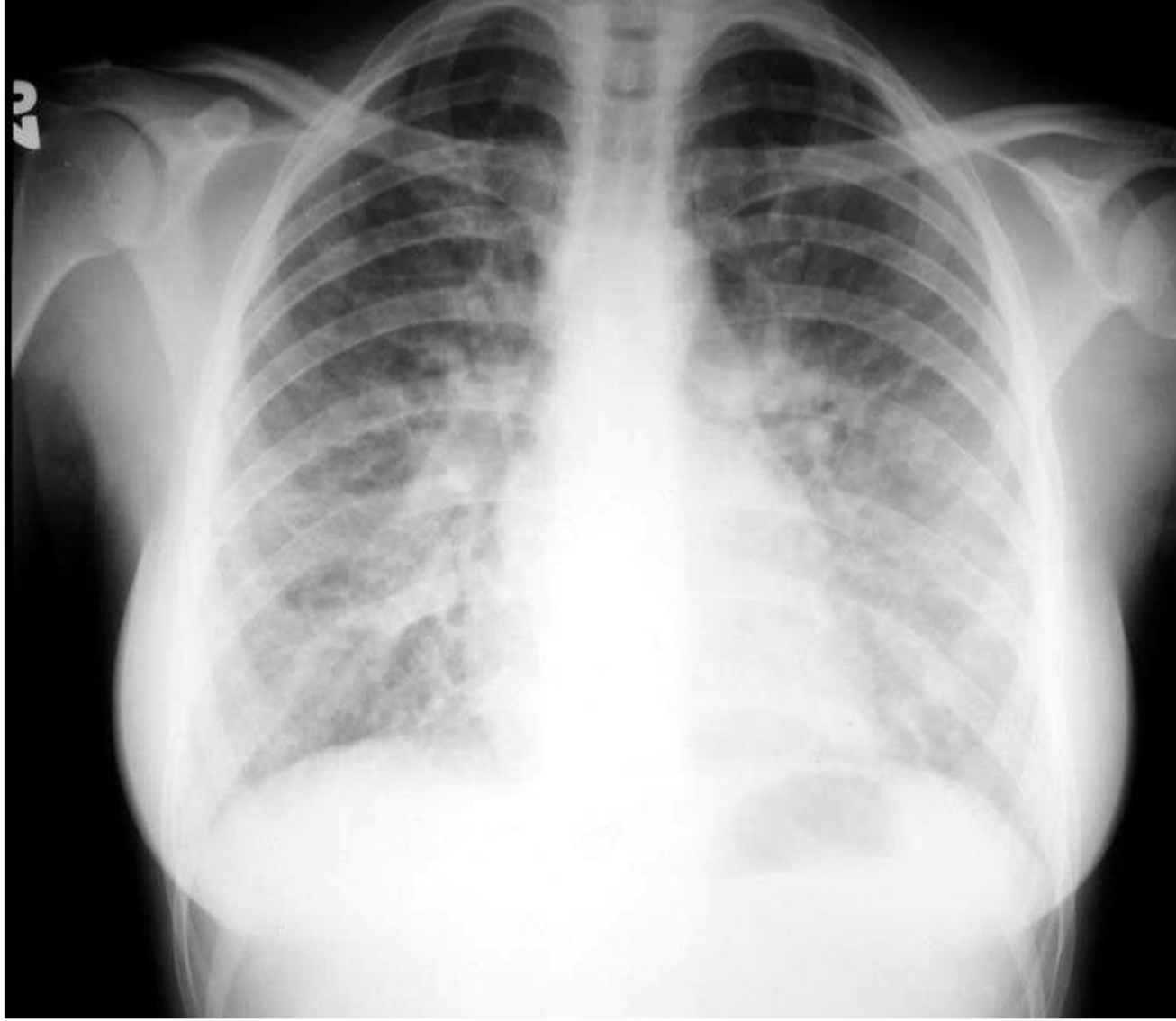Tiroid ca metastazi



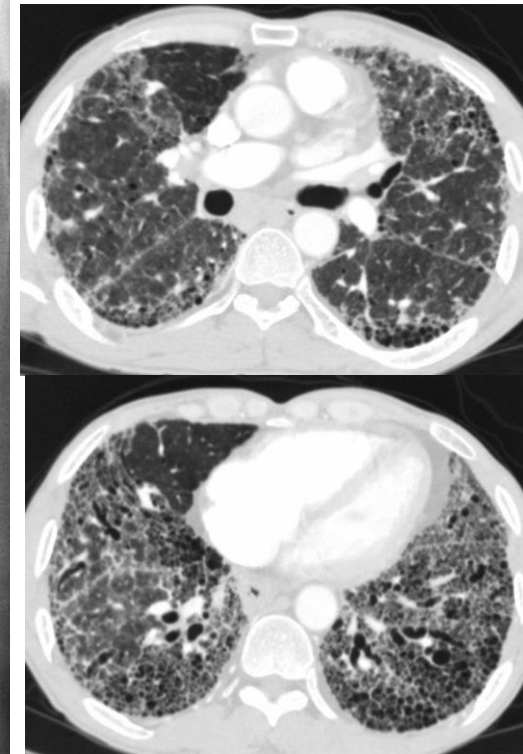
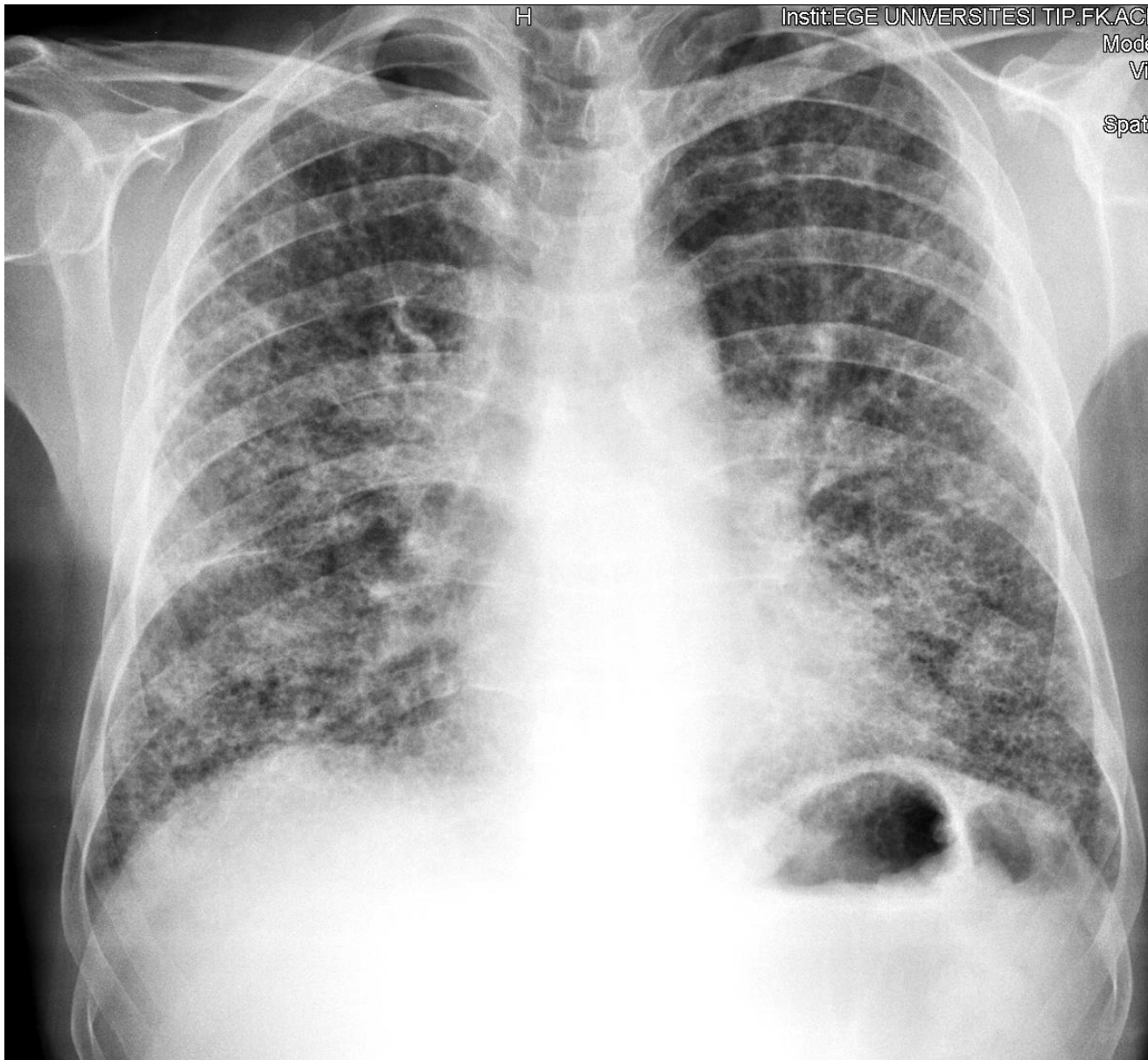
Alveoler mikrolitiazis



KKY

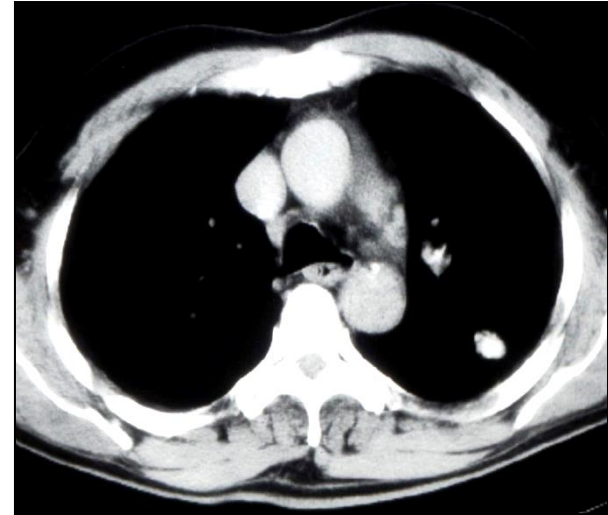
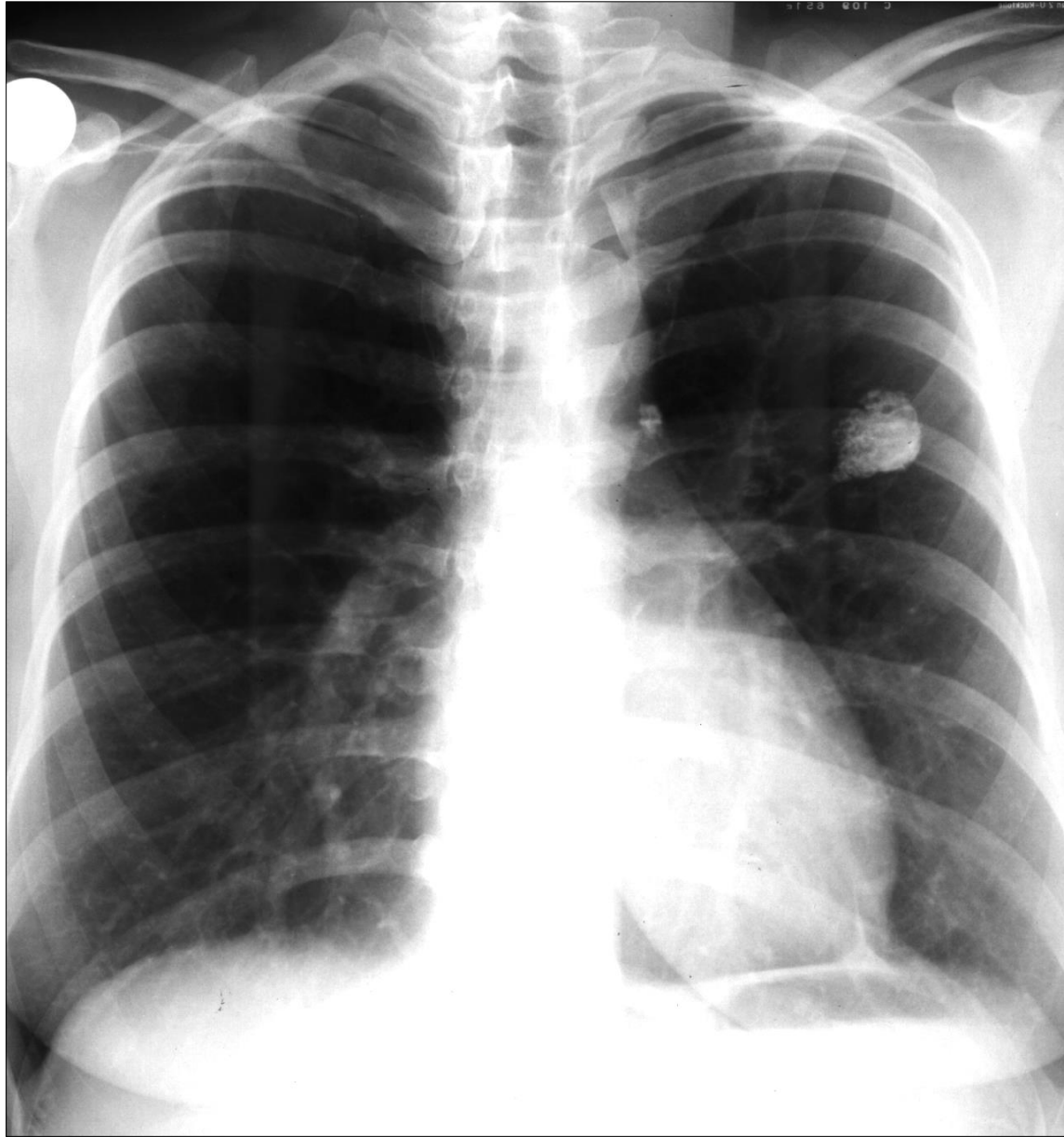


Mitral darlık akciğer ödemi

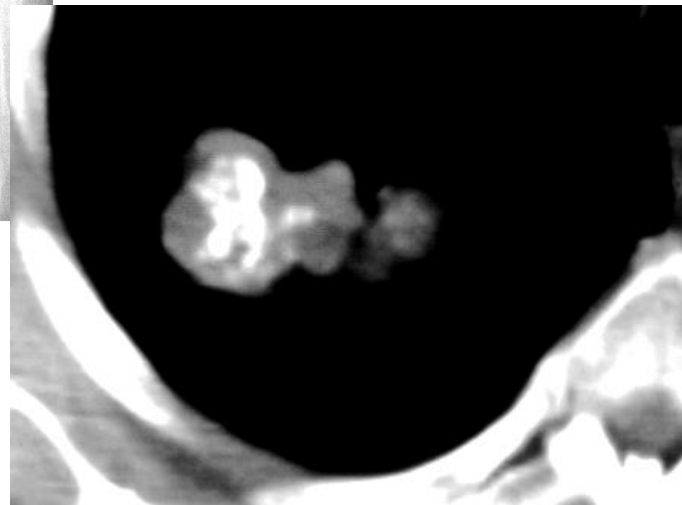
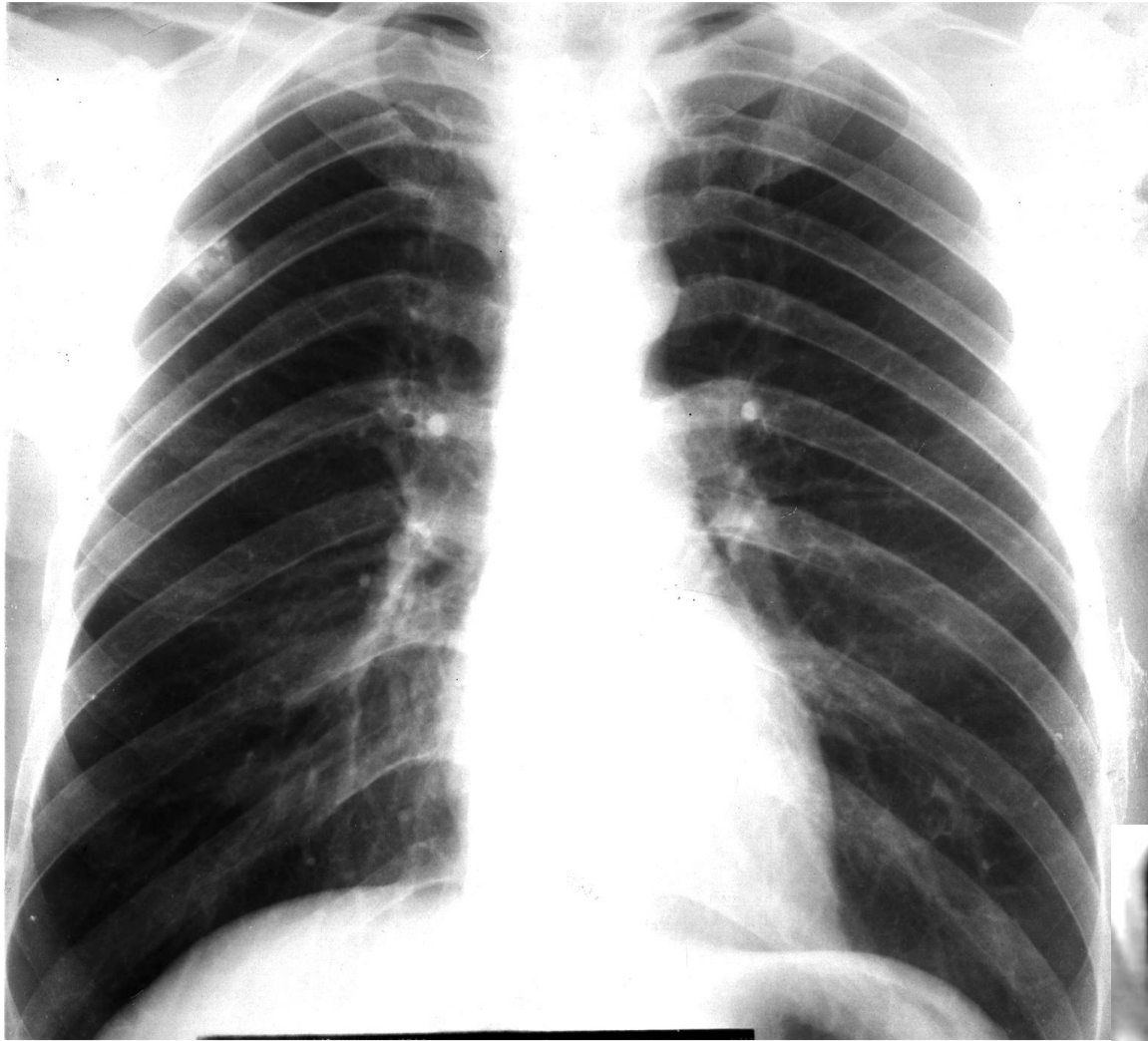

Pulmoner fibrozis

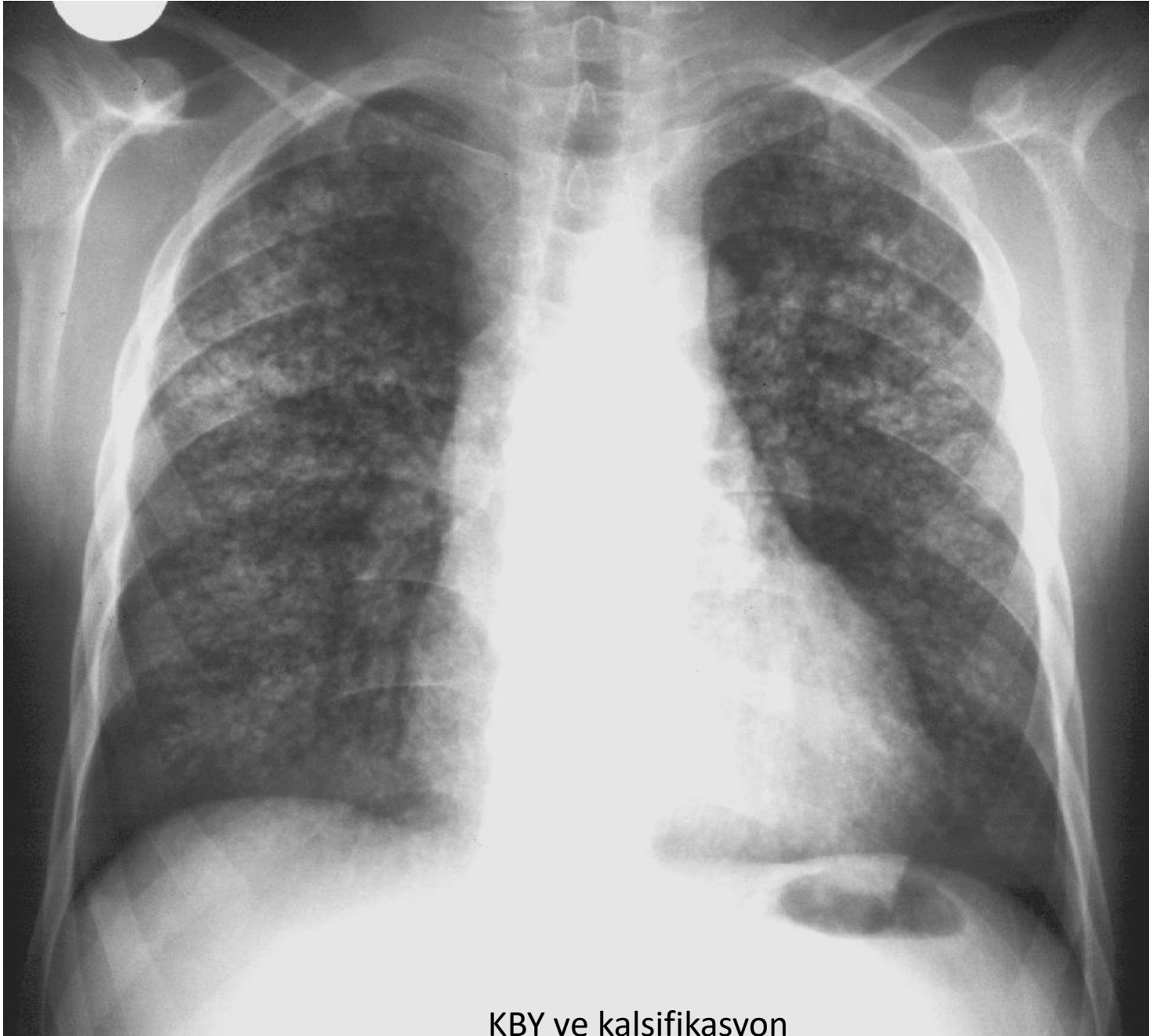
YÜKSEK DANSİTELİ LEZYONLAR (Kalsifik / ossifik)



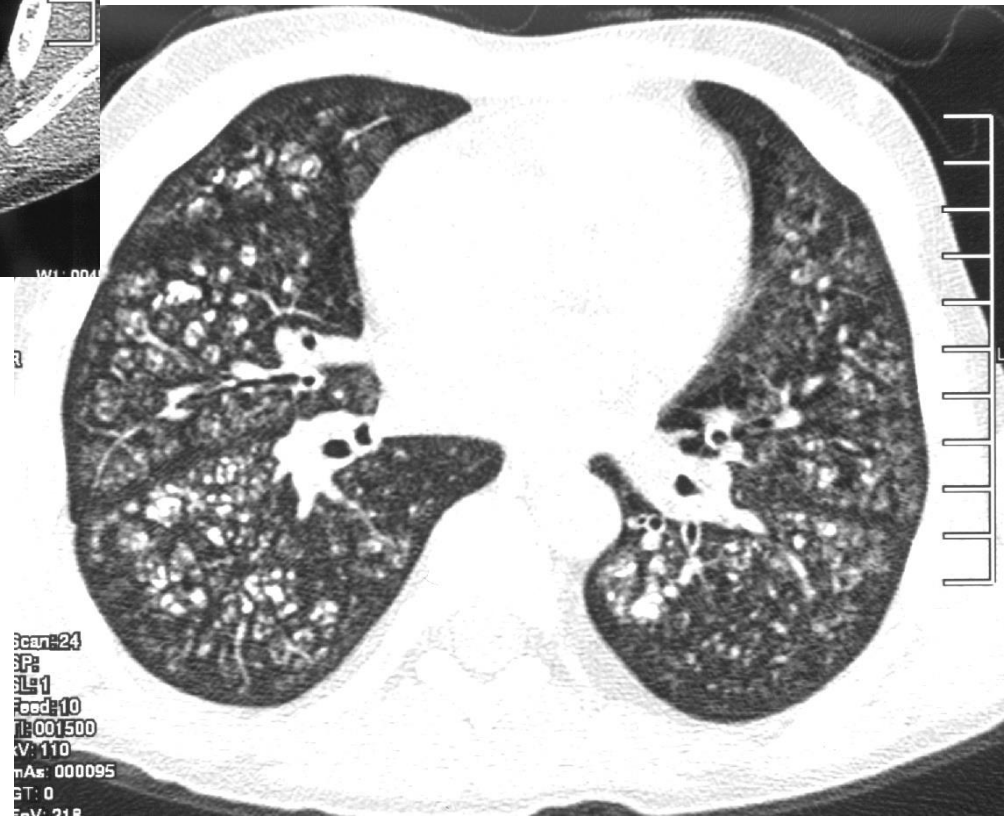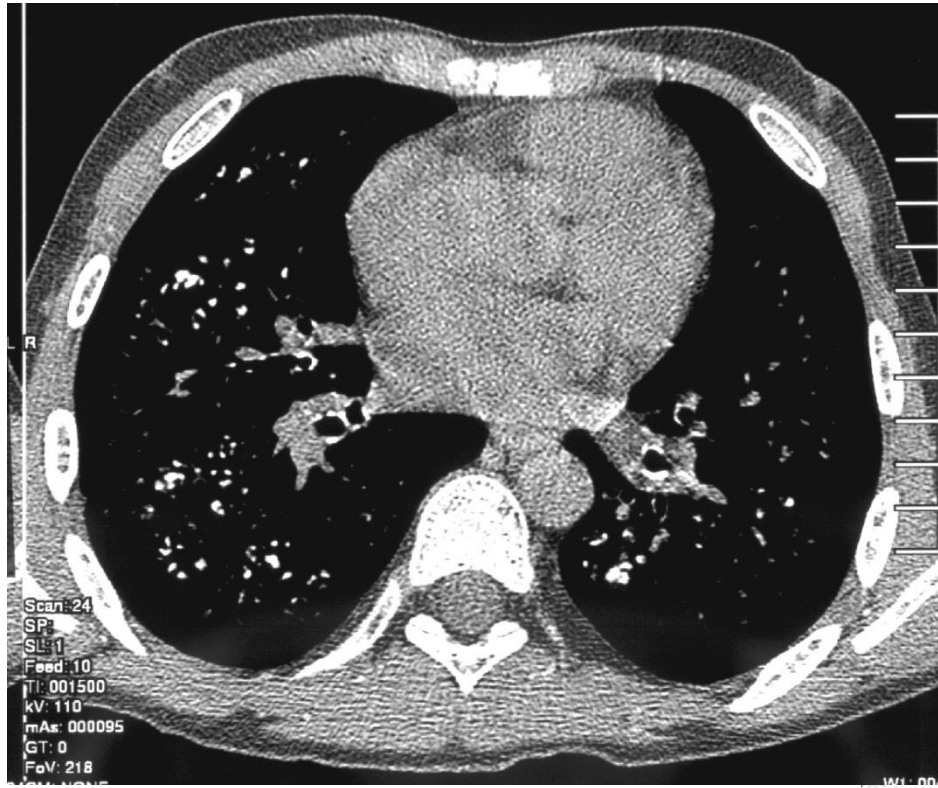
Kalsifik granülom

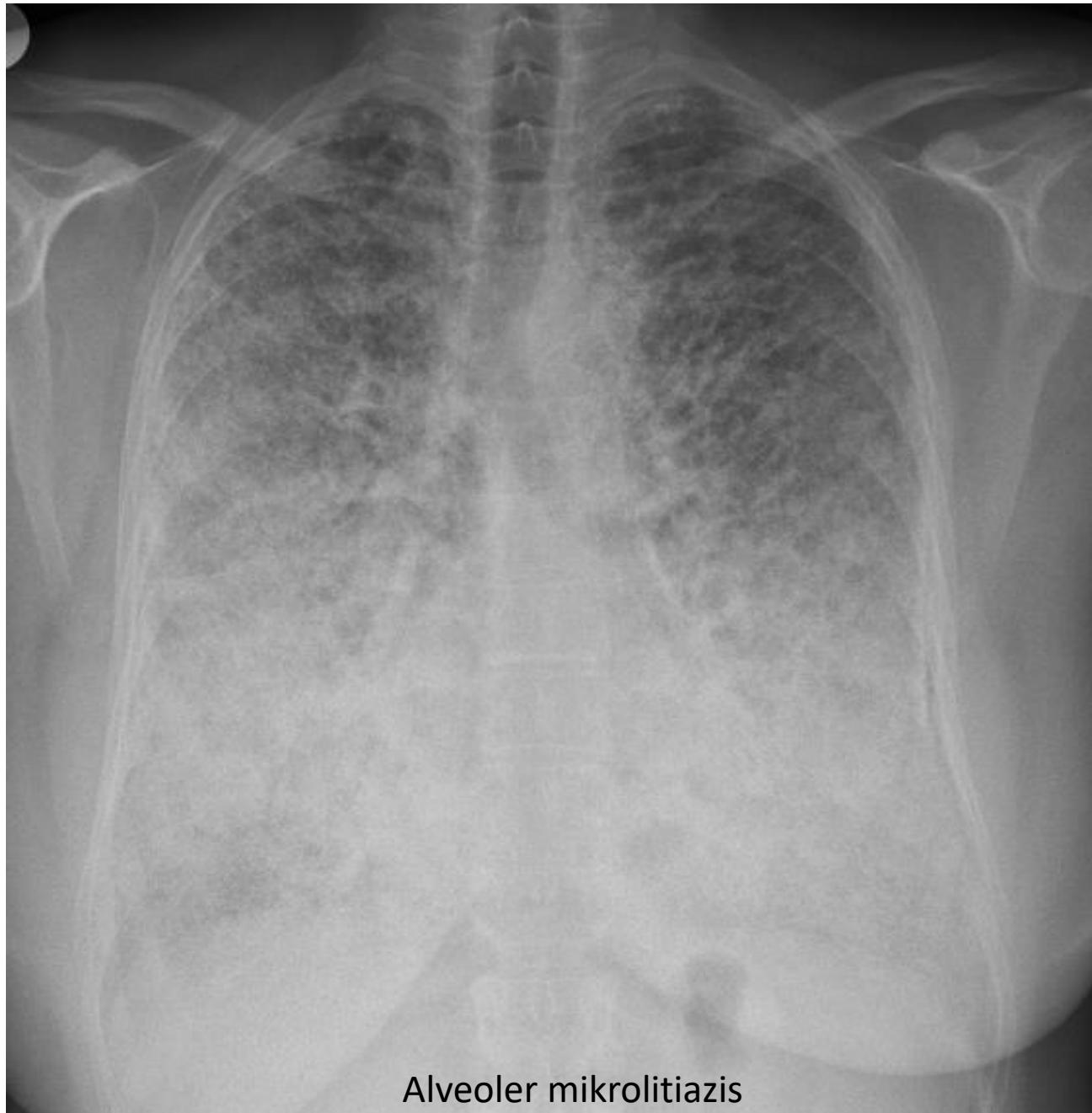

Hamartom

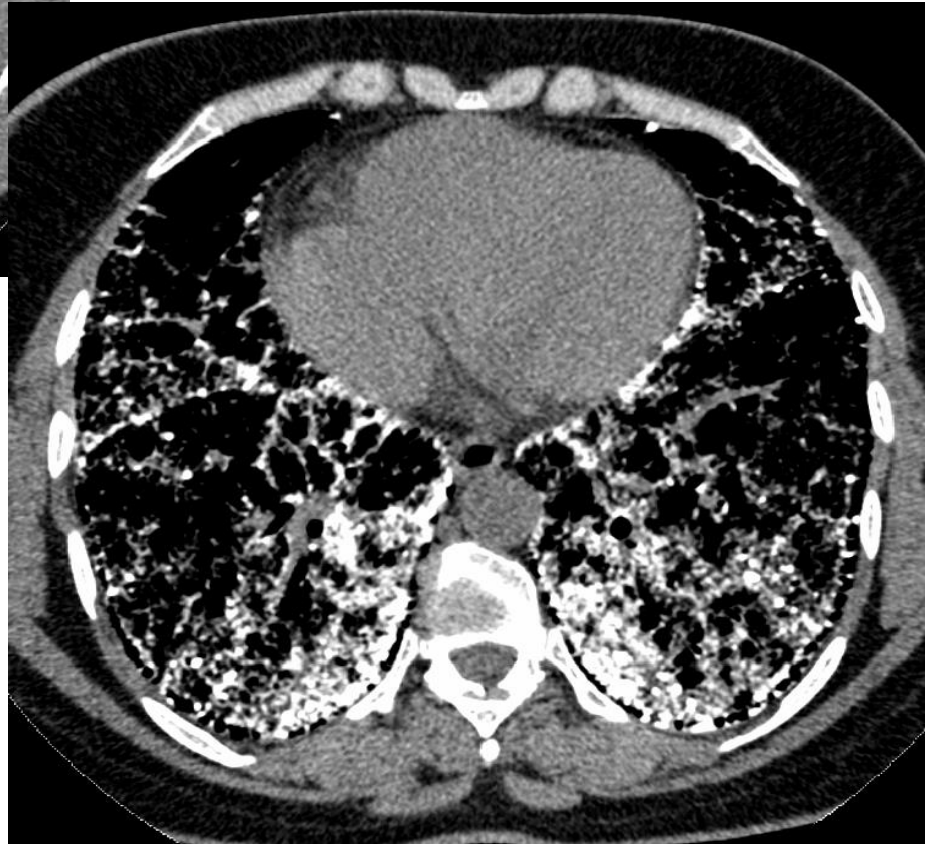
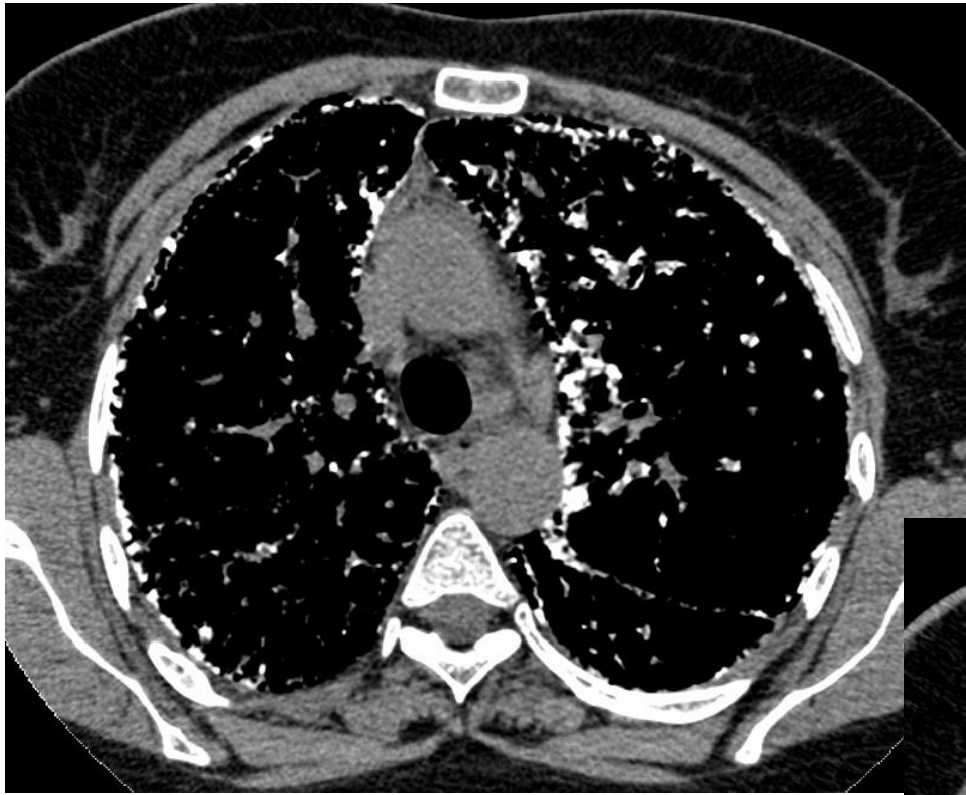


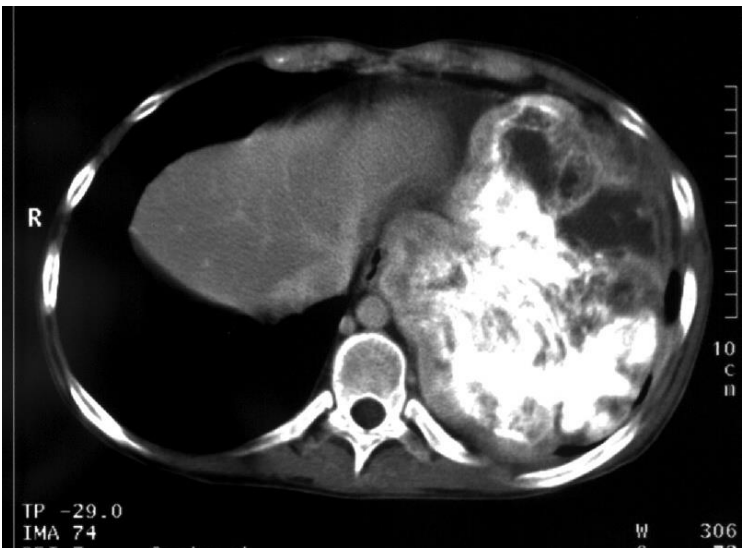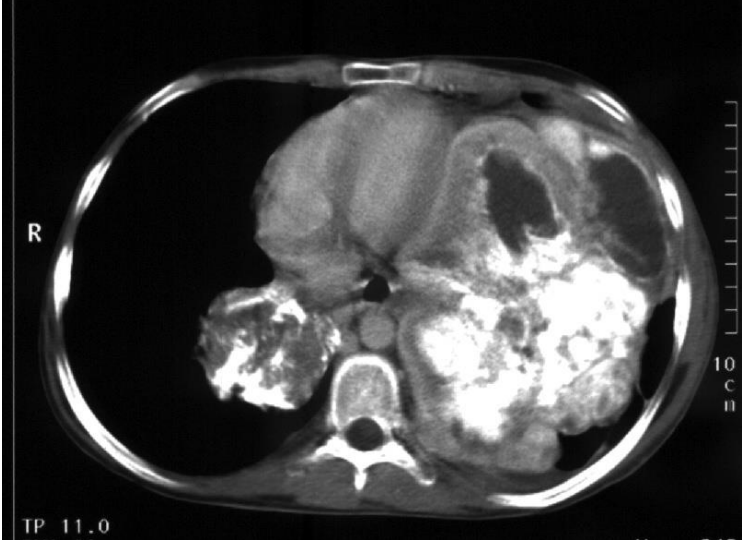
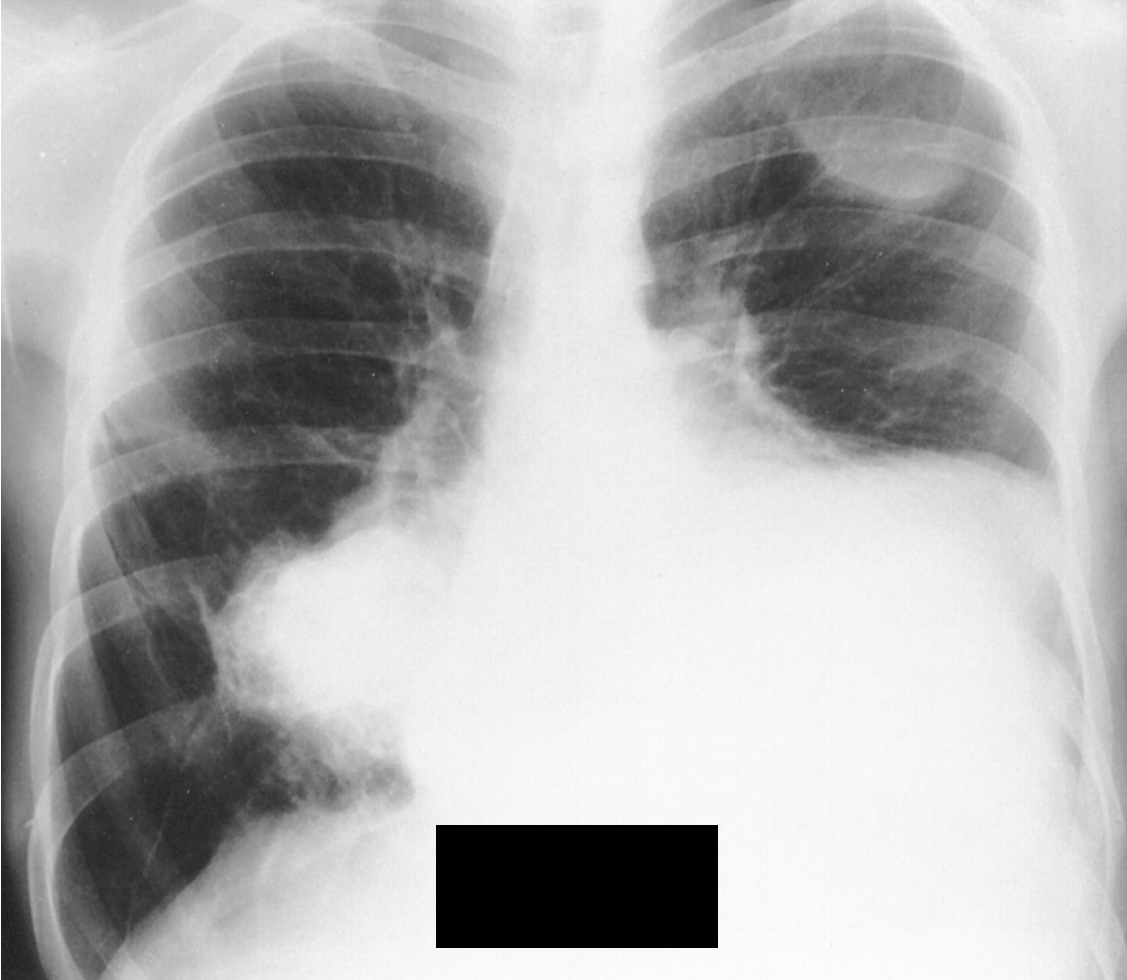
KBY ve kalsifikasyon





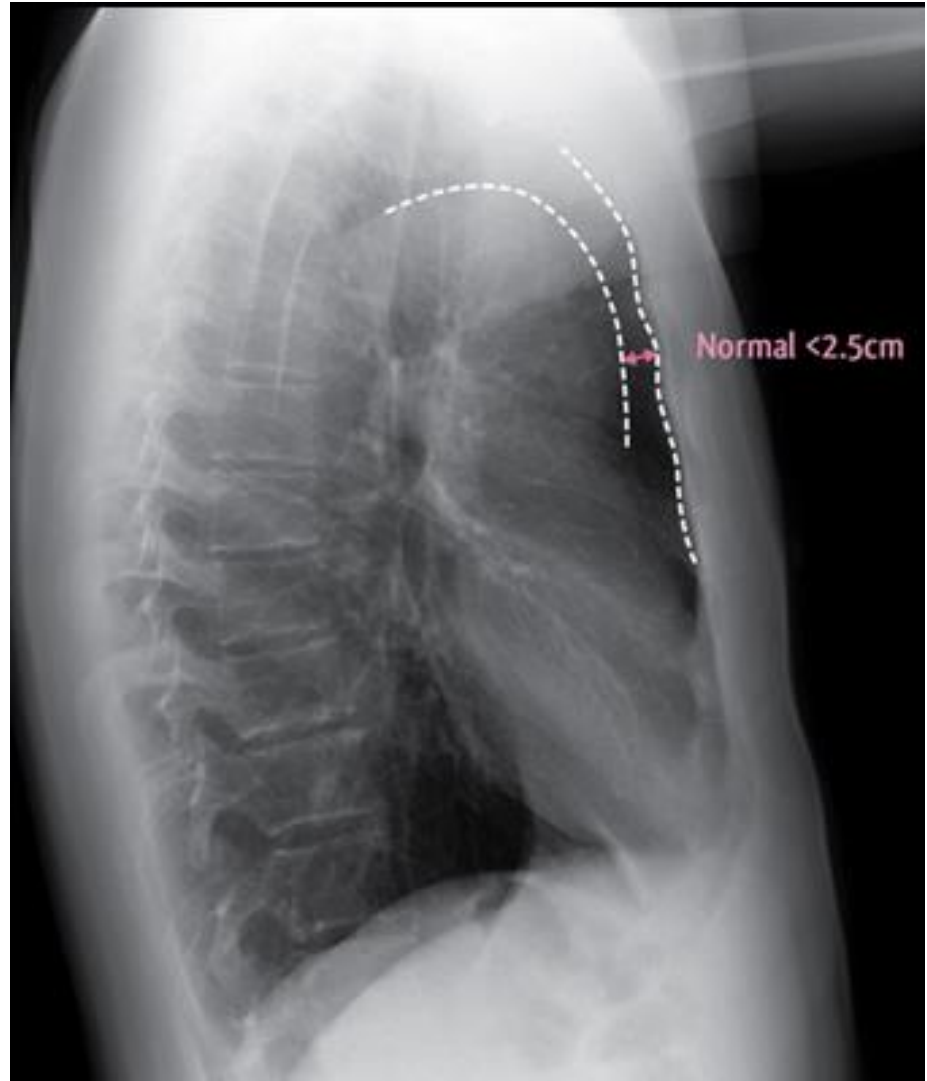
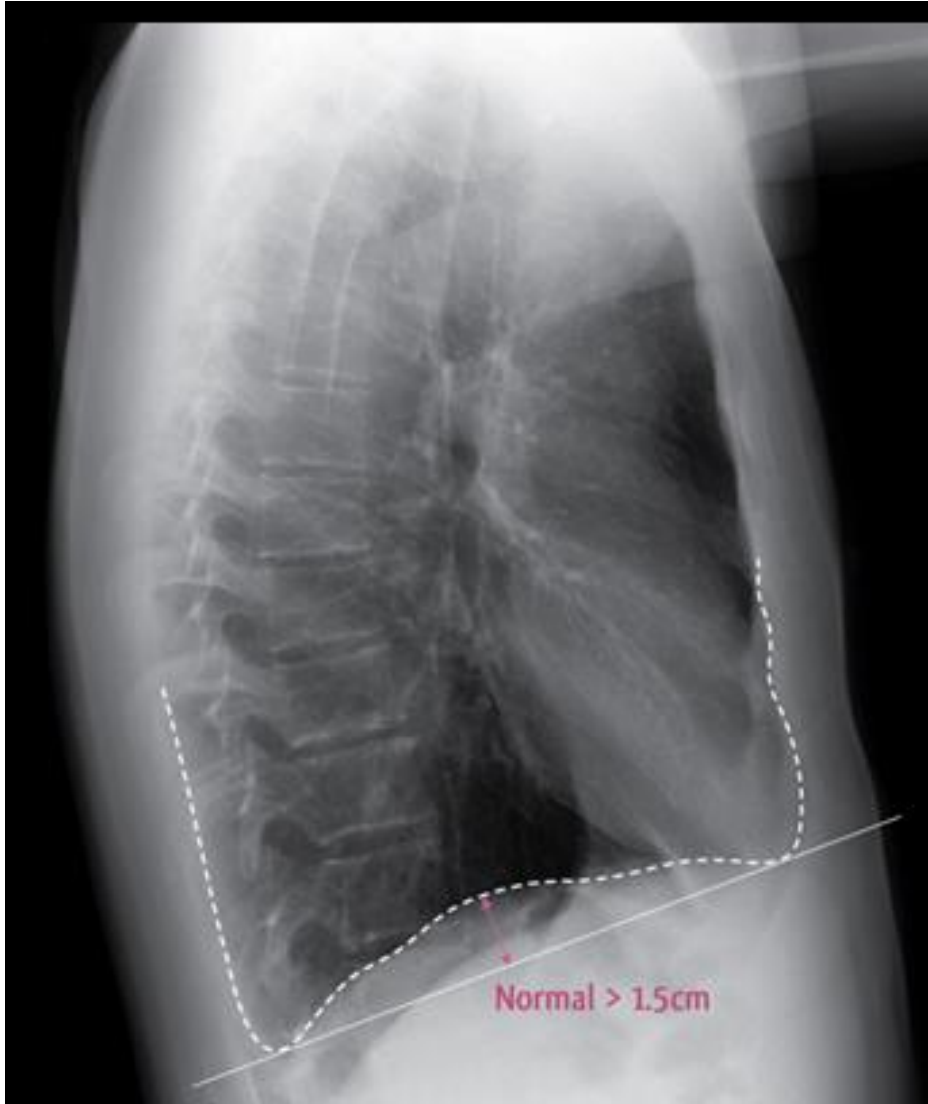
Alveoler mikrolitiazis

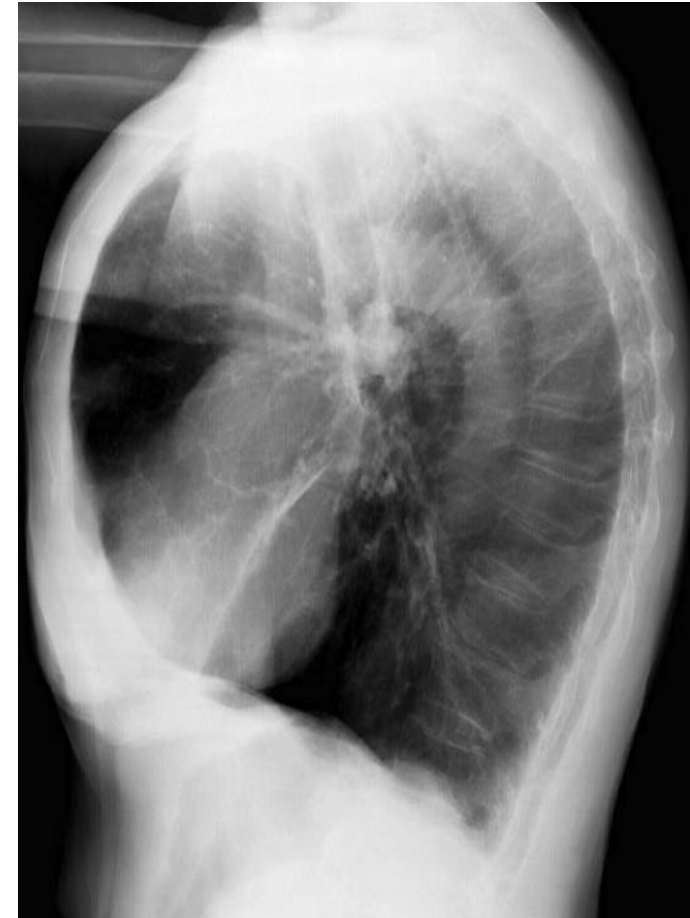
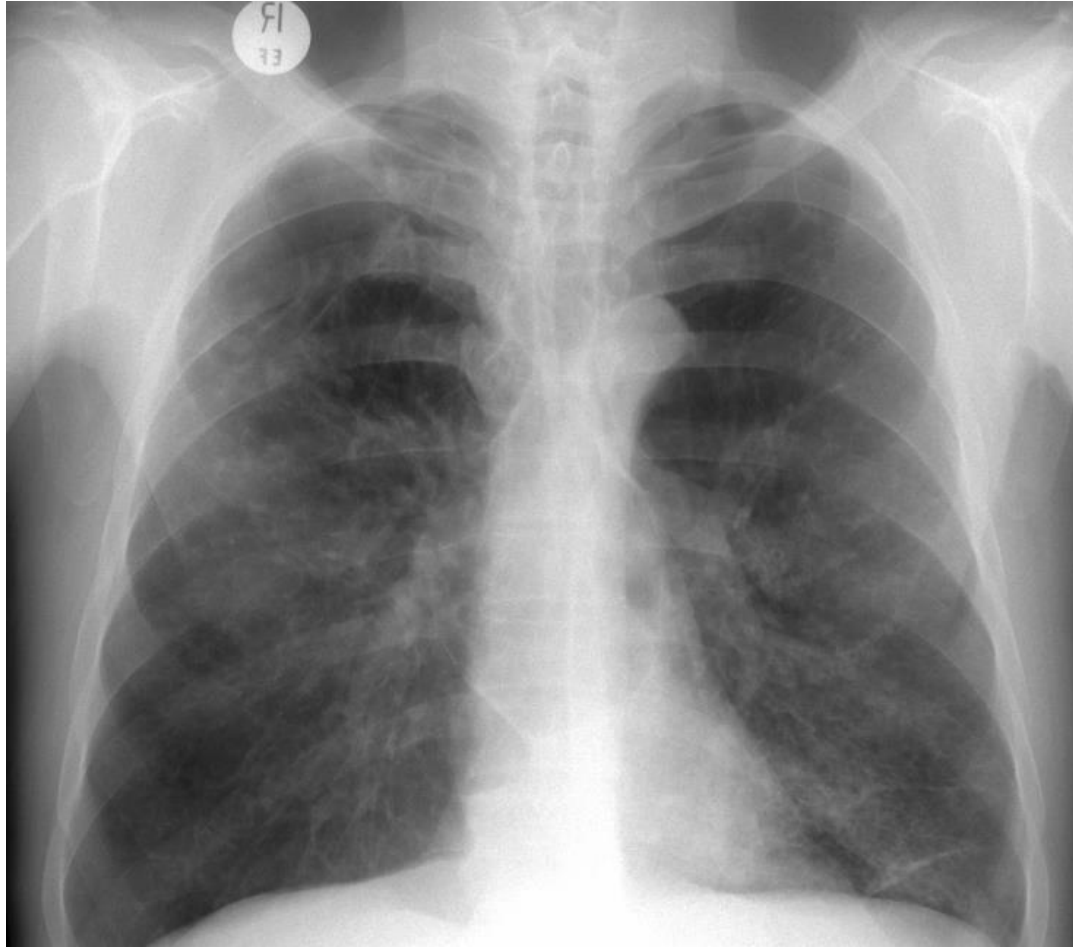


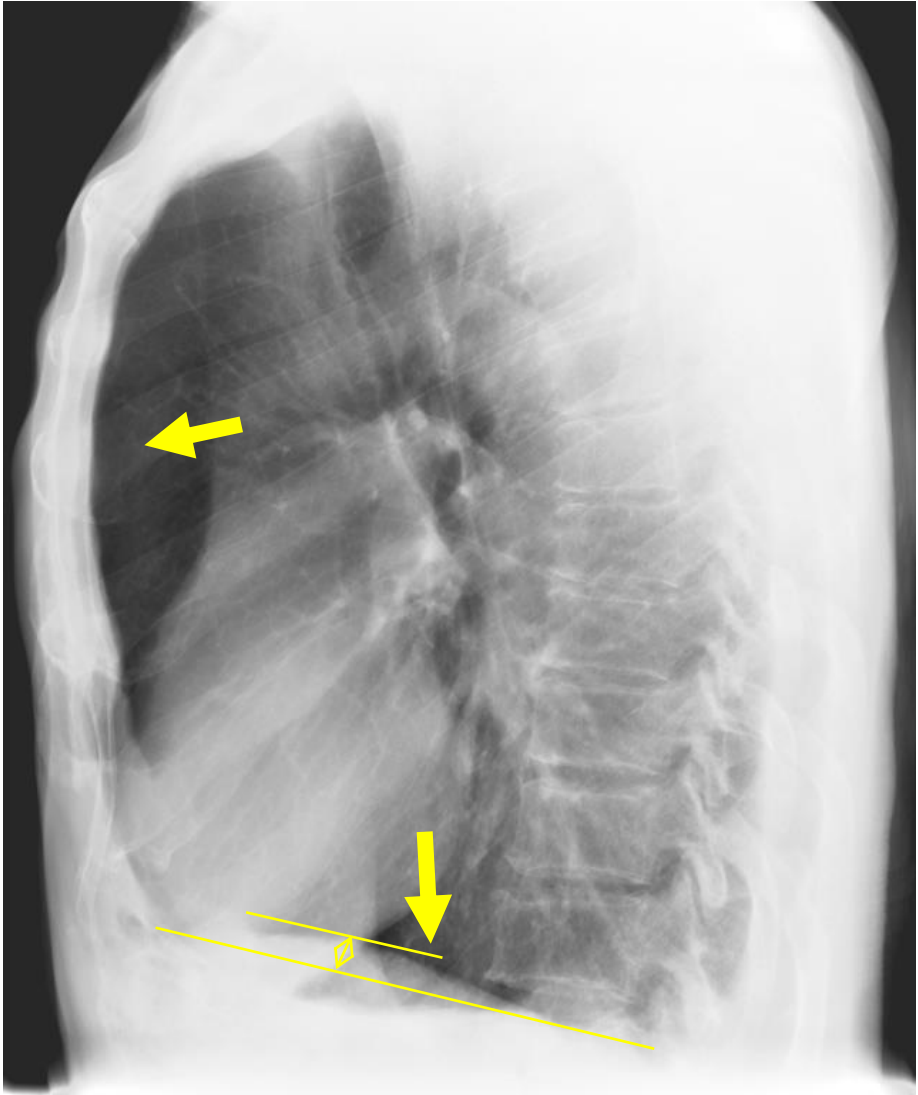
Osteosarkom metastazi

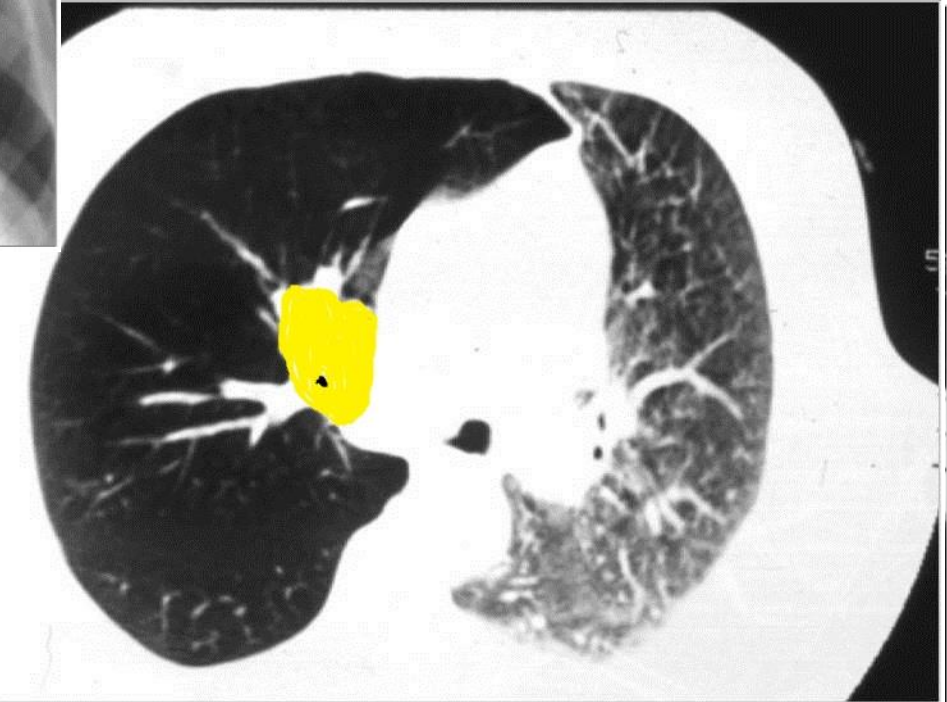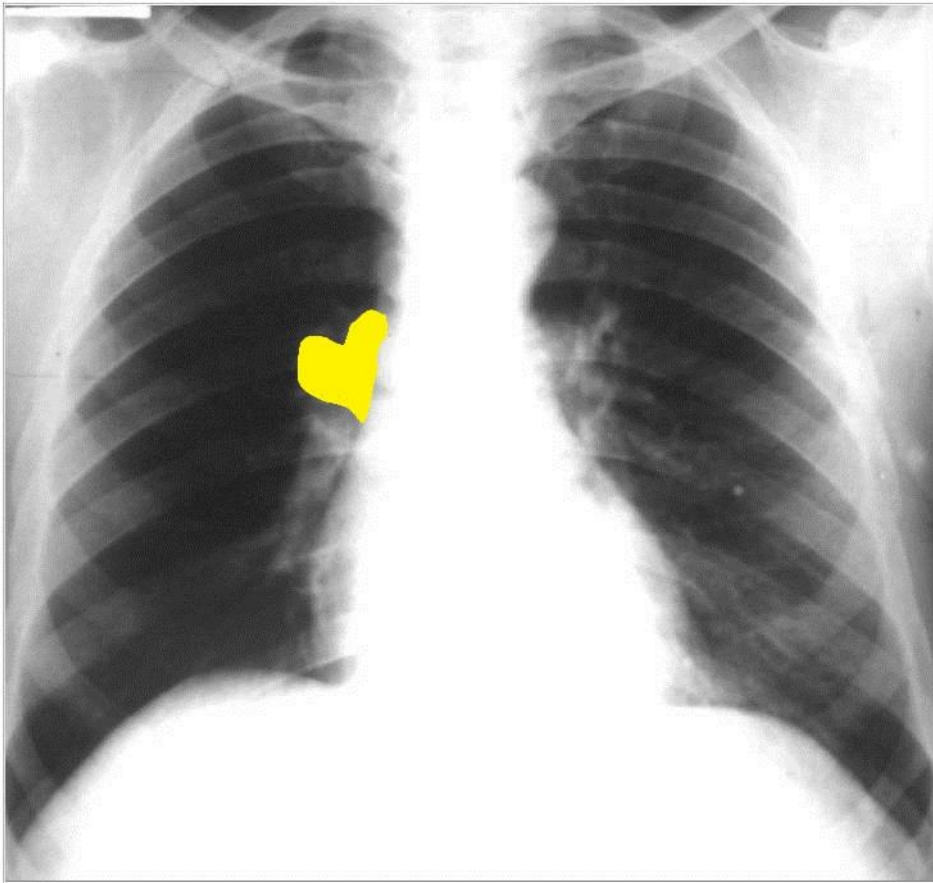
HİPERLUSENT AKCİĞER



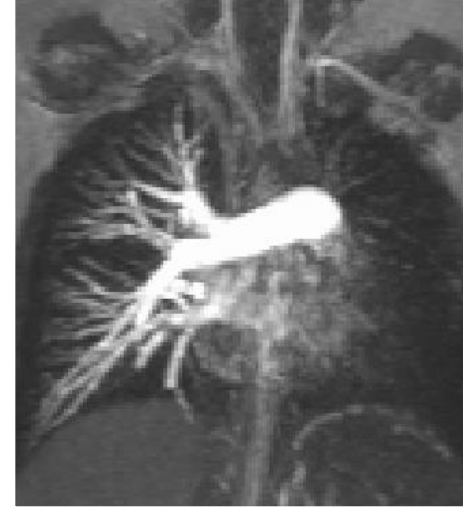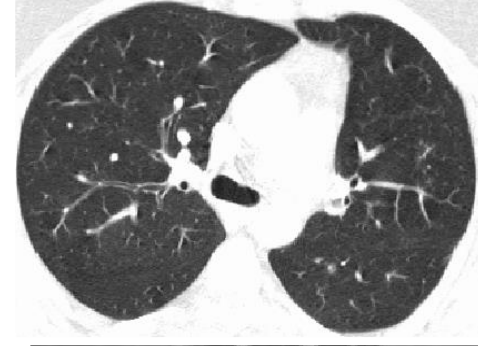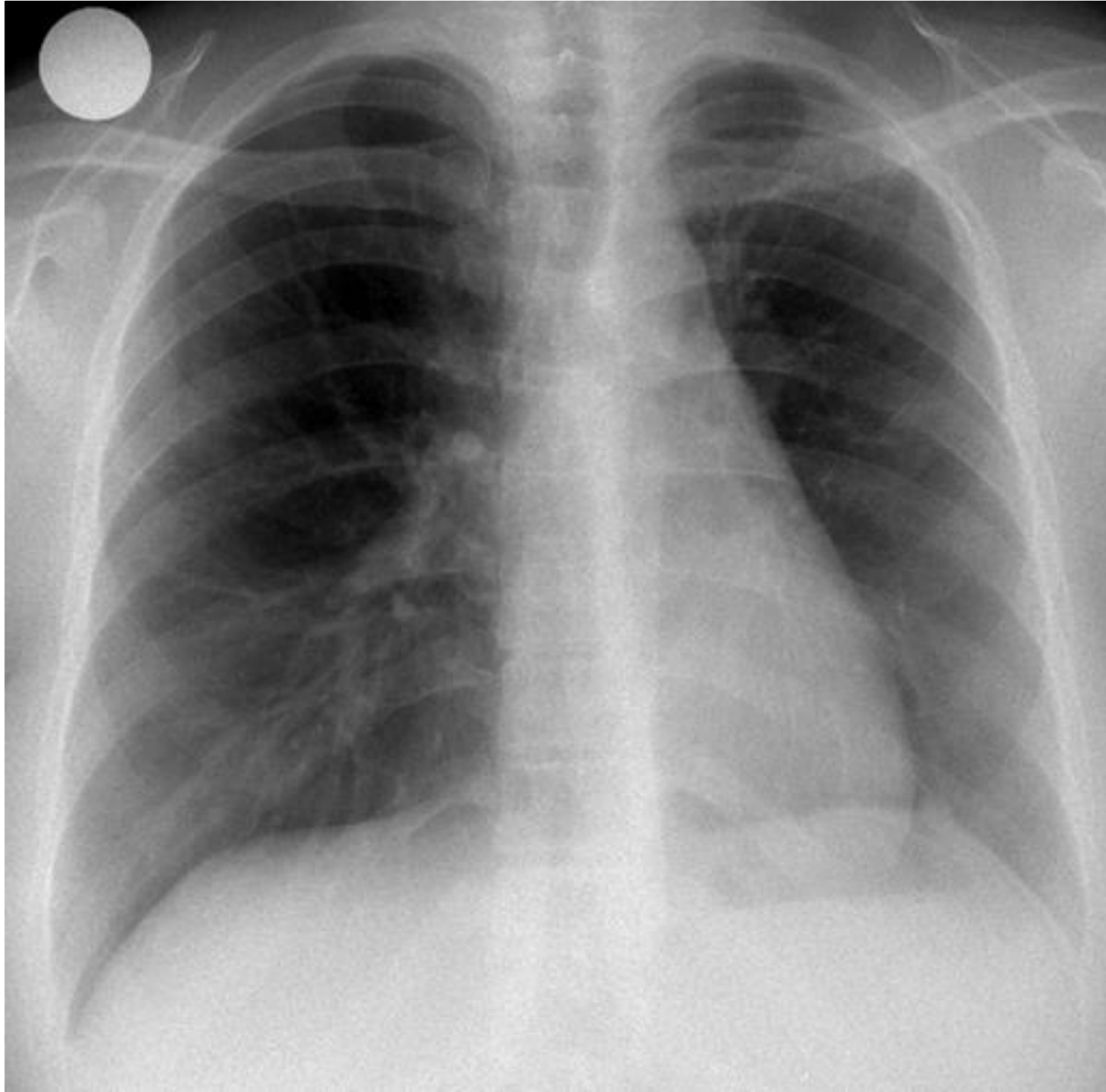


Amfizem

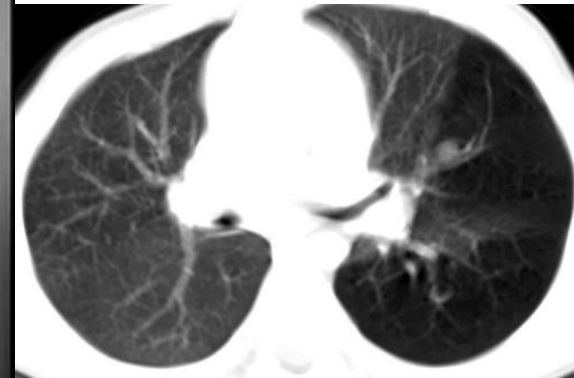
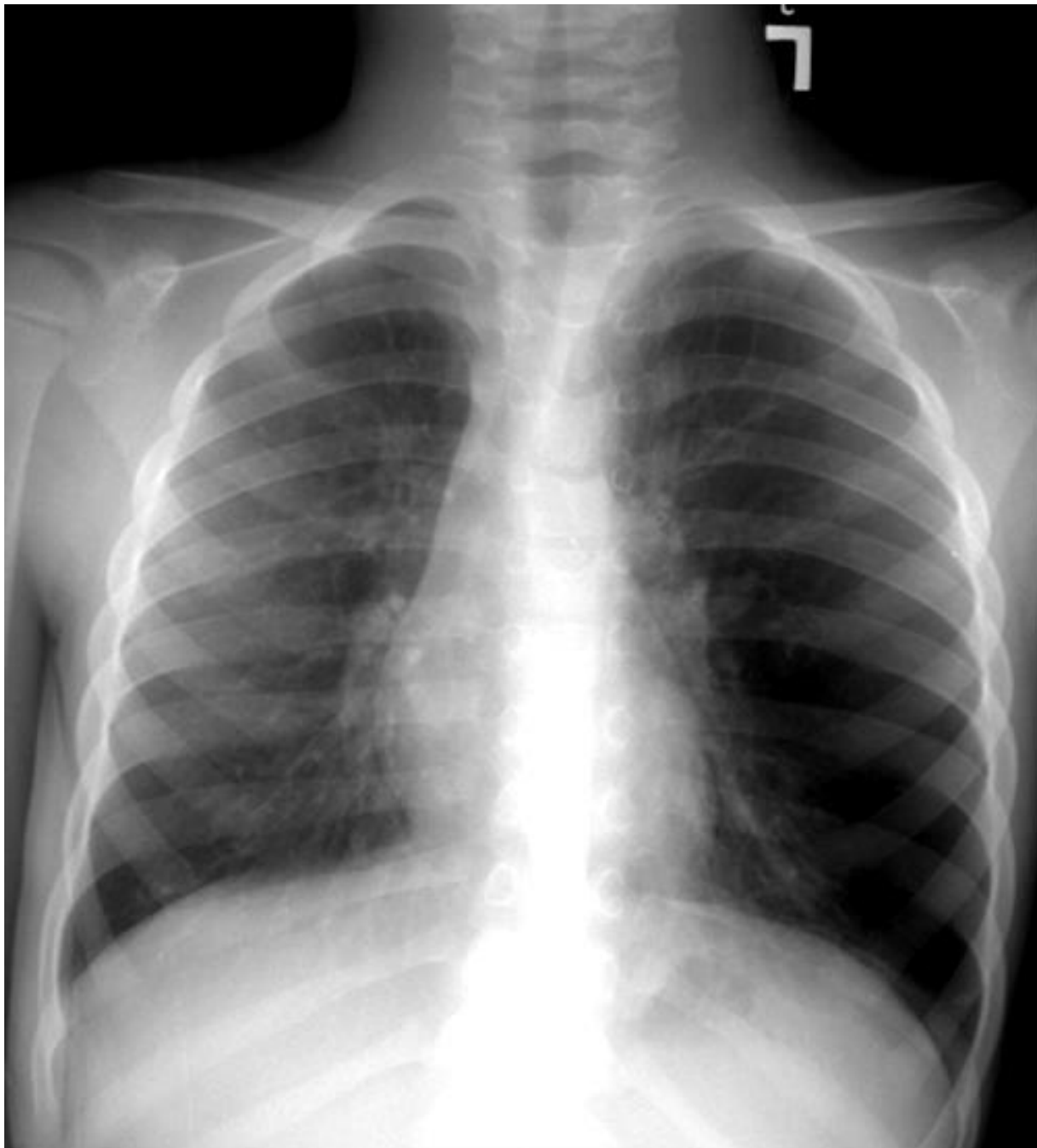




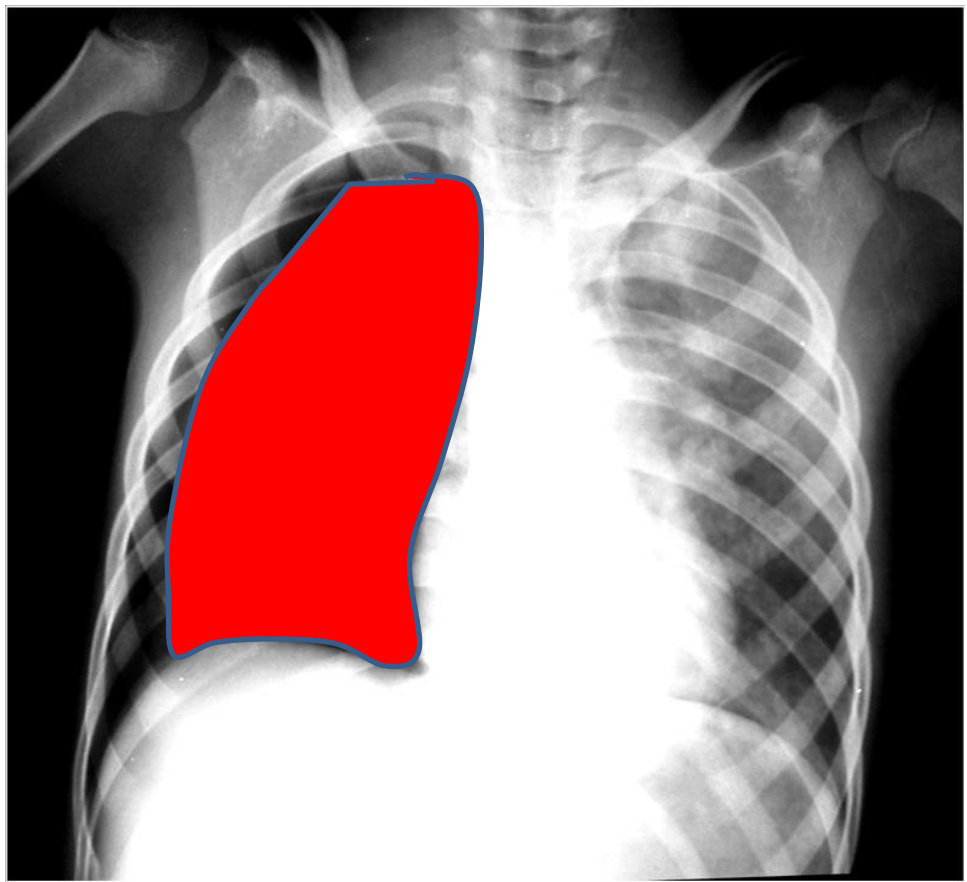
Santral akciğer kanseri

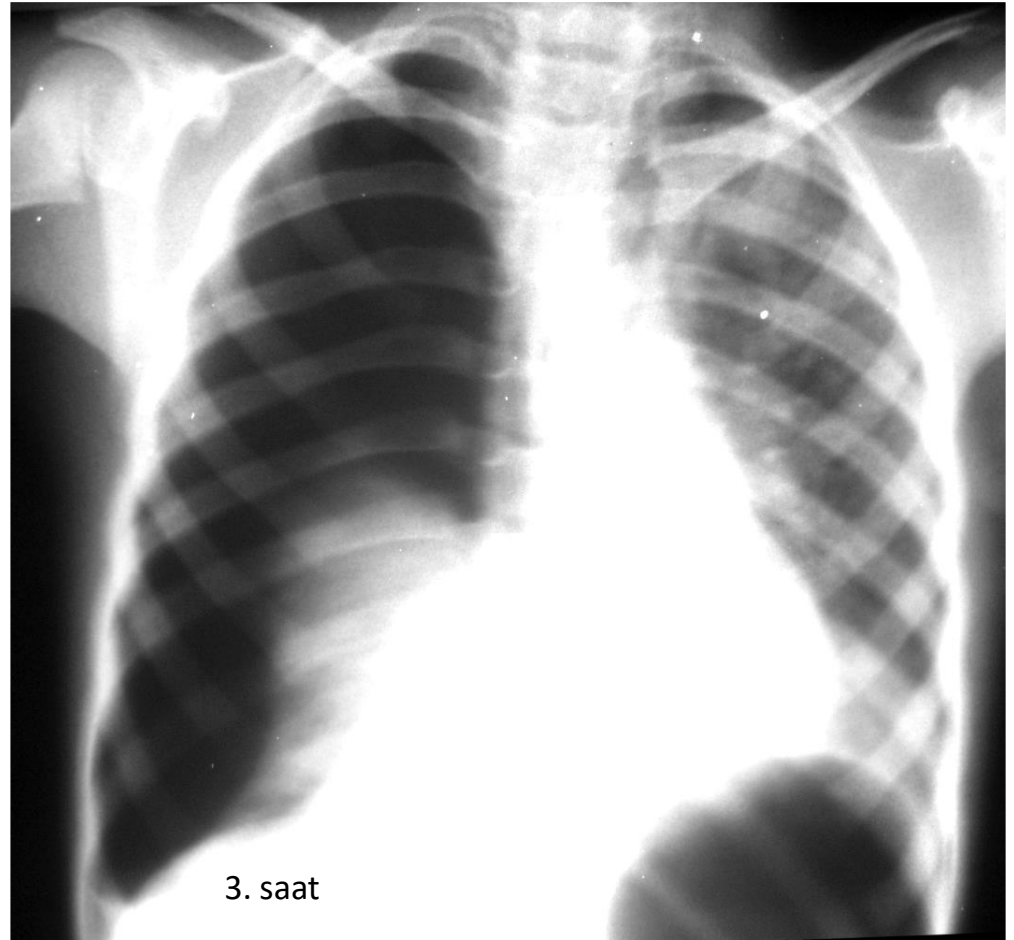
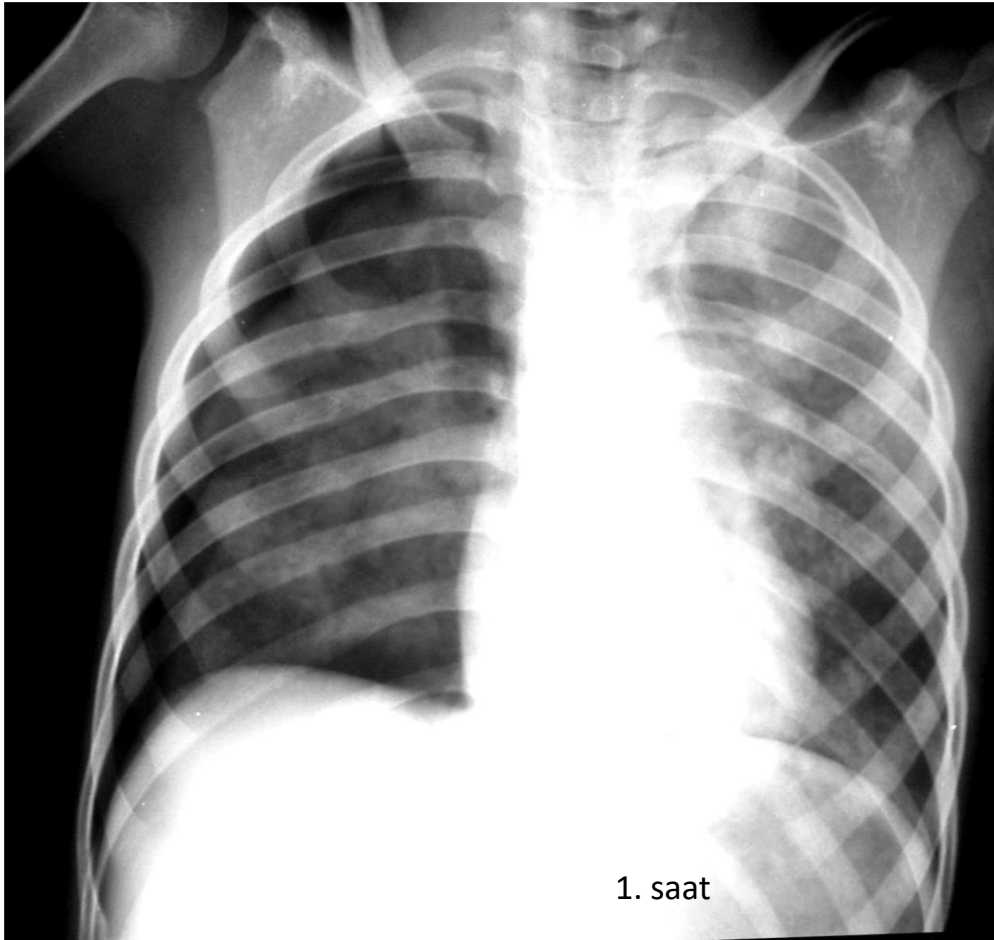


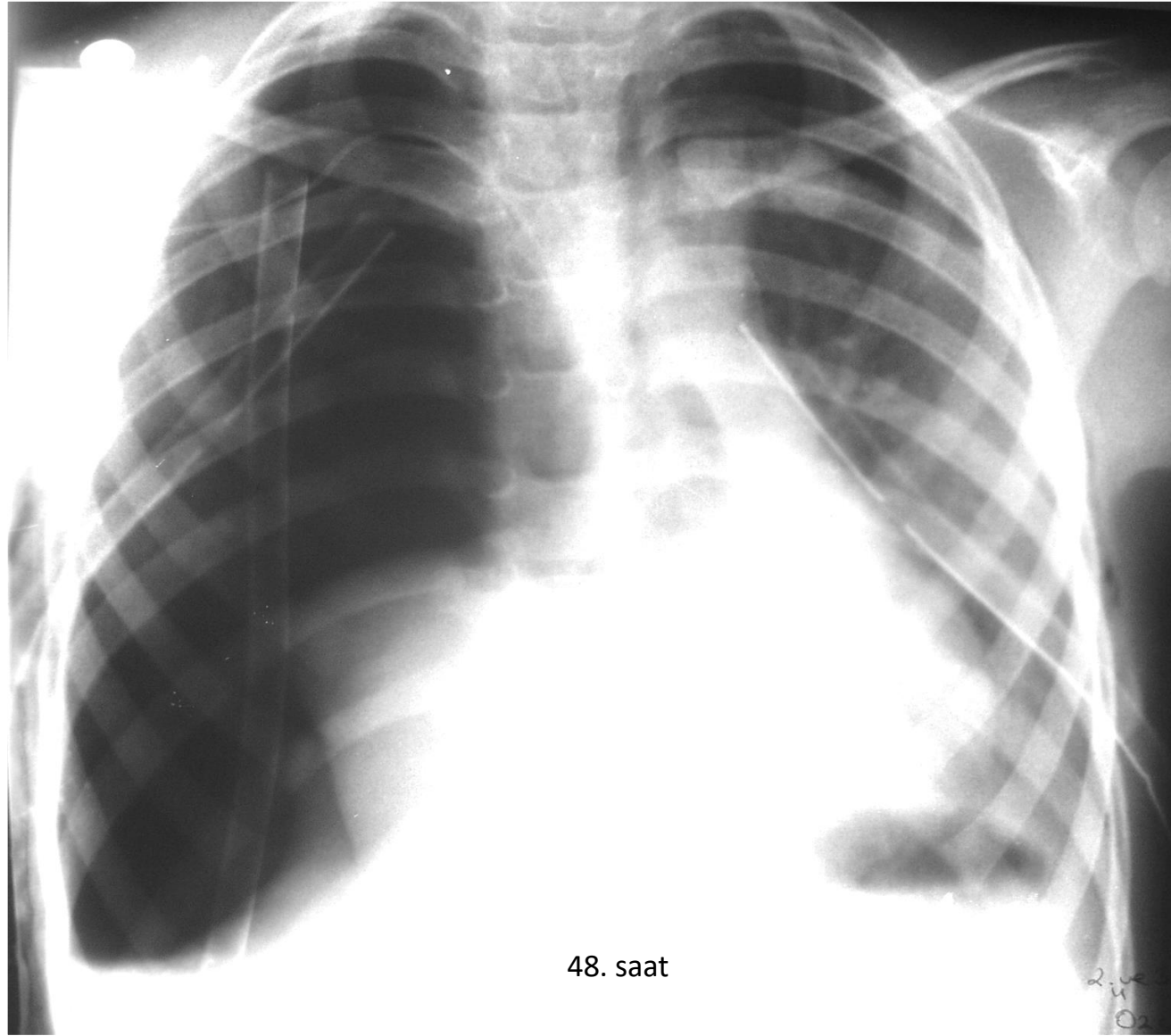Sol pulmoner arter yokluđu



Swyer-James sendromu

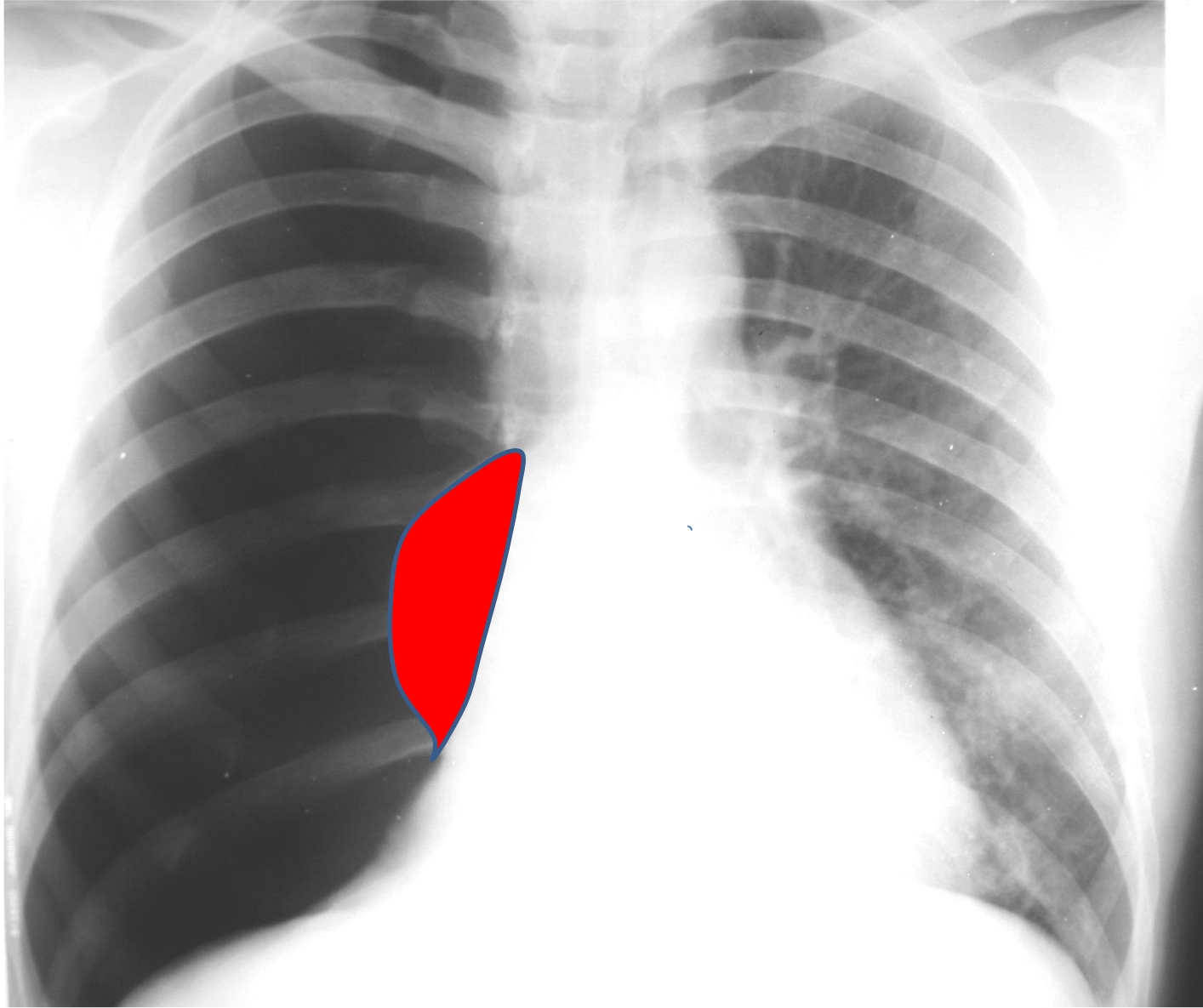


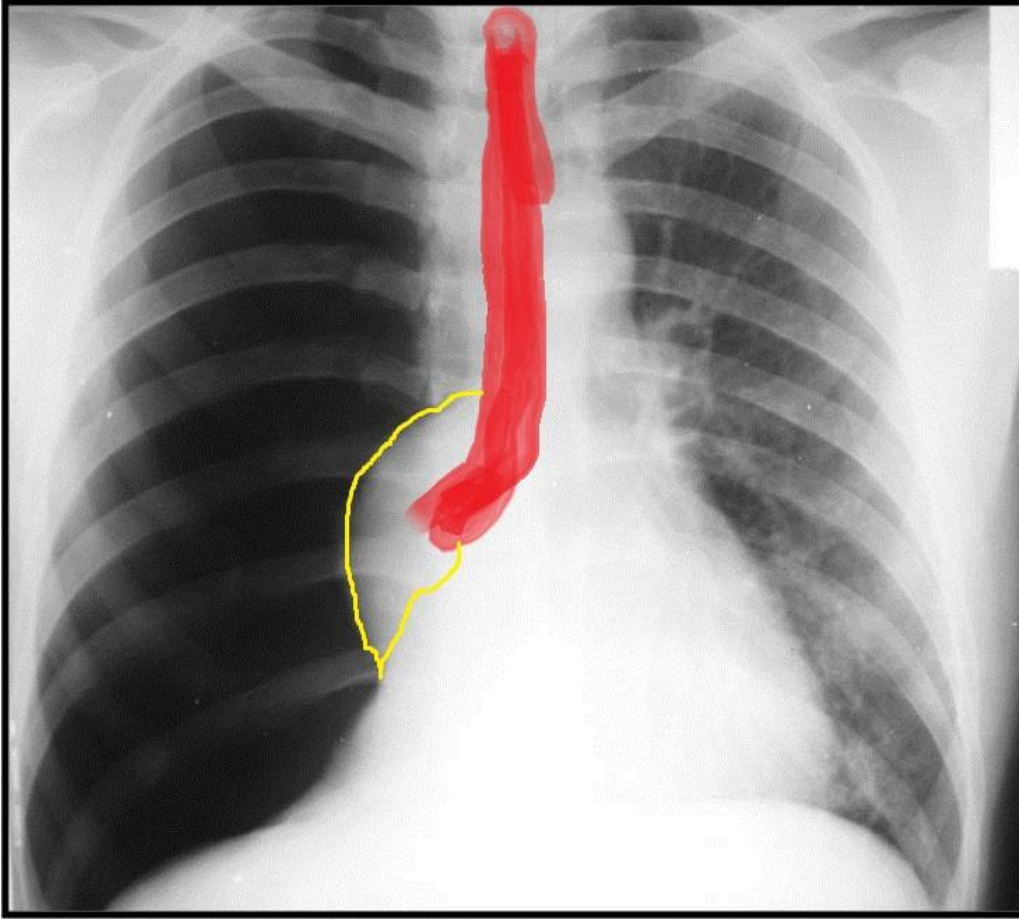




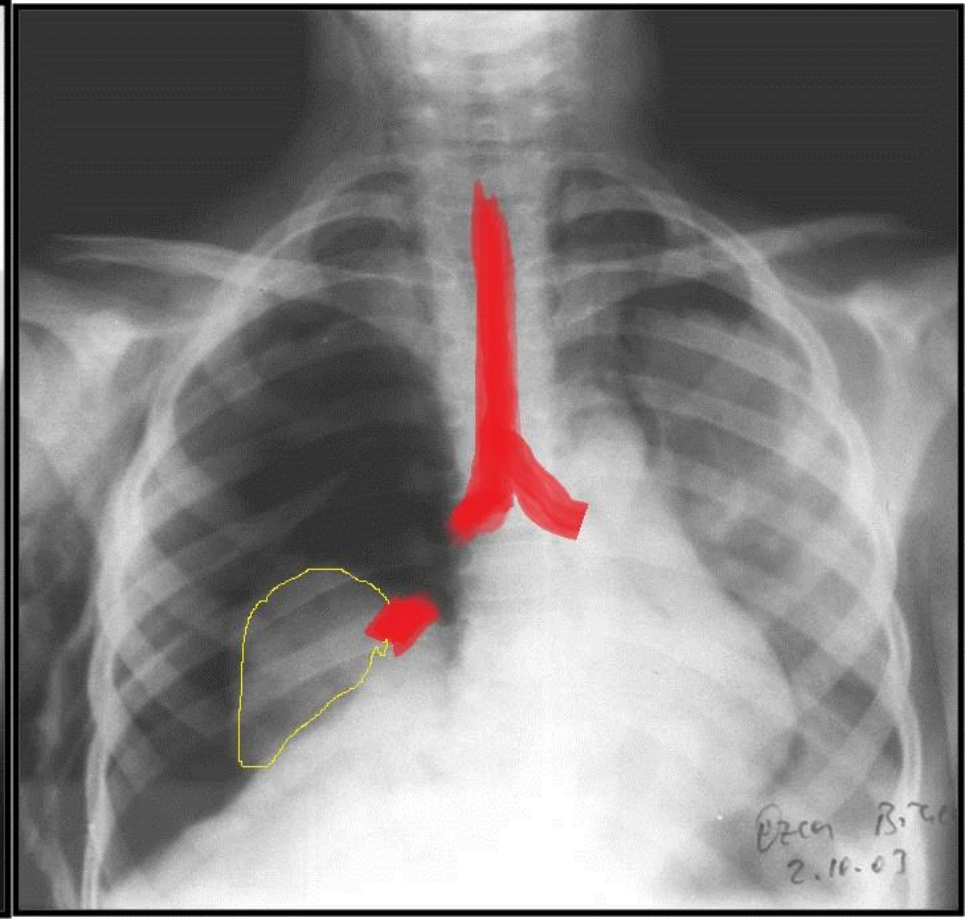
48. saat

2.4
02



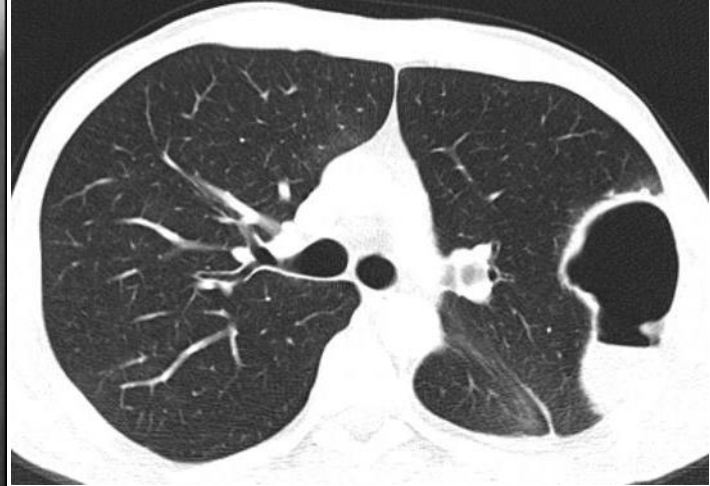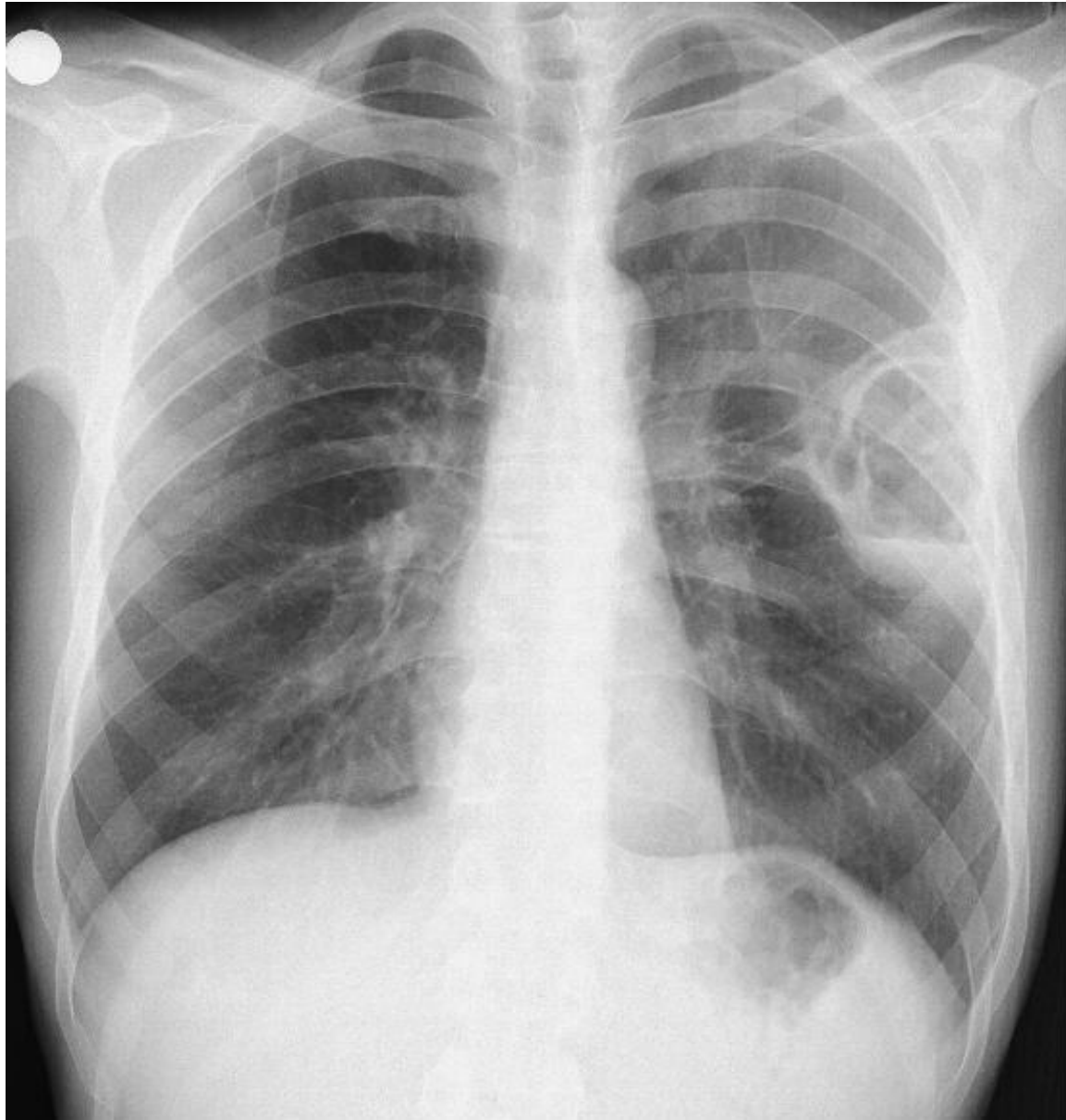


TOTAL
PNÖMOTORAKS

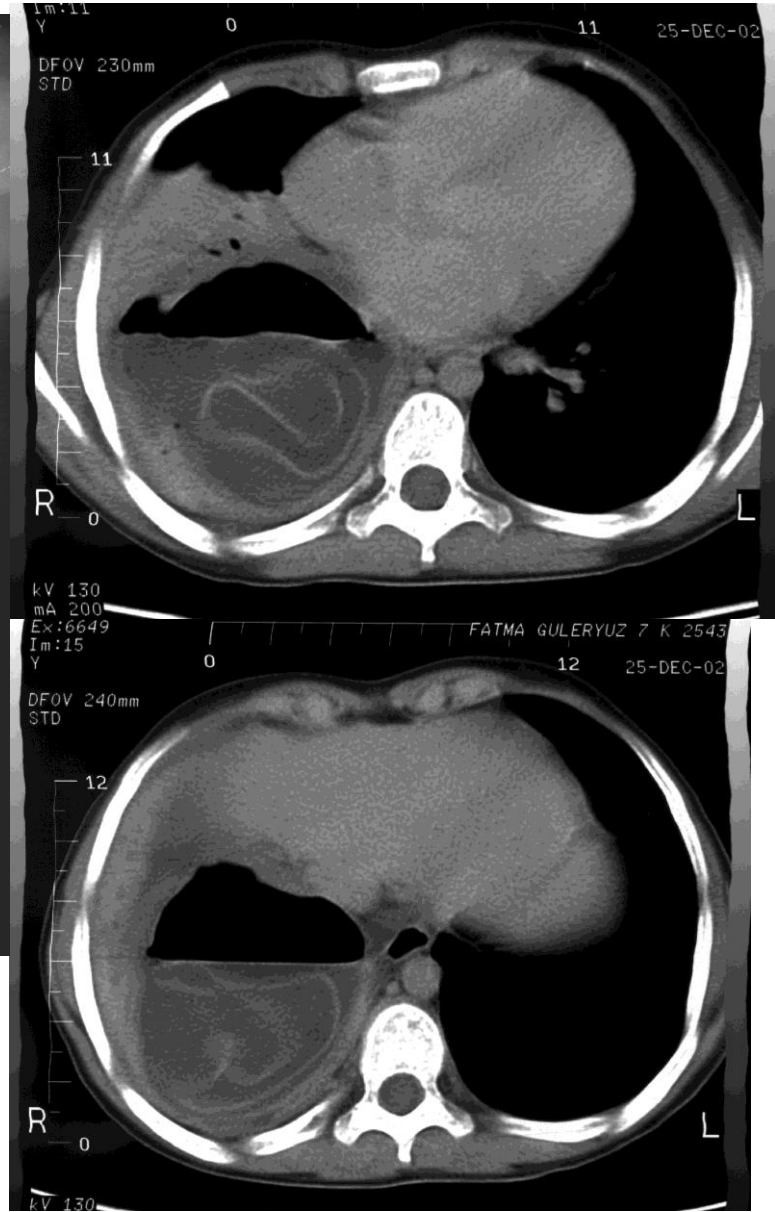
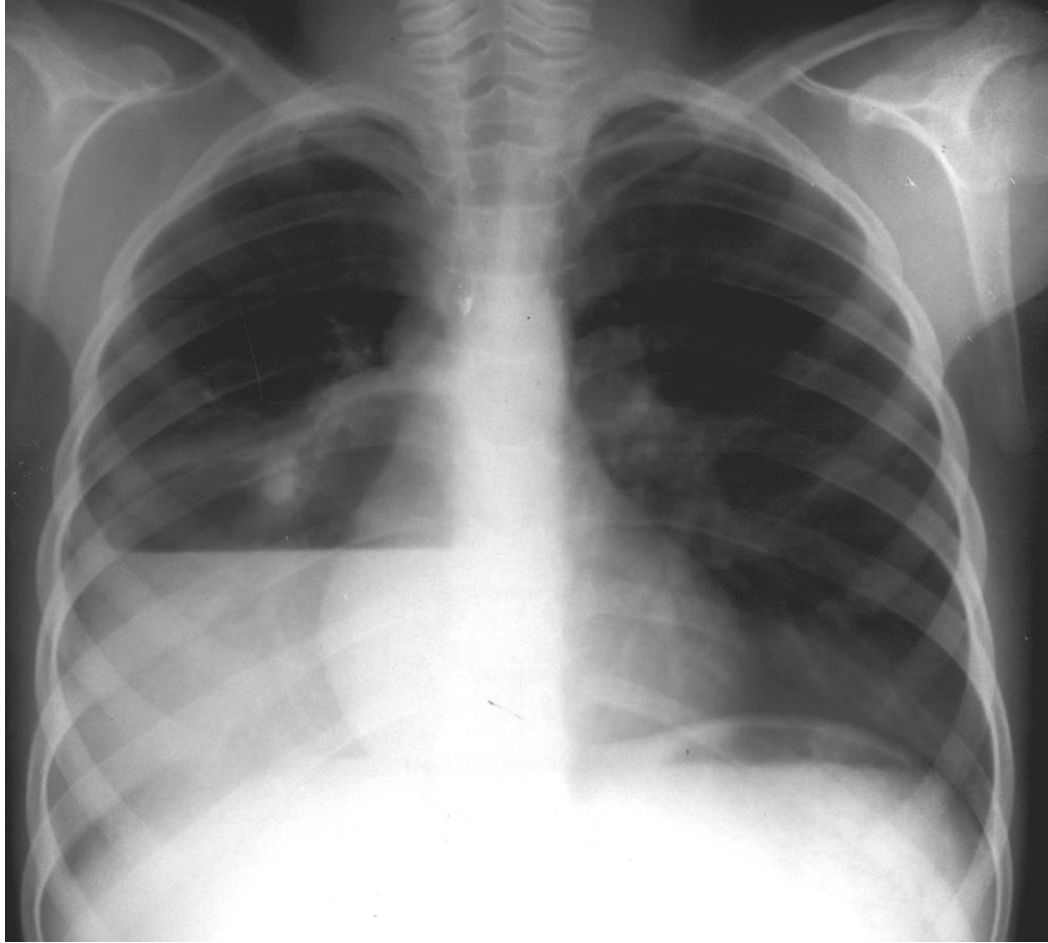

BRONŞ RÜPTÜRÜ
(VE PNÖMOTORAKS)

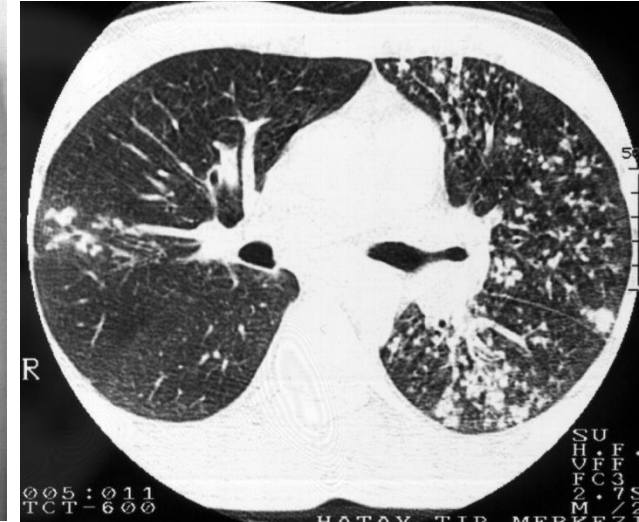
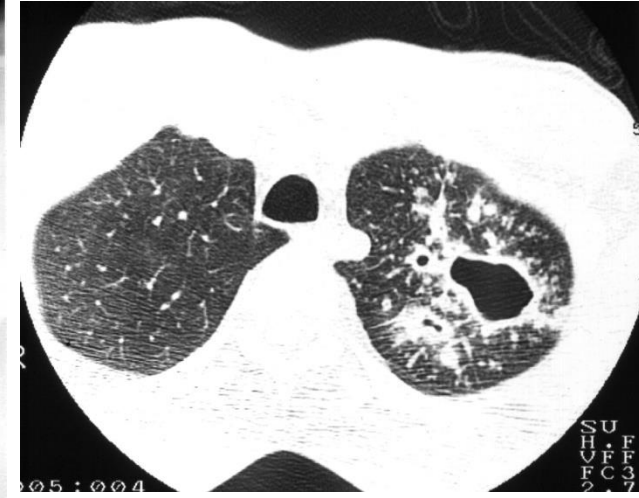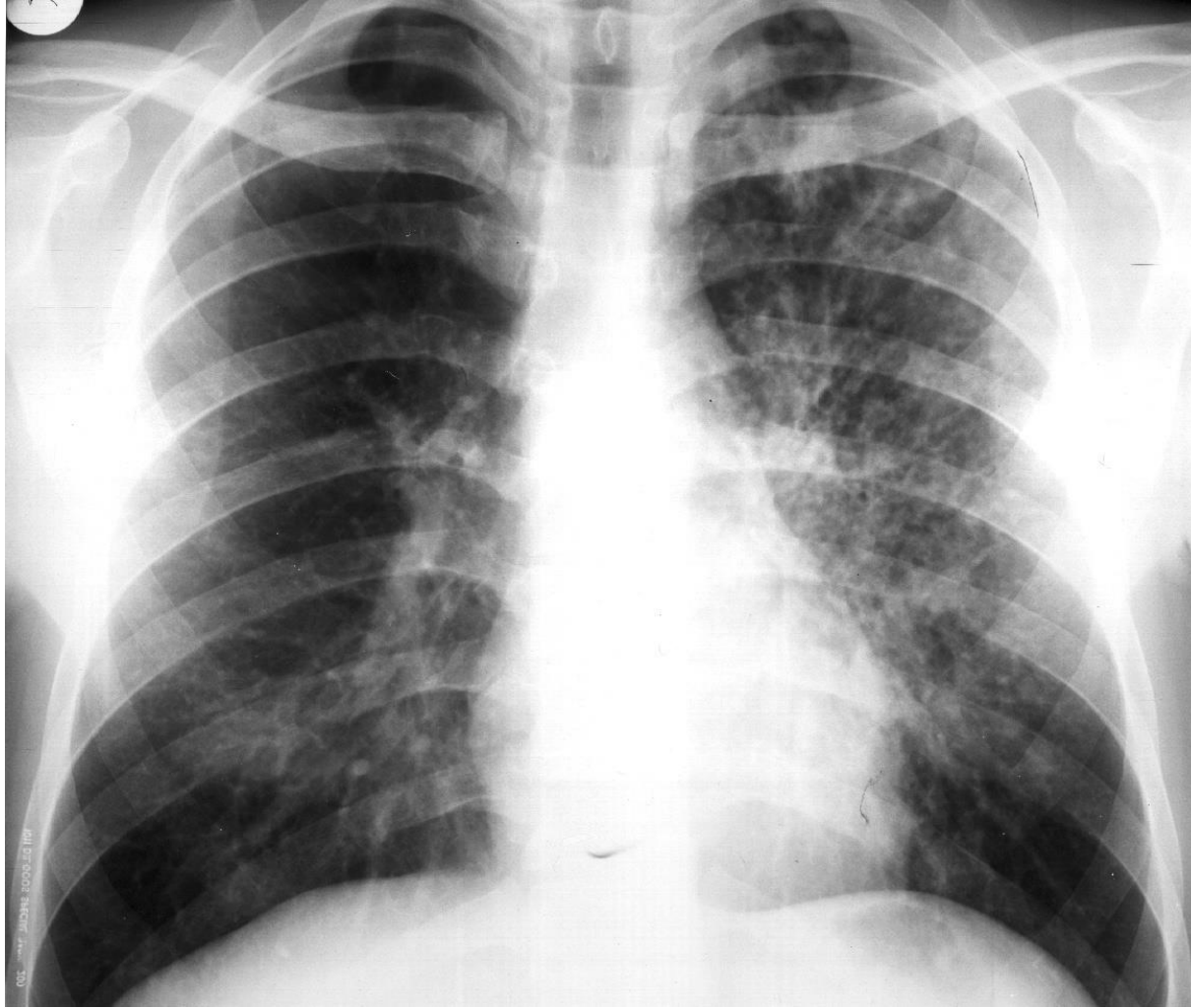
KİSTİK / KAVİTER LEZYONLAR



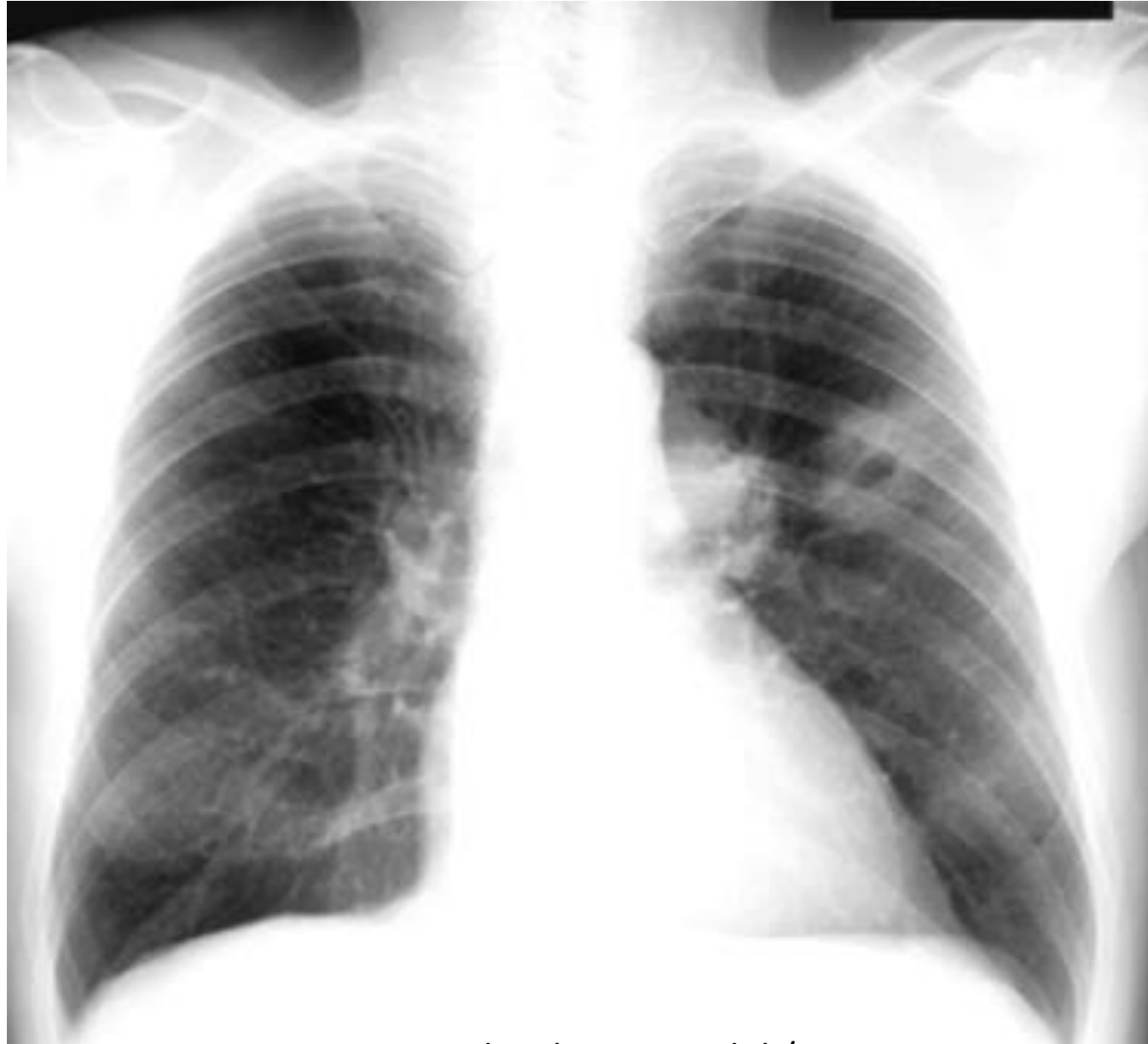Abse



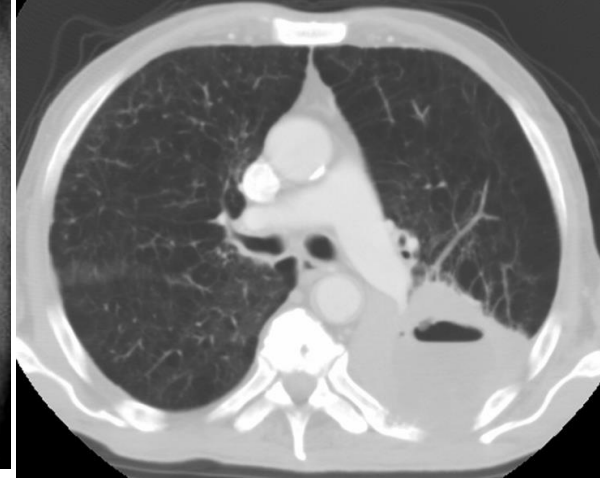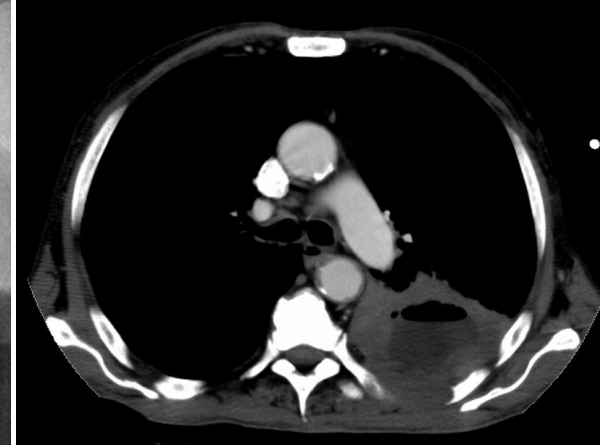
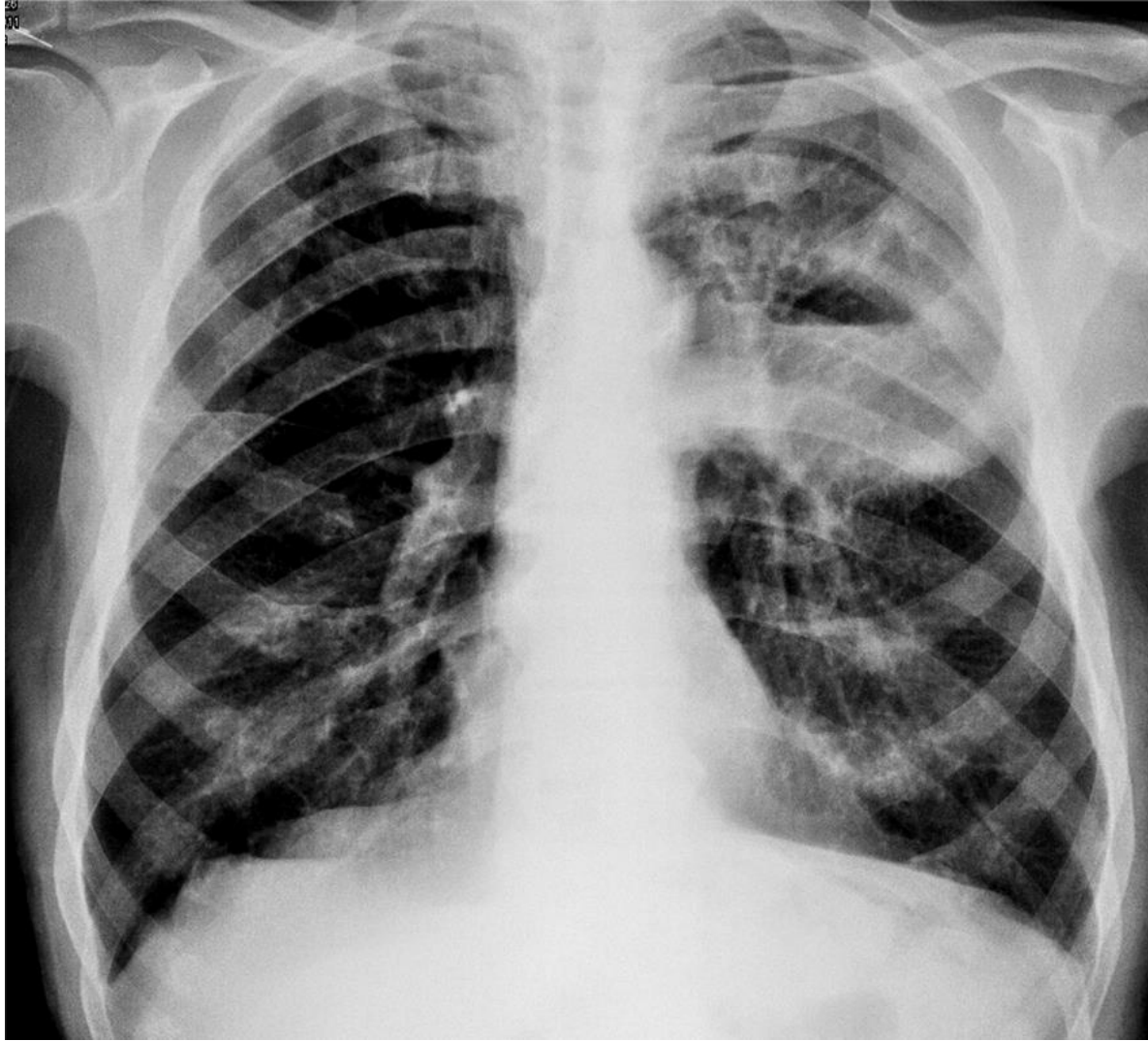
Patlamış kist hidatik



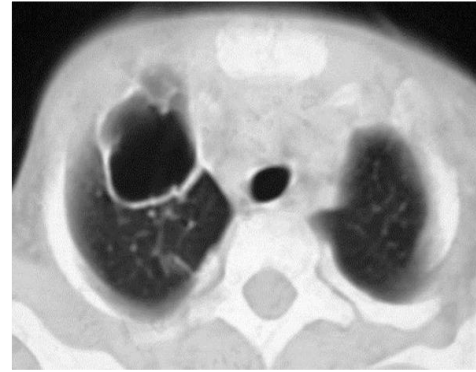
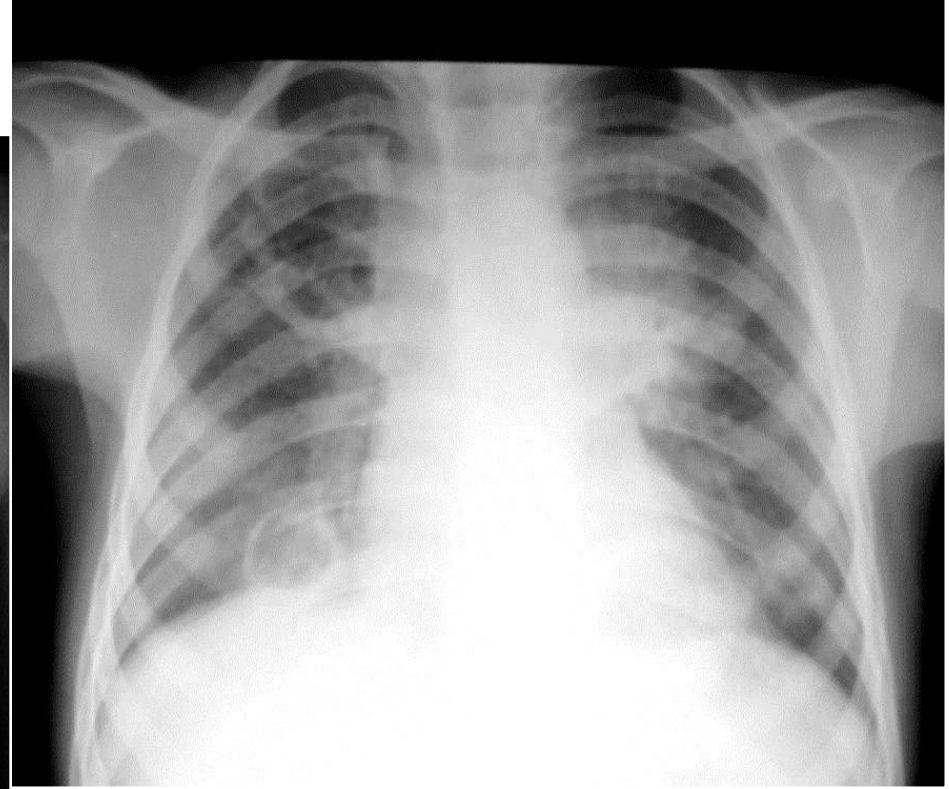
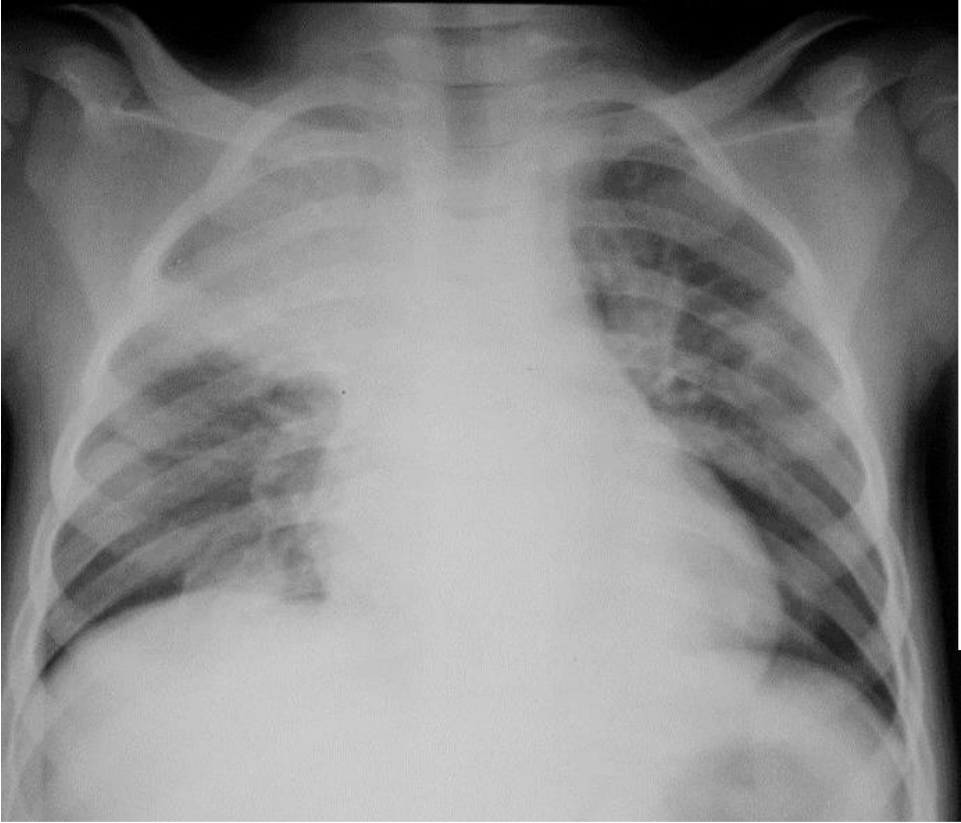
Reaktivasyon tüberkülozu



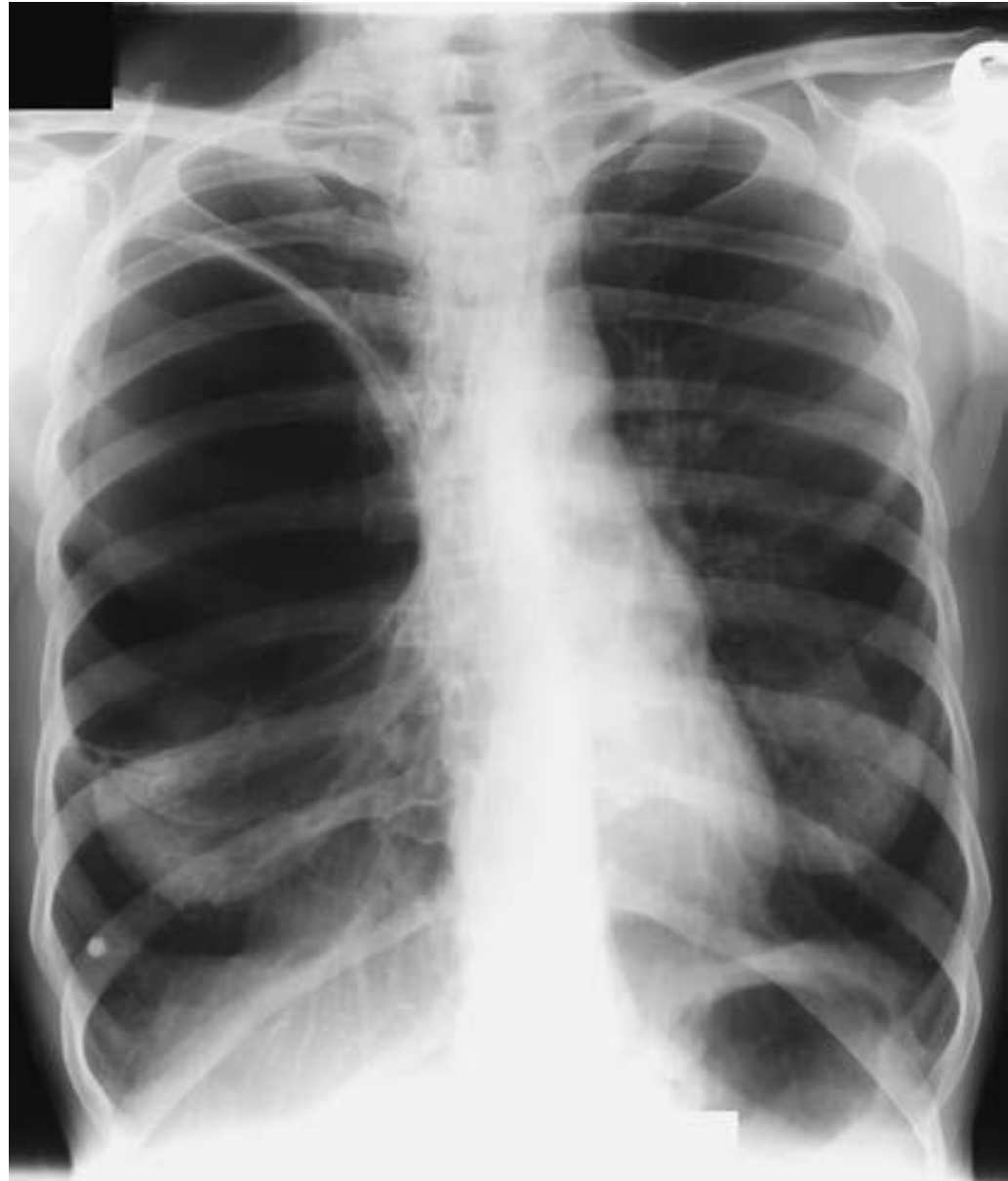Malign kaviter nodül /SCC



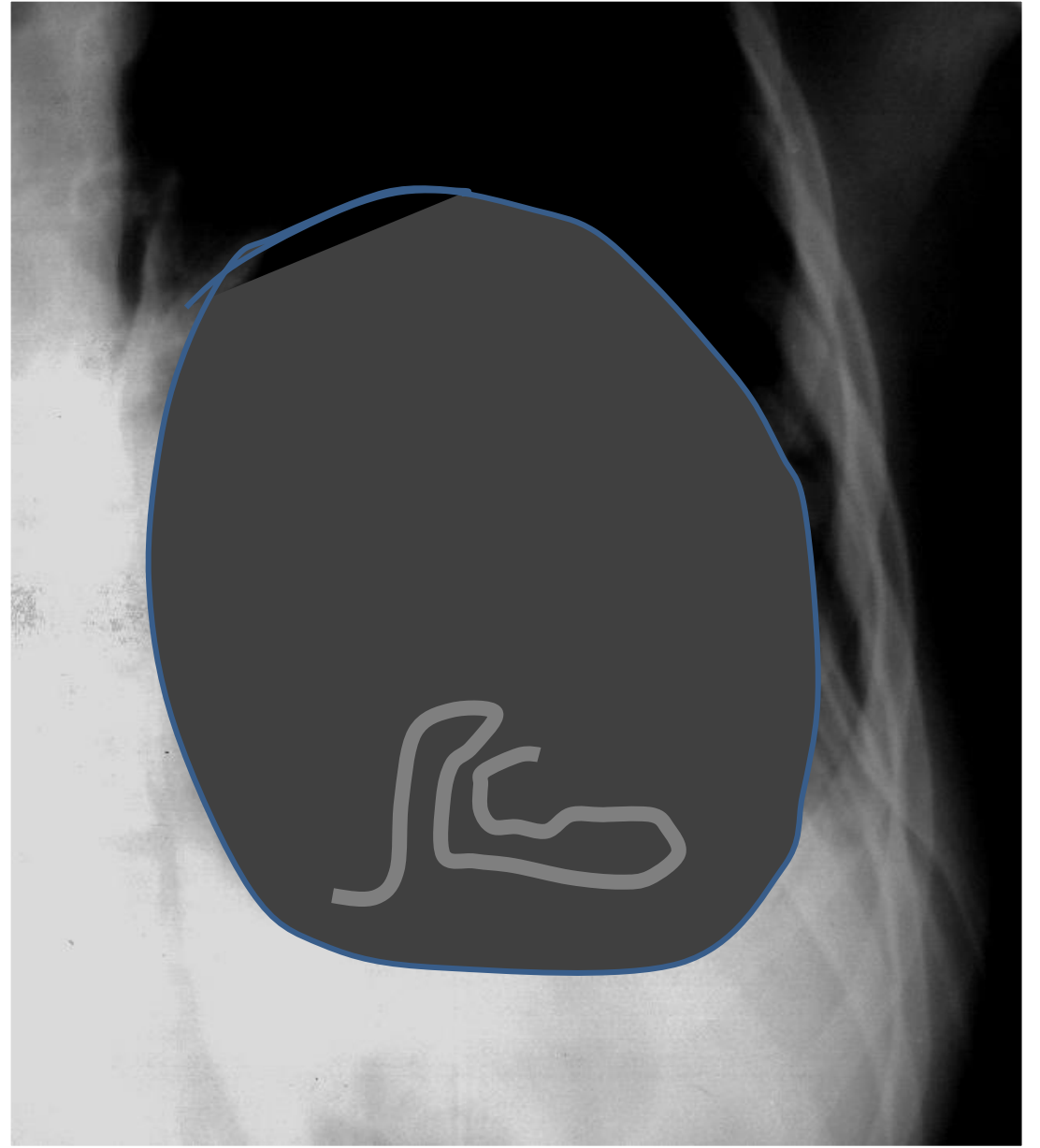
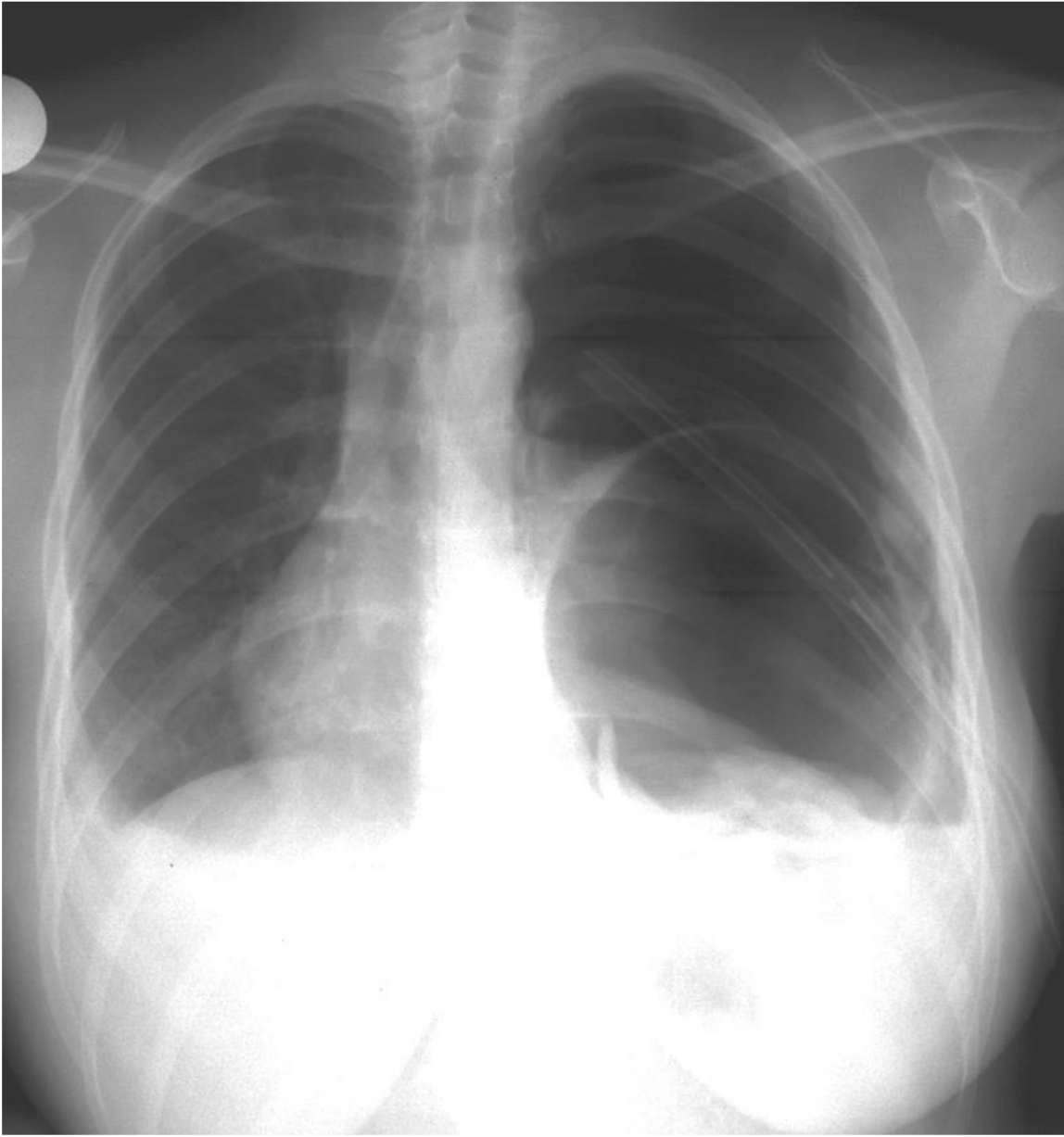
Akciğer kanseri



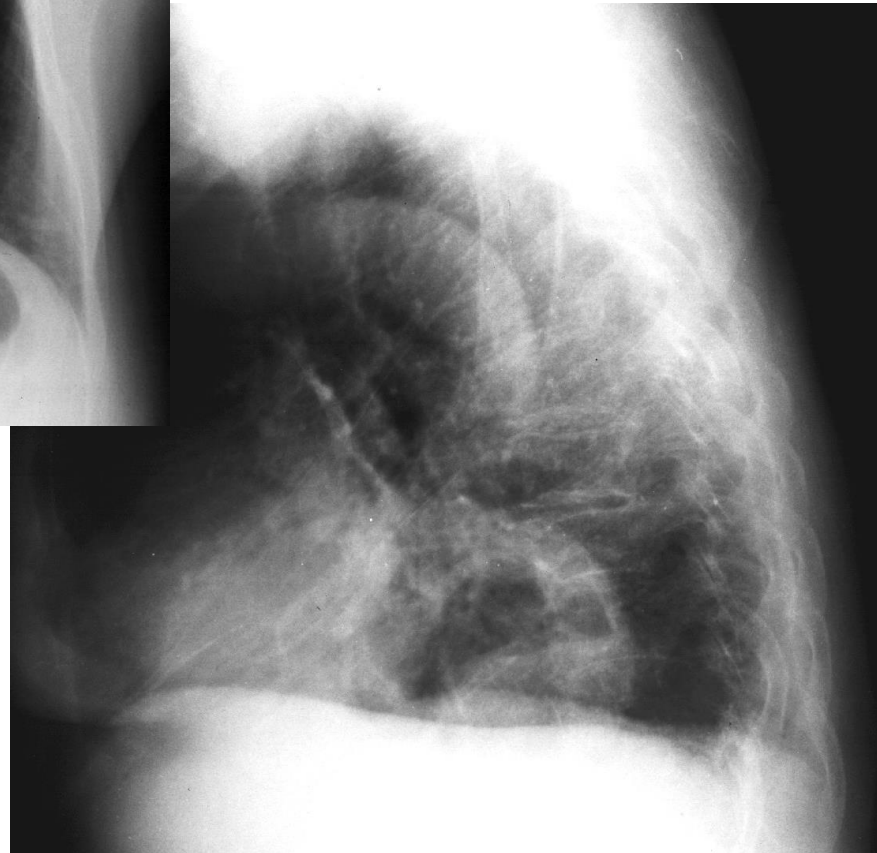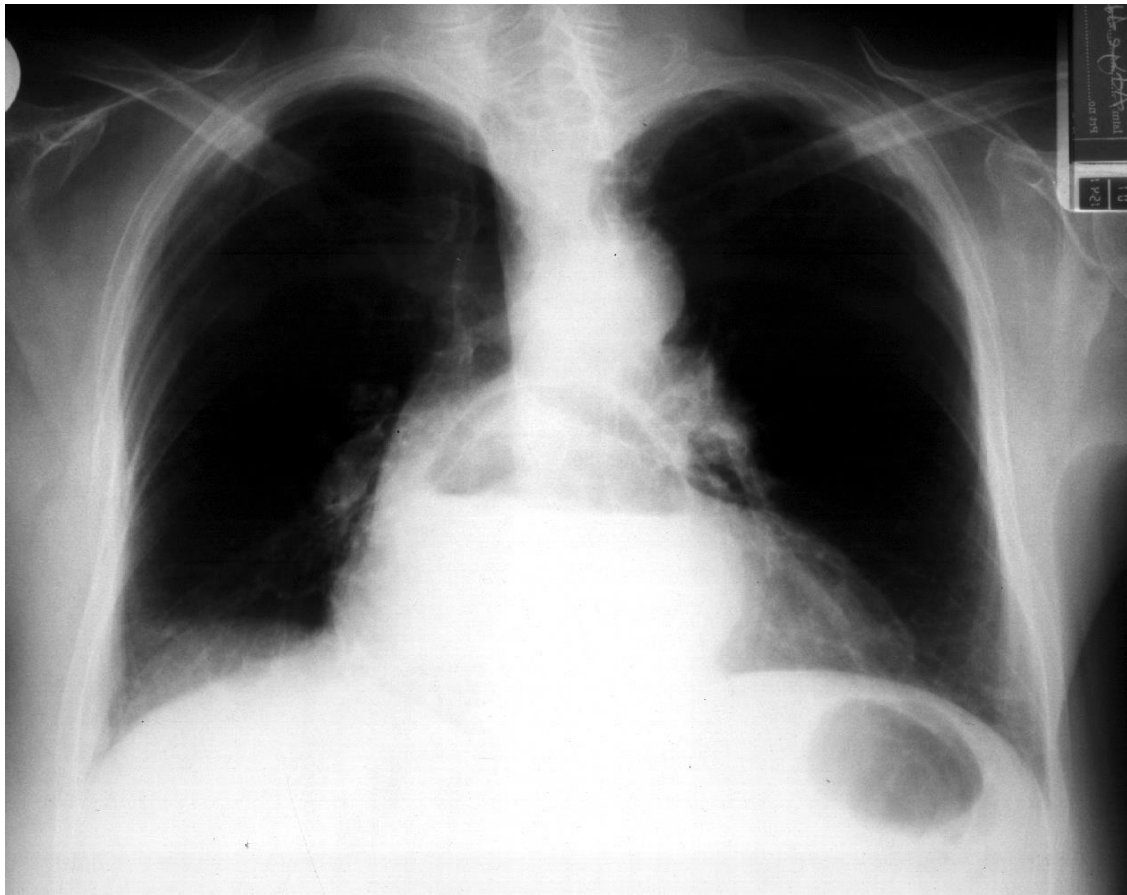Stafiolok pnömonisi ve pnömosel



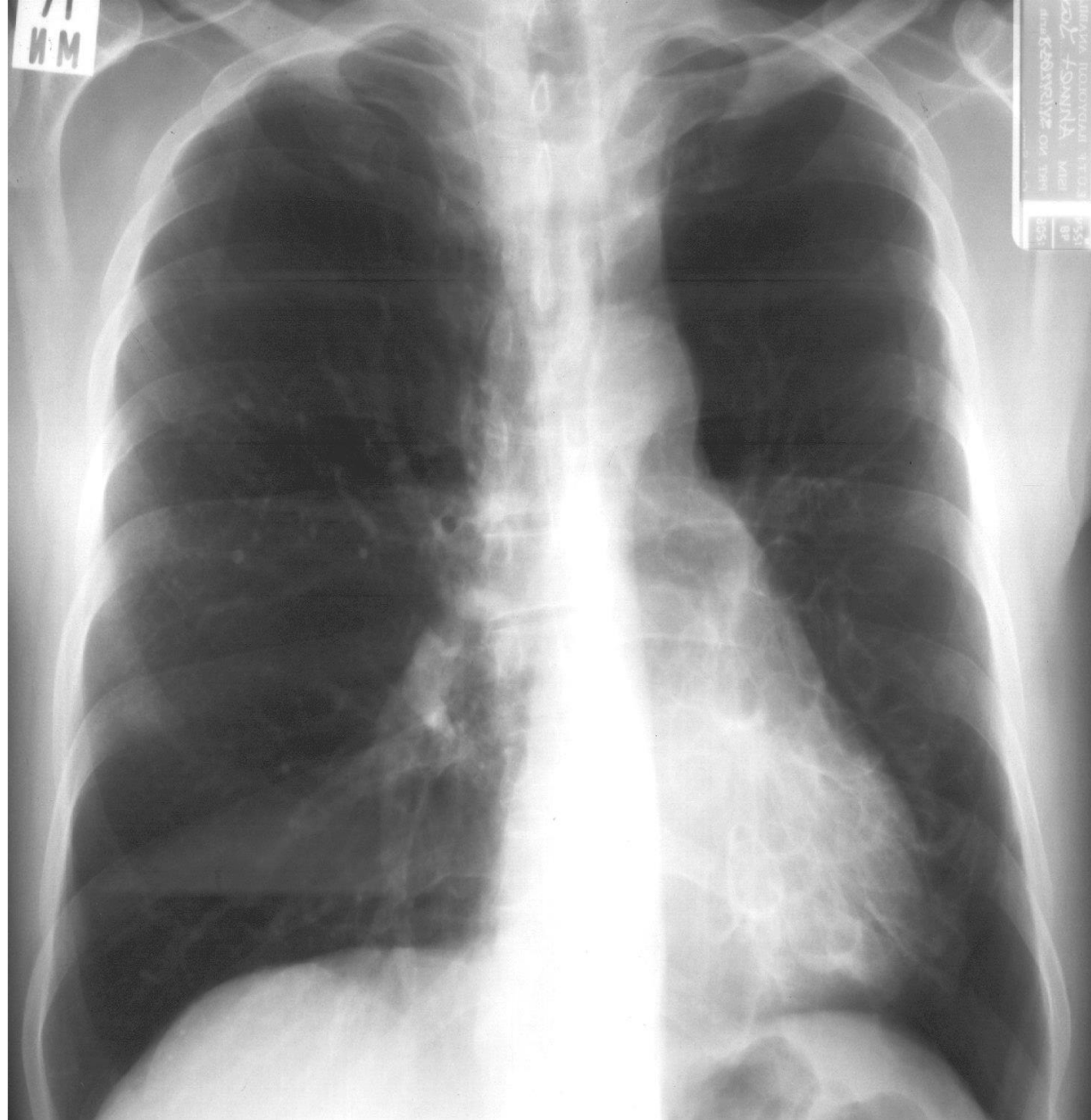
Dev bül



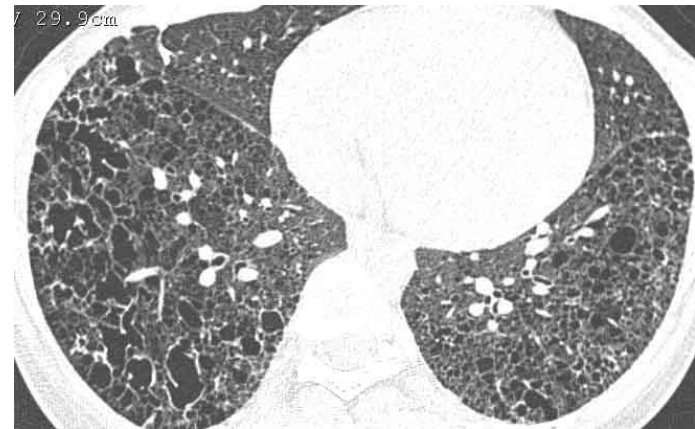
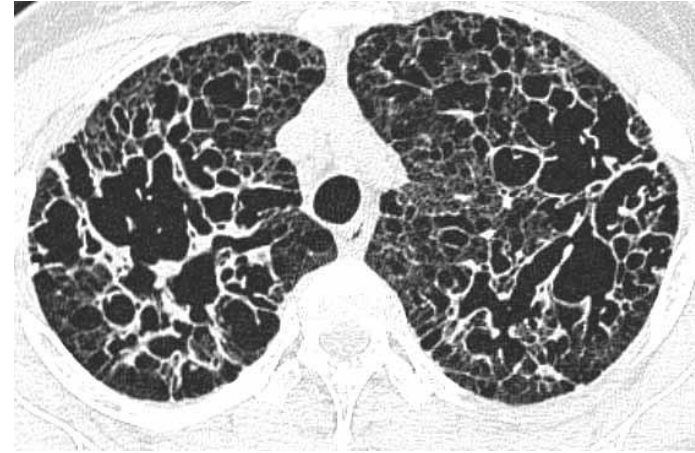
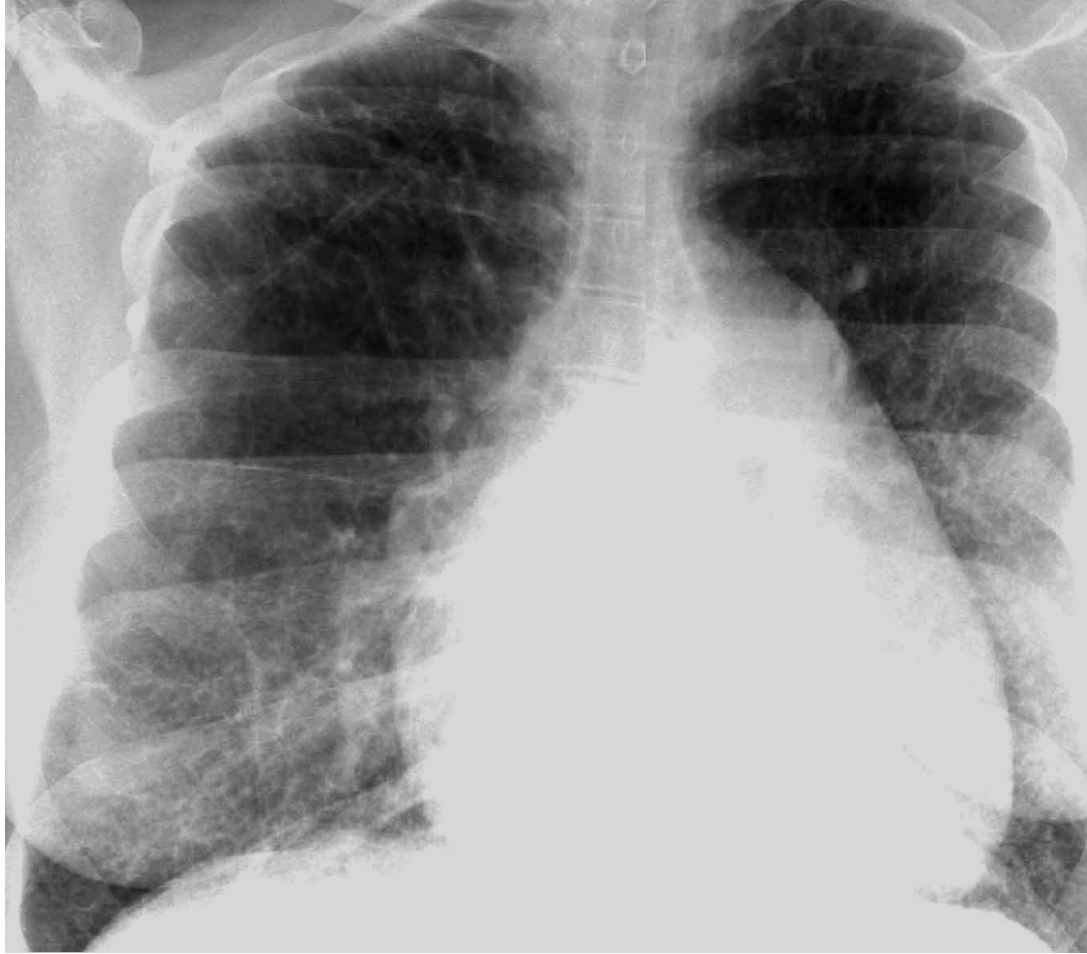PERFORE KİST HİDATİK



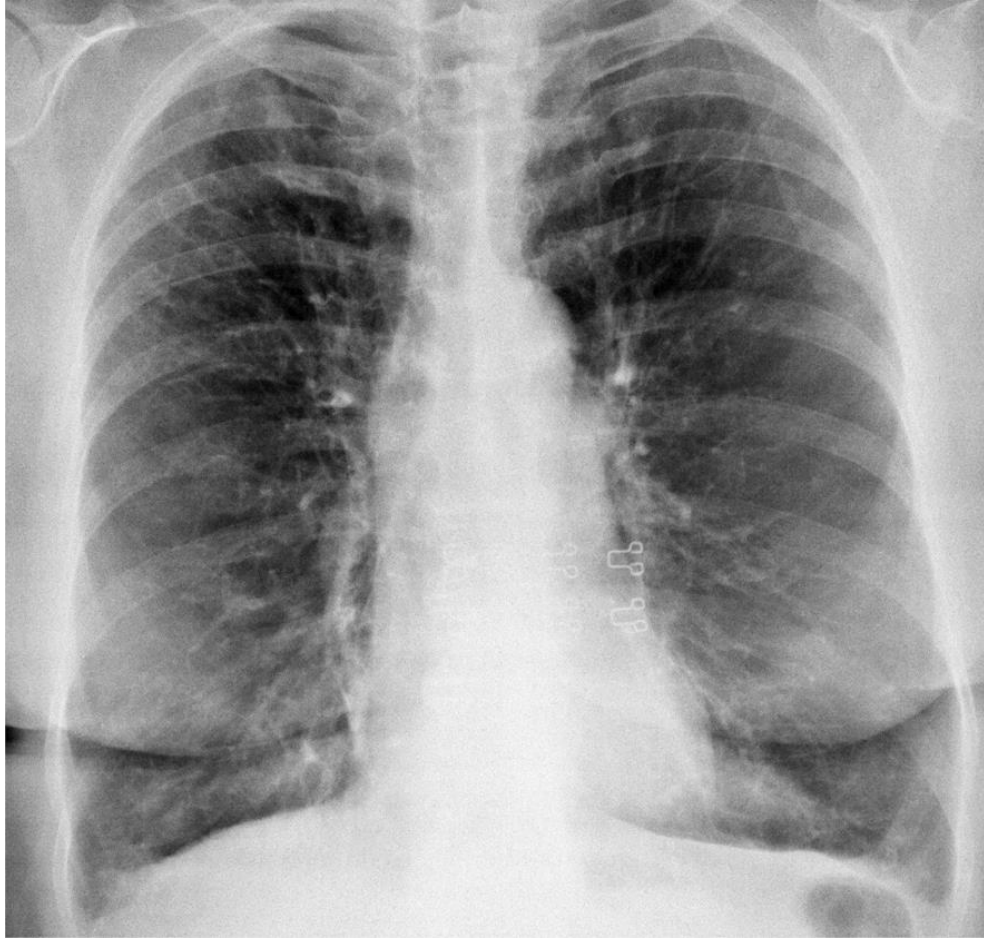
Hiatus hernisi



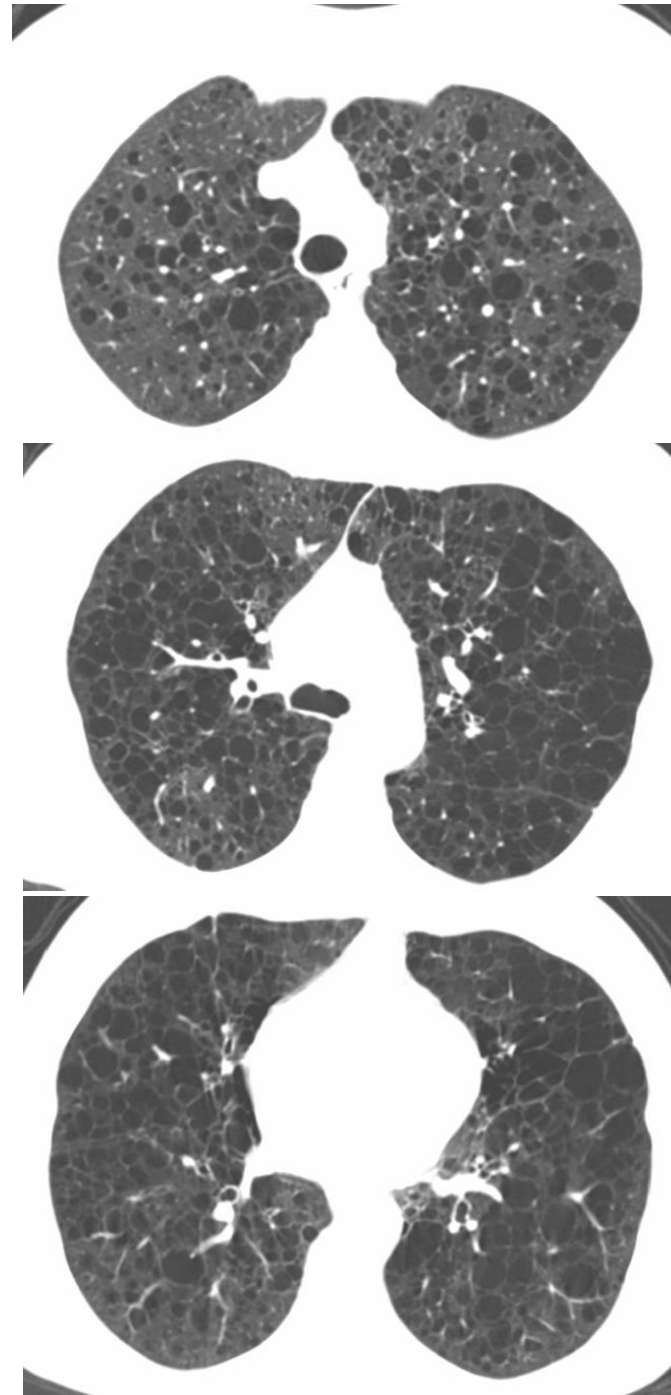
Bronşektazi



LHH



LAM



TEŞEKKÜRLER