

# Nükleer Tıp (PET/BT ve V/Q)

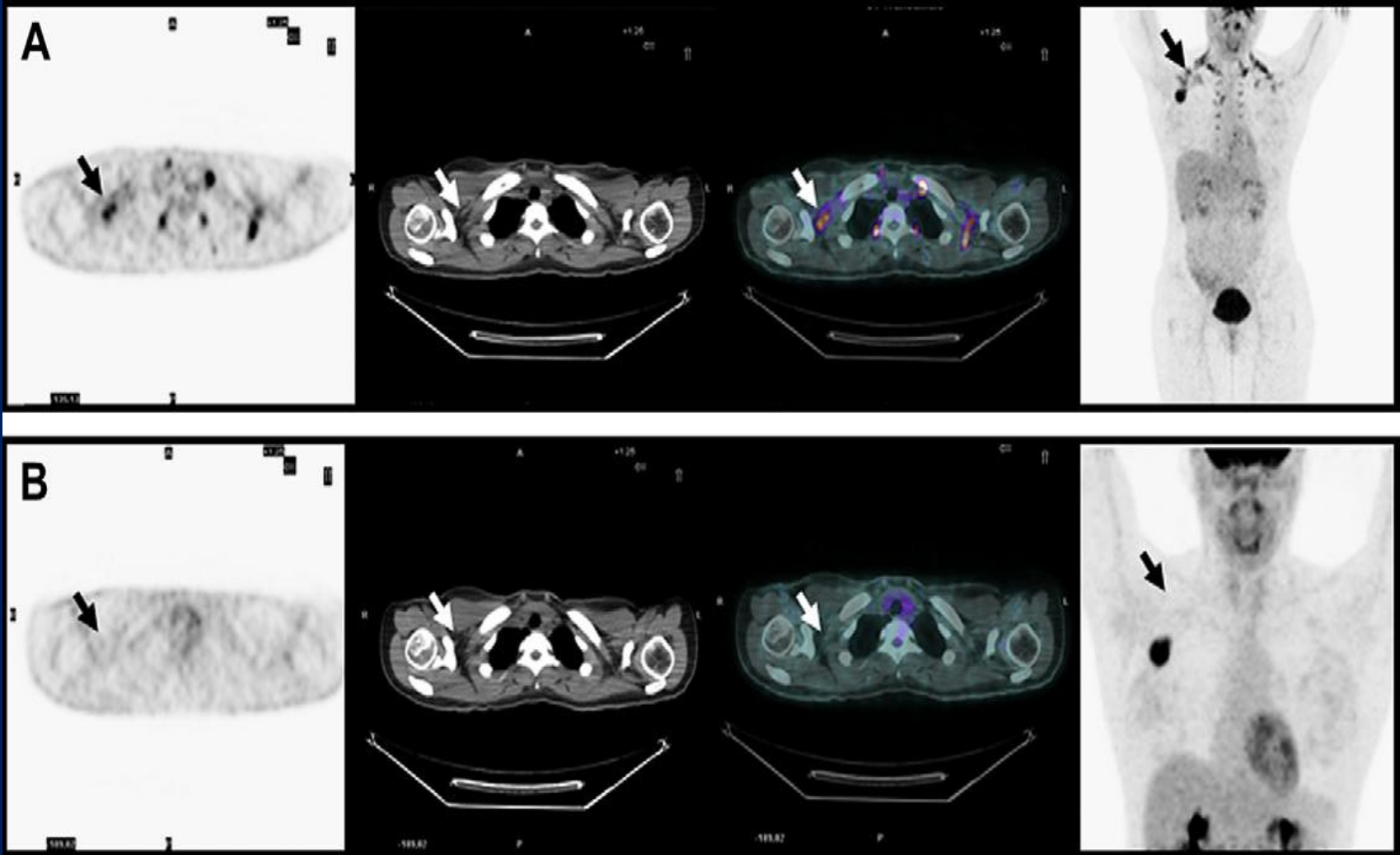
Dr. Murat Tuncel

# PET/BT Sunum planı

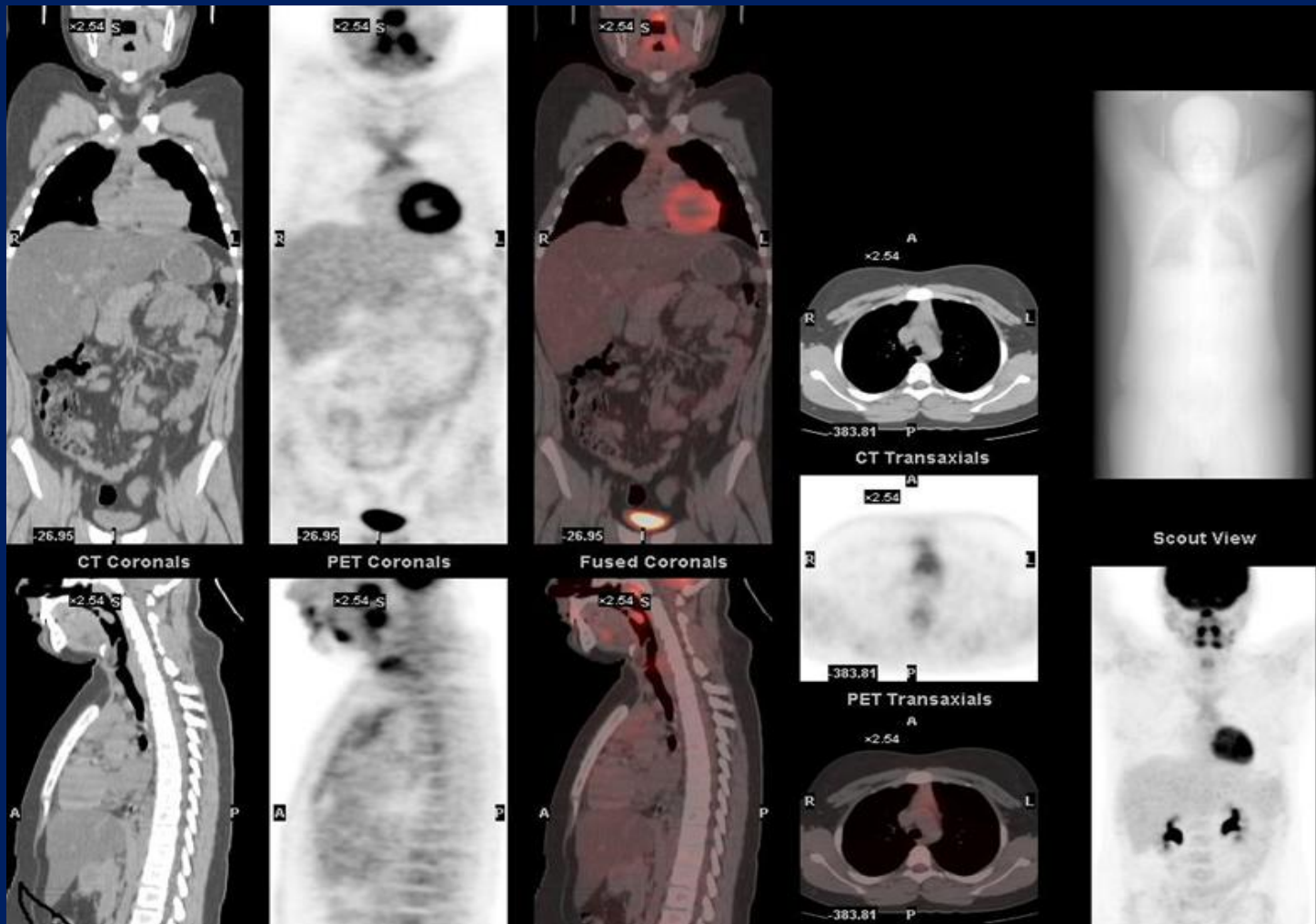
- Fizyolojik ve benign tutulumlar
- Akciğer PET-BT tümör görüntüleme özel durumlar
- PET-BT'nin katkıları ve limitasyonları
- KHDAK'da PET-BT

# Fizyolojik ve benign tutulumlar

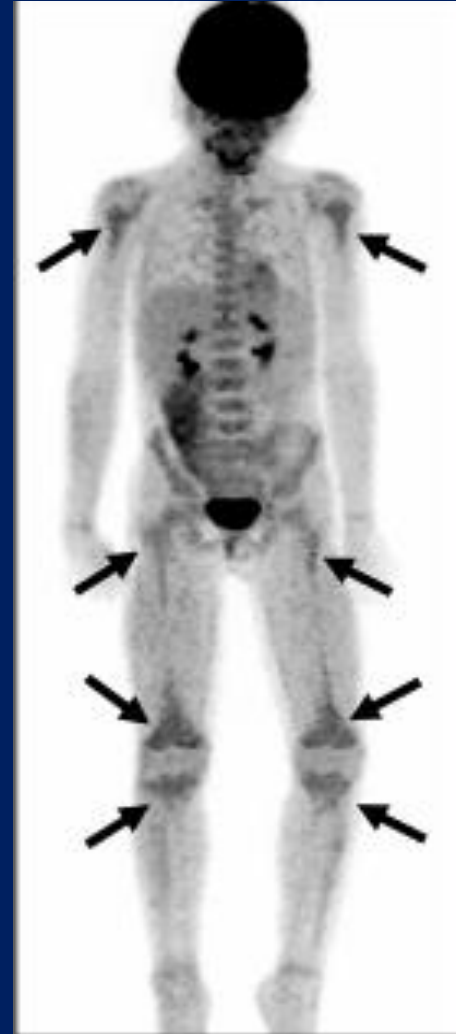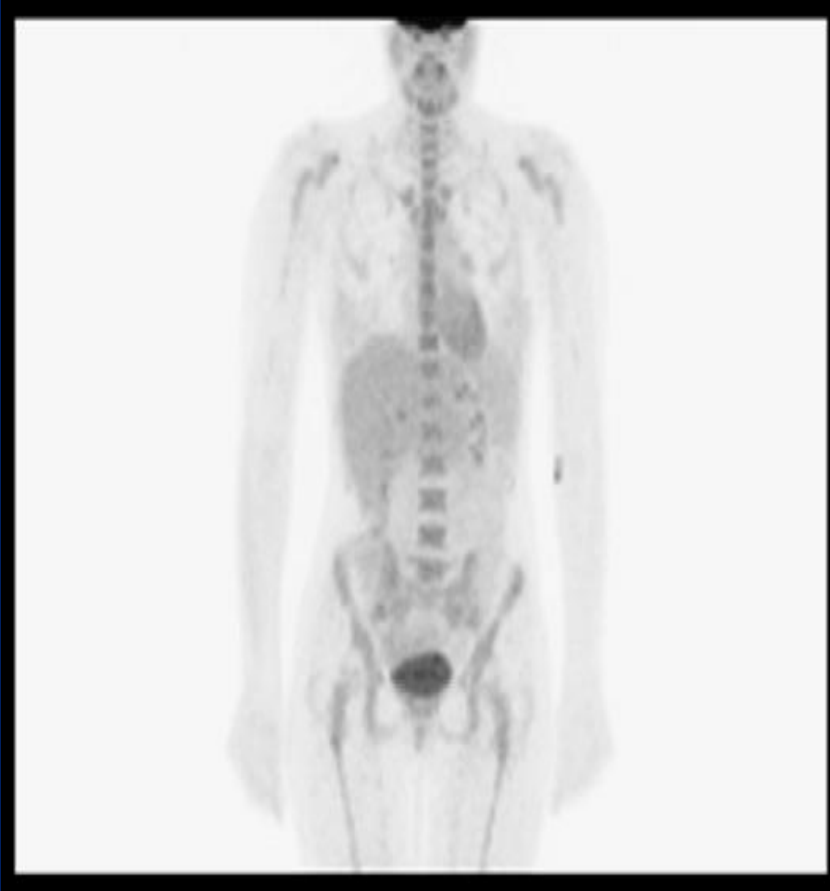# Kahverengi yağ dokusu



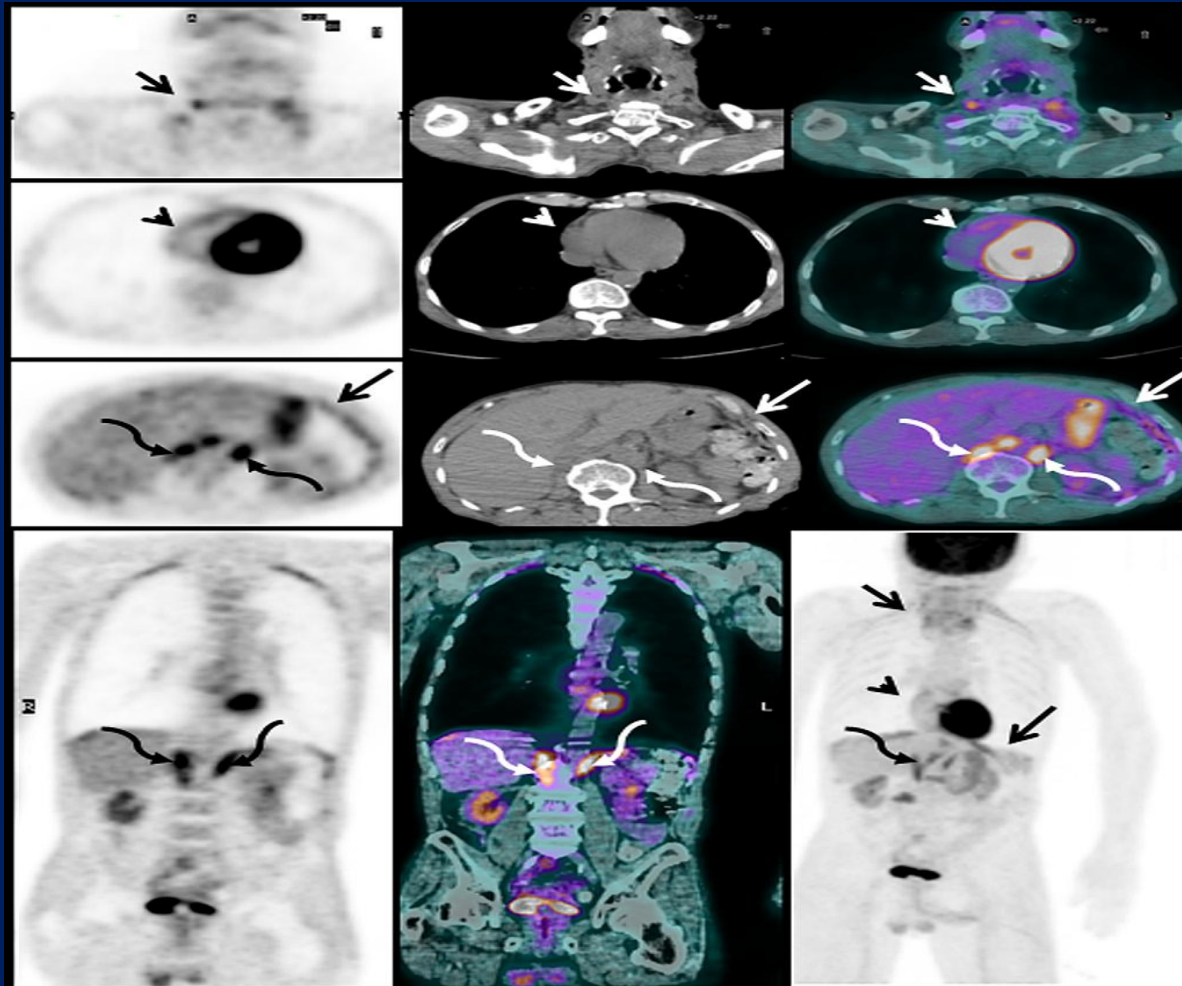
# Timik tutulum



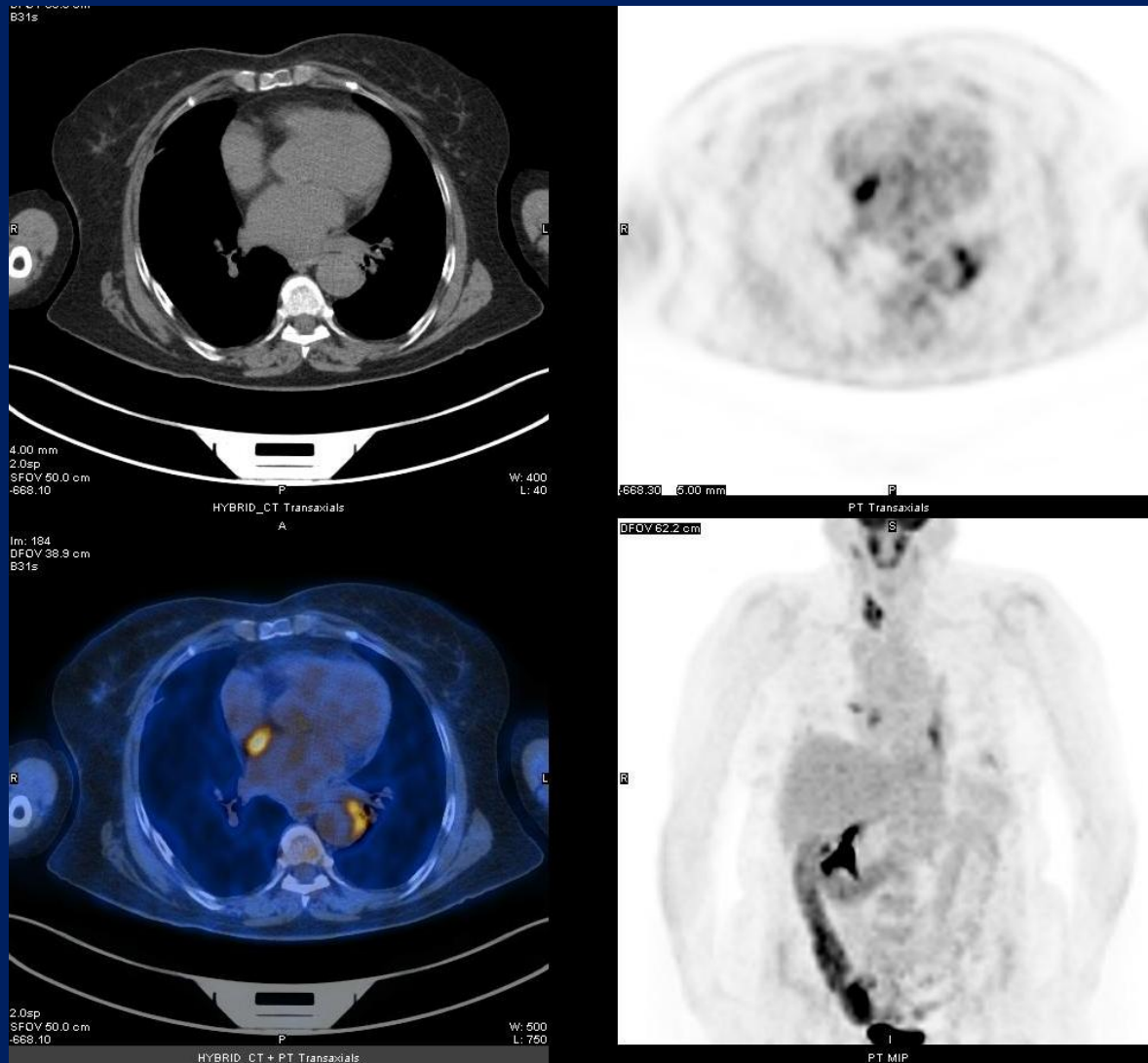
# Kemik iliđi aktivasyonu



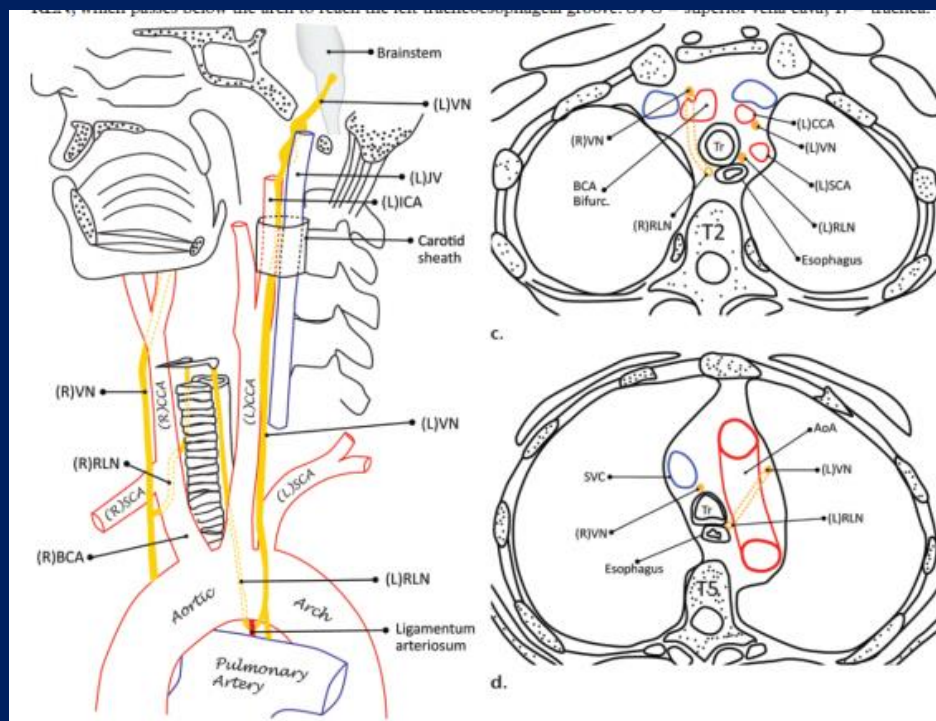
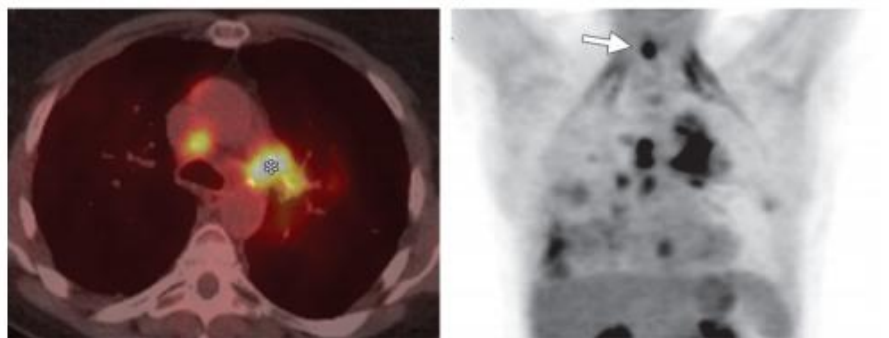
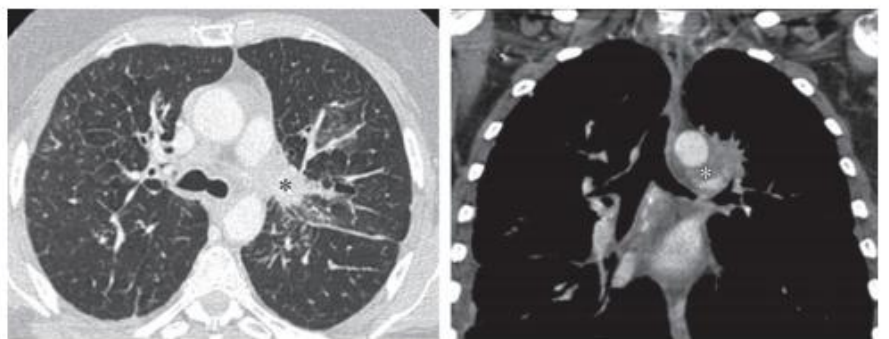
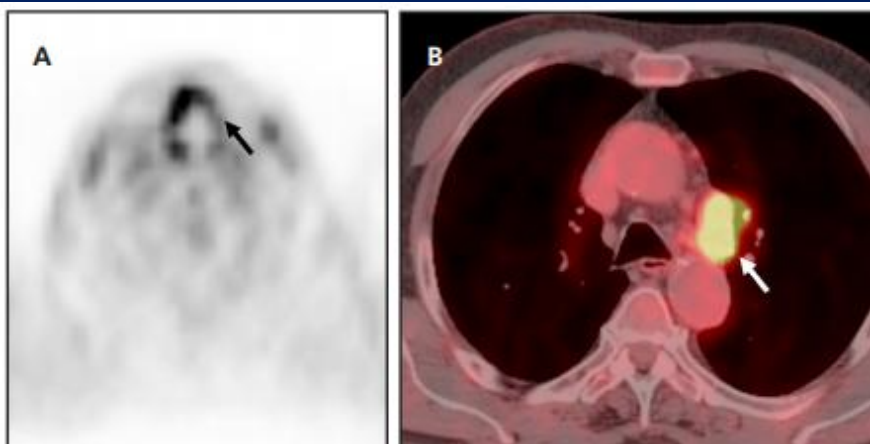
# Solunum kasları



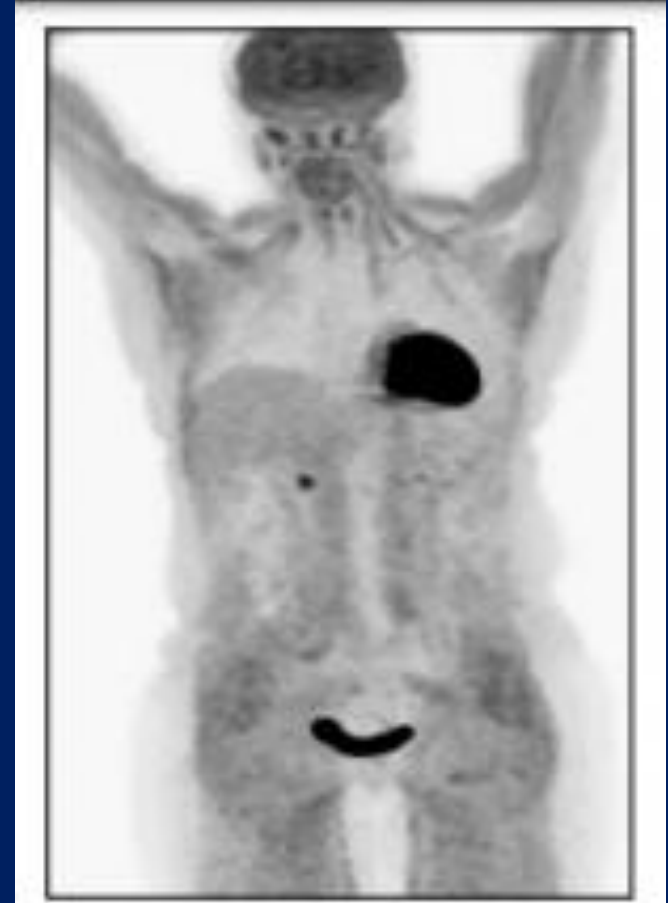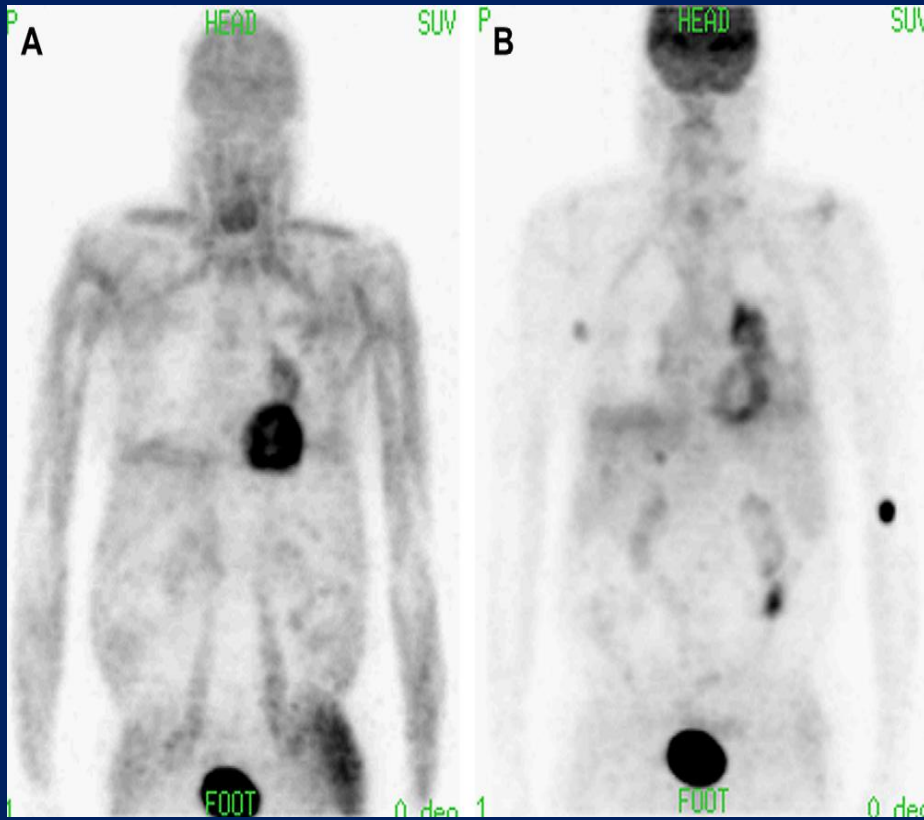
# Intra-artriyal septumun lipomatöz hipertrofisi



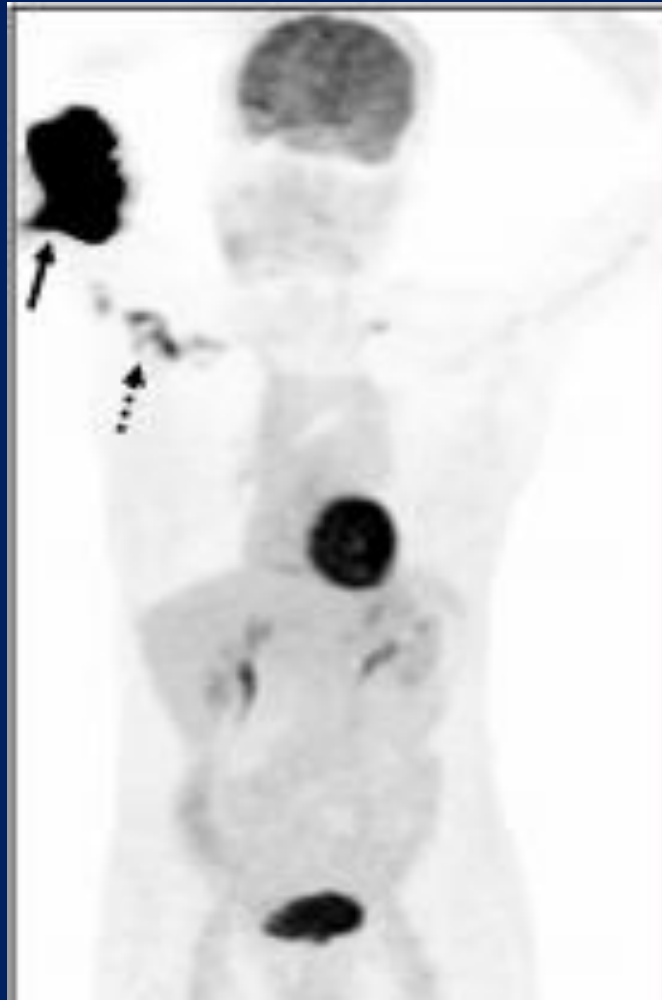




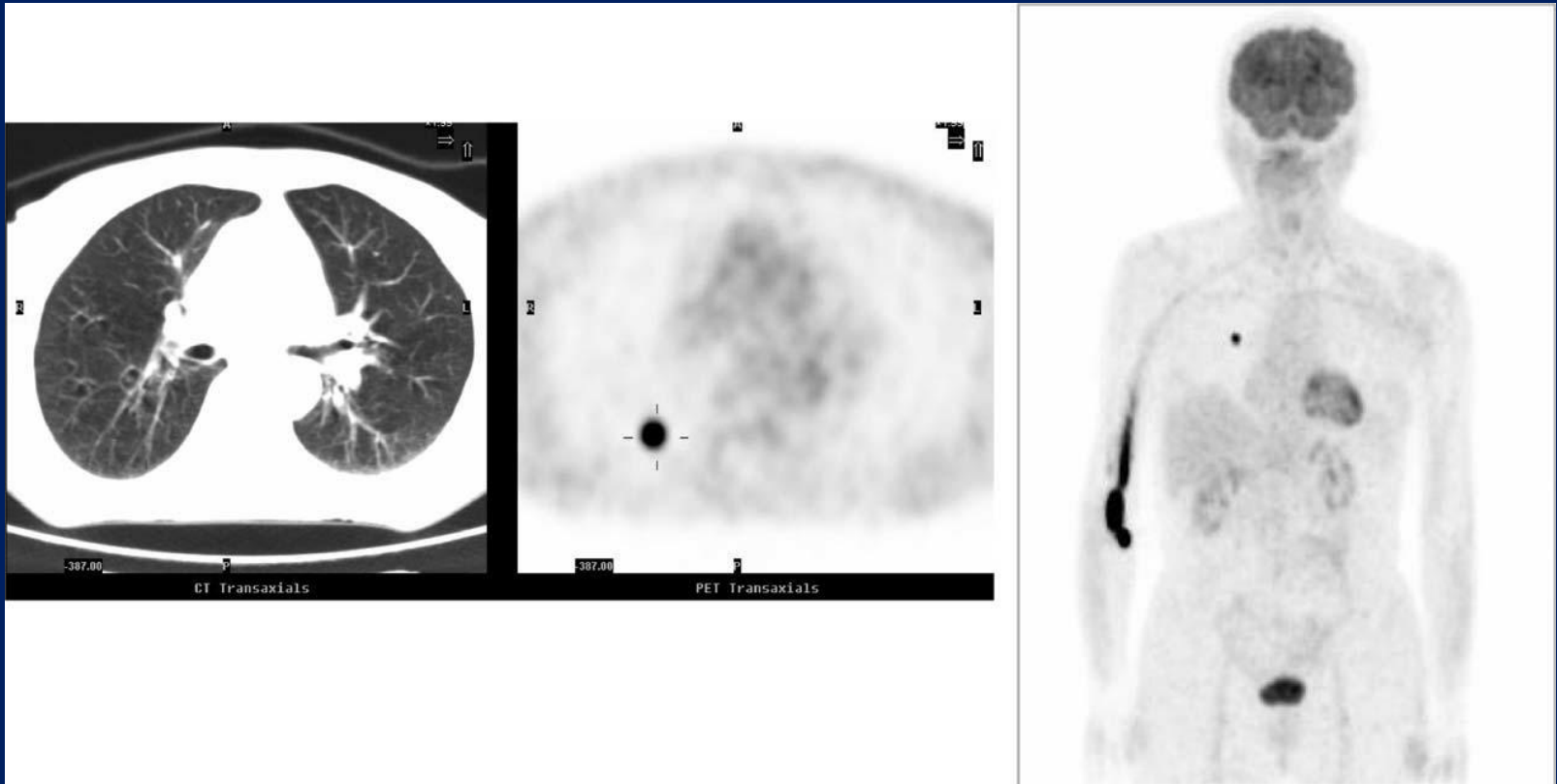
# Hiperglisemi



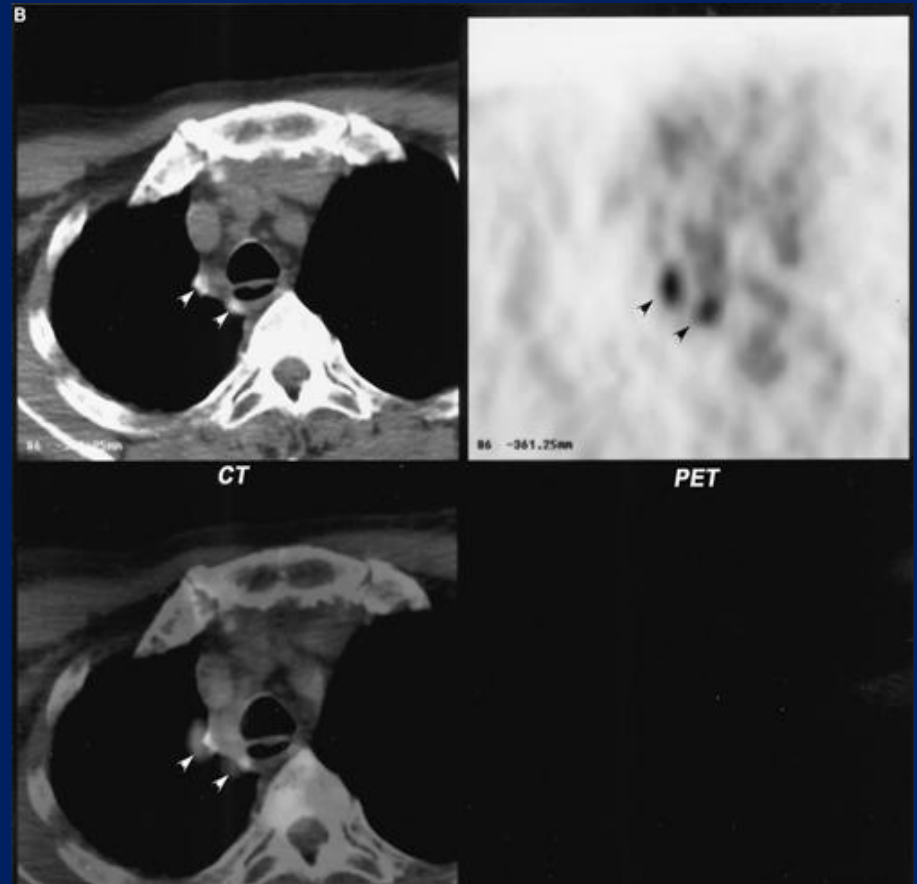
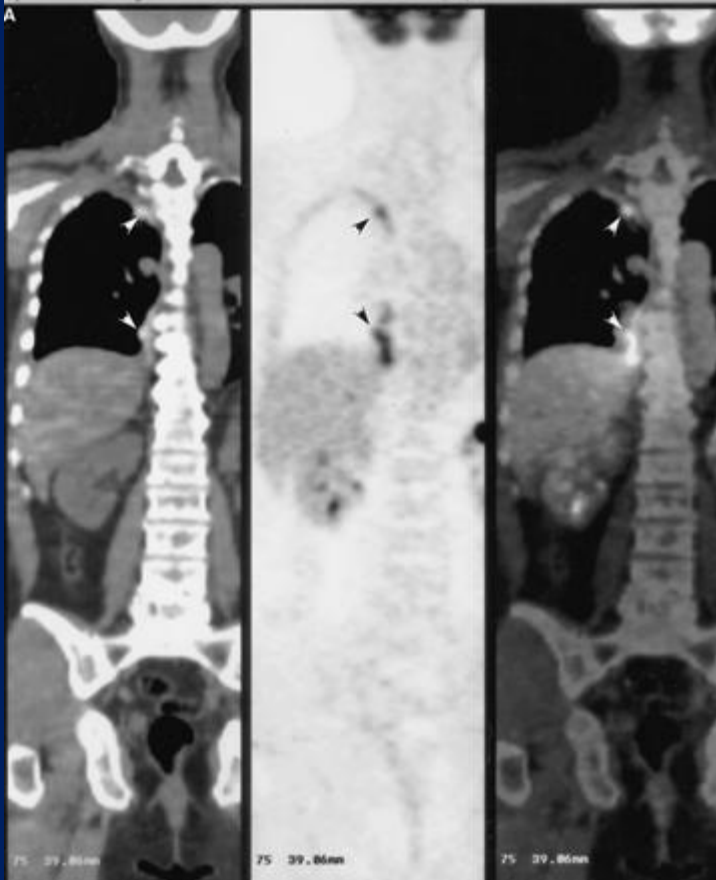
# Ekstravazasyon



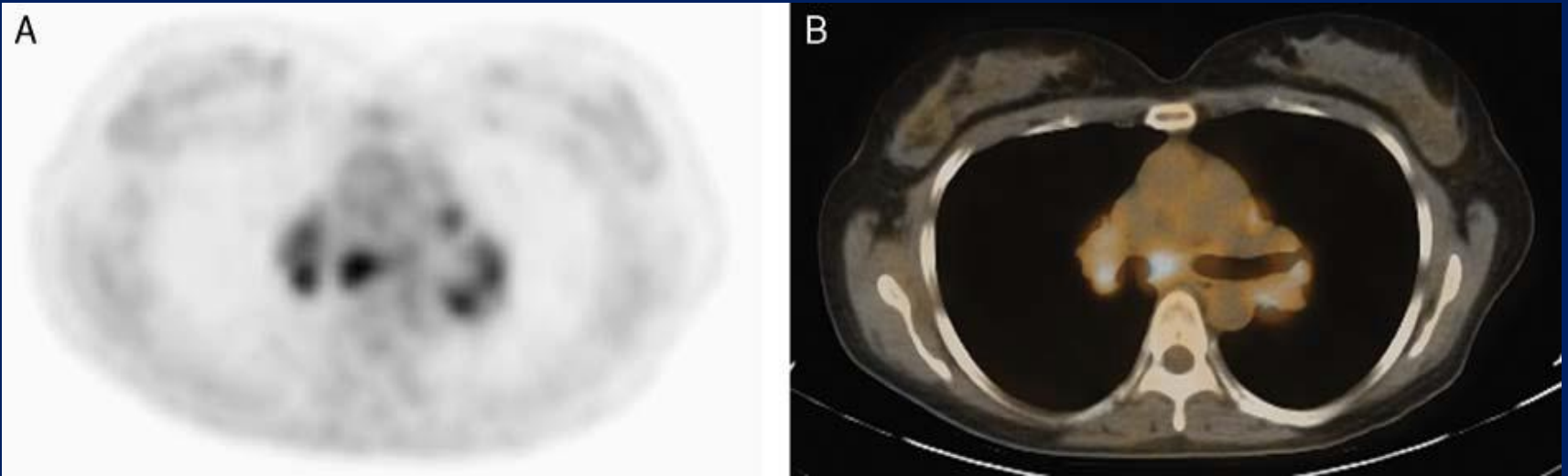
# FDG emboli



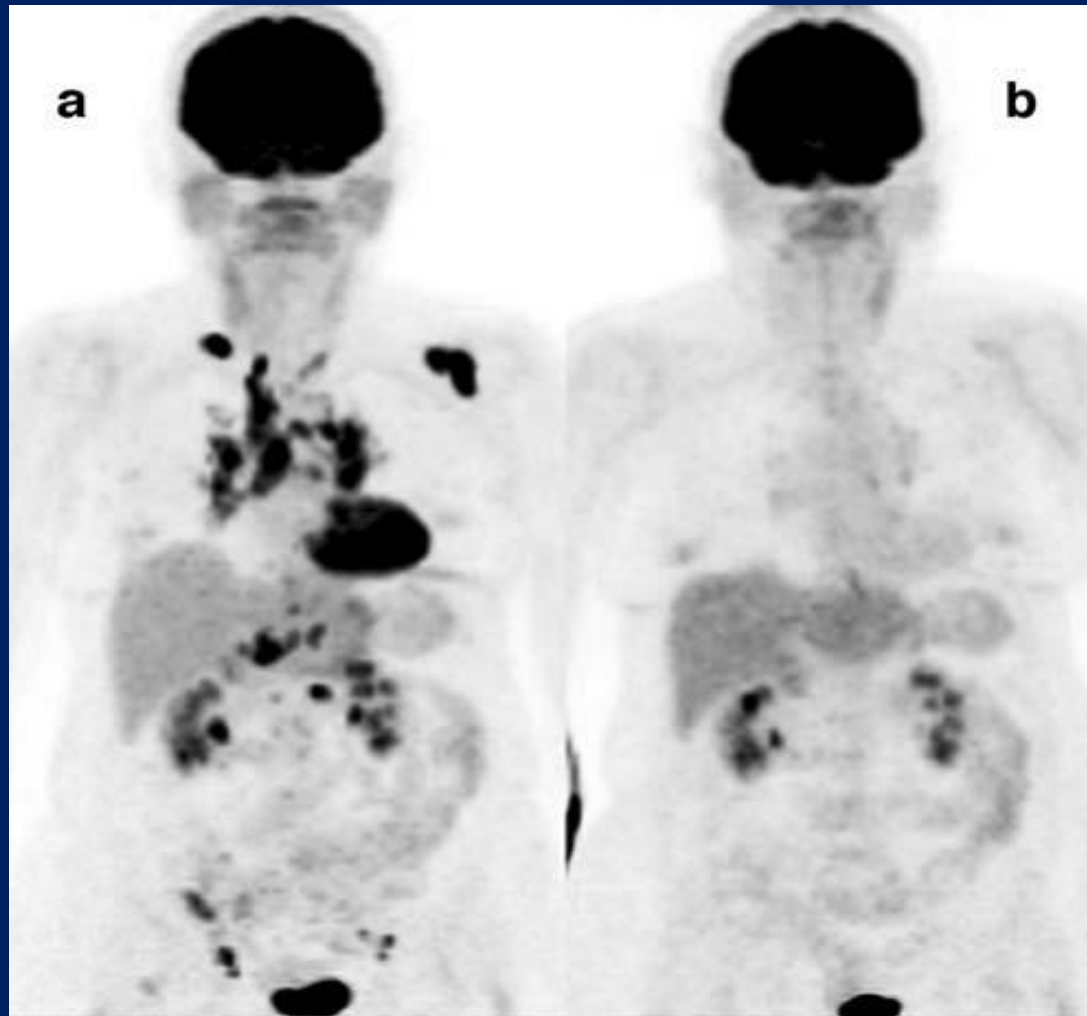
# Talk plörodez



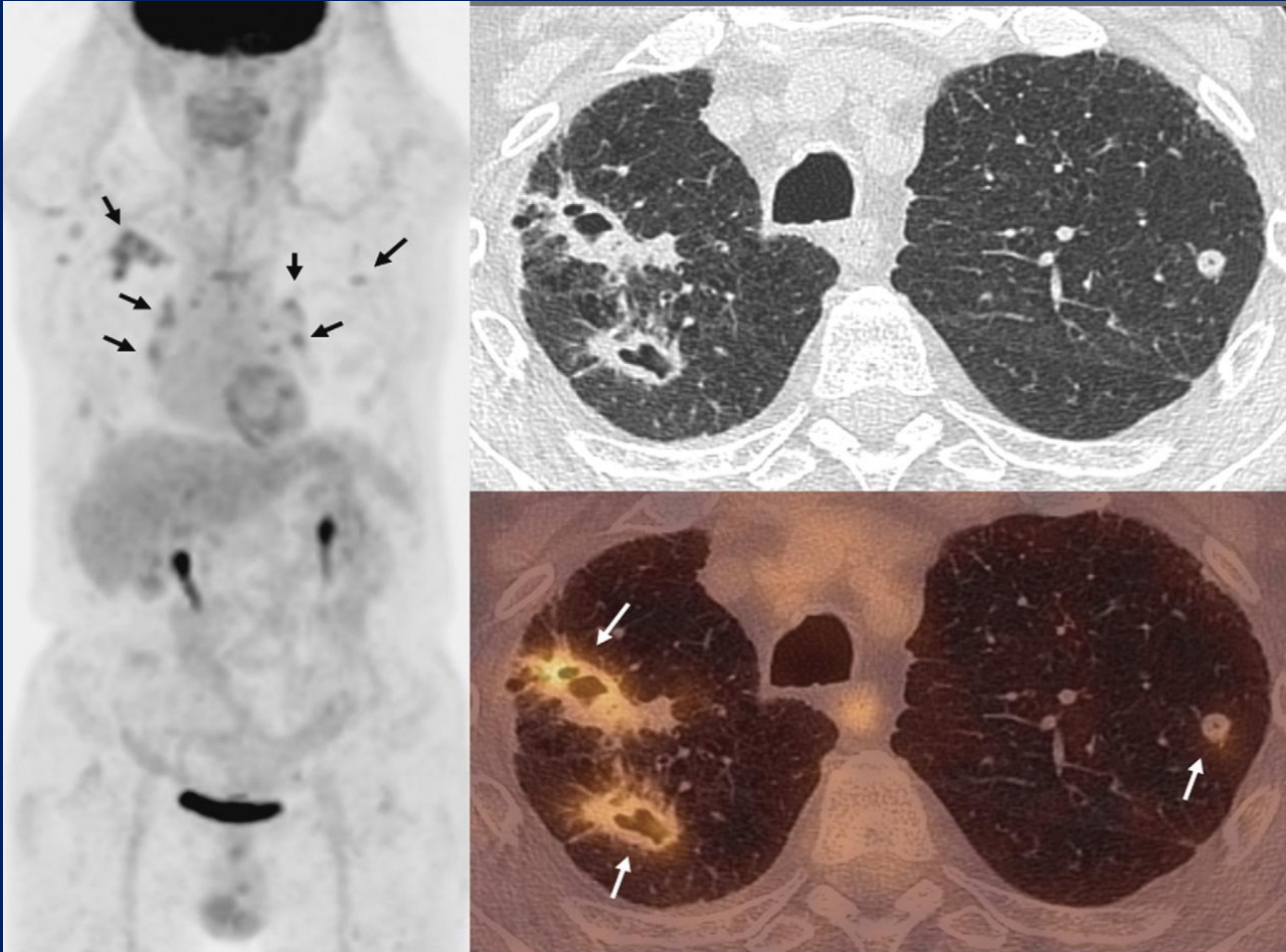
# Sarkoidoz



# Sarkoidoz



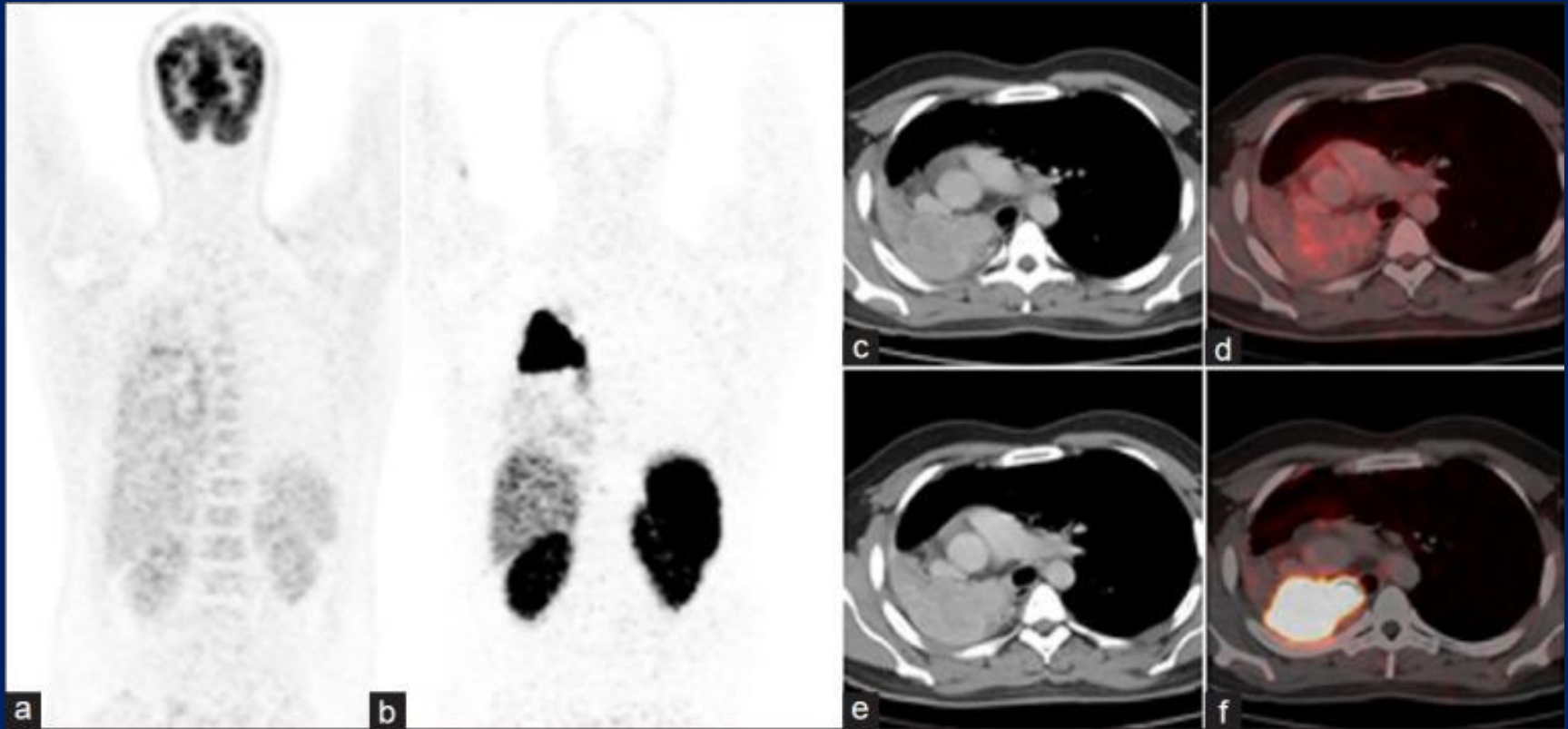
# Tüberküloz



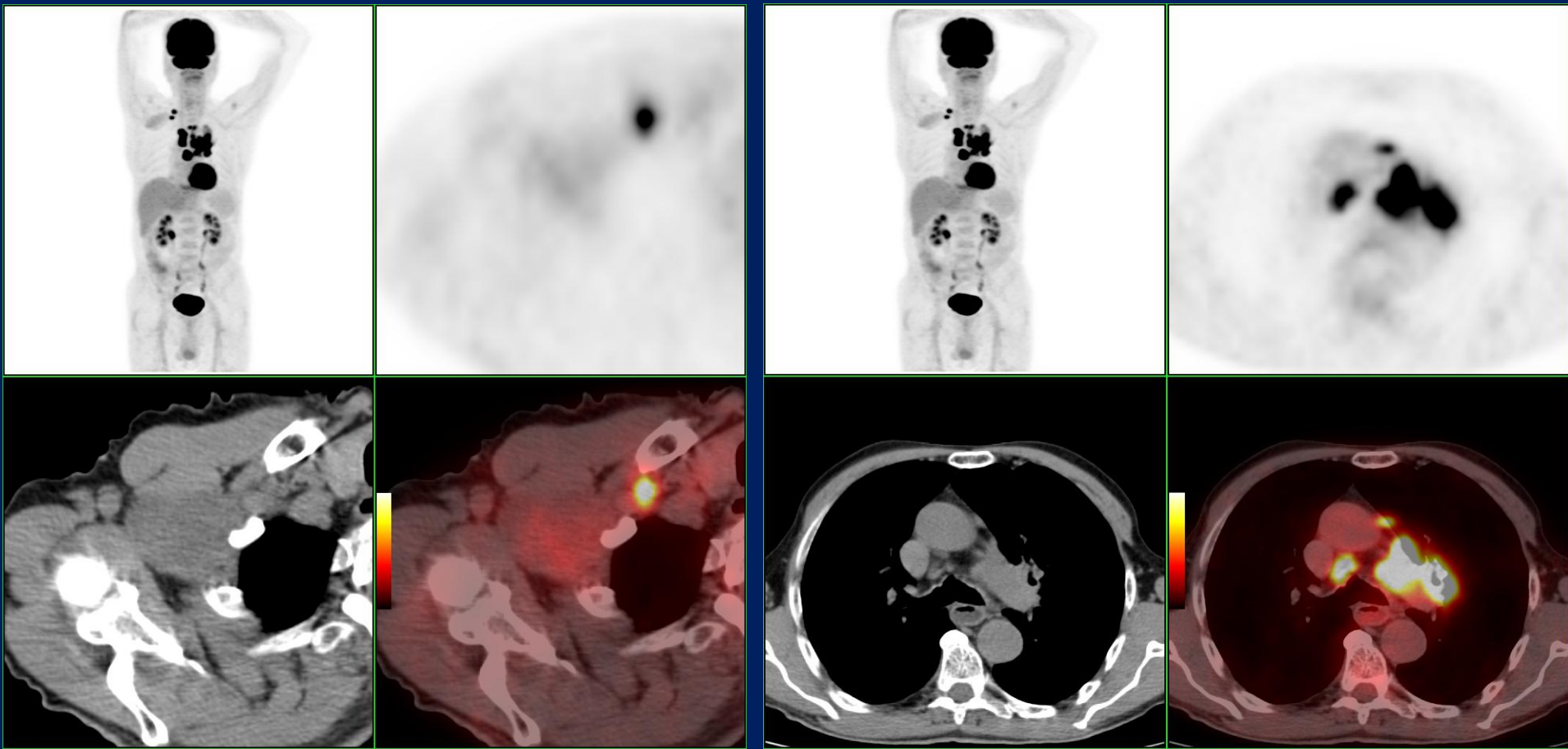


# Akciğer PET-BT tümör görüntüleme özel durumlar

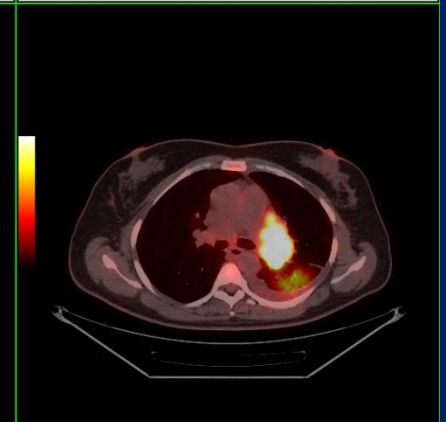
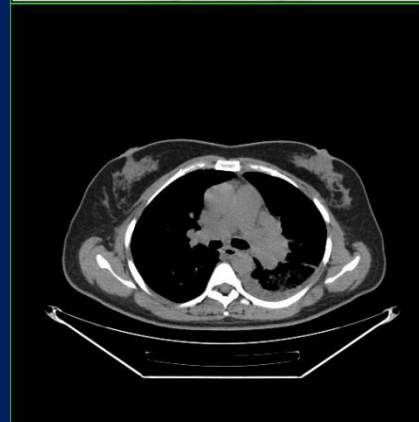
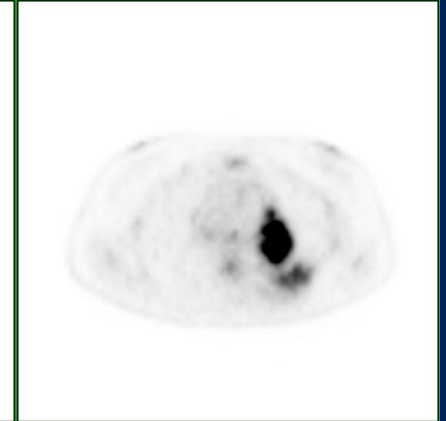
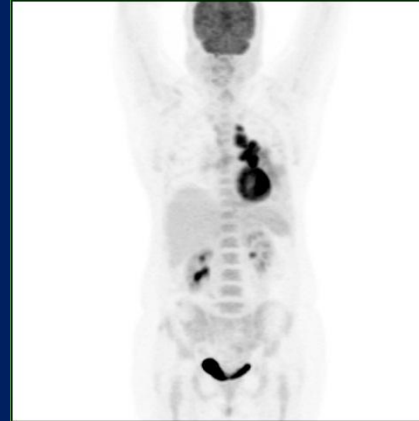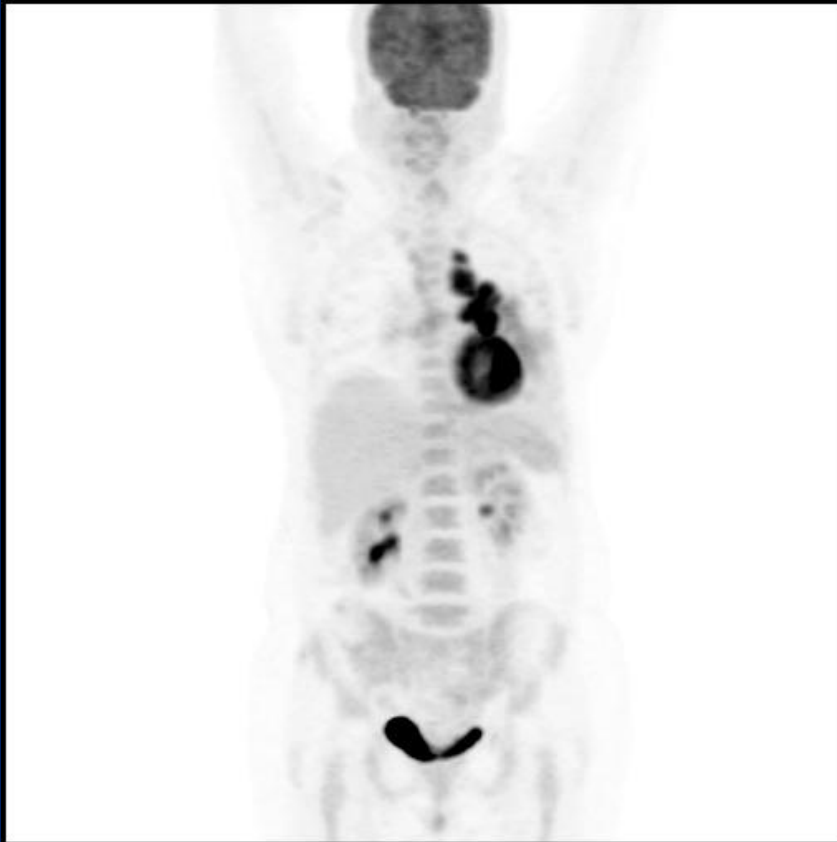# Karsinoid

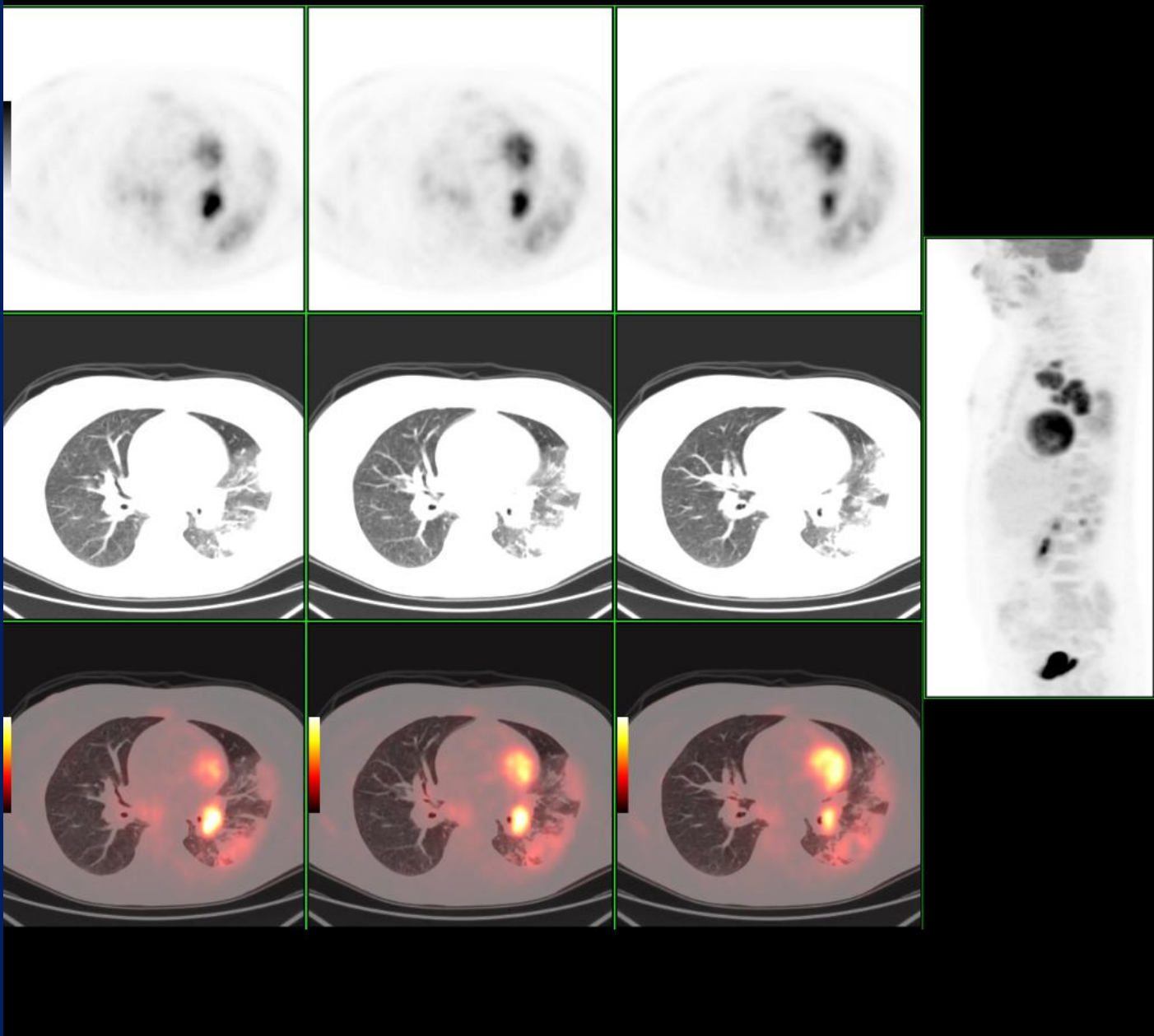


# Schwannom



# Post-obstruktif pnömoni





KHDAK'da PET-BT

# PET temel teknik özellikler

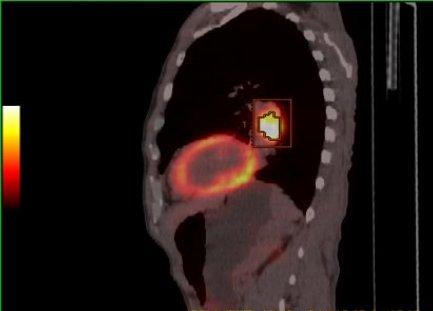
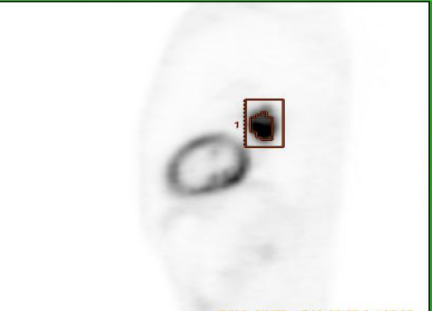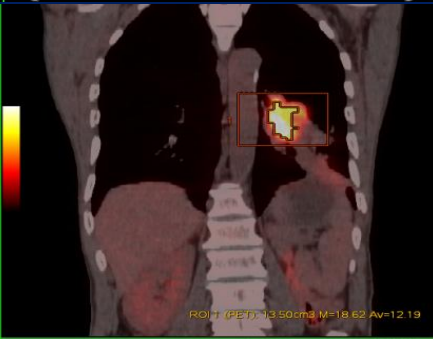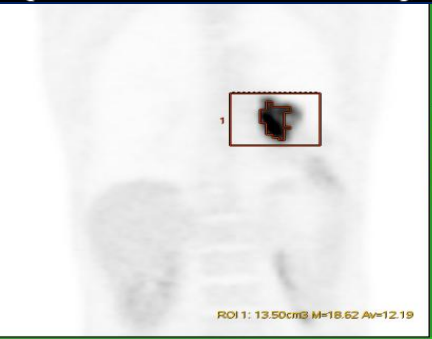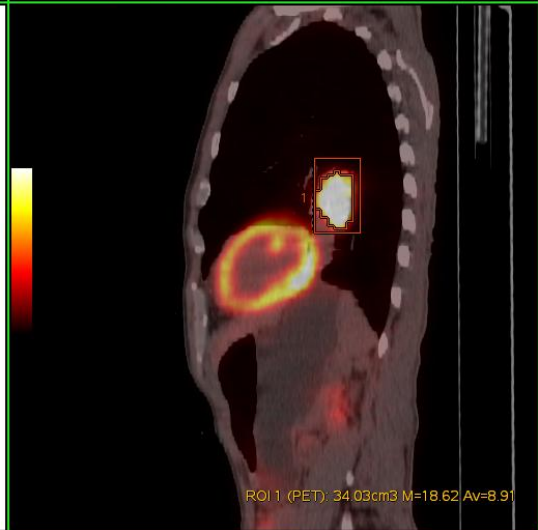
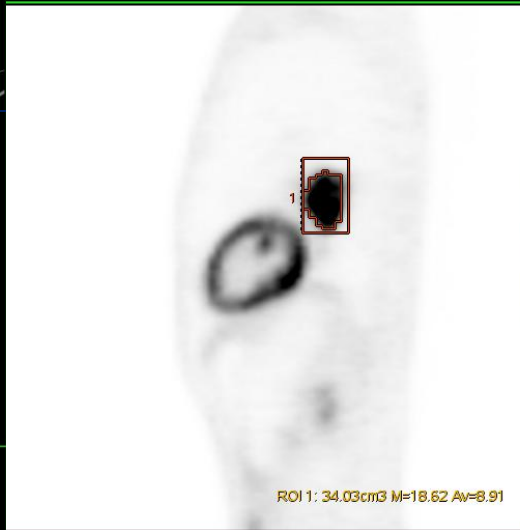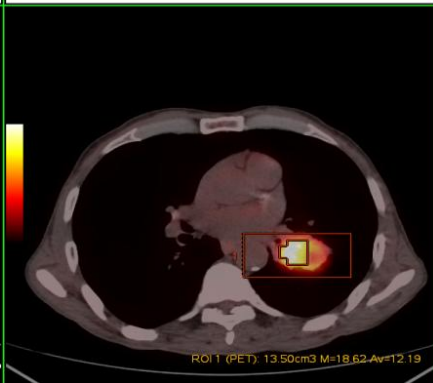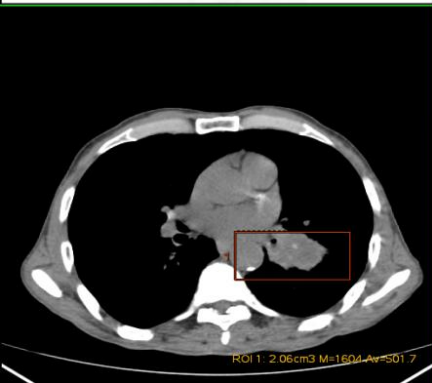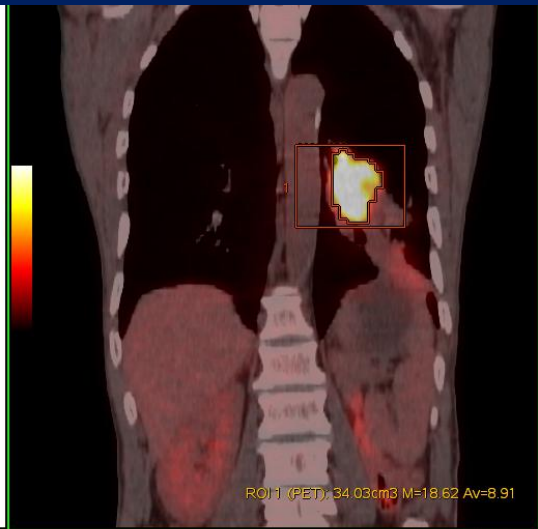
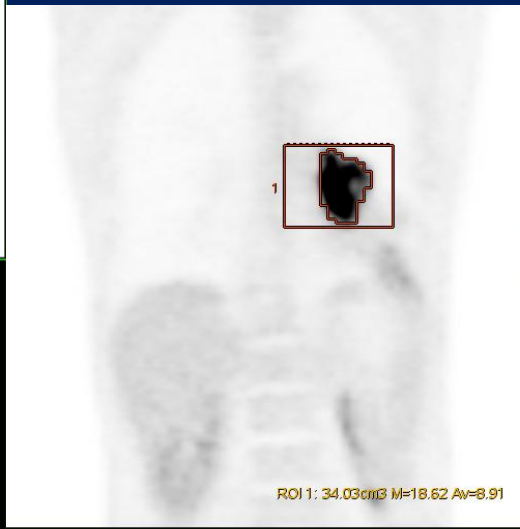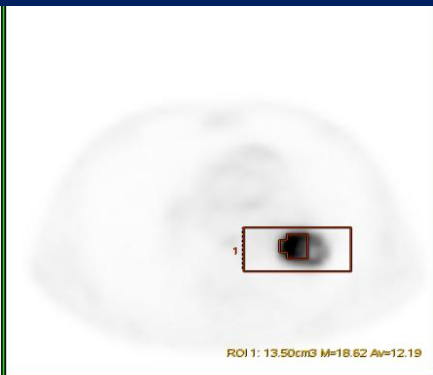
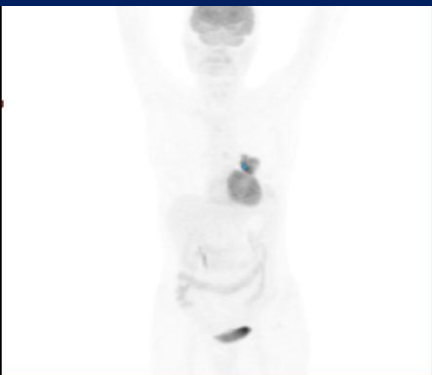
# SUV

Dekay düzeltmeli aktivite x vücut ağırlığı/ enjekte edilen aktivite

## Etkileyen faktörler

- Kan glukozu
- Enjeksiyon tekniği
- Çekim zamanı
- Rekonstrüksiyon tipi
- Atenüasyon düzeltmesi....
- Lezyon yapısı, boyutu
- Agresivitesi

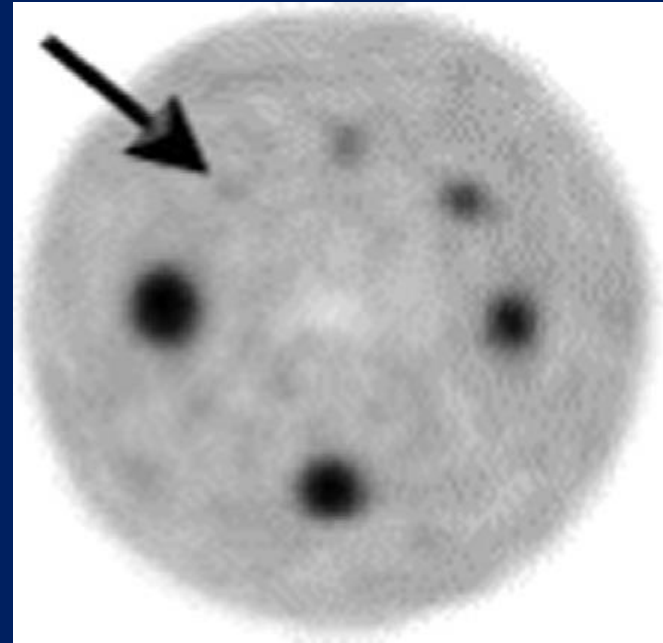




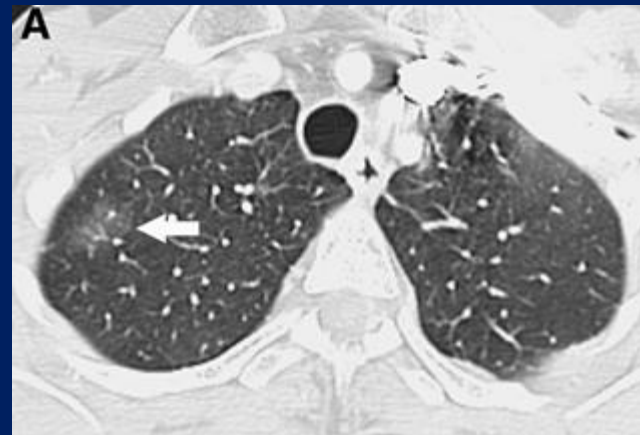
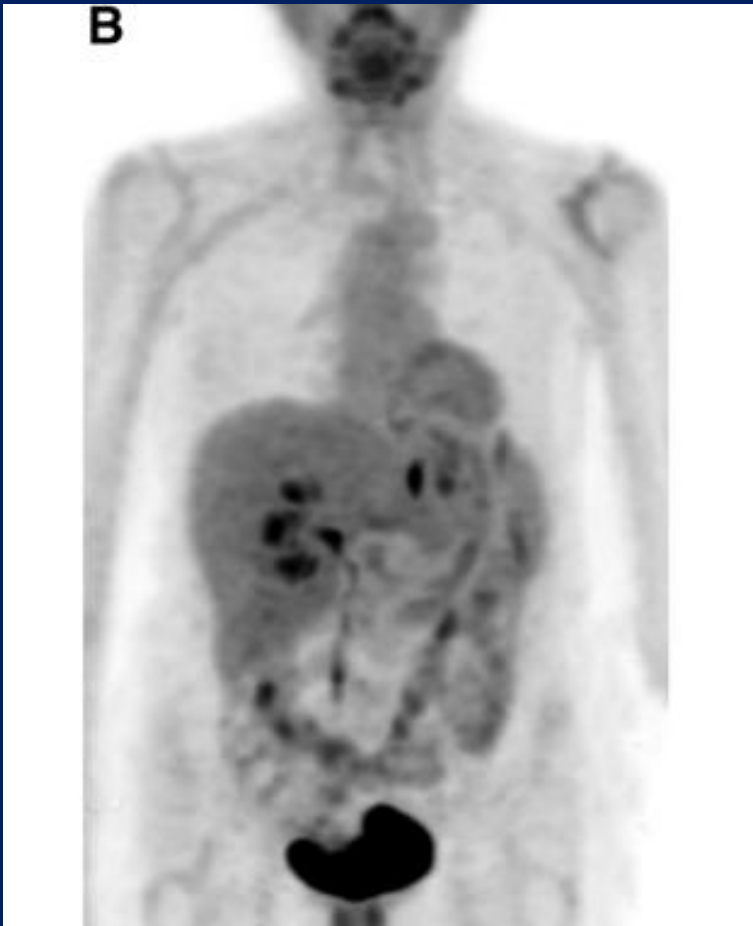
MTV, TLG

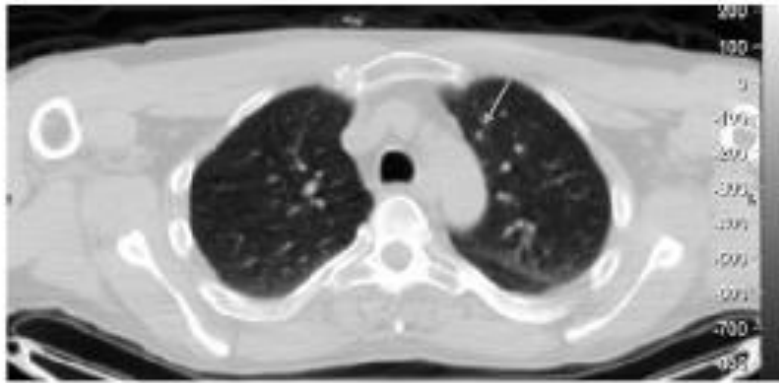
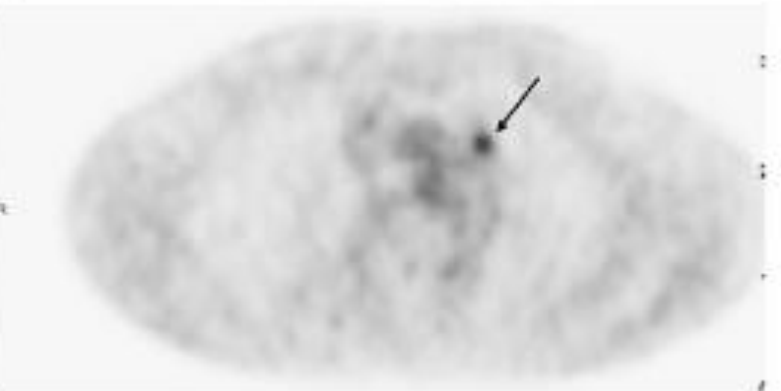
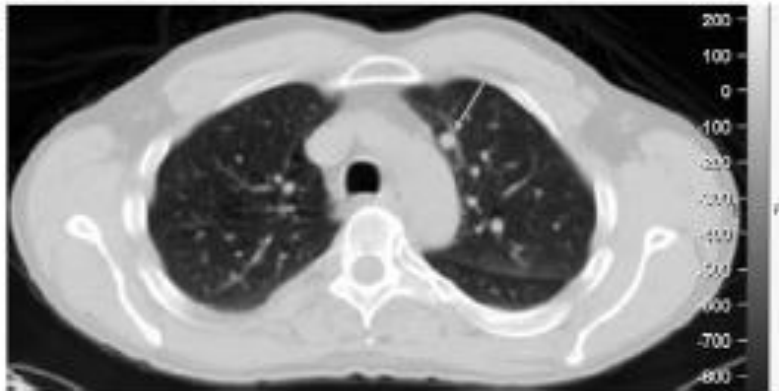
# Parsiyel hacim etkisi

- Fantom 6 küre  
(4, 3, 2.5, 2, 1.5 ve 1.25 cm çap),  
Küre [18F]-FDG aktivitesi : 15 kBq/ml  
Zemin aktivite: 1.8 kBq/ml,



# Adenokarsinoma in situ

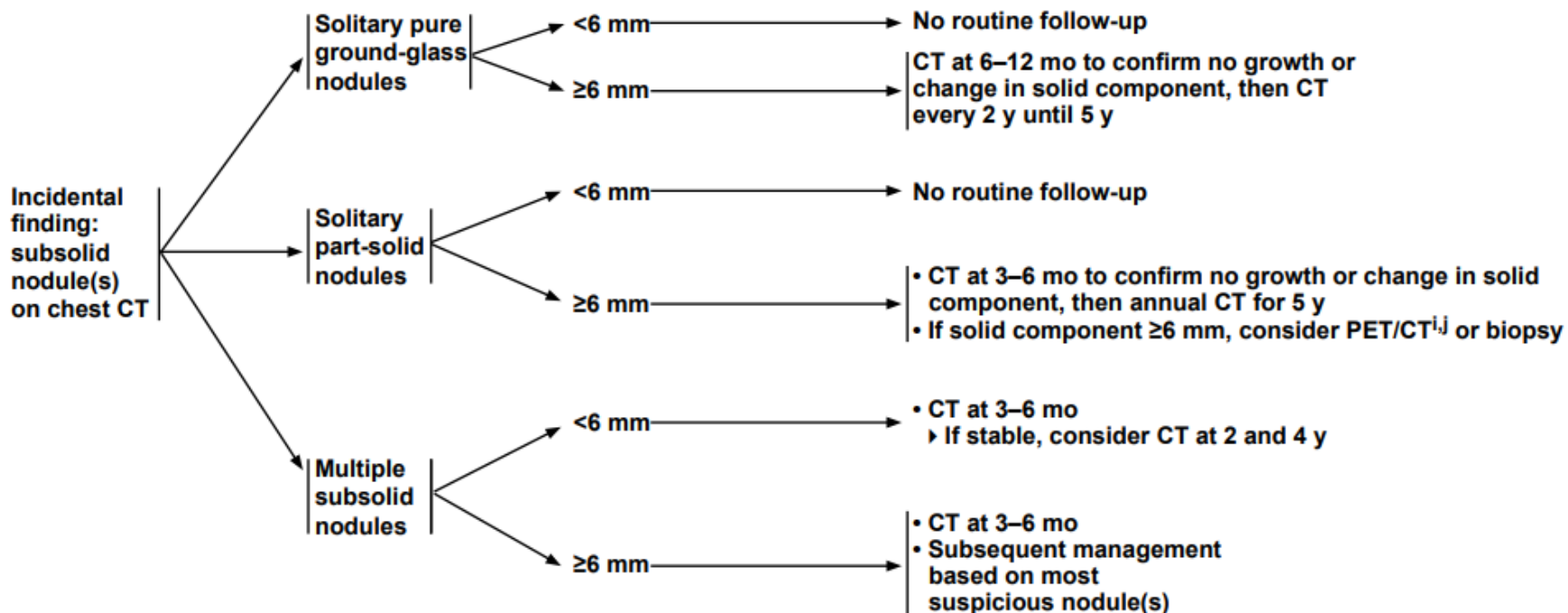


**A****B**



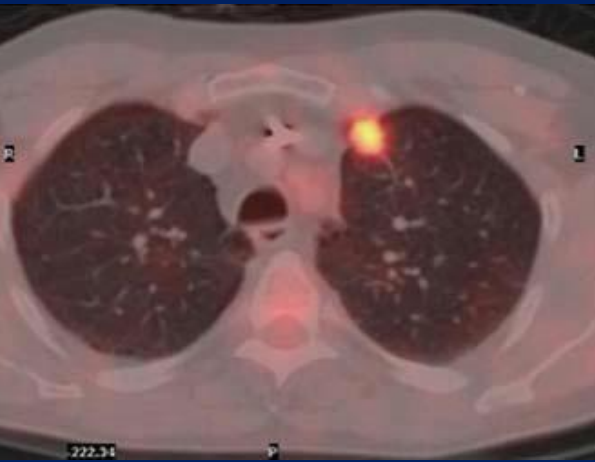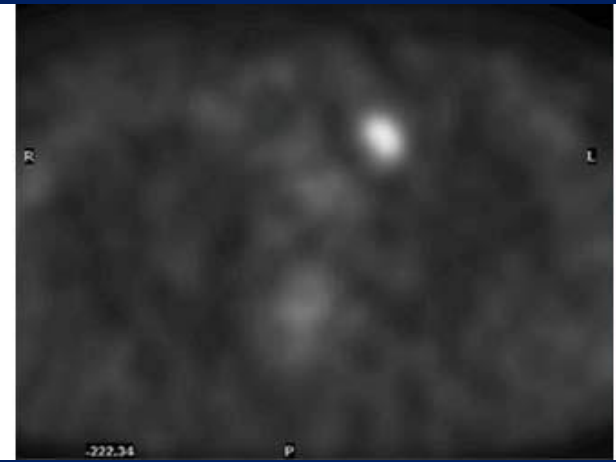
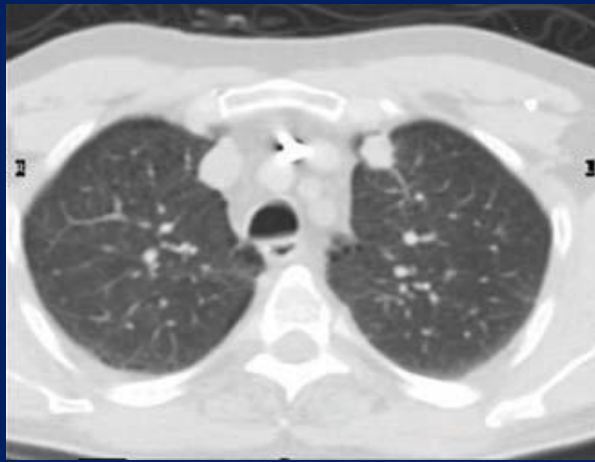
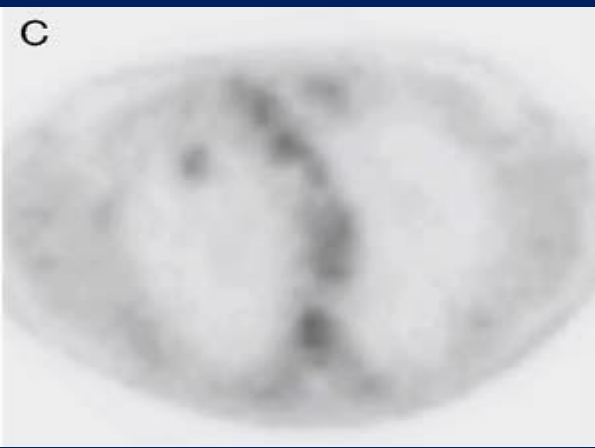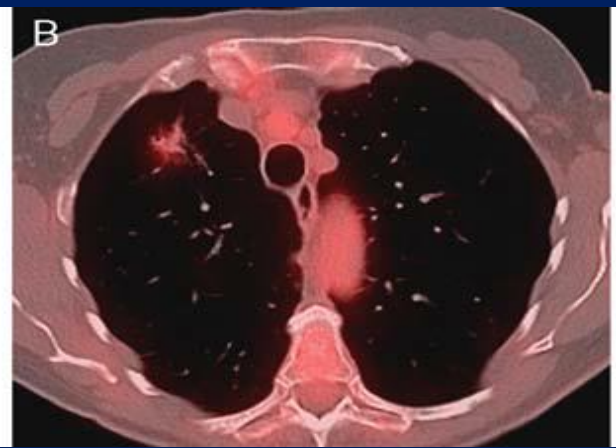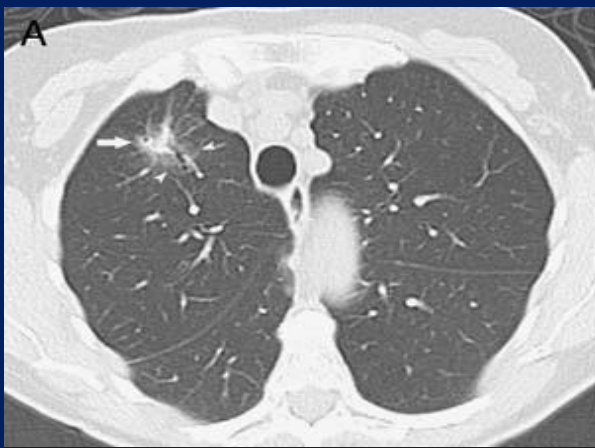
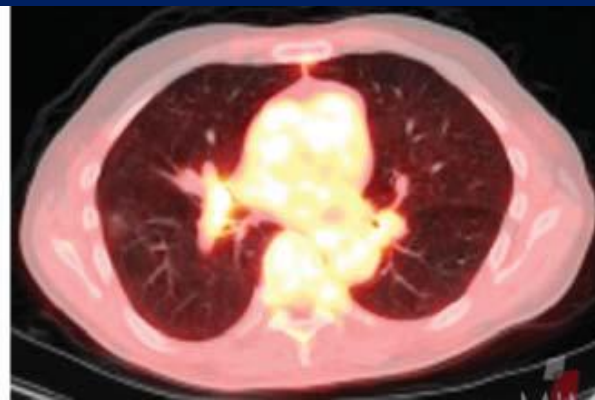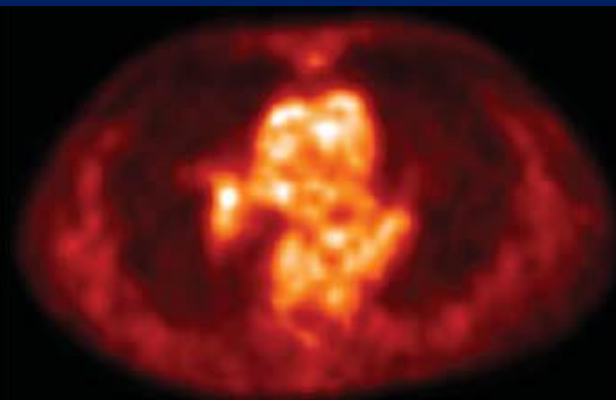
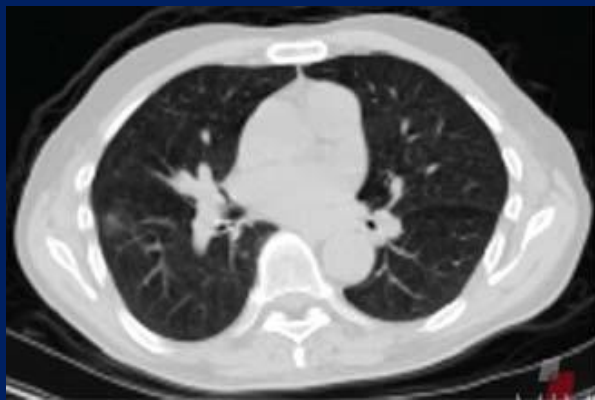
### FINDINGS

### FOLLOW-UP<sup>c,d,g,h</sup>



Subject of articles/ first author and year [ref.]	No. of articles/ modality	Total no. of patients	Study design	Important findings and results	Evidence level
PET(-CT) in SPN (pooled results)	14	1,847	3 prospective 11 retrospective	PET-CT can rule out malignancy in a solid SPN due to high sensitivity, and reduces need for biopsy if negative because of higher specificity than CT (recommendation level A)	
Fletcher 2008 [26]	PET	532	Prospective	Sensitivity PET vs. CT 92 % vs. 96 % Specificity PET vs. CT 82 % vs. 41 %	1b
Christensen 2006 [32]	PET	41	Retrospective	Sensitivity PET vs. CT 96 % vs. 100 % Specificity PET vs. CT 76 % vs. 29 %	2b
Harders SW 2012 [27]	PET-CT	168	Prospective	Sensitivity PET-CT vs. CT 97 % vs. 93–96 % Specificity PET-CT vs. CT 47 % vs. 34–53 %	1b
Kagna 2009 [33]	PET-CT	307	Retrospective	Sensitivity PET-CT vs. CT 94 % vs. 97 % Specificity PET-CT vs. CT 70 % vs. 48 %	2b
Jeong 2006 [38]	PET-CT	100	Retrospective	Sensitivity PET-CT vs. CT 88 % vs. 82 % Specificity PET-CT vs. CT 77 % vs. 66 %	2b
Kim 2007 [37]	PET-CT	42	Retrospective	Sensitivity PET-CT vs. CT 97 % vs. 93 % Specificity PET-CT vs. CT 85 % vs. 31 %	2b
Yi 2006 [29]	PET-CT	119	Retrospective	Sensitivity PET-CT vs. CT 96 % vs. 81 % Specificity PET-CT vs. CT 88 % vs. 93 %	2b
Bar-Shalom 2008 [36]	PET-CT	56	Retrospective	Sensitivity PET-CT 96 % Specificity PET-CT 83 %	2b
Nomori 2004 [28]	PET	131	Prospective	Sensitivity PET solid SPN > 1 cm 90 % Specificity PET solid SPN > 1 cm 71 % Sensitivity PET GGO > 1 cm 10 % Specificity PET GGO > 1 cm 20 %	1b

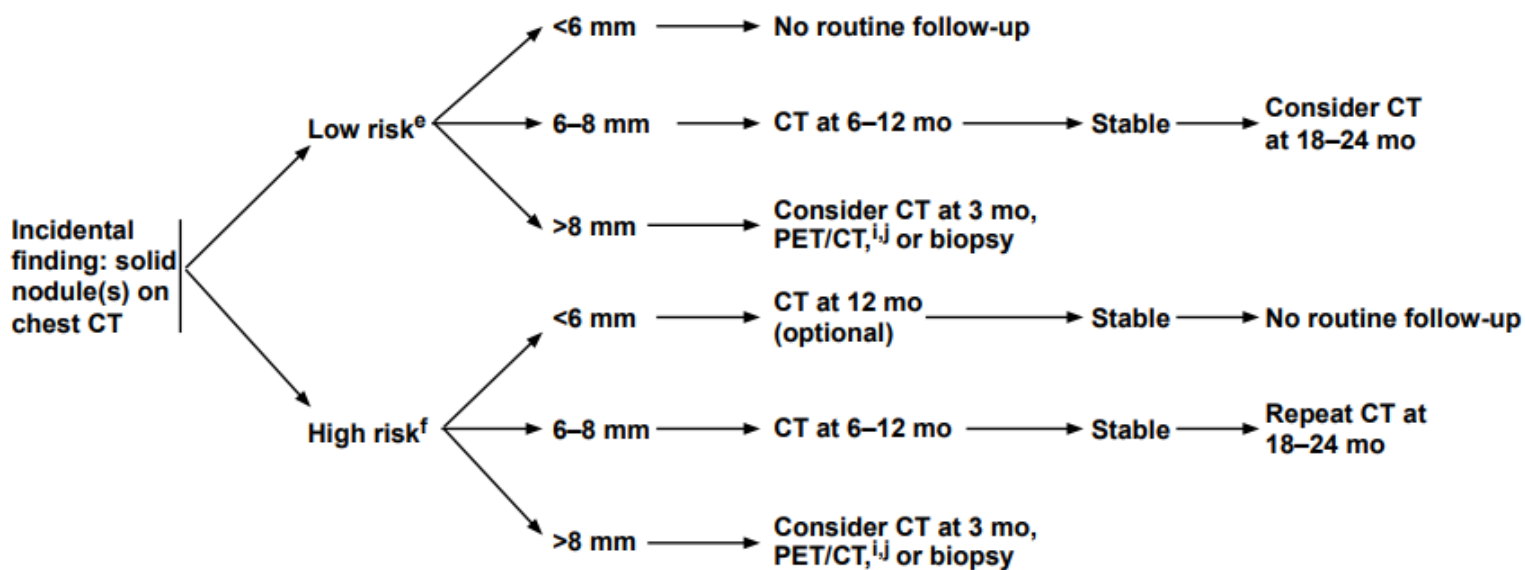
Herder 2004 [35]	PET	35	Retrospective	Sensitivity SPN PET ≤ 1 cm 93 % Specificity SPN PET ≤ 1 cm 77 %	2b
Dewan 1995 [39]	PET	33	Retrospective	Sensitivity PET 100 % Specificity PET 78 %	2b
Heynemann 2002 [30]	PET	15	Retrospective	Sensitivity PET 38 %	2b
Yap 2002 [31]	PET	41	Retrospective	Sensitivity of PET depends on BAC-component. In pure BAC, sensitivity of PET was 33 %	2b
Daniels 2007 [34]	PET	16	Retrospective	Sensitivity PET 75 %	2b





### FINDINGS

### FOLLOW-UP<sup>c,d,g,h</sup>



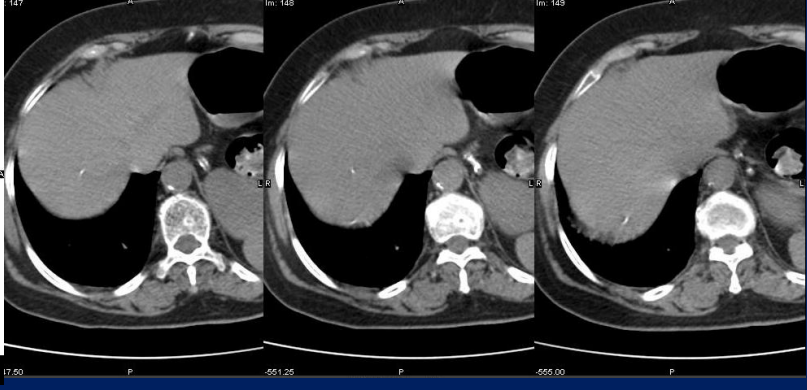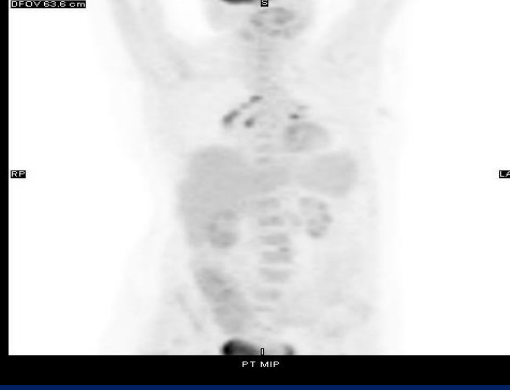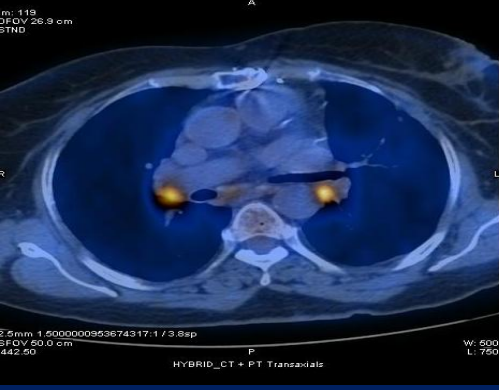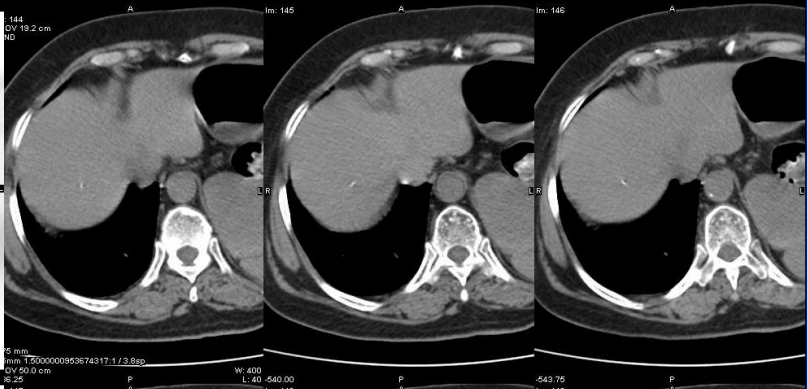
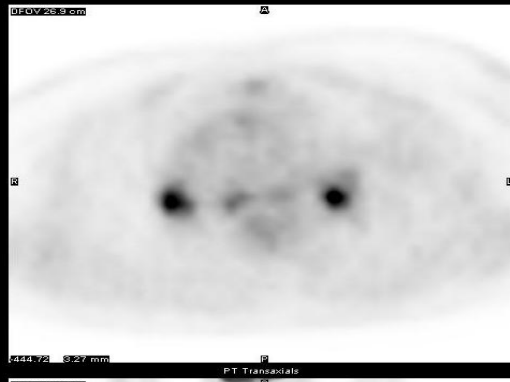


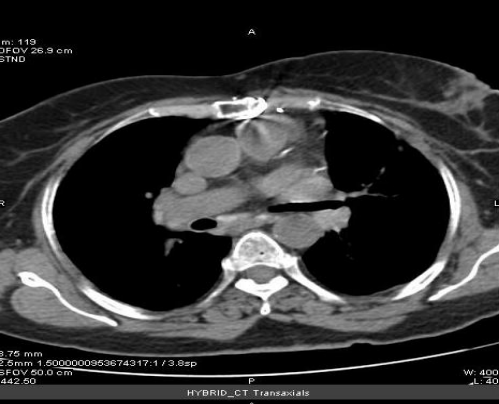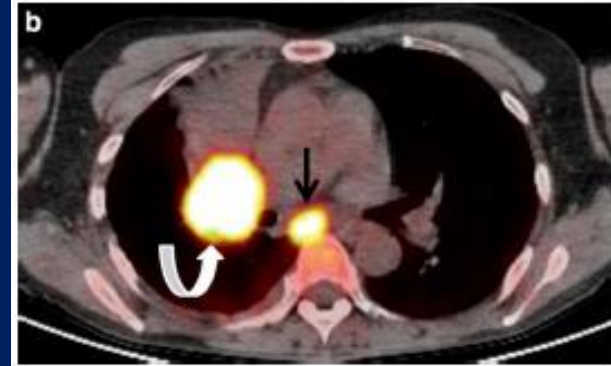
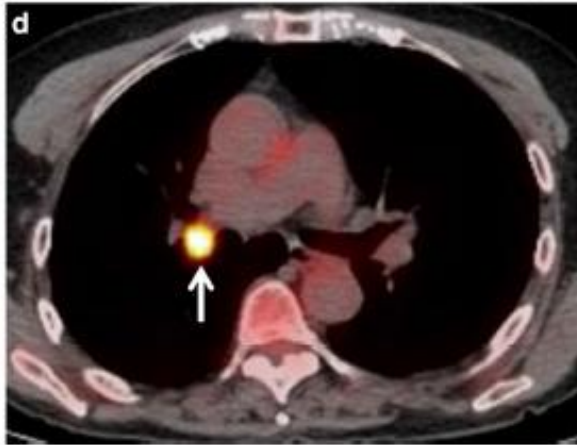
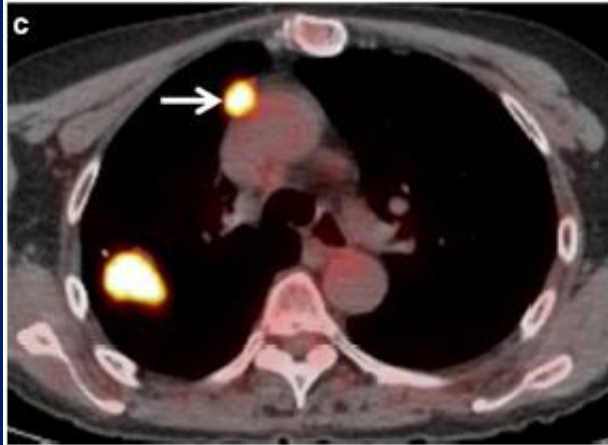
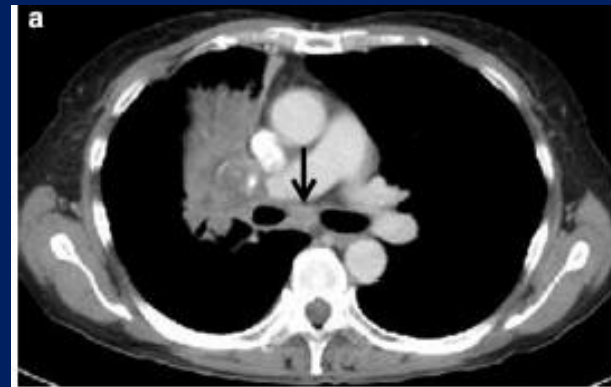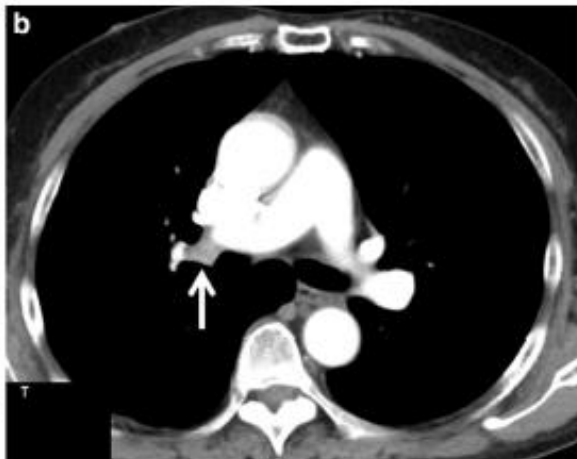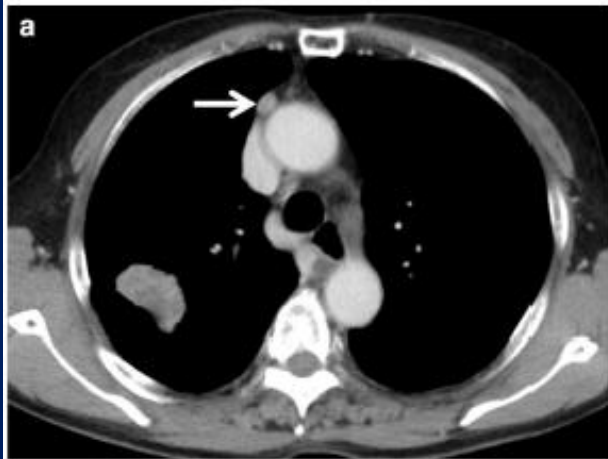
# Mediastinal evreleme

- Hassasiyet: %61-85 Özgüllük : %79-90
- BT'de lenf nodu büyümüşse hassasiyet: %100 Özgüllük : %78
- BT'de küçük lenf nodu: Hassasiyet: %82 ve özgüllük %93

# Benign kriterler

- Bilateral hiler, milimetrik LN
- Primer tümörden yüksek tutulum
- BT'de kalsifikasyon, hiperdens lenf nodları
- Karaciğer ve dalakta kalsifikasyon
- SUV: <2.5





# Mikroskopik hastalık

- Mikroskopik N2 hastalıkta hassasiyet: %61 ve NÖD: %87

## Risk faktörü

- Adenokarsinom
- Üst ve orta lobdaki tümörler
- Büyük >3 cm, SUV >4
- Santral tümör
- N1 pozitif tümör

(CeCT ve PET-CT olarak N0 ise EUS ve Mediastinoskopi ile N2 oranı %2,9 ve 3,7 CeCT ve PET-CT olarak N1 ise %17,6 ve 23,5 )

CLINICAL ASSESSMENT    PRETREATMENT EVALUATION<sup>g</sup>

Stage IA  
(peripheral T1abc, N0)

- PFTs (if not previously done)
- Bronchoscopy (intraoperative preferred)
- Consider pathologic mediastinal lymph node evaluation<sup>h,i</sup>
- FDG PET/CT scan<sup>j</sup> (if not previously done)

Negative mediastinal nodes

Positive mediastinal nodes

Operable

Medically inoperable<sup>l</sup>

Surgical exploration and resection<sup>l</sup> + mediastinal lymph node dissection or systematic lymph node sampling

Definitive RT including stereotactic ablative radiotherapy (SABR)<sup>m,n</sup>

See Stage IIIA/IIIB (NSCL-7) or Stage IIIB/IIIC (NSCL-11)

See Adjuvant Treatment (NSCL-3)

Stage IB (peripheral T2a, N0)  
Stage I (central T1abc-T2a, N0)  
Stage II (T1abc-2ab, N1; T2b, N0)  
Stage IIB (T3, N0)<sup>e</sup>  
Stage IIIA (T3, N1)

- PFTs (if not previously done)
- Bronchoscopy
- Pathologic mediastinal lymph node evaluation<sup>h</sup>
- FDG PET/CT scan<sup>j</sup> (if not previously done)
- Brain MRI with contrast<sup>k</sup> (Stage II, IIIA) (Stage IB [optional])

Negative mediastinal nodes

Positive mediastinal nodes

Operable

Medically inoperable<sup>l</sup>

Surgical exploration and resection<sup>l,o</sup> + mediastinal lymph node dissection or systematic lymph node sampling

Definitive RT including SABR<sup>m</sup>

Definitive chemoradiation<sup>m,r</sup>

See Stage IIIA/IIIB (NSCL-7) or Stage IIIB/IIIC (NSCL-11)

Consider adjuvant chemotherapy<sup>p</sup> (category 2B) for high-risk stages IB-IIB<sup>q</sup>

Durvalumab<sup>r</sup> (category 1)

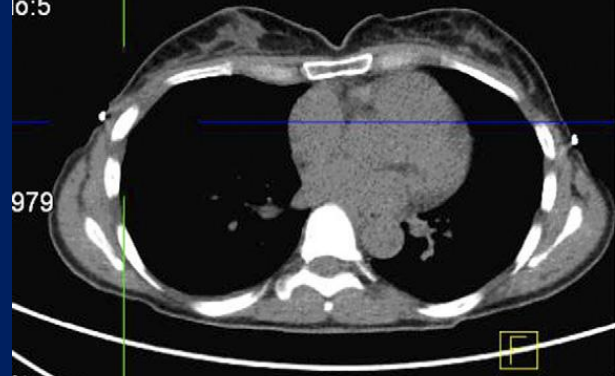See Adjuvant Treatment (NSCL-3)

# Uzak metastaz

## KHDAK

- Evre 1: %7.5
- Evre 2: %18
- Evre 3: %24
  
- M1 metastazını saptamada FDG PET hassasiyeti, özgüllüğü, PÖD ve NÖD %83, %90, %36, ve %99'dur
- KS'den üstün ve adrenal met değerlendirilmede doğruluk >%90

Dt:  
Tm:  
lo:5



21  
Image No. 96,97  
SP F433.7  
SL: 3.000

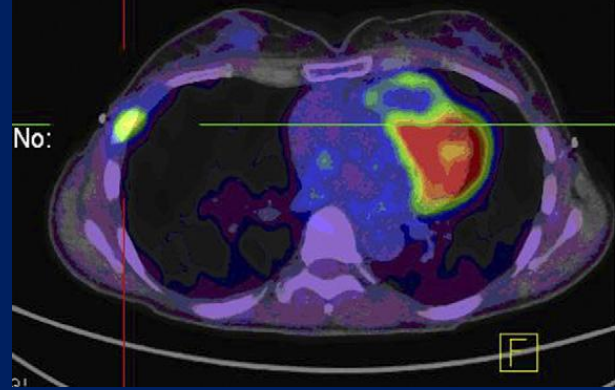
VW 300  
C 40

91104966  
7/0/1954  
7/08/2009  
15:20 AM

PMCC  
Biograph 64  
syngo CT 2006A

USED MPR  
urrent

No:



21

MPR  
PT AC  
Current

Rt

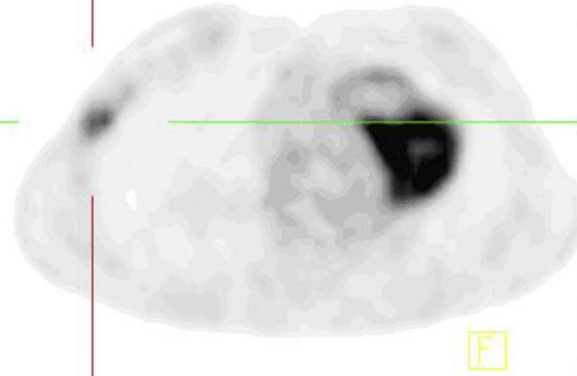
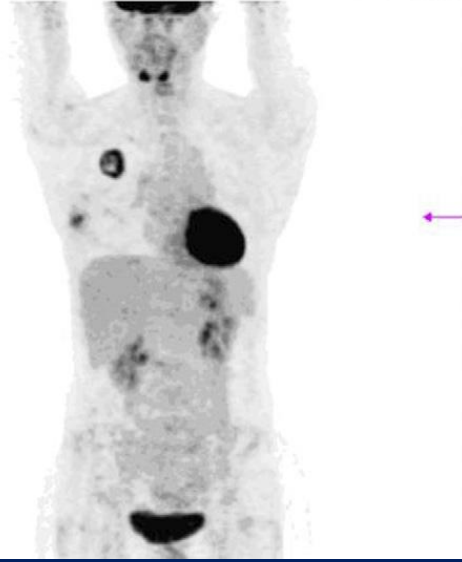


Image No. 96,97  
SP F433.7  
SL: 3.000

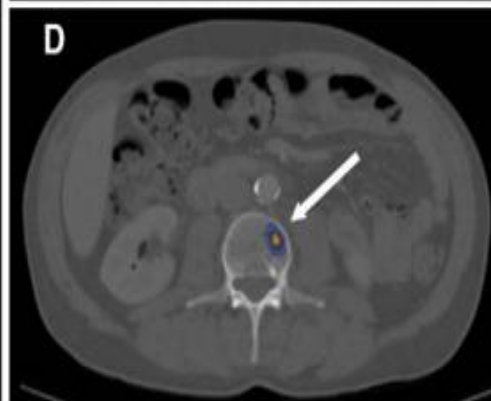
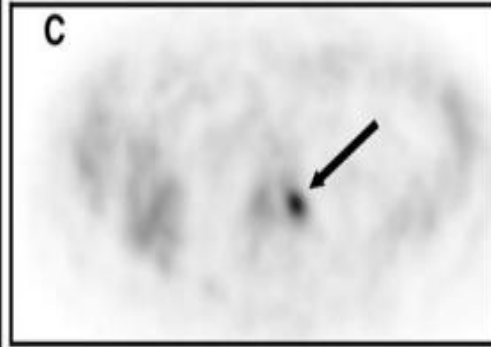
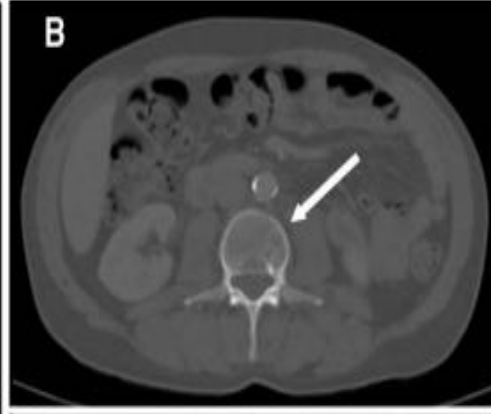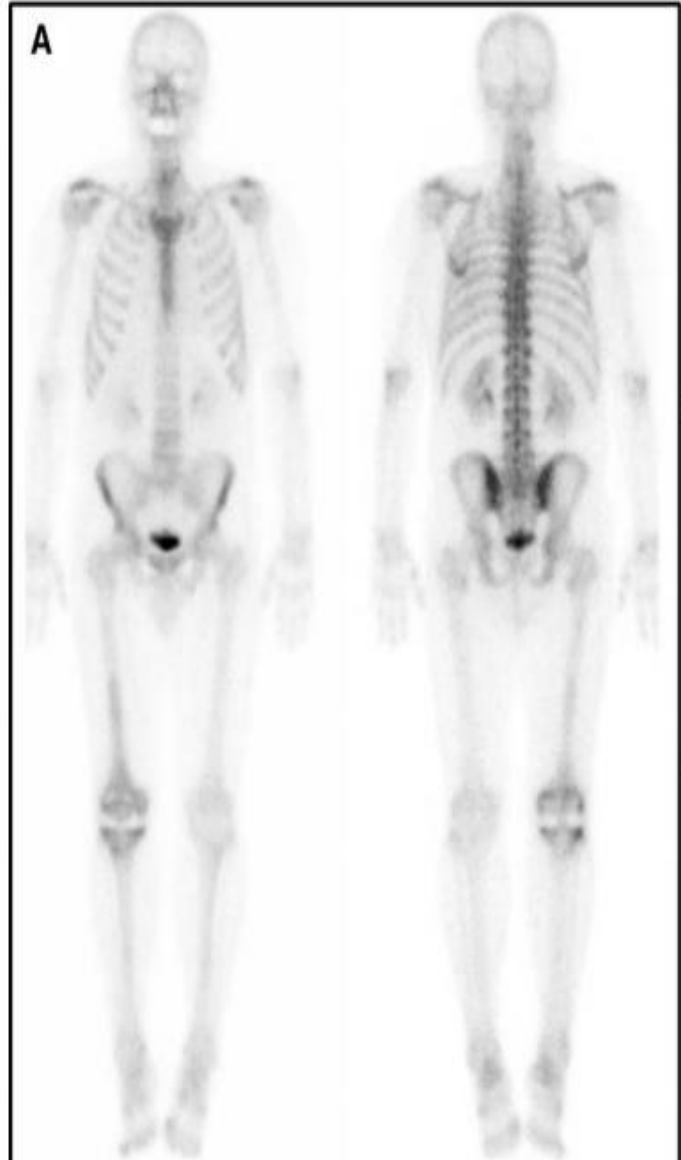
T 7.53 SUV bw  
B 0.00 SUV bw

1

AC\_CT



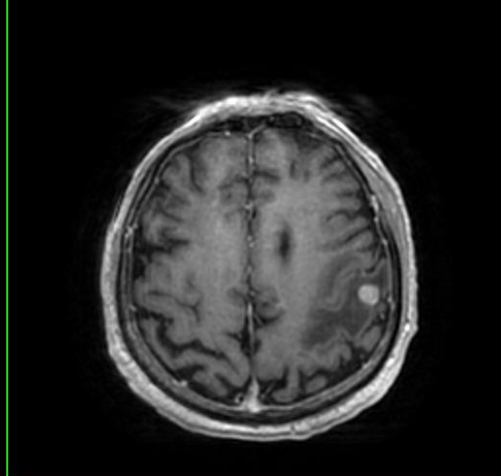
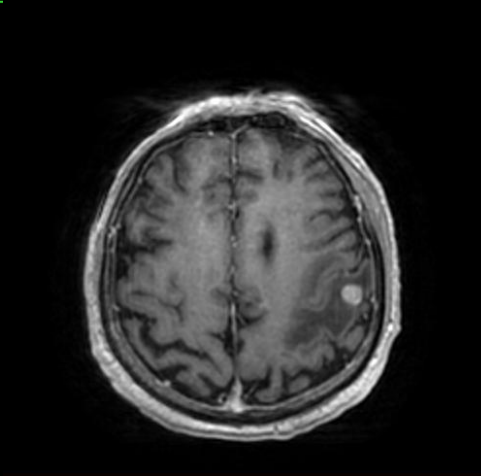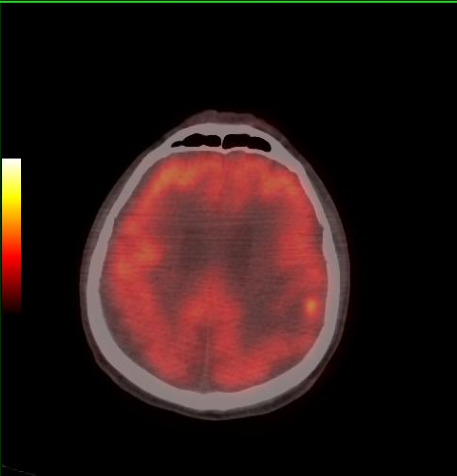
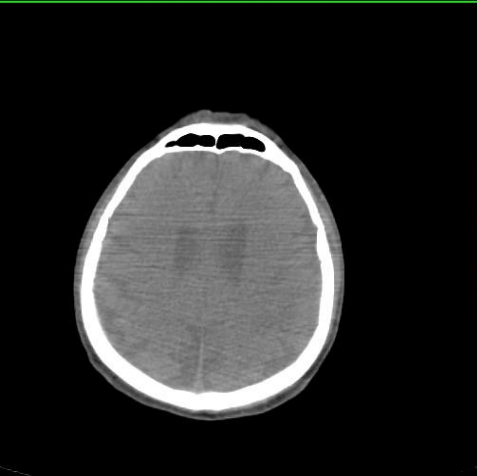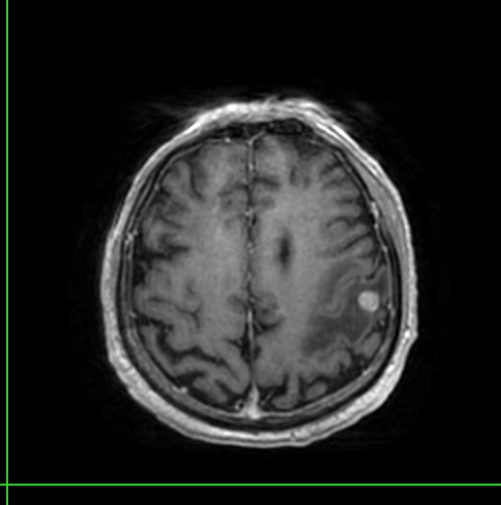
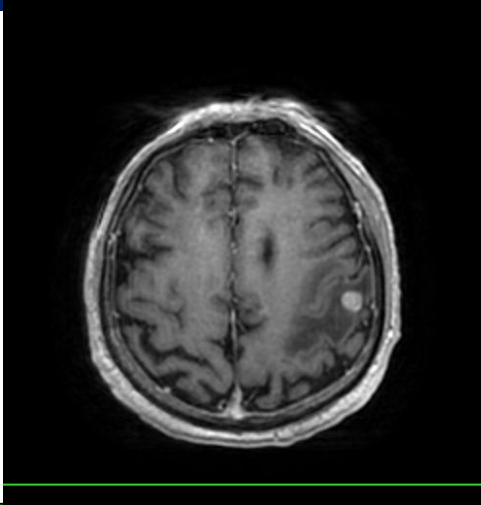
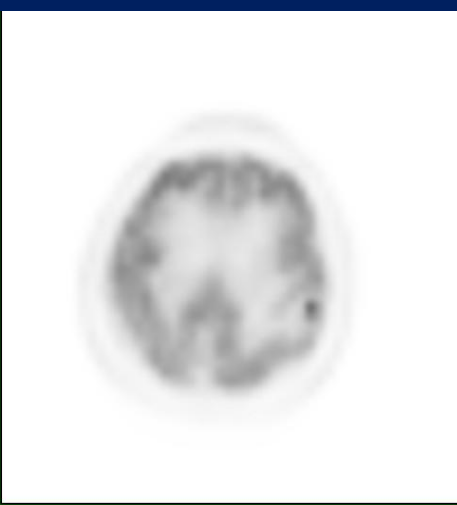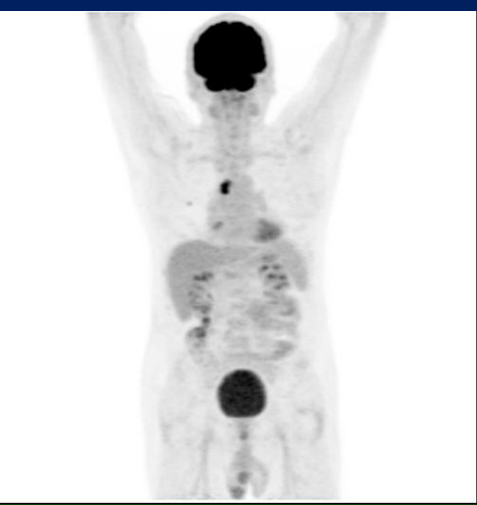


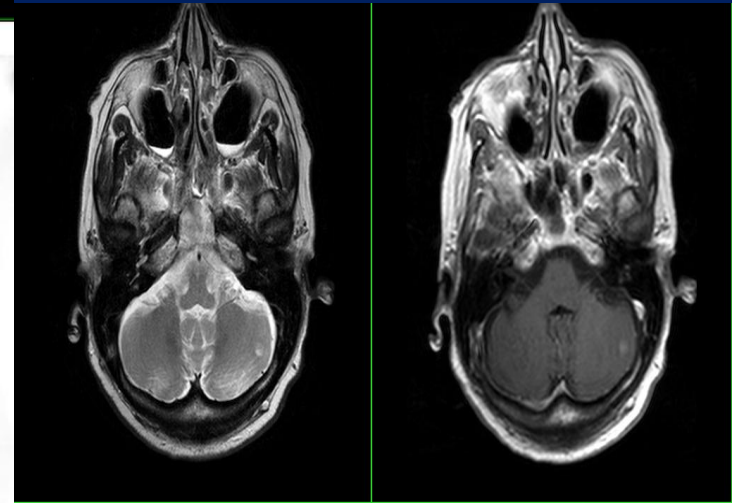
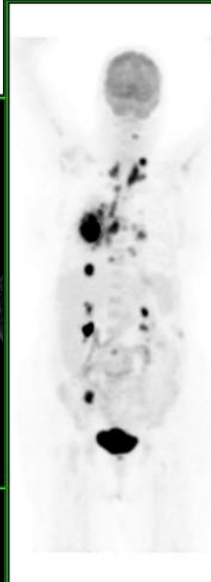
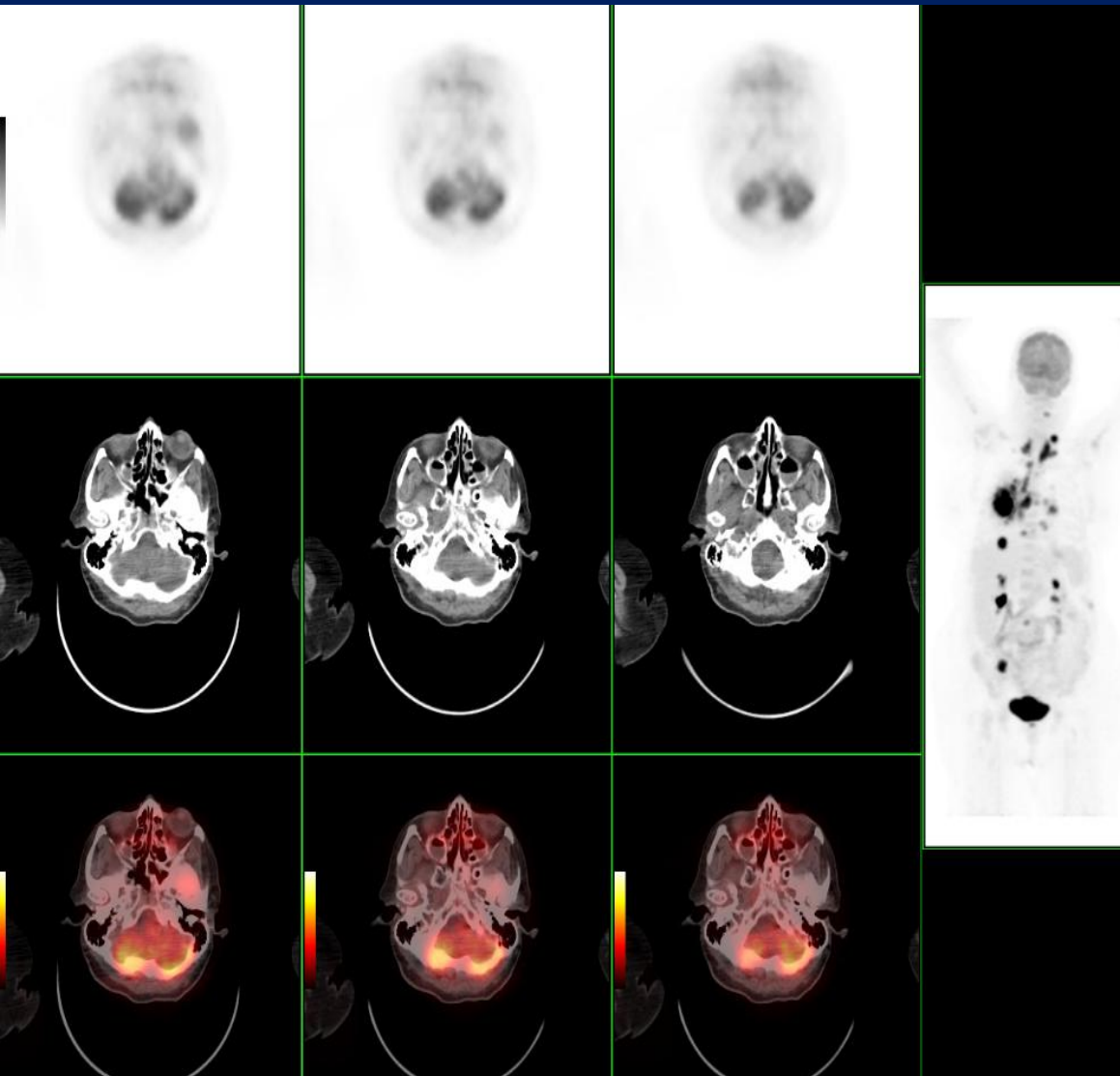


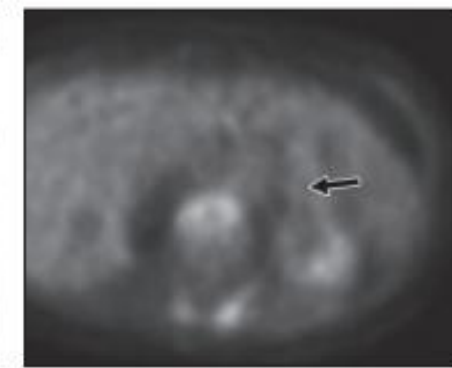
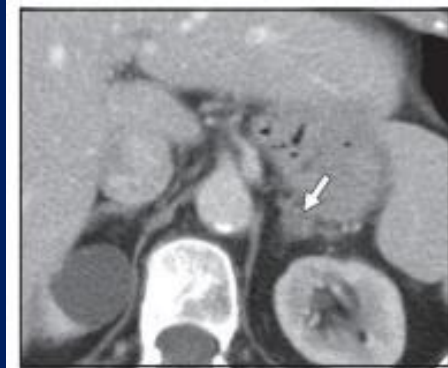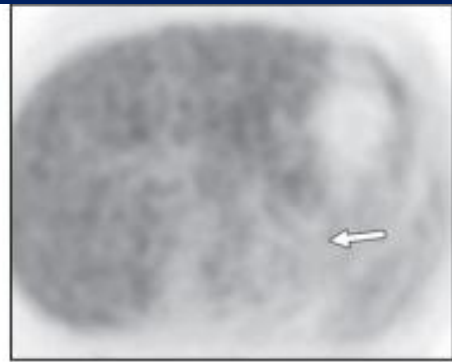
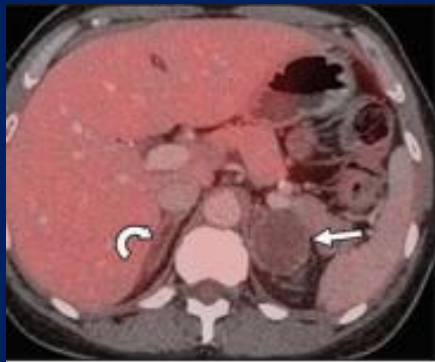Hassasiyet ve özgüllük

FDG PET/CT: %93 ve %95

KS: %87 ve %82

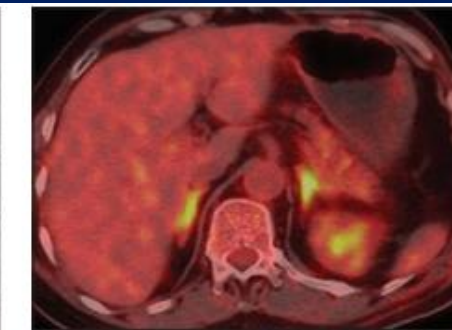
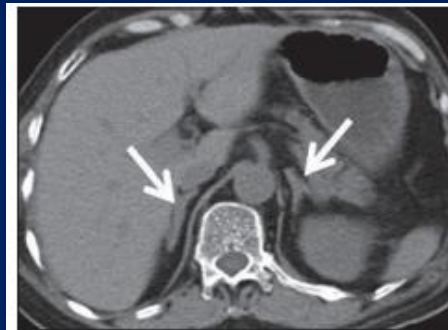






A

B

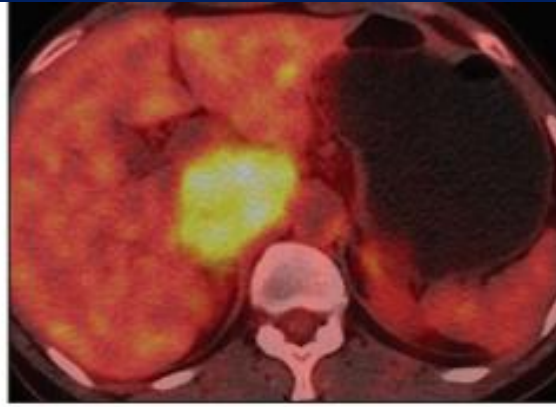
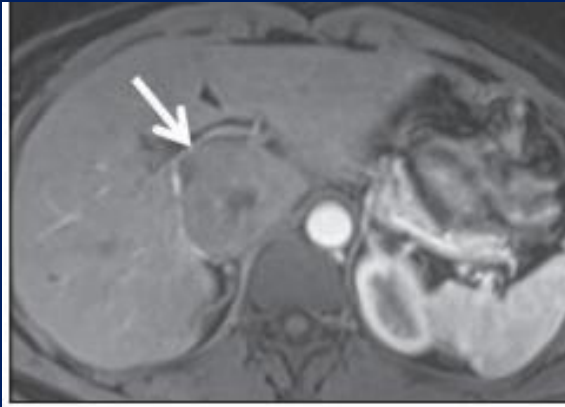


A

B

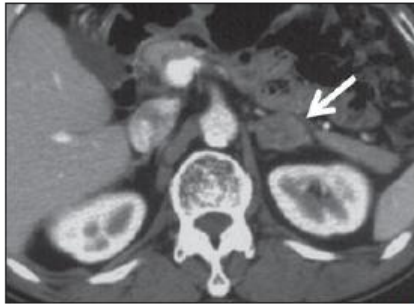
**TABLE 3**  
Size, Density (HU), and SUV for All Masses and for Benign and Malignant Masses Separately

Lesion type	Parameter	Size (cm)	HU	SUV
Total (n = 175)	Mean	2.44	16	5
	SD	1.55	20.56	5.48
	Minimum	0.6	-93.0	.3
	Maximum	11.0	50.0	26.2
Benign (n = 107)	Mean	2.02	4.06	1.78
	SD	0.80	17.23	.91
	Minimum	0.7	-93.0	.3
	Maximum	4.6	38.0	6.4
Malignant (n = 68)	Mean	3.11	34.73	10.13
	SD	2.13	6.64	5.74
	Minimum	0.6	19.0	1.1
	Maximum	11.0	50.0	26.2

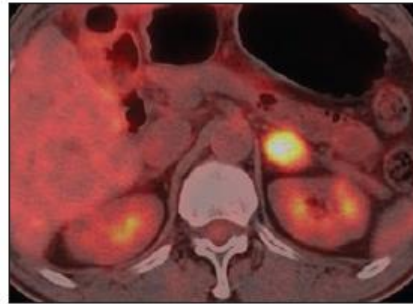


Feokromositoma

HCC met

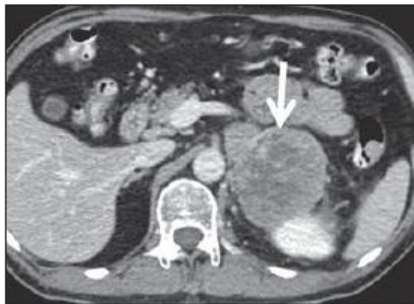


A

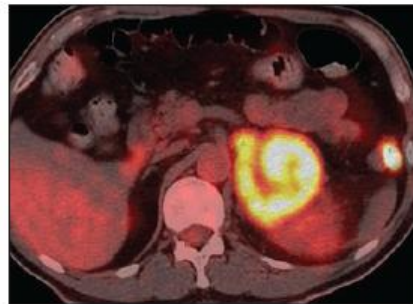


B

KHDAK met



A

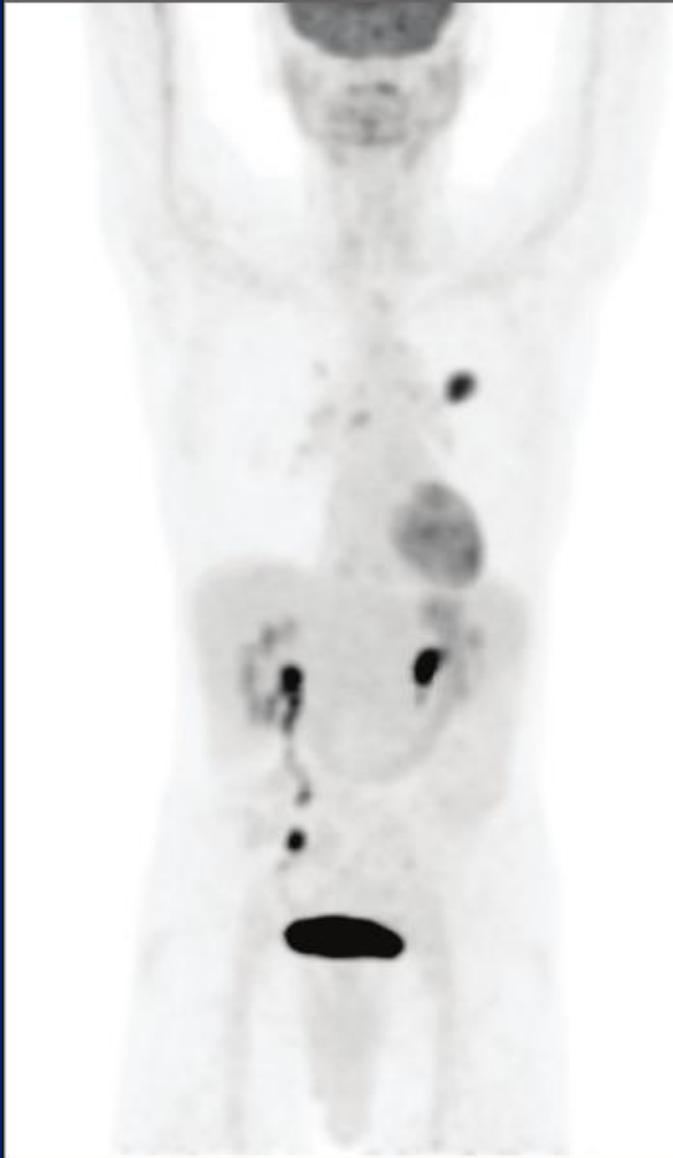


B

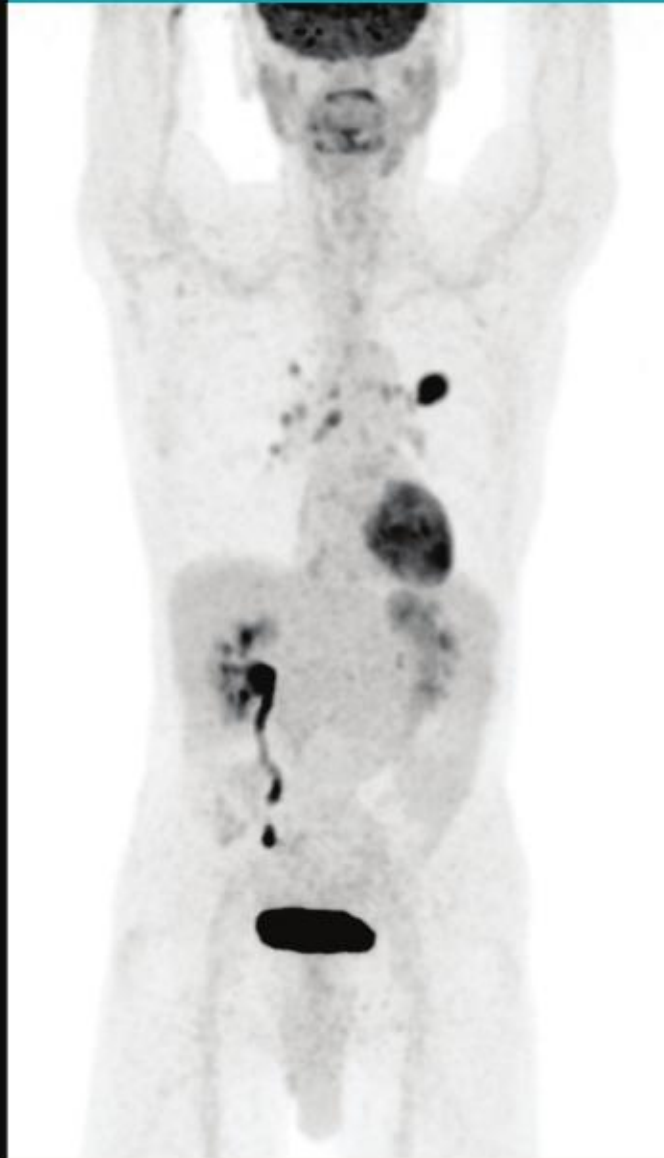
Diğer TBC, lymphoma

Gelecek

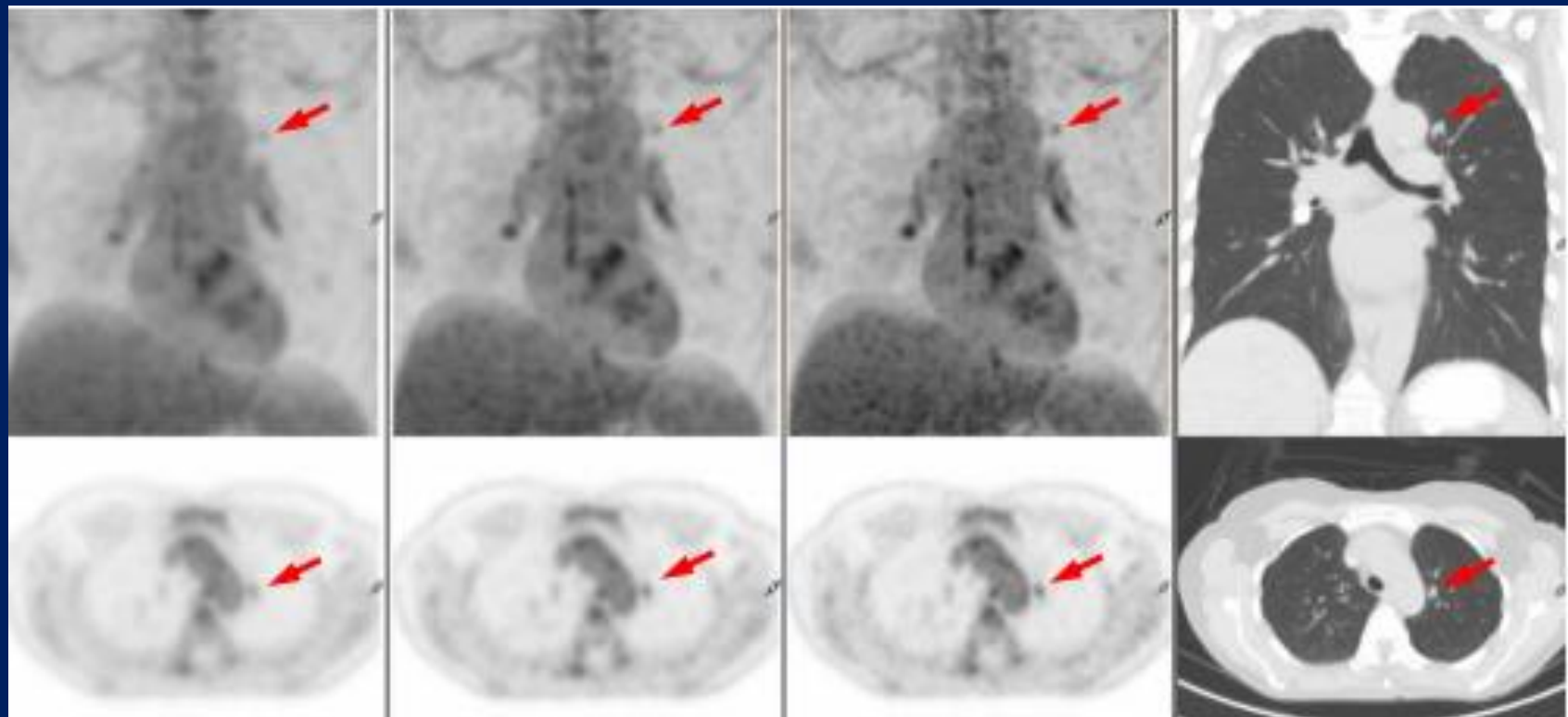
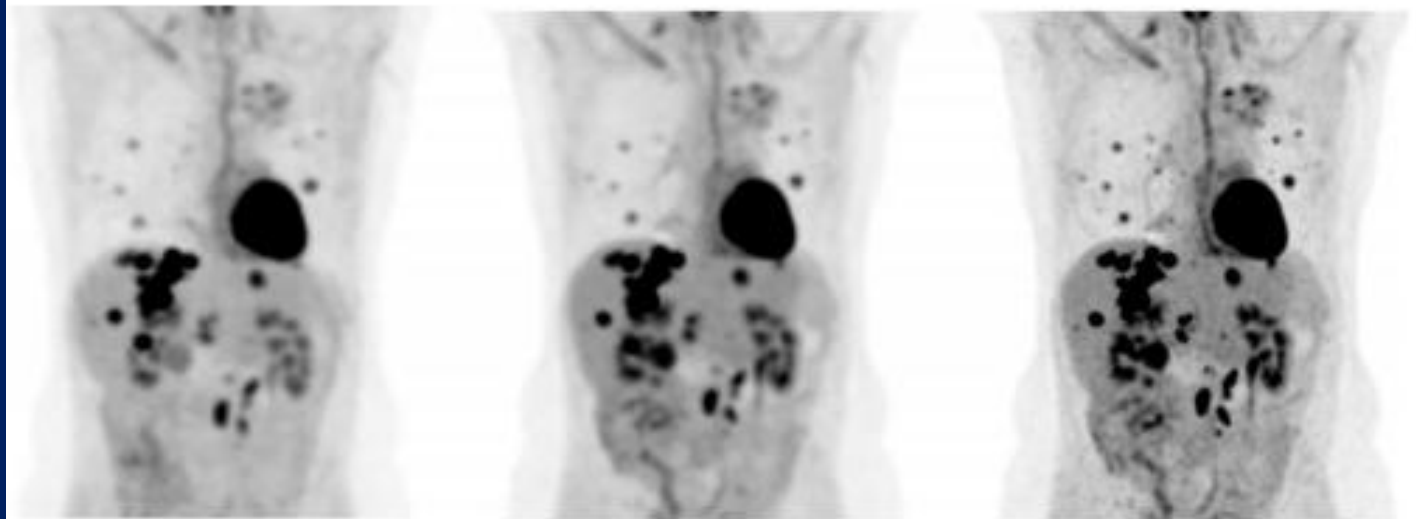
Analog PET Scan\*



Vereos Digital PET Scan

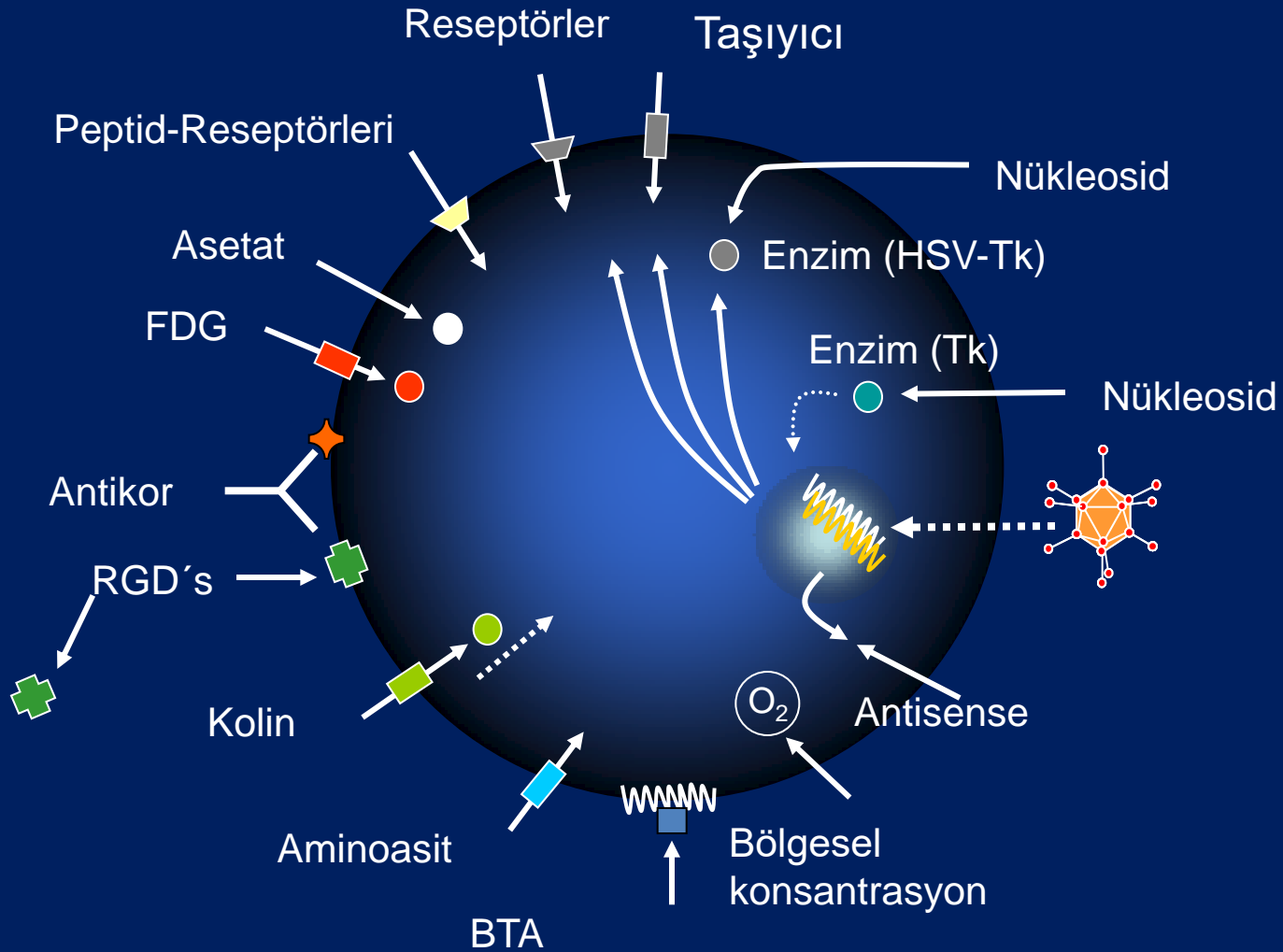


Vereos sensitivity gain  
Up to ~ 2x greater.

**a****b****c**



# PET radyofarmasötikleri



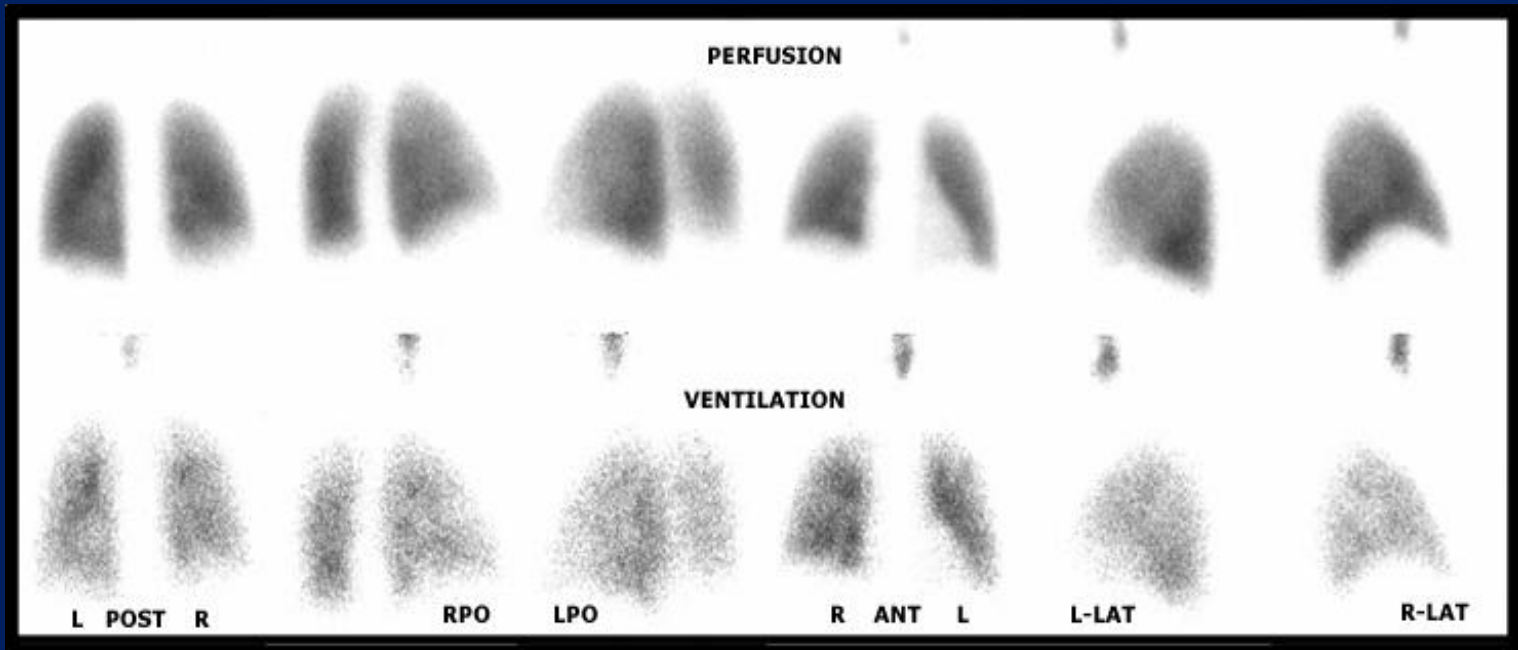
# Akciğer ventilasyon ve perfüzyon sintigrafisi

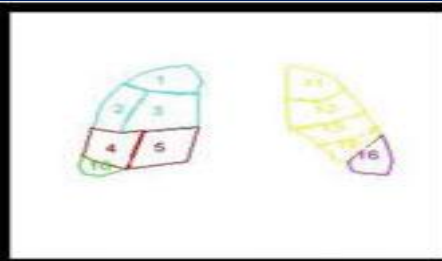
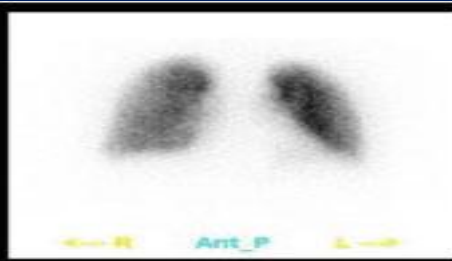
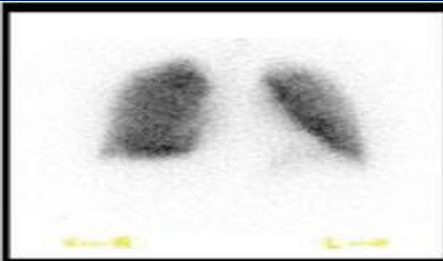
## Perfüzyon Ajanları

- Tc-99m MAA
- Tc-99m HSA

## Ventilasyon Ajanları

- Aerosoller (Tc-DTPA)
- Technegas
- Xe-133

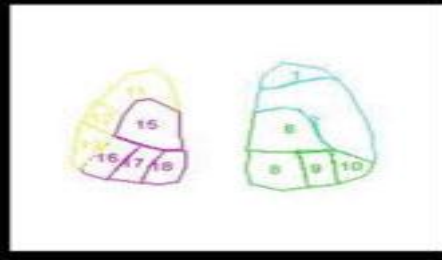
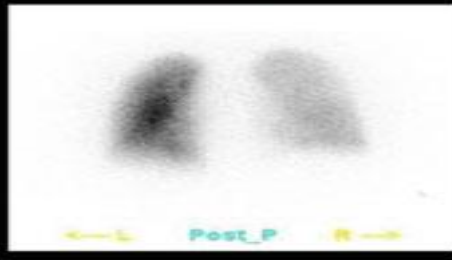
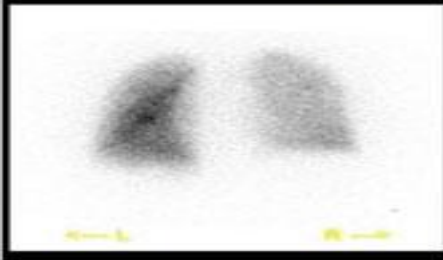




Click Segment to Highlight

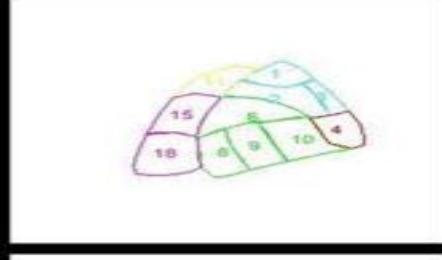
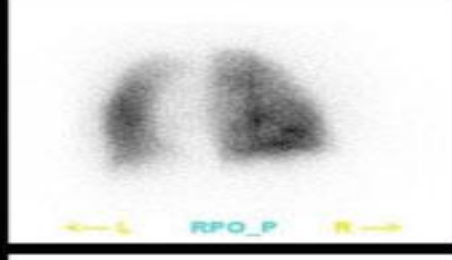
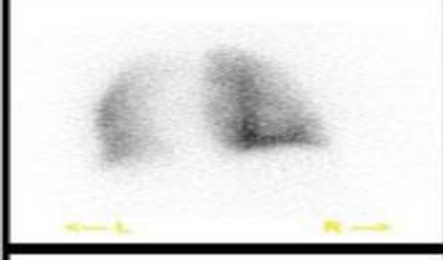
**Right Upper Lobe**

- 1. Apical
- 2. Posterior
- 3. Anterior



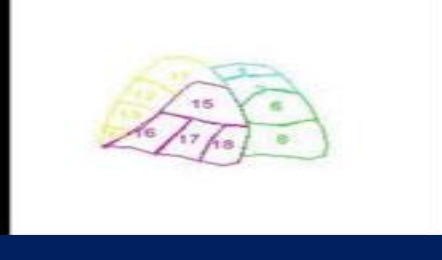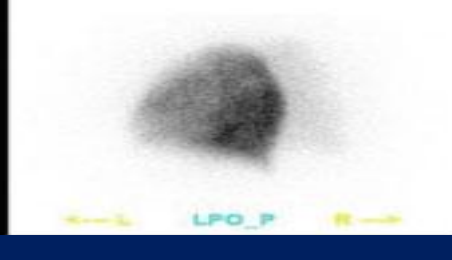
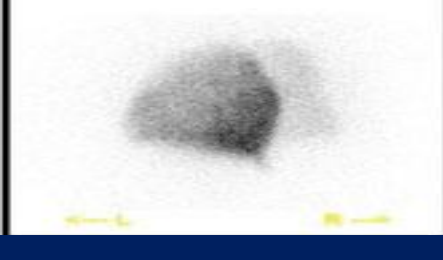
**Right Medial Lobe**

- 4. Lateral
- 5. Medial



**Right Lower Lobe**

- 6. Superior
- 7. Medial Basal
- 8. Posterior Basal
- 9. Lateral Basal
- 10. Anterior Basal



**Left Upper Lobe**

- 11. Apical Posterior
- 12. Anterior
- 13. Superior Lingual
- 14. Inferior Lingual






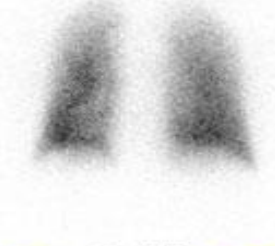








**Left Lower Lobe**

- 15. Superior
- 16. Anteromedial Basal
- 17. Lateral Basal
- 18. Posterior Basal

- V/P sintigrafisi
  - 'Match' defekt
  - **'Mismatch' defekt**
  - 'Reverse mismatch' defekt

## V/P mismatch:

- Pulmoner, lobar, segmental/subsegmental arter PTE
- DDX: Kongenital pulmoner vasküler anormaliteler, venoklusif hastalık, vaskulit, akciğer kanseri veya tbc medastinal adenopati

 <p>Ant_V</p>	 <p>Ant_P</p>	 <p>Ant_Ref</p>	<p>Click Segment to Highlight</p>
 <p>Post_V</p>	 <p>Post_P</p>	 <p>Post_Ref</p>	<p><b>Right Upper Lobe</b></p>
 <p>RPO_V</p>	 <p>RPO_P</p>	 <p>RPO_Ref</p>	<p>1. Apical</p>
 <p>LPO_V</p>	 <p>LPO_P</p>	 <p>LPO_Ref</p>	<p>2. Posterior</p>
			<p>3. Anterior</p>
			<p><b>Right Medial Lobe</b></p>
			<p>4. Lateral</p>
			<p>5. Medial</p>
			<p><b>Right Lower Lobe</b></p>
			<p>6. Superior</p>
			<p>7. Medial Basal</p>
			<p>8. Posterior Basal</p>
			<p>9. Lateral Basal</p>
			<p>10. Anterior Basal</p>
			<p><b>Left Upper Lobe</b></p>
			<p>11. Apical Posterior</p>
			<p>12. Anterior</p>
			<p>13. Superior Lingual</p>
			<p>14. Inferior Lingual</p>
			<p><b>Left Lower Lobe</b></p>
			<p>15. Superior</p>
			<p>16. Anteromedial Basal</p>
			<p>17. Lateral Basal</p>
			<p>18. Posterior Basal</p>

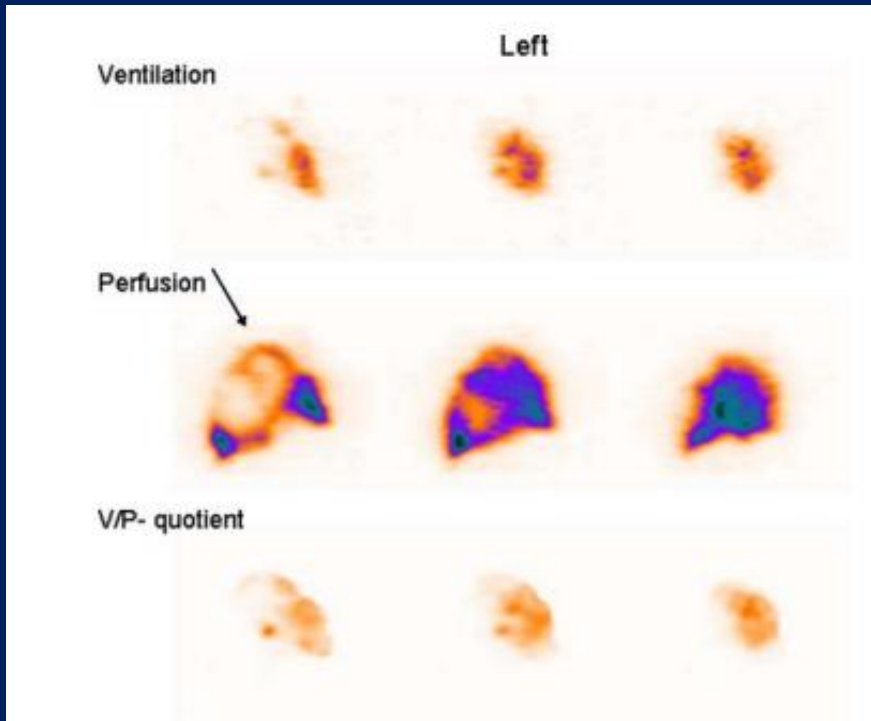
## V/P match:

- Hem perfüzyon hem de ventilasyon etkileniyor.
- PE dışı intrinsik akciğer hastalıkları. Etken çoğunlukla hava yolları ve akciğer parankimi hastalığı

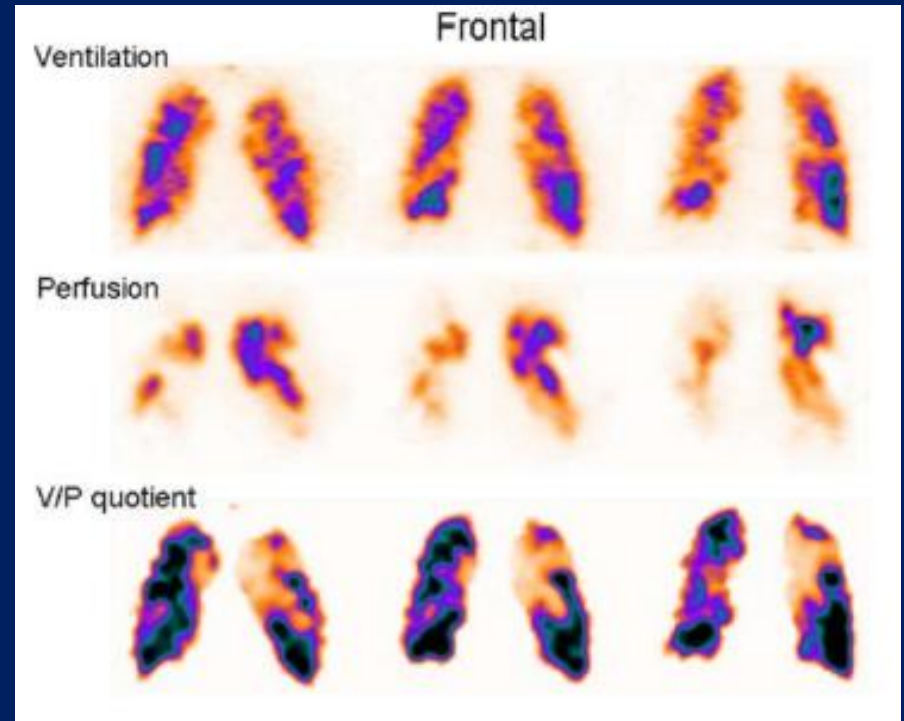
## Reversed V/P mismatch:

- Ventilasyon perfüzyondan da çok etkileniyor
- Pnömoni, KOAH





Reverse mismatch,  
pnömoni, 'Stripe sign'

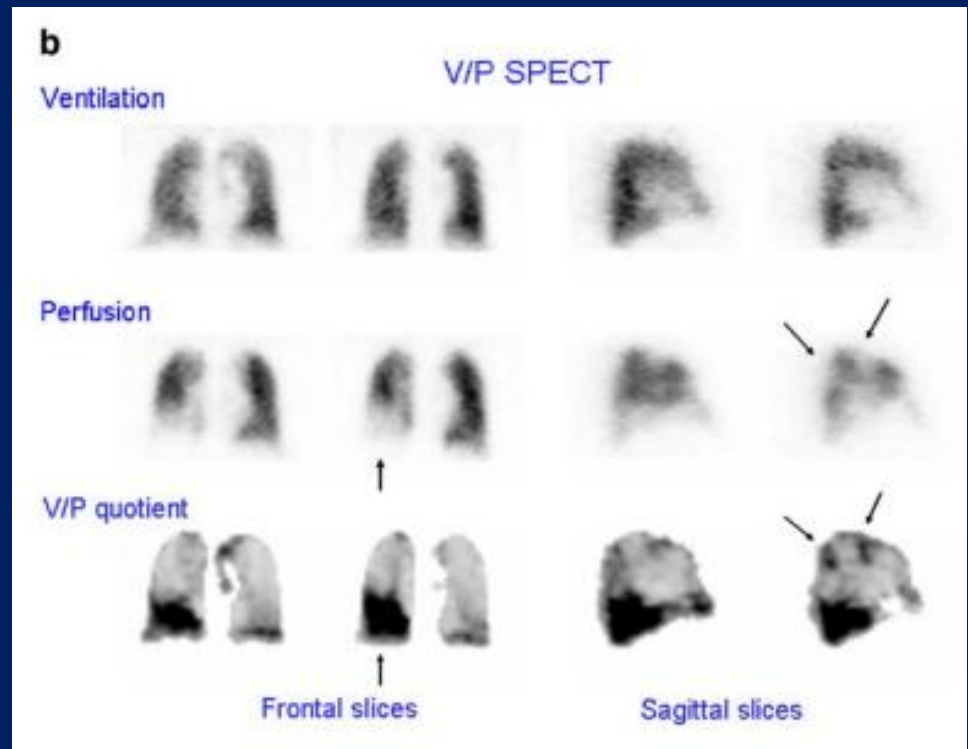
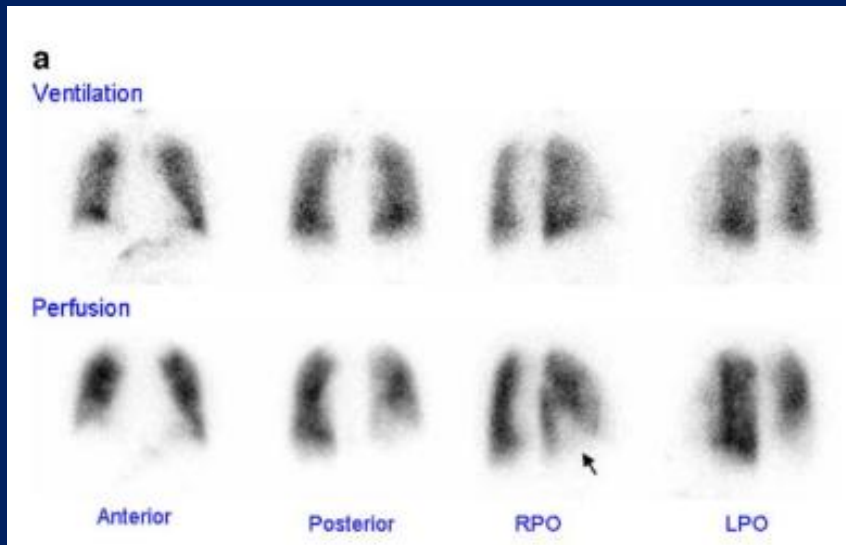


KOAH VE PTE

# V/P değerlendirme

PIOPED	Modified PIOPED II	Perfusion-only modified PIOPED II	Perfusion-only PISAPED
High LR >2 large mismatched (V:Q) segmental defects*	High LR ≥2 large mismatched (V:Q) segmental defects*	PE present ≥2 large mismatched (Q:CXR) segmental defects*	PE present ≥1 wedge-shaped Q defects
Borderline high LR 2 large mismatched (V:Q) segmental defects*			
Intermediate LR 2 moderate or 1 large mismatched (V:Q) defect* Difficult to categorize as high or low	Nondiagnostic All other findings	Nondiagnostic All other findings	Nondiagnostic Cannot classify as PE-present or PE-absent
Borderline low LR 1 matched (V:Q) defect, CXR-negative			
Low LR Nonsegmental perfusion defects† Q defect substantially < CXR defect Matched (V:Q) defects, CXR-negative Any number of small Q defects*			
Normal No Q defects	Very low LR Nonsegmental† Q defect < CXR lesion 1-3 small segmental* defects Solitary matched (V:Q:CXR) defect (≤1 segment) in mid or upper lung Stripe sign‡ Solitary large pleural effusion§ ≥2 matched (V:Q) defects, regionally normal CXR	PE absent Very low probability Nonsegmental† Q defect < CXR lesion 1-3 small segmental* defects Solitary matched (Q:CXR) defect (≤1 segment) in mid or upper lung Stripe sign‡ Solitary large pleural effusion§	PE absent Non-wedge-shaped Q defect Contour defect caused by enlarged heart, mediastinum, or diaphragm Near-normal Q Normal Q
	Normal No Q defects		

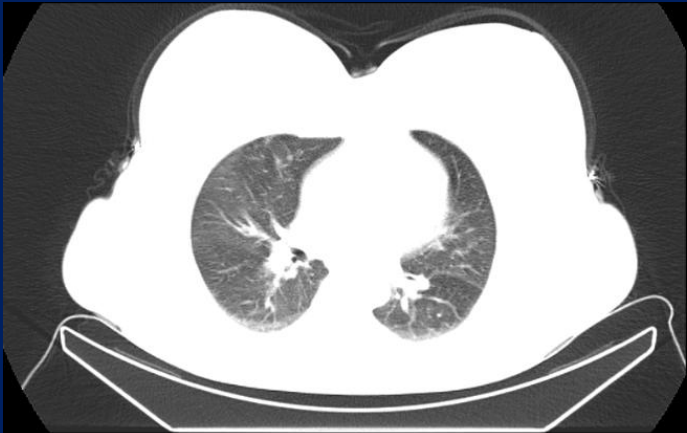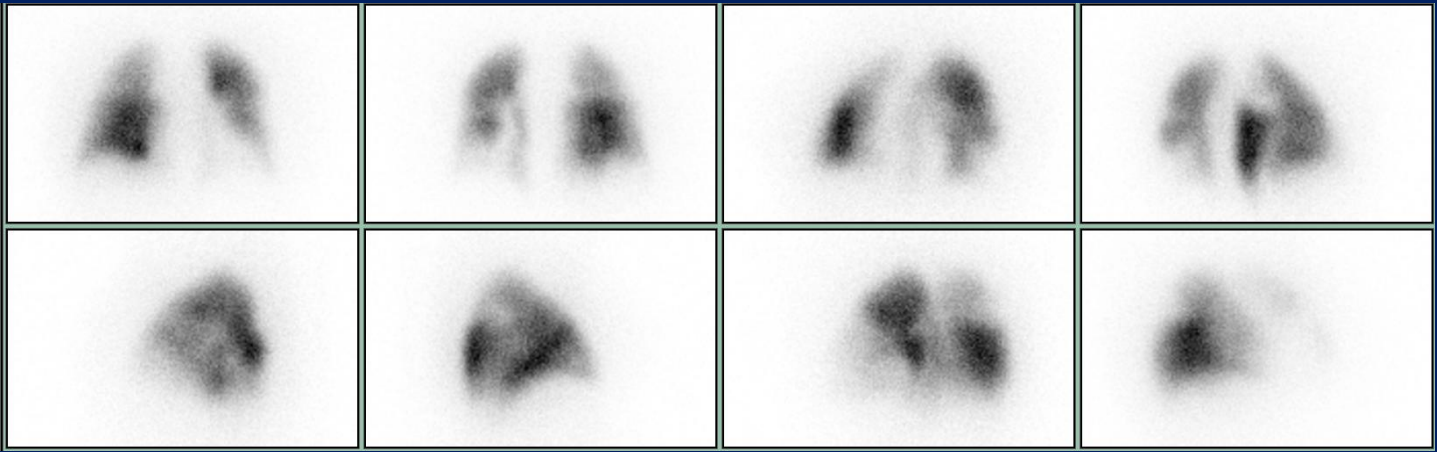
# Planar vs SPECT



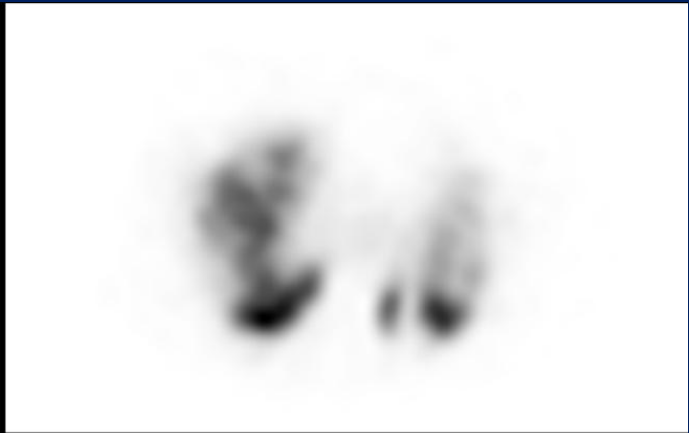# V/P SPECT değerlendirme

- **Embolizm yok:** Normal perfüzyon, Mismatch olmaksızın match veya reverse mismatch ,  
Lobar,segmental veya subsegmental patern göstermeyen mismatch
- **Embolizm var:** Pulmoner vasküler anatomiye uyan en az 1 segmentte veya 2 subsegmentte V/P mismatch defekt
- **Non-diagnostik:** Çok sayıda V/P anomalisi spesifik hastalığa sığmayan

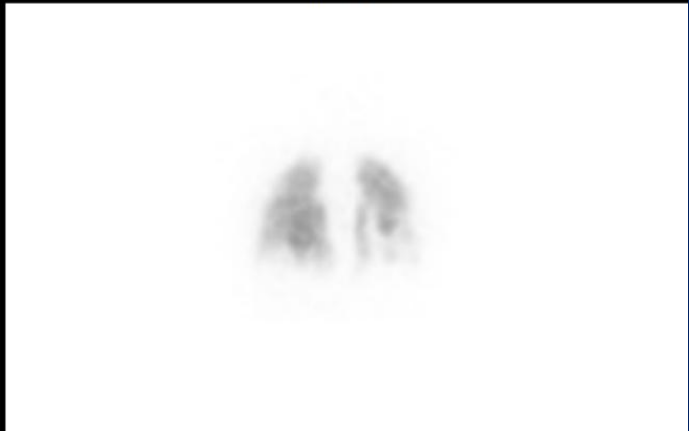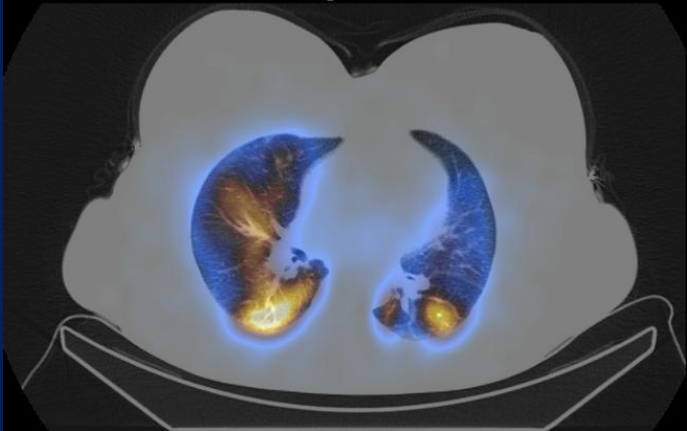
- Bu kurallar ile > 3000 hastada;
- NÖD :97–99%, hassasiyet: 96–99% ve özgüllük : 91–98%, Non-diagnostik oranlar 1–3%
- KPETH V/P sintigrafi hassasiyeti 96% to 97% ve özgüllük 90%, Kontrastlı BT hassasiyeti 51%.
- V/P'nin KTEPH için NÖD  $\geq$  %98, hassasiyeti  $\geq$  %96 özgüllük  $\geq$  %90



HYBRID\_CT Transaxials



IRAC Transaxials



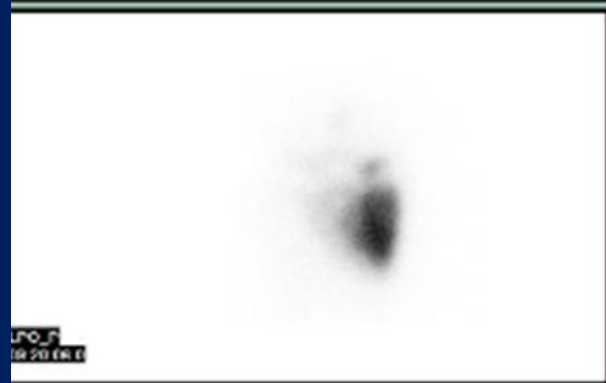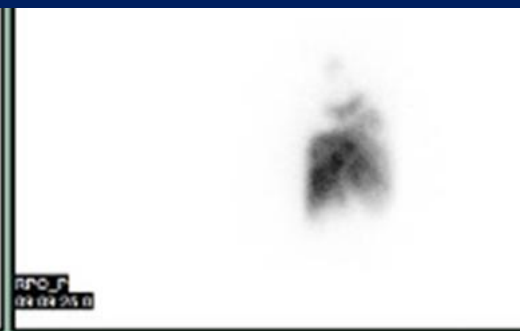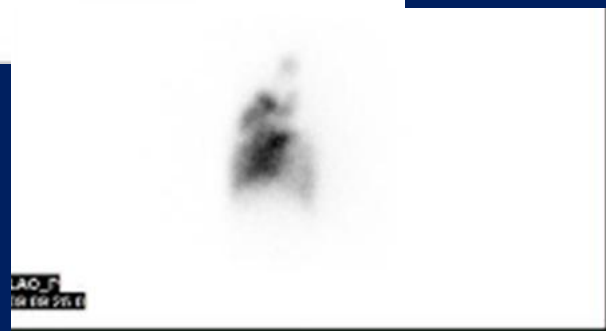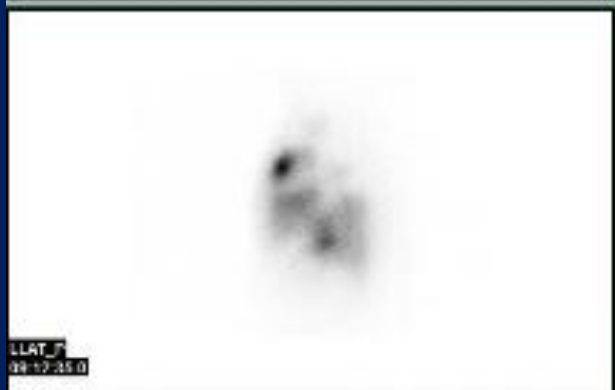E.A, 72Y, E  
10239914

-Emekli maden ocağı işçisi, geçirilmiş PTE, dispne şikayeti mevcut.  
-PHT, KTEPH?

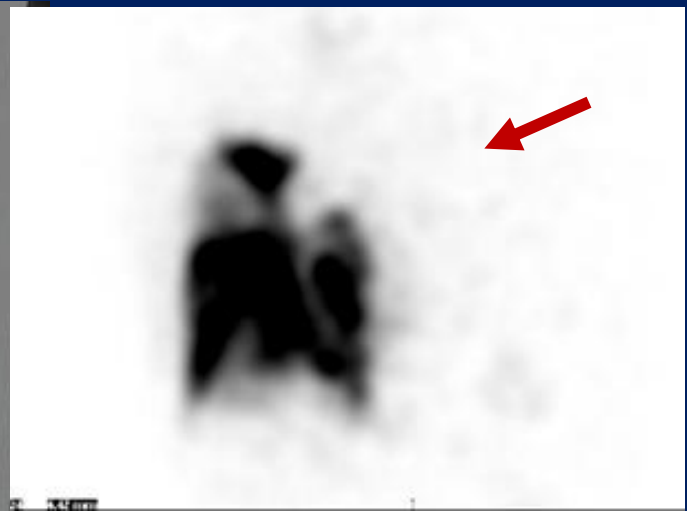
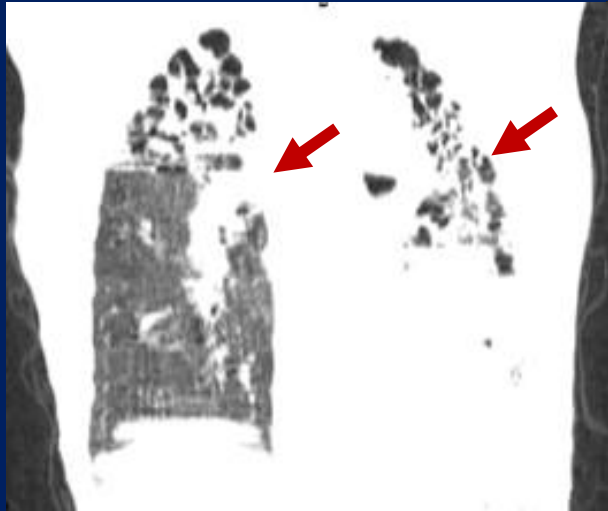
Toraks BT: Sol ana pulmoner arter ve izlenebilen dallarında emboli yok

Sol akciğer tamamında, sağ akciğer üst orta ve alt lobda bronşiektatik alanlar

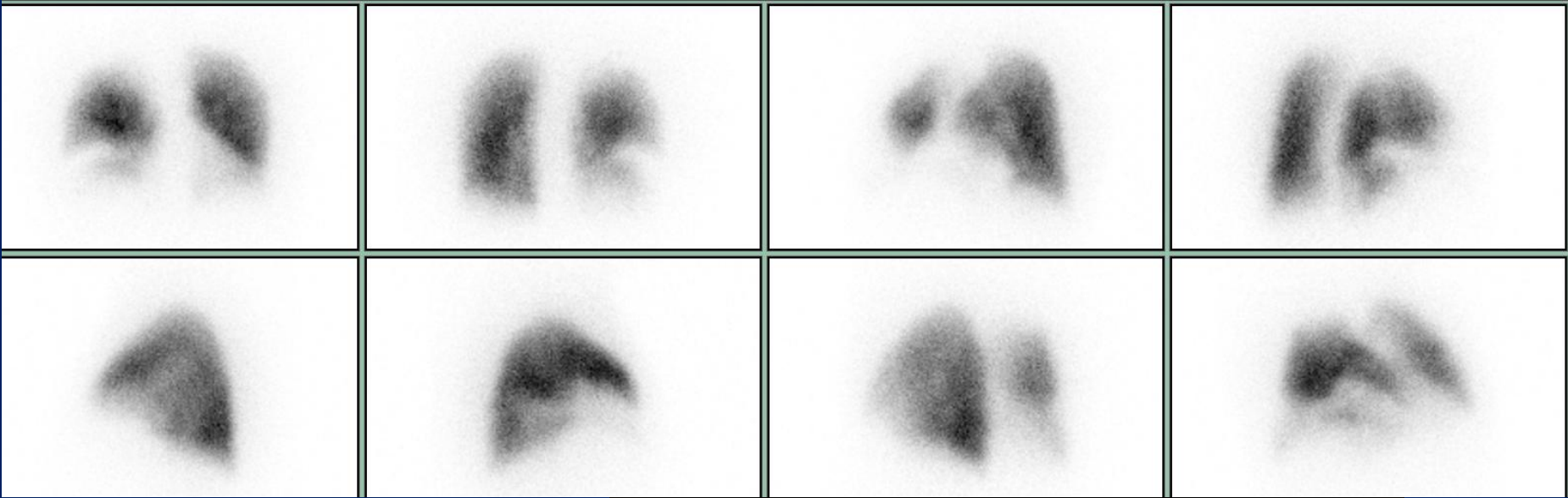
Ana pulmoner arterde genişleme



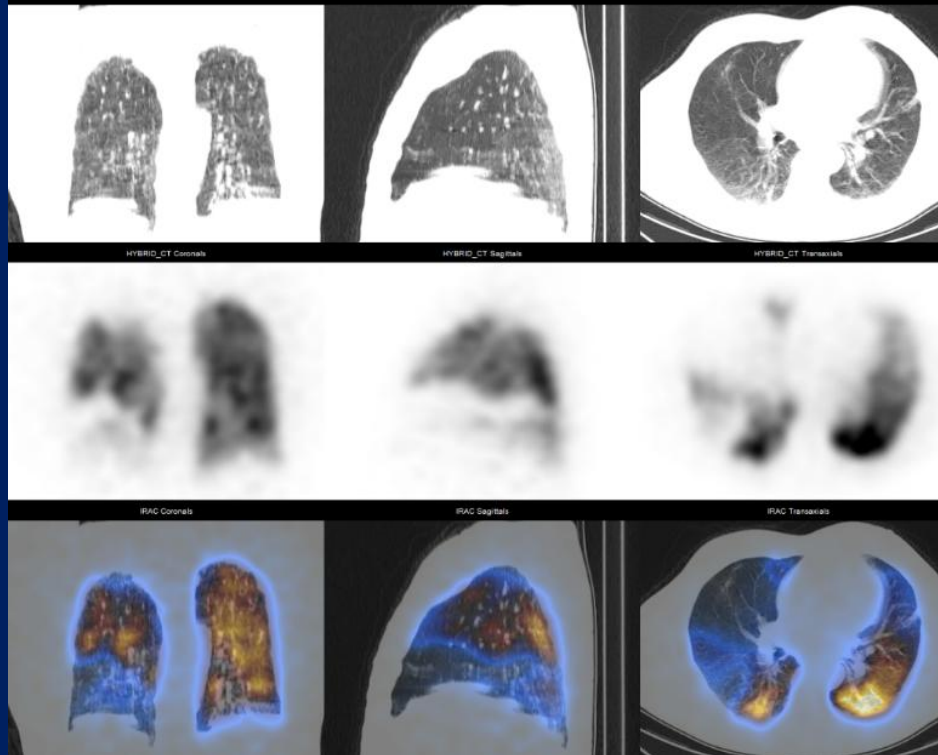


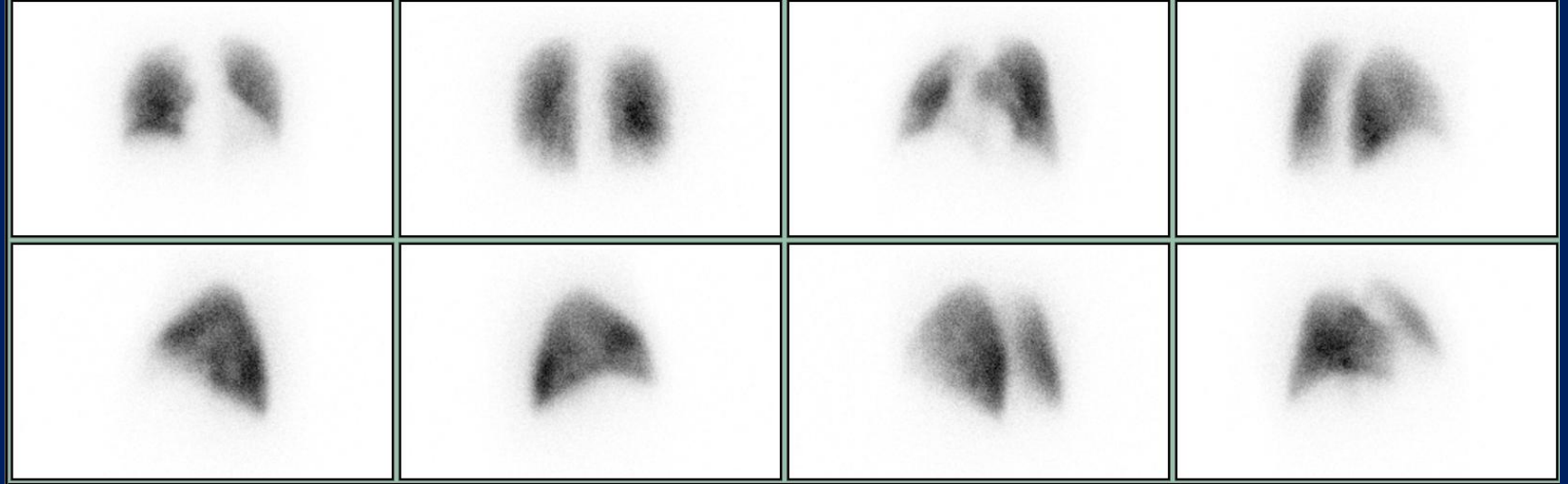


- DI 56 y E
- D-Dimer yüksekliği BFT bozukluğu Kr 1.82 GFR 40
- D dimer 4.3
- Sağ femoral ven tromboze

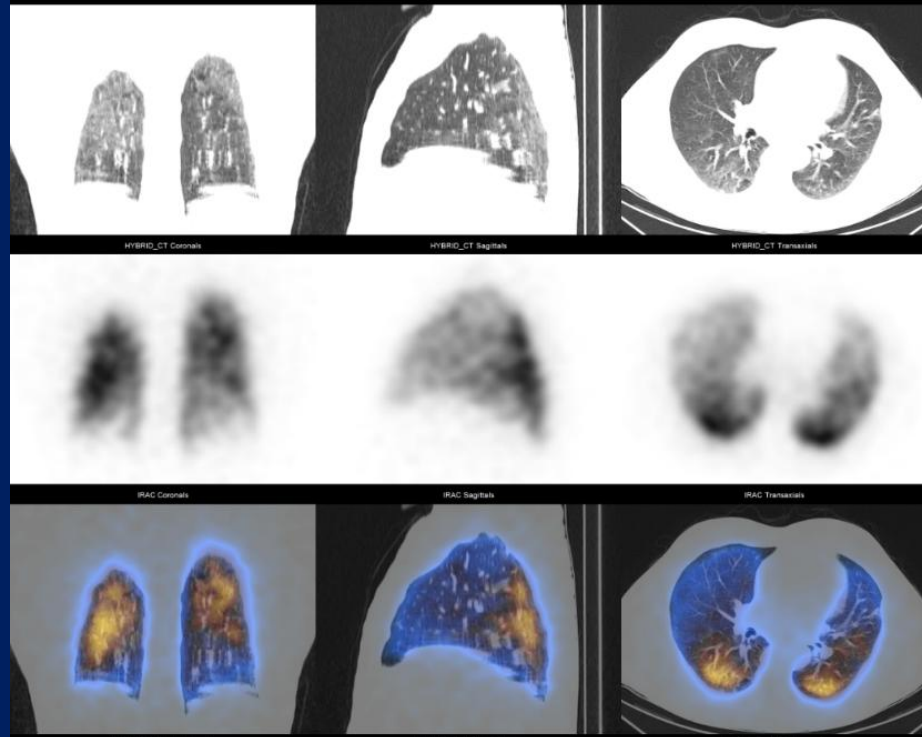


Sağ akciğer orta ve alt loblarda defekt, kama tarzında ve mozaik görünüm





7 ay sonra defekte  
tama yakın düzelme  
D-Dimer 0.8



- Akut PE sonrası %70 -85 hasta 6-12 ay da tam düzelme
- V/P sintigrafik çalışma ile trombus çözülmesi 3. ayda pik yapar

- Teşekkürler

- [muratmtx@yahoo.com](mailto:muratmtx@yahoo.com)

- [murat.tuncel@hacettepe.edu.tr](mailto:murat.tuncel@hacettepe.edu.tr)