



GİRİŐİMSEL PULMONOLOJİDE NELER VAR

VE

OLGU RNEKLERİ

DOĐ.DR. MEHMET AKİF ZGL

SaĐlık Bilimleri niversitesi

**Yedikule GĐs Hastalıkları ve GĐs Cerrahisi SaĐlık Uygulama ve
AraŐtırma Merkezi**

NELER VAR

TANISAL AMAÇLI

- **EBUS (Radial ve Konveks prob)**
- **Navigasyon sistemleri**
- **Transbronşial kriyobiopsi**
- **Medikal Torakoskopi**

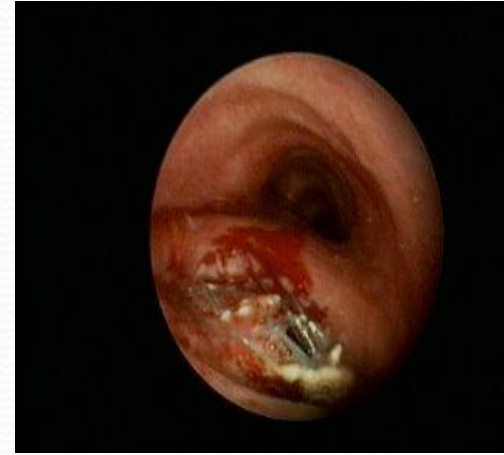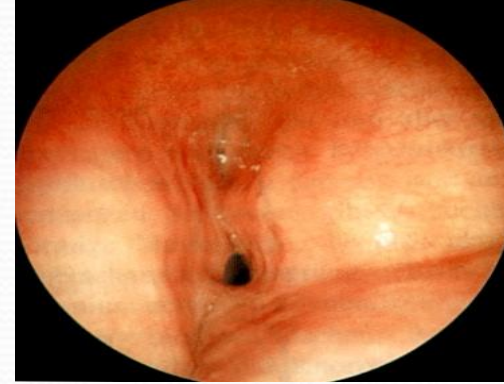TEDAVİ AMAÇLI

- **Bronkoskopik hacim azaltıcı yöntemler (Valf ,Coil)**
- **Bronşial Termoplasti**
- **Sıcak Yöntemler**
- **Soğuk Yöntemler**
- **Mekanik rezeksiyon ve dilatasyon**
- **Stent**
- **Total akciğer lavajı**

Akciğer Kanseri - Ölüm

Akciğer kanserli hastaların % 35-40'ı lokal hastalığın progresyonundan ölürlür.

- **Malign Plevral /Perikardiyal Effüzyon**
- **Vena Cava Superior Sendromu**
- **Masif Hemoptizi**
- **Trakeo Özefajial Fistül**
- *Büyük Hava Yolu Darlıkları*



Chen K, et al. J Emerg Med. 1998;16(1):83-92.

Ernst A, et al. Am J Respir Crit Care Med. 2004;169(12):1278-1297.

Carrol et al. Eur J Cancer Clin Oncol 1986;22:1352-56

Malign Büyük Hava Yolu Darlığı Semptomlar

- **Öksürük**
 - İleri evre AC CA hastal \geq % 90 (1,2)
- **Dispne**
 - İleri evre AC CA hastalarında % 95 (2)
- **Hemoptizi**
 - İleri evre AC CA hastalarında % 63 (2)



CHEST

Supplement

DIAGNOSIS AND MANAGEMENT OF LUNG CANCER, 3RD ED: ACCP GUIDELINES

Symptom Management in Patients With Lung Cancer

Diagnosis and Management of Lung Cancer, 3rd ed: American College of Chest Physicians Evidence-Based Clinical Practice Guidelines

Michael J. Simoff, MD, FCCP; Brian Lally, MD; Mark G. Slade, MBBS, FCCP; Wendy G. Goldberg, MSN, APRN, BC; Pyng Lee, MD, FCCP; Gaetane C. Michaud, MD, FCCP; Momen M. Wahidi, MD, MBA, FCCP; and Mohit Chauha, MD, FCCP

Airway Obstruction

4.1.1. In lung cancer patients with inoperable disease and symptomatic airway obstruction, therapeutic bronchoscopy employing mechanical debriement, brachytherapy, tumor ablation or airway stent placement is recommended for improvement in dyspnea, cough, hemoptysis and overall quality of life (QOL) (Grade 1C).

1 Iyer S, et al. Lung Cancer 2013;81(2):288-93.

2 Iyer S, et al. Support Care Cancer 2014;22(1):181-7

Chest 2013;143(5):455s-497s

HANGİ ŞARTLAR BAŞARIYI ARTIRIR

- ▶ **Bronkoskop tümöre ulaşabilmeli**
- ▶ **Tümörün bronş içinde yayılımı sınırlı olmalı**
- ▶ **Stenoz distalindeki akciğer fonksiyonel olmalı**
- ▶ **Hastanın performans durumu iyi olmalı**
- ▶ **Elektif şartlar (ACİL ŞARTLAR DEĞİL)**



CHEST

OFFICIAL PUBLICATION OF THE AMERICAN COLLEGE OF CHEST PHYSICIANS

**Therapeutic Bronchoscopy for
Malignant Central Airway Obstruction:
Success Rates and Impact on Dyspnea and Quality of Life**

David E. Ost MD MPH,¹ Armin Ernst MD, Horiana B. Grosu MD, Xiudong Lei PhD, Javier Diaz-Mendoza MD, Mark Slade MBBS, Thomas R. Gildea MD MS, Michael Machuzak MD, Carlos A. Jimenez MD, Jennifer Toth MD, Kevin L. Kovitz MD, Cynthia Ray MD, Sara Greenhill MD, Roberto F. Casal MD, Francisco A. Almeida MD MS, Momen Wahidi MD, George A. Eapen MD, David Feller-Kopman, Rodolfo C. Morice MD, Sadia Benzaquen MD, Alain Tremblay MDCM,
Michael Simoff MD On behalf of the AQUIRE Bronchoscopy Registry

- 15 Merkez, 947 hasta 1115 işlem uygulanmış.
- İşlemlerin teknik başarısı %93 (%90-%98 P=0,02)
- Stent takmak başarı oranını artıran bir etken olarak saptanmışken, tek bir ablatif tekniğin teknik başarıya ulaşmada bir üstünlüğü bulunmamıştır.
- Yalnız risk değerlendirmesi temel alınarak terapötik bronkoskopiden uzak durmamak gereklidir. Çünkü işlemde en fazla faydayı yüksek riskli hastaların gördüğü tespit edilmiştir.
- İşlem kararı alınırken; Yalnız işlemin riski değil aynı zamanda potansiyel yararın önemi de dikkate alınmalıdır.

Interventional pulmonology for patients with central airway obstruction

An 8-year institutional experience

[Chia-Hung Chen](#),^{a,b,c} [Biing-Ru Wu](#),^{a,e} [Wen-Chien Cheng](#),^{a,e,d} [Chih-Yu Chen](#),^{a,e} [Wei-Chun Chen](#),^{a,e,d} [Te-Chun Hsia](#),^{a,b,d}
[Wei-Chih Liao](#),^{a,c,d,*} [Chih-Yen Tu](#),^{a,e,f,*} and [Wu-Huei Hsu](#)^{a,e}

Medicine®

[Medicine \(Baltimore\)](#). 2017 Jan; 96(2): e5612.

Published online 2017 Jan 13. doi: [10.1097/MD.0000000000005612](https://doi.org/10.1097/MD.0000000000005612)

variable	No., %
Endoscopic success	583 (95)
Mortality after procedure	4 (0.7)
Major morbidity	
Halitosis	41 (6.7)
Iatrogenic pneumonia	24 (3.9)
Granulation tissue formation	16 (2.6)
Stent infections	11 (1.8)
Stent migration	8 (1.3)
Stent fracture	2 (0.3)
Pneumothorax	6 (1.0)

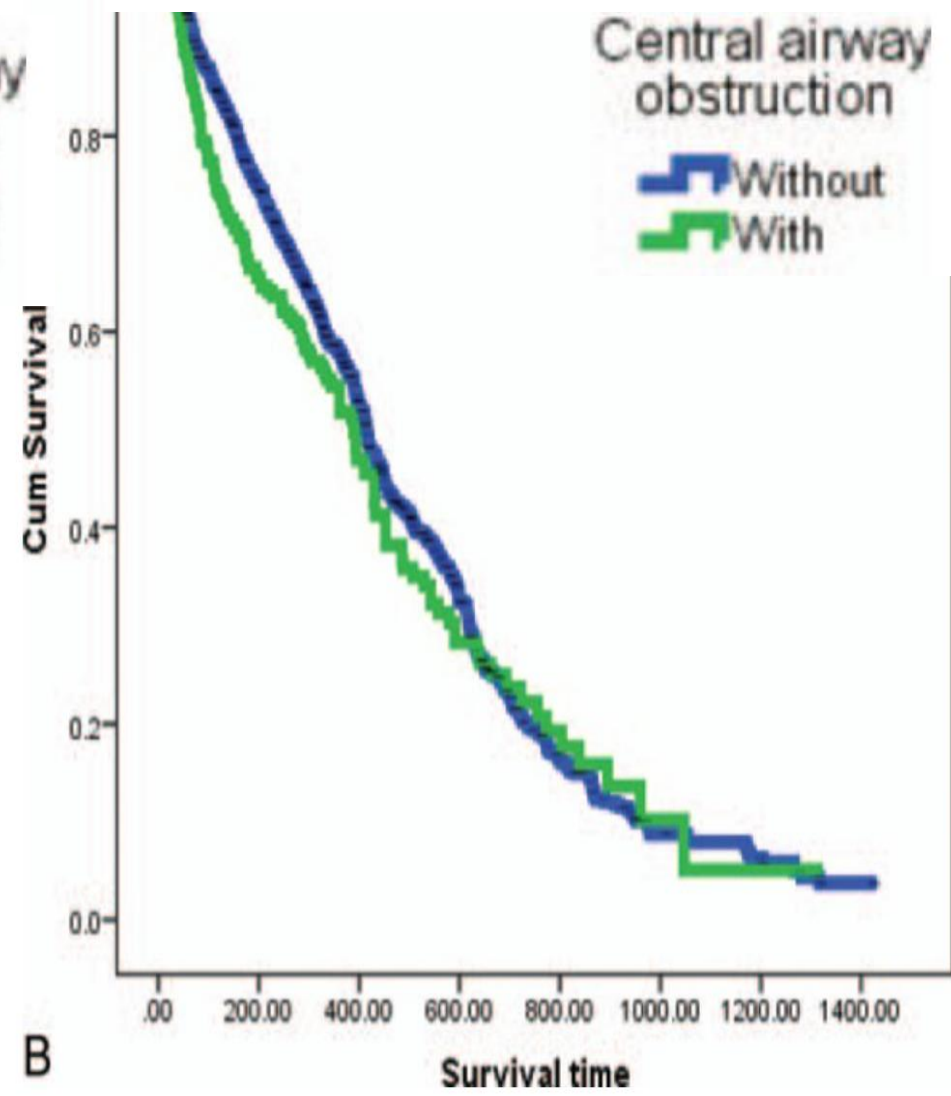
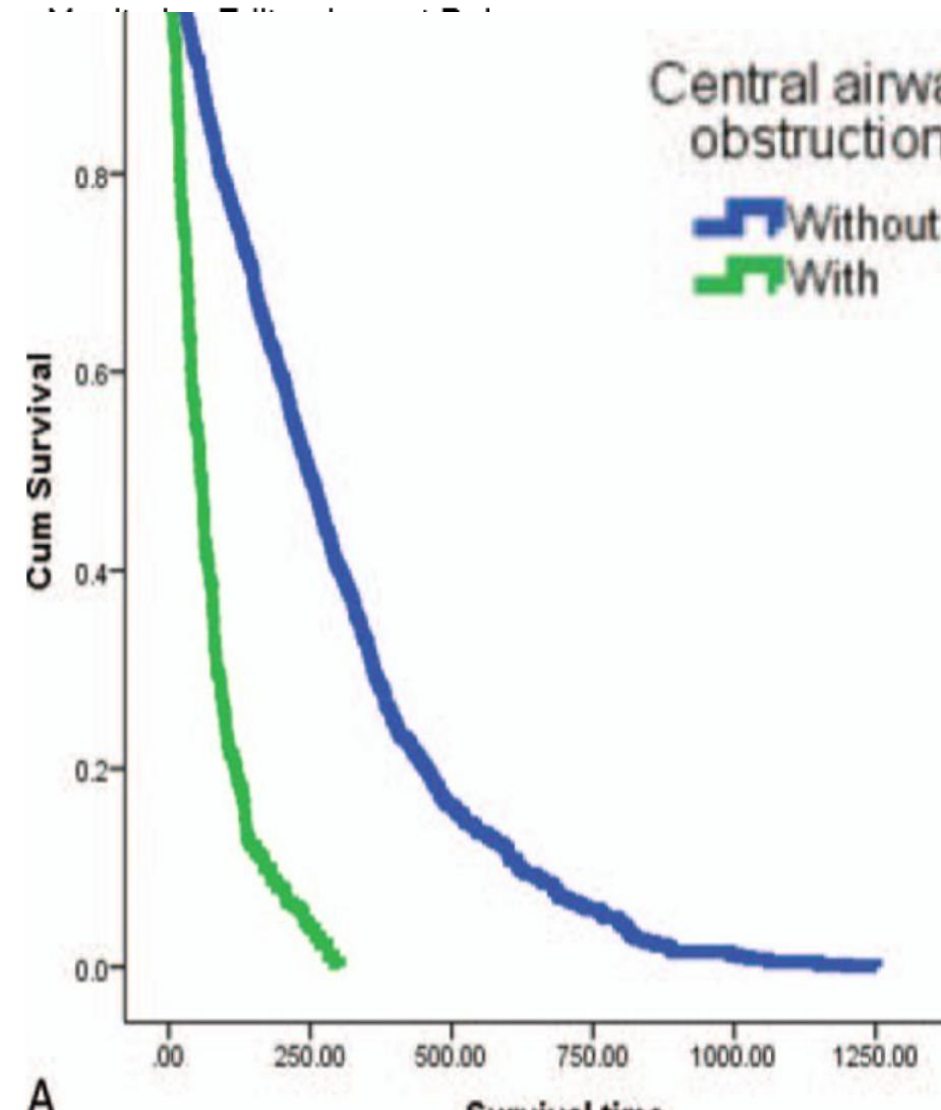
Interventional pulmonology for patients with central airway obstruction

An 8-year institutional experience

[Chia-Hung Chen](#),^{a,b,c} [Biing-Ru Wu](#),^{a,e} [Wen-Chien Cheng](#),^{a,e,d} [Chih-Yu Chen](#),^{a,e} [Wei-Chun Chen](#),^{a,e,d} [Te-Chun Hsia](#),^{a,b,d}
[Wei-Chih Liao](#),^{a,c,d,*} [Chih-Yen Tu](#),^{a,e,f,*} and [Wu-Huei Hsu](#)^{a,e}

Medicine (Baltimore). 2017 Jan; 96(2): e5612.

Published online 2017 Jan 13. doi: [10.1097/MD.00000000000005612](https://doi.org/10.1097/MD.00000000000005612)



Endobronşiyal tedavi yöntemleri

• Sıcak yöntemler

**Elektrokoter,
Argon plazma koagulasyon(APC),
Lazer**

• Soğuk yöntemler

Kriyoterapi

- **Rijid bronkoskopi ile mekanik temizleme,**
- **Dilatasyon**

Endobronşiyal stent uygulanması

Brakiterapi

Fotodinamik tedavi

Endobronşiyal tedavi yöntemleri

Kısa süreli etki

Uzun süreli etki

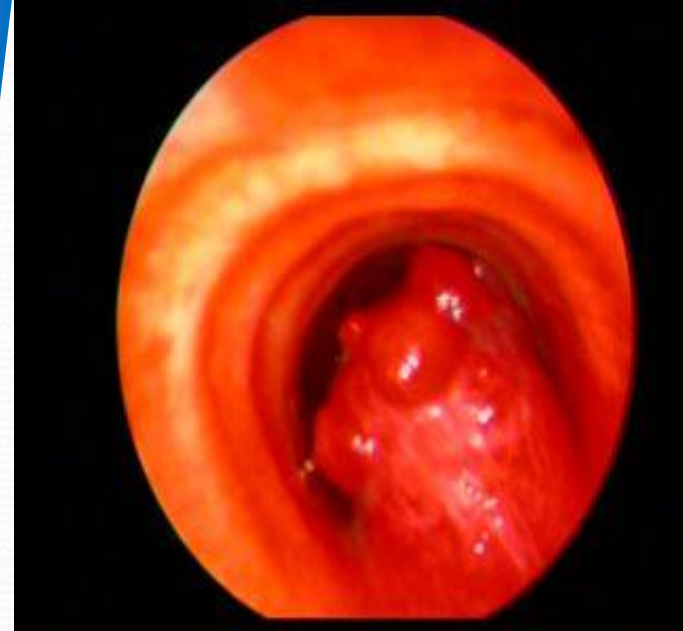
Mekanik debulking

Laser, APC

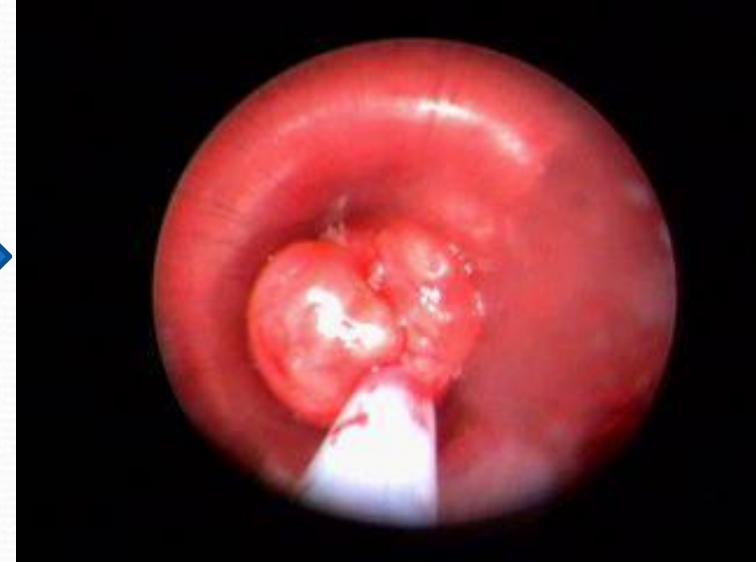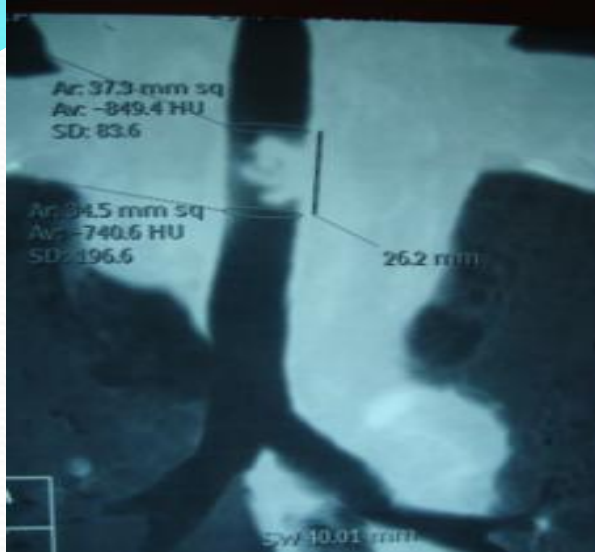
Stent

PDT

Kriyoterapi



Bronkoskopik tedavi yöntemleri



Hızlı Yöntem
Debulking
Lazer
Elektrokoter
APC



Kriyoekstraksiyon
Mekanik Rezeksiyon
Mikrodebrider

Başarı
% 91 (1)
% 83 (2)
%100 (3)

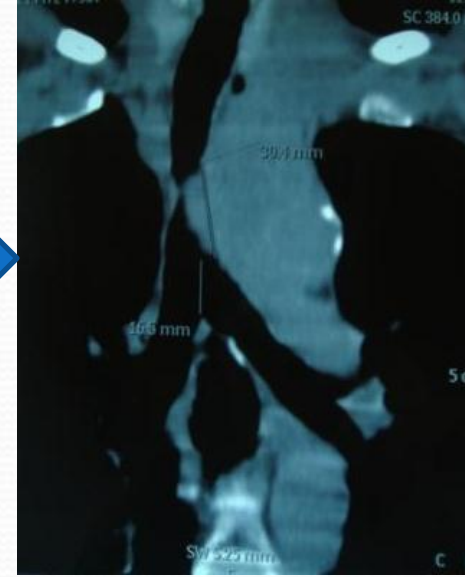
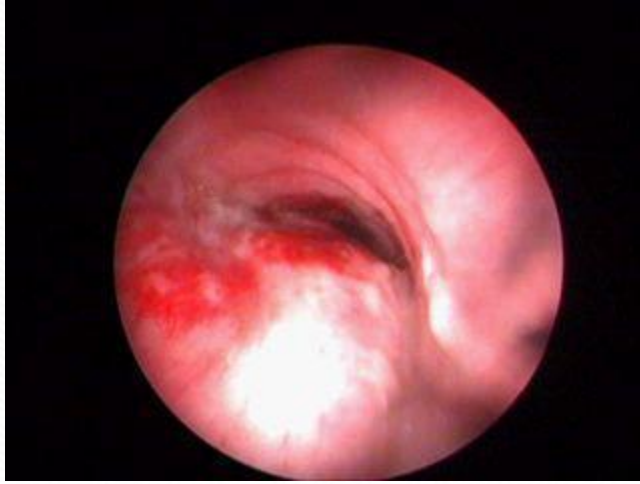
Lazer
Elektrokoter
APC (± MR)

Başarı
% 83-93 (1)
% 88-89 (1)
% 91-96 (1,2)

1 Wahidi MM. Chest 2007;131:261-274

2 Herth FJ. Chest 2005;128(4):209

Bronkoskopik tedavi yöntemleri



Yöntem

Dilatasyon

STENT

Başarı

Dilatasyon

% 43 (1)

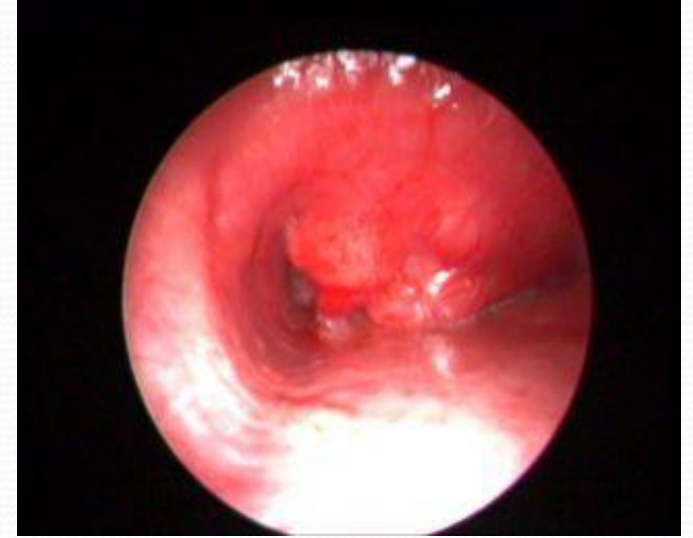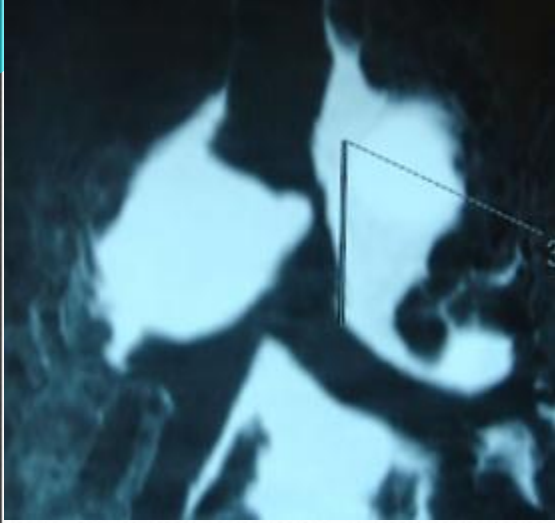
Stent

% 82-97 (2)

1 Hautmann H, et al. Chest 2001;120:43-49.

2 Wahidi MM. Chest 2007;131:261-274

Bronkoskopik tedavi yöntemleri



Hızlı Yöntem

Debulking
Lazer
Elektrokoter
APC
Mekanik Rezeksiyon
Kriyoekstraksiyon
Mikrodebrider

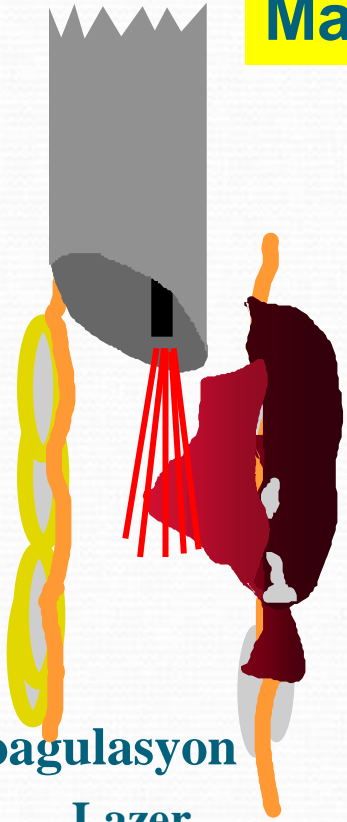
Yavaş Yöntem

Kriyoterapi
PDT
Brakiterapi

Yöntem

Dilatasyon
STENT

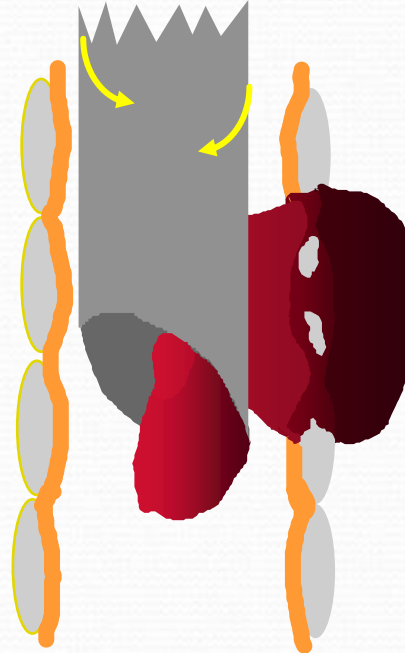
Malign havayolu stenozu



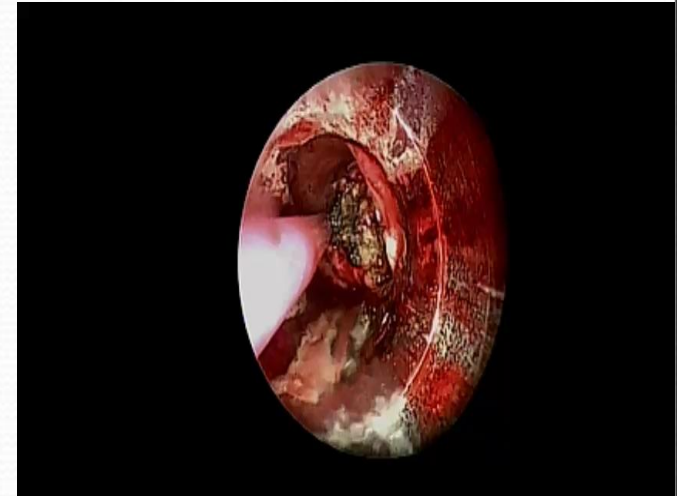
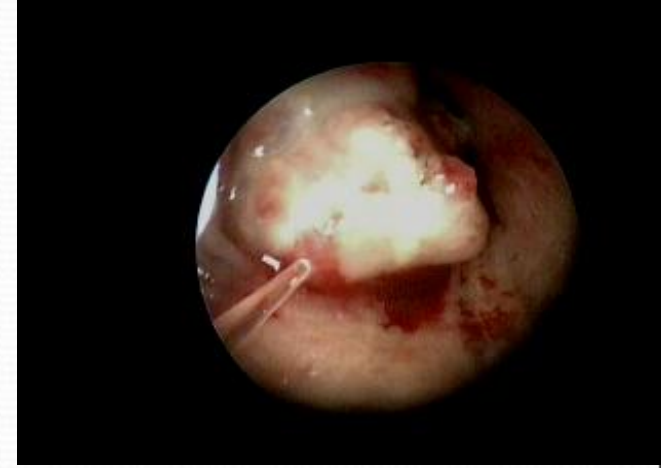
Koagulasyon

- Lazer
- Elektrokoter -APC
- Kriyoterapi

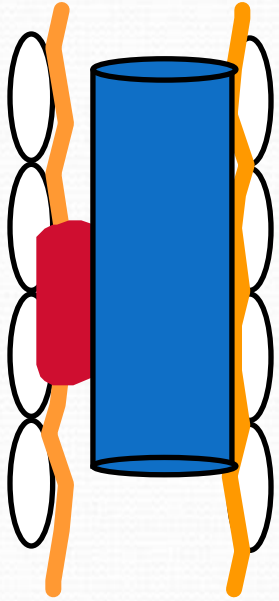
çevir
&
it



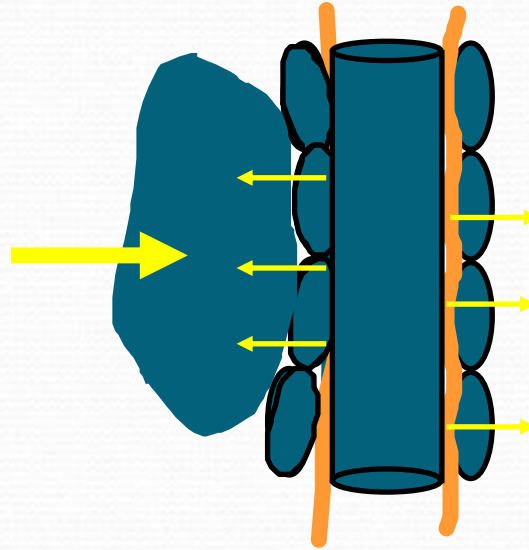
Mekanik debulking



Bronkoskopik tedavi yöntemleri



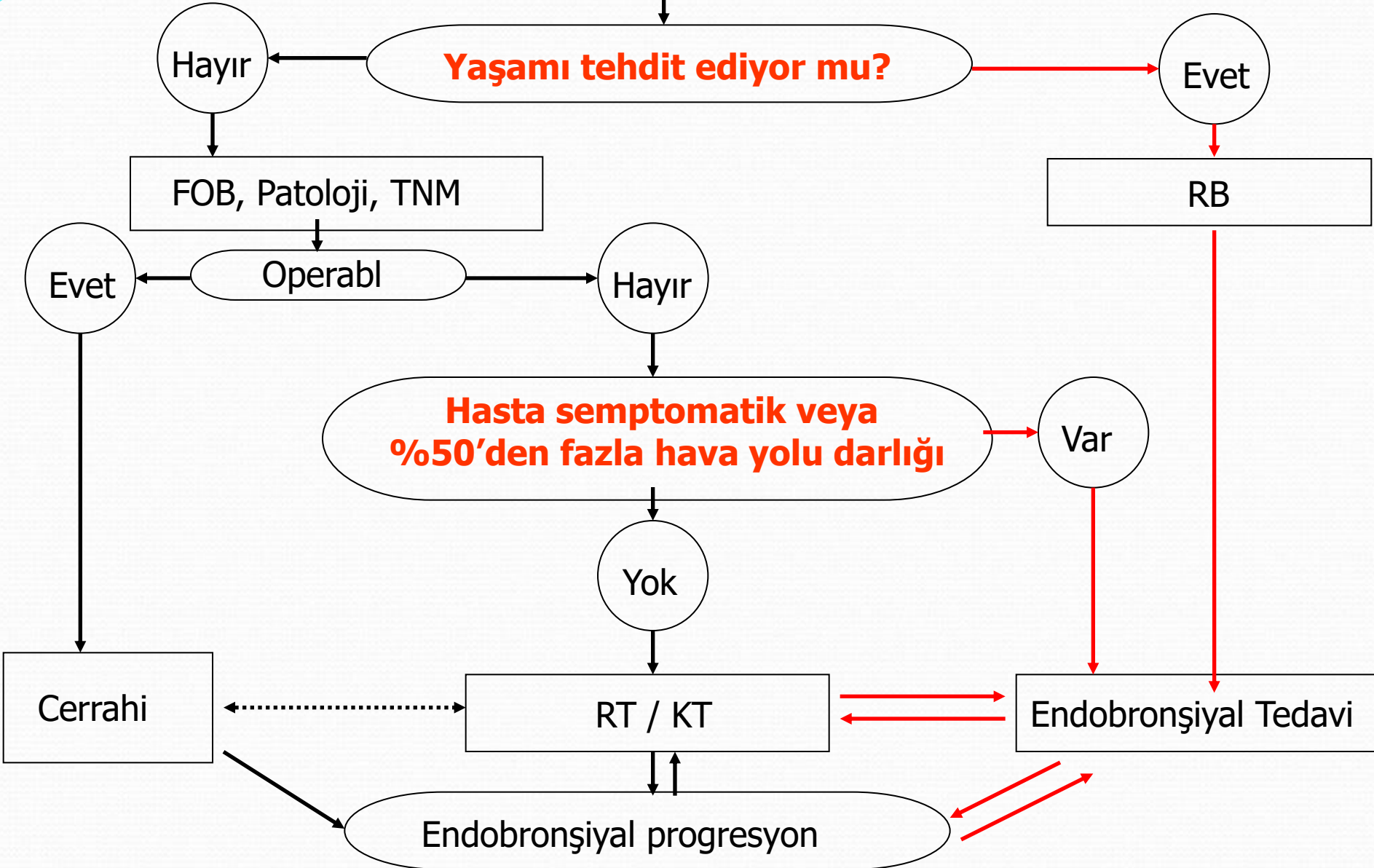
Bariyer etkisi



Atel etkisi



Malign Büyük Hava Yolu Darlığı

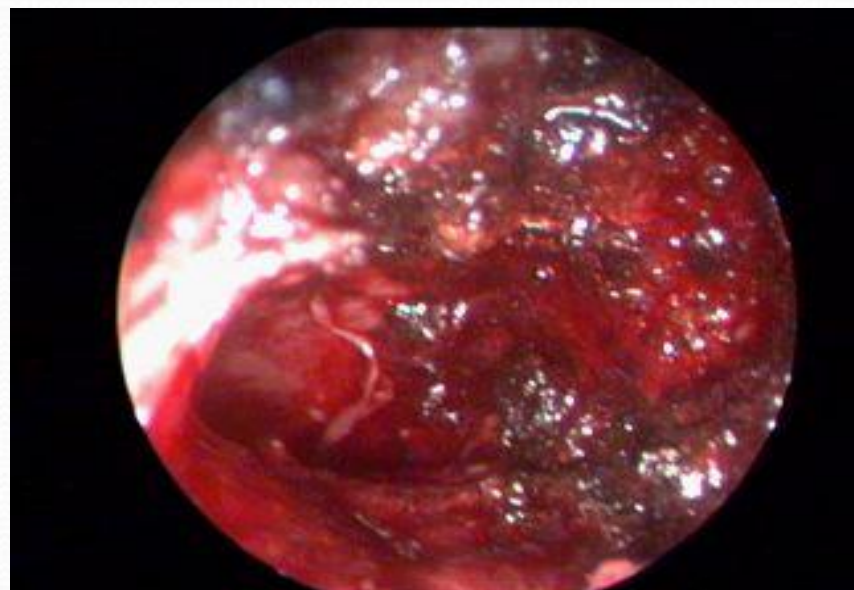
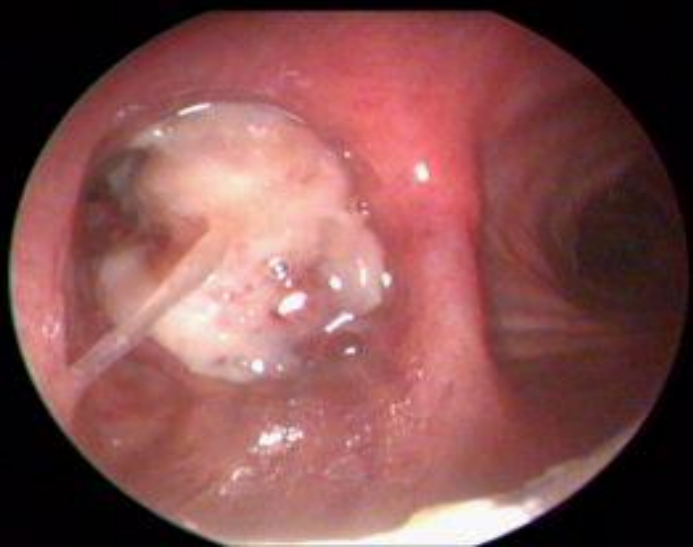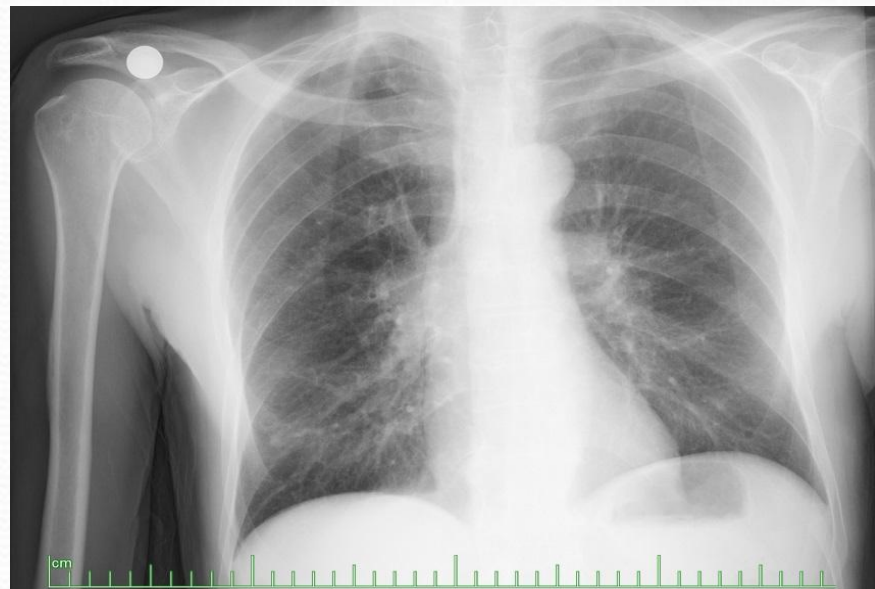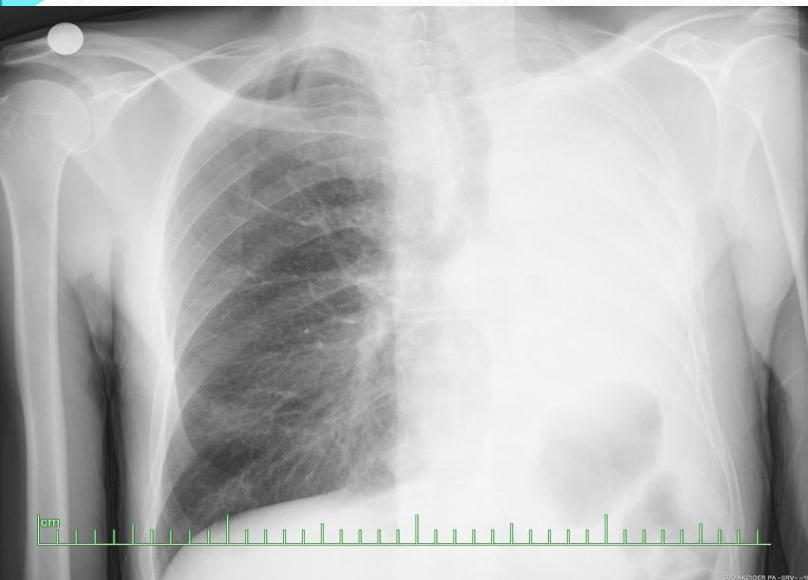


STENT

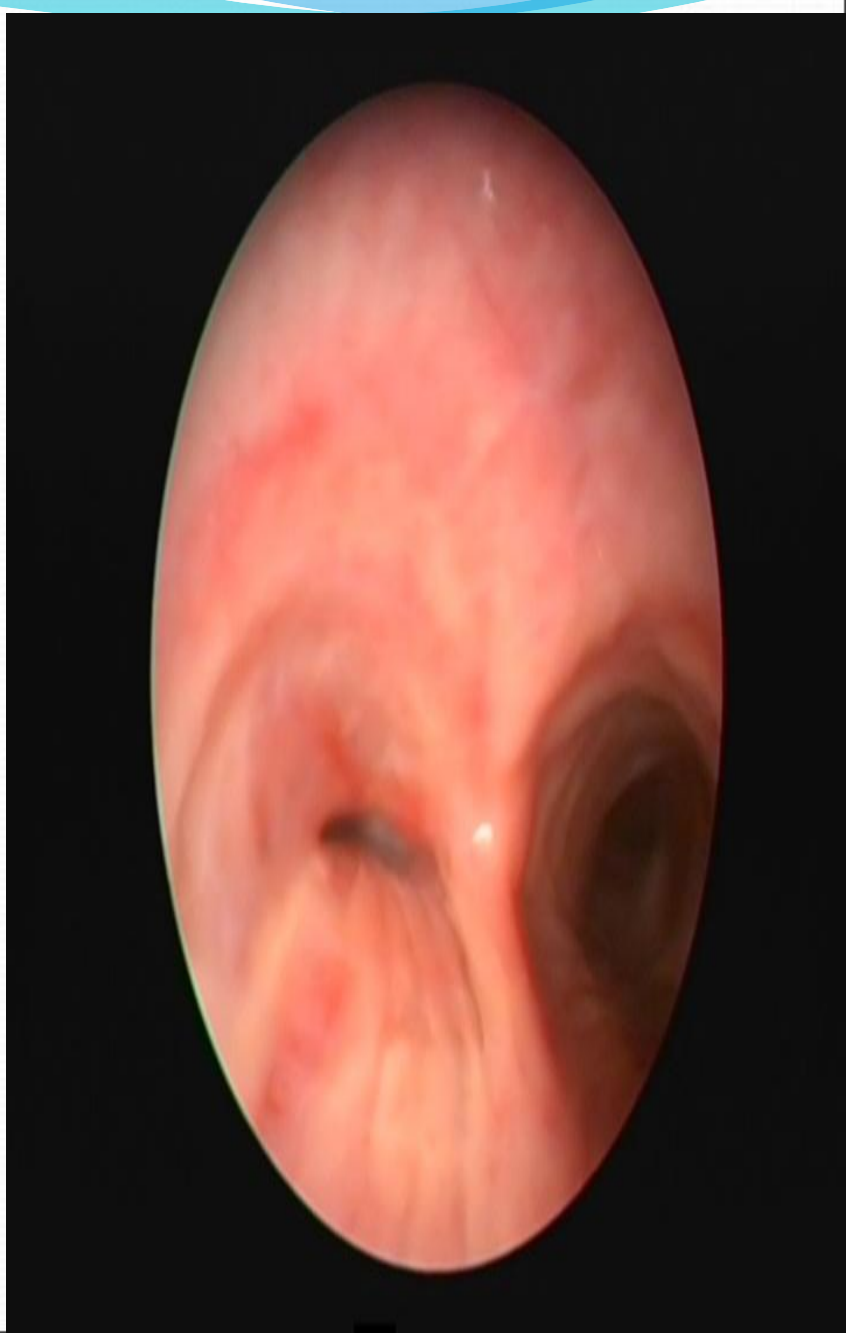
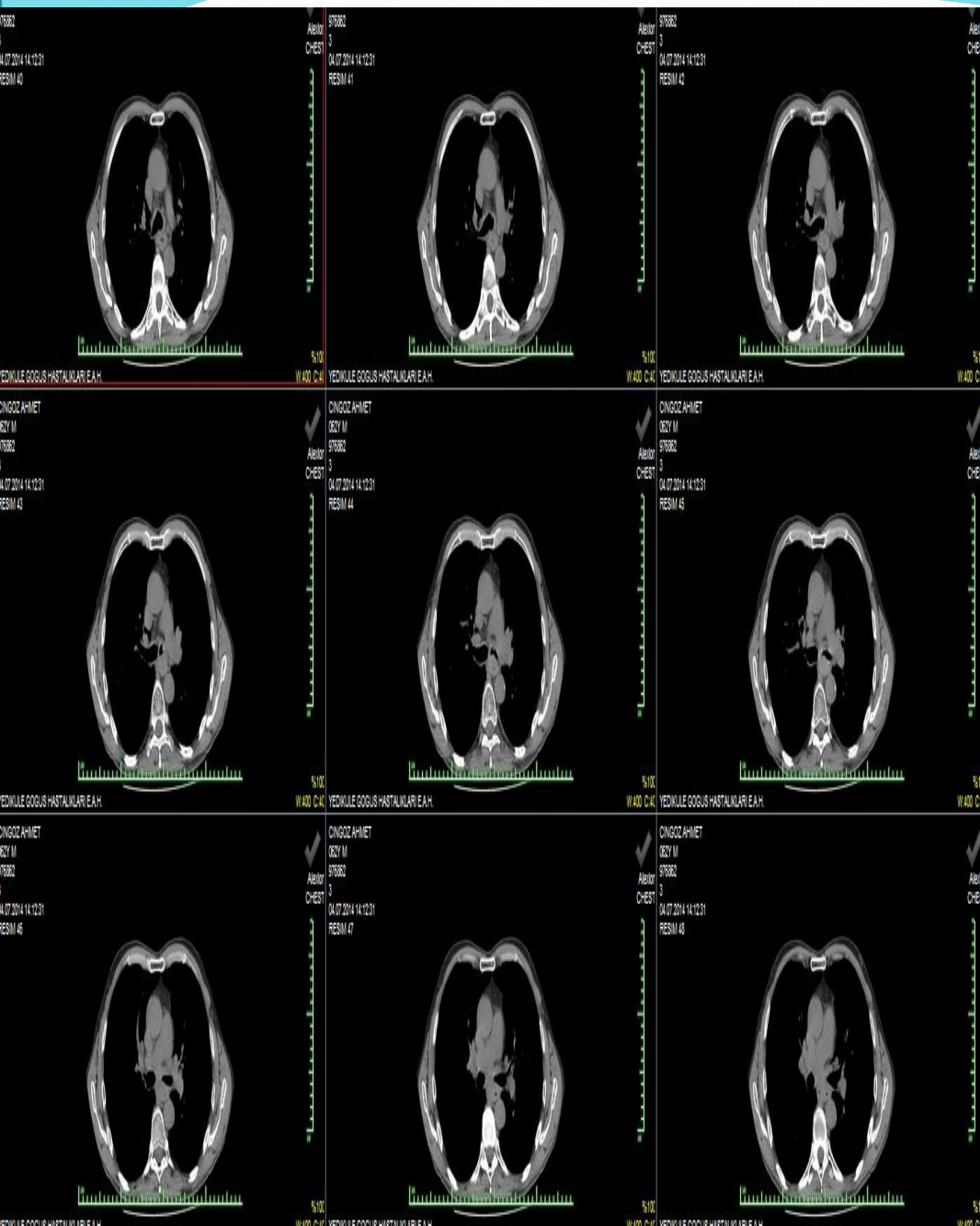
- **Malign**

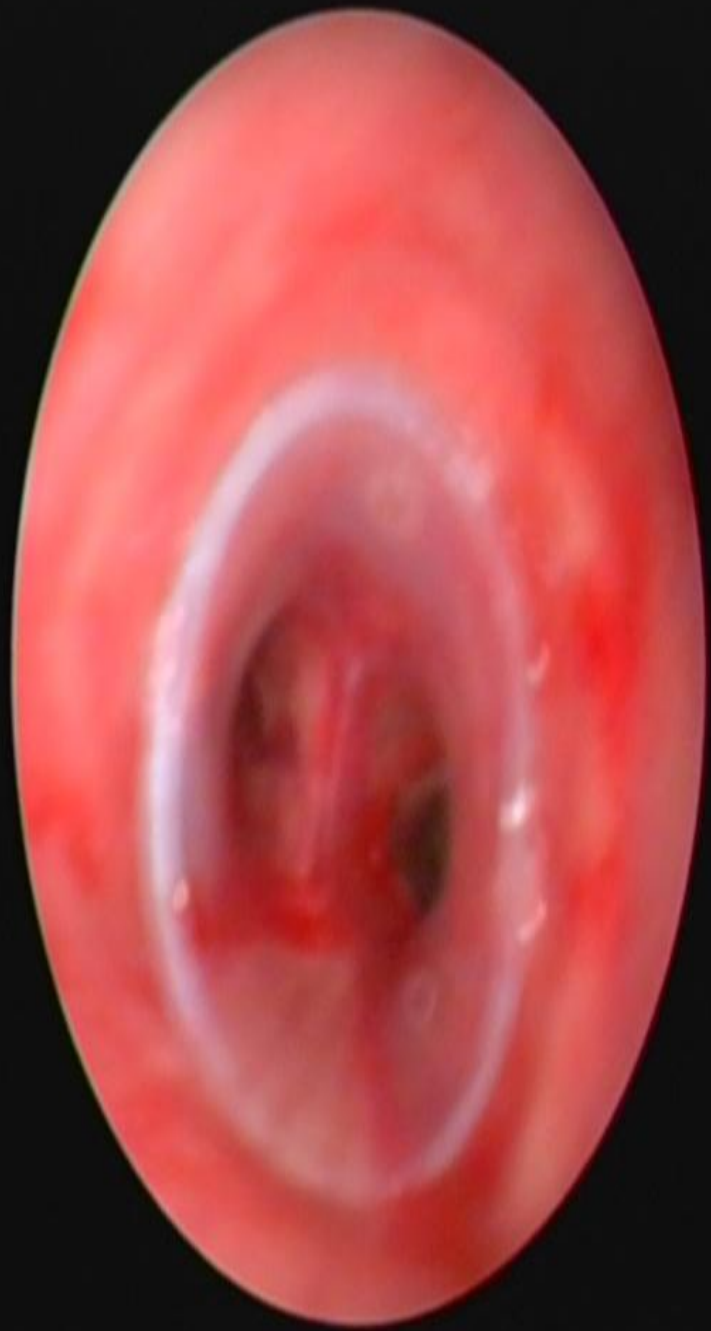- Endobronşiyal tümör(tümör temizliğinin yetersiz oluşu,tedaviye rağmen relaps, lokal relapsın yüksek ihtimal oluşu)
- Bronş, özefagus veya baş-boyun tümörleri nedeniyle dıştan bası
- Mediastinal lenf bezlerinden dolayı dıştan bası
- Malign fistül (Ör: trakeo-özefageal fistül)

OLGU 1 PA AC GRAFİSİ ve BRONKOSKOPİ



OLGU 1 TORAKS BT



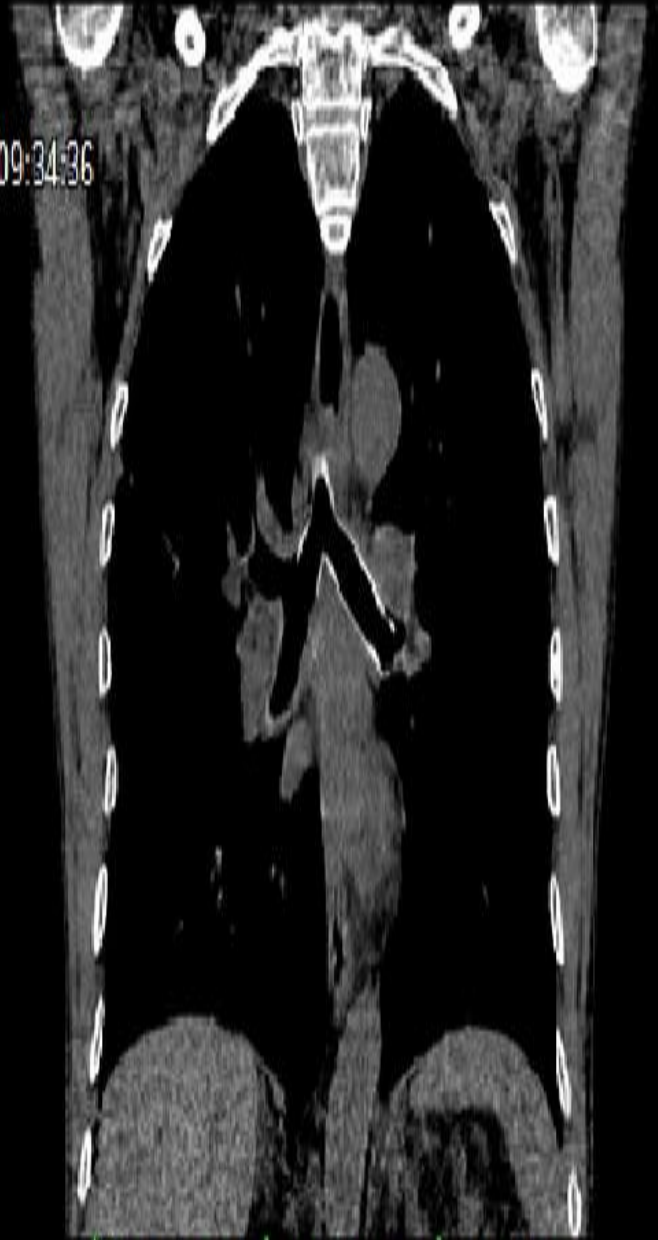


62Y M

76862

0.02.2015 09:34:36

RESIM 52



Alexis
CHES



% 10

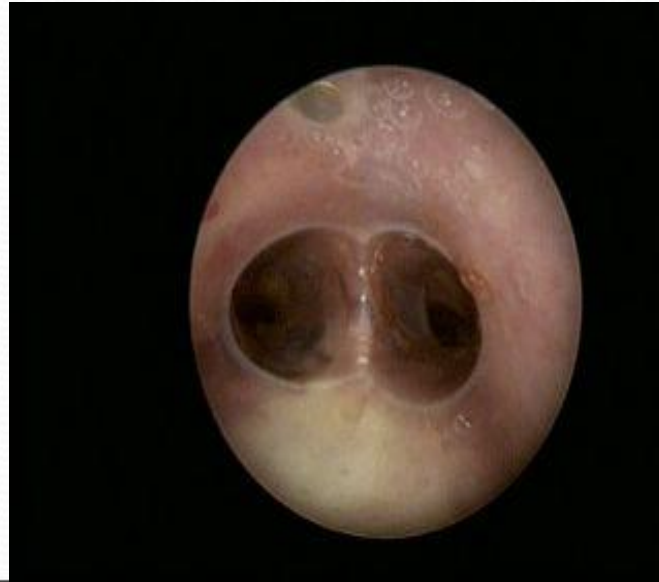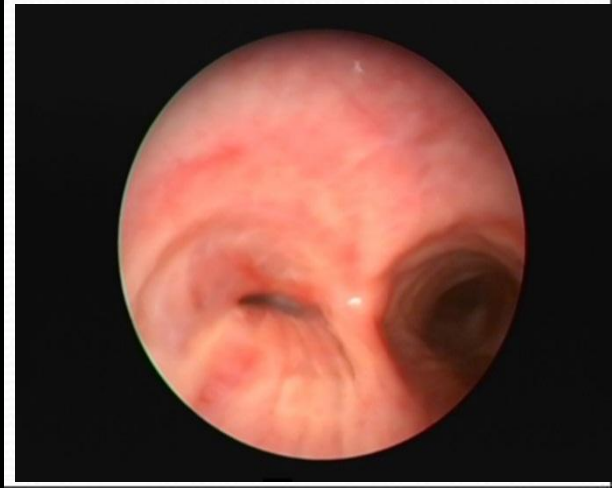
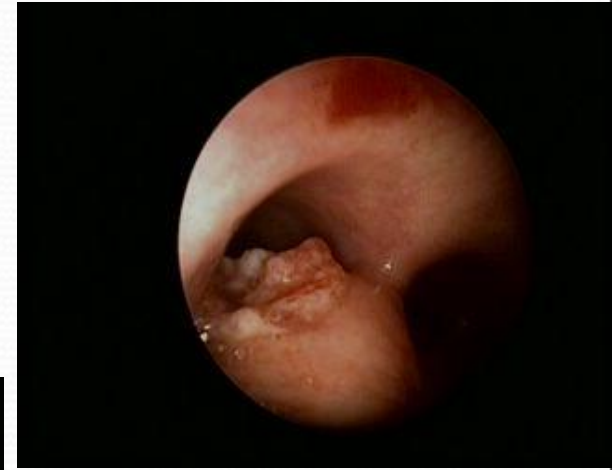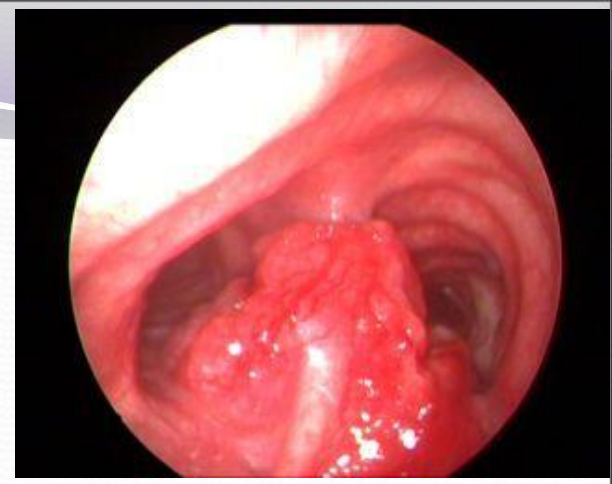
► Silikon Y Stent

Karina tutulumu

**Trakea 1/3 distalinde veya orta hatta
trakeal stent stabil deęilse ve migrasyon
riski yksekse**

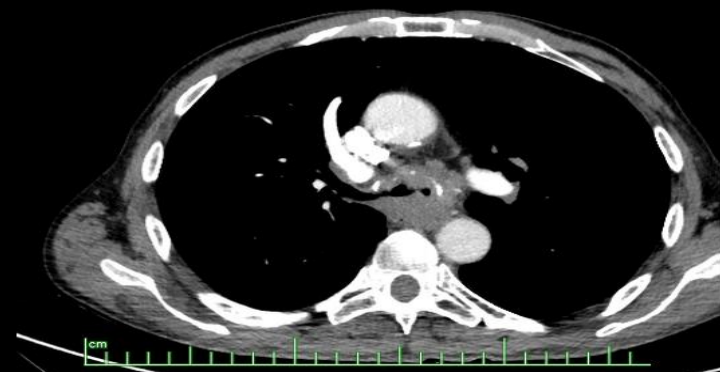
Trakeo ve/veya bronko-zefagial fistl

Ana bronş proksimalindeki stenoz

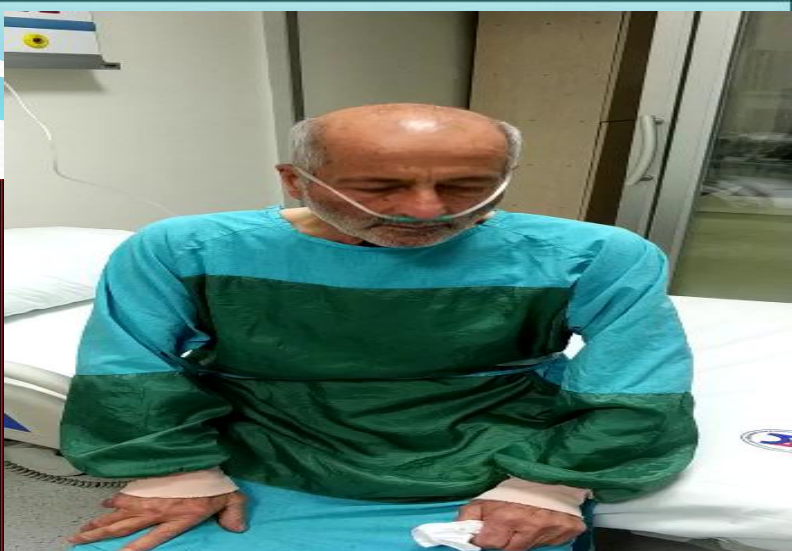

2.olgu

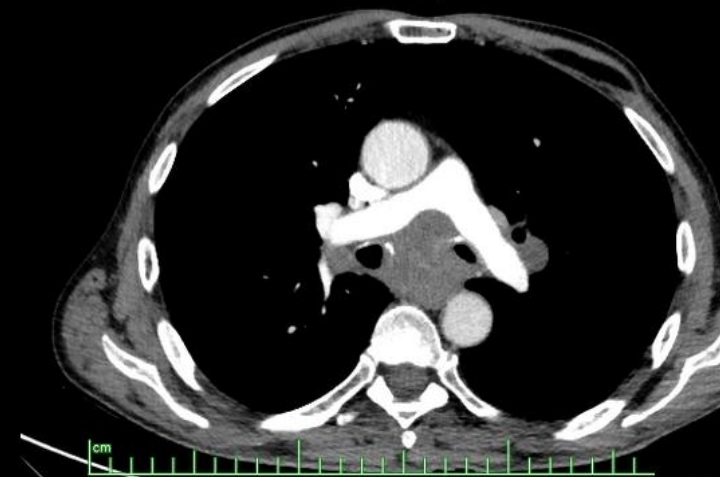HIKMET DONMEZ
069Y M
36109095272
1
16.11.2017 22:49:22
RESIM 67



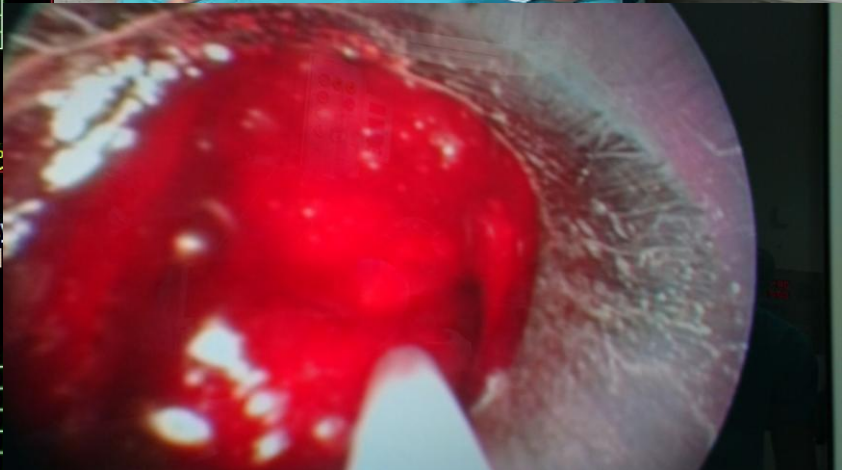
Ingenuity CT
CHEST



HIKMET DONMEZ
069Y M
36109095272
1
16.11.2017 22:49:22
RESIM 75

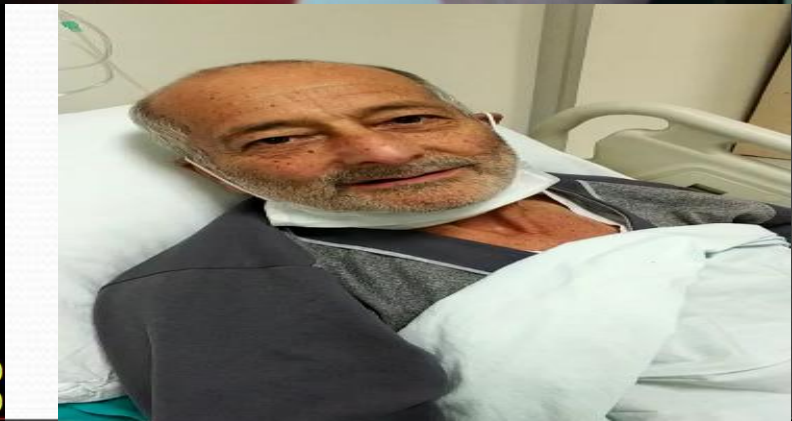

Ingenuity
CH

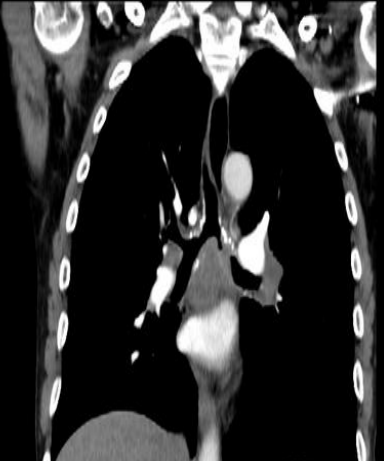


YEDIKULE GOG.HAST.VE GOG.CERRAHI.E.A.H.

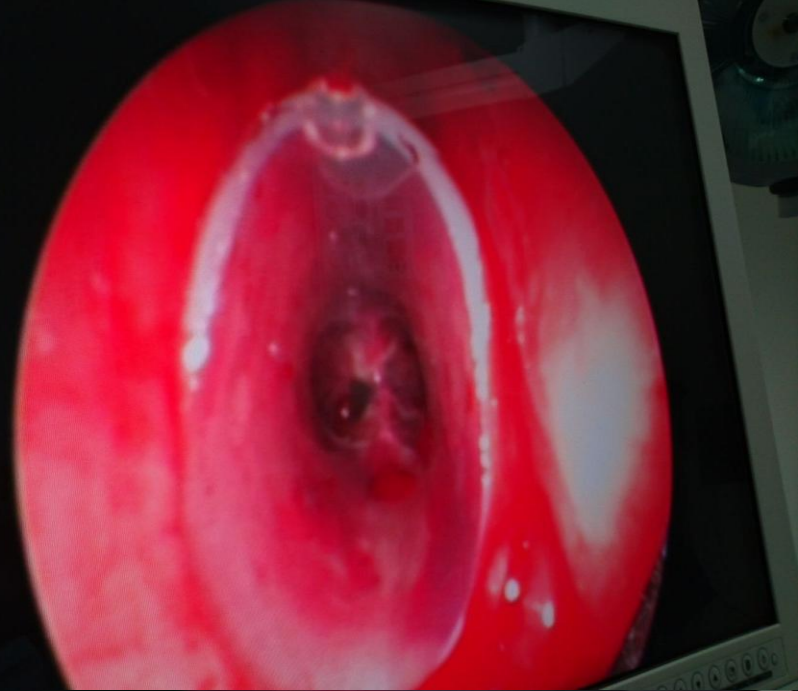
%100
W:350 C:60



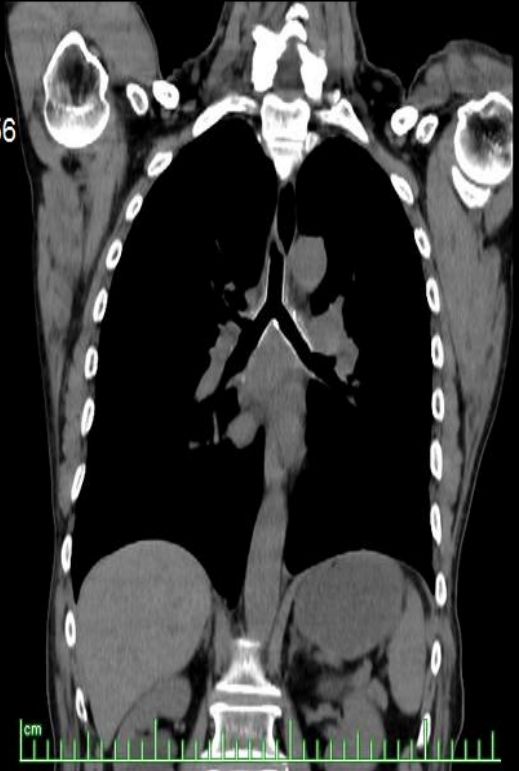HIKMET DONMEZ
069Y M
36109095272
1
16.11.2017 22:49:22
RESIM 37



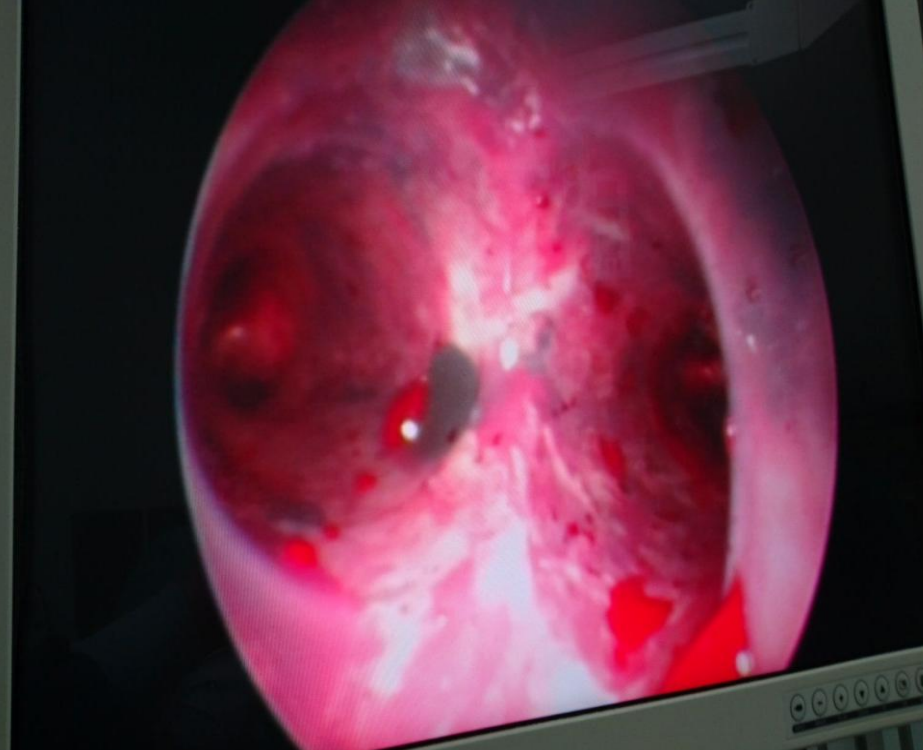
Ingenuity CT
CHEST



HIKMET DONMEZ
069Y M
36109095272
1
23.11.2017 20:42:56
RESIM 40



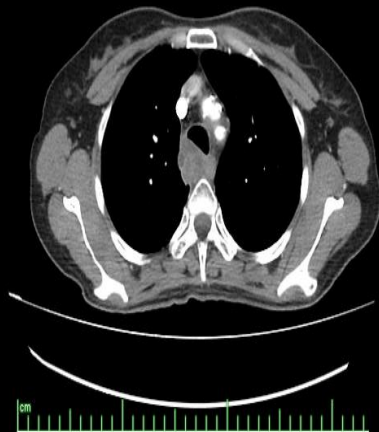Ingenuity CT
CHEST



%100

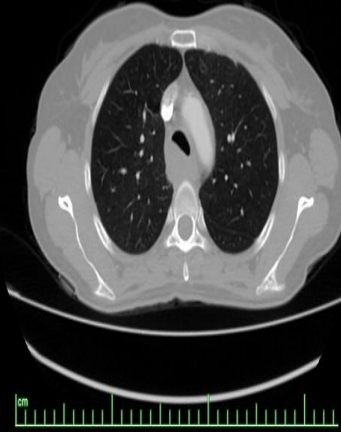OLGU 3 STENT VIDEO

ER DILEK
051Y F
24977075472
2
15.07.2015 09:26:28
RESIM 30



YEDIKULE GOGUS HASTALIKLARI E.A.H.

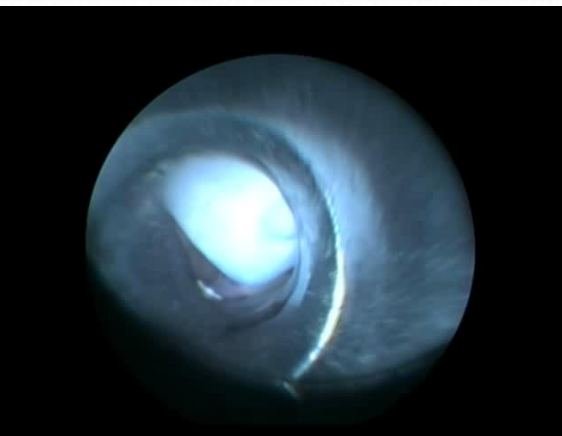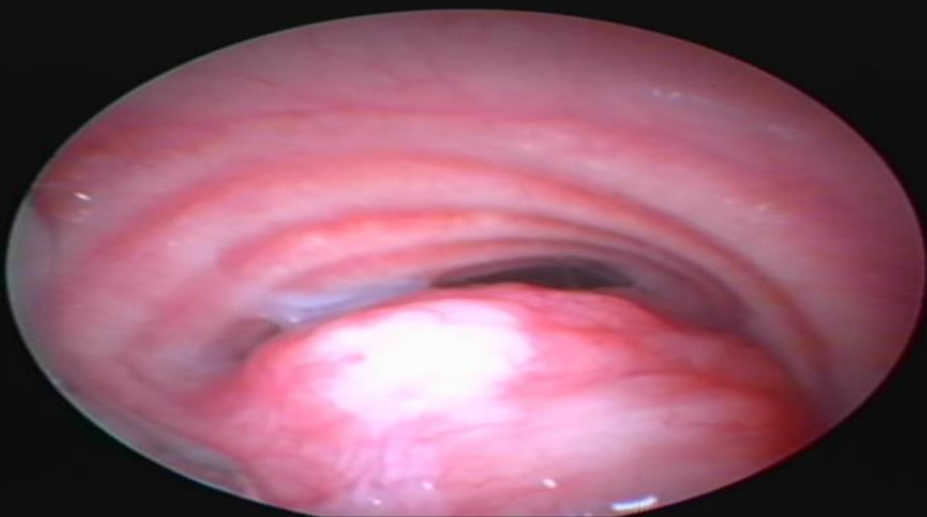
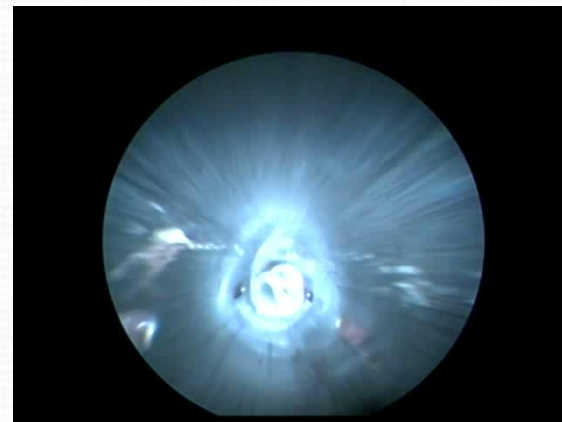
Alexion
CHEST
ER DILEK
051Y F
24977075472
2
15.07.2015 09:26:28
RESIM 32



%100
W:400 C:40

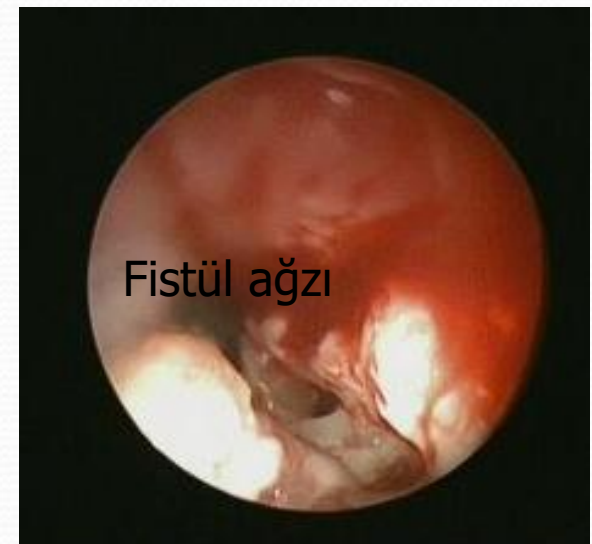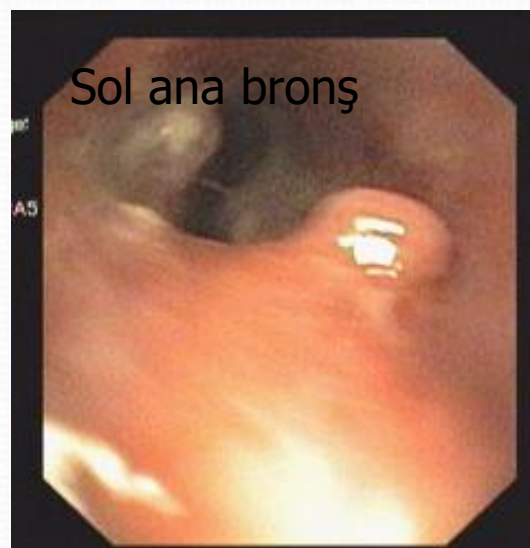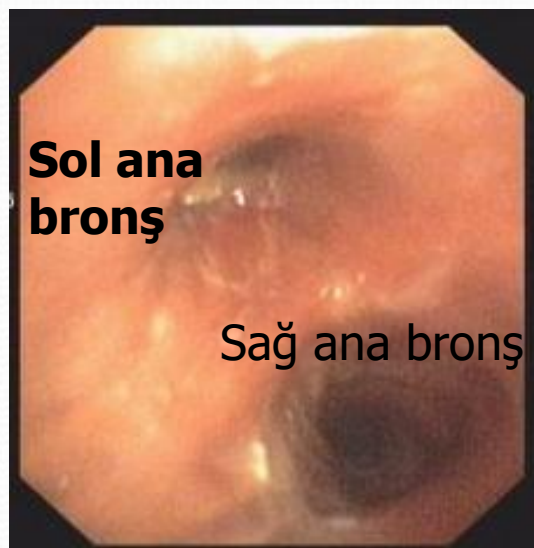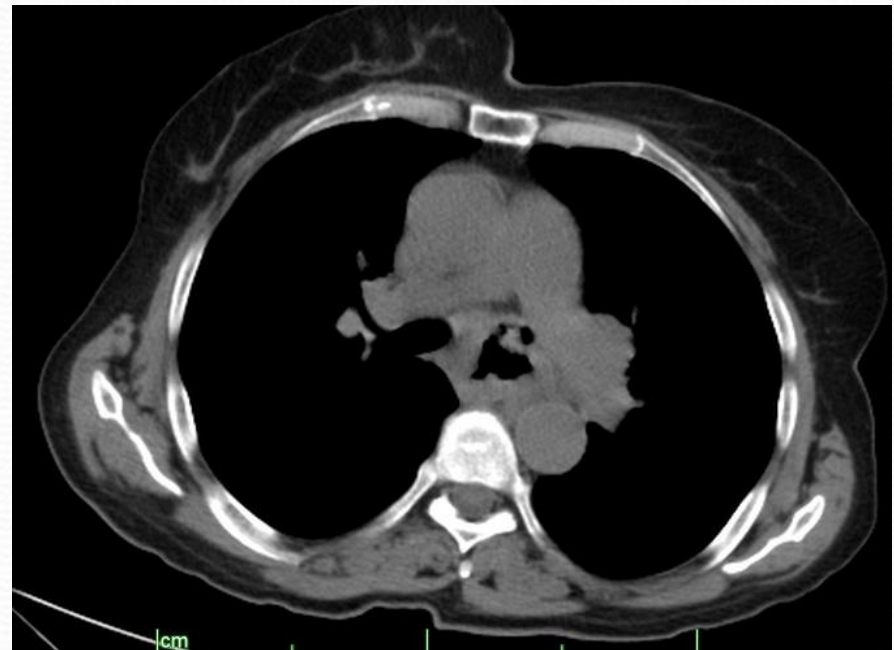
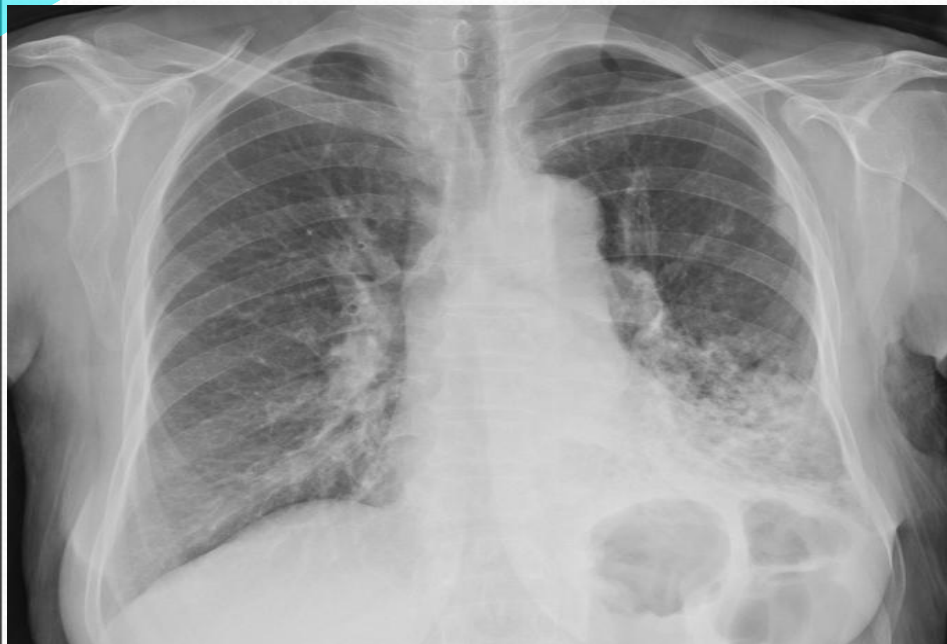YEDIKULE GOGUS HASTALIKLARI E.A.H.

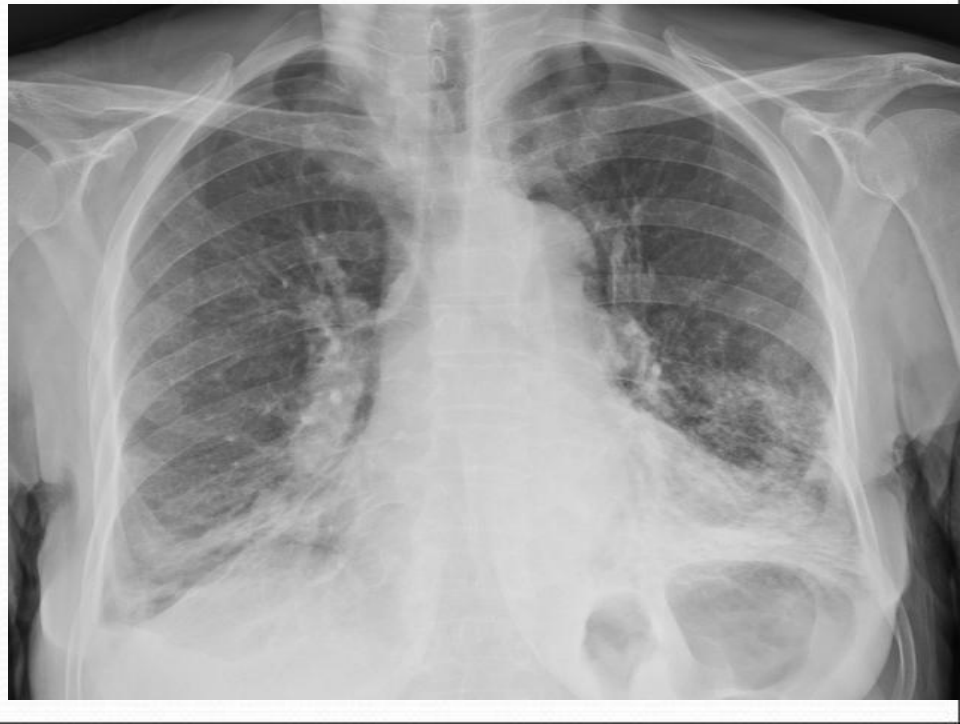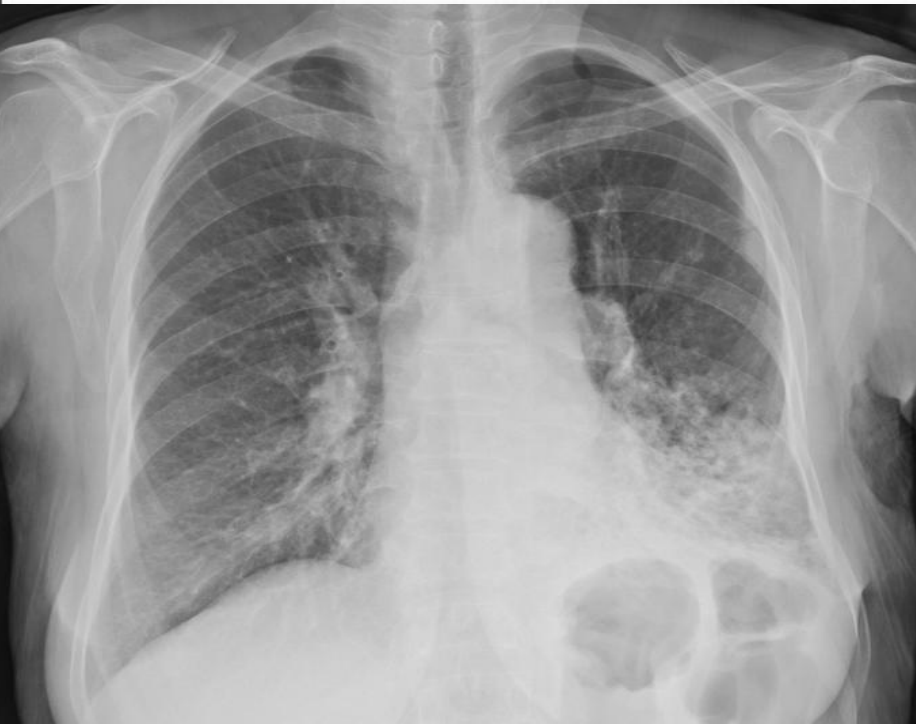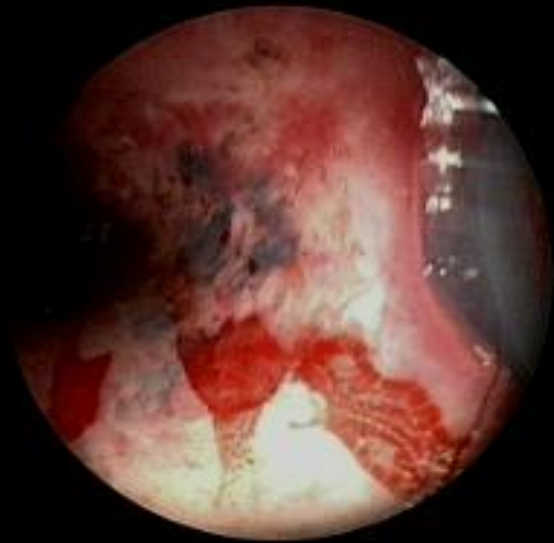
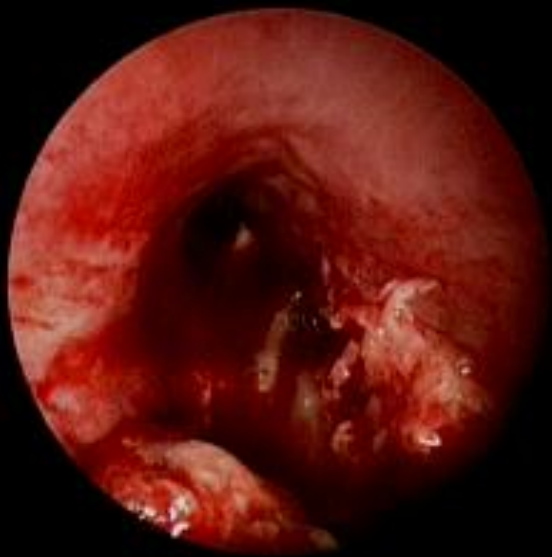Alexion
CHEST



%100
W:1699 C:-158

4.OLGU

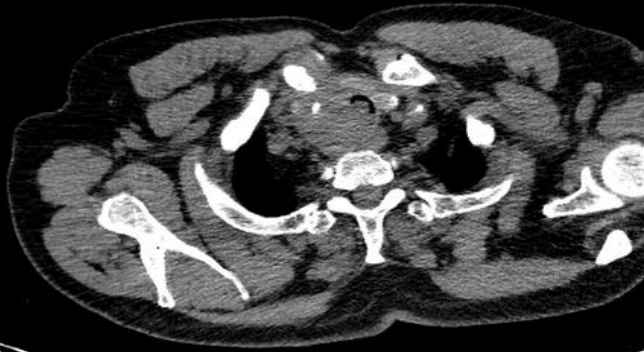



5.OLGU

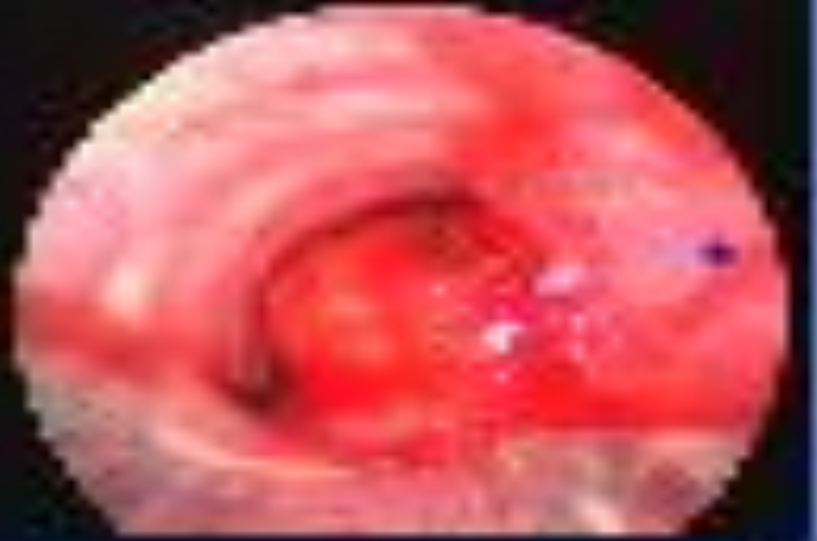
AZIZ BAYRAM
065Y M
61663363802
1
14.04.2017 10:00:31
RESIM 29

Ingenuity CT
CHEST



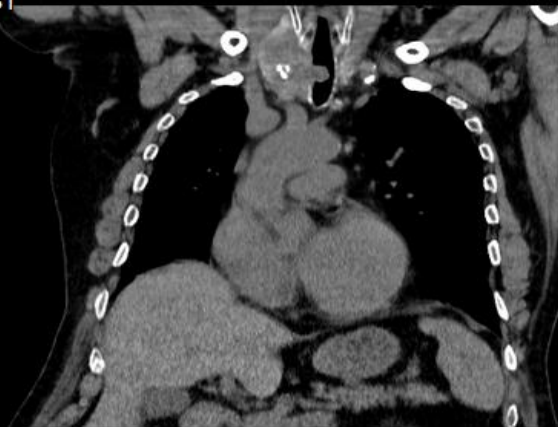%100
W:350 C:60

YEDIKULE GOG.HAST.VE GOG.CERRAHI E.A.H.



AZIZ BAYRAM
065Y M
61663363802
1
14.04.2017 10:00:31
RESIM 61

Ingenuity CT
CHEST

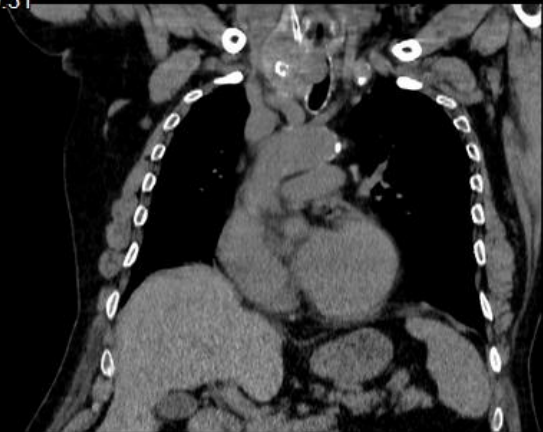

%100
W:350 C:60

YEDIKULE GOG.HAST.VE GOG.CERRAHI E.A.H.

AZIZ BAYRAM
065Y M
61663363802
1
14.04.2017 10:00:31
RESIM 60

Ingenuity CT
CHEST



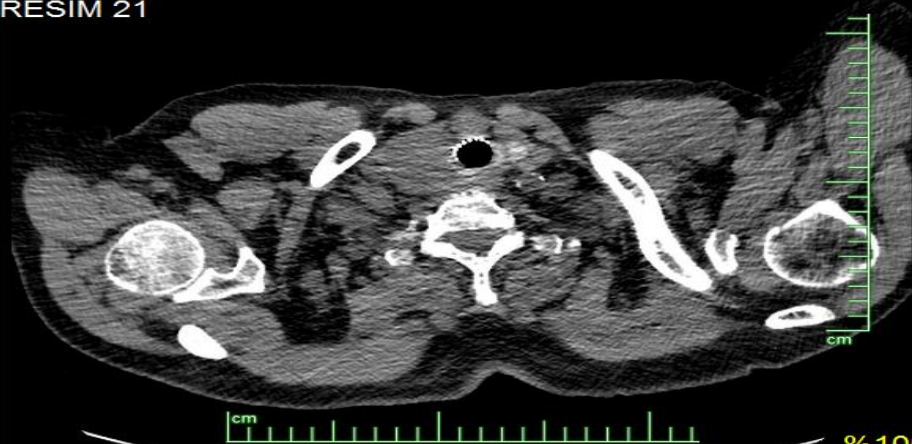
%100
W:350 C:60

YEDIKULE GOG.HAST.VE GOG.CERRAHI E.A.H.

5.OLGU

AZIZ BAYRAM
065Y M
61663363802
1
25.04.2017 14:31:41
RESIM 21

Ingenuity CT
CHEST

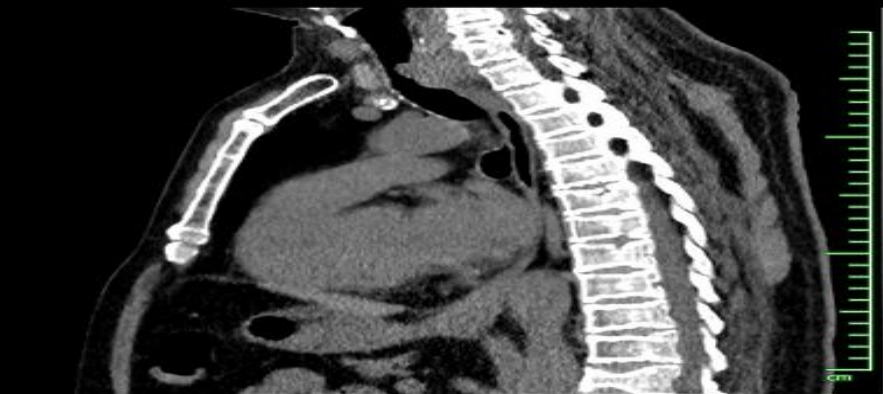


%100

YEDIKULE GOG.HAST.VE GOG.CERRAHI-E.A.H. W:350 C:60

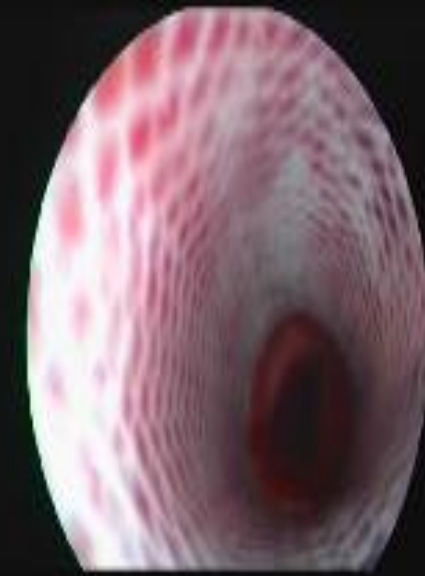
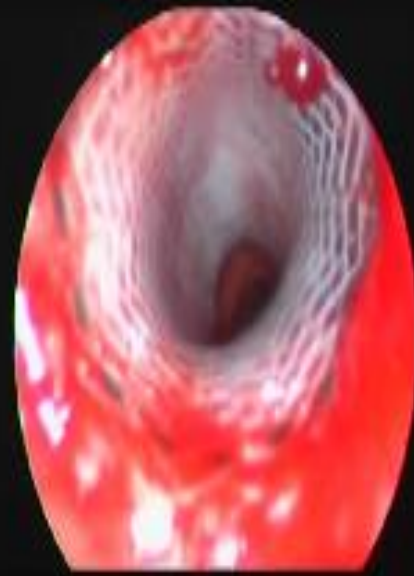
AZIZ BAYRAM
065Y M
61663363802
1
14.04.2017 10:00:31
RESIM 66

Ingenuity CT
CHEST



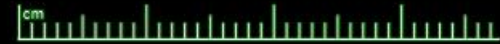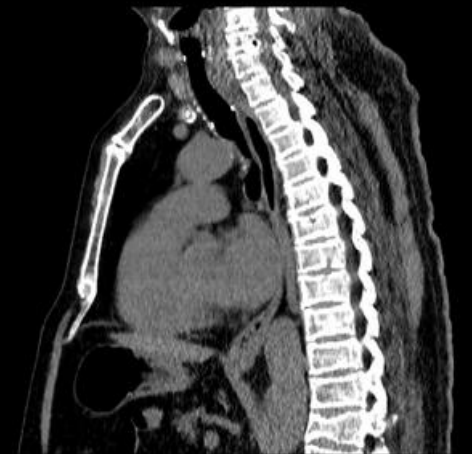%100

YEDIKULE GOG.HAST.VE GOG.CERRAHI E.A.H. W:350 C:60



AZIZ BAYRAM
065Y M
61663363802
1
25.04.2017 14:31:41
RESIM 67

Ingenuity CT
CHEST



%100

YEDIKULE GOG.HAST.VE GOG.CERRAHI E.A.H. W:350 C:60

BRONŞİAL Y STENT

Oki stent application in different indications: Six cases.

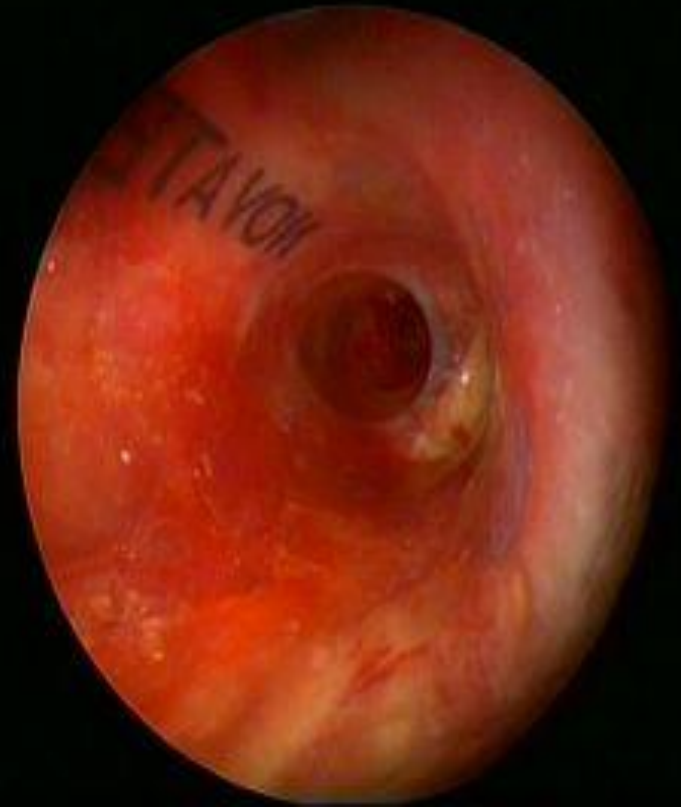Özgül MA, Çetinkaya E, Çörtük M, Tanrıverdi E, Yıldırım BZ, Balci MK, Issaka A, Özgül G.

Clin Respir J. 2016 Jun 22. doi: 10.1111/crj.12521

1)

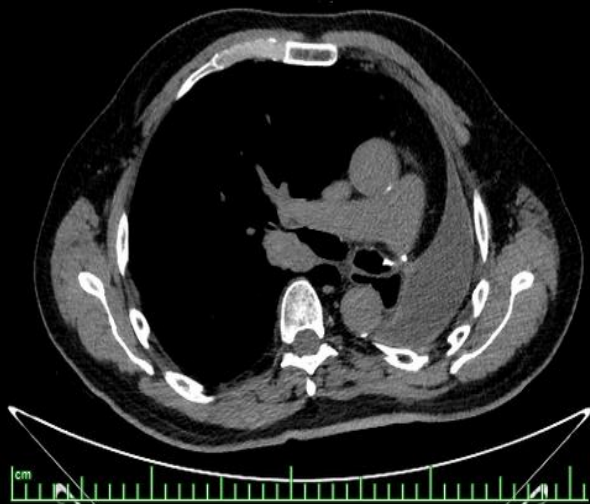


2)



MAHMUT KACAN
062Y M
44740108244
1
04.11.2017 14:54:54
RESIM 67

Ingenuity CT
CHEST

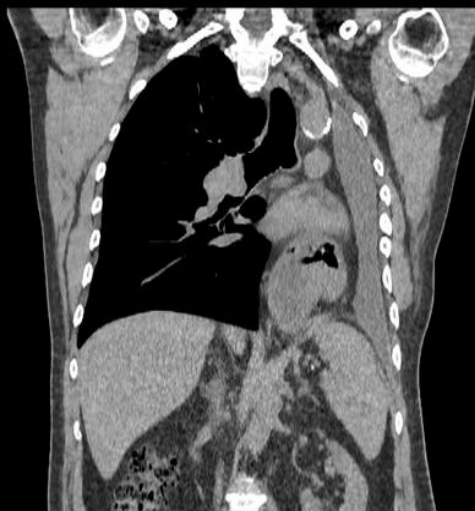

%100
W:350 C:60

YEDIKULE GOG.HAST.VE GOG.CERRAHI'E.A.H.

MAHMUT KACAN
062Y M
44740108244
1
04.11.2017 14:54:54
RESIM 46

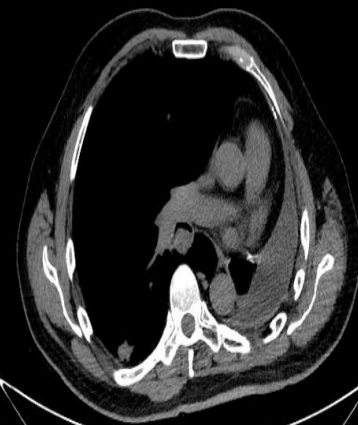Ingenuity CT
CHEST



%100

MAHMUT KACAN
062Y M
44740108244
1
04.11.2017 14:54:54
RESIM 76

Ingenuity CT
CHEST

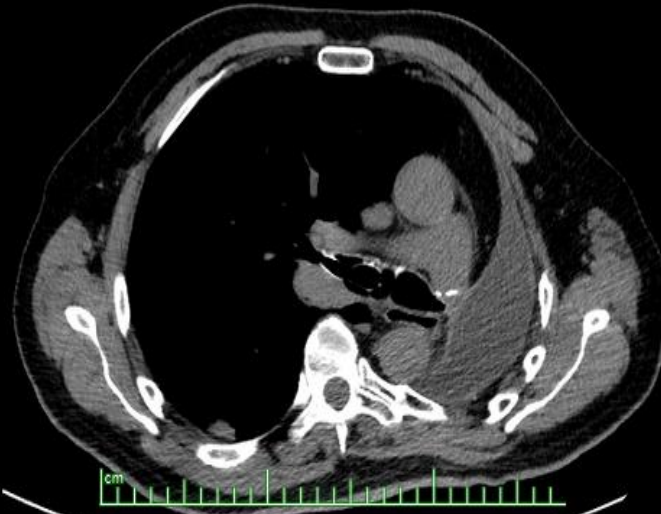

%100
W:350 C:60

YEDIKULE GOG.HAST.VE GOG.CERRAHI'E.A.H.

MAHMUT KACAN
062Y M
44740108244
1
07.11.2017 21:58:40
RESIM 60

Ingenuity CT
CHEST

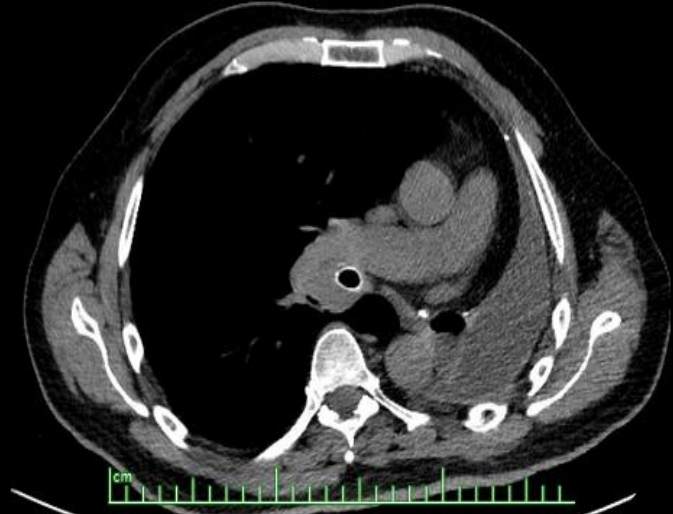

YEDIKULE GOG.HAST.VE.GOG.CERRAHI E.A.H.

%100
W:350 C:60

MAHMUT KACAN
062Y M
44740108244
1
07.11.2017 21:58:40
RESIM 68

Ingenuity CT
CHEST

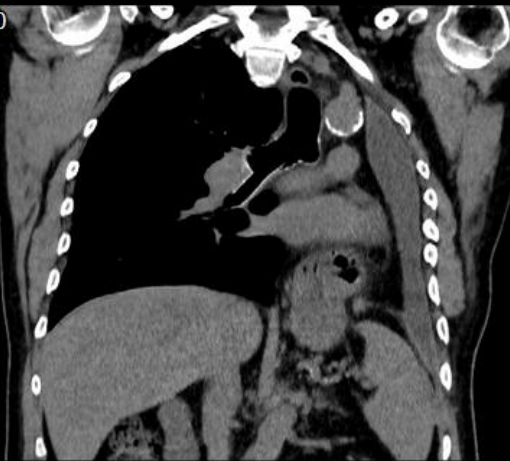

YEDIKULE GOG.HAST.VE.GOG.CERRAHI E.A.H.

%100
W:350 C:60

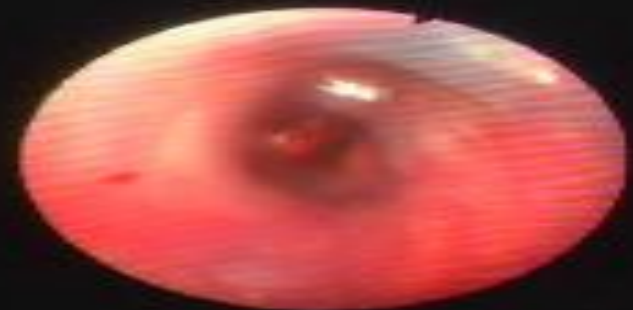
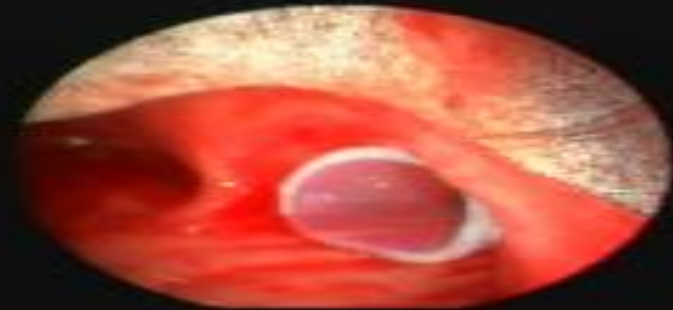
MAHMUT KACAN
062Y M
44740108244
1
07.11.2017 21:58:40
RESIM 43

Ingenuity CT
CHEST

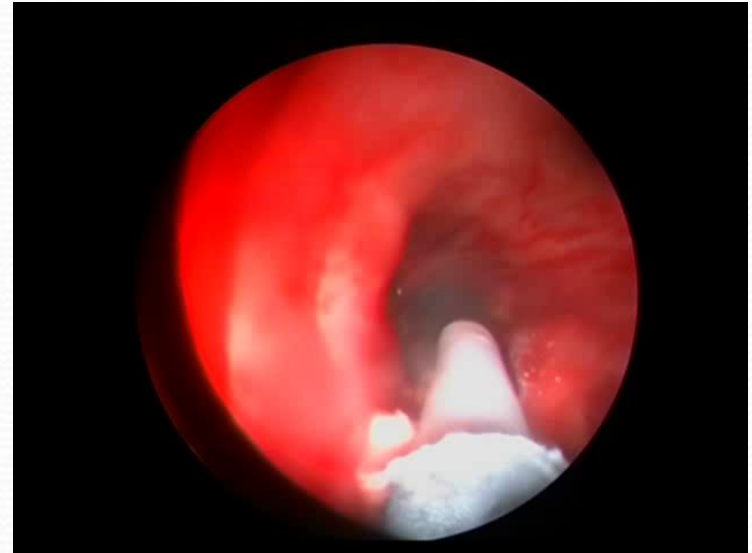
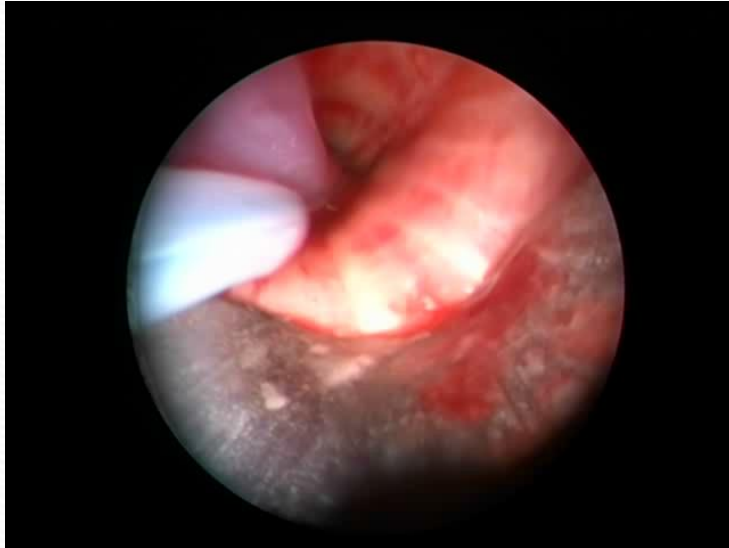


YEDIKULE GOG.HAST.VE.GOG.CERRAHI E.A.H.

%100
W:350 C:60



6.OLGU VIDEO



STENT

- **Benign**

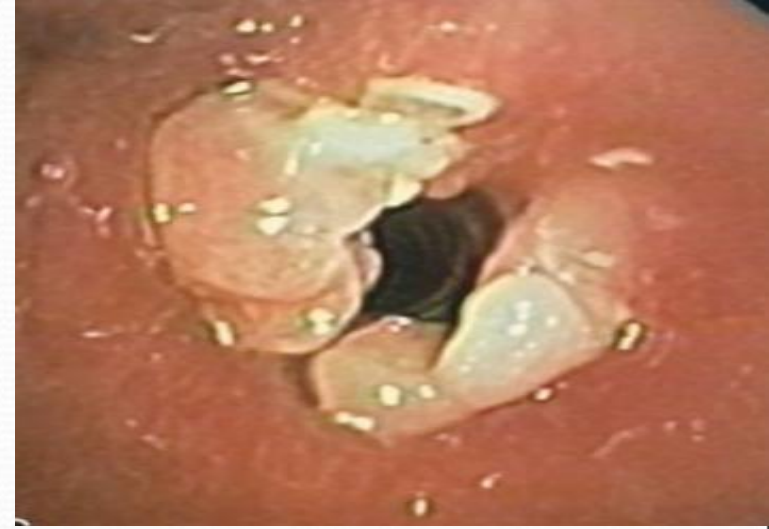- Post-entübasyon stenozu
- Trakeobronkomalazi
- Post-anastomozlar (Akciğer transplantasyonu, akciğer rezeksiyonu)
- Sistemik hastalıklar (Infiltratif hastalıklar, Vaskülit
- TB, tekrarlayıcı polikondrit)
- Dış yapılardan bası (Damarsal veya mediastinal)

STENOZ MORFOLOJİK ÖZELLİKLERİ

- 1. Granulasyon dokusu

Basit şeklidir.

Trakeal duvar olaya katılmaz.



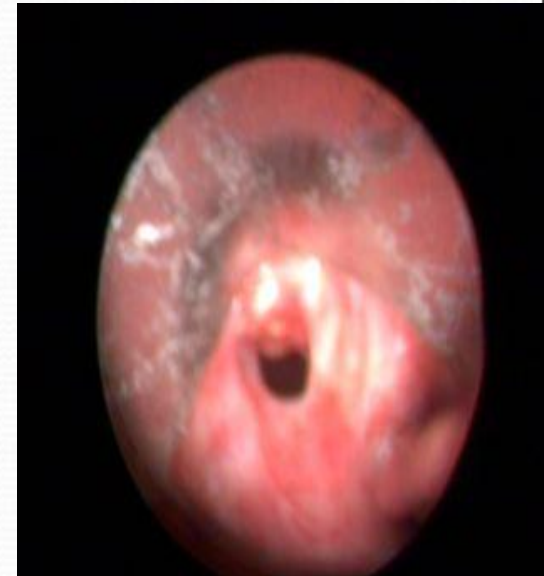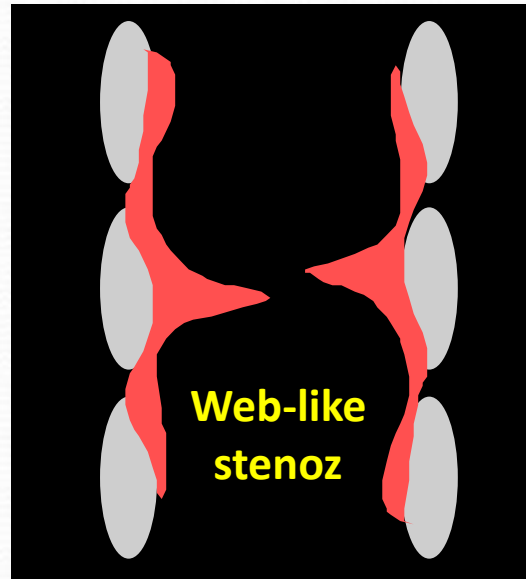
- 2. Web like stenoz

Mukozal hastalık

Membranöz konsantrik stenoz

Darlık segmenti < 1 cm,

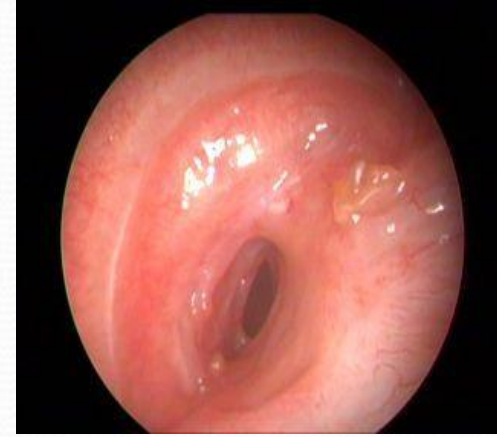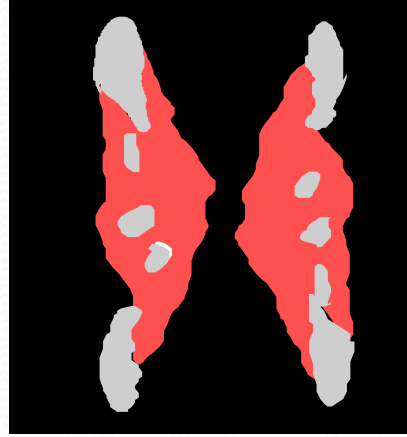Kartilaj tutulumu yok



STENOZ MORFOLOJİK ÖZELLİKLERİ

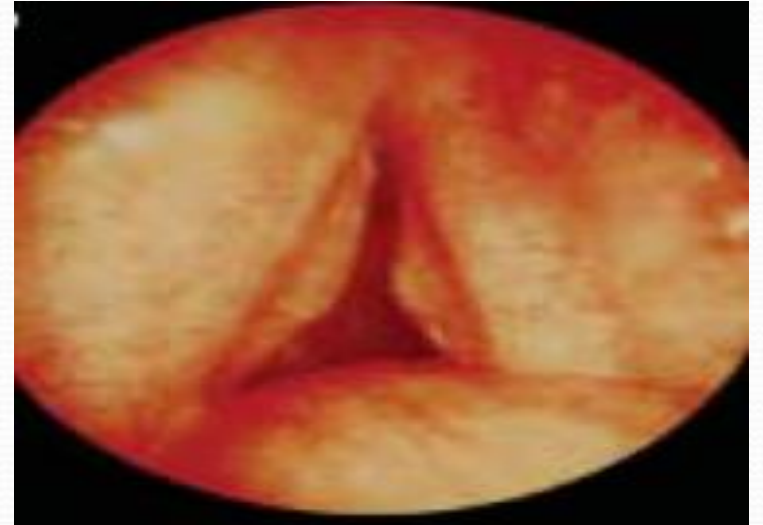
- 3. Kompleks tip

İntramural hastalık
Darlık segmenti > 1 cm
Kartilaj tutulumu var
Malazi



- 4. A shape trakeal stenoz


Genelde trakeostomi sonrası görülür.





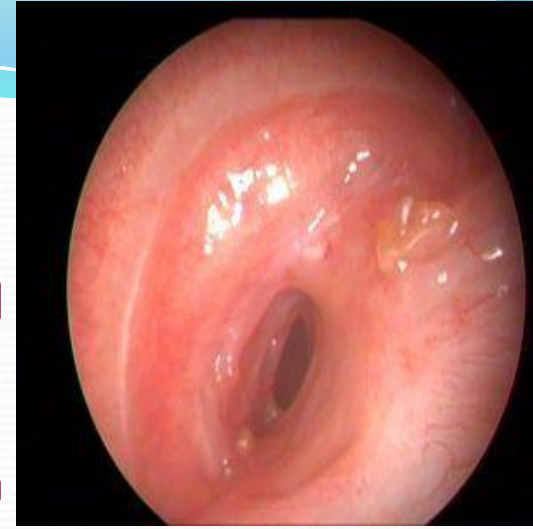

TEDAVİ

Bronkoskopik tedavi

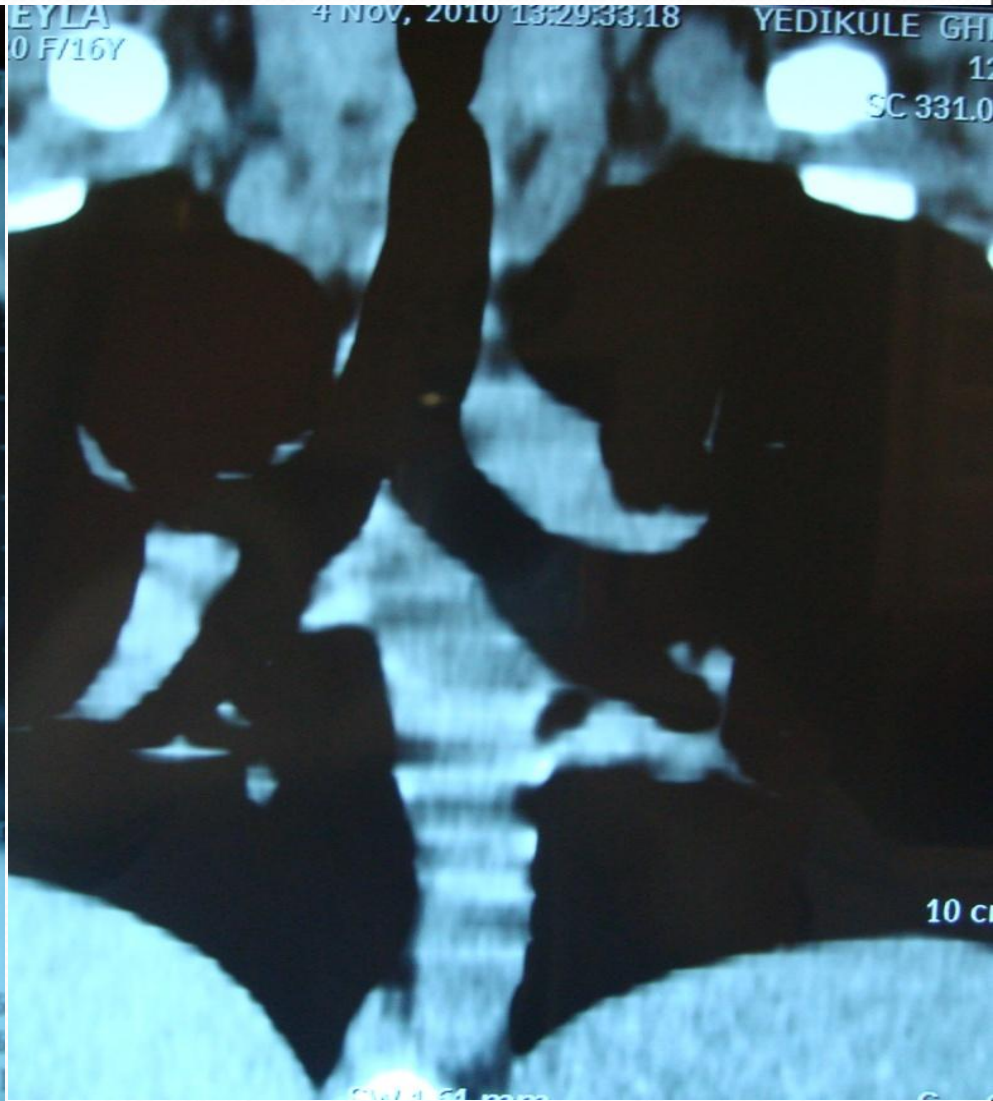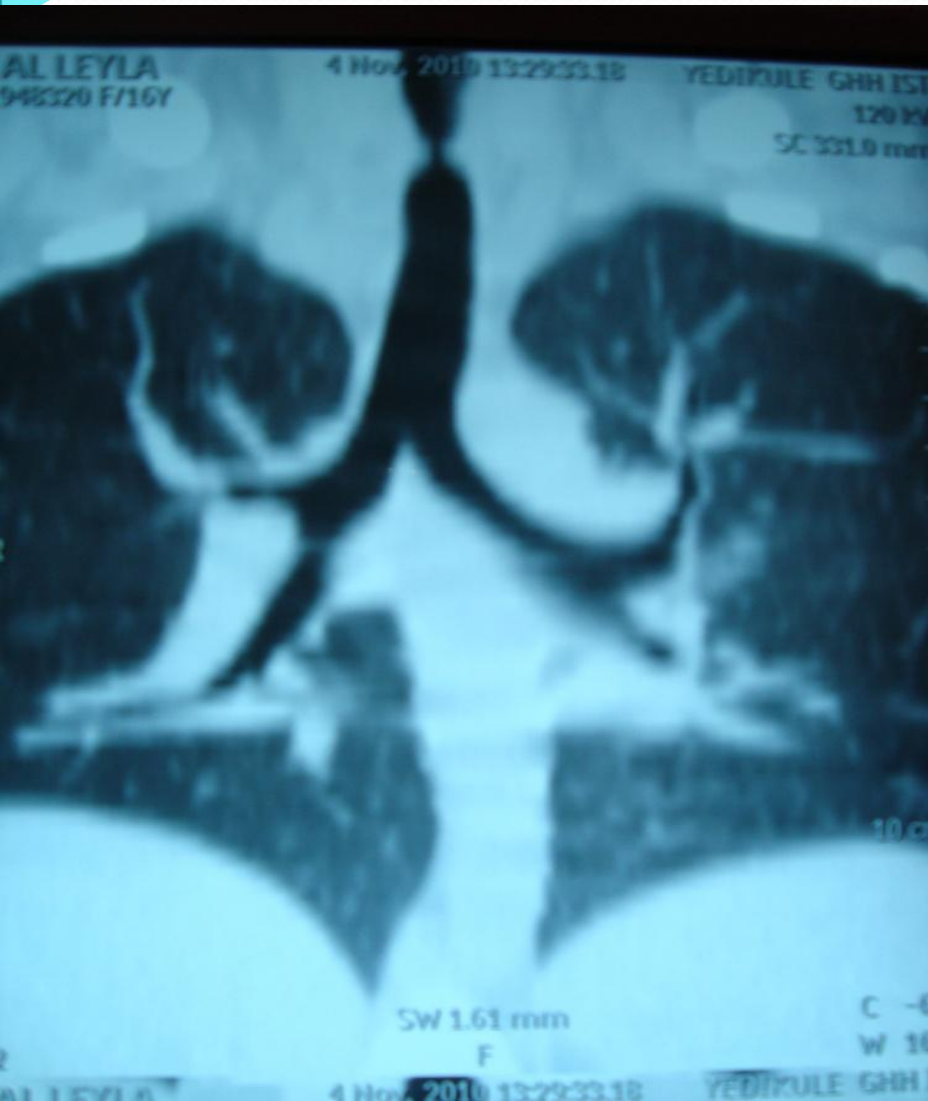
- Dilatasyon
- Sıcak yöntemler
- Soğuk yöntemler
- Brakiterapi
- Stent
- Stenotik silikon stent
- Montgomery T tüp
- Cerrahi

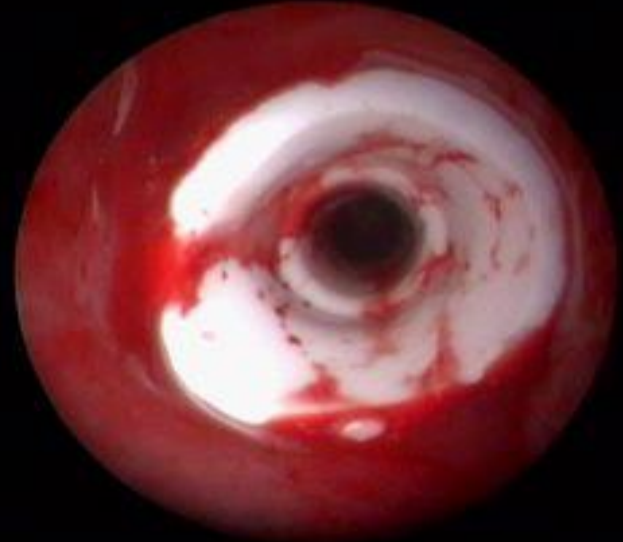
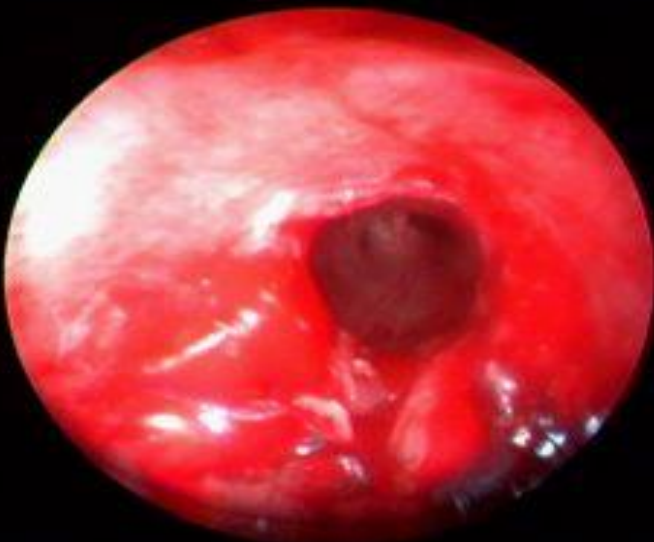
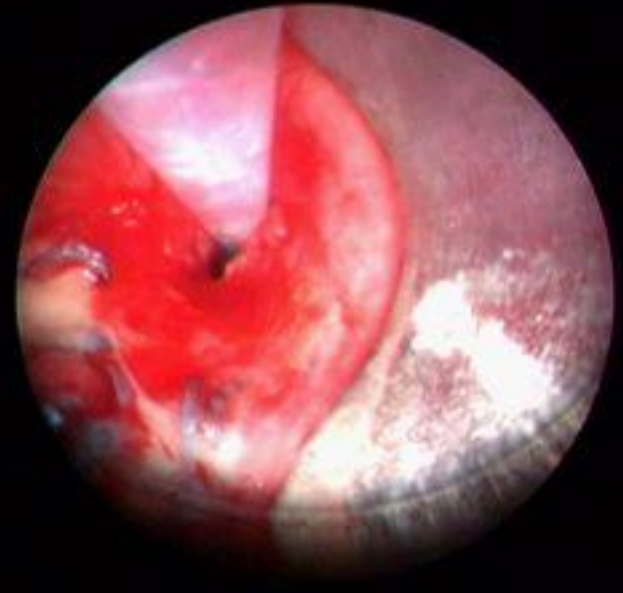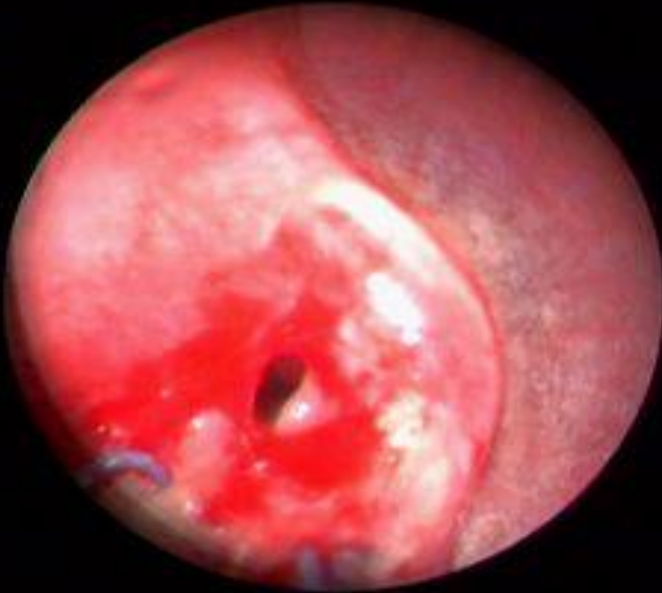Kartilaj kaybının desteklenmesi

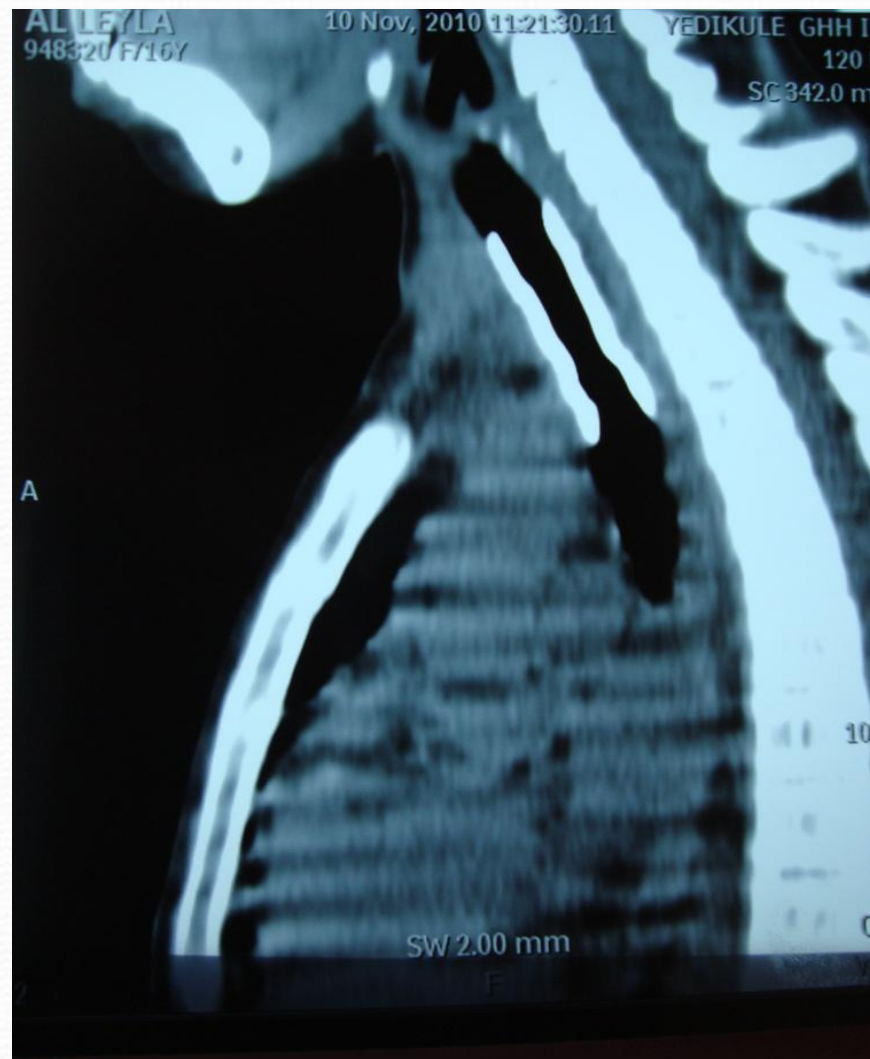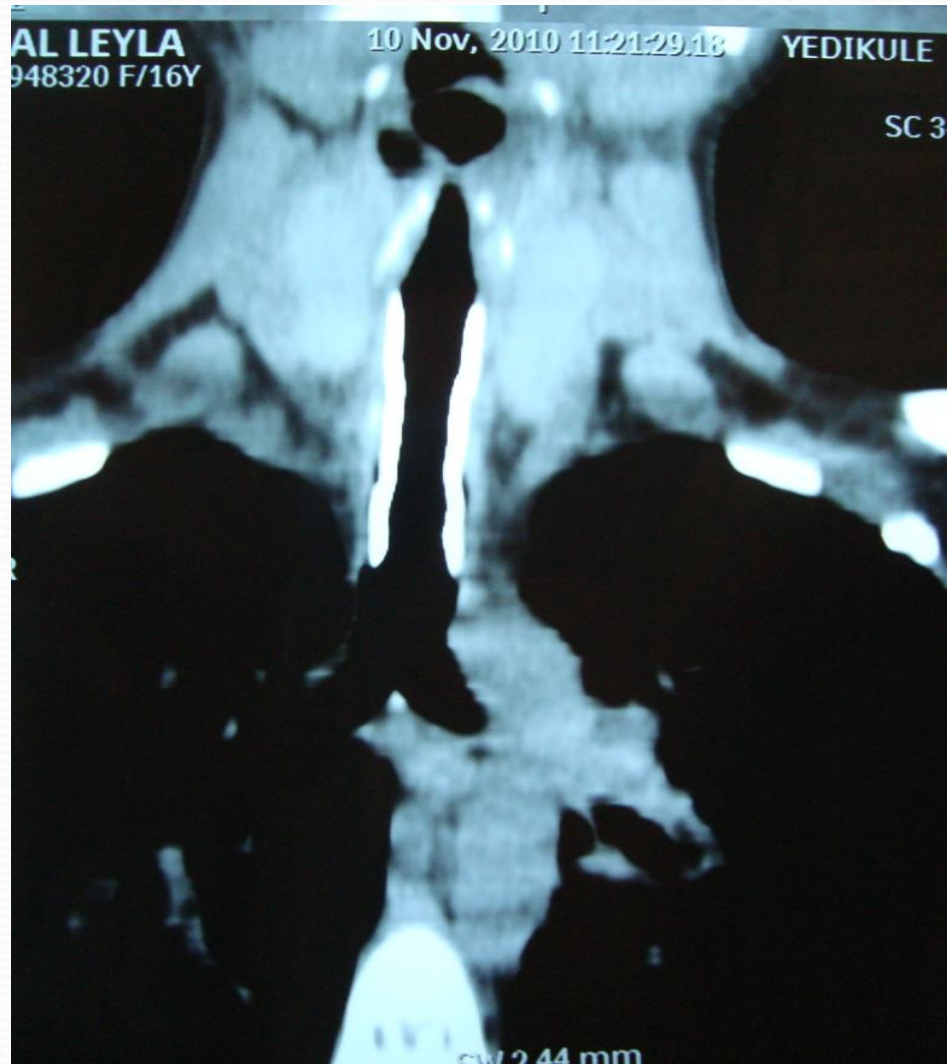


7.OLGU

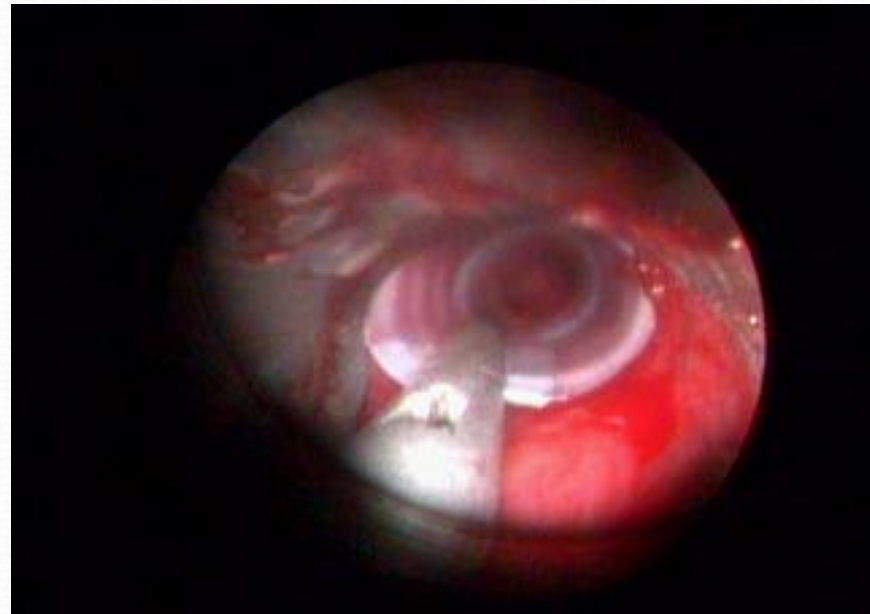
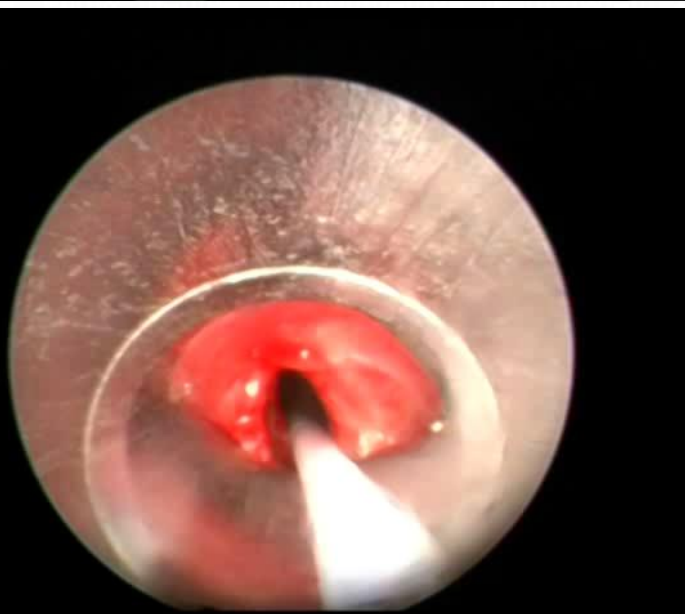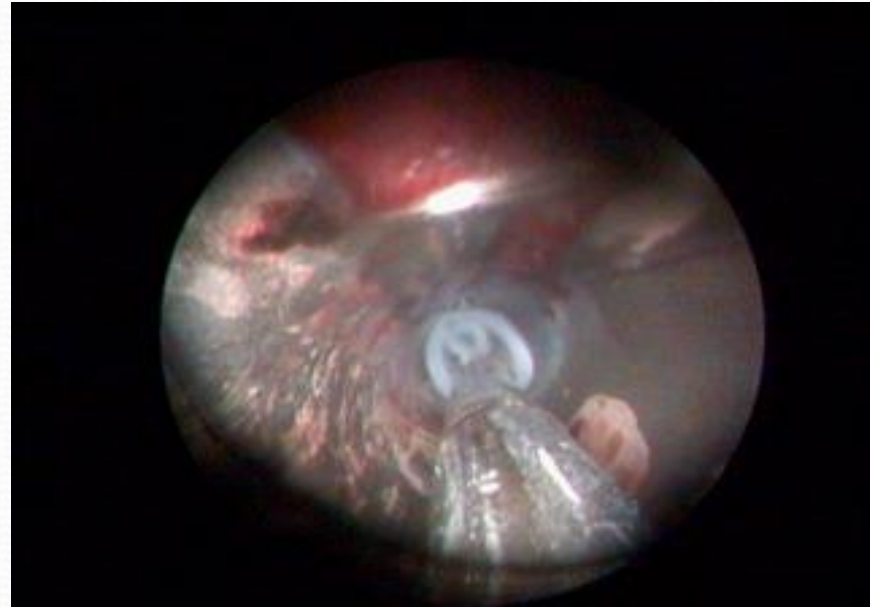
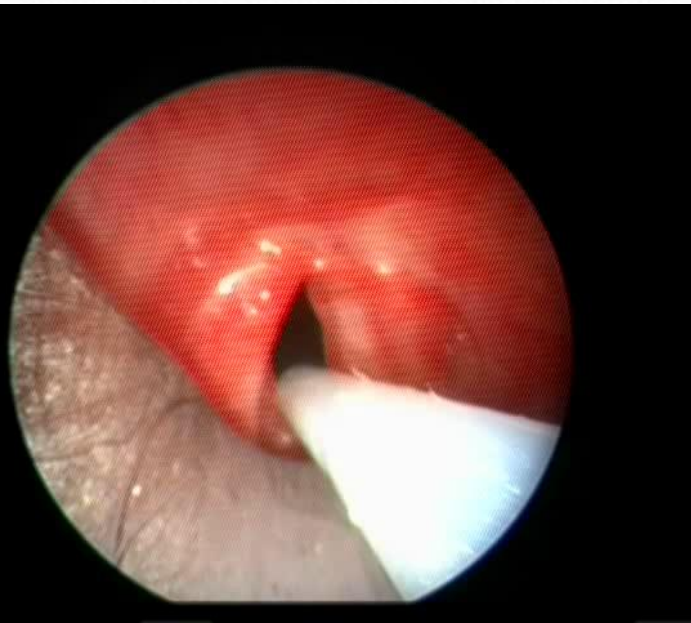




7.OLGU

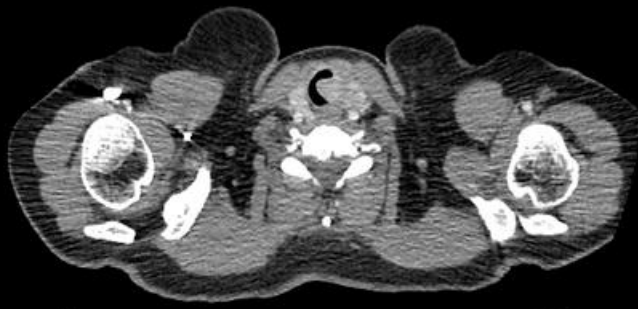

OLGU 8 VIDEO



9.OLGU


BATCIK FERIDE
041Y F
28394585712
1
07.10.2015 09:44:46
RESIM 1



YEDIKULE GOGUS HASTALIKLARI E.A.H.

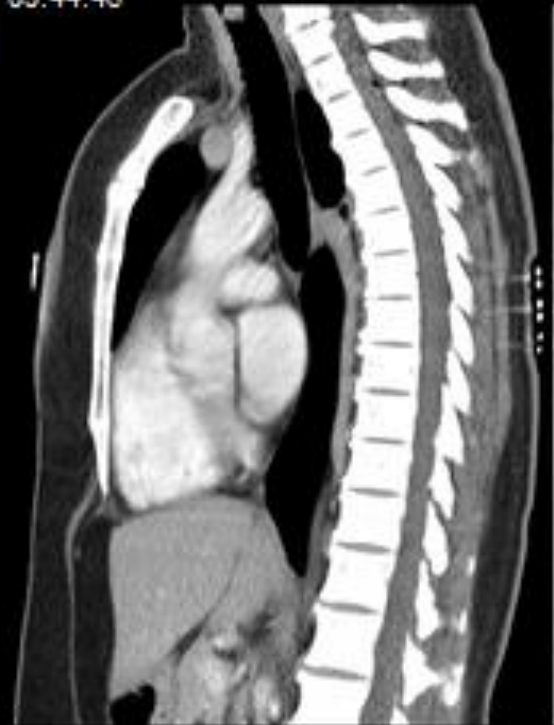BATCIK FERIDE
Ale: 041Y F
CHE 28394585712
1

07.10.2015 09:44:46
RESIM 36



%
W:400 C

Alexion
CHEST

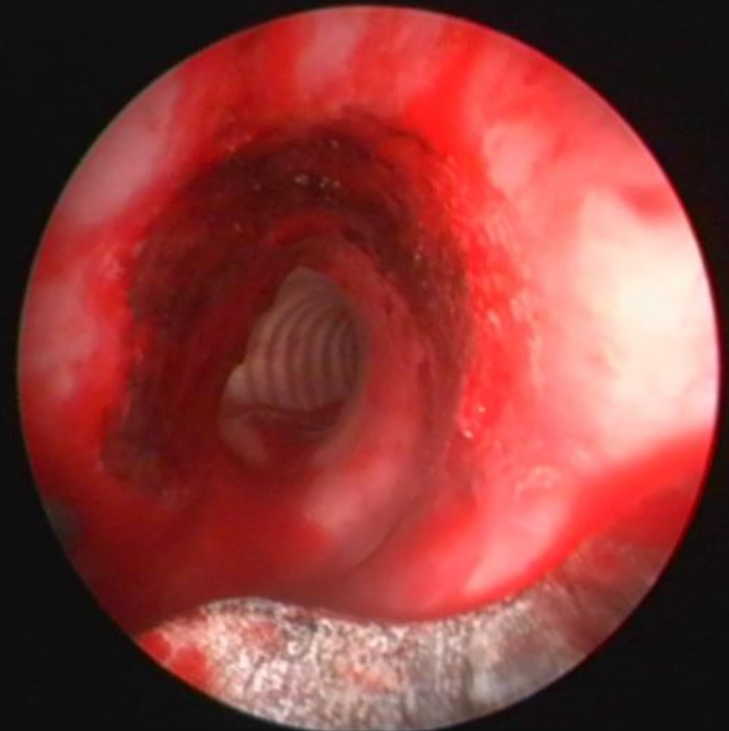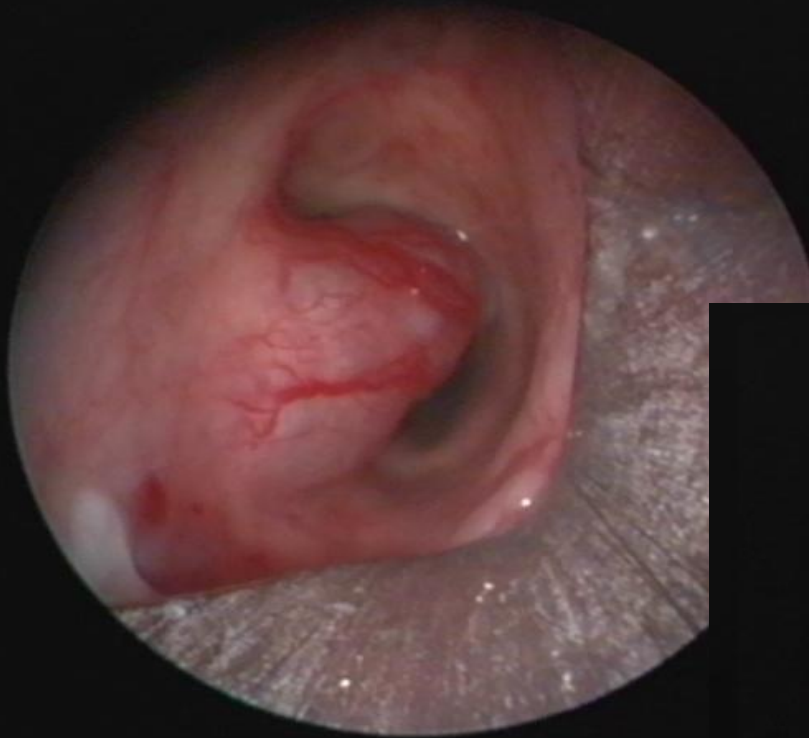


%100

9.OLGU VIDEO

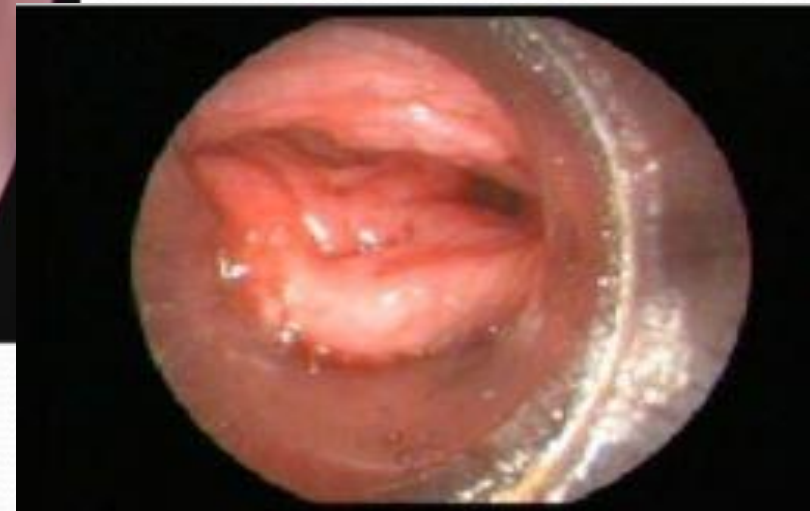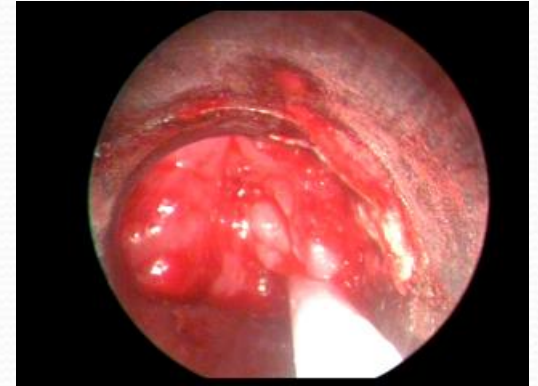
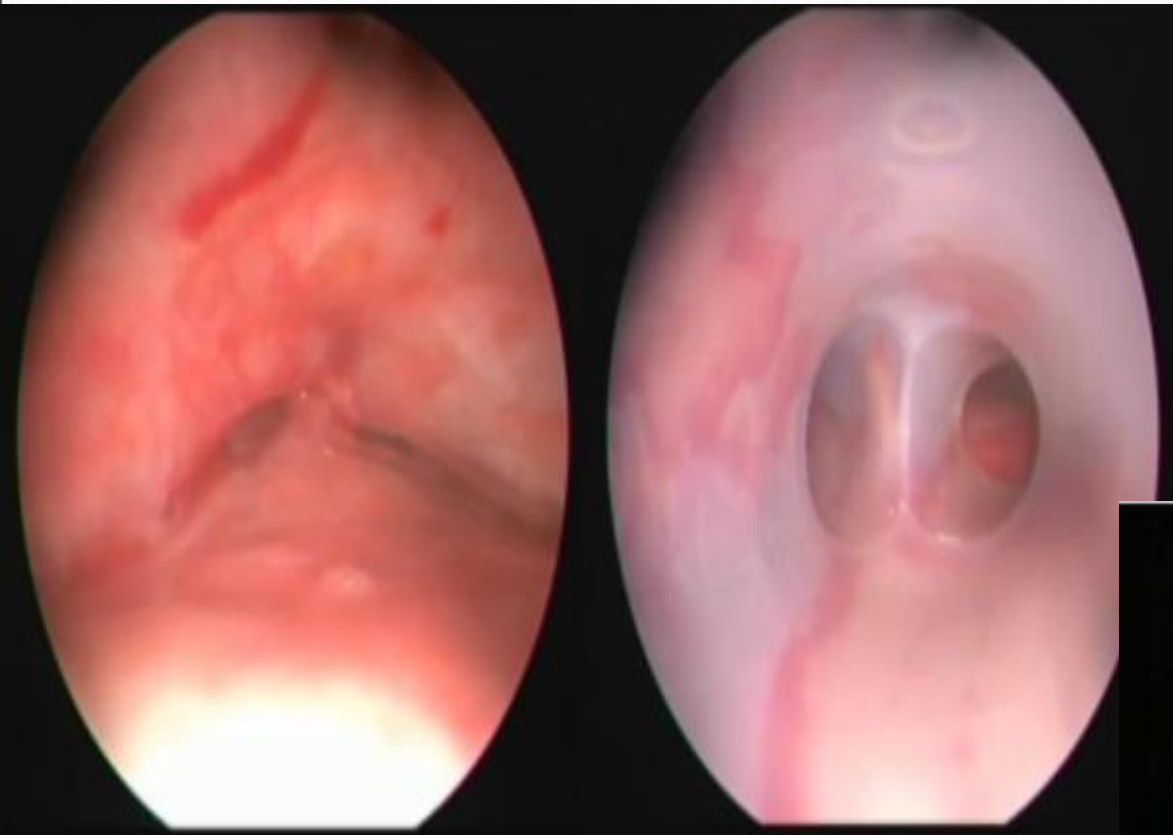


tiroid doku video.mpg



Our Experience on Silicone Y-Stent for Severe COPD Complicated With Expiratory Central Airway Collapse.

Ozgul MA, Cetinkaya E, Cortuk M, Iliaz S, Tanriverdi E, Gul S, Ozgul G, Onaran H, Abbasli K, Dincer HE.
J Bronchology Interv Pulmonol. 2017 Apr;24(2):104-109. doi: 10.1097/LBR.0000000000000346





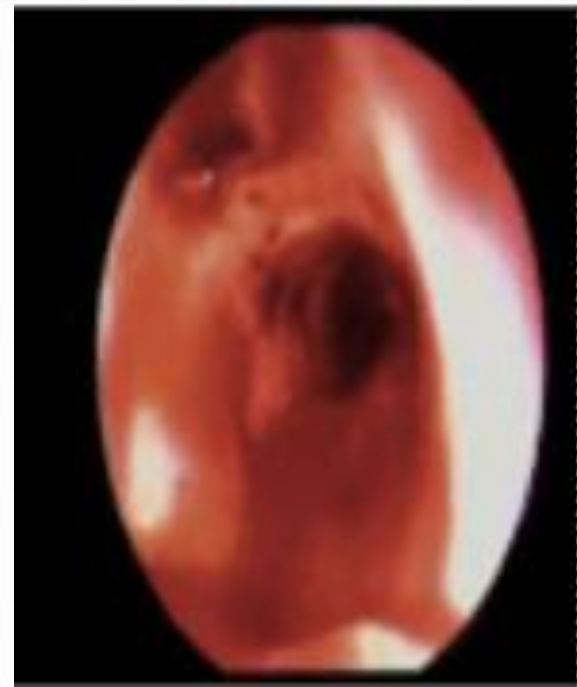
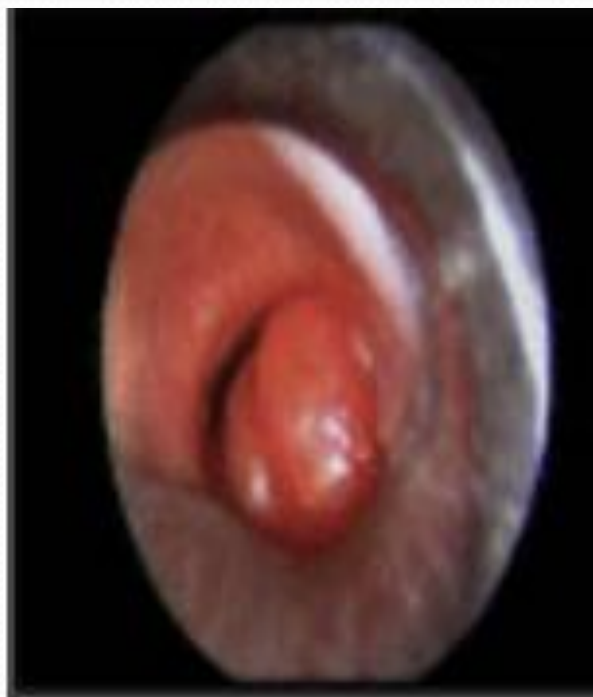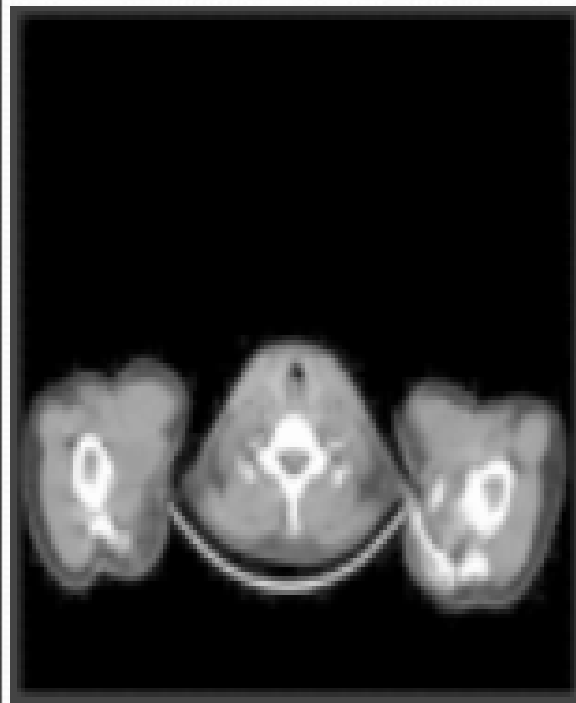Respiratory Medicine Case Reports

journal homepage: www.elsevier.com/locate/rmcr

Case report

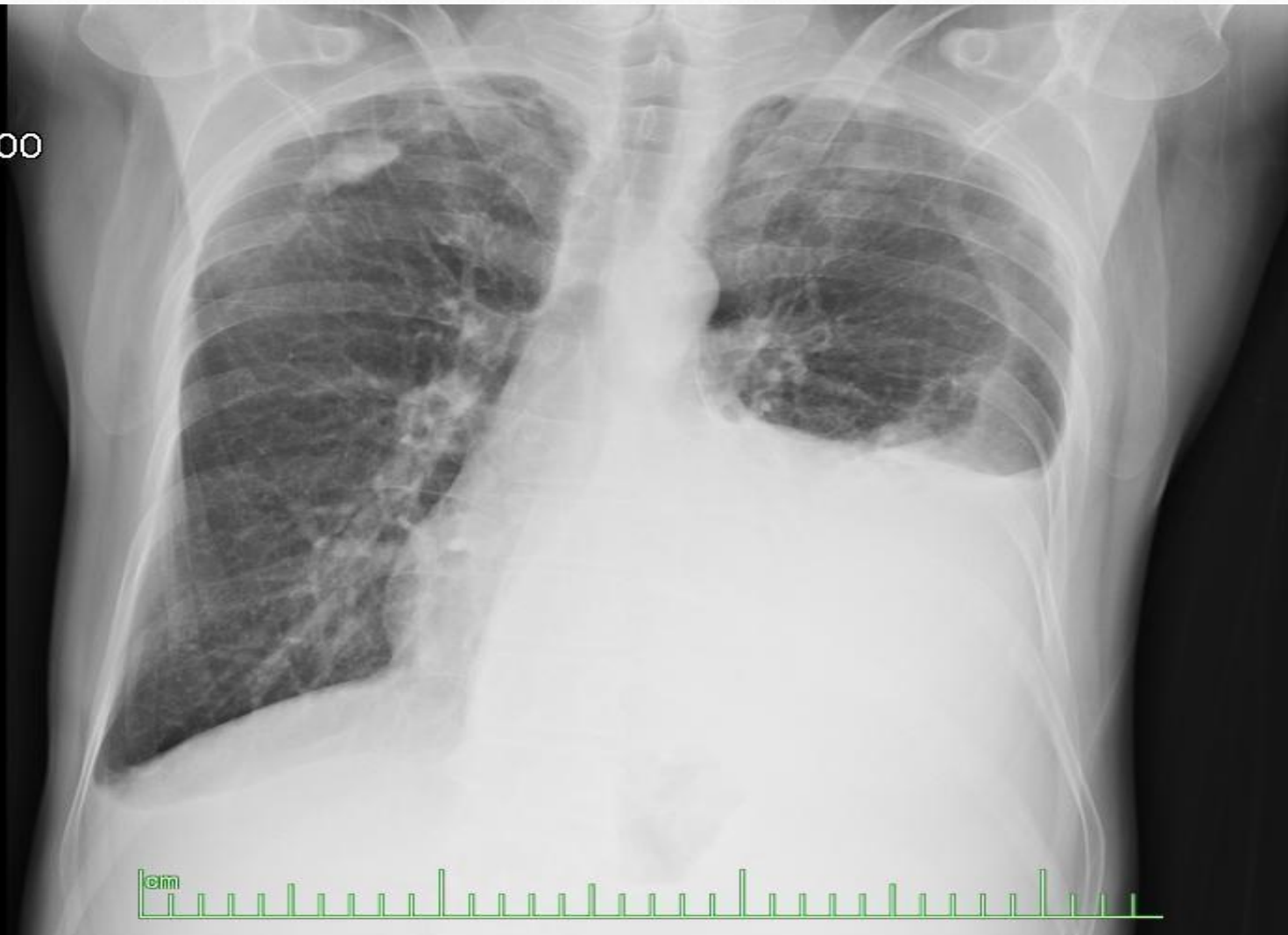A rare tumor of trachea: Inflammatory myofibroblastic tumor diagnosis and endoscopic treatment

Mehmet Akif Özgül ^a, Ümran Toru ^{b, *}, Murat Acat ^c, Güler Özgül ^d, Erdoğan Çetinkaya ^a,
H. Erhan Dinçer ^e, Derya Özden Omaygenç ^f, Halide Nur Ürer ^g

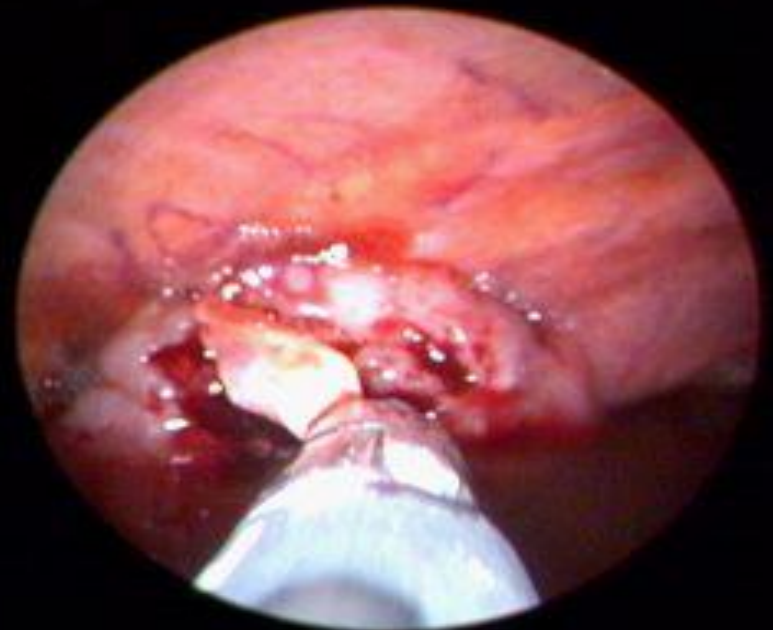
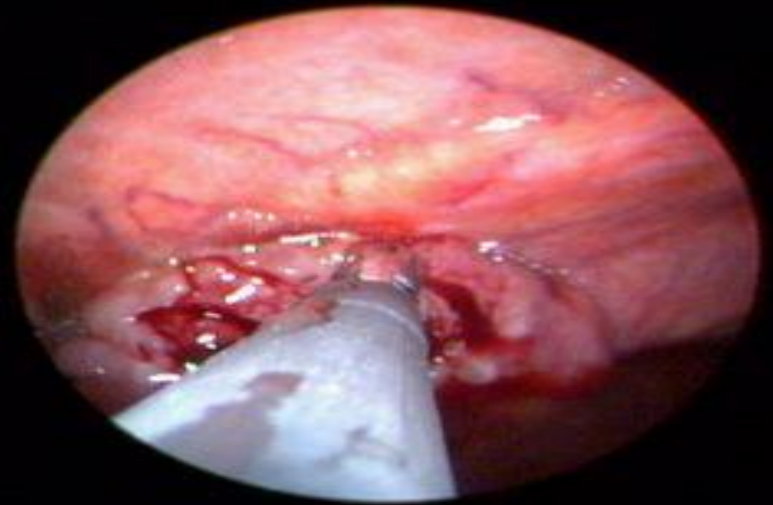
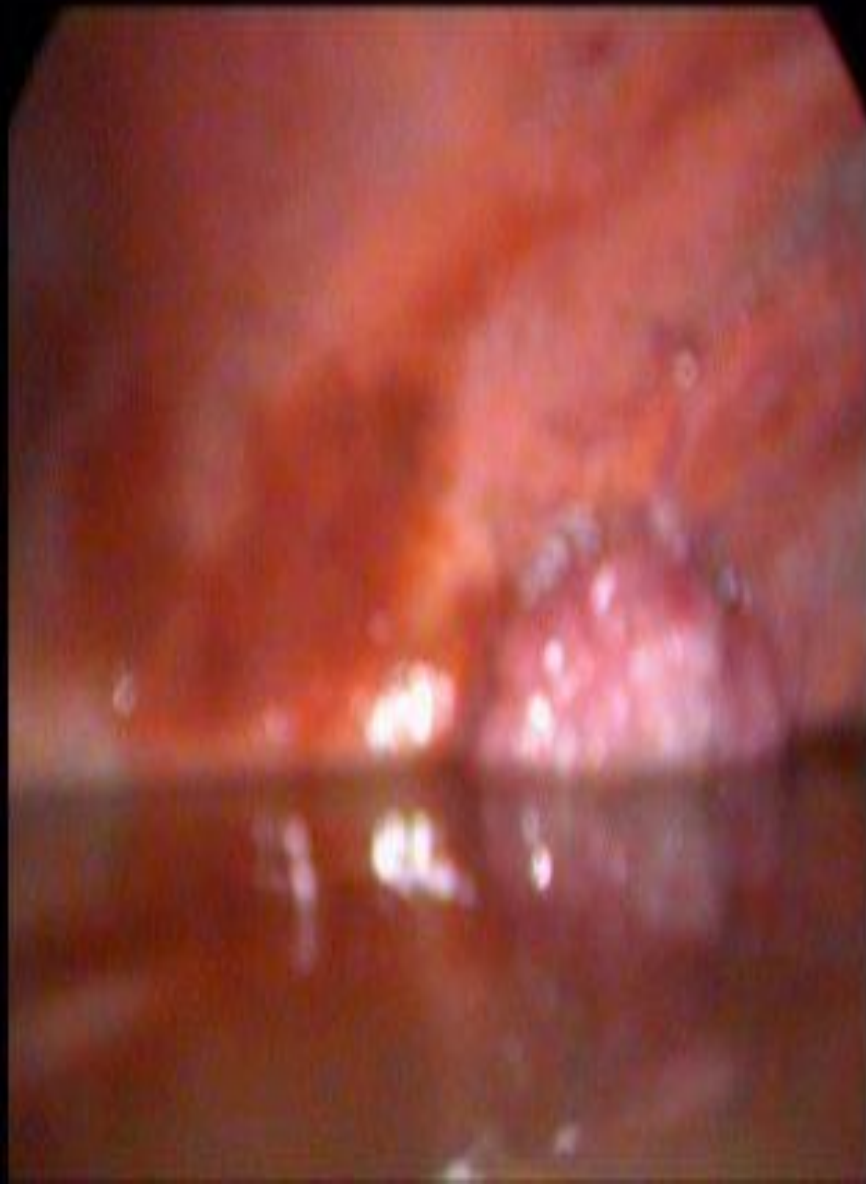12.OLGU

CELAL AGYAR
M
1500495
04.11.2013 00:00:00
RESIM 1



12.OLGU



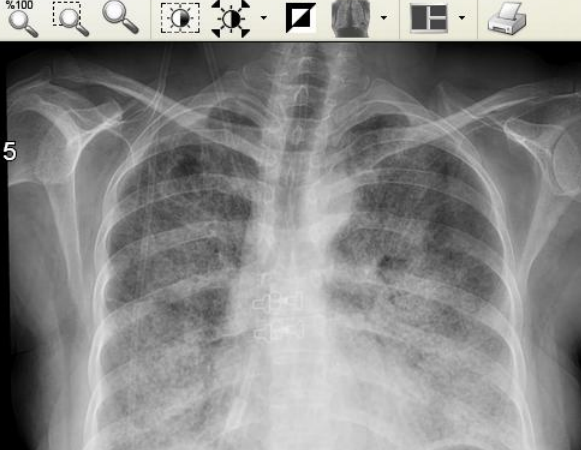
13.OLGU

Advision Dicom Görüntüleyici

Dosya Seçenekler Yardım

Dosya GULUMSER AYSU [DX] 24.12.2013

Görünüm Araçlar Seçenekler



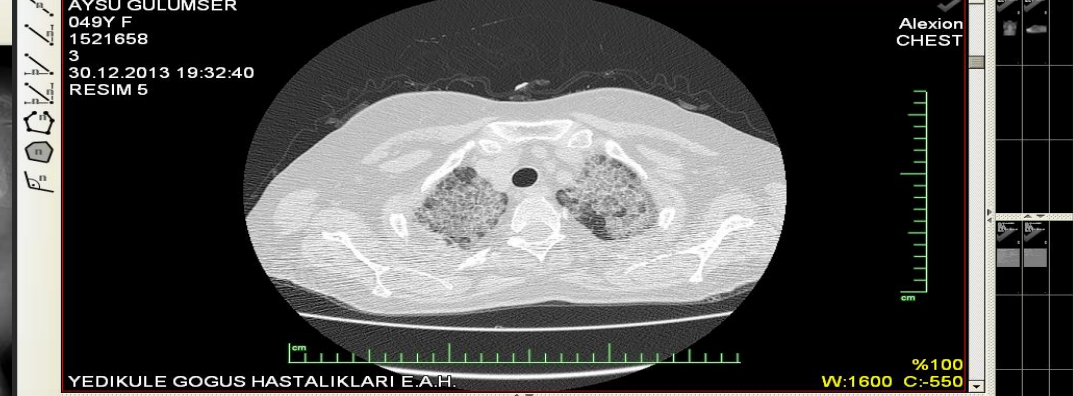GULUMSER AYSU
F
1521658
24.12.2013 14:20:15
RESIM 2

Advision Dicom Görüntüleyici

Dosya Seçenekler Yardım

Dosya AYSU GULUMSER [CT] 30.12.2013

Görünüm Araçlar Seçenekler



AYSU GULUMSER
049Y F
1521658
3
30.12.2013 19:32:40
RESIM 5

YEDIKULE GOGUS HASTALIKLARI E.A.H.

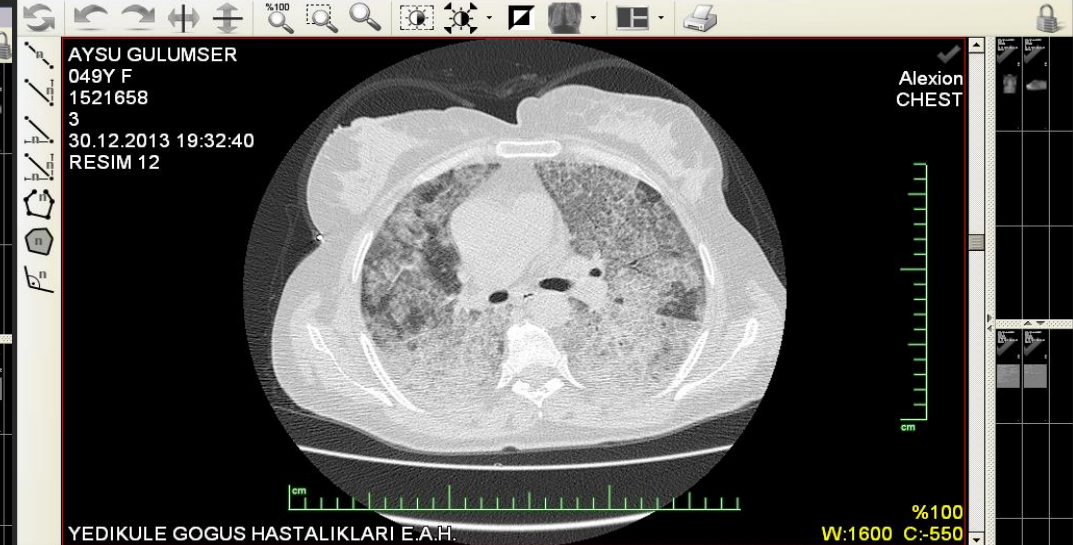W:1600 C:-550

Advision Dicom Görüntüleyici

Dosya Seçenekler Yardım

Dosya AYSU GULUMSER [CT] 30.12.2013

Görünüm Araçlar Seçenekler



AYSU GULUMSER
049Y F
1521658
3
30.12.2013 19:32:40
RESIM 12

YEDIKULE GOGUS HASTALIKLARI E.A.H.

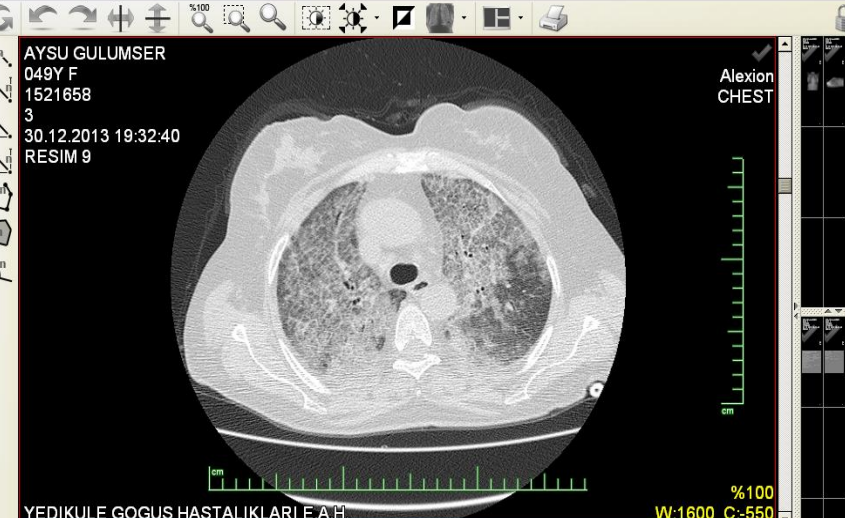
W:1600 C:-550

Advision Dicom Görüntüleyici

Dosya Seçenekler Yardım

Dosya AYSU GULUMSER [CT] 30.12.2013

Görünüm Araçlar Seçenekler



AYSU GULUMSER
049Y F
1521658
3
30.12.2013 19:32:40
RESIM 9

YEDIKULE GOGUS HASTALIKLARI E.A.H.

W:1600 C:-550

13.OLGU



13.OLGU

Advision Dicom Görüntüleyici

leyici

Dosya Seçenekler Yardım

v2.5.3.150

v2.5.3.150

Dosya GULUMSER AYSU [DX] 24.12.2013

GULUMSER AYSU [DX] 02.01.2014

Dosya Görünüm Araçlar Seçenekler

Seçenekler



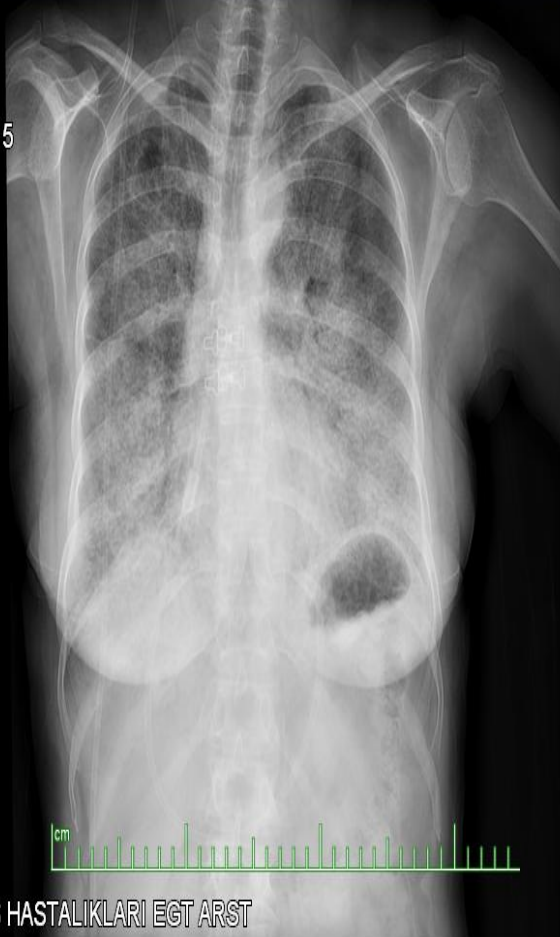GULUMSER AYSU

F

1521658

24.12.2013 14:20:15

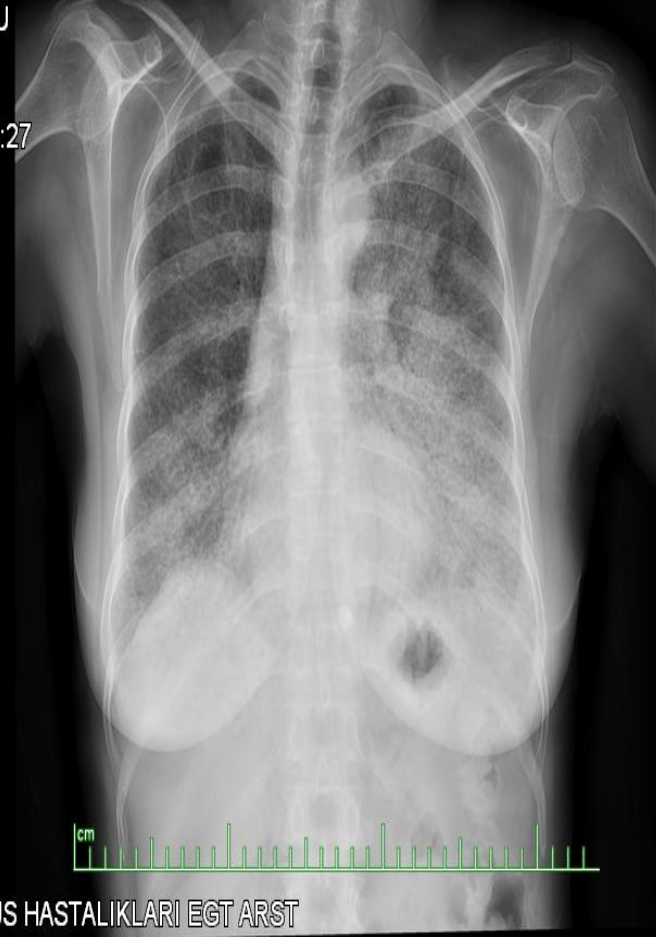RESIM 2



DR Digital System
AKCIGER AYAKTA

AYSU

09:56:27



DR Digital System
AKCIGER AYAKTA

YEDIKULE GOGUS HASTALIKLARI EGT ARST

%100
W:16383 C:8192

GOGUS HASTALIKLARI EGT ARST

%100
W:16383 C:8192

Başlat

Görüntüleme - Panates

3A.1 Göğüs Polikliniği ...

Advision Dicom Görün...

13:08

Görüntüleme - Panates

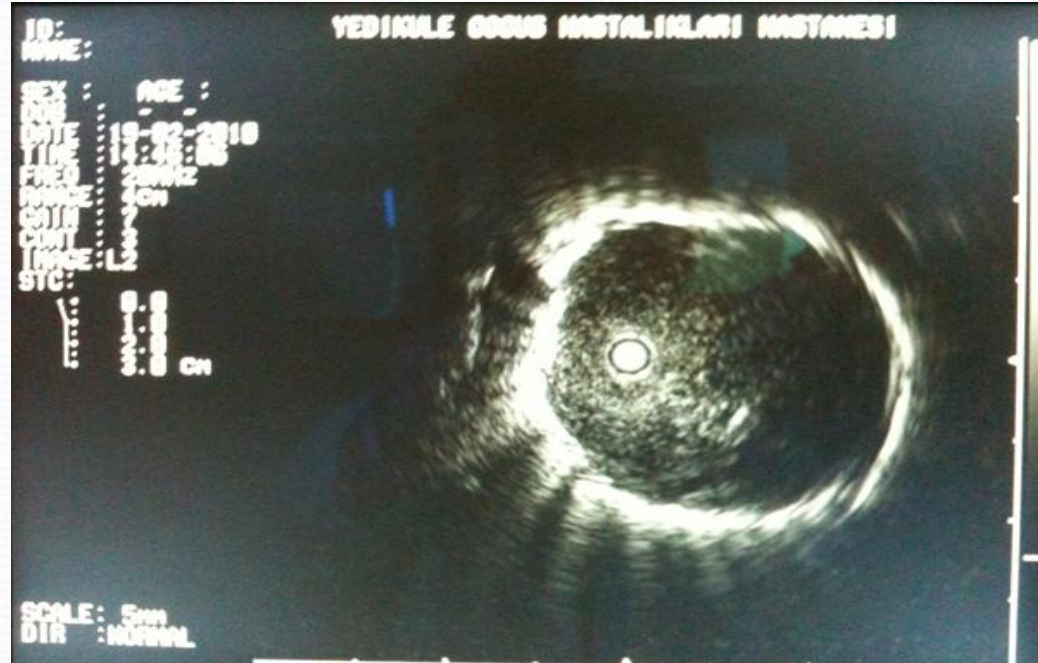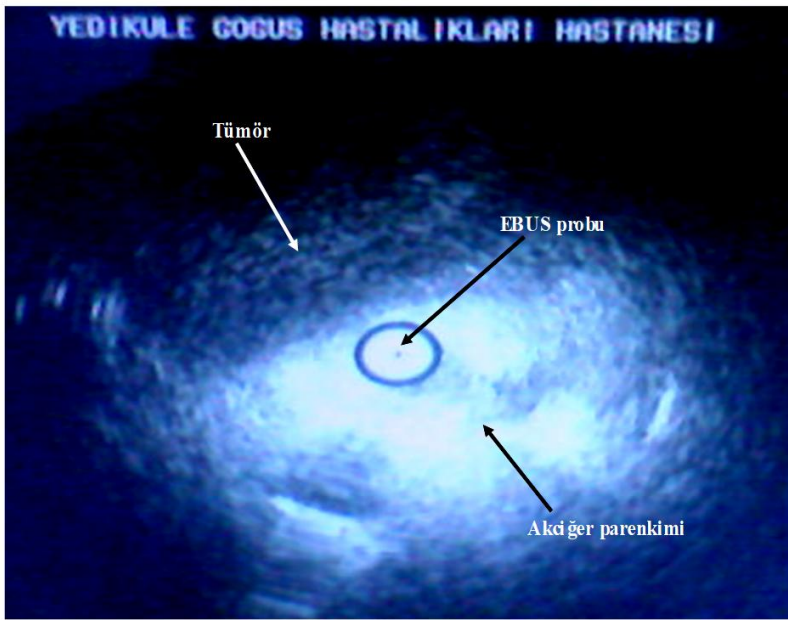
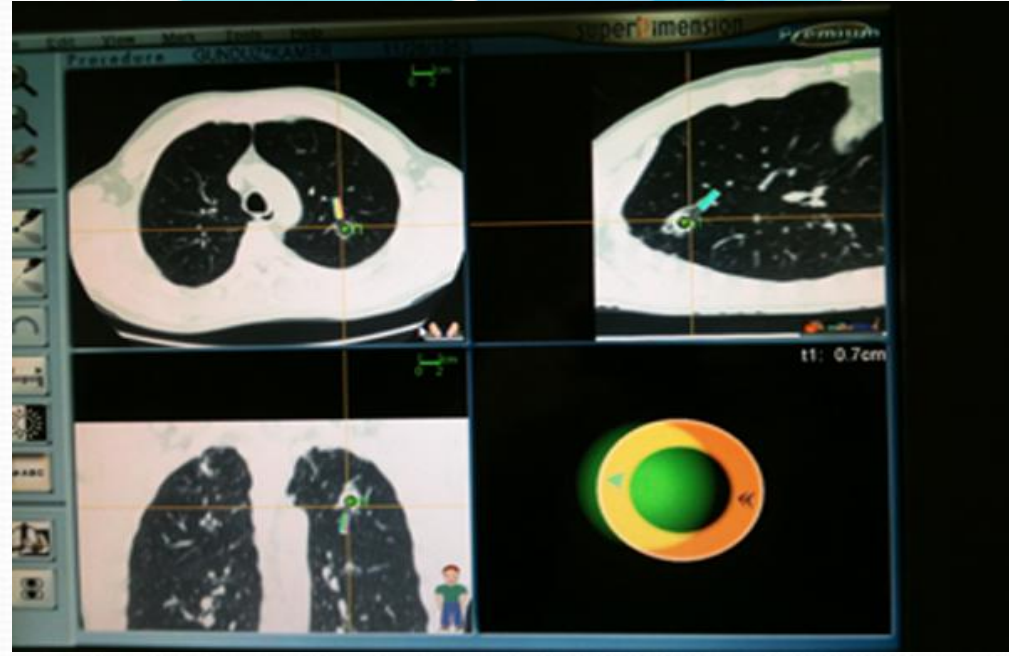
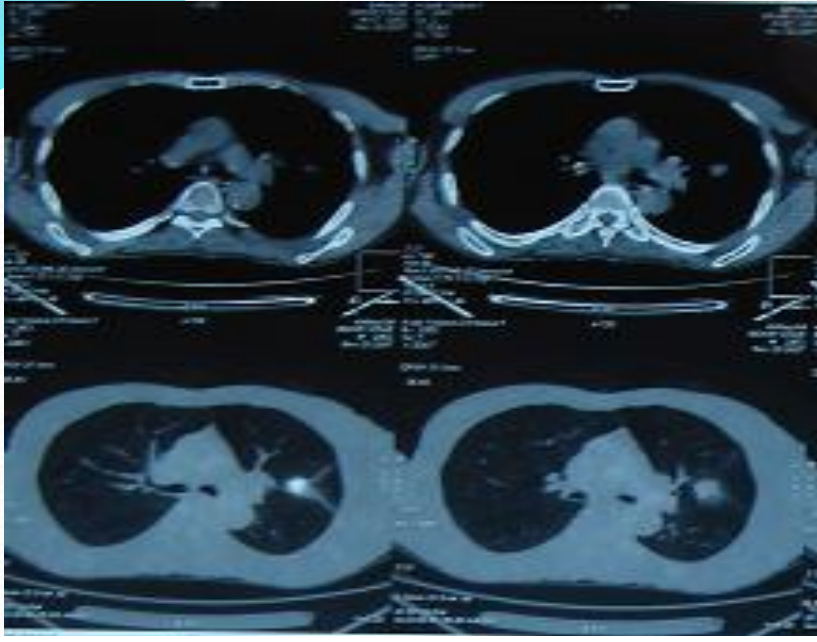
3A.1 Göğüs Polikliniği ...

Microsoft PowerPoint ...

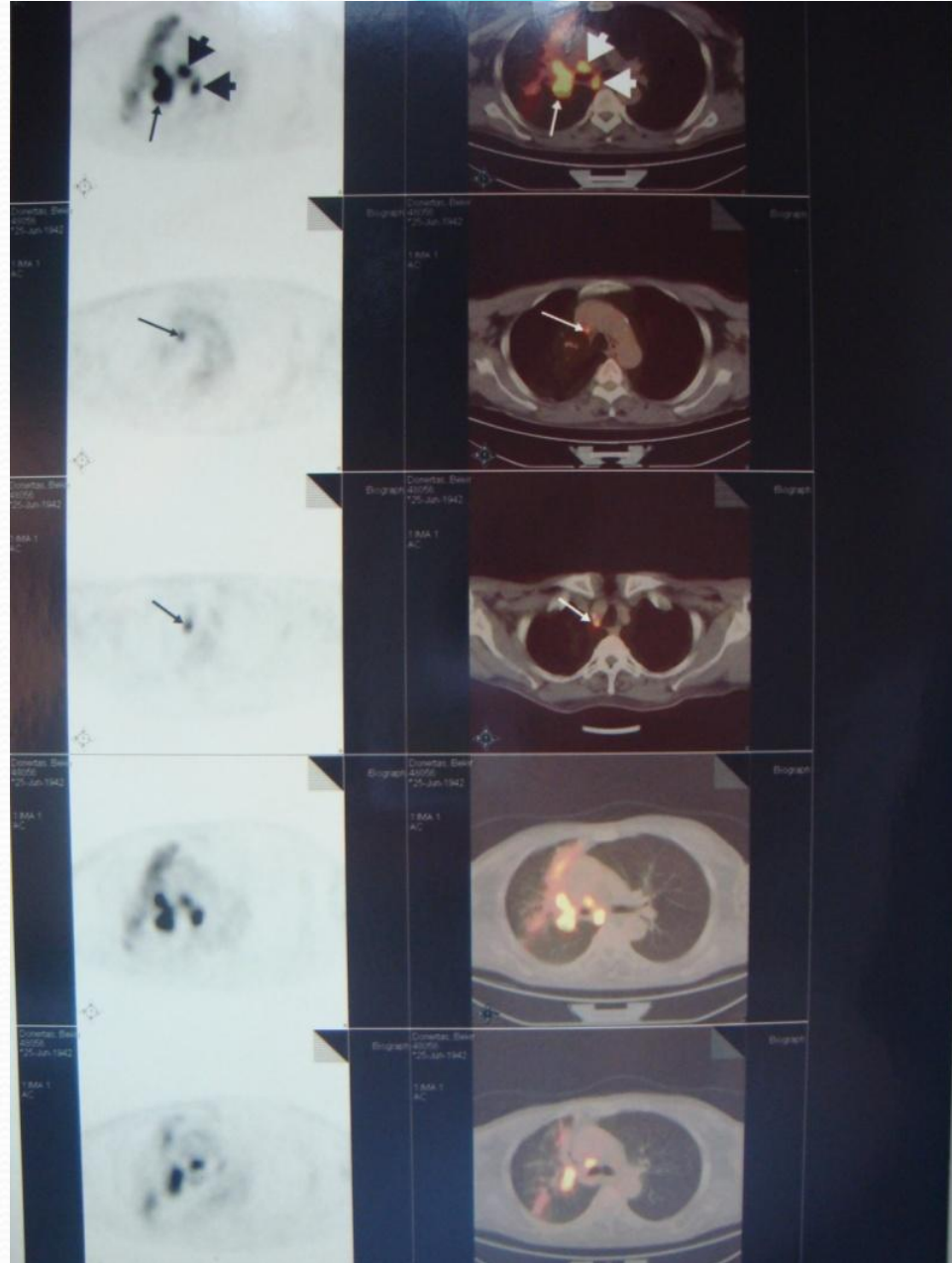
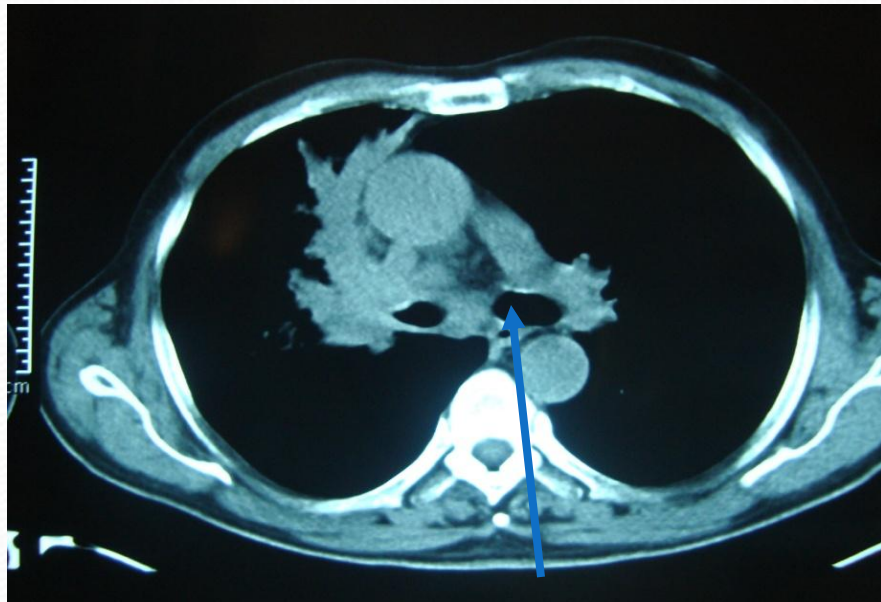
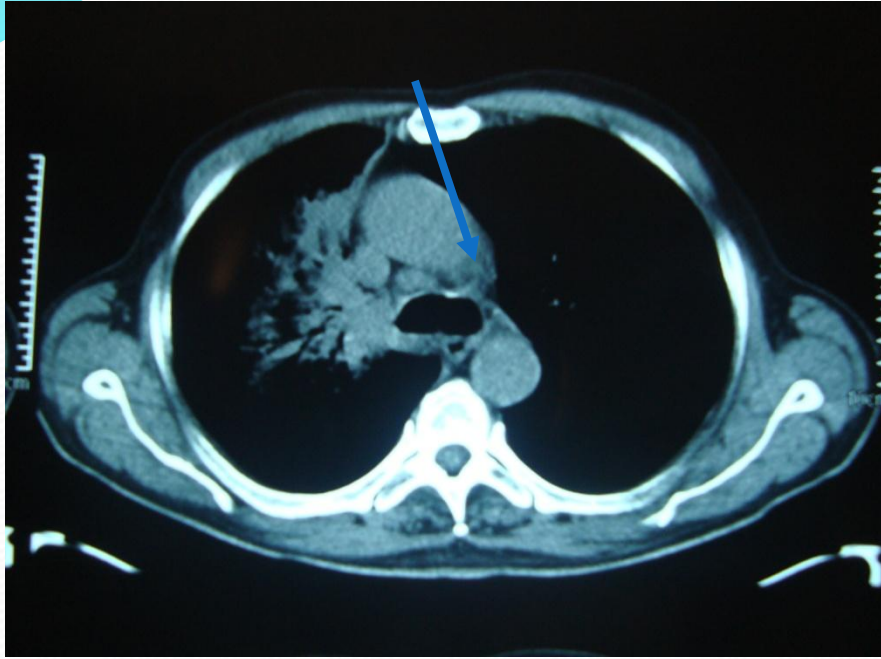
Advision Dicom Görün...

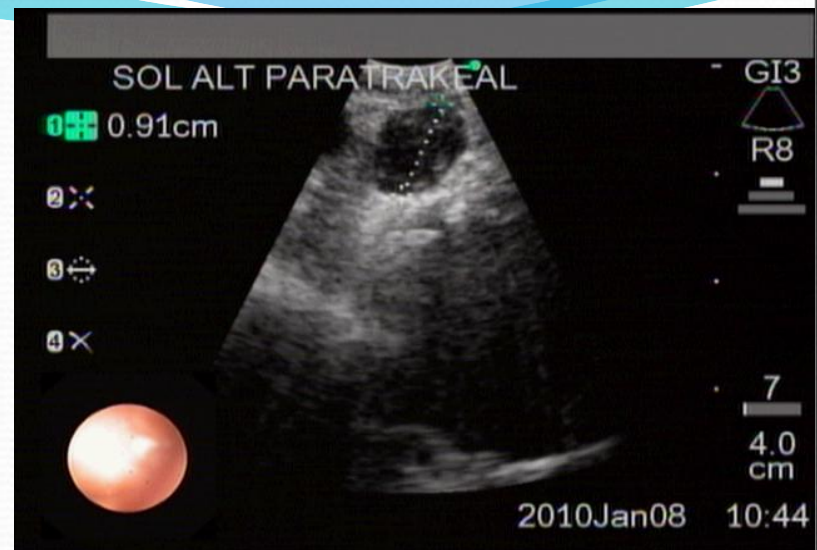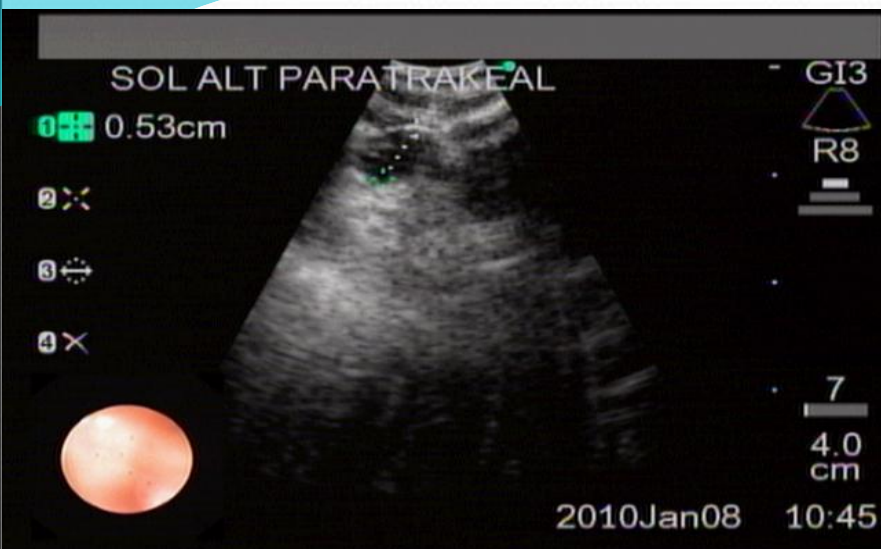
13:09

14.OLGU

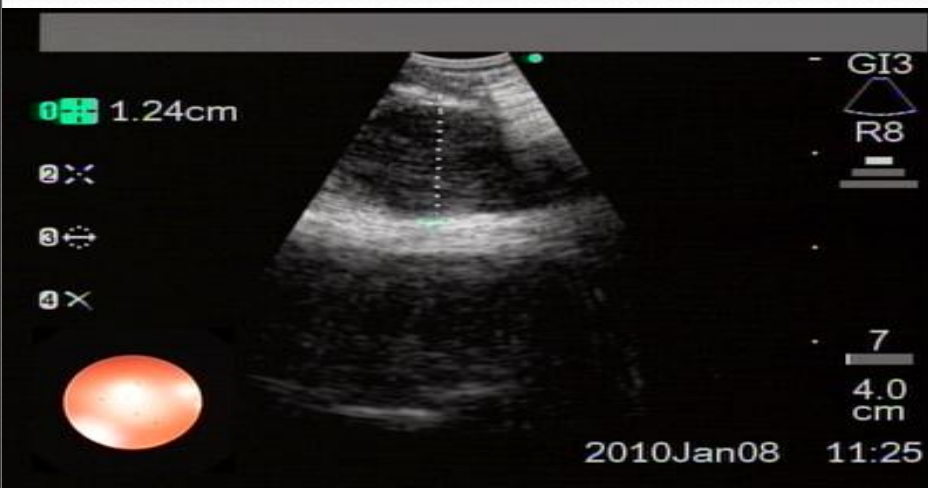


15.OLGU

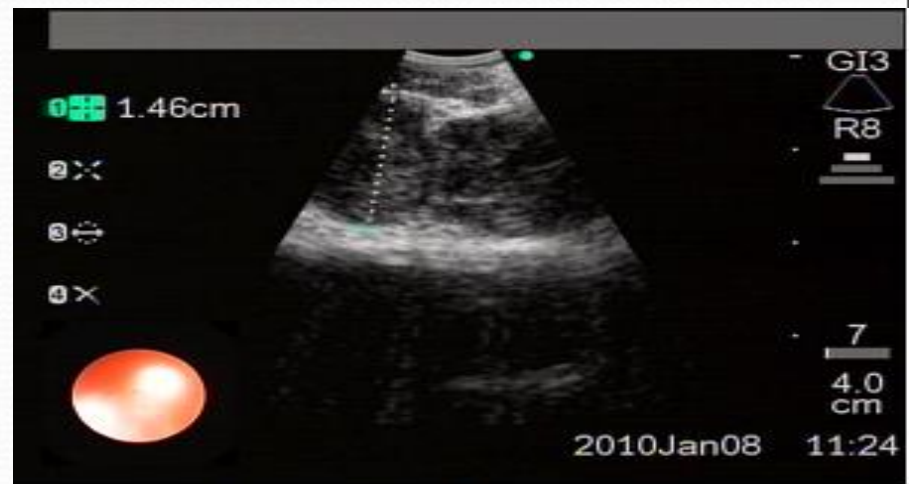




BT ve PET'de var



4R-prekarinal lam



4R-prekarinal lam

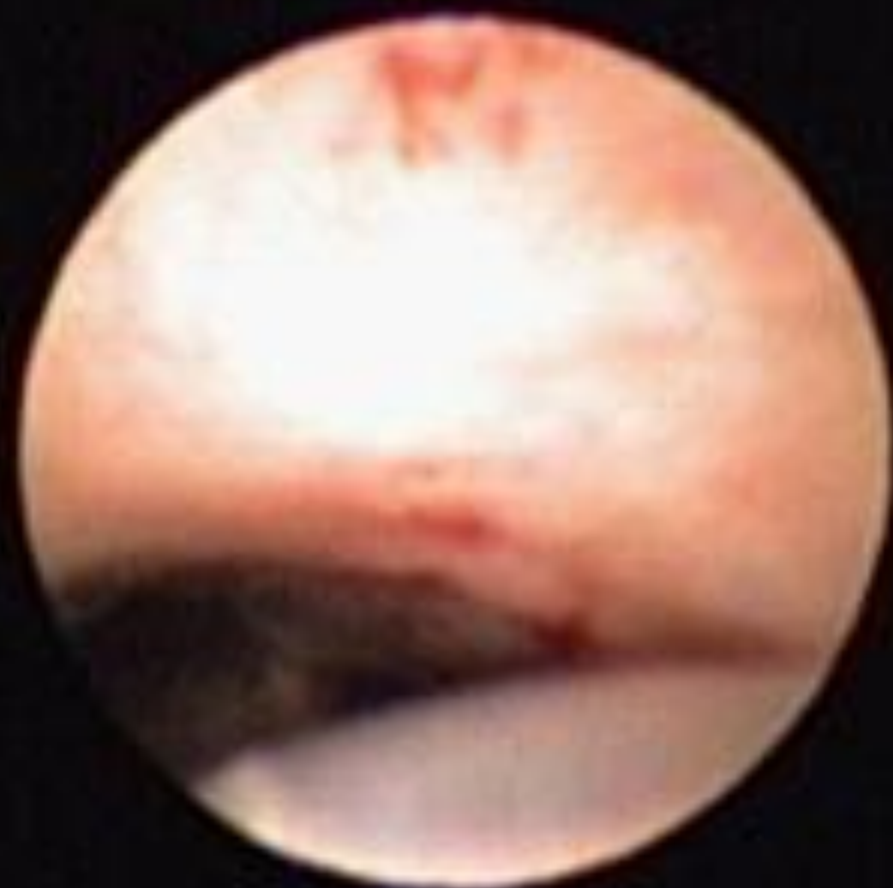
ID:
Name:

Sex: Age:

D.O.B.:
09/04/2010

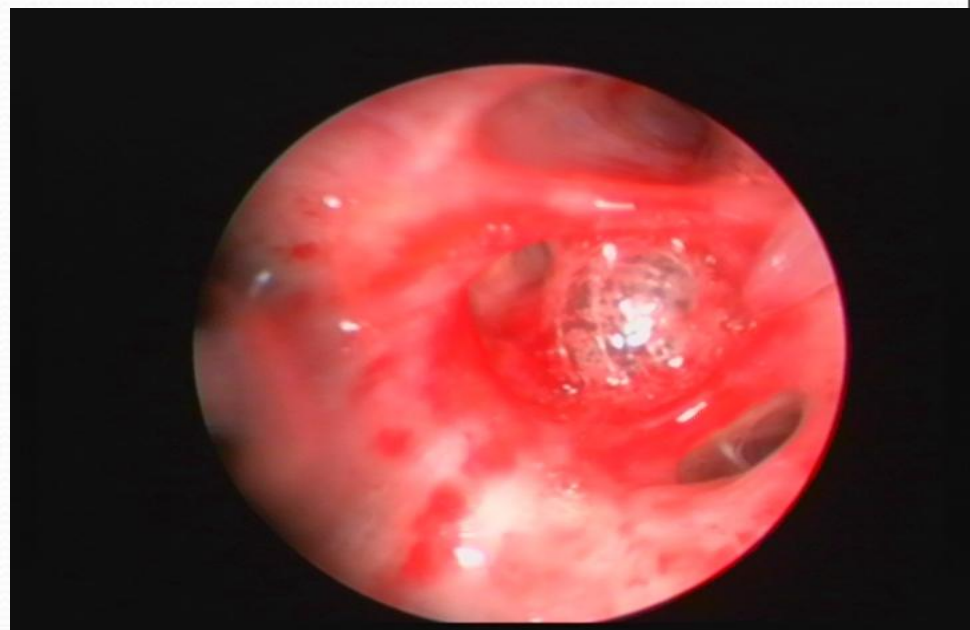
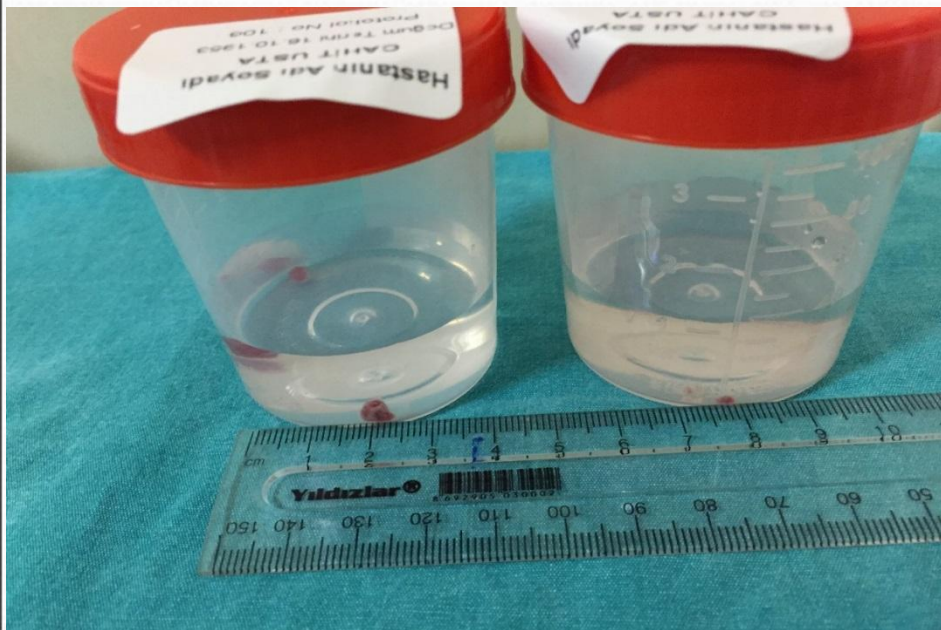
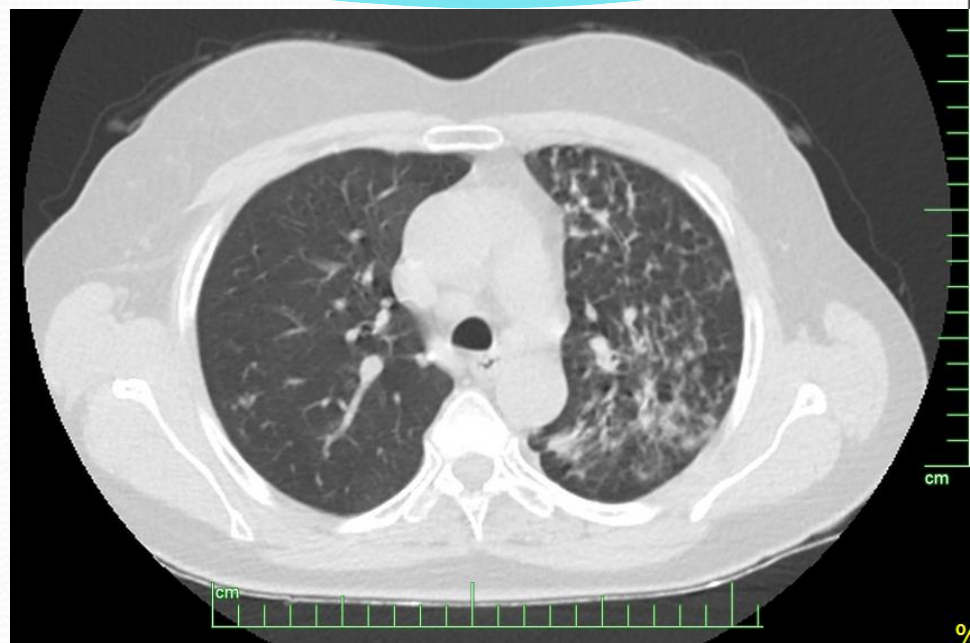
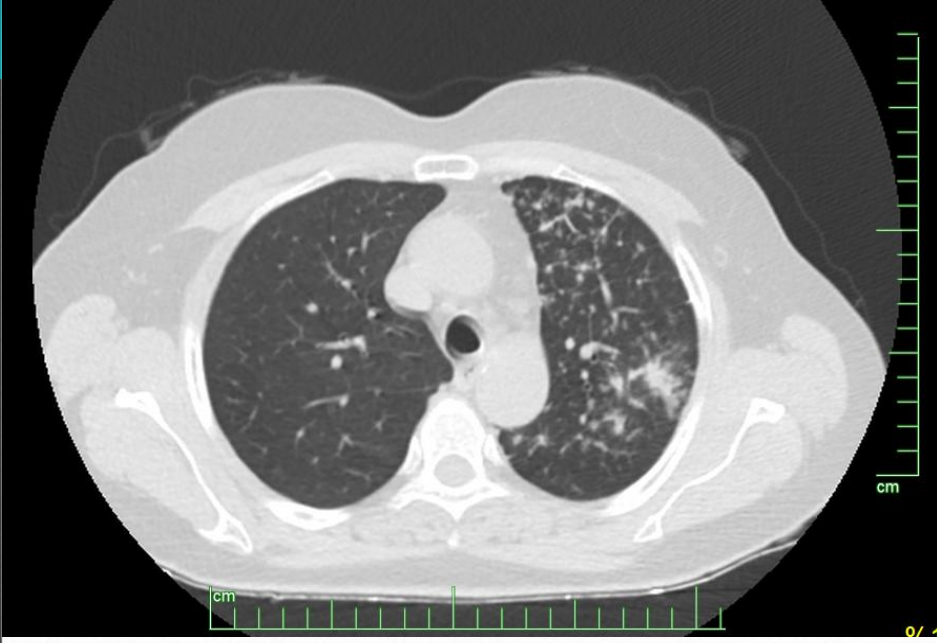08:58:20

Q:N In:A1



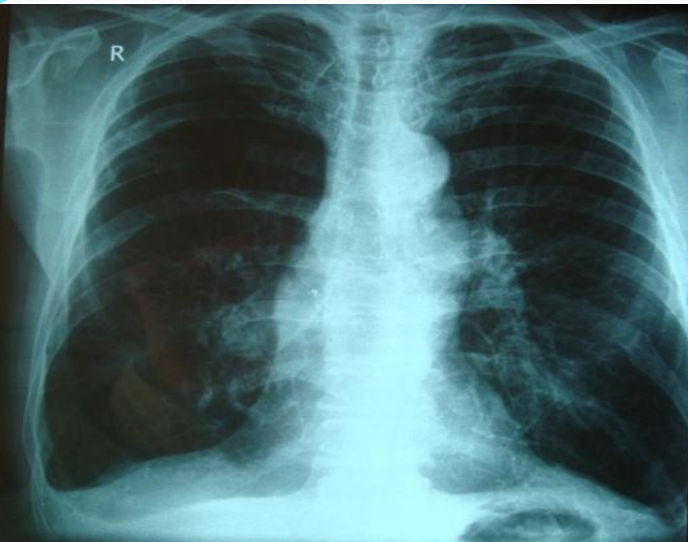
Physician:
Comment:

16.OLGU





16.OLGU



KADR ATALI POL 429912 04 13.08.2011 14:44:18
SUREYYAPASA GOG. HAS. VE GOG. CER. EGT. ARS. VE HASTANESI

Patient Name: ATALI SUREYYA

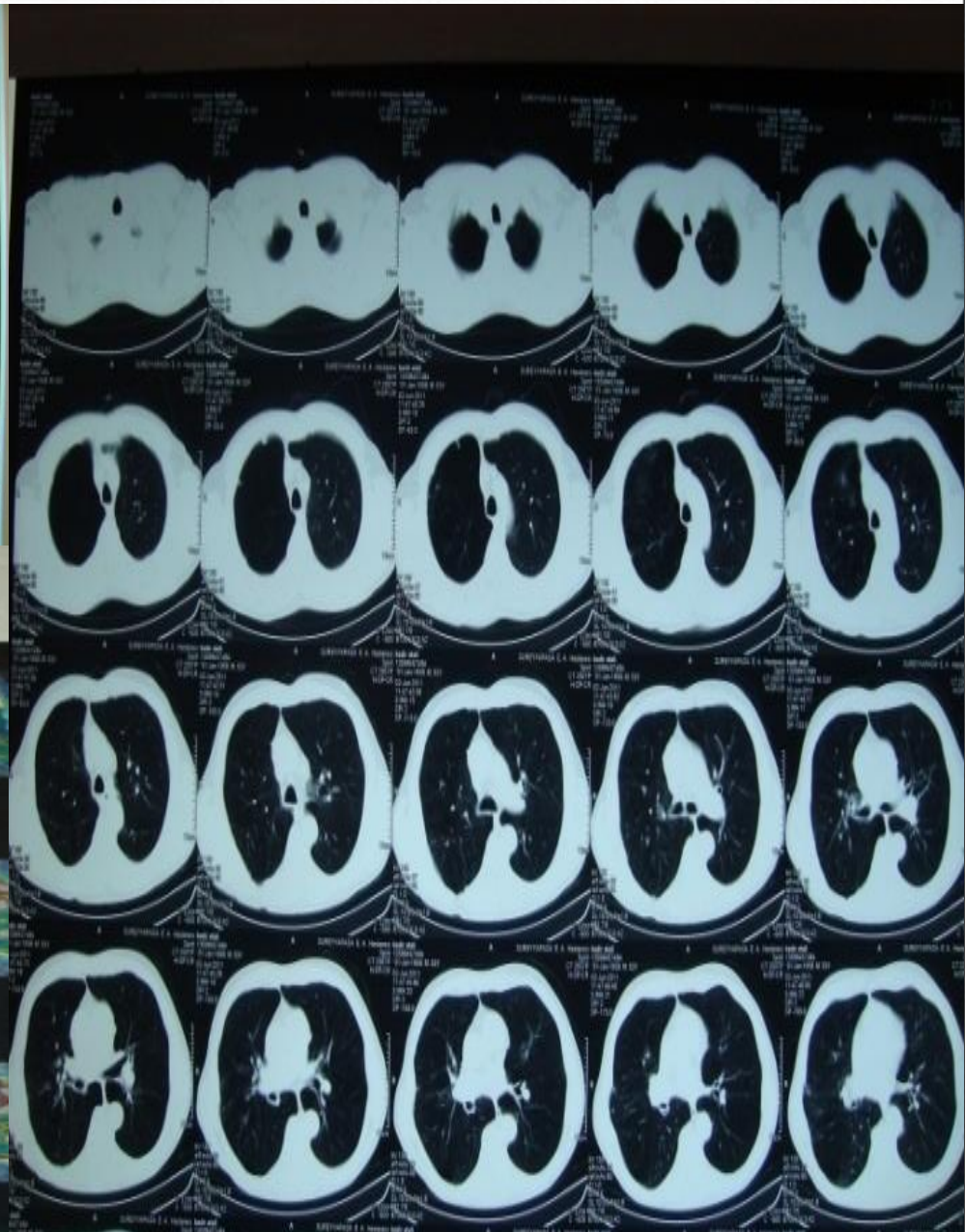
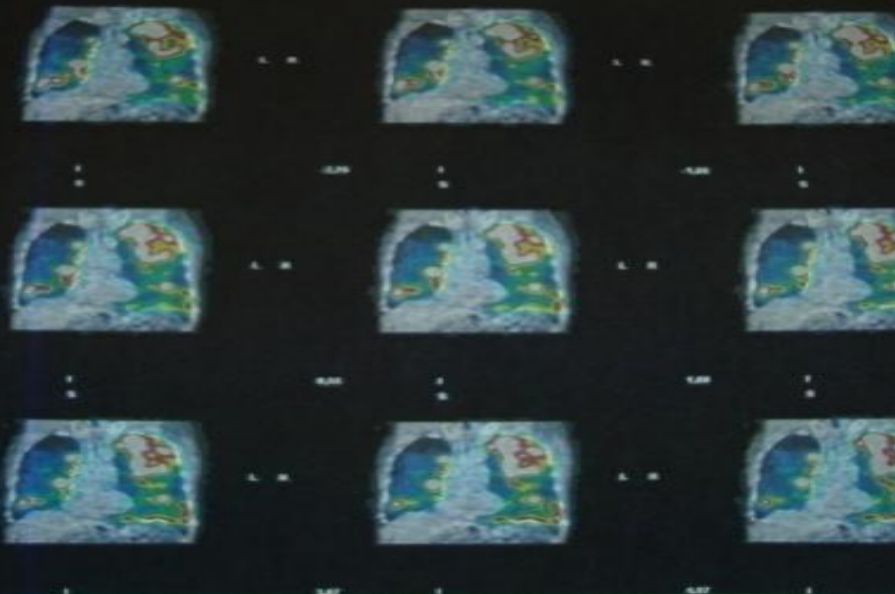
Study Name: Toraksal BT

Patient No: 2812 0062323

Date & Time: 06.07.2011


SD CEMETIYANI SUNI HASTANE ANKAR
NUMERU: 2812 0062323

Microchip No: 00000000000000000000

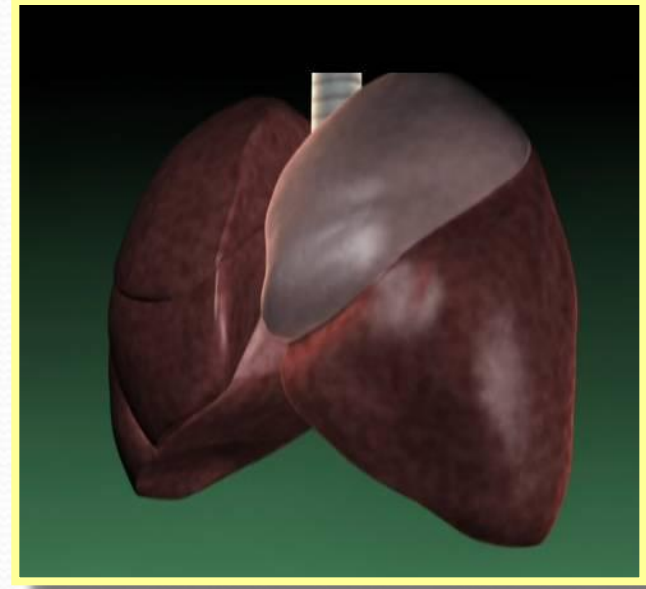
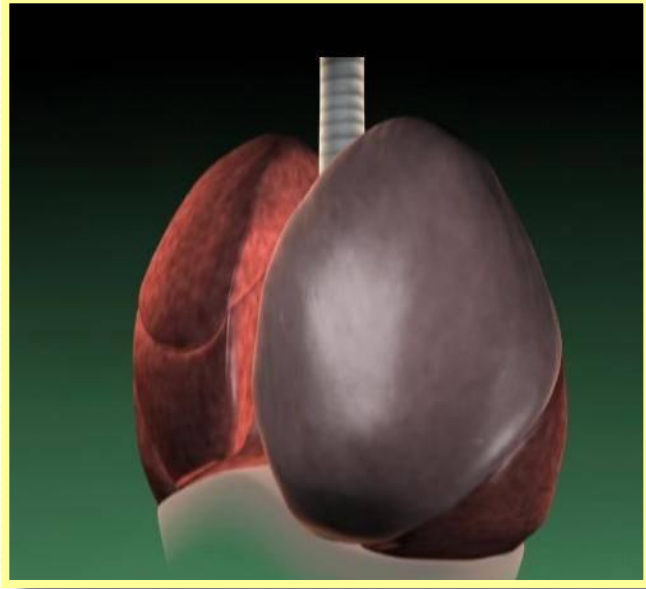
Hacim azaltma tedavisinde öngörülen etki mekanizması

Aşırı havalanmış
akciğer



Hacim azalması & Hava
akışının yeniden
düzenlenmesi



Hedef Lob
Hacim
Azalması

Düzelen
Solunum
Mekanizması

Egzersiz
Kapasitesinde
düzelme
& QoL

Mortalite ↓?

16.OLGU

parameter	unit	pred	act	ref
FVC ₀	l	2.96	2.11	80
FEV1	l	3.07	0.71	21
FEV1/FVC	%	76	23	30
PEF	l/s	7.98	2.42	30
MEF75	l/s	7.07	0.31	4
MEF50	l/s	4.21	0.21	5
MEF25	l/s	1.5	0.21	9
MEF25-75	l/s	3.3	0.21	6
VC	l	4.0	5.58	82
IC	l	1.11	1.49	48
TGV	l	3.47	7.27	210
VA	l	1.11	1.49	48
TLC	l	6.58	5.58	167
ERV	l	1.10	1.49	235
RV	l	2.37	5.58	235
RV/TLC	%	36	60	164

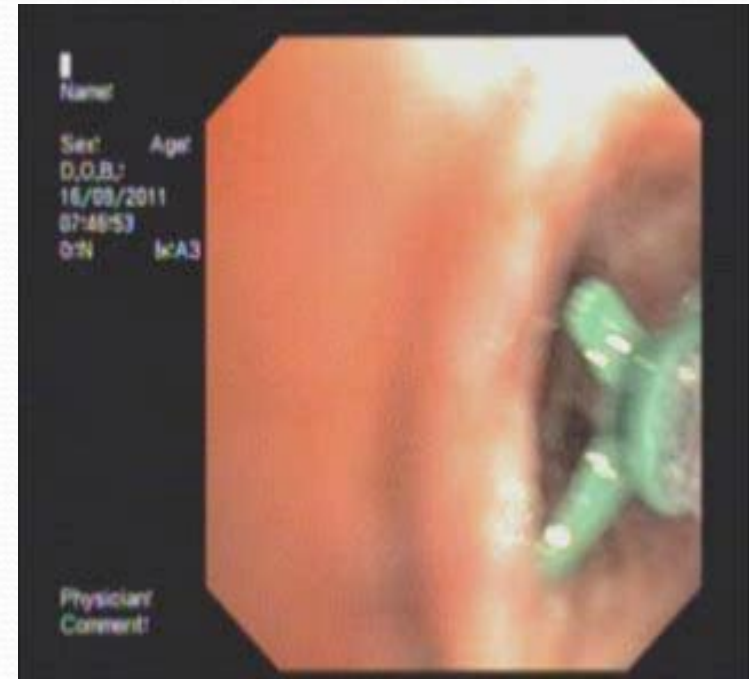
FEV1

0.71(%23)

TLC

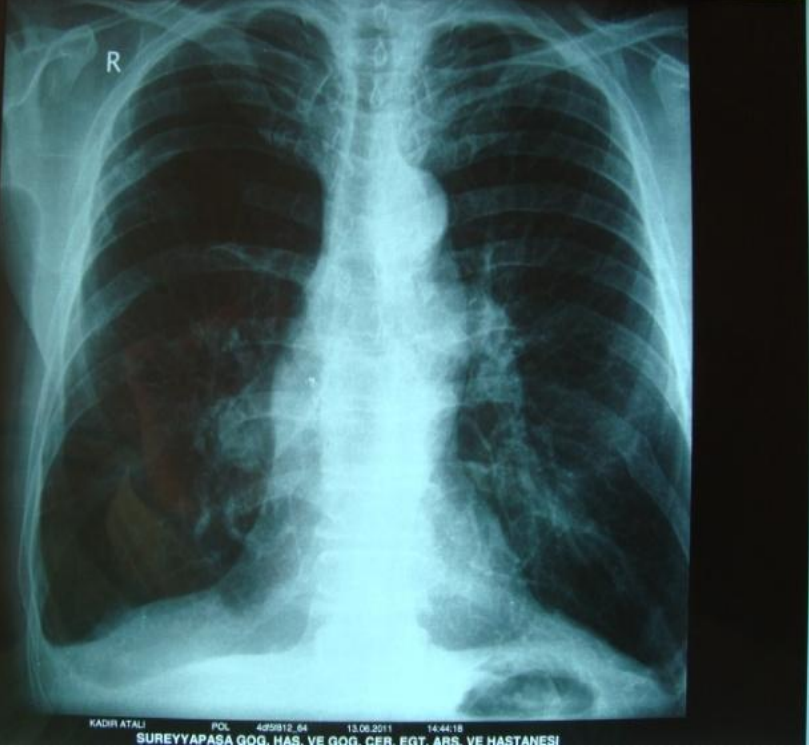
8.90(%135)

RV 5.58(%235)

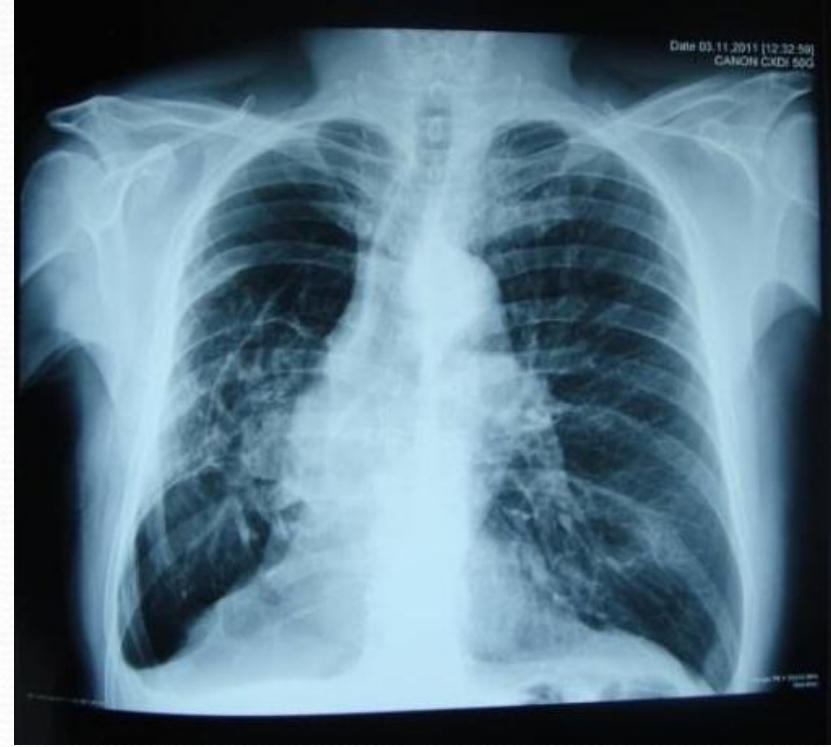


- 6 DYT 213 m
- MMRC dispne ölçeği: 4

16.OLGU



İşlem öncesi

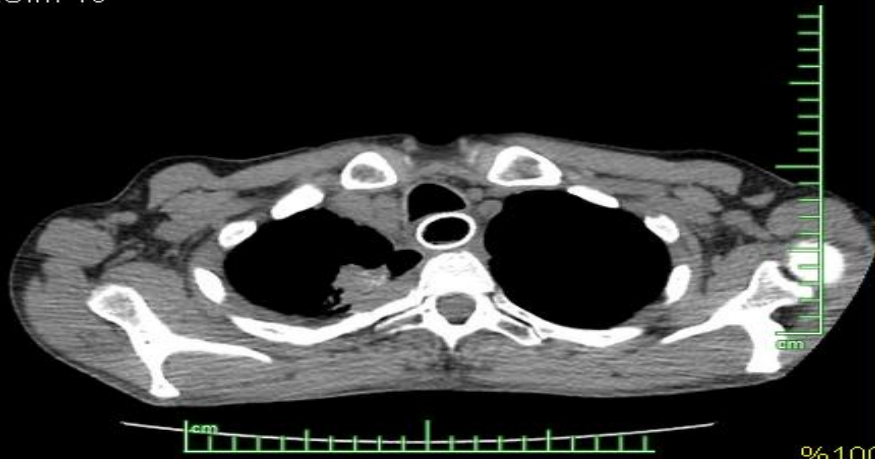


İşlemden 2 ay sonra

5.OLGU

CIVIS BAHRI
047Y M
1364283 SALB
3
01.04.2014 15:33:53
RESIM 15

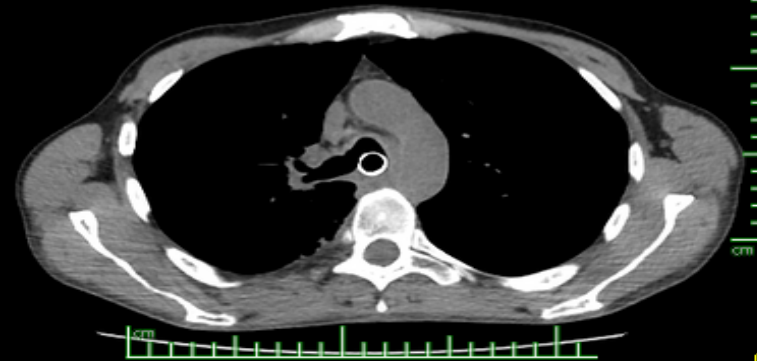
Alexion
CHEST



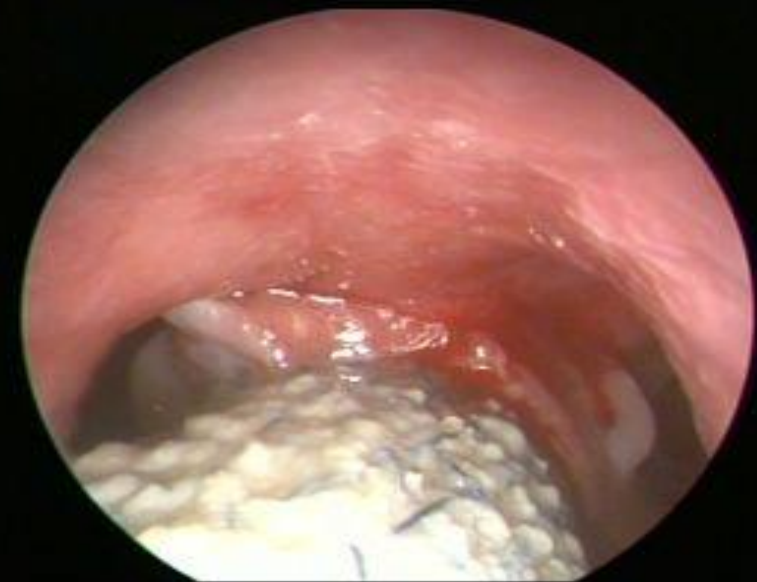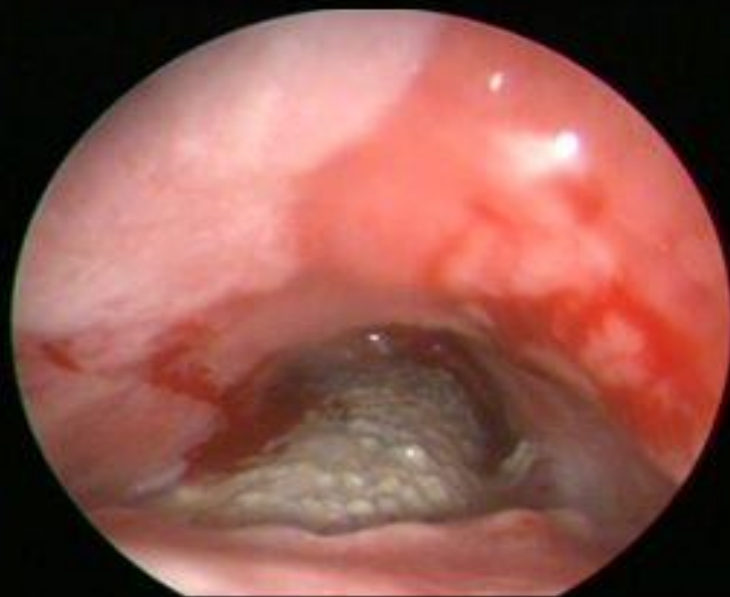YEDIKULE GOGUS HASTALIKLARI E.A.H. W:400 C:40 %100

CIVIS BAHRI
047Y M
1364283 SALB
3
01.04.2014 15:33:53
RESIM 31

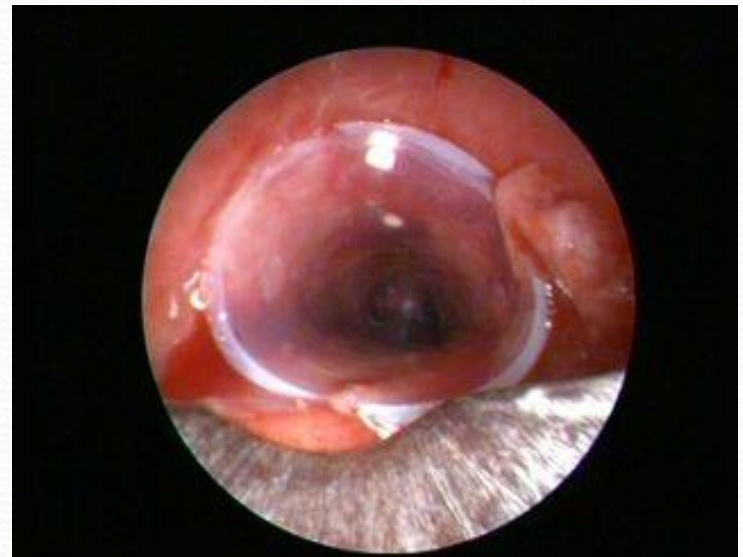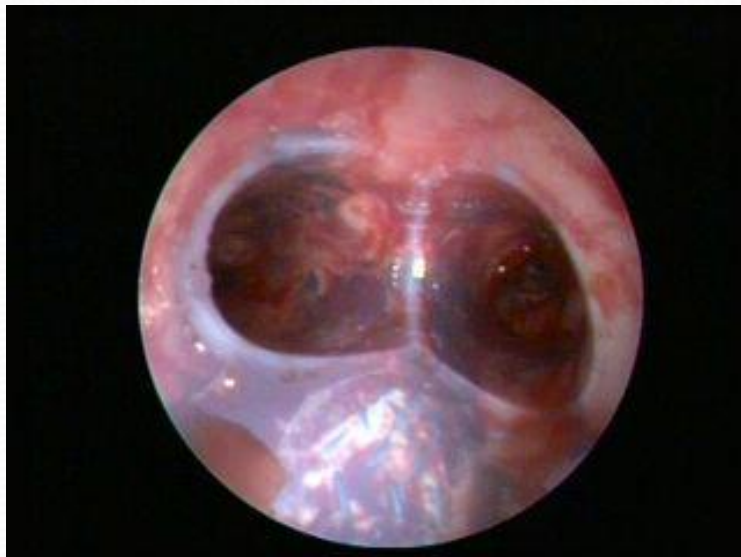
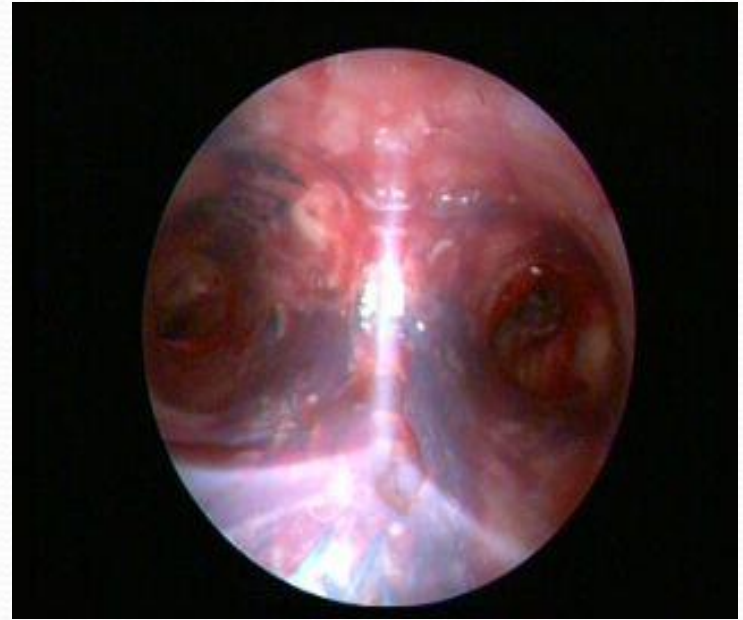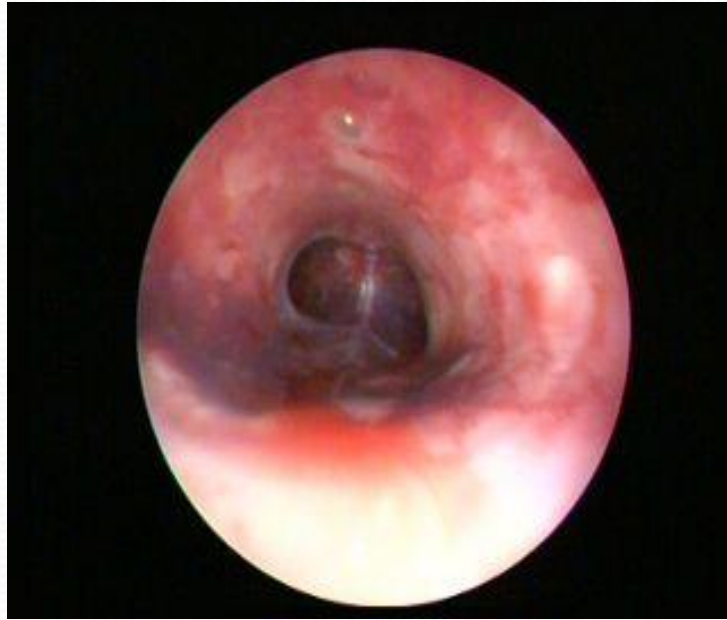Alexion
CHEST

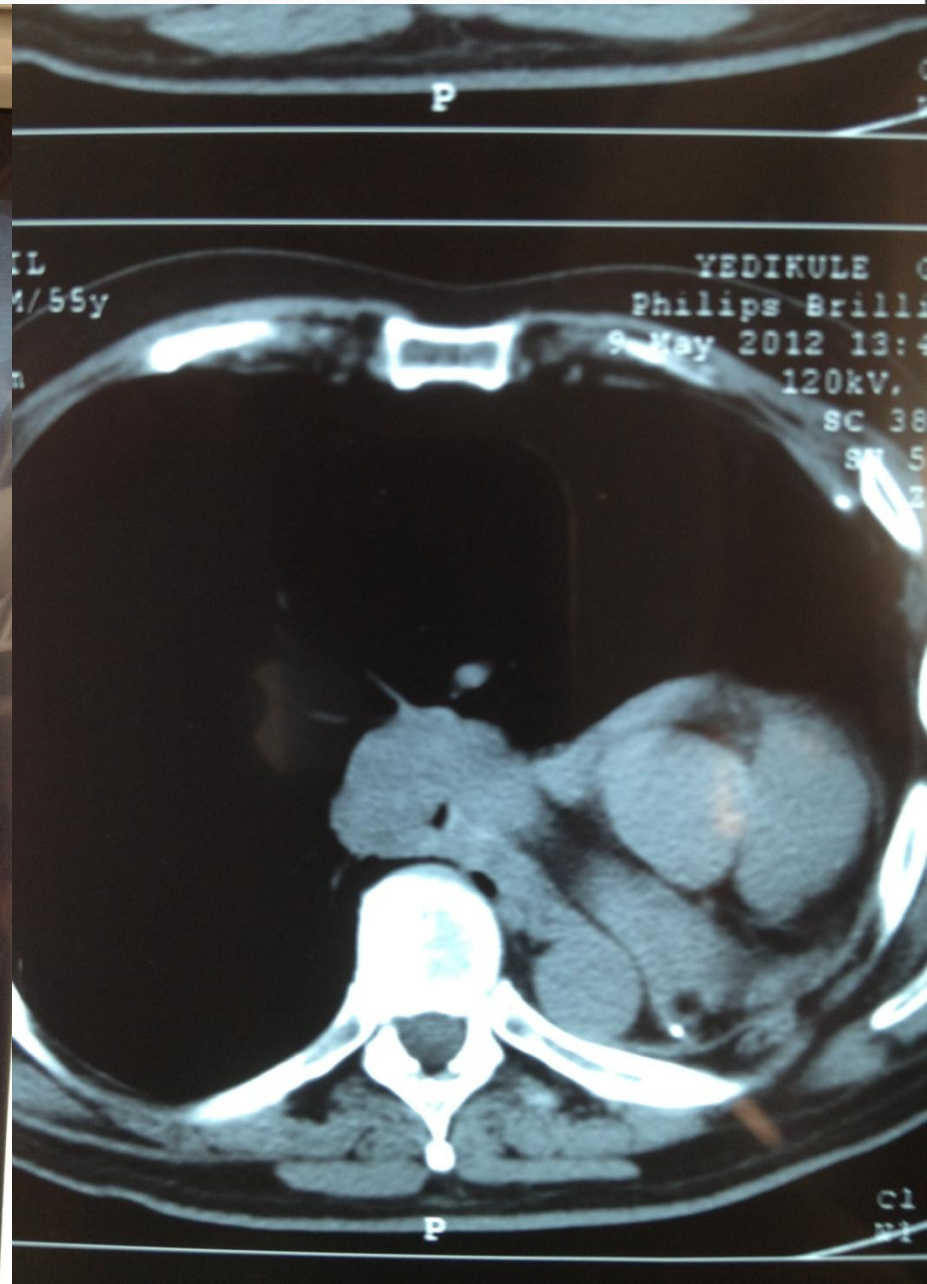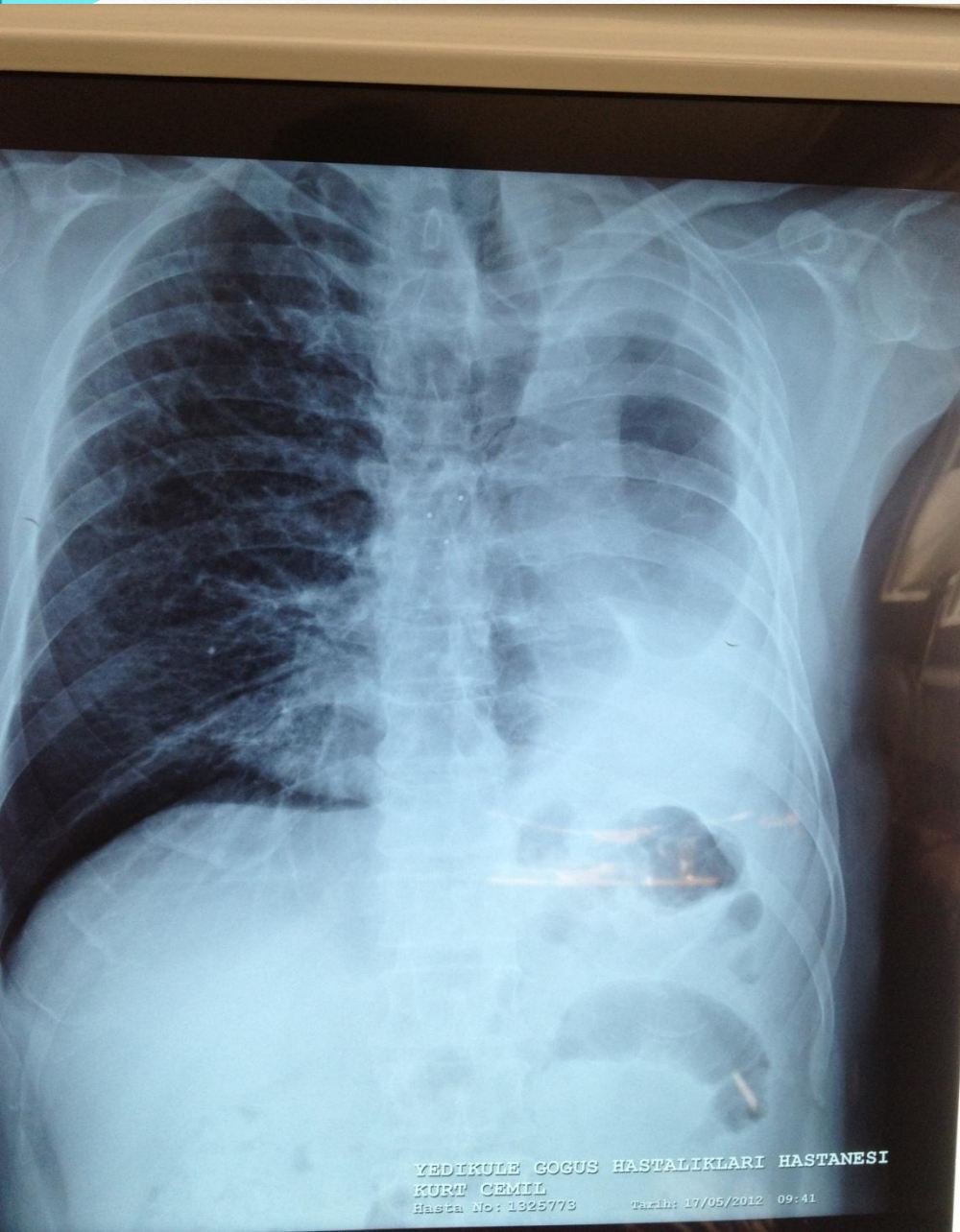


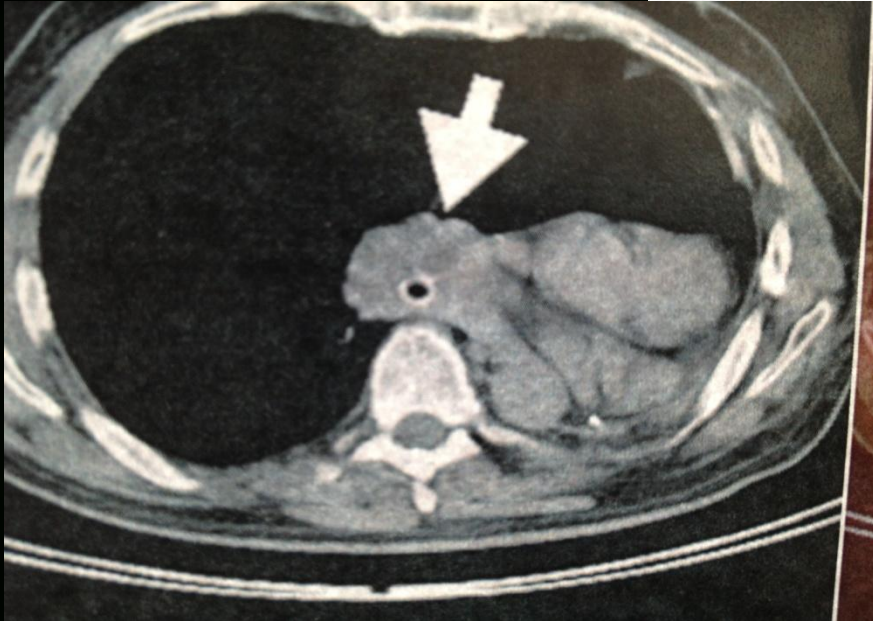
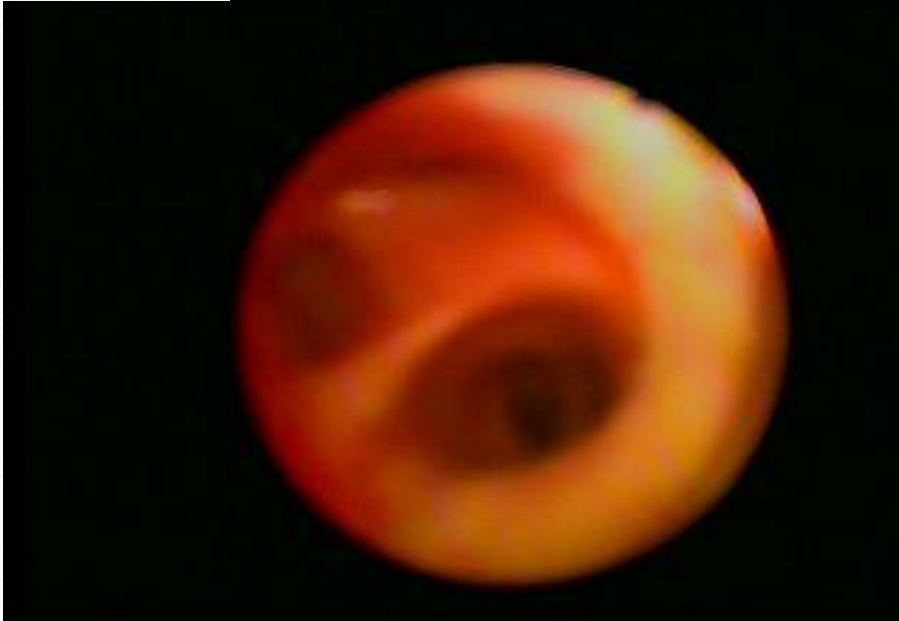
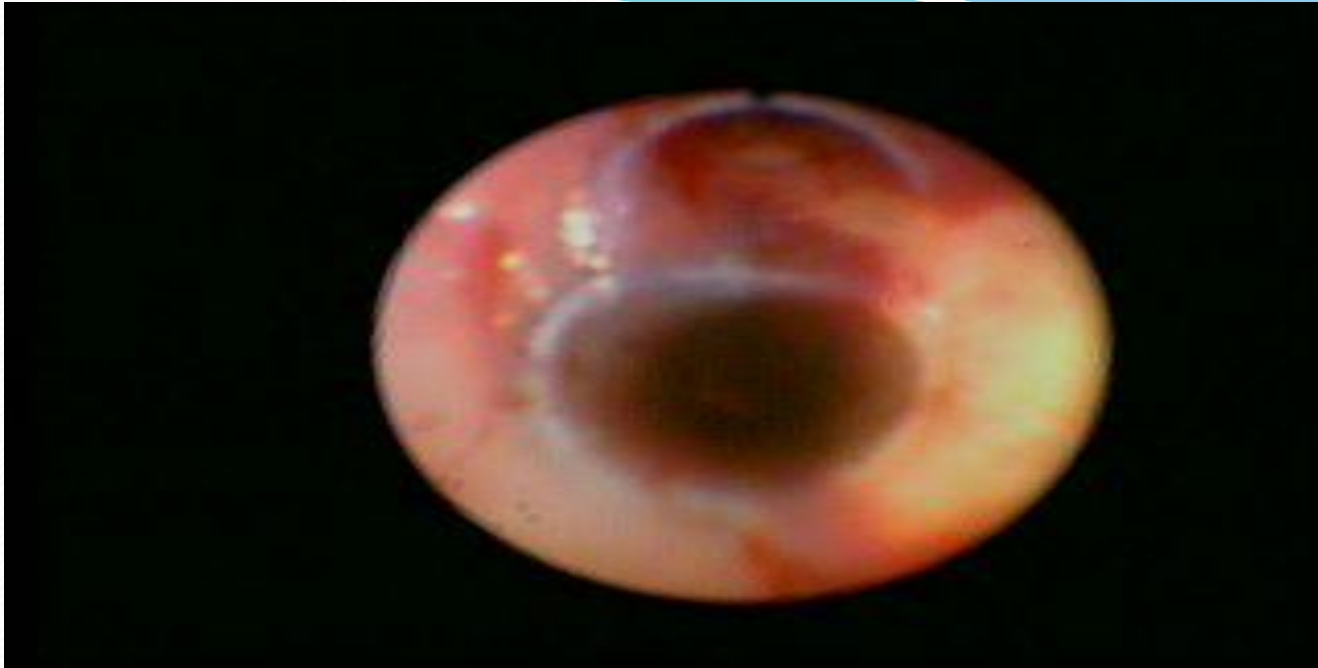YEDIKULE GOGUS HASTALIKLARI E.A.H. W:400 C:40 %100

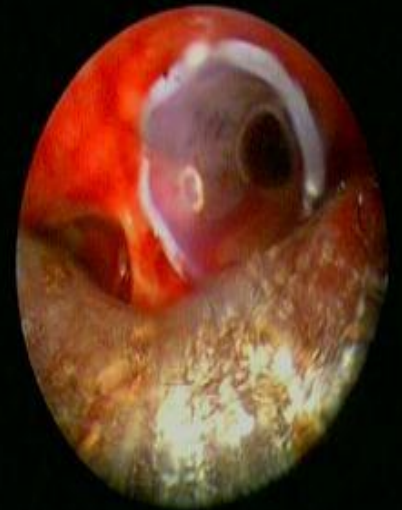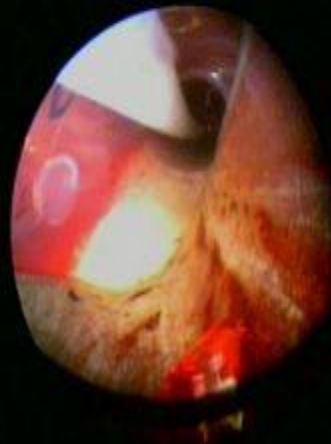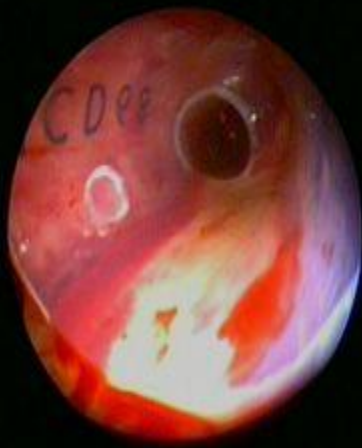
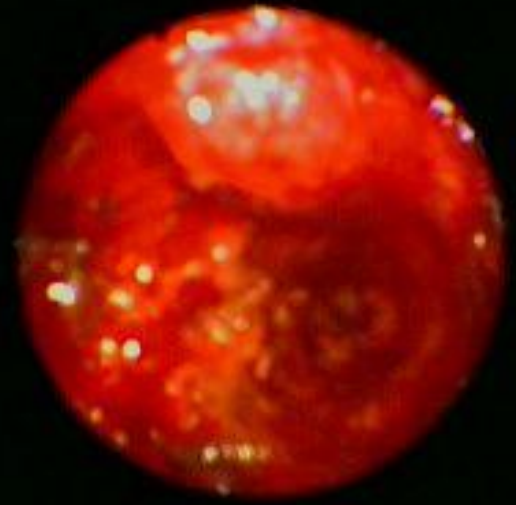


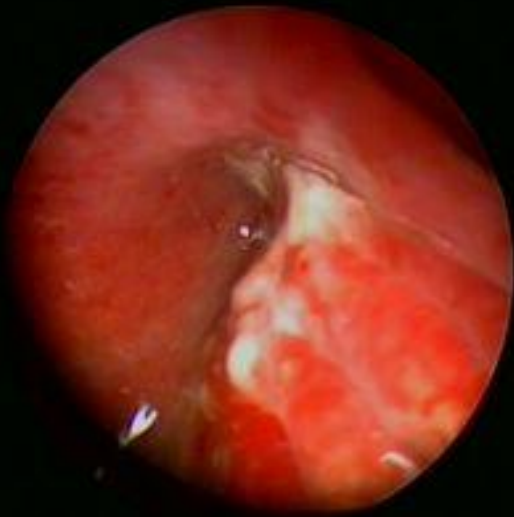5.OLGU

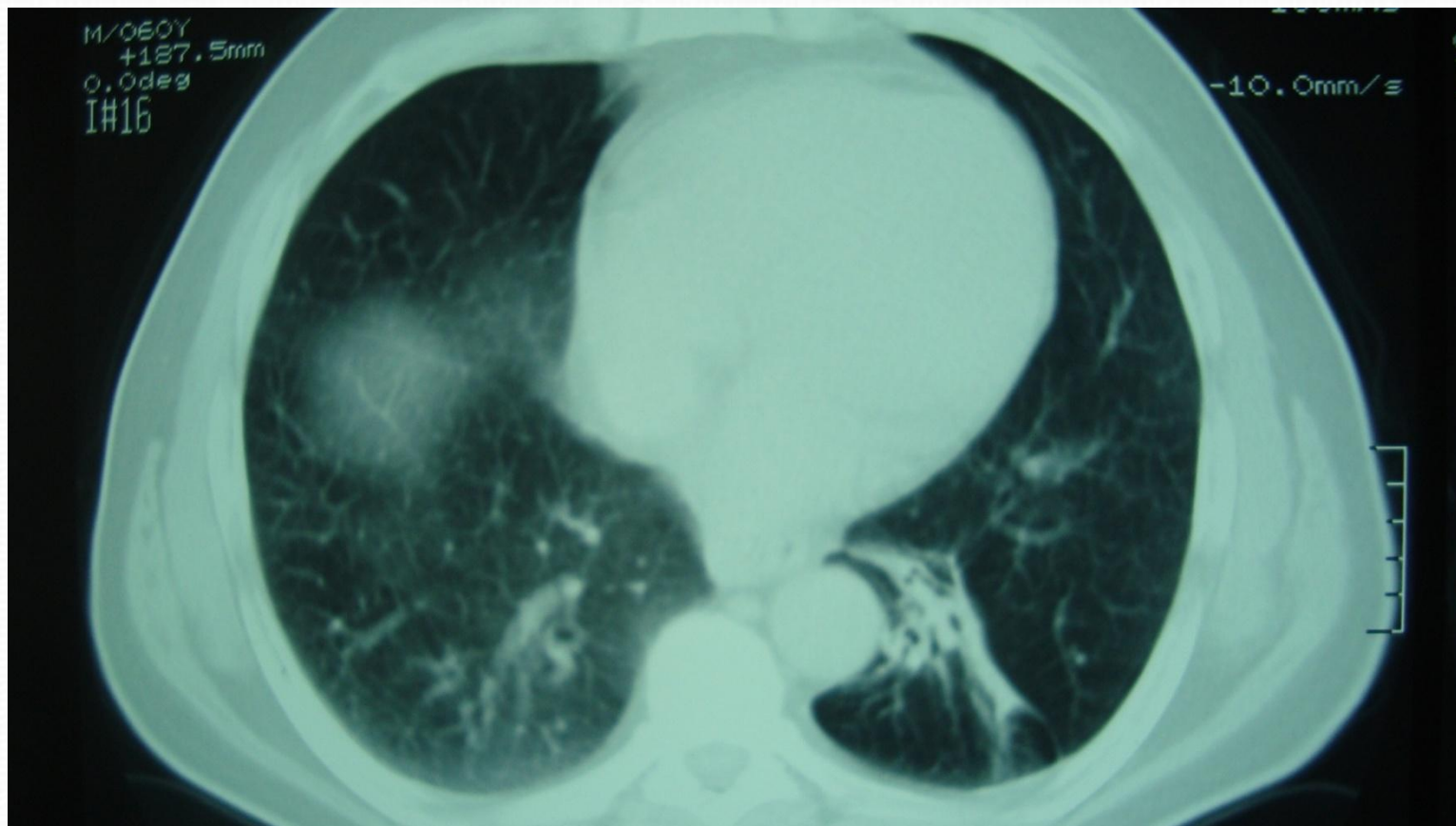




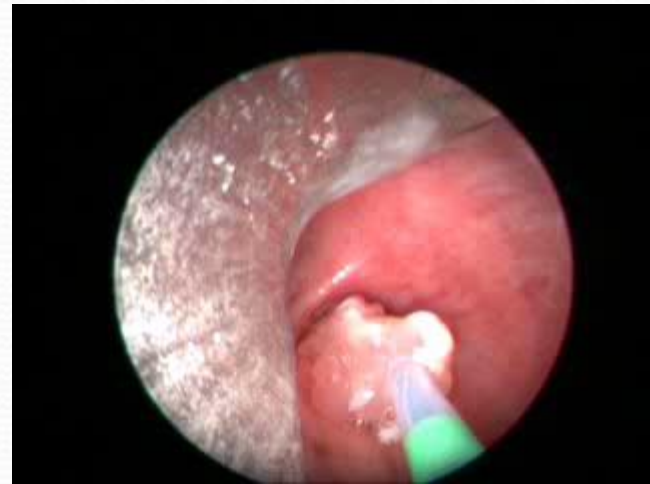
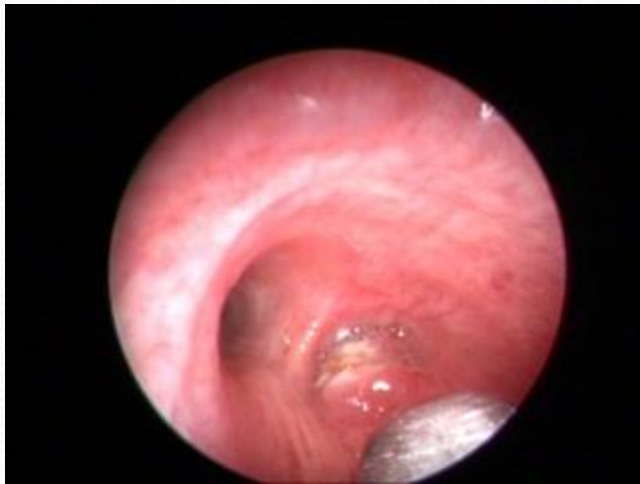


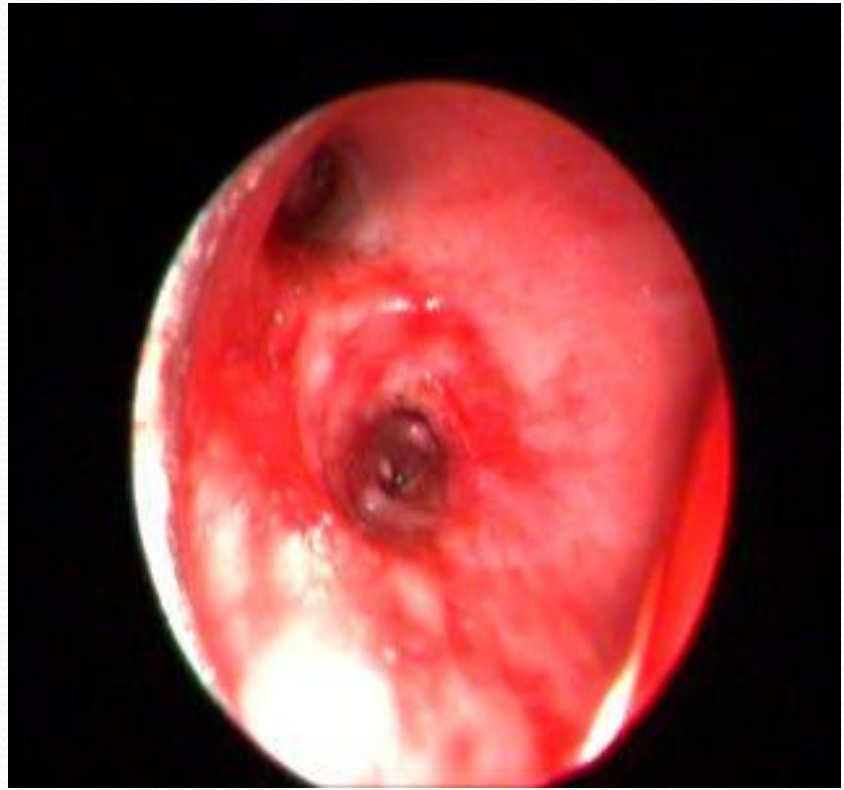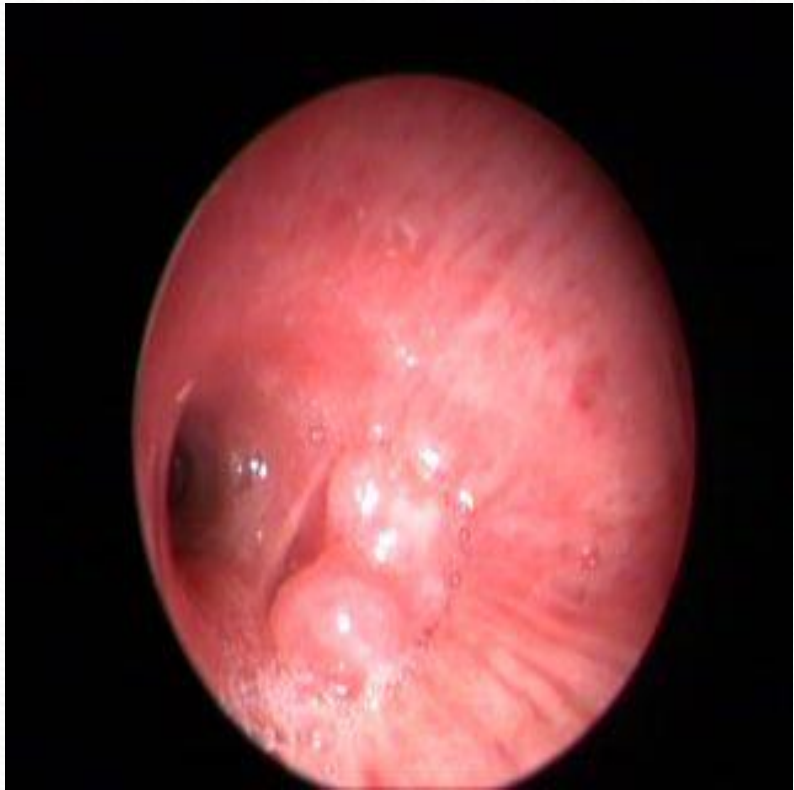M.O



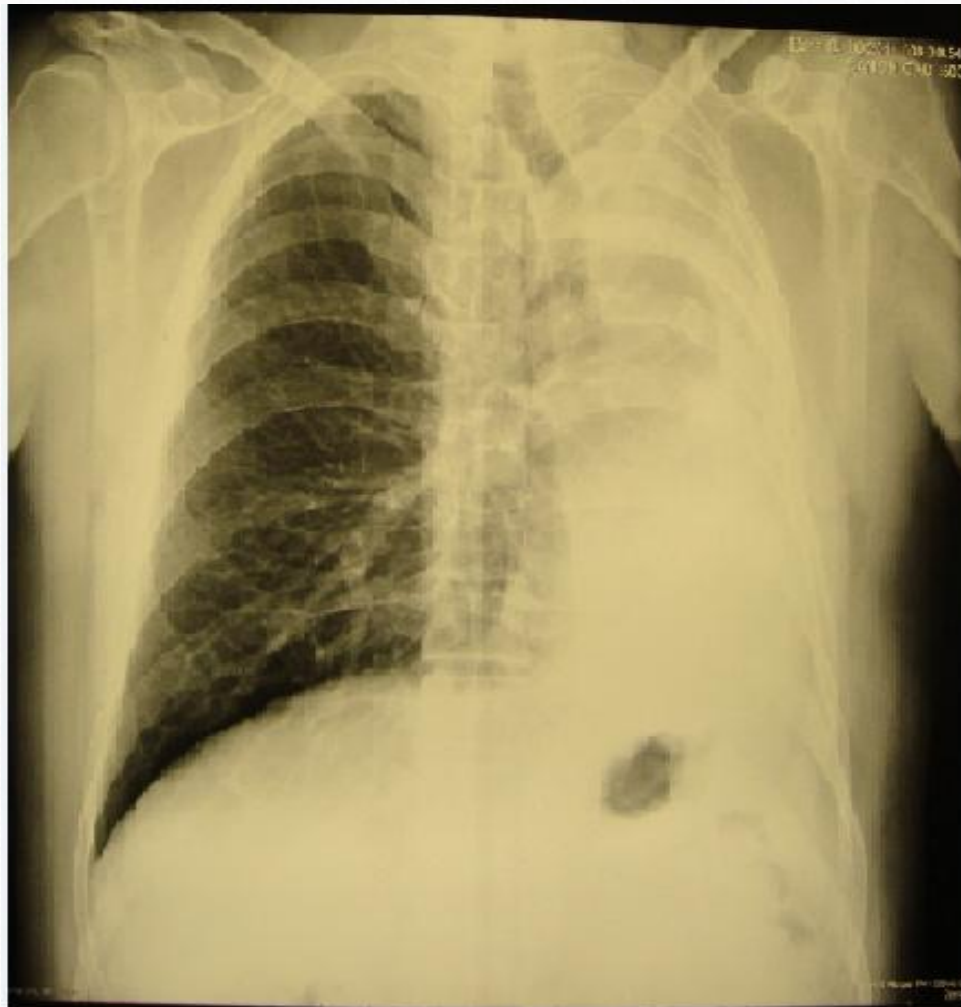
M.O



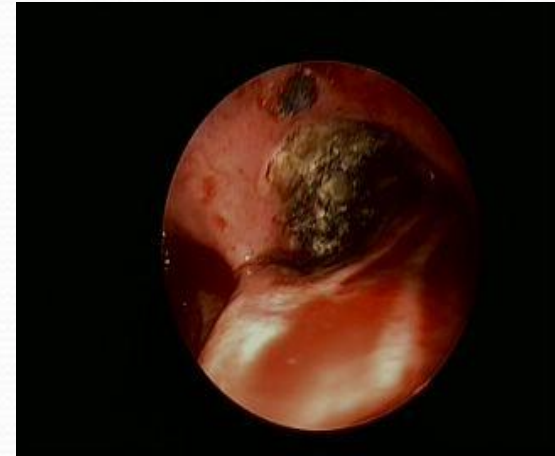
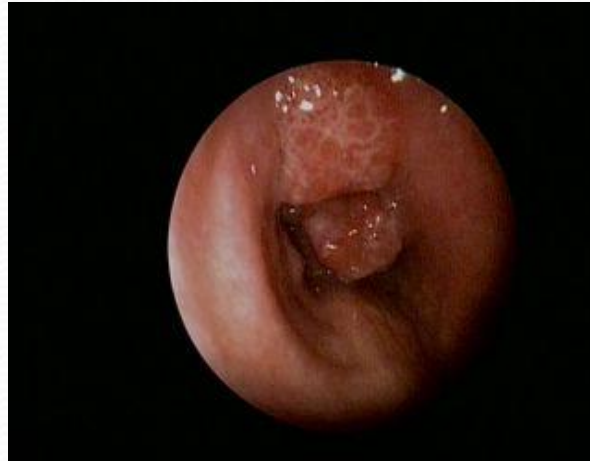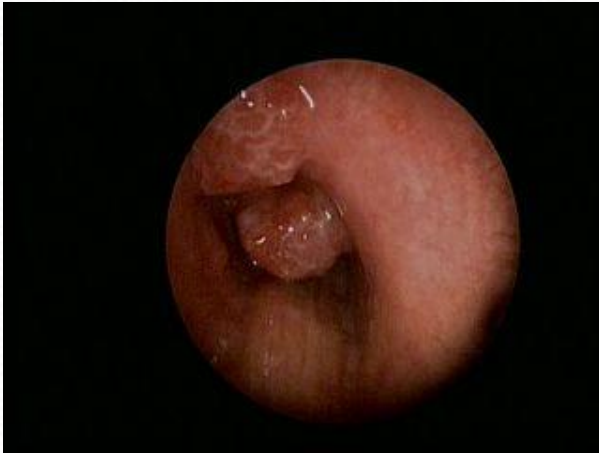M.O



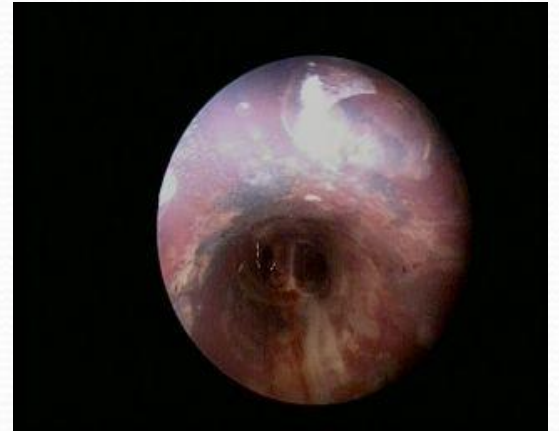
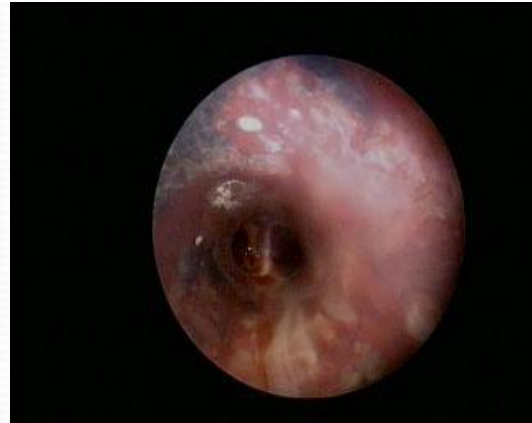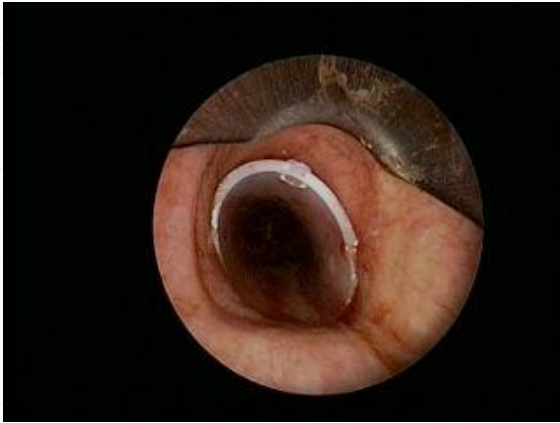K.G



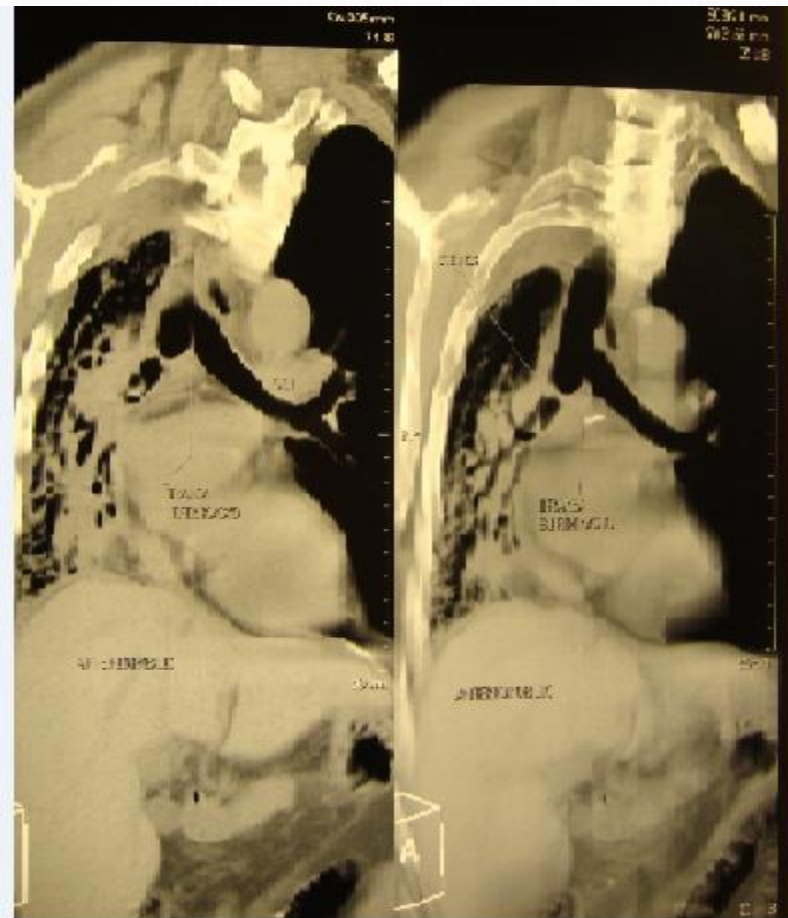
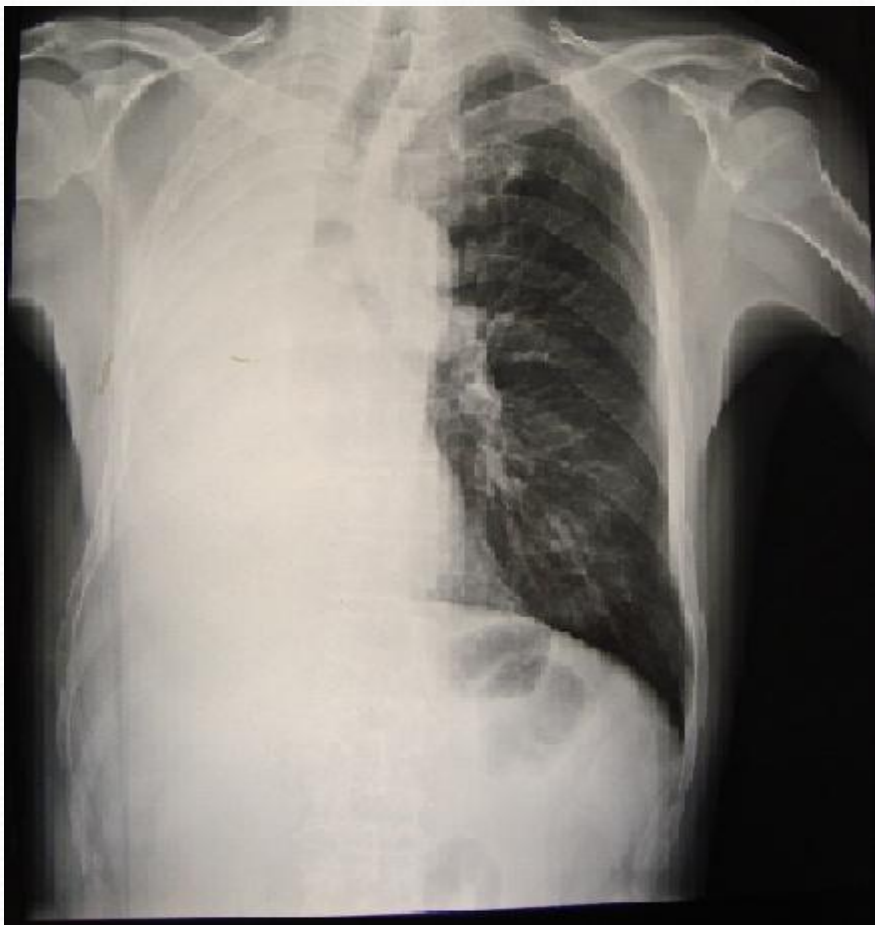
K.G



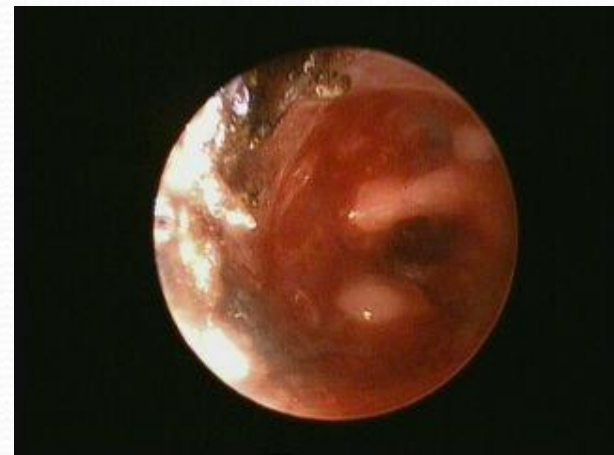
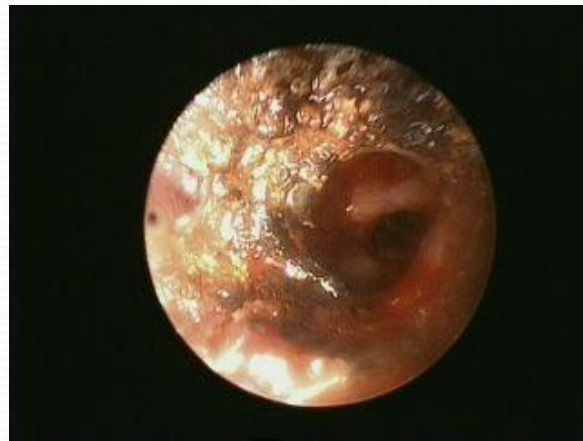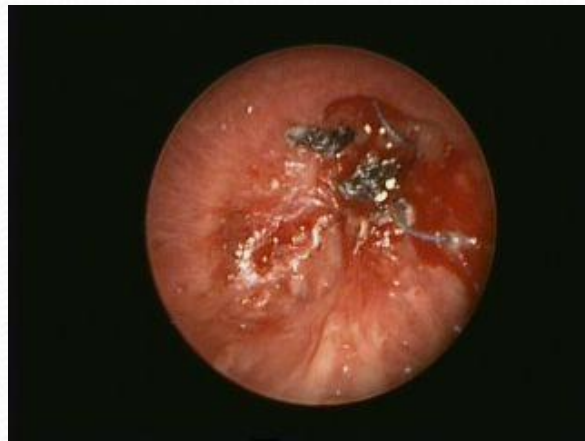K.G



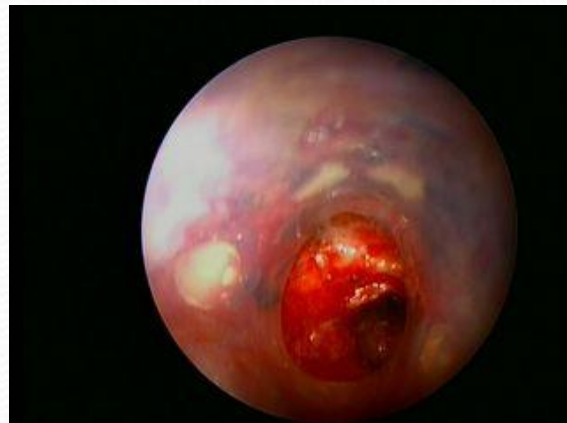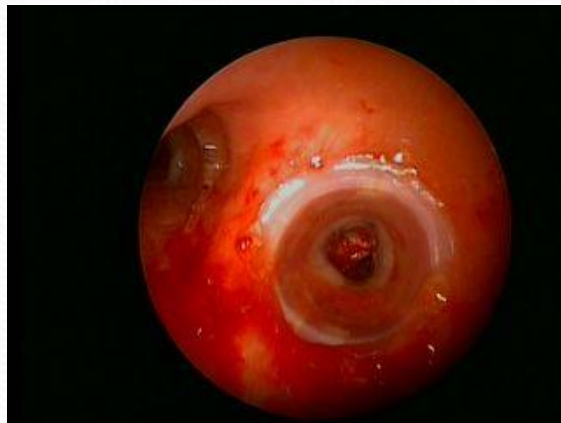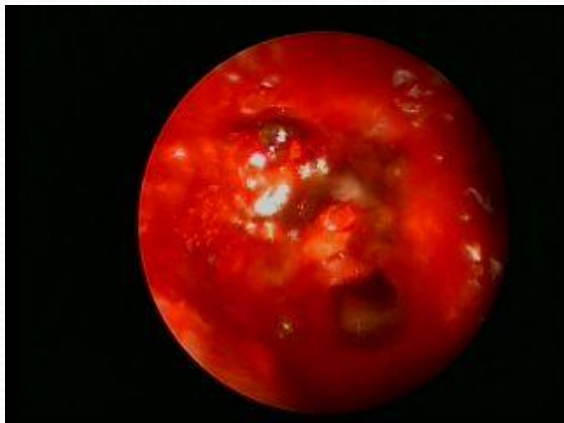
K.A



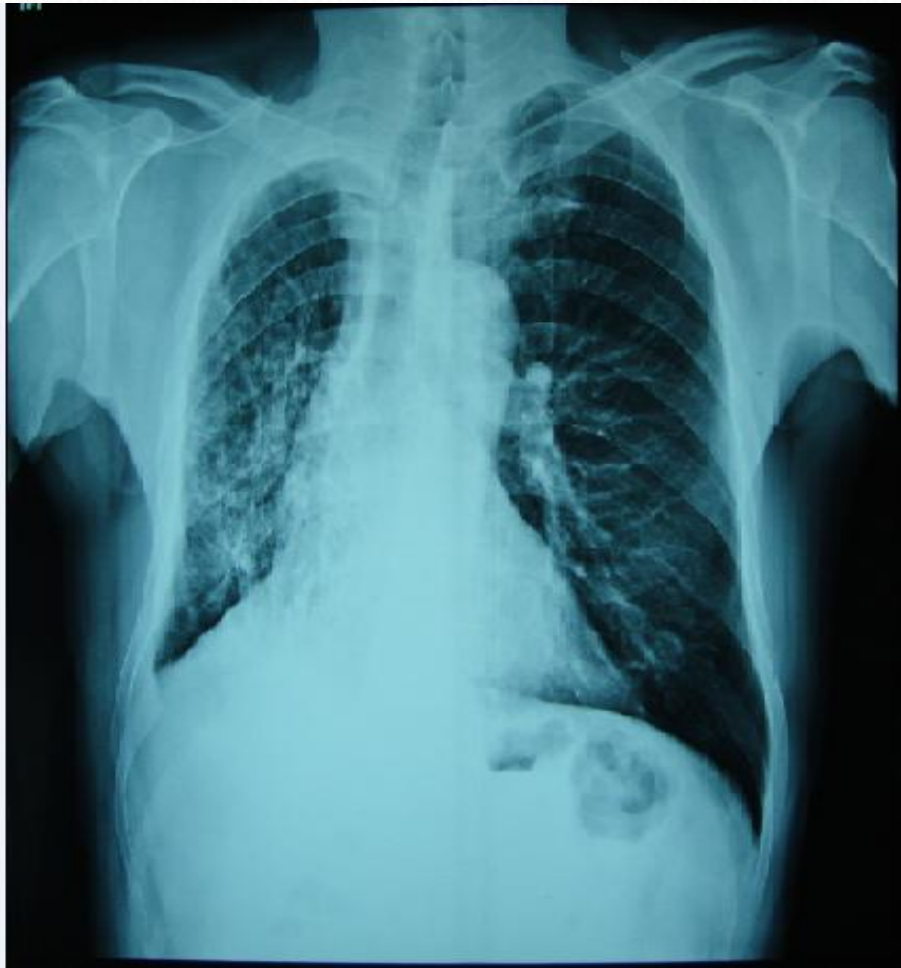K.A



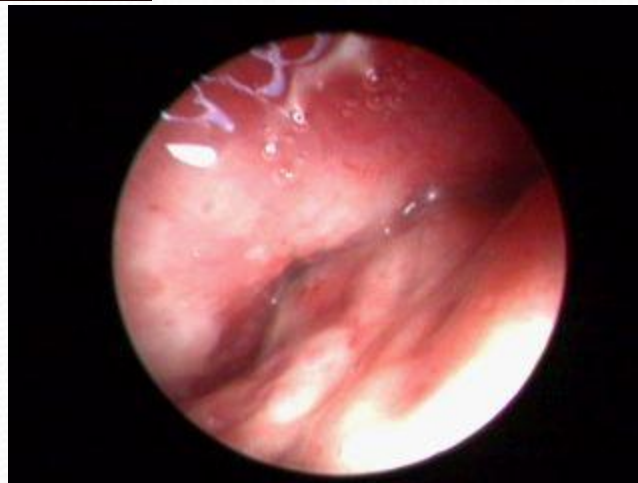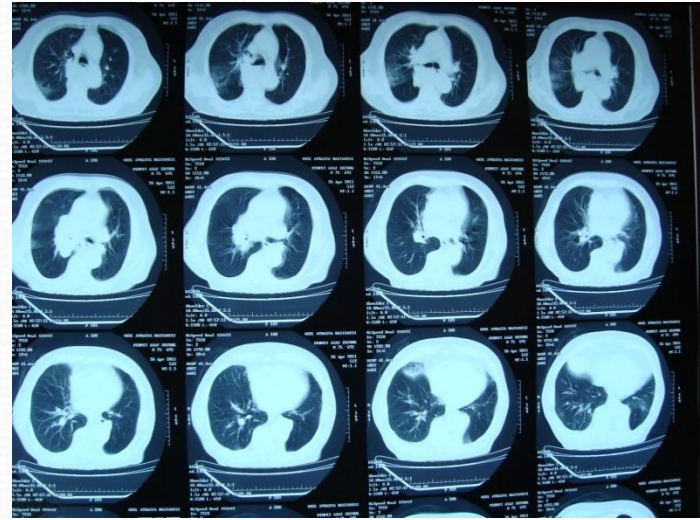
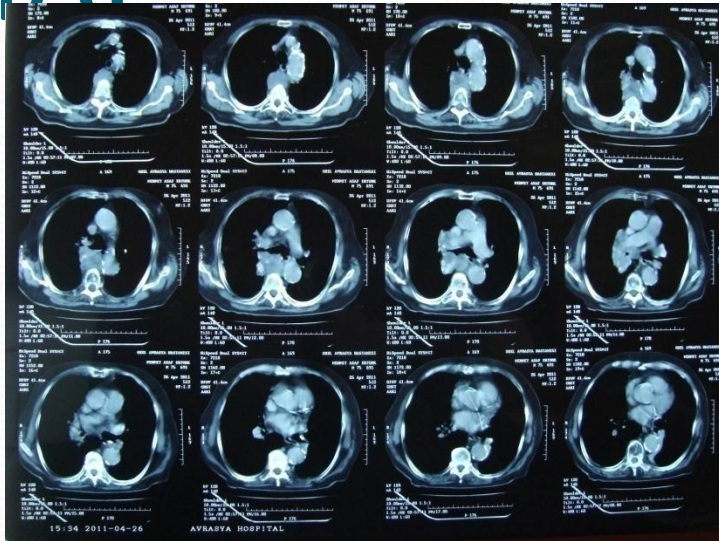
K.A



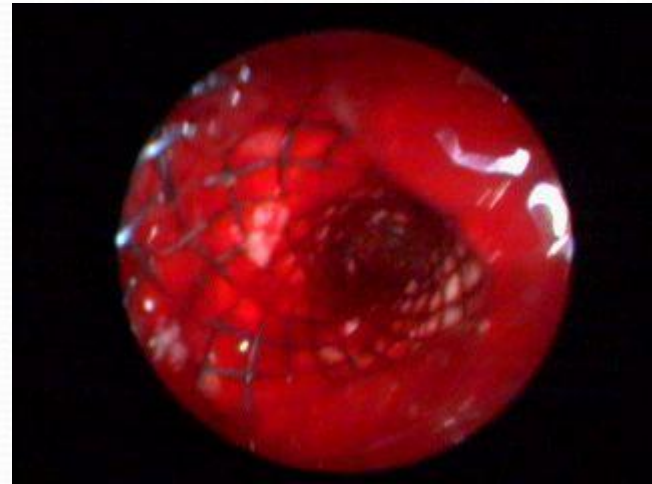
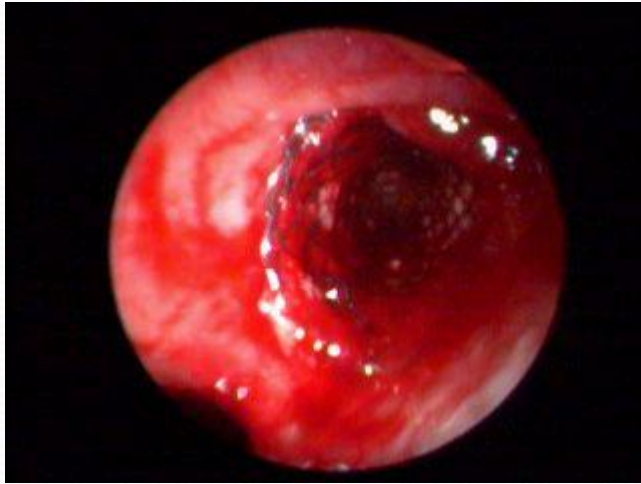
K.A



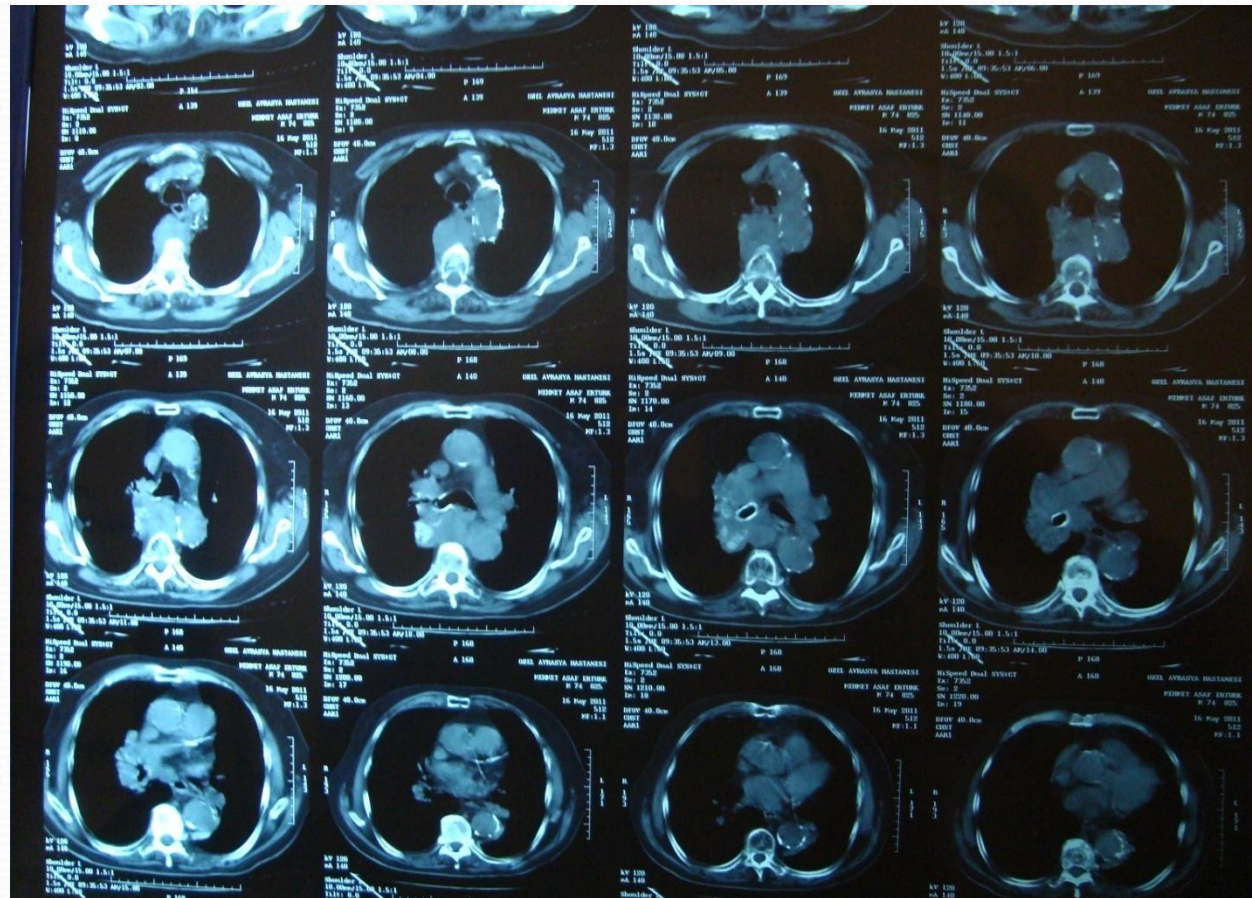
MAF



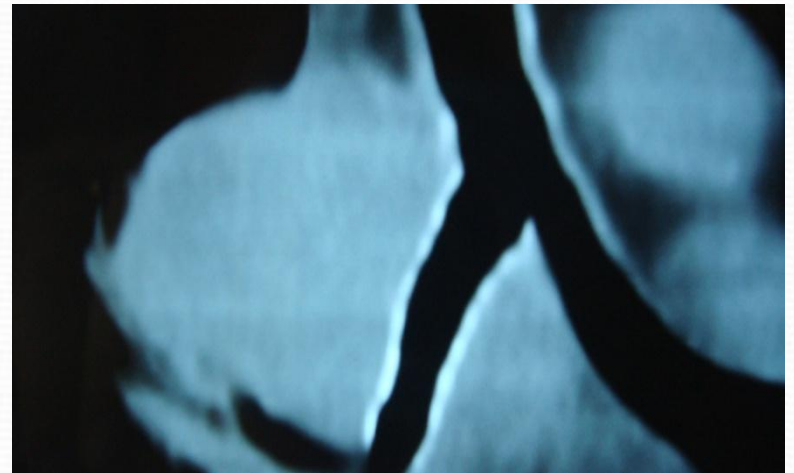
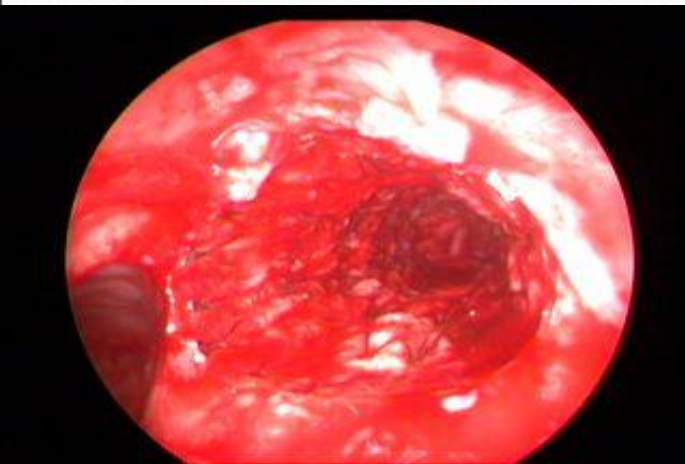
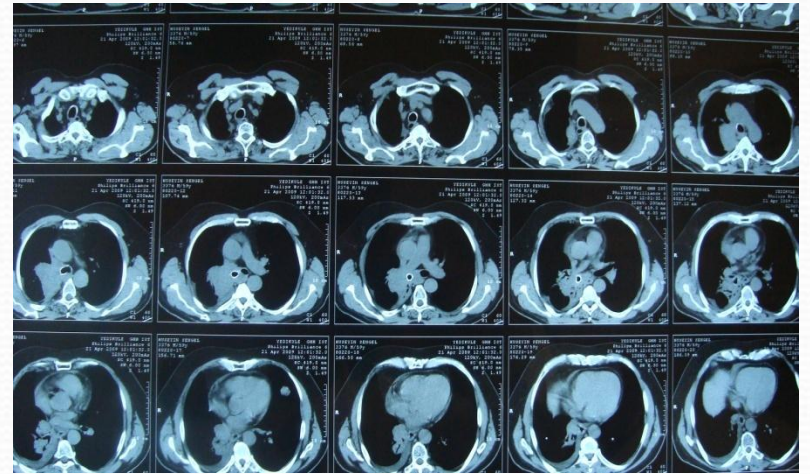
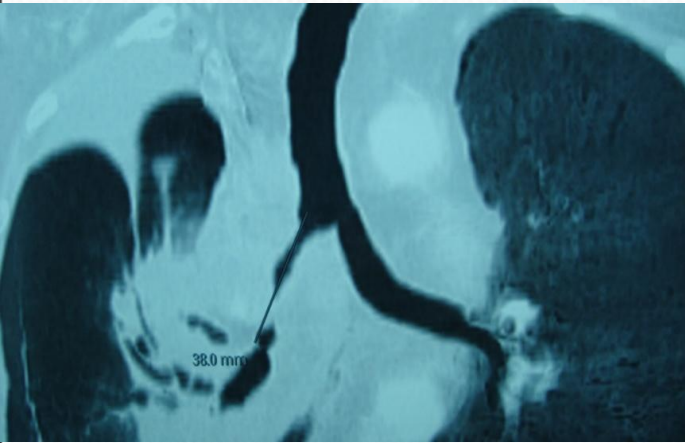M.A.E



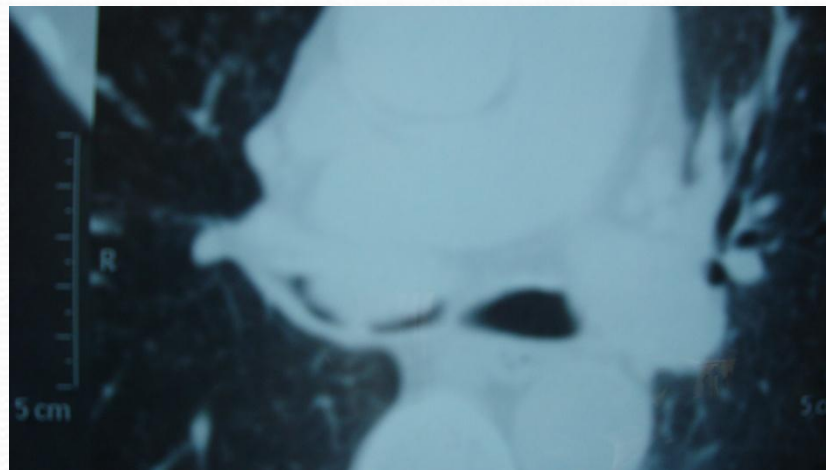
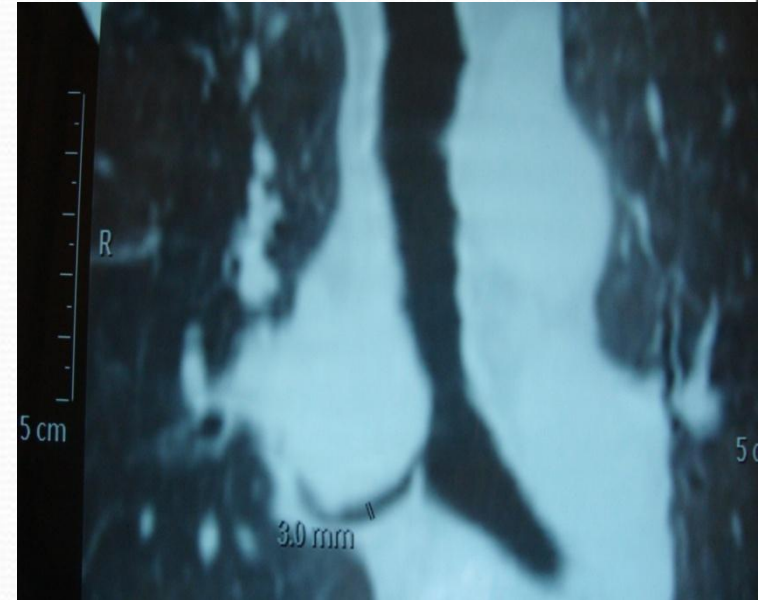
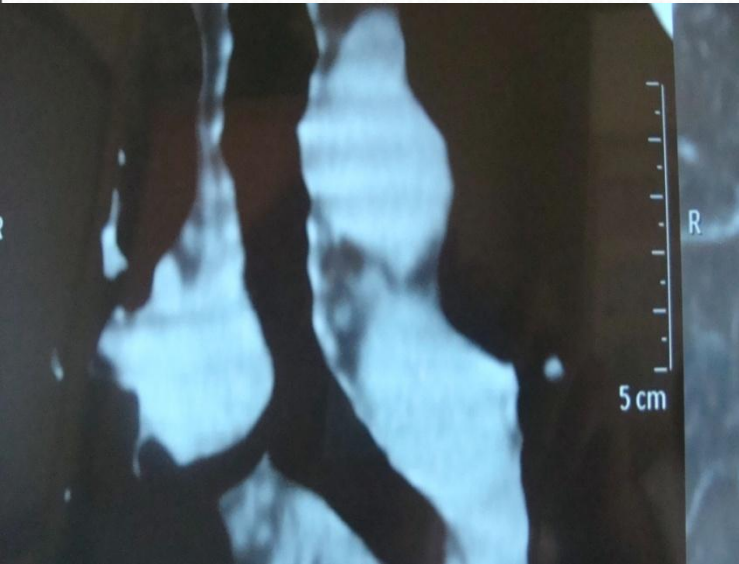M.A.E



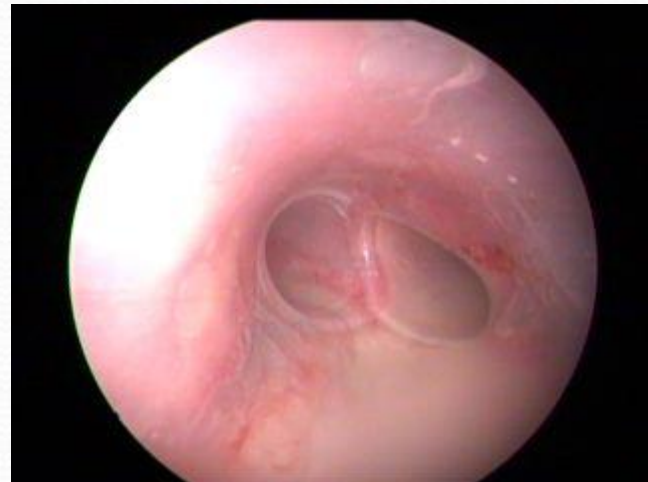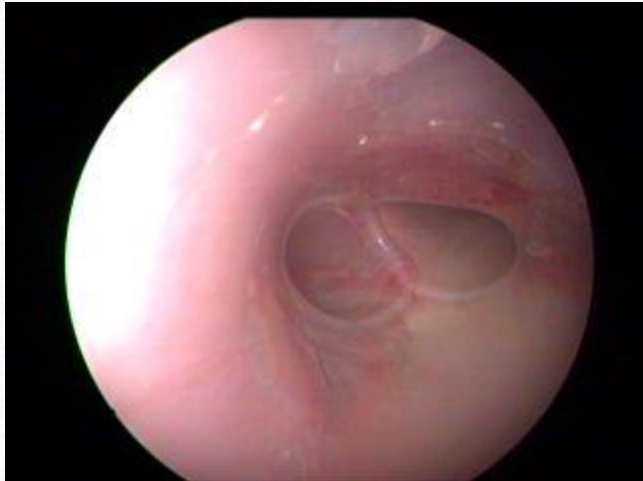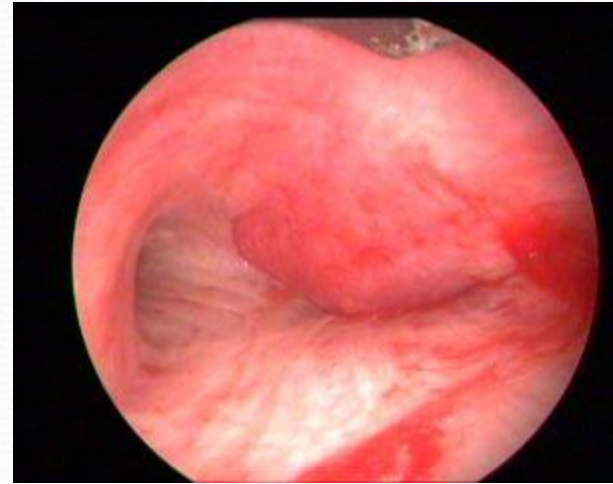
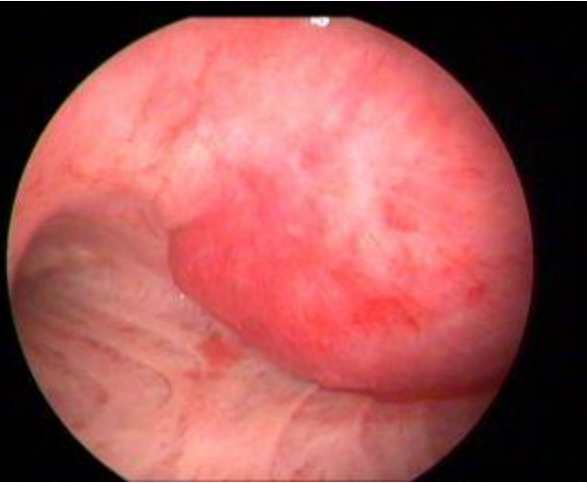
HŞ, 59y, E



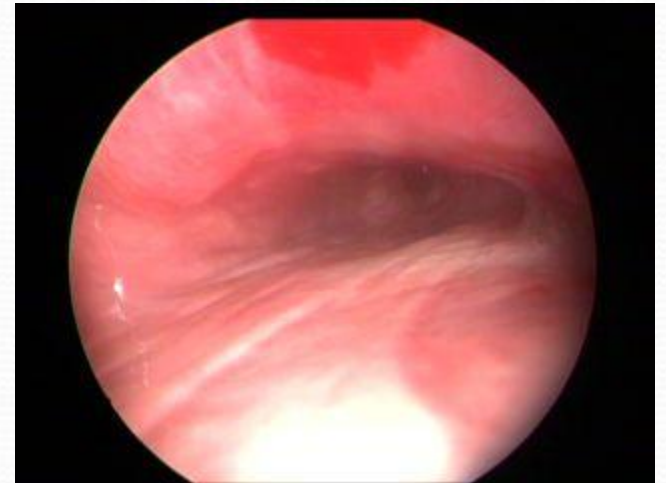
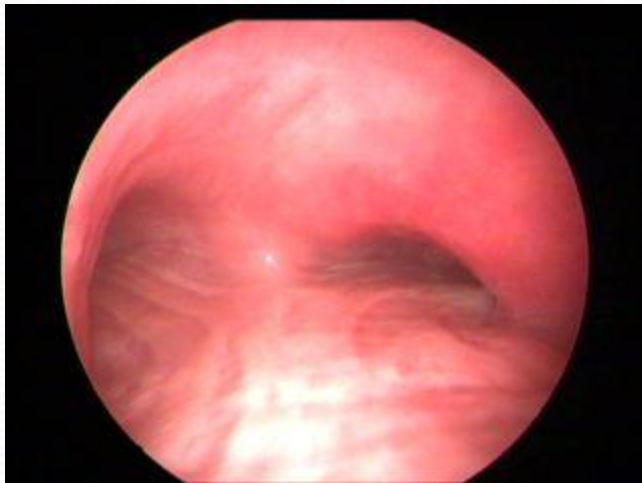
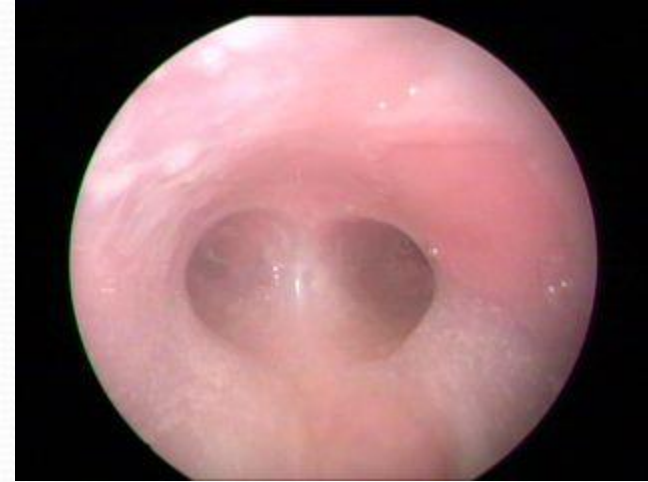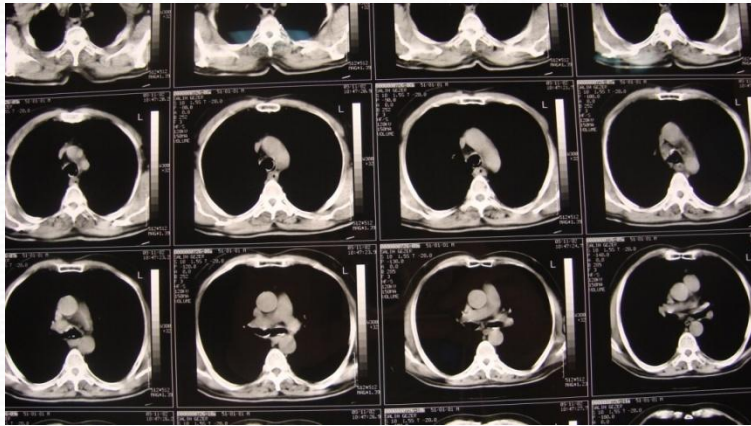
SG, 58Y, E-2.9.2009



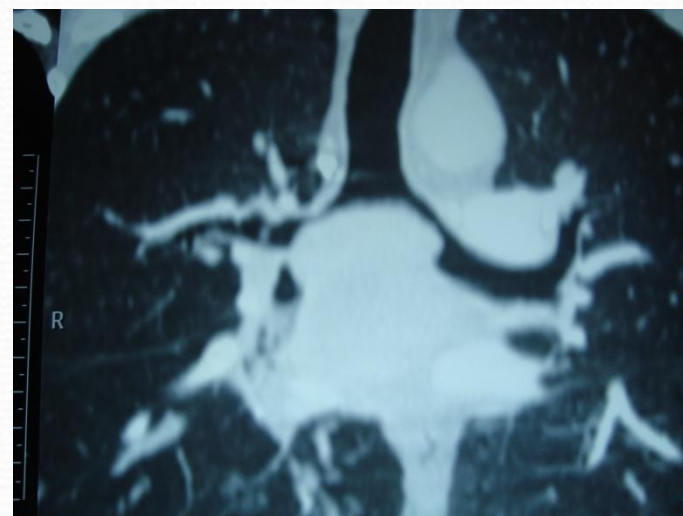
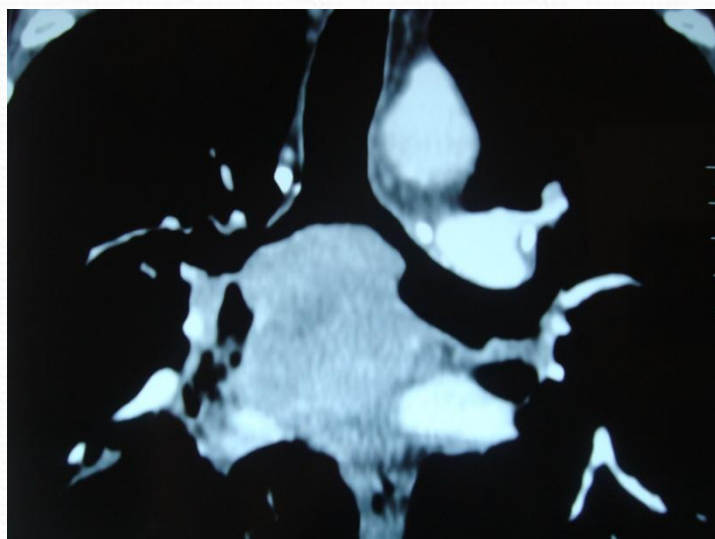
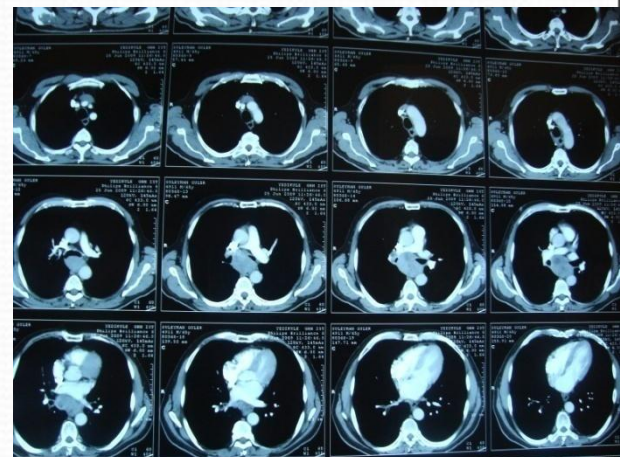
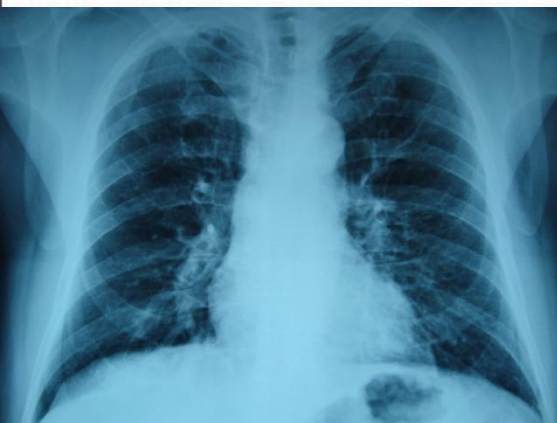SG, 58Y, E-2.9.2009



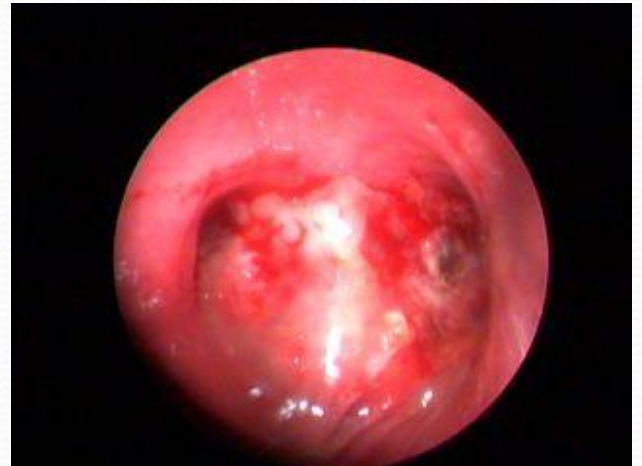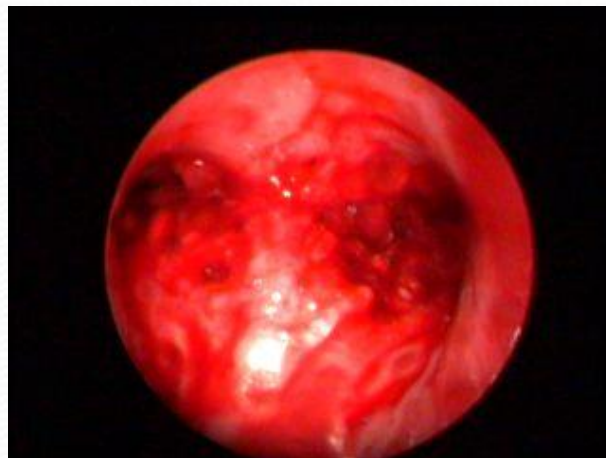
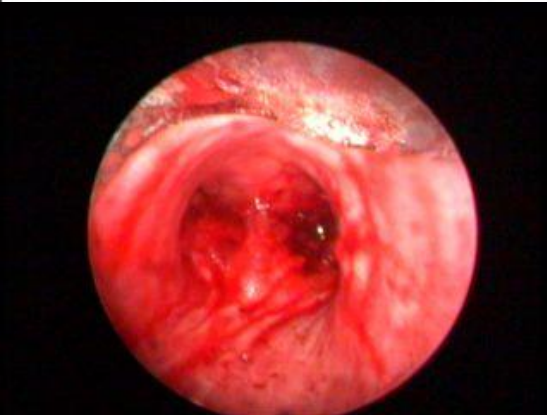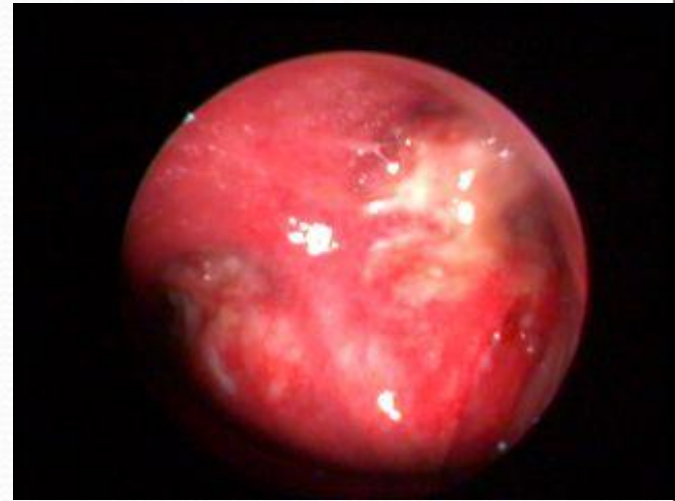
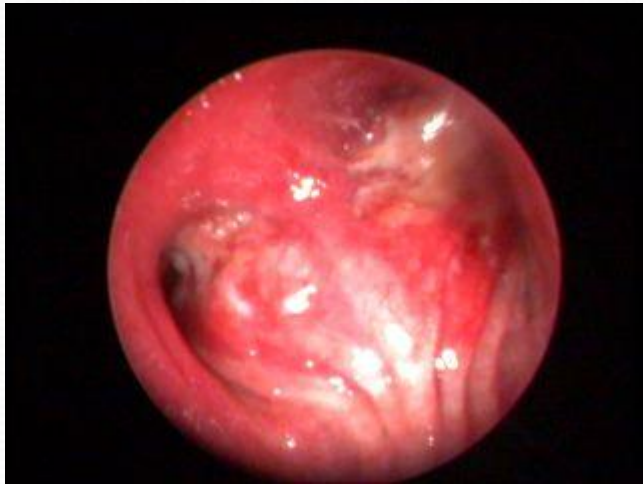SG, 58Y, E-2.9.2009



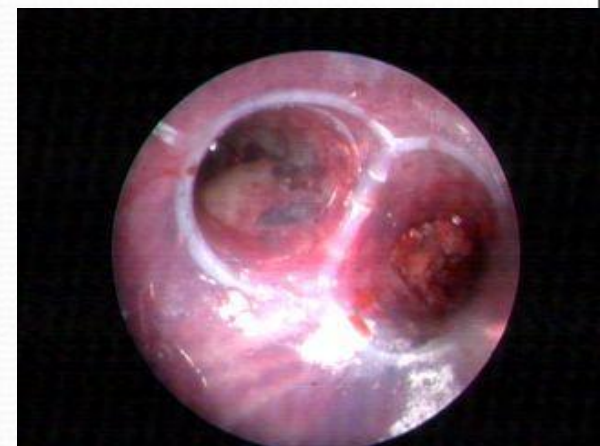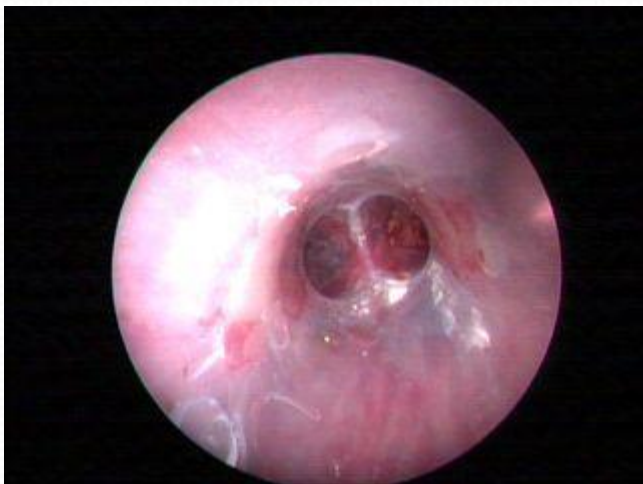SG, 60y, e- 3.7.2009



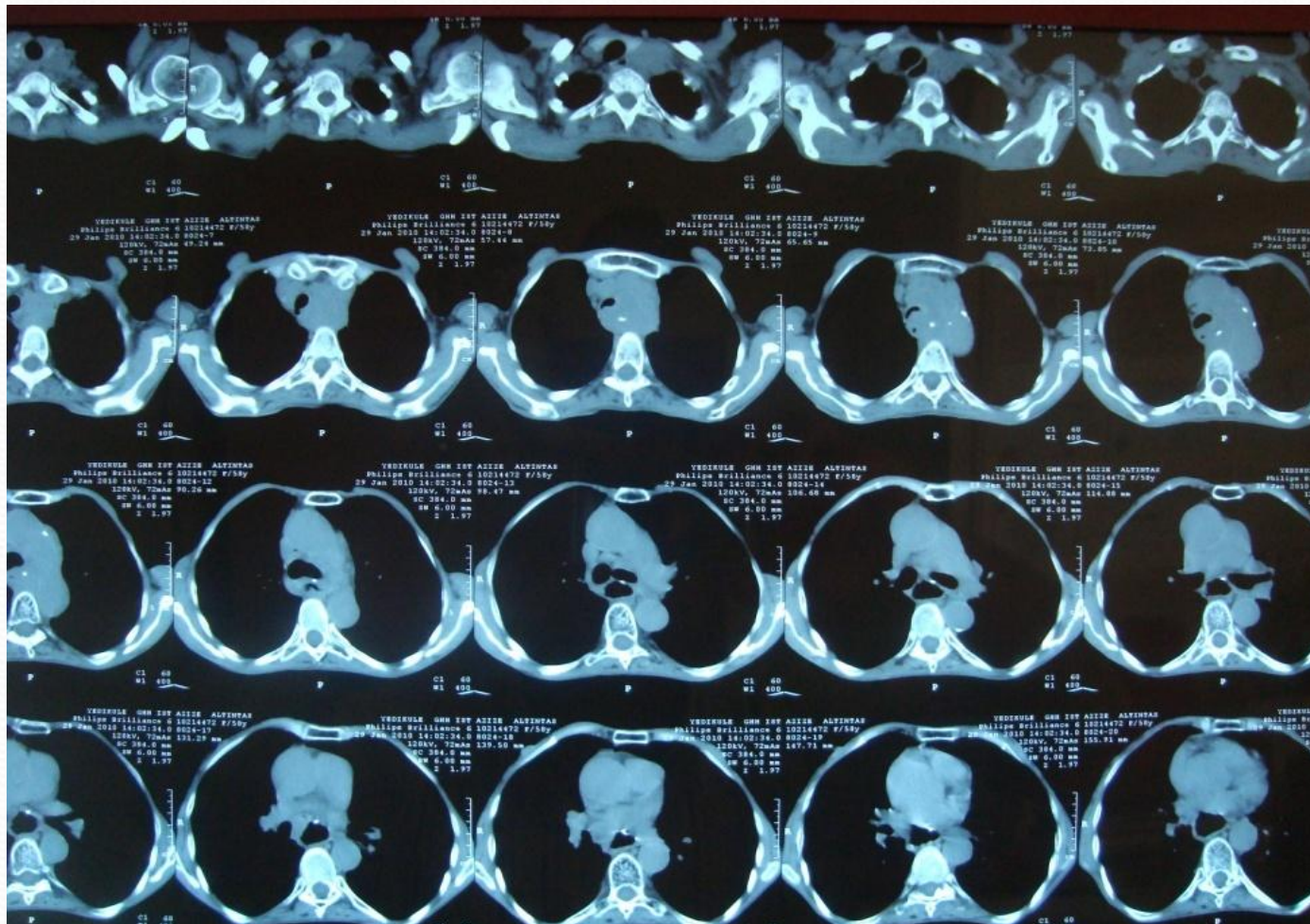
SG, 60y, e- 3.7.2009



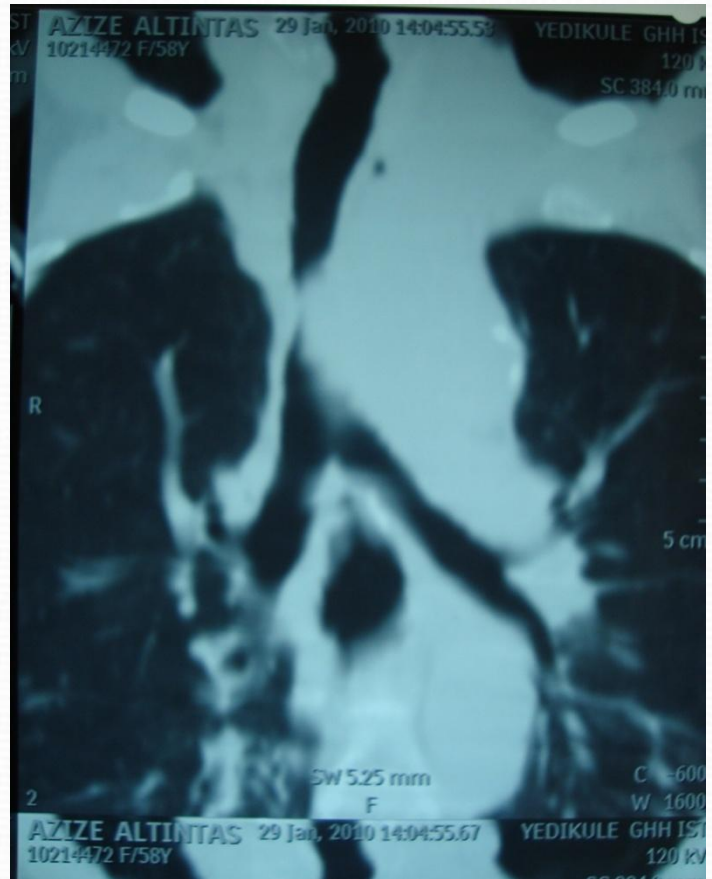
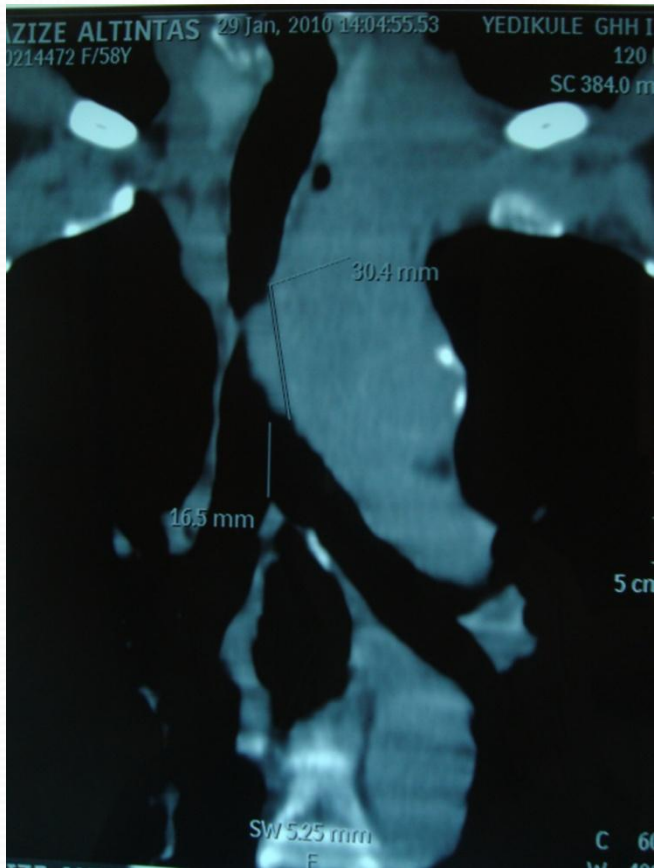
SG, 60y, e- 3.7.2009



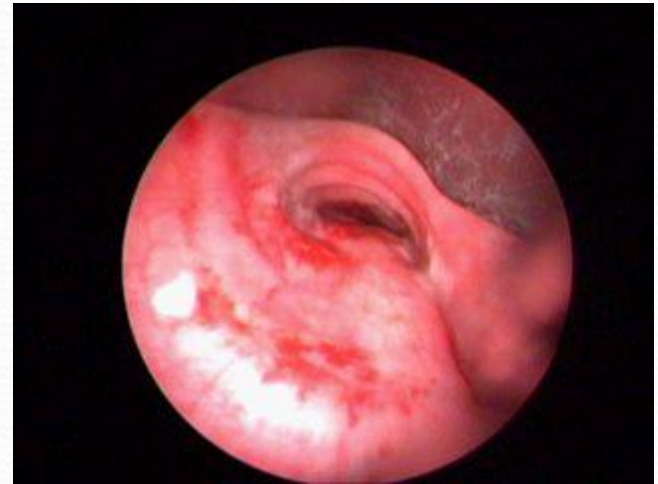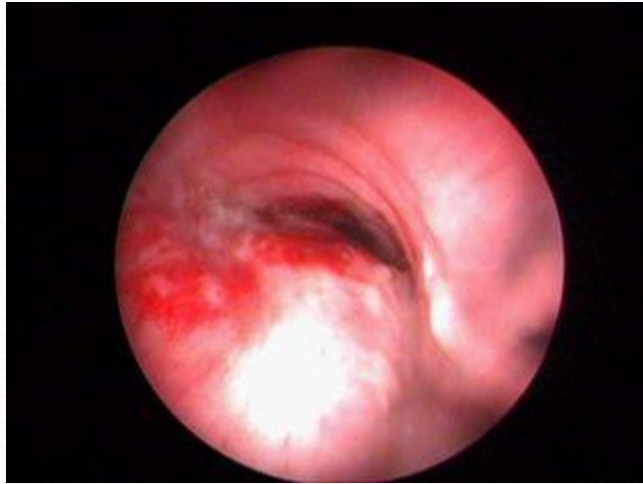AA, 59 Y, K

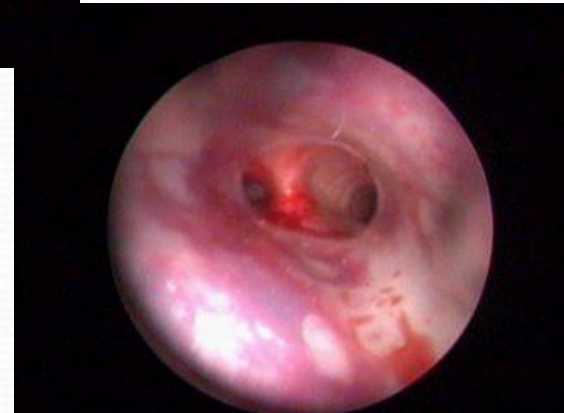
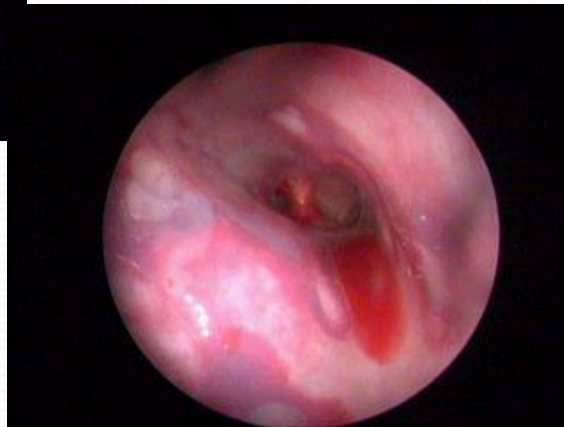
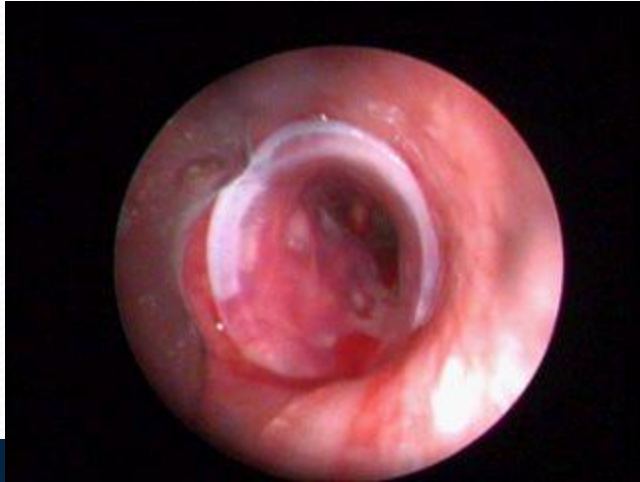AA



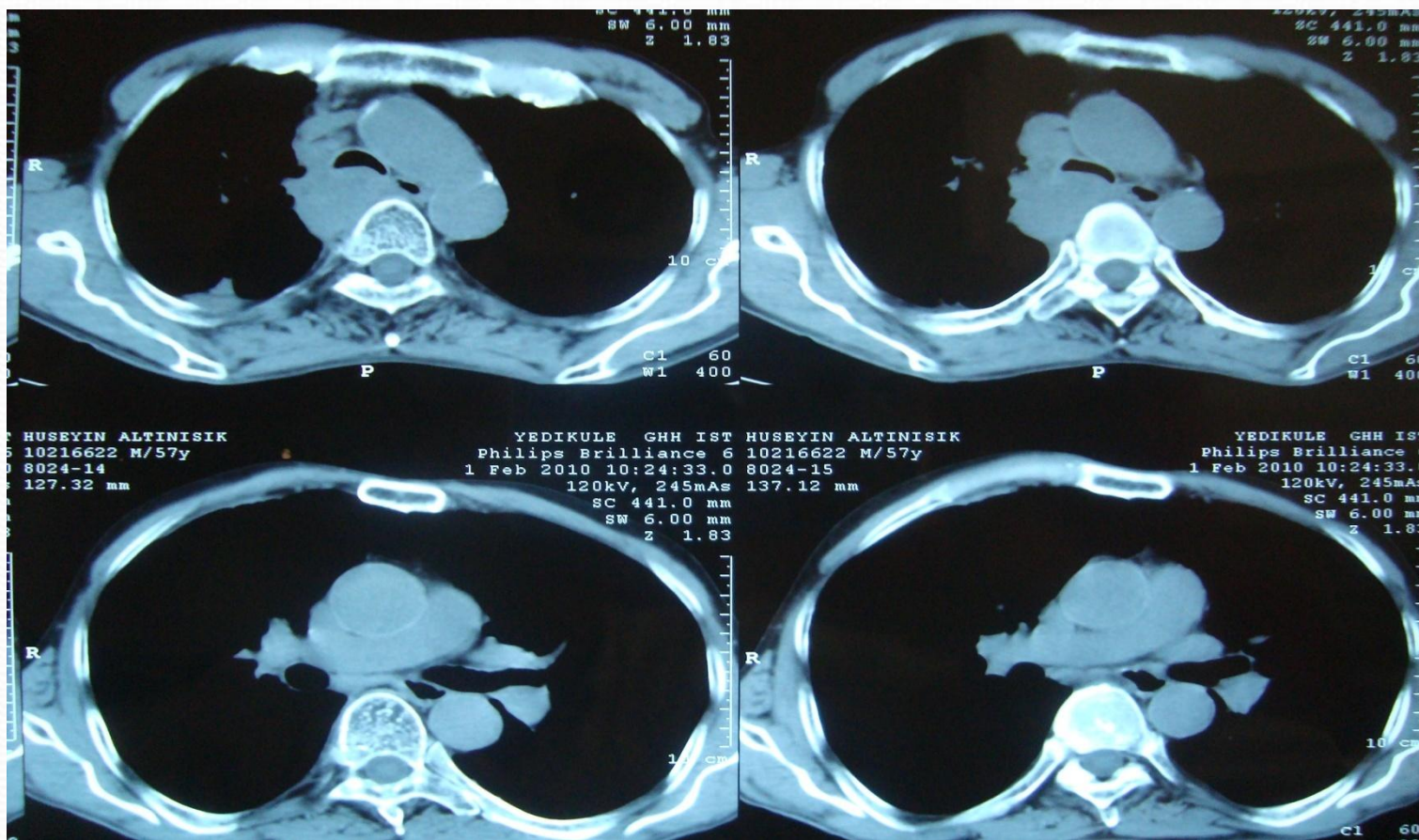
AA



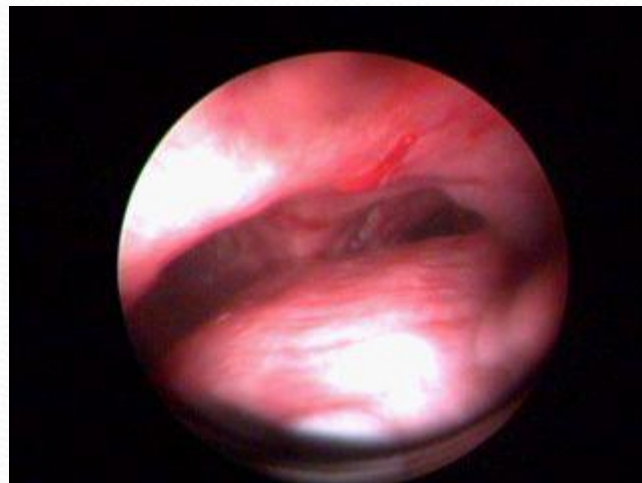
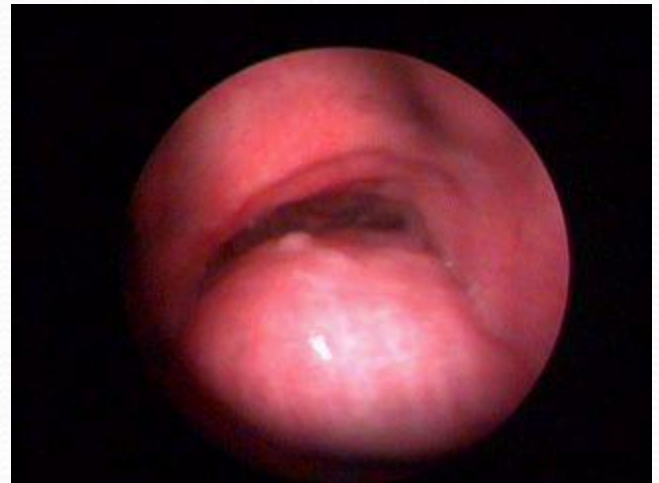
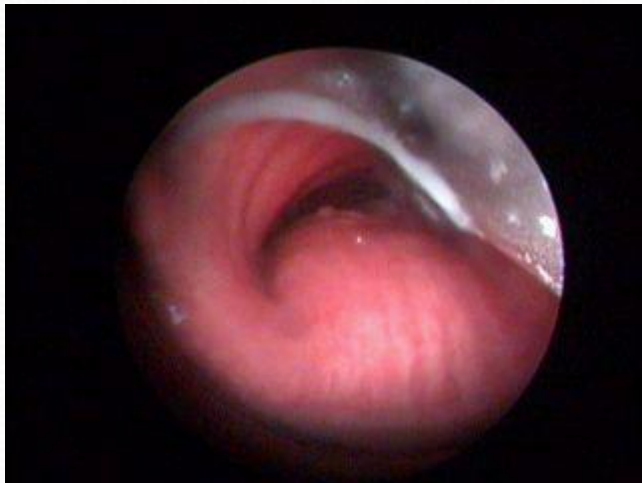

16x70 mm dumon silikon stent

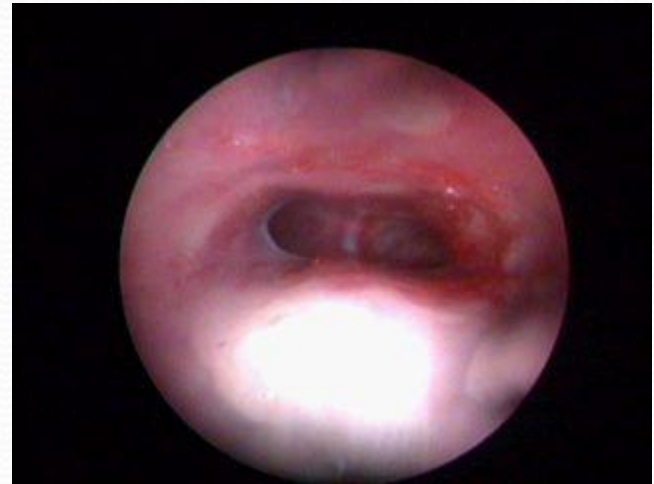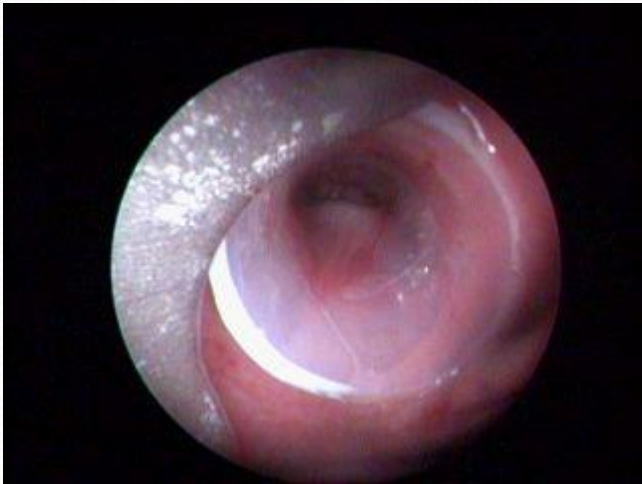HA, 57 Y, E



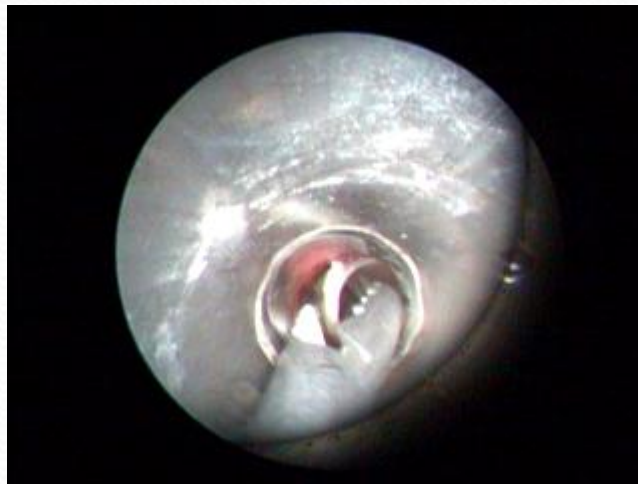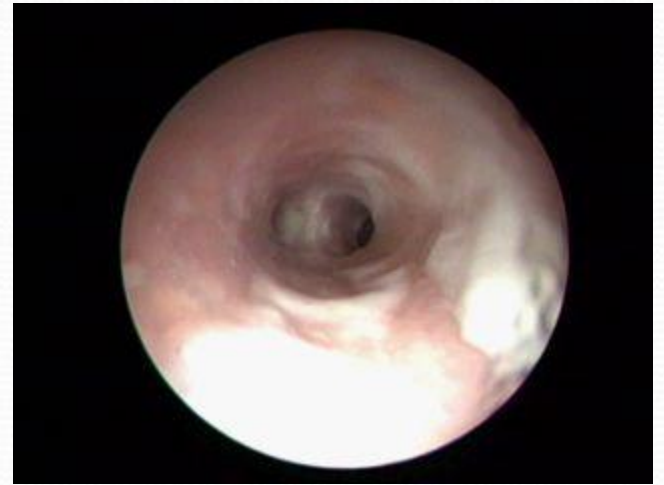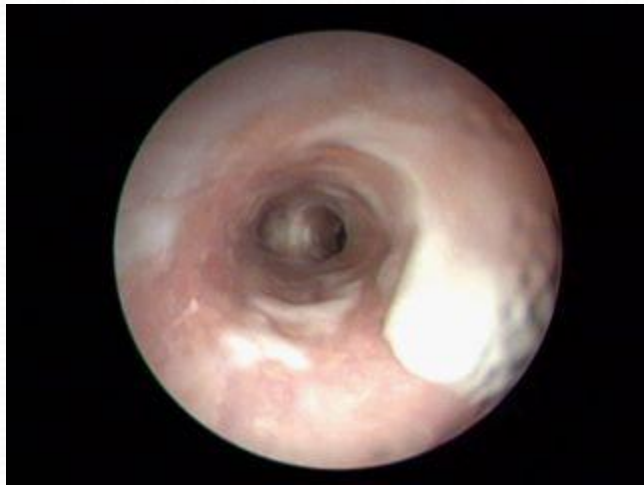HA



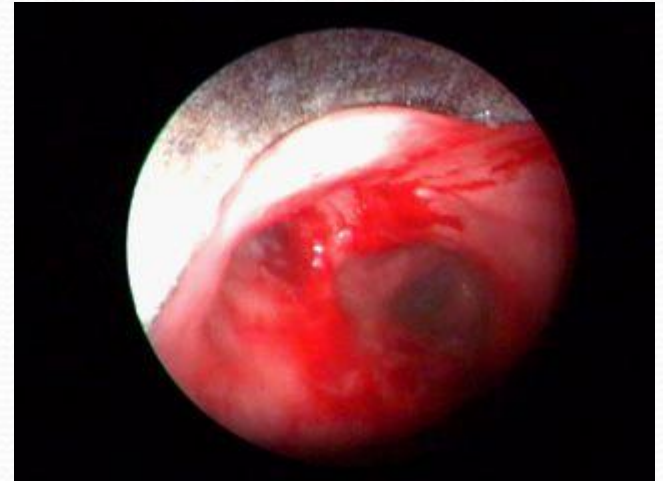
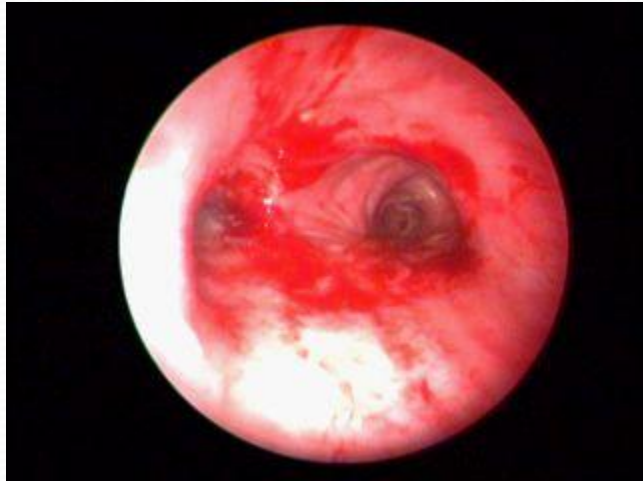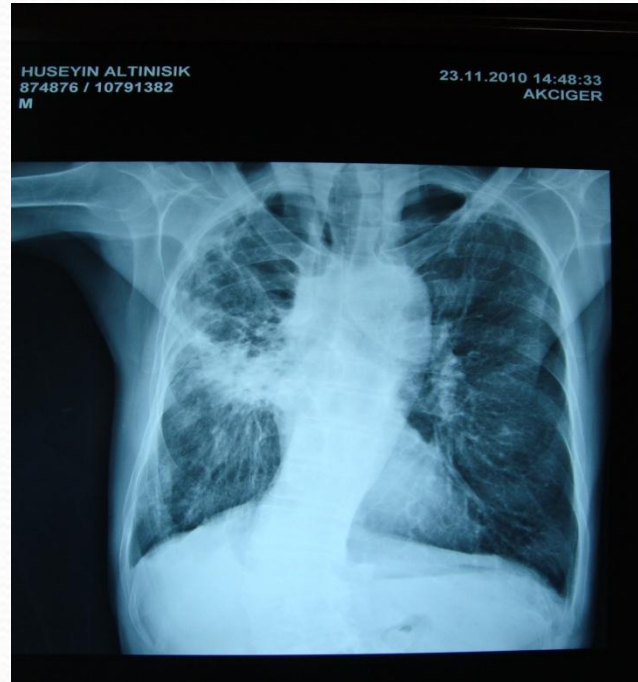HA



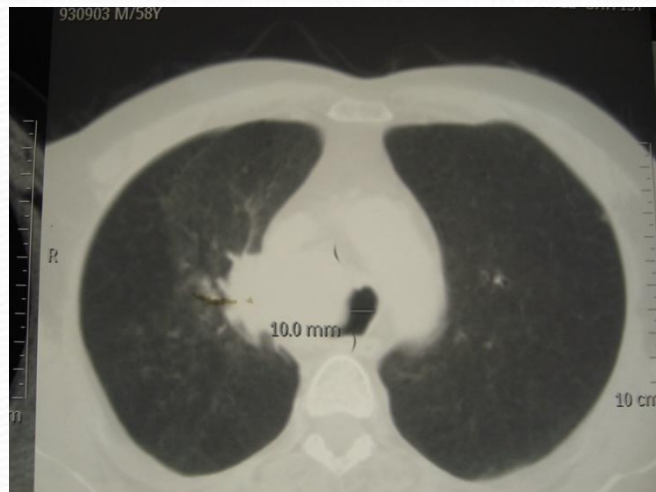
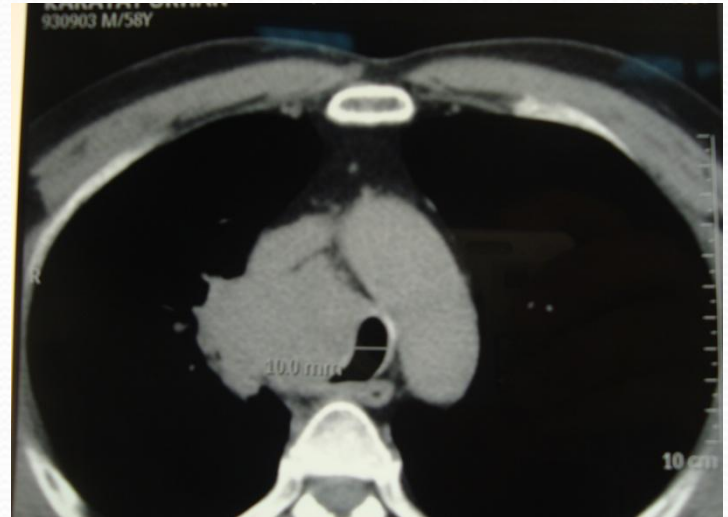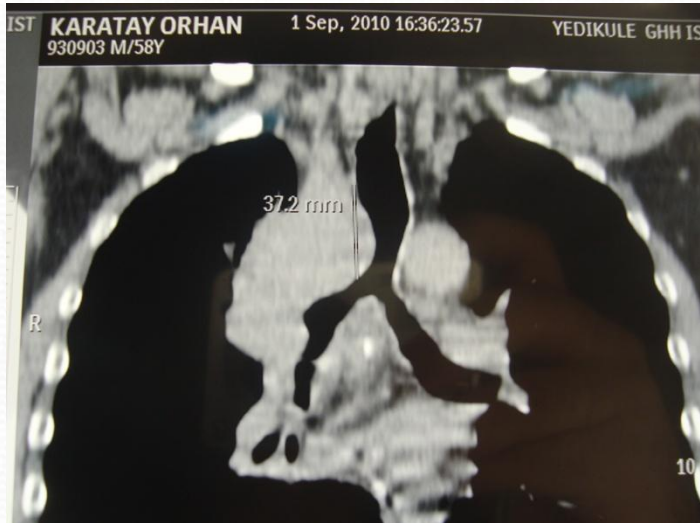
HA



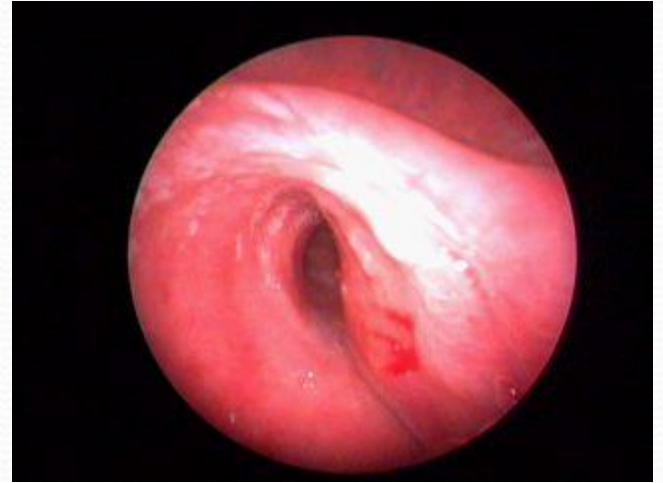
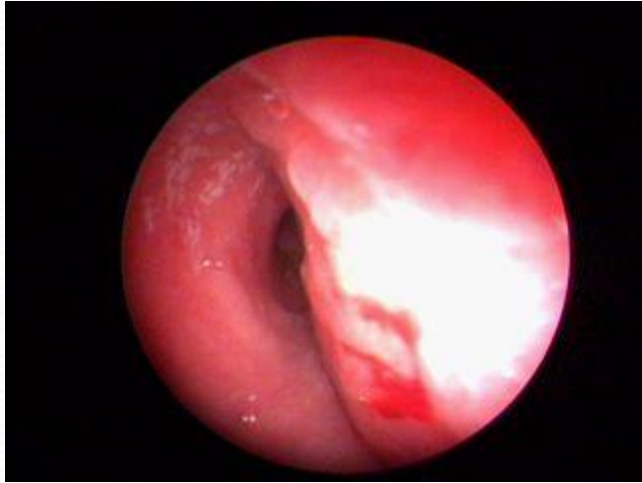HA



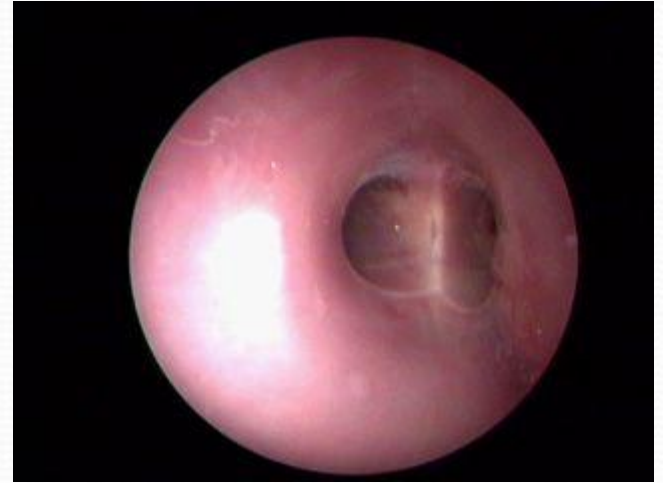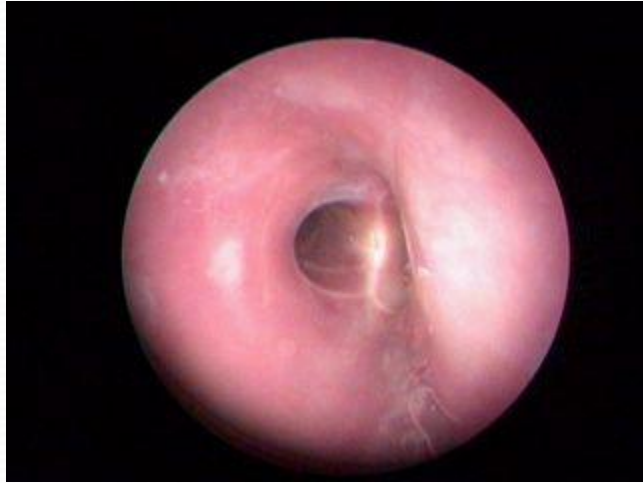OK, 46 Y, E



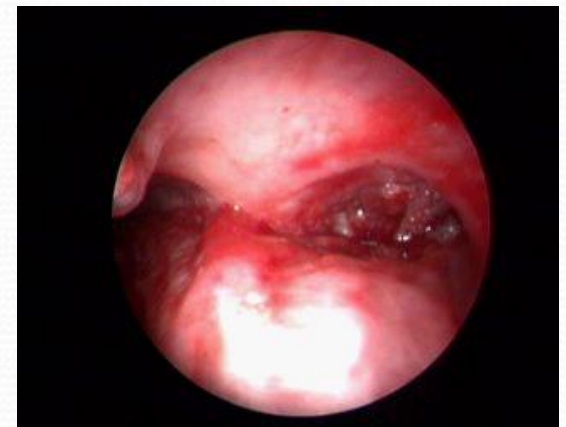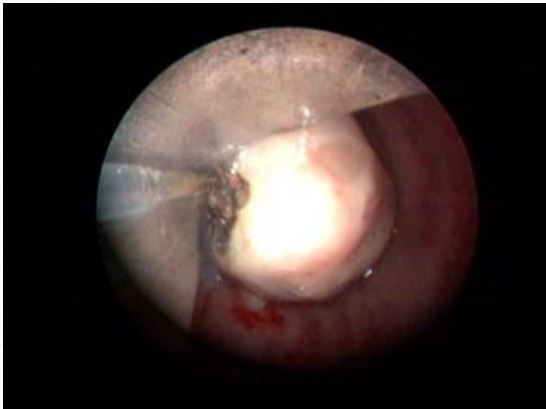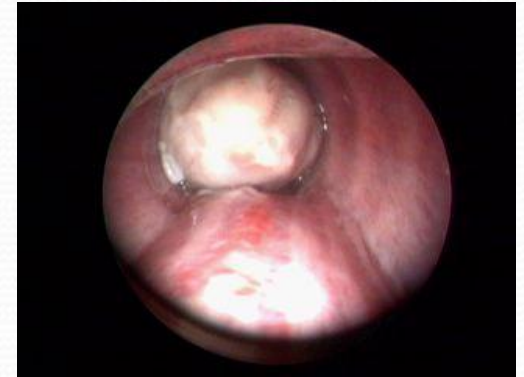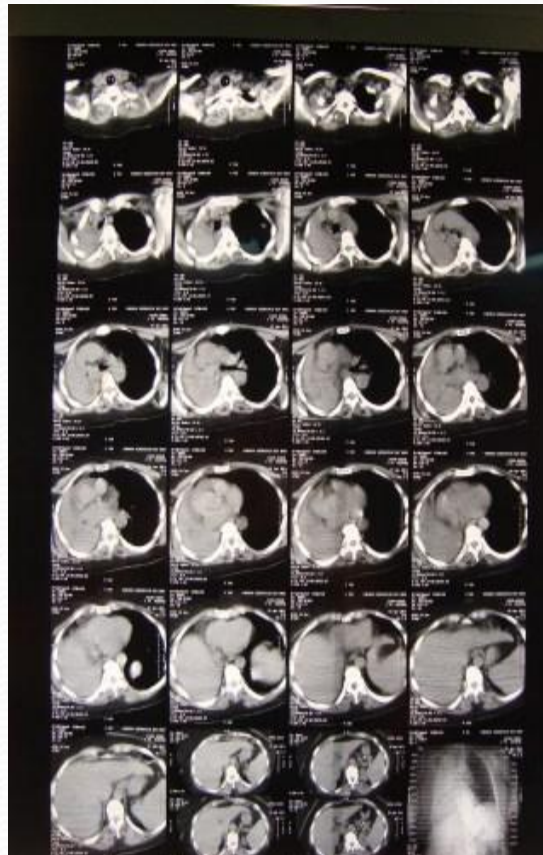
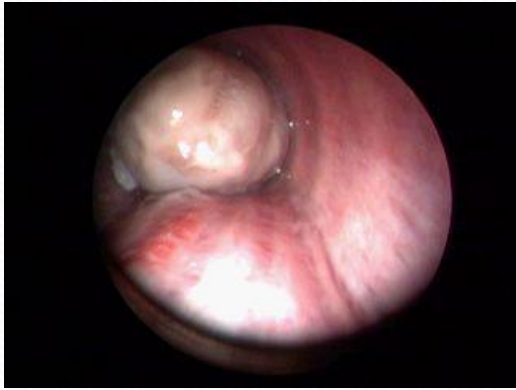
OK



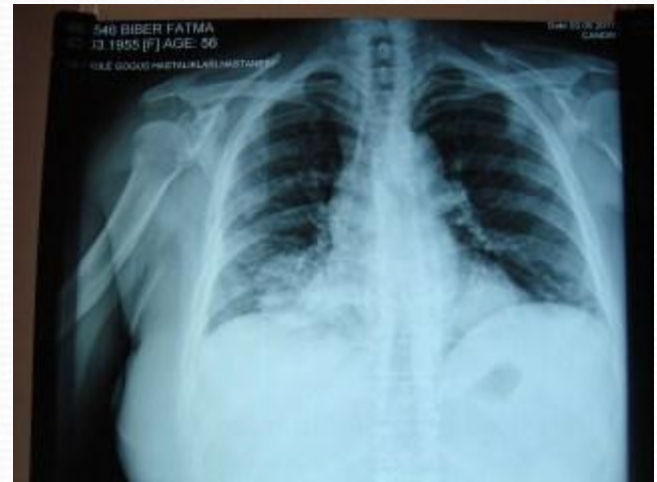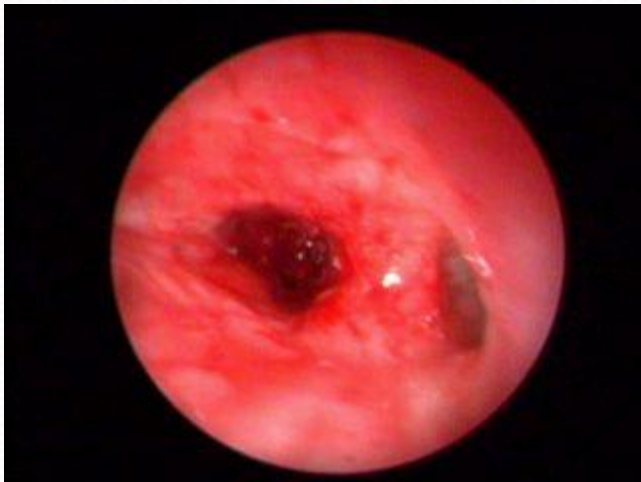OK



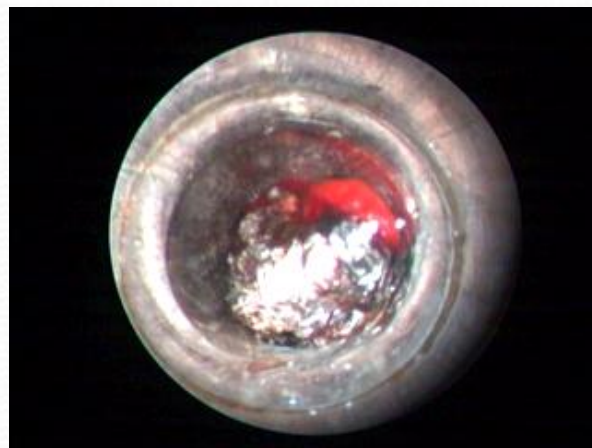
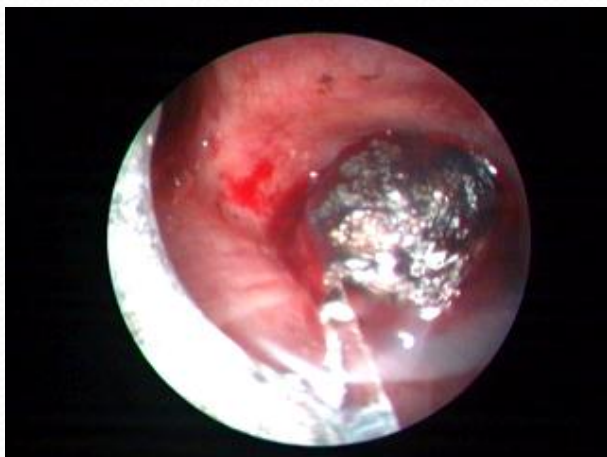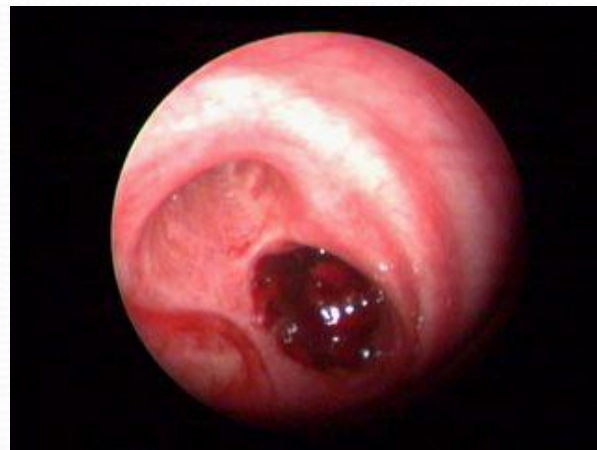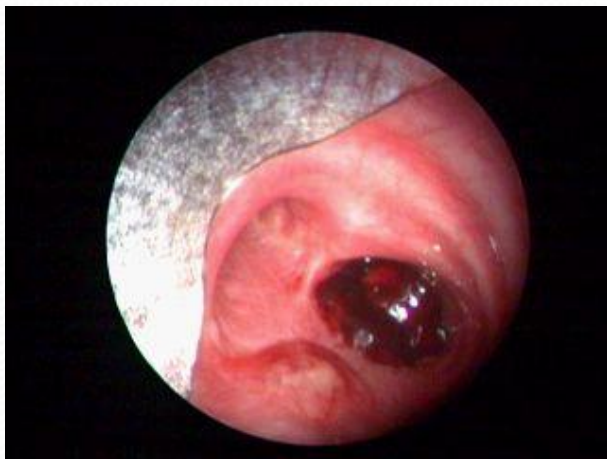FB



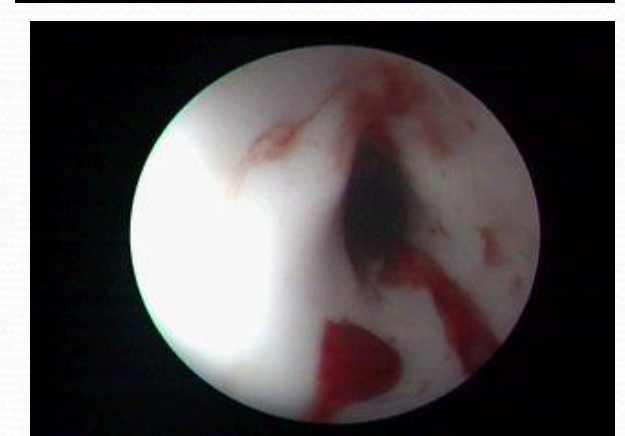
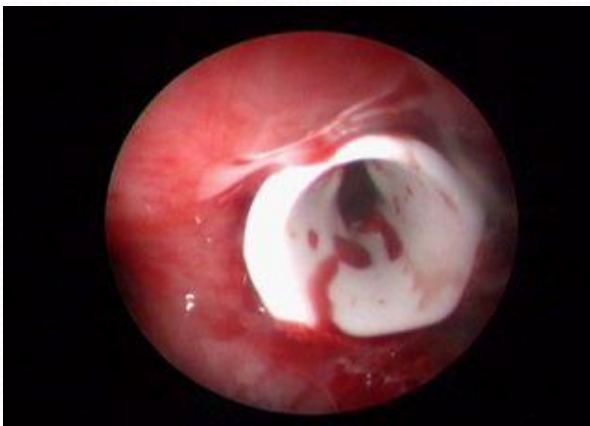
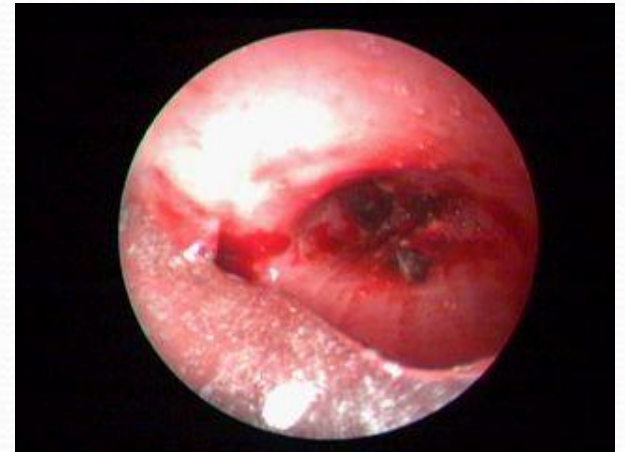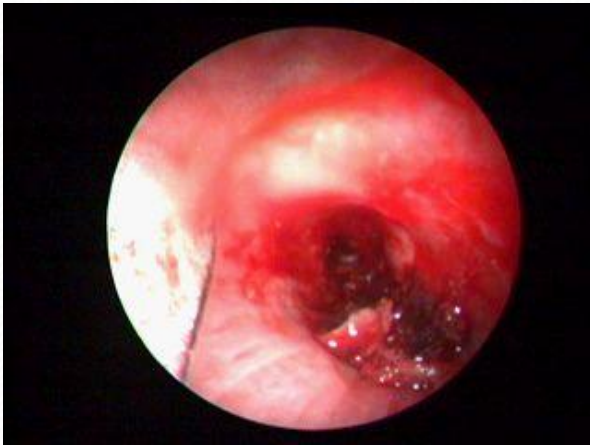FB



AE



AE



11.OLGU TRANSPLANTASYON

