

Pulmoner Vasküler Hastalıklar

# AKUT PULMONER EMBOLİDE RADYOLOJİK ÖNEMLİ MESAJLAR

Dr. Recep SAVAŞ

Ege Üniversitesi Tıp Fakültesi Radyoloji AD, İzmir

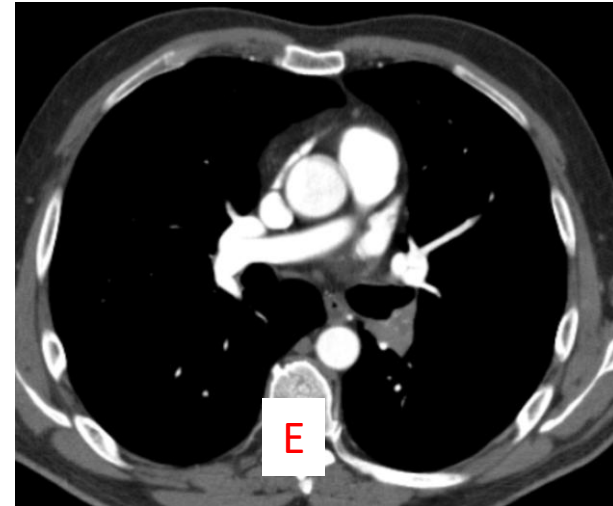
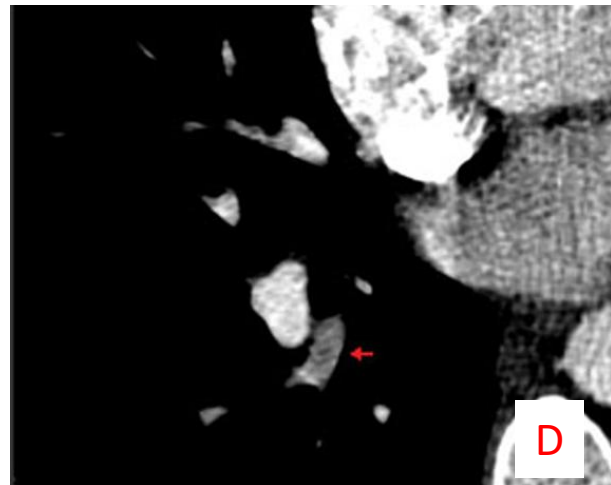
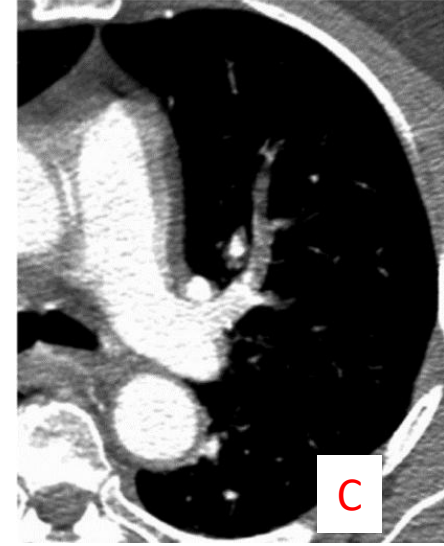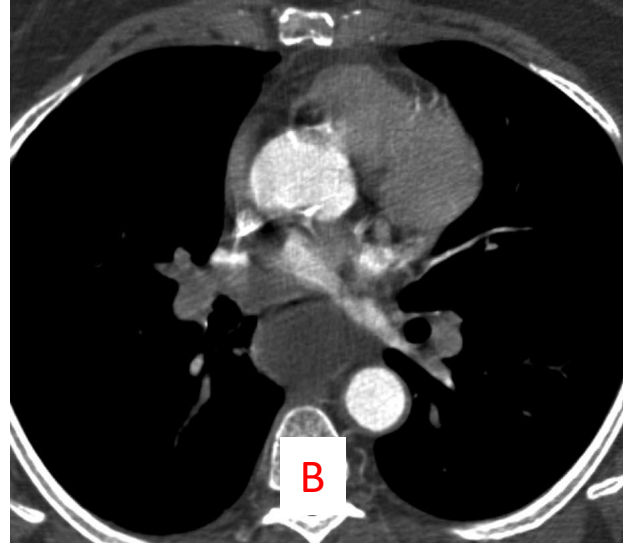
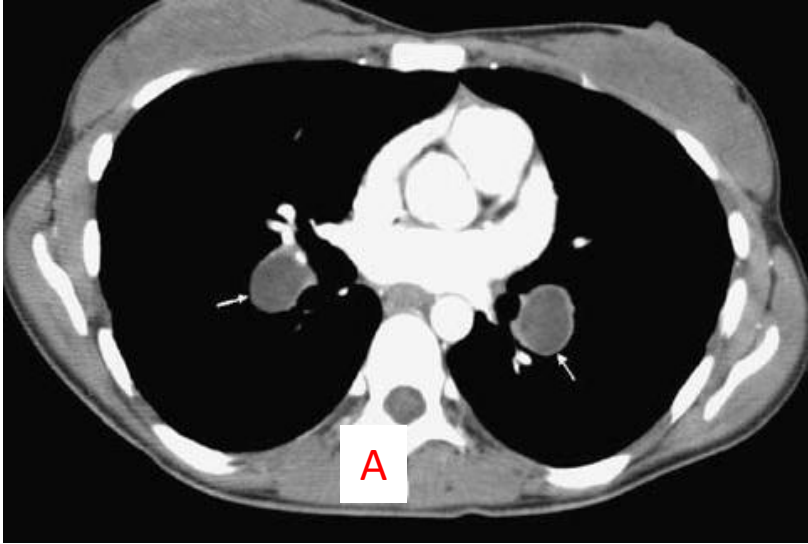
AKCİĞER HASTALIKLARI VE YOĞUN BAKIM GÜNLERİ TANI VE TEDAVİDE SON GELİŞMELER SEMPOZYUMU  
9 ARALIK 2017, CUMARTESİ HYATT REGENCY, ATAKÖY/İSTANBUL

# ÖZET:

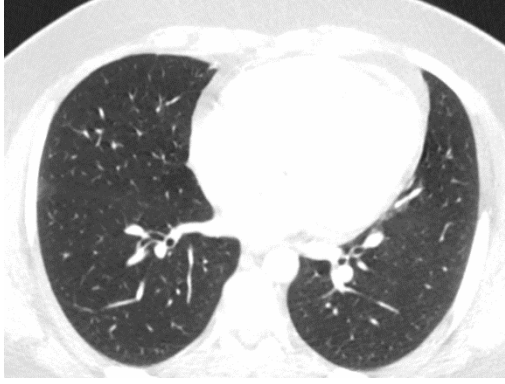
\*Mesajlarla :

- Radyolojik yöntemler ve bulgular
- Tanı zorlukları
- Kontrastsız BT'den emboli düşünme kriterleri

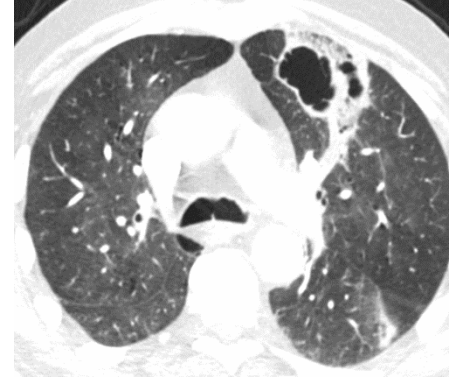Hangi görüntü için pulmoner tromboemboli düşünürsünüz ?



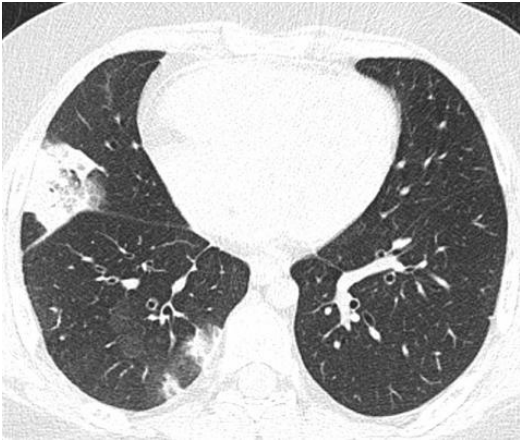
Hangi görüntü için pulmoner tromboemboli düşünmezsiniz ?



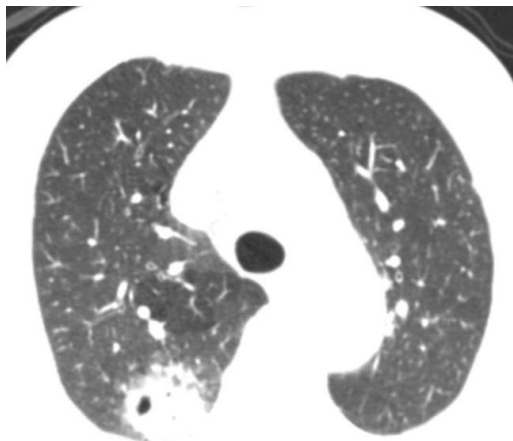
A



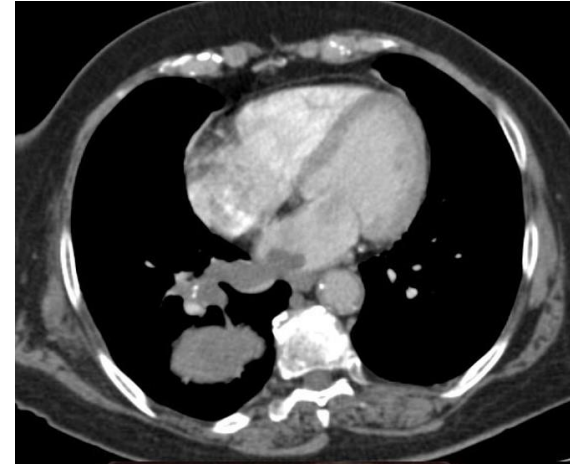
B



C



D



E

# GÖRÜNTÜLEME YÖNTEMLERİ

- Direk göğüs grafisi
- Bilgisayarlı tomografi
- Manyetik rezonans görüntüleme/ MR anjiyografi
- Anjiyografi (DSA)
- Doppler US
- PET/BT

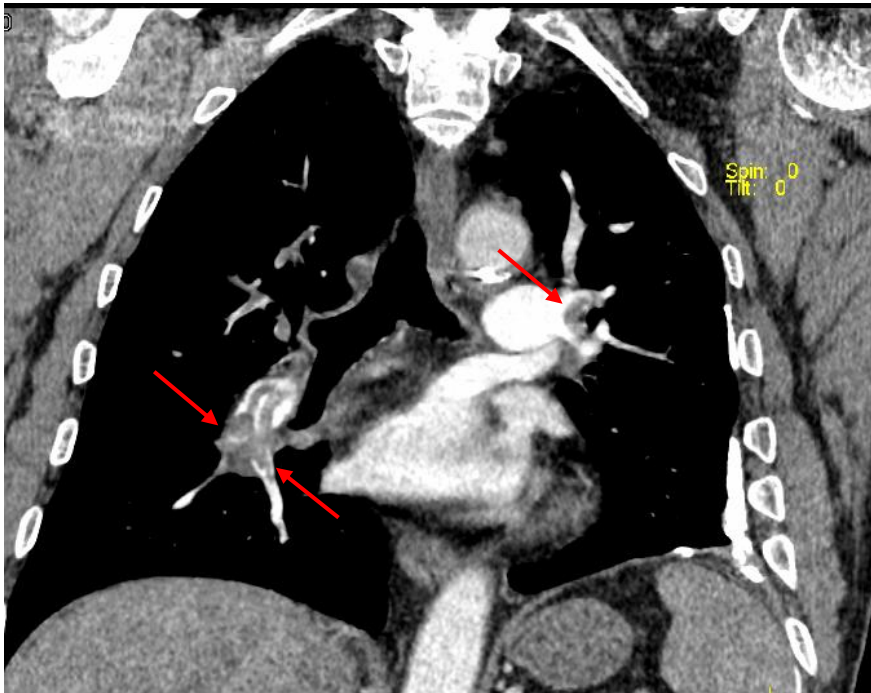
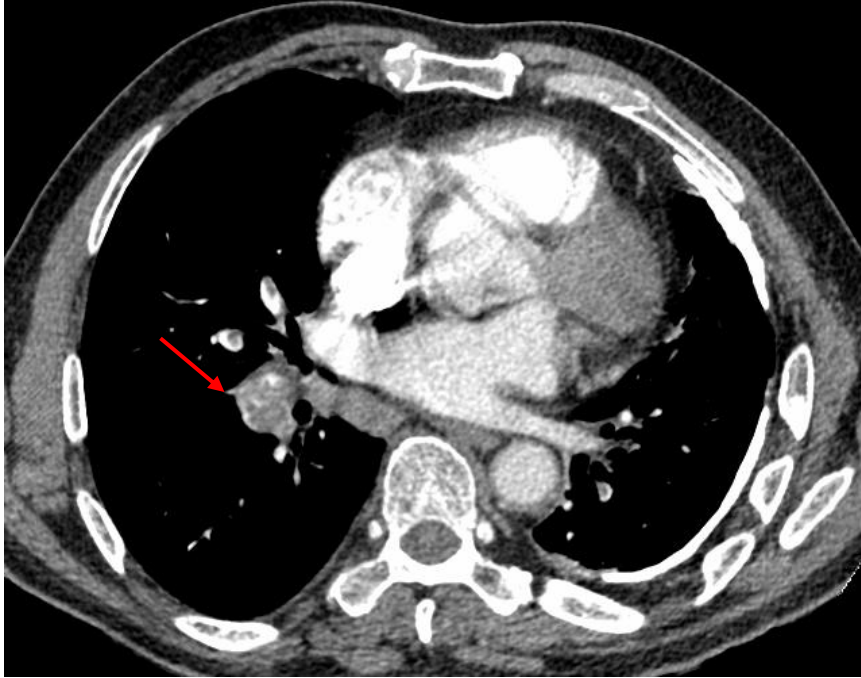
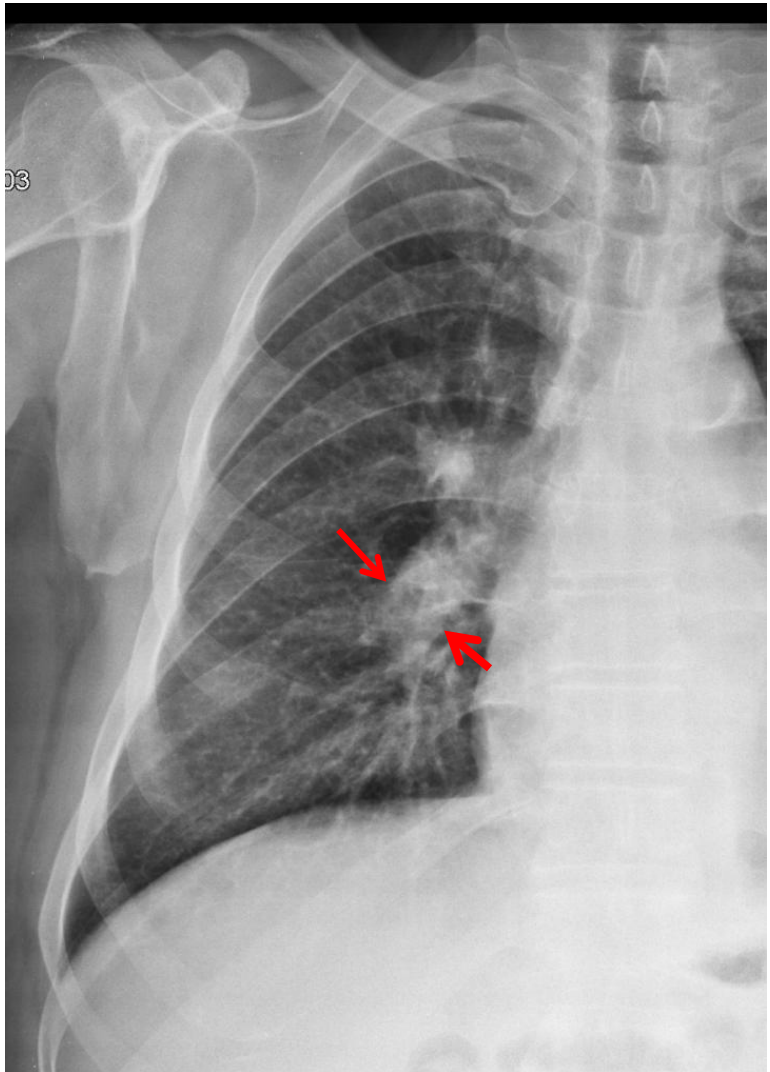
# DİREK GÖĞÜS GRAFİSİ

- Bulgular nonspesifik

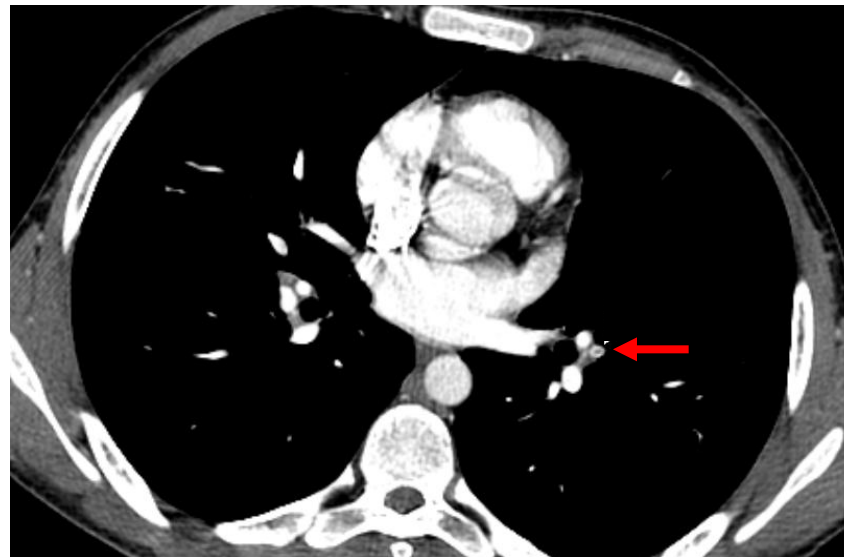
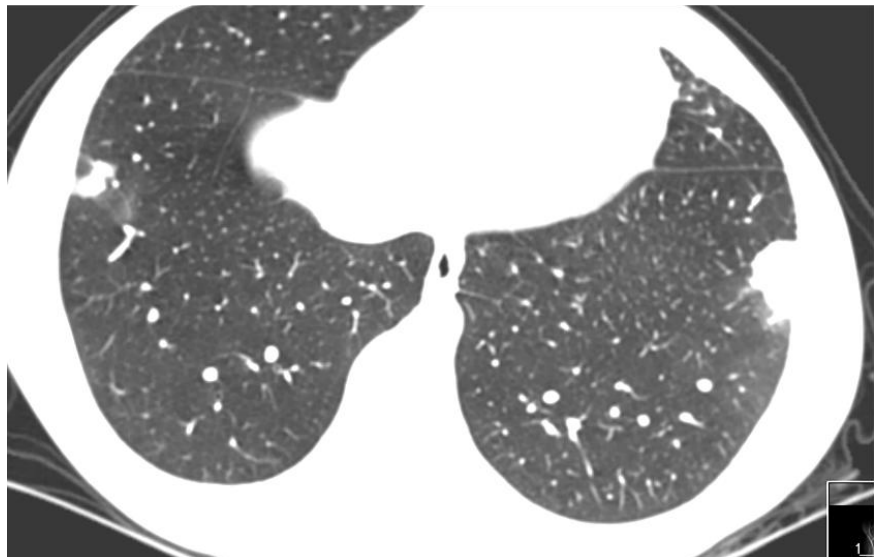
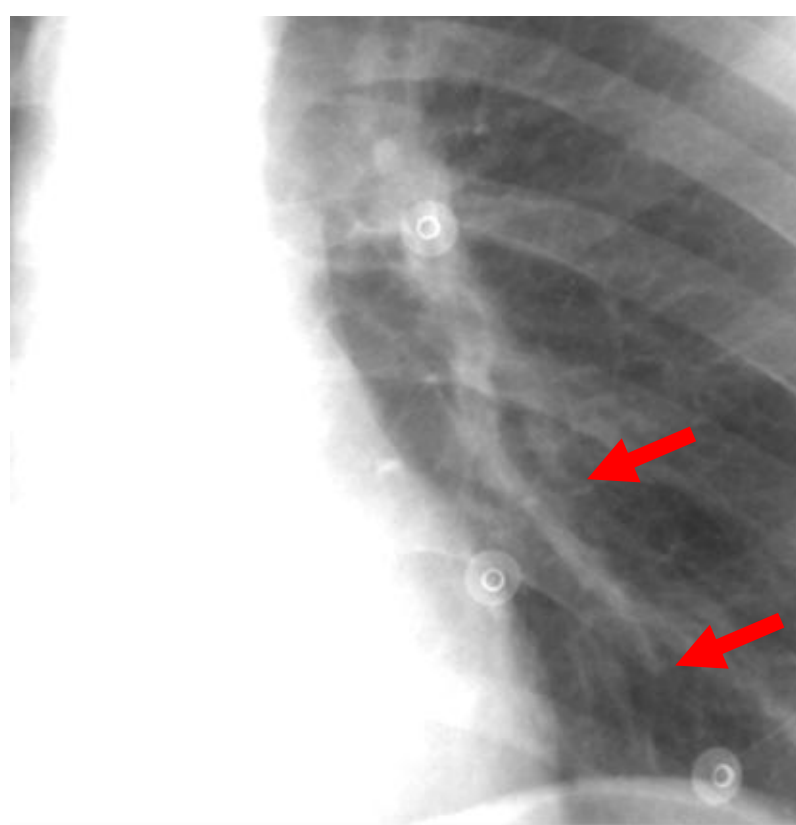
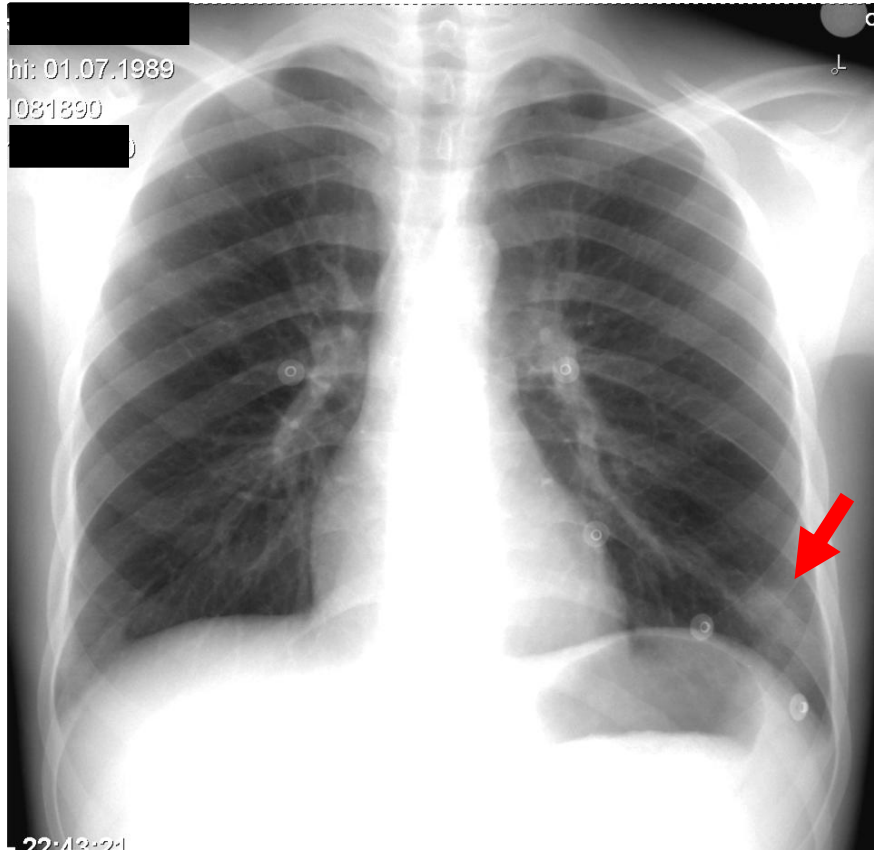
Gerçek pozitiflik → % 39

Yalancı negatiflik → % 61

- Emboliyi taklit eden durumları dışlama









# Spiral BT Anjiyografi

Kolay eriřilebilir

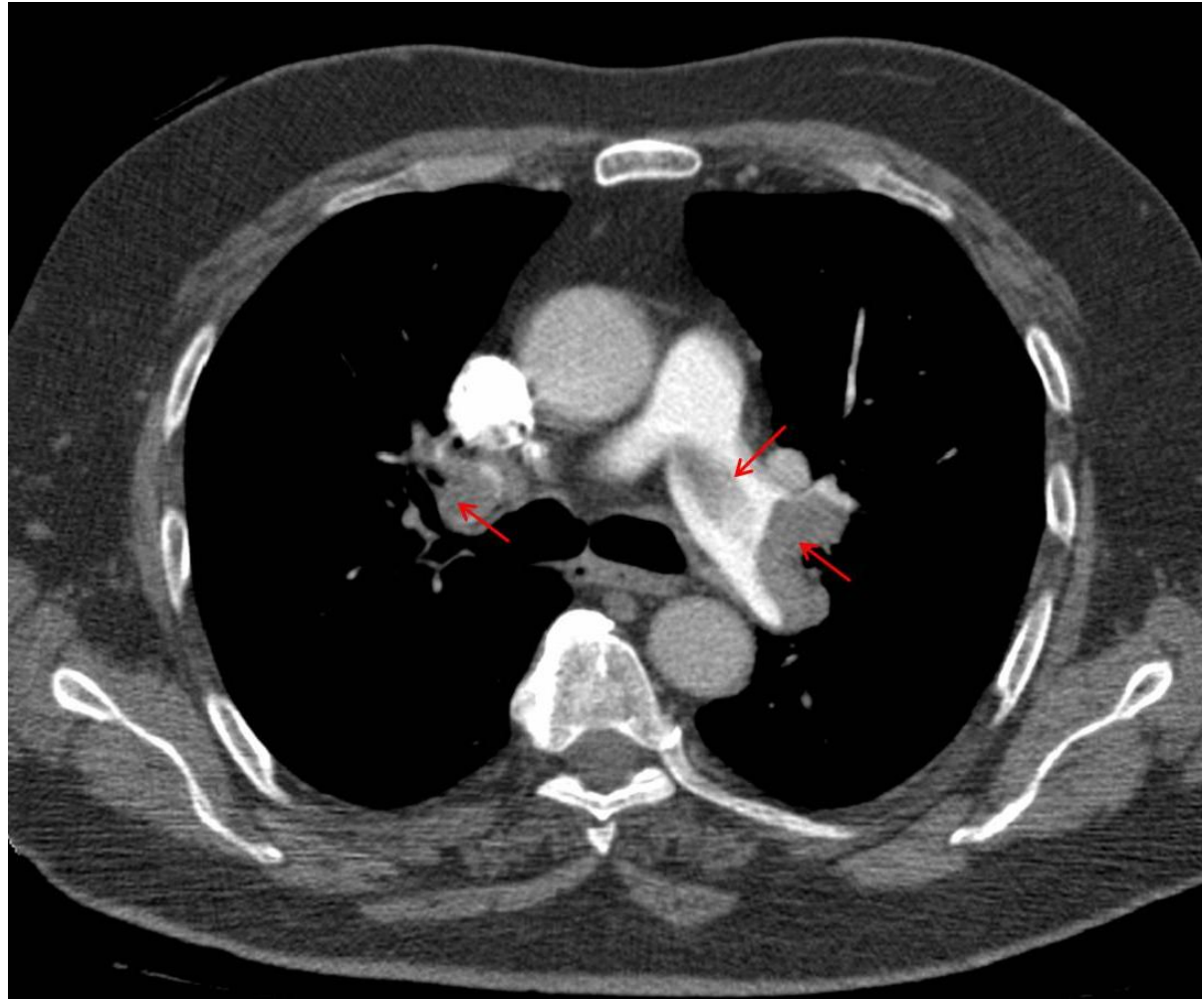
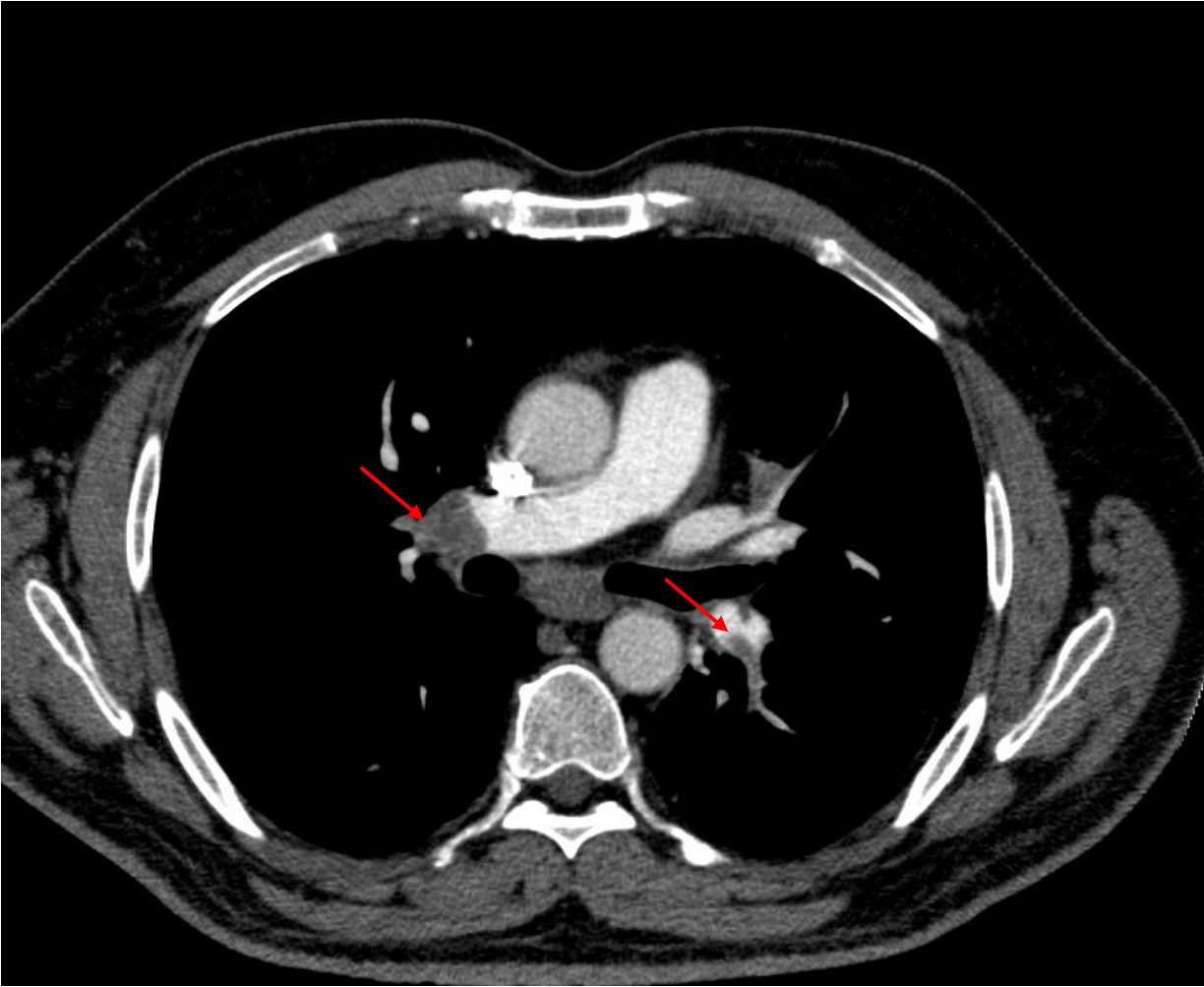
Kısa tetkik süresi

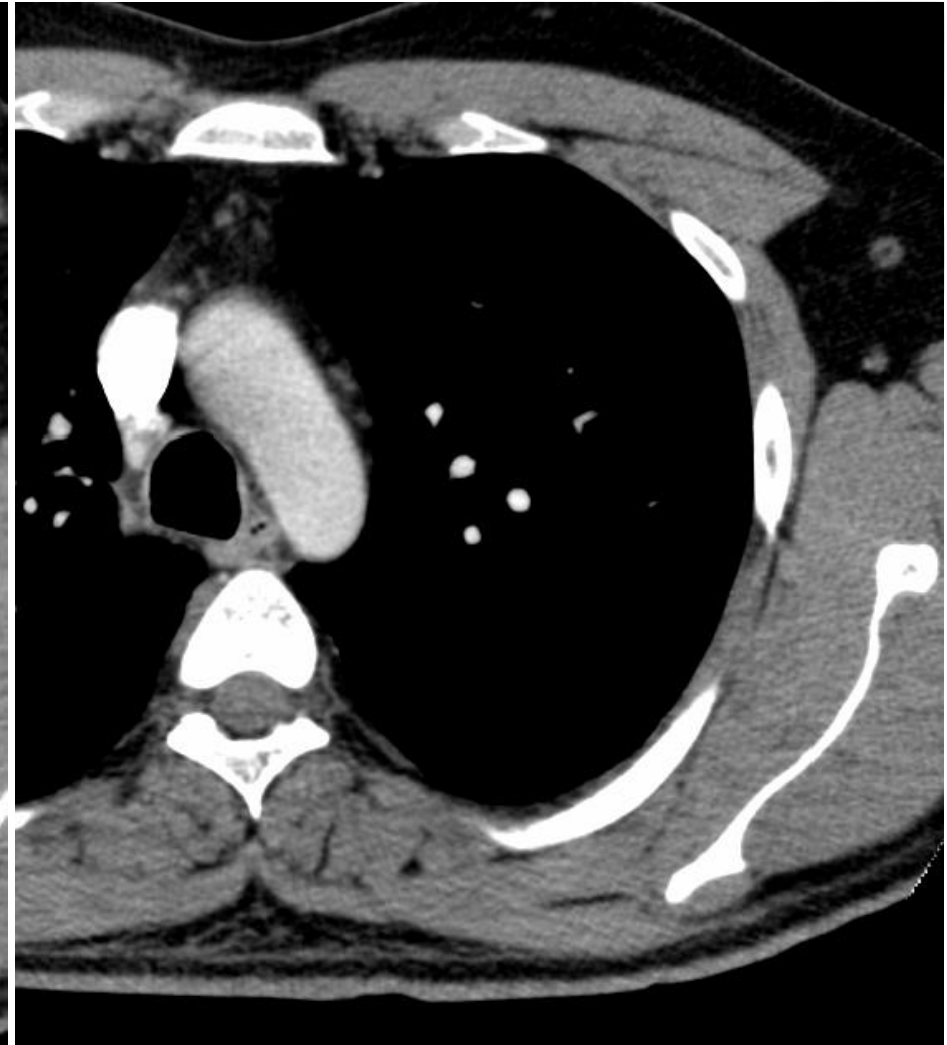
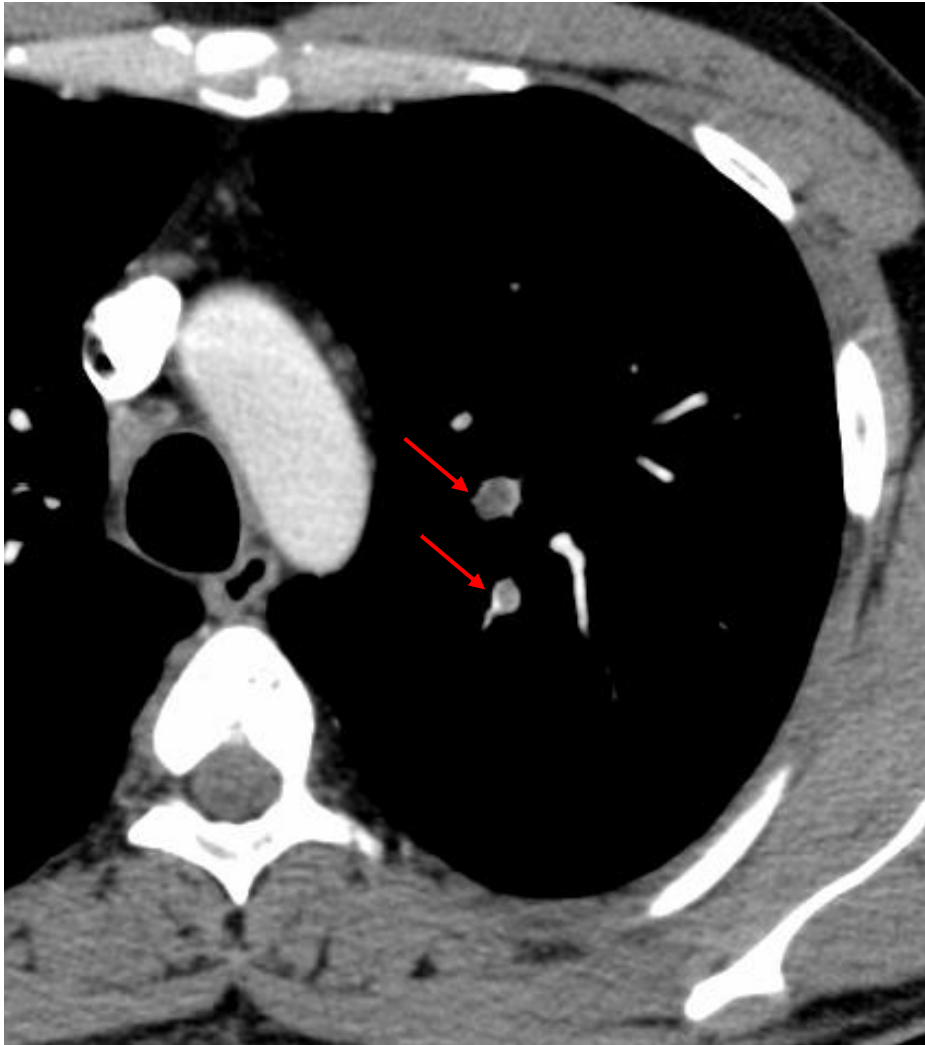Yararlılık / maliyet oranı

Takip olasılığı

# Bilgisayarlı Tomografi

- Direk pıhtıyı, pıhtı yükünü gösterebilir.
- Doğruluk değeri
  - Ana dallarda % 95'lerin üzerinde iken
  - Subsegmental dallarda % 25-52'lerde





# Pulmoner embolide BT bulguları

## Tanıyı Destekleyici Bulgular

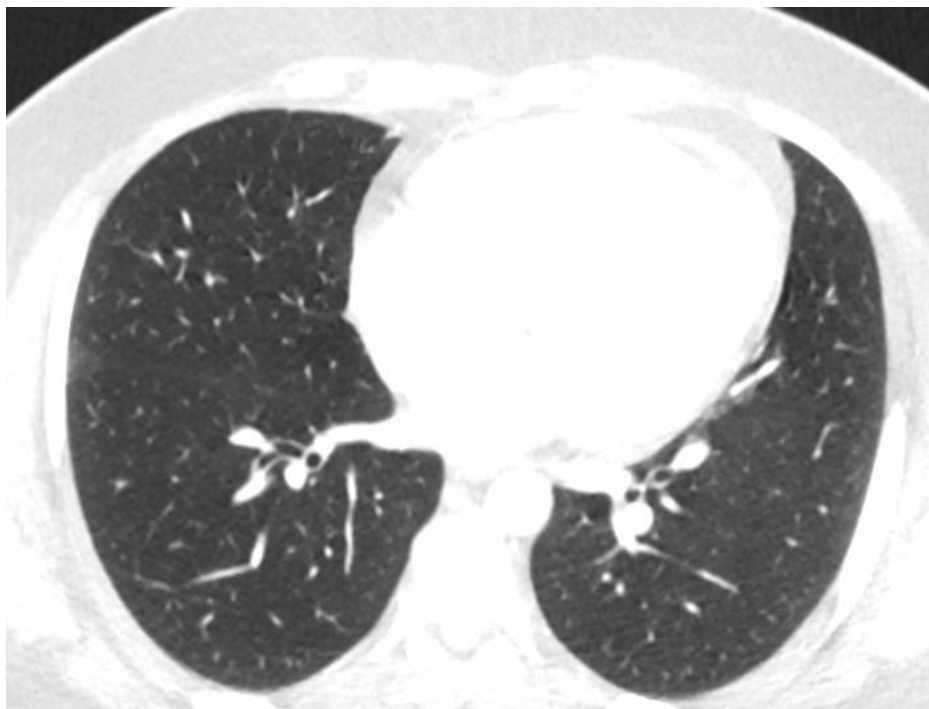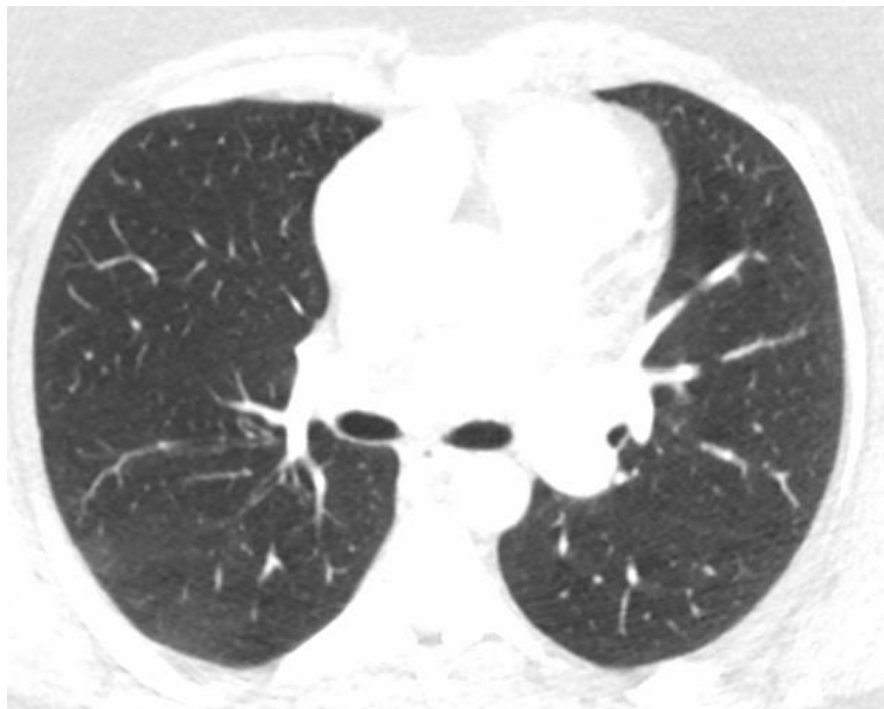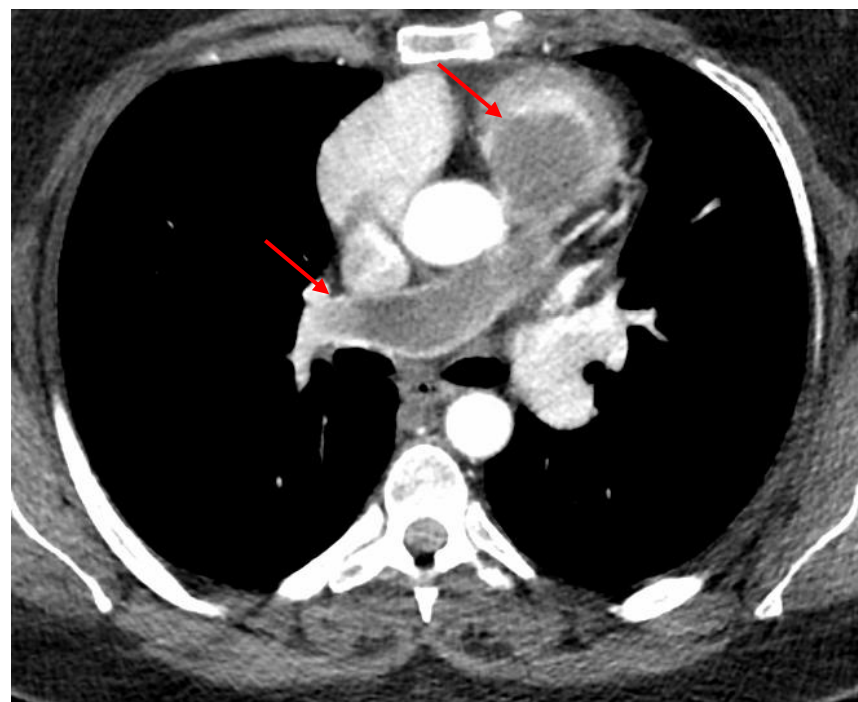
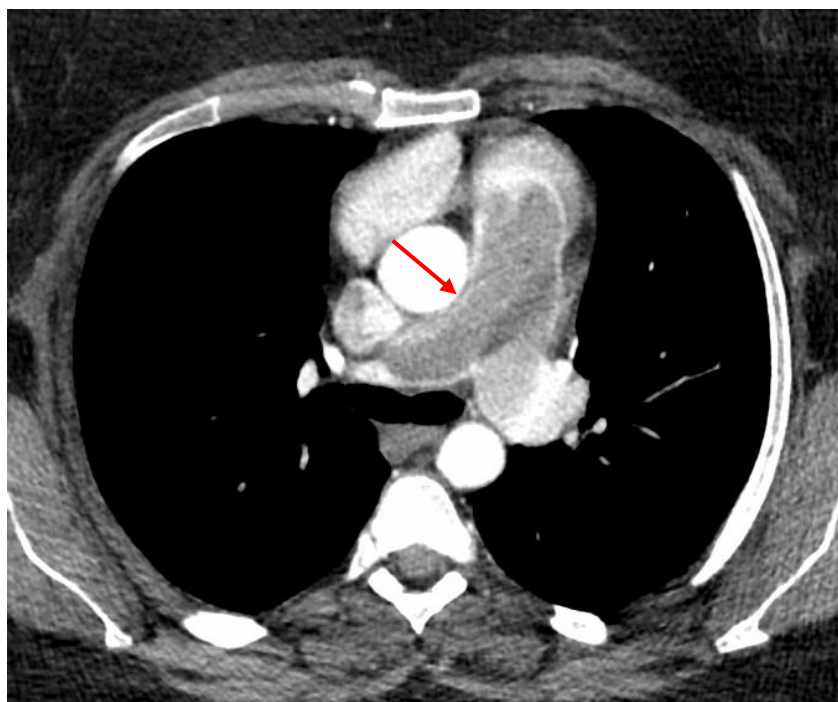
### PARANKİMAL KONSOLİDASYON

- Kama şeklinde veya ters halo işareti
- Tabanı plevraya oturan
- Sıklıkla alt loblarda
- ≈ % 25-60

# Pulmoner embolide BT bulguları

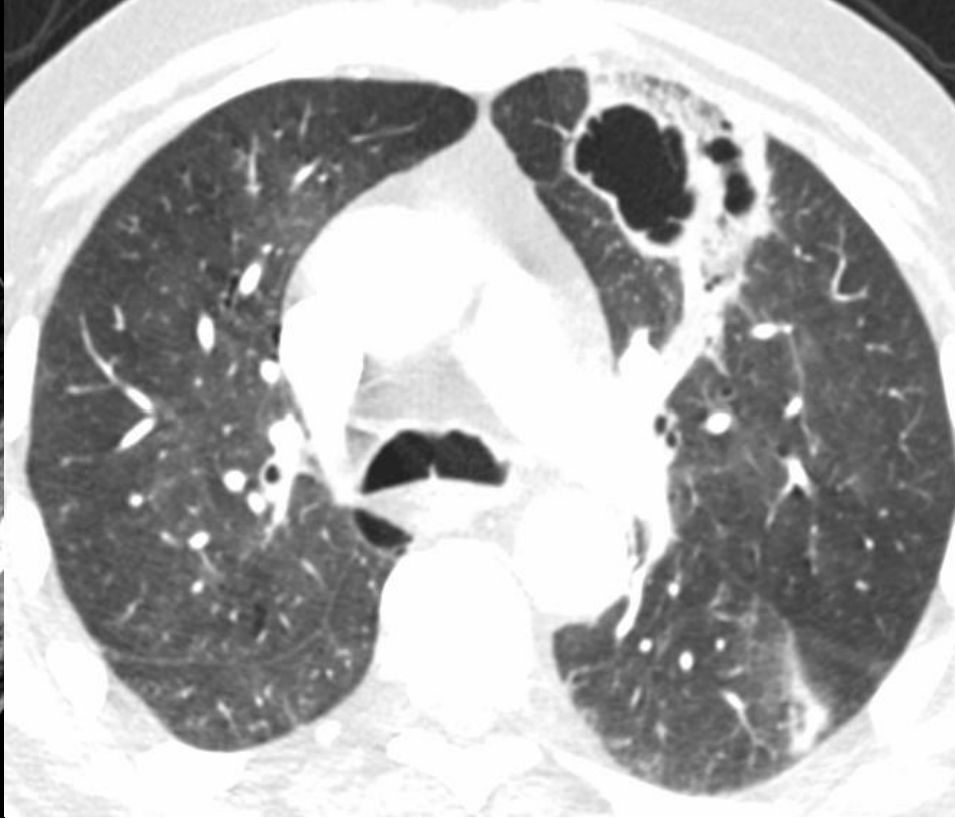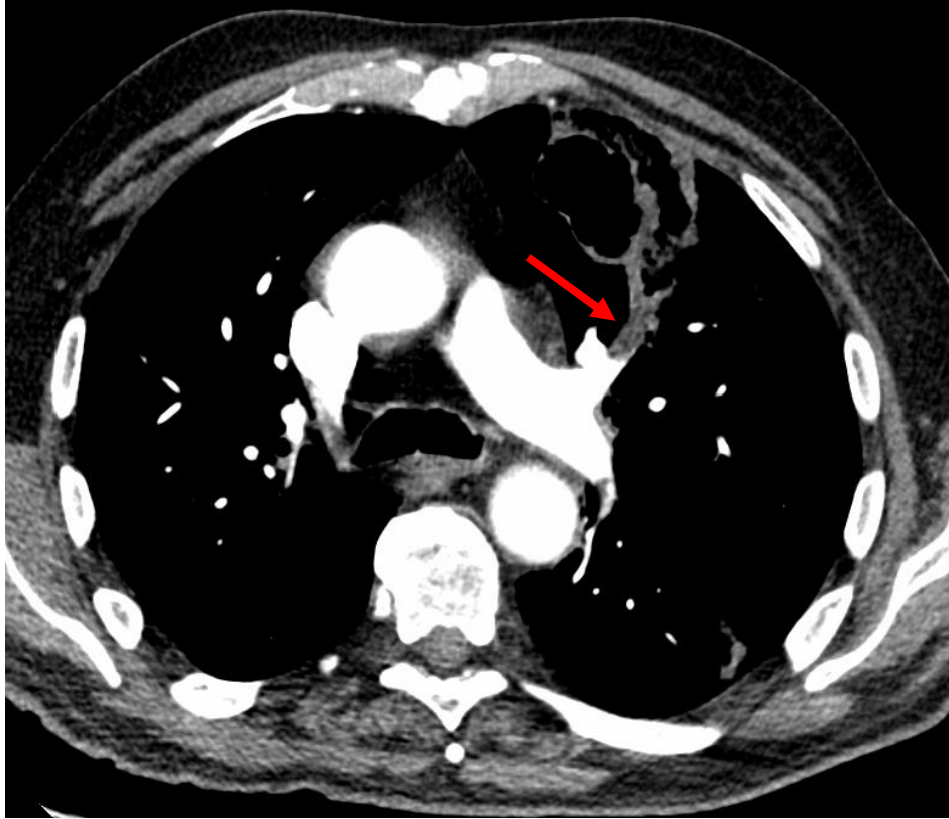
- \*Oligemik alanlar / kavitasyon
- \*Ters halo işareti- hava kabarcıkları içeren konsolidasyon
- \*Atelektazi
- \*Lineer bantlar
- \*Plevral effüzyon

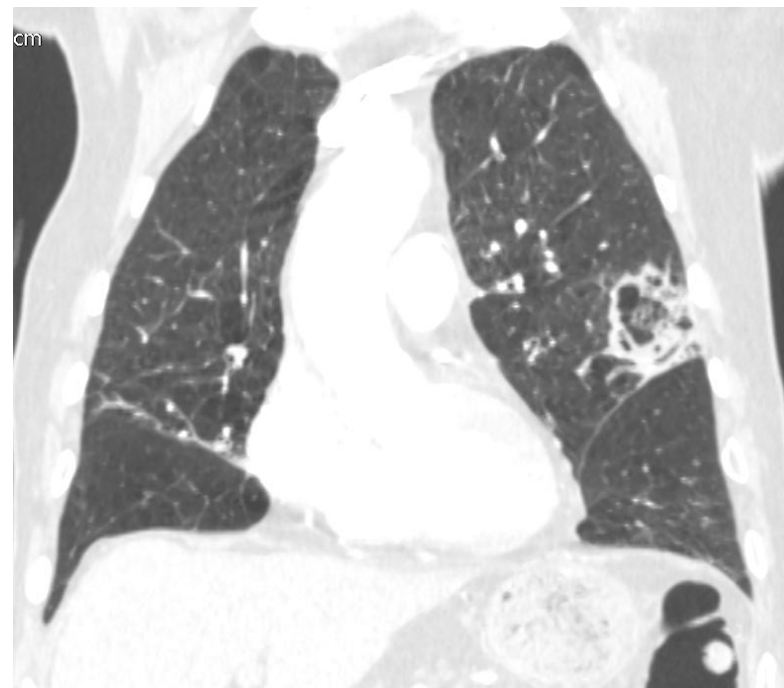
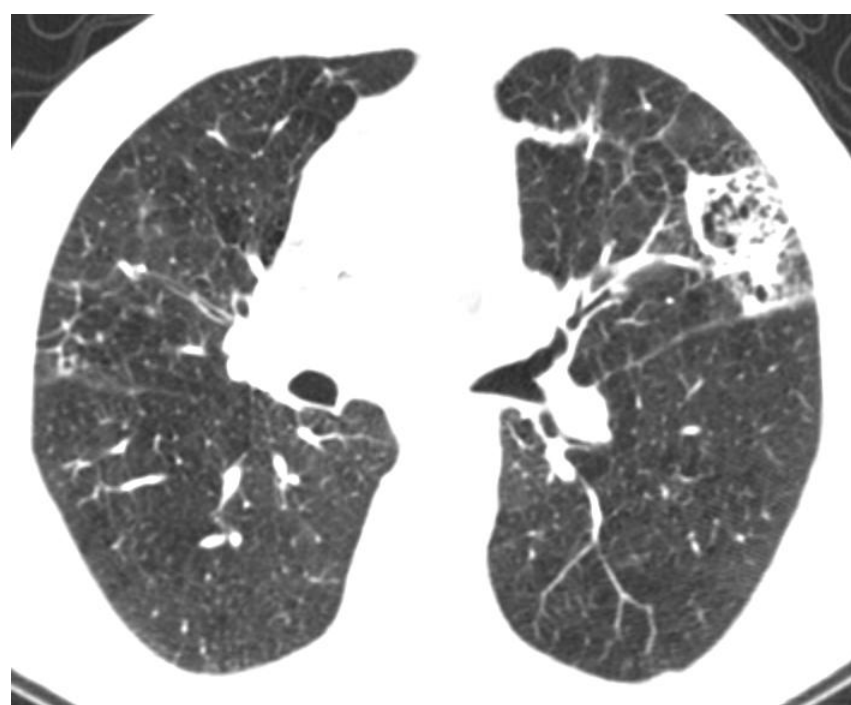
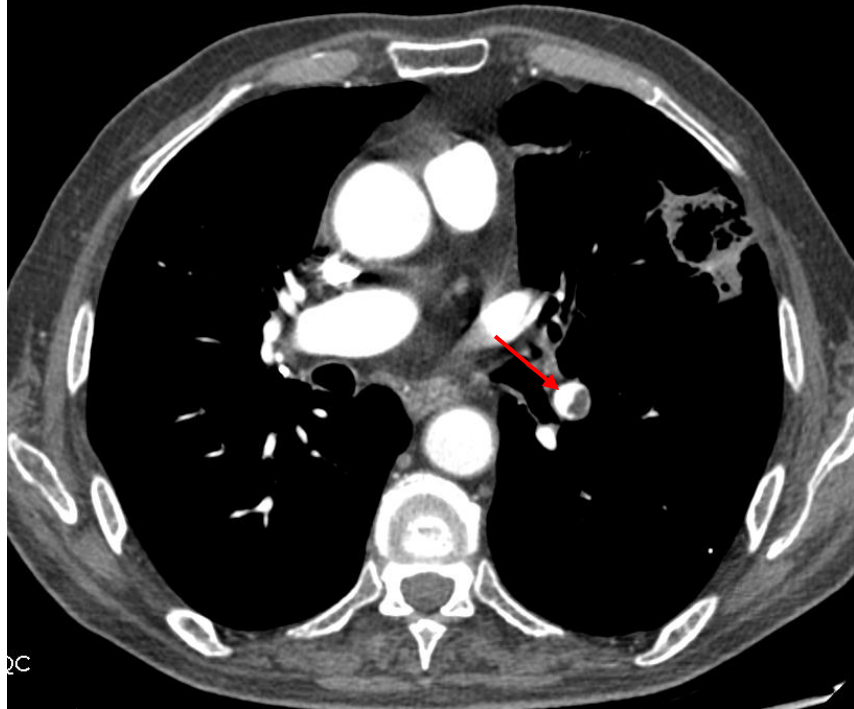
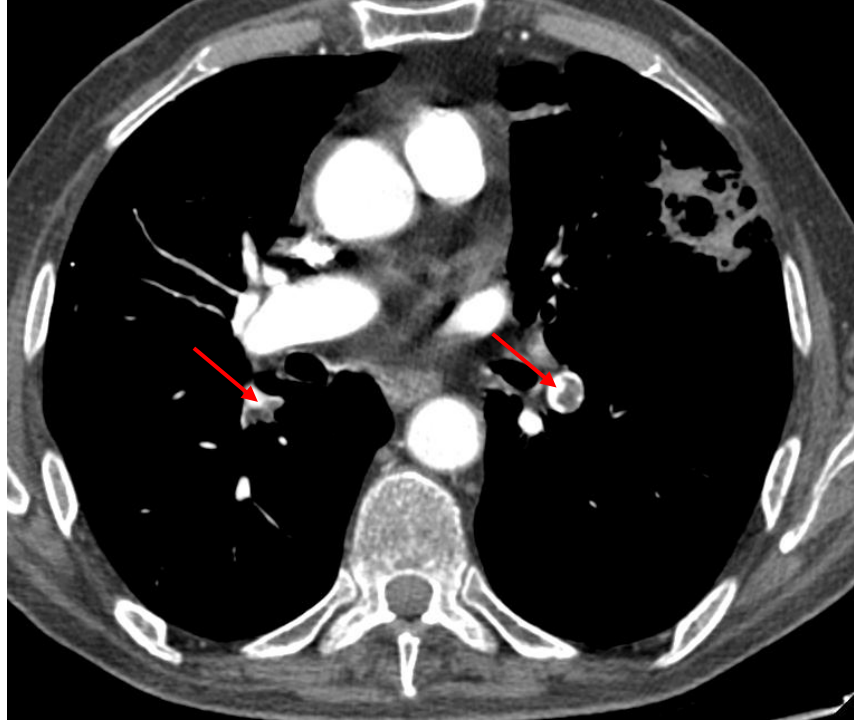




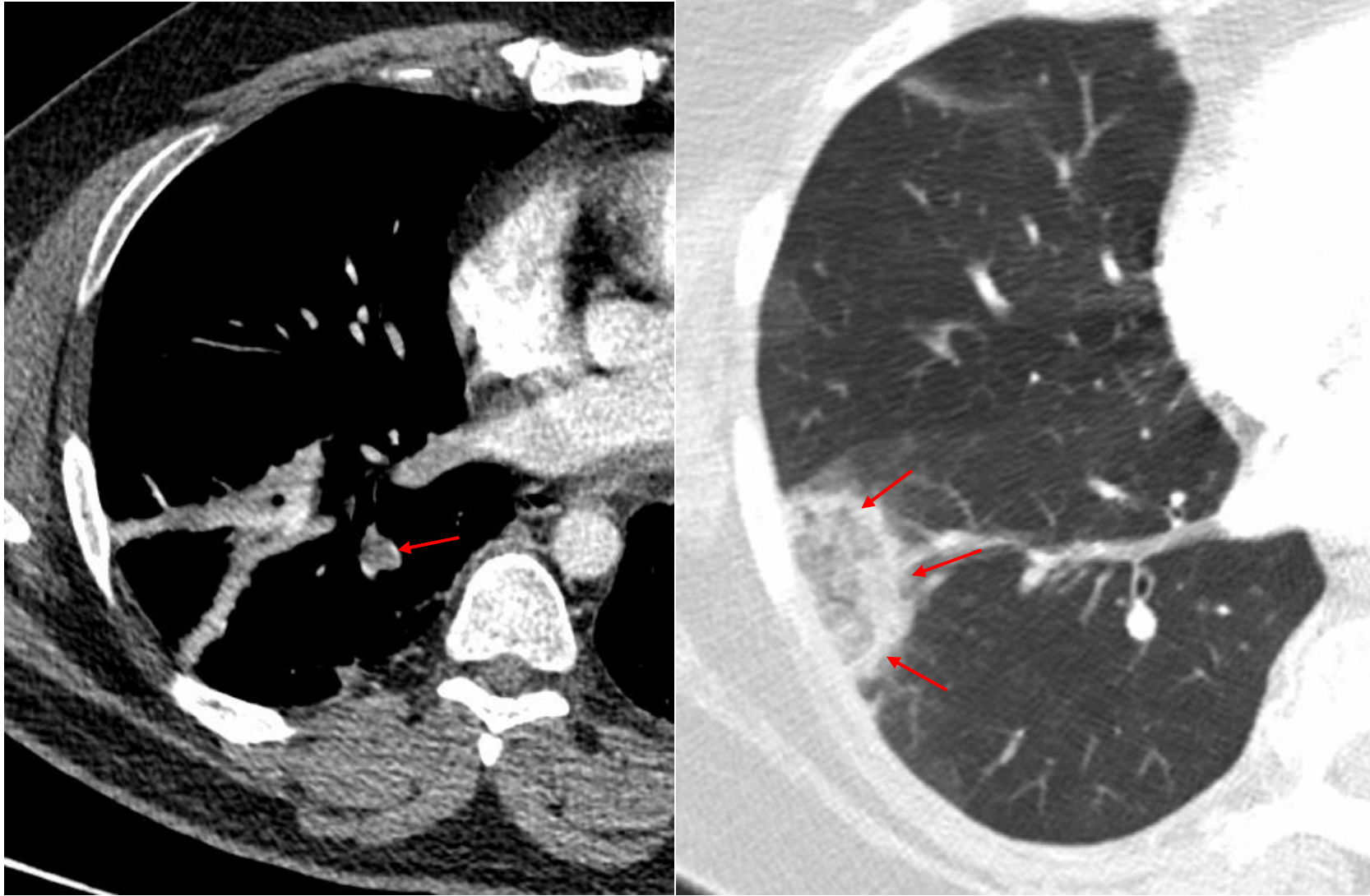
# MESAJ 1

ANA PULMONER ARTER  
DALLARINDA GENİŞ  
TROMBOEMBOLİLERE RAĞMEN  
İNFARKT GELİŞMEYEBİLİR VEYA  
PARANKİMAL BULGU  
OLMAYABİLİR







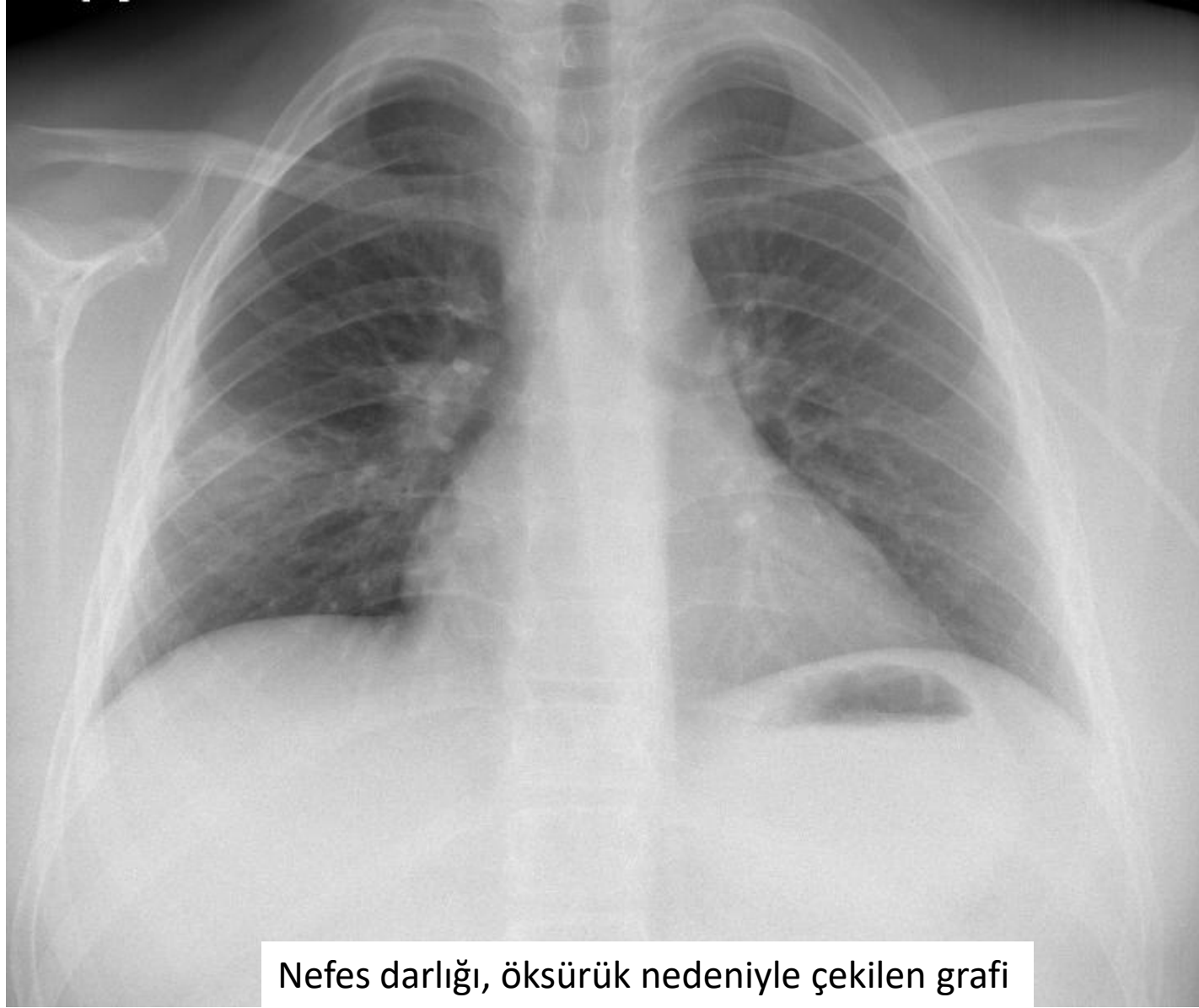

Ters halo işareti

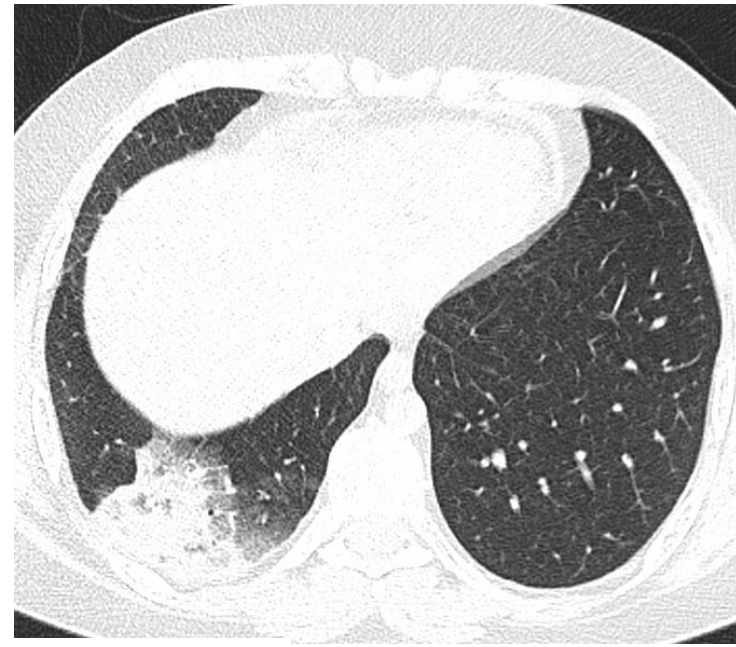
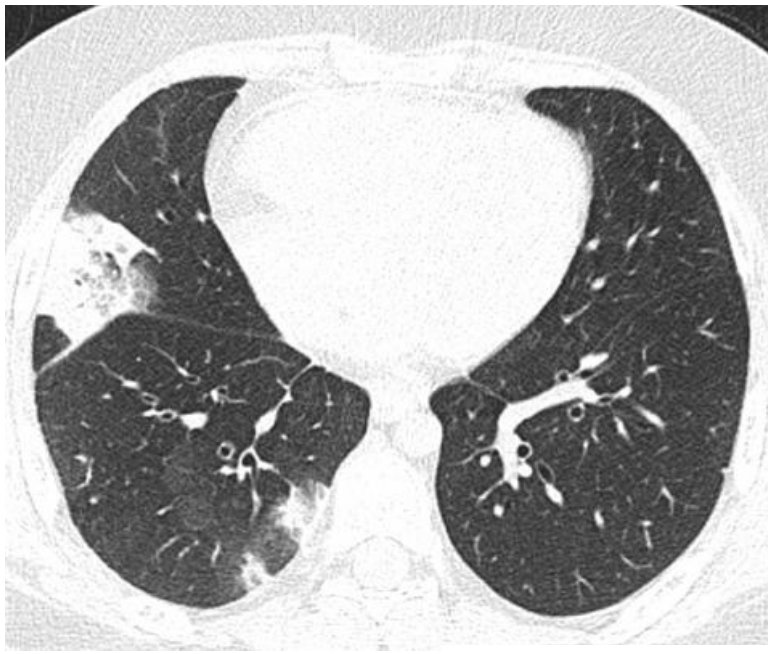
## MESAJ 2

PARANKİMDE PERİFERİK  
KONSOLIDASYON İÇİNDE  
KÜÇÜK HAVA TANECİKLERİ  
GÖRÜLÜYOR VEYA TERS HALO  
BULGUSU VARSA  
EMBOLİ DÜŞÜNMEİ

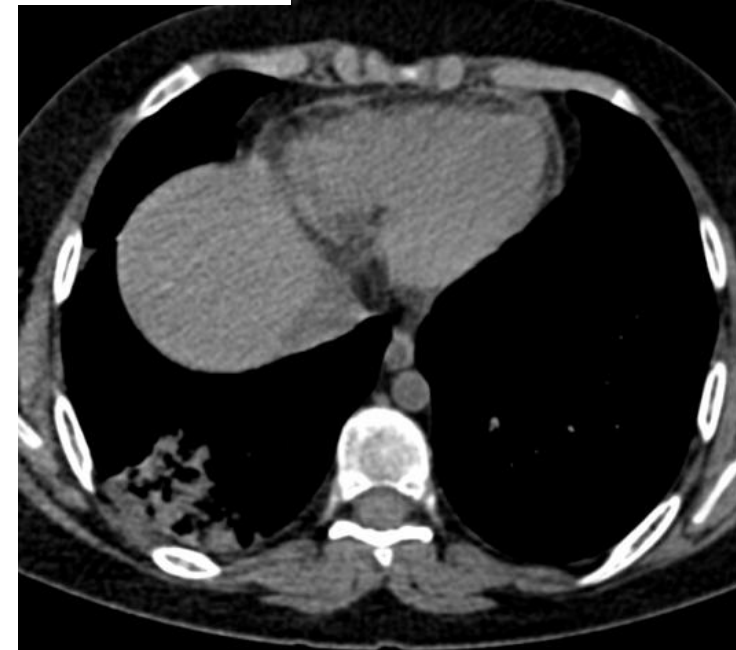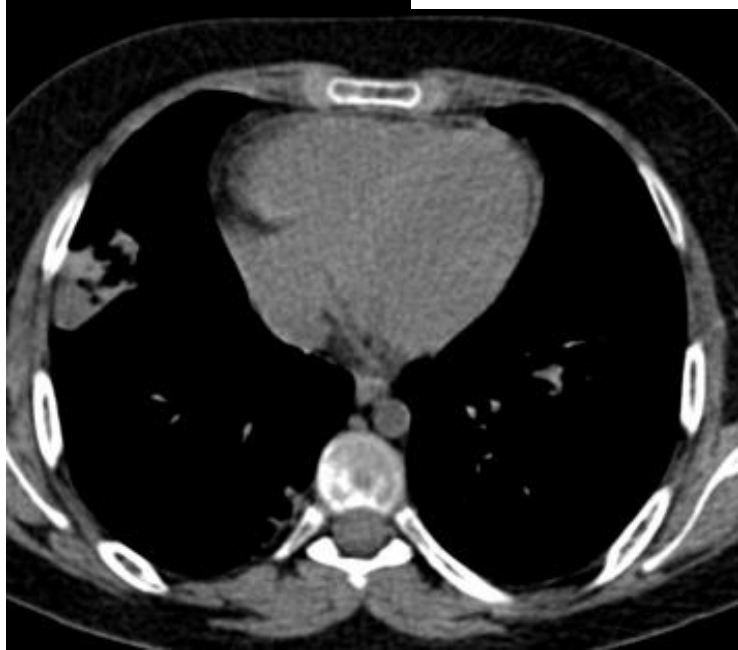



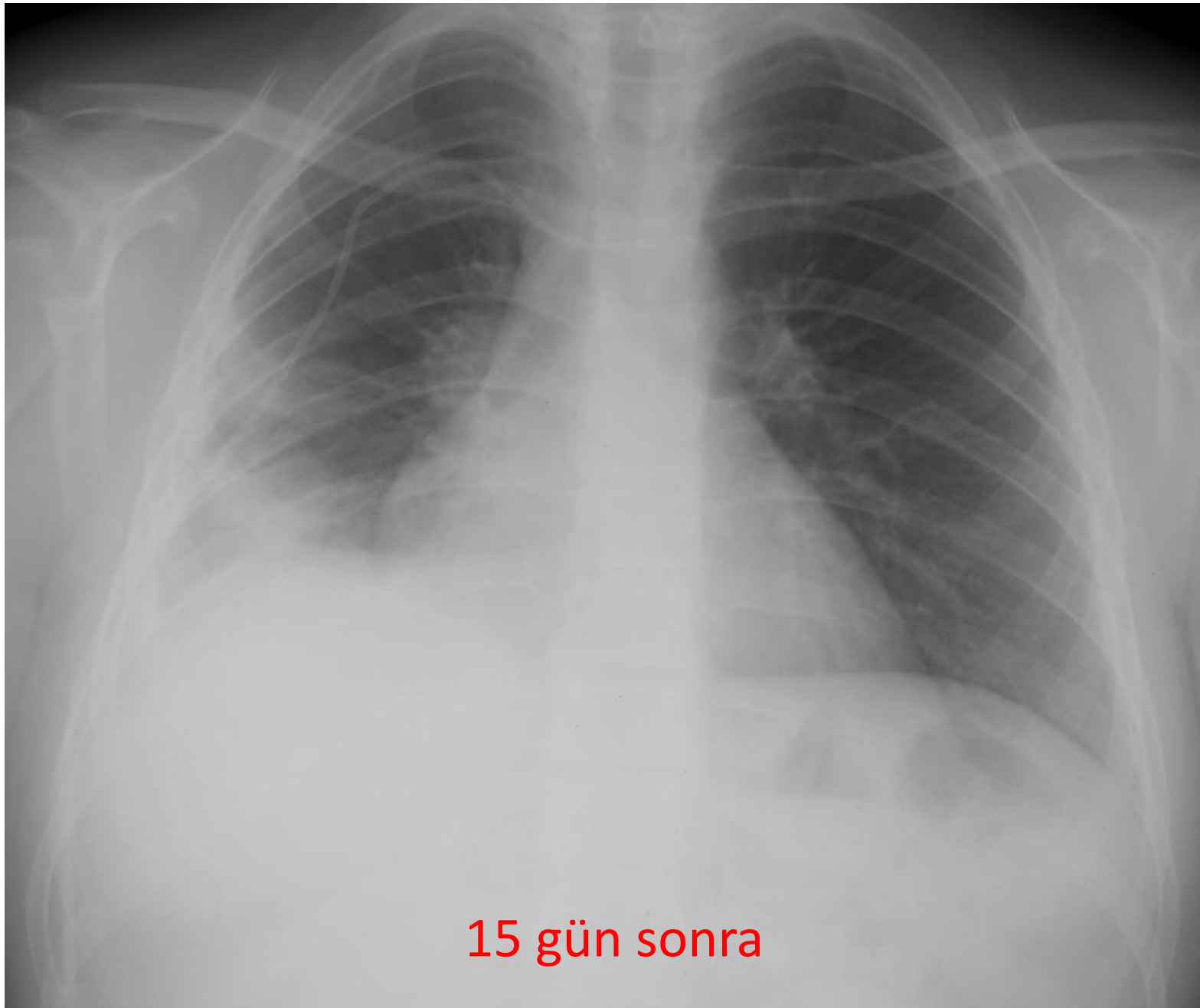
Nefes darlığı, öksürük nedeniyle çekilen grafi

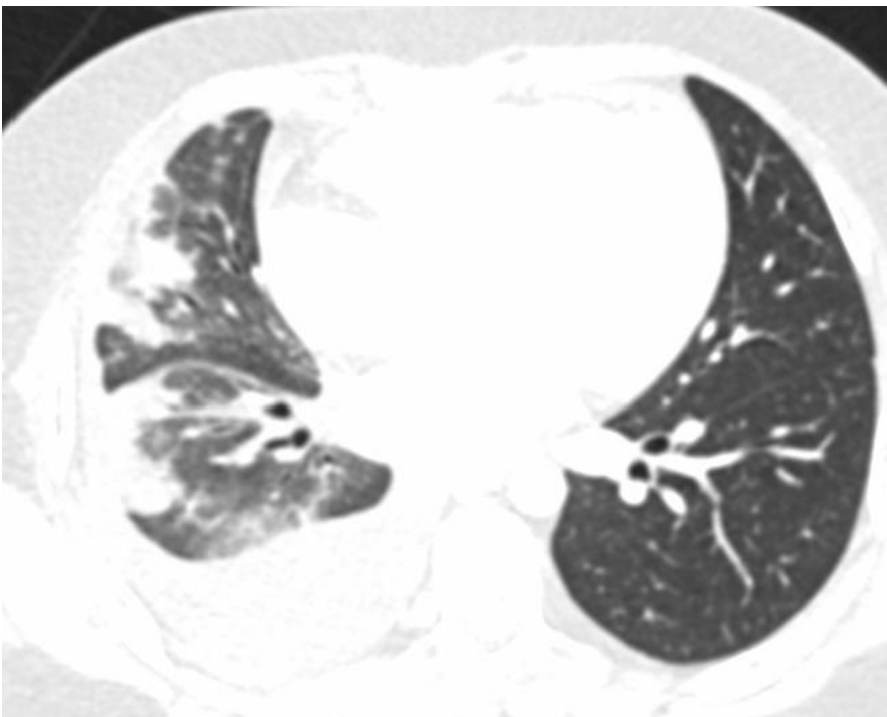
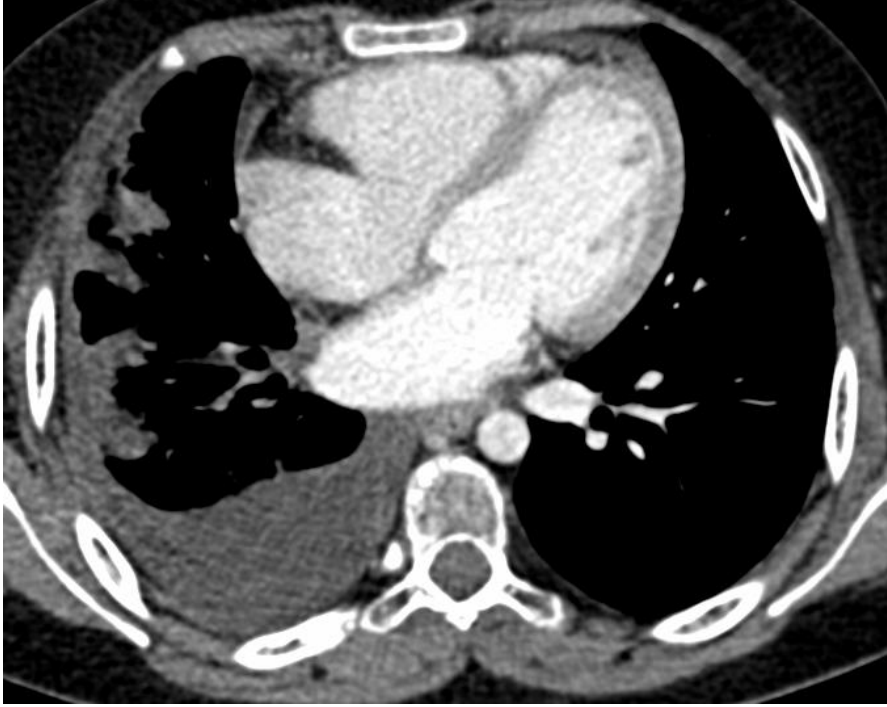


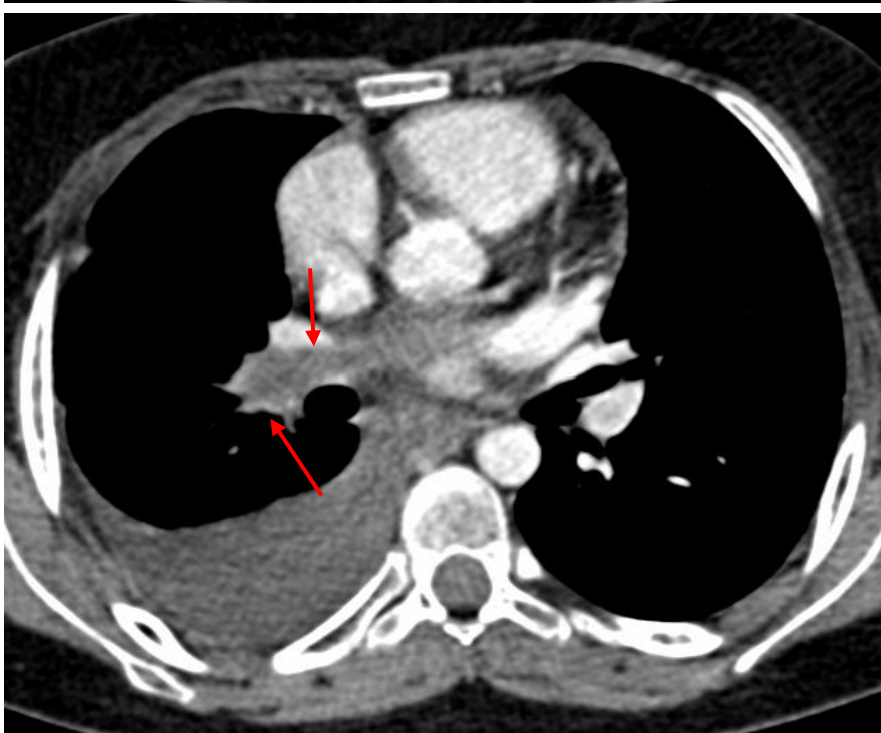
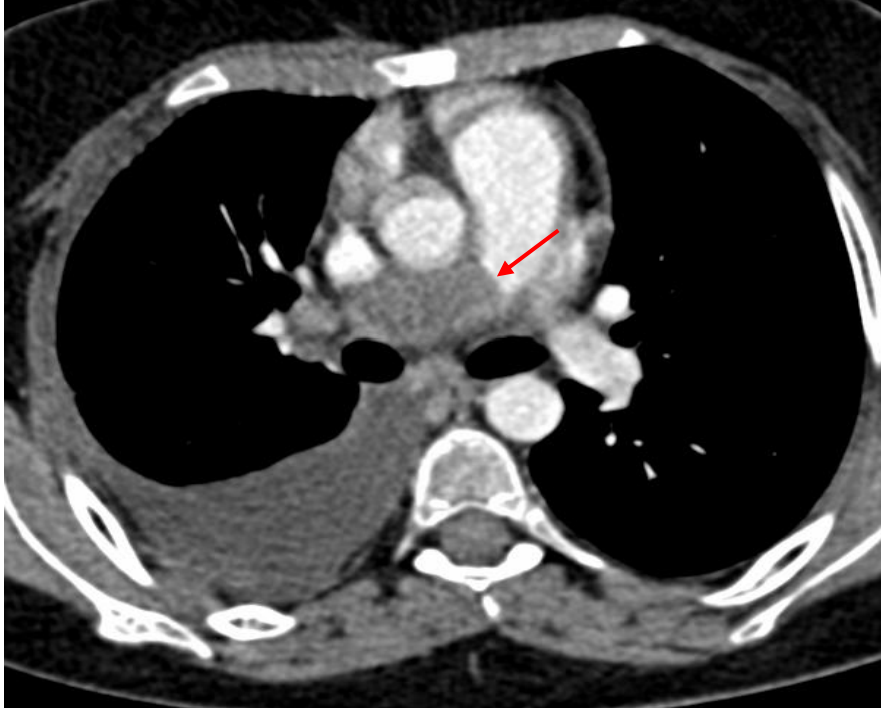
Kontrastsız BT: Pnömoni düşünülmüş





15 gün sonra





# MESAJ 3

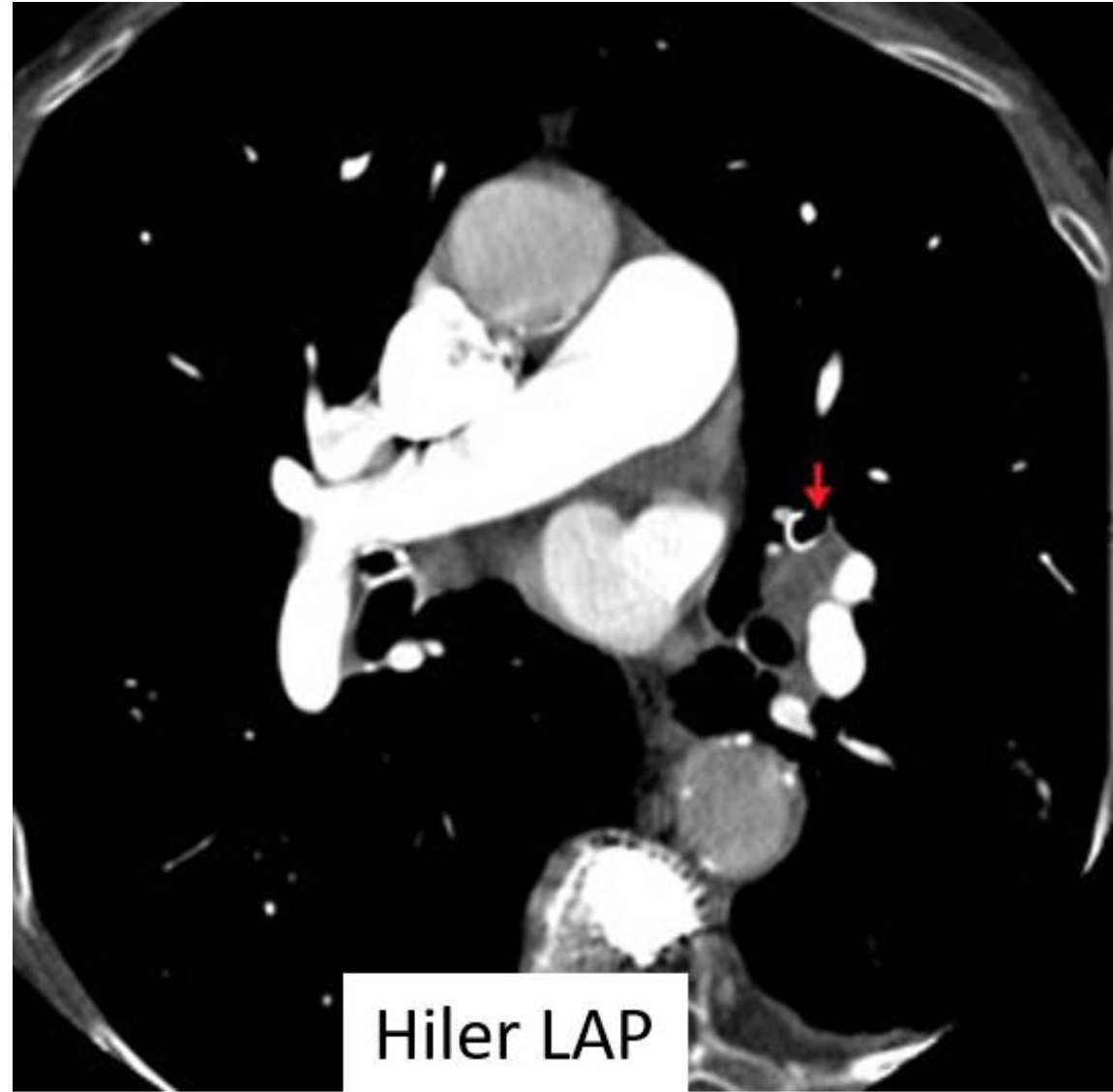
İYİLEŞMEYEN PARANKİMAL  
KONSOLİDASYONLAR  
PROGRESE OLUYORSA  
EMBOLİ AYIRICI TANIDA  
DÜŞÜNÜLMELİDİR



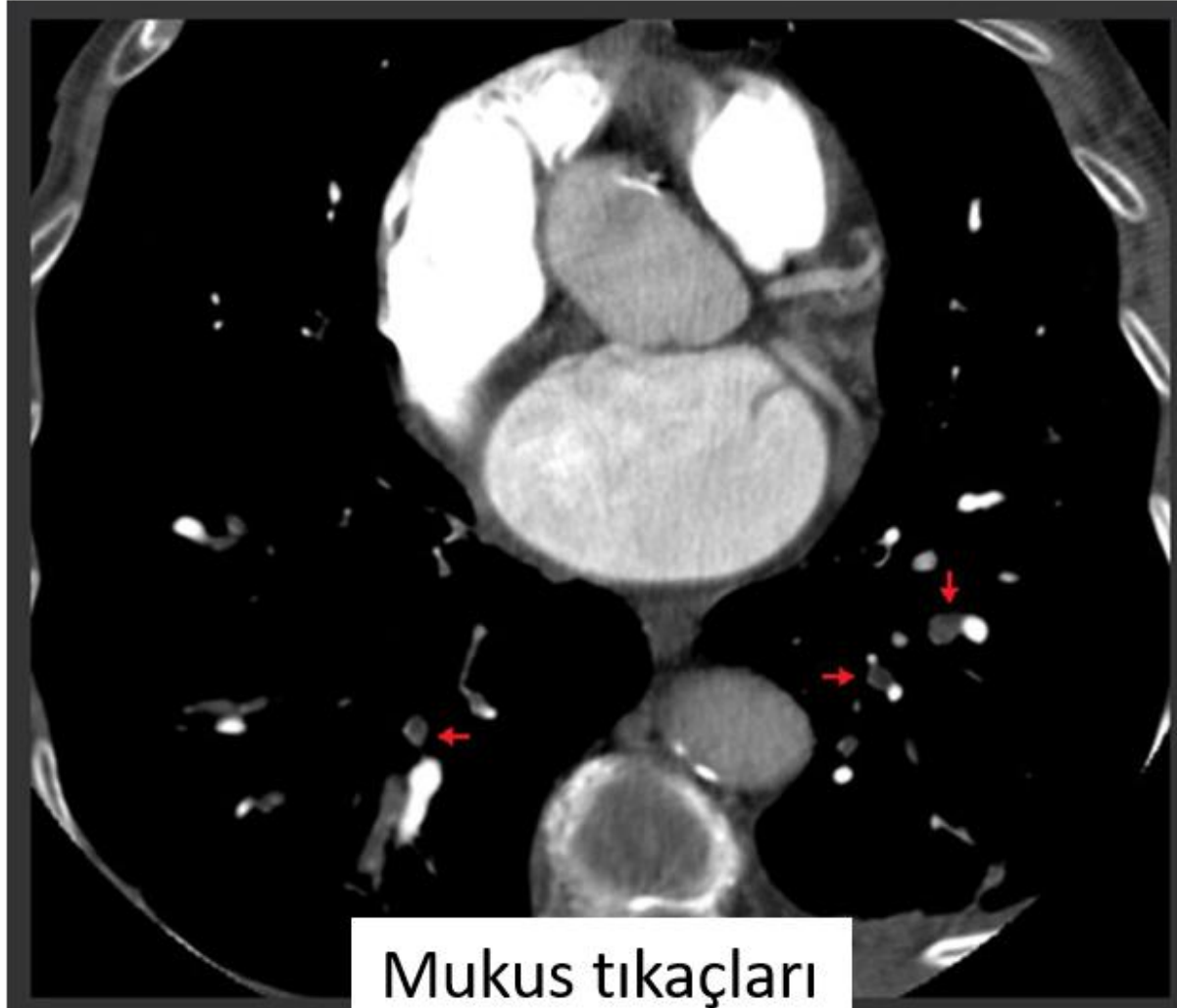
# BT ile embolide tanısal güçlükler

- Radyasyon (gebeler başta)
- Kontrast madde verilmesi (böbrek yetmezliği, alerji vb)
- Uygun kontrastlanma sağlanamaması
- Kötü görüntüler /nefes tutamama
- İnce kesit kullanılmaması (1 mm ve daha ince kesit alınmalı)
- Emboliyi taklit eden durumlar (lenf bezi, mukus tıkaçı vb)
- Akut/kronik ayırım yapamama
- Obez hastalarda çekim zorluğu

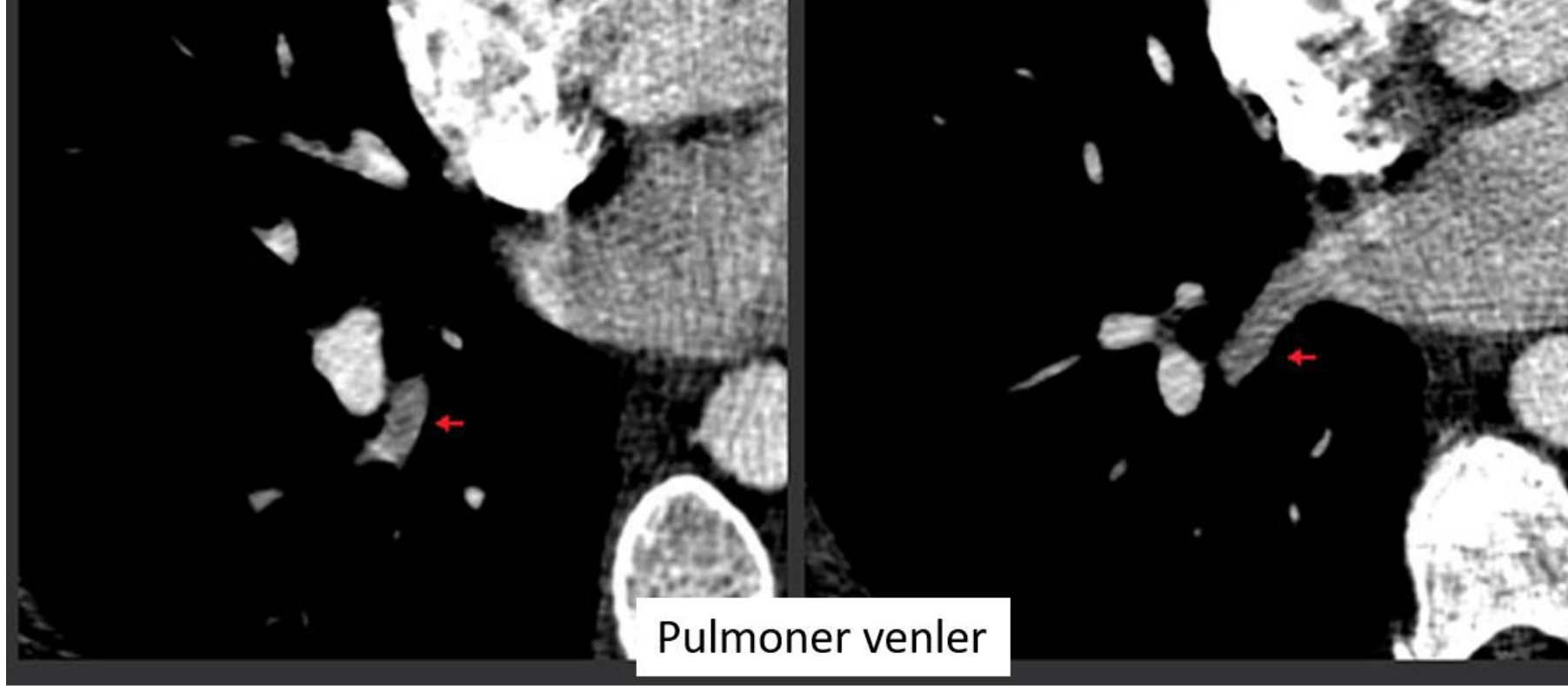
Tanıyamama veya yanlış emboli tanısı sebebi



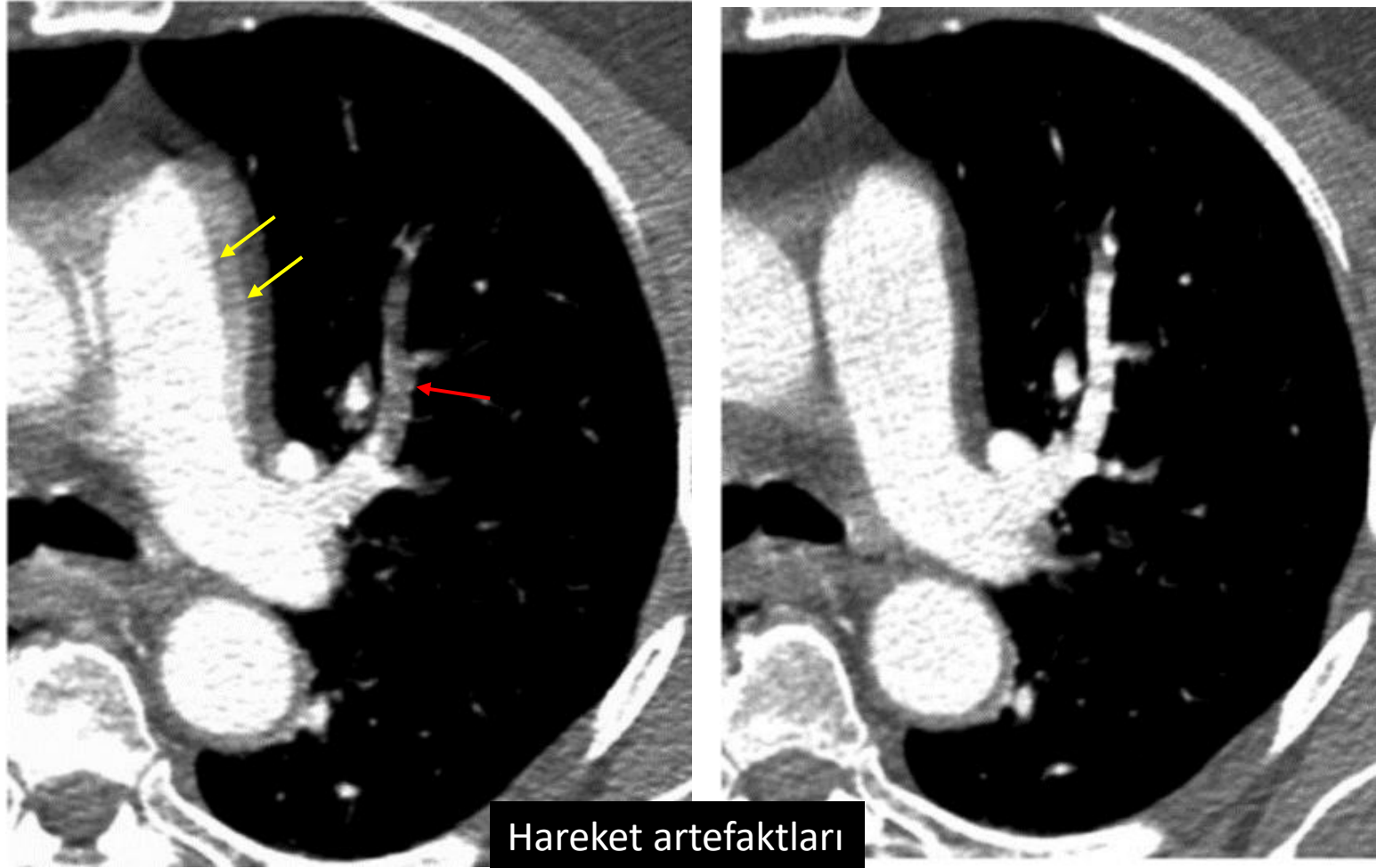
PULMONER TROMBOEMBOLİ OLARAK YORUMLANABİLİR



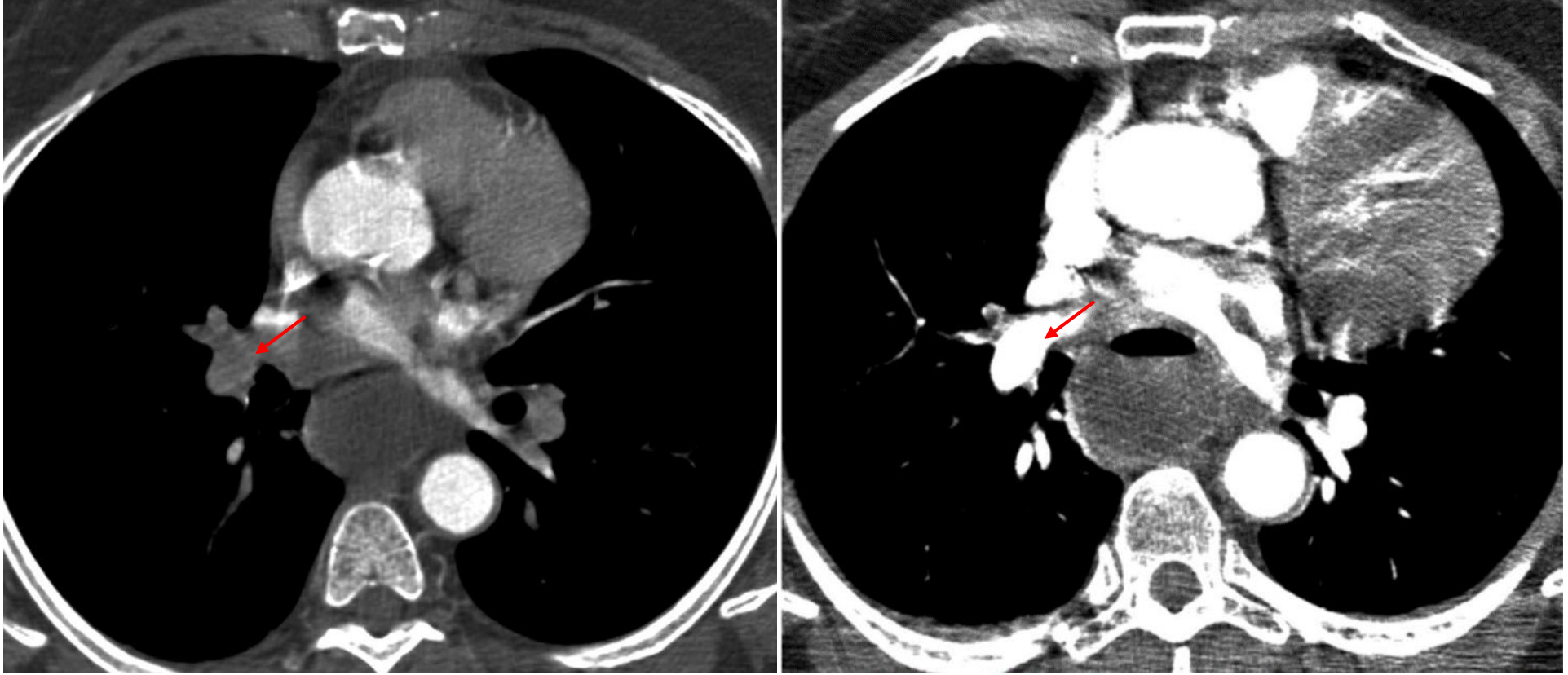
**PULMONER TROMBOEMBOLİ OLARAK YORUMLANABİLİR**



**PULMONER TROMBOEMBOLİ OLARAK YORUMLANABİLİR**

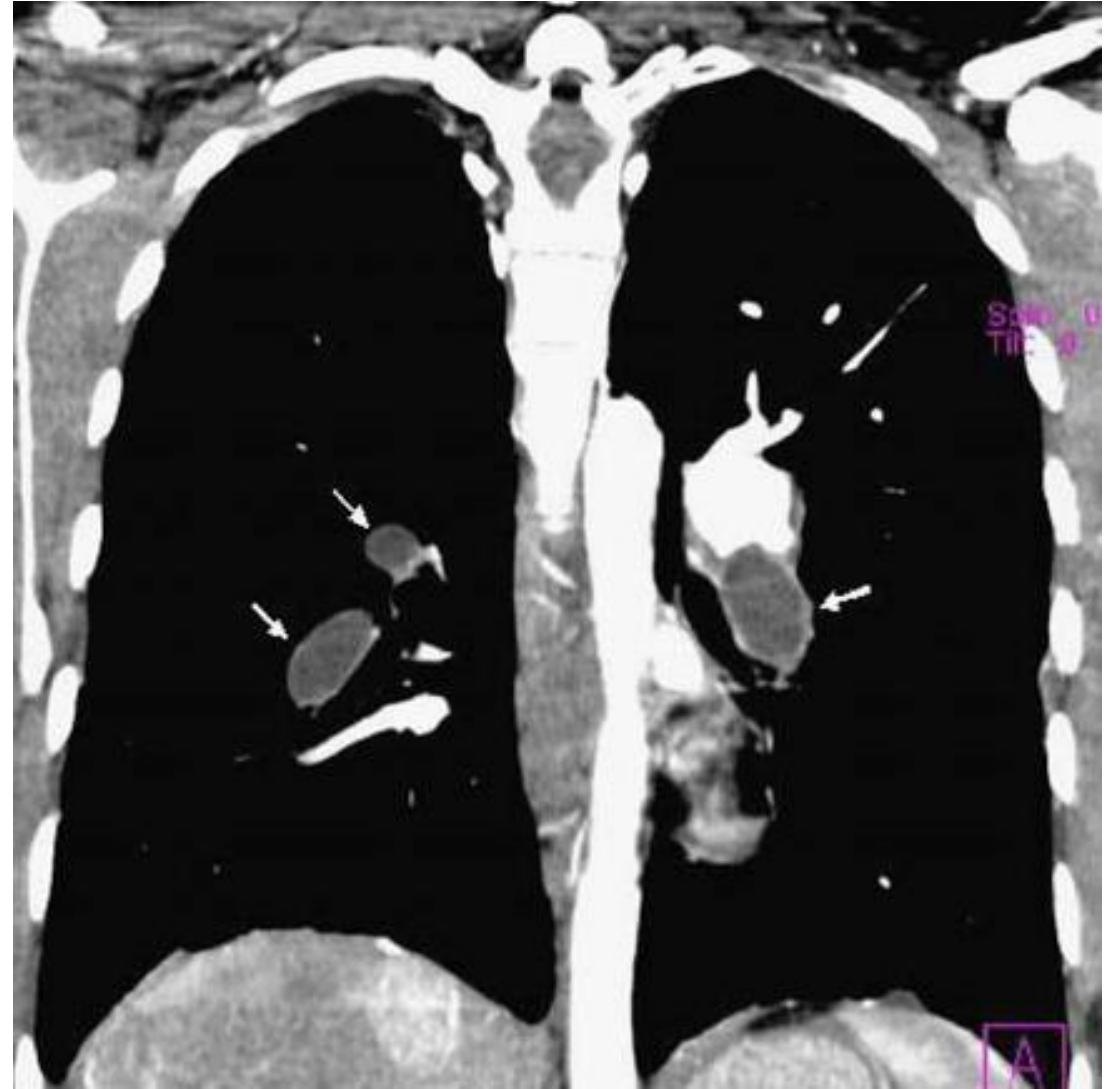
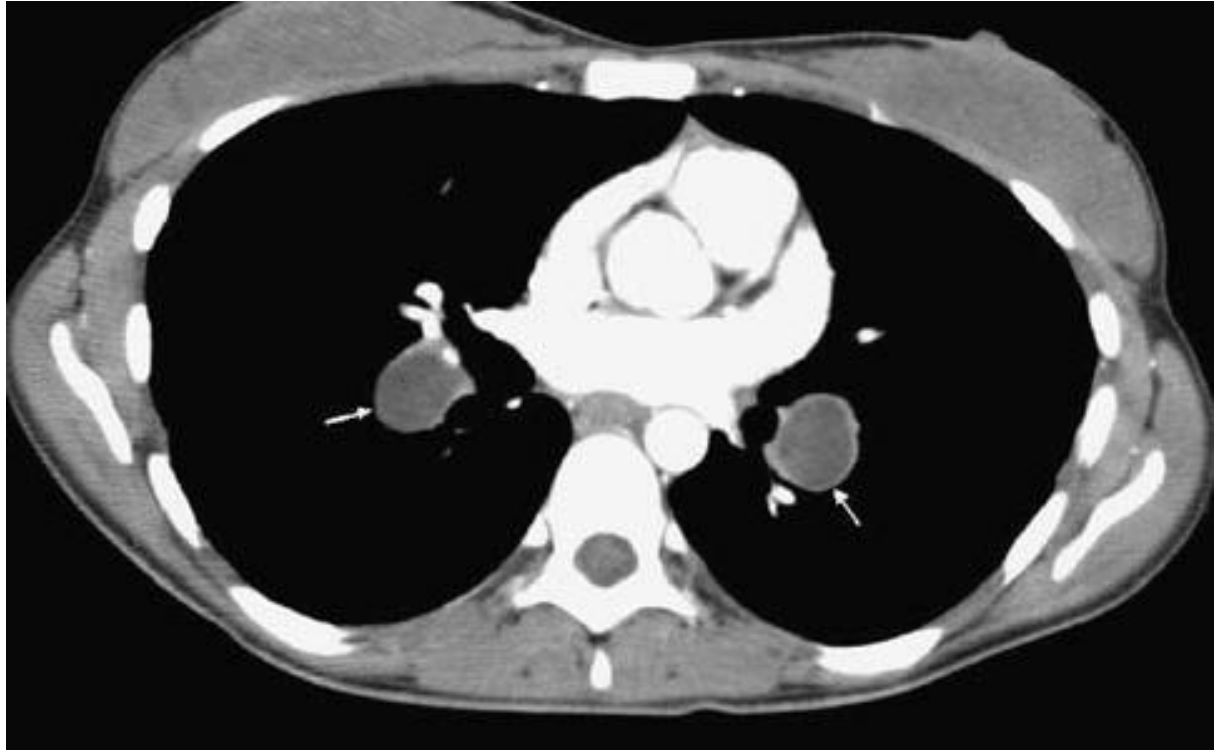
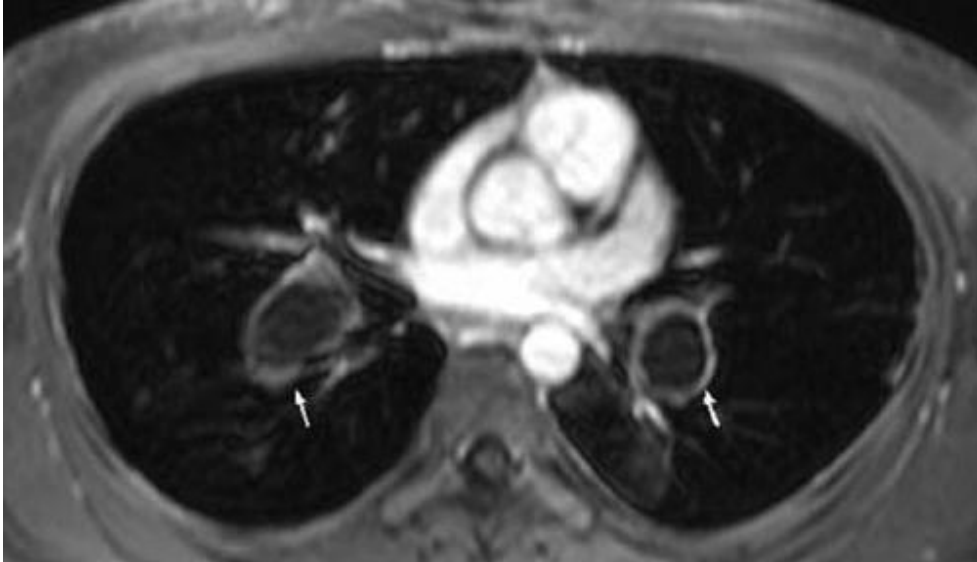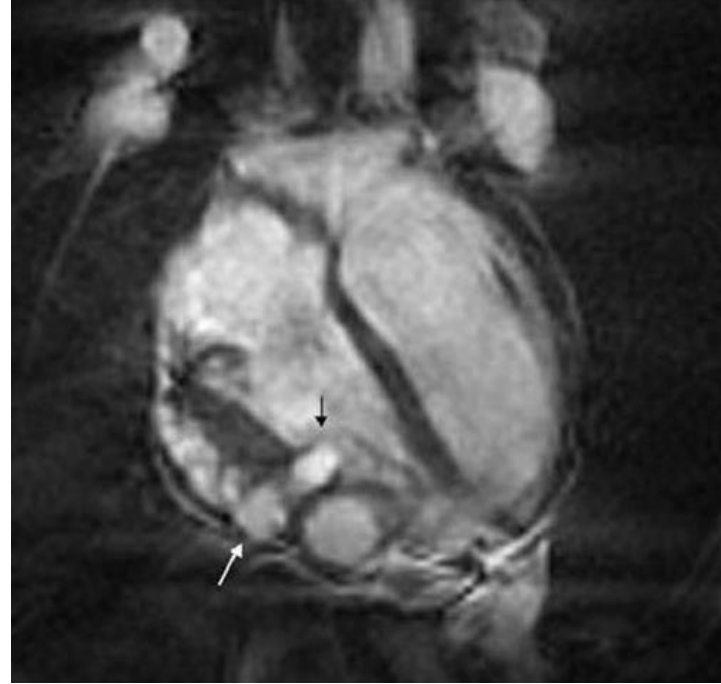
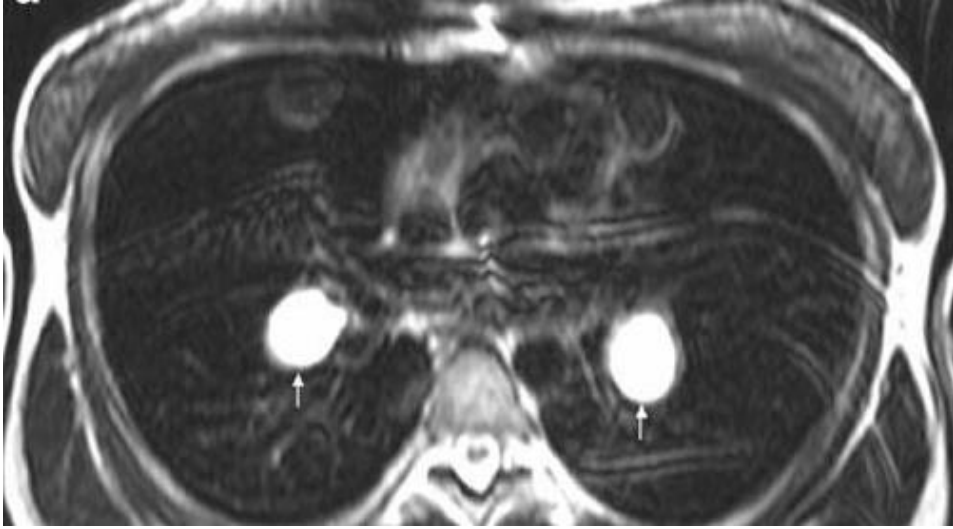
**PULMONER TROMBOEMBOLİ OLARAK YORUMLANABİLİR**



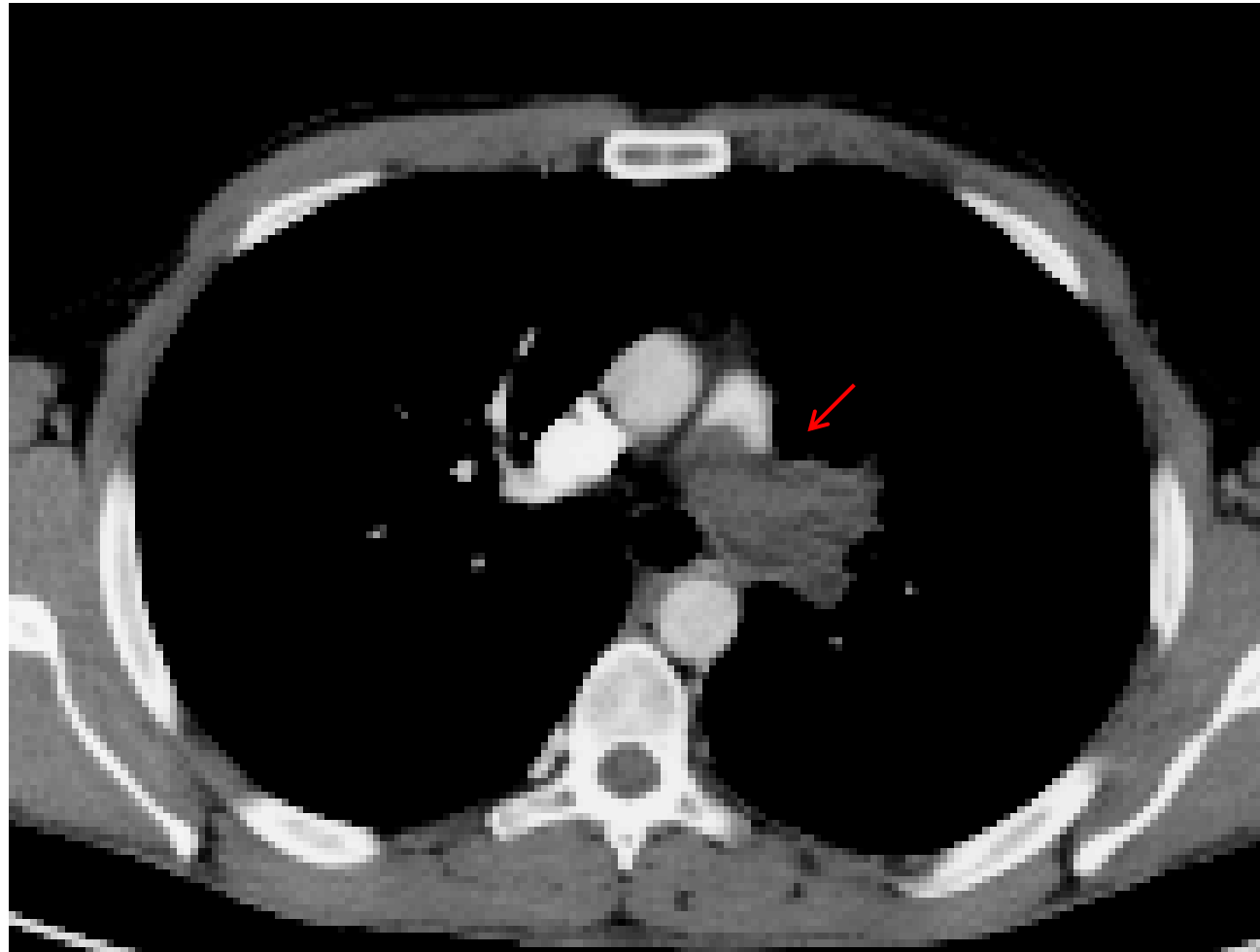
YETERSİZ KONTRAST TROMBOEMBOLİ GİBİ GÖRÜLEBİLİR







Pulmoner arter yerleşimli kist hidatik

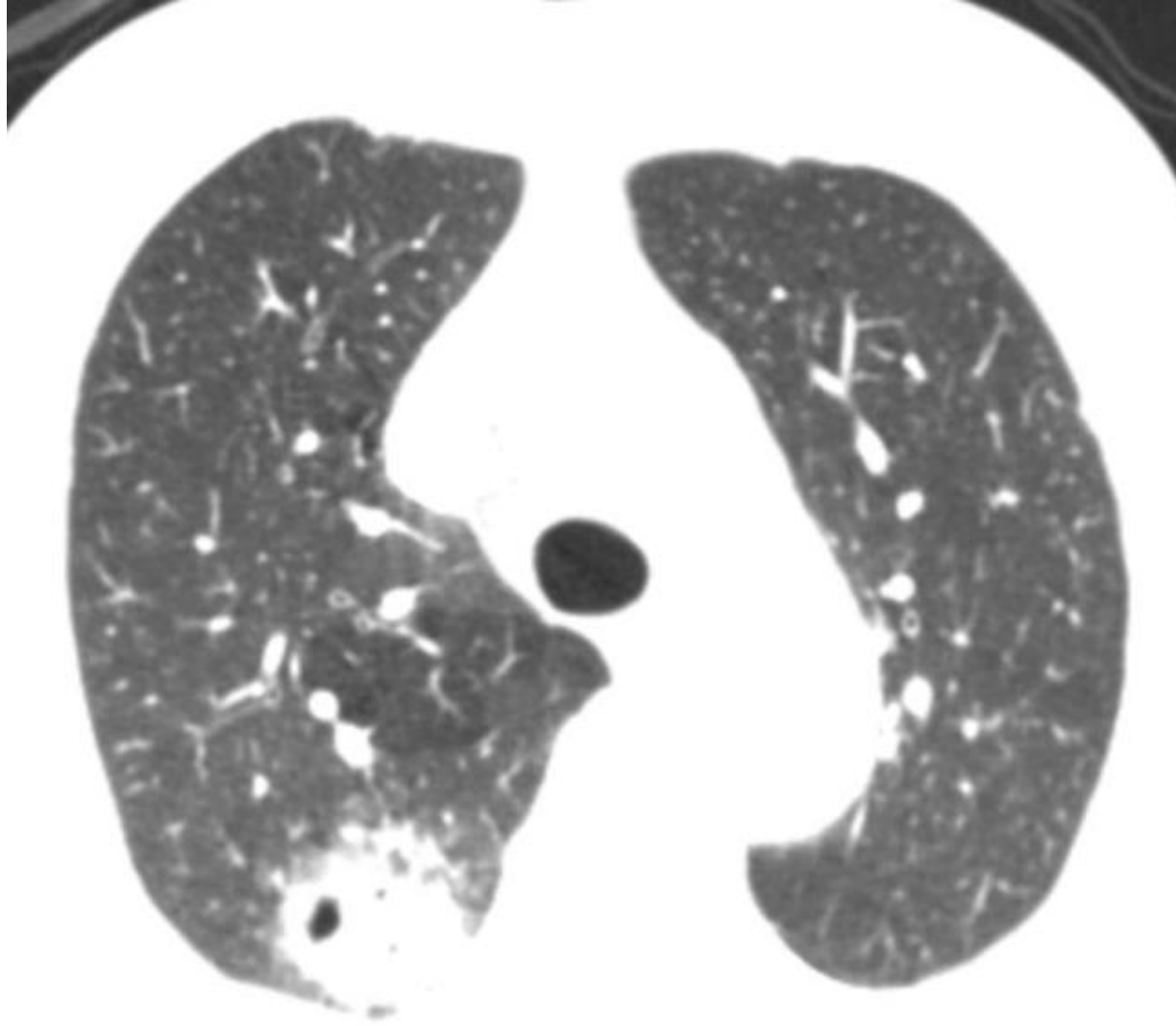


Pulmoner anjiosarkom

# MESAJ 4

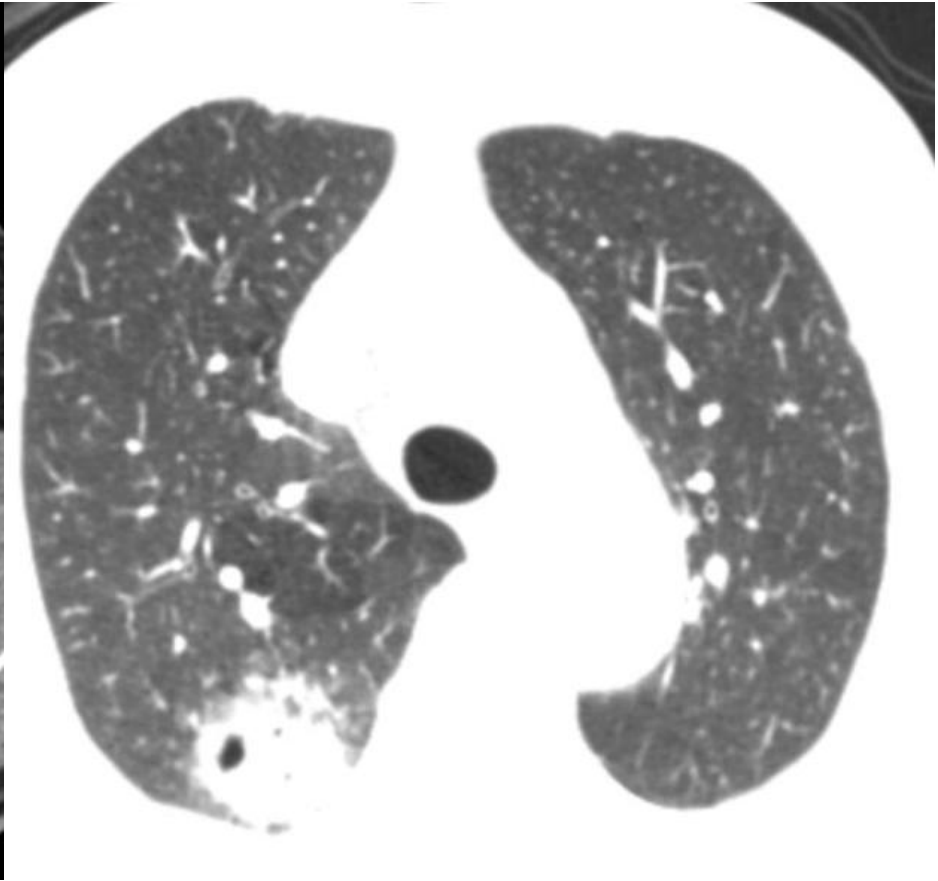
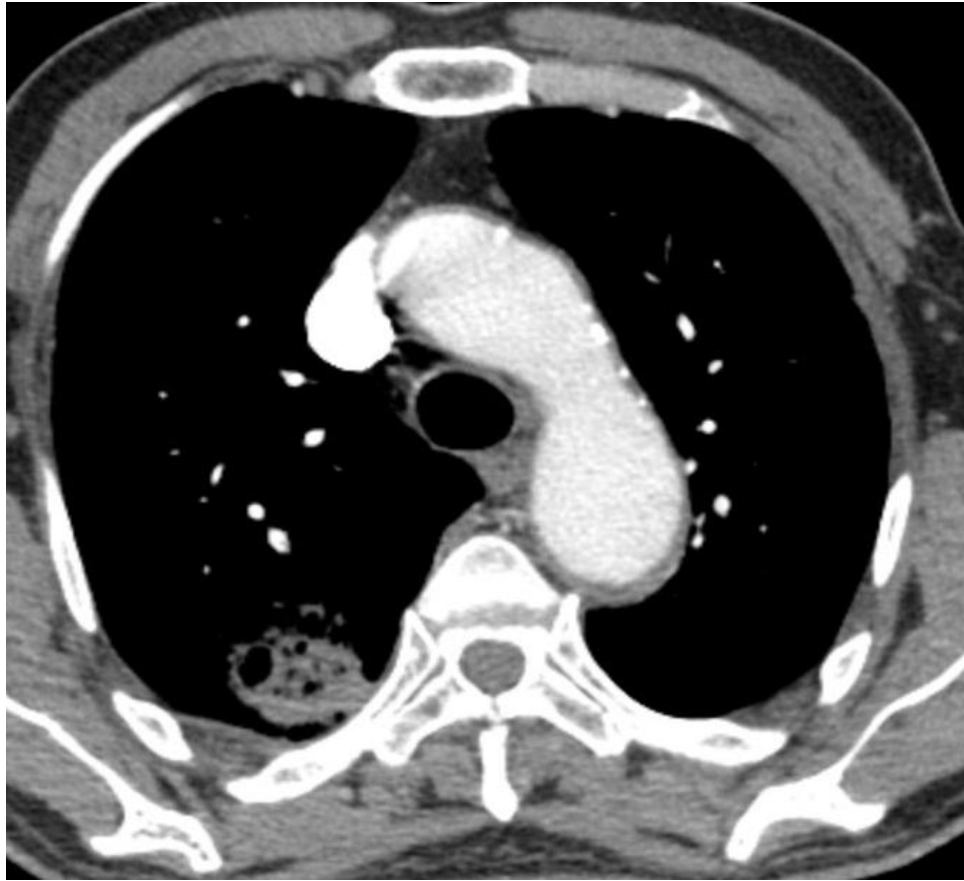
TROMBOEMBOLİYİ TAKLİT  
EDEN DURUMLAR  
BİLİNMEİ VE AKILDA  
TUTULMALIDIR

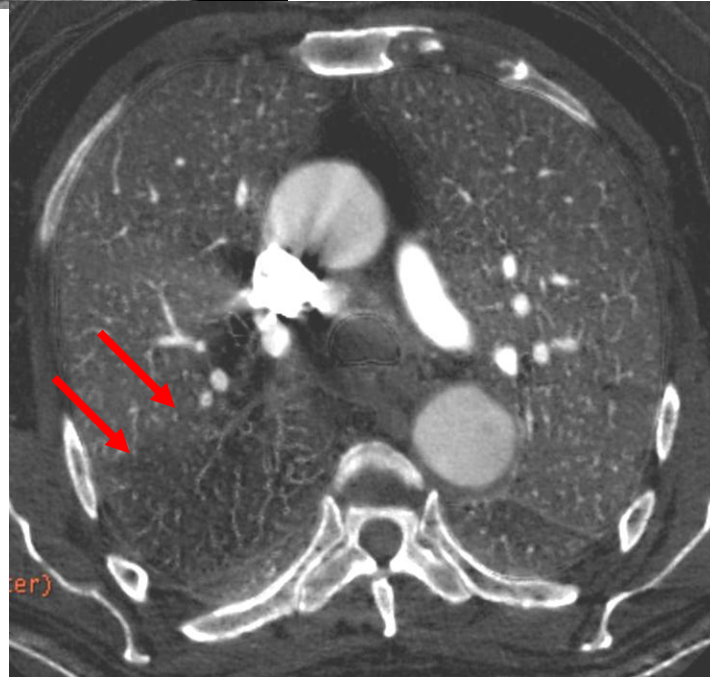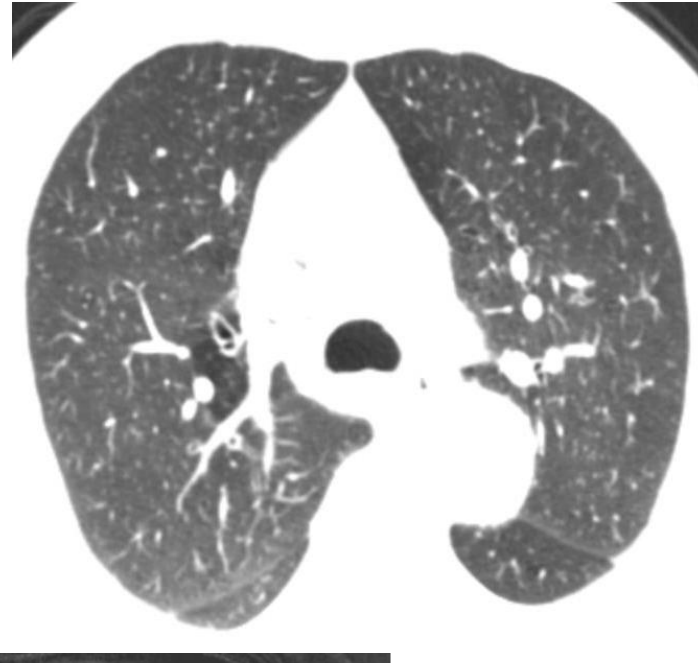
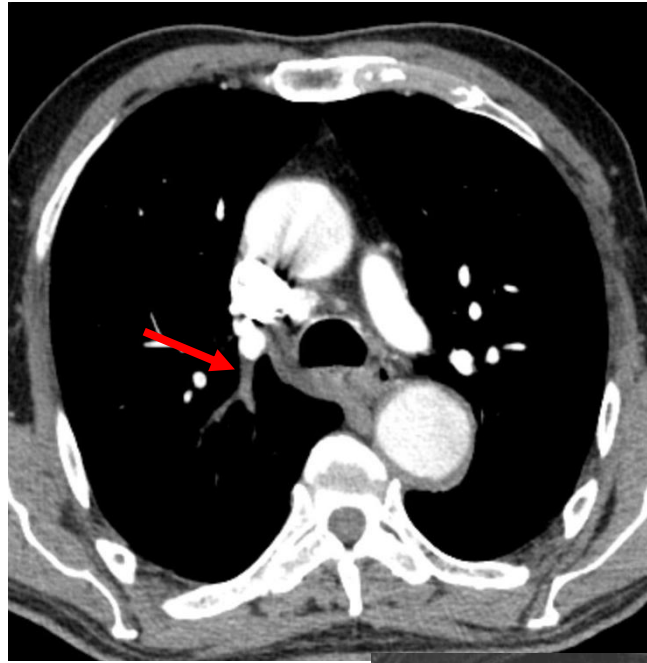
# DUAL ENERJİ BT VE TROMBOEMBOLİ

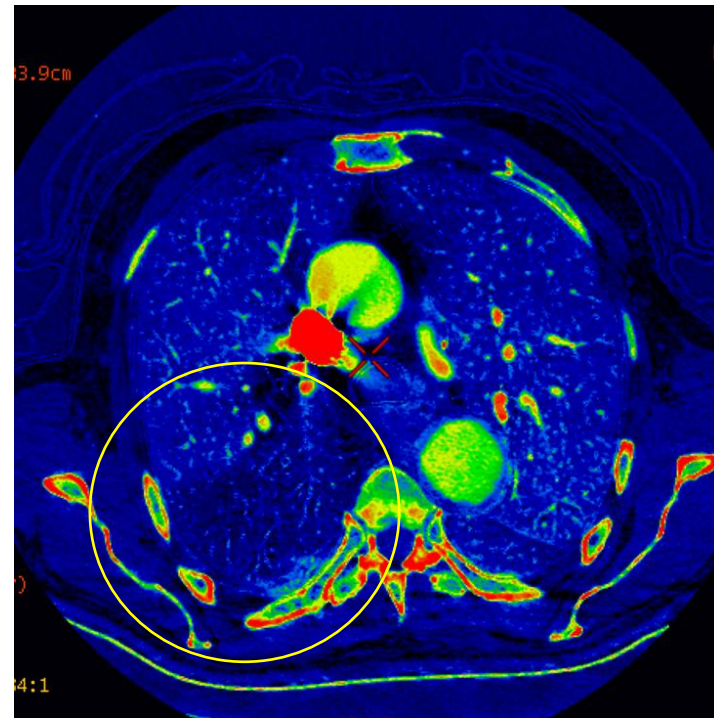
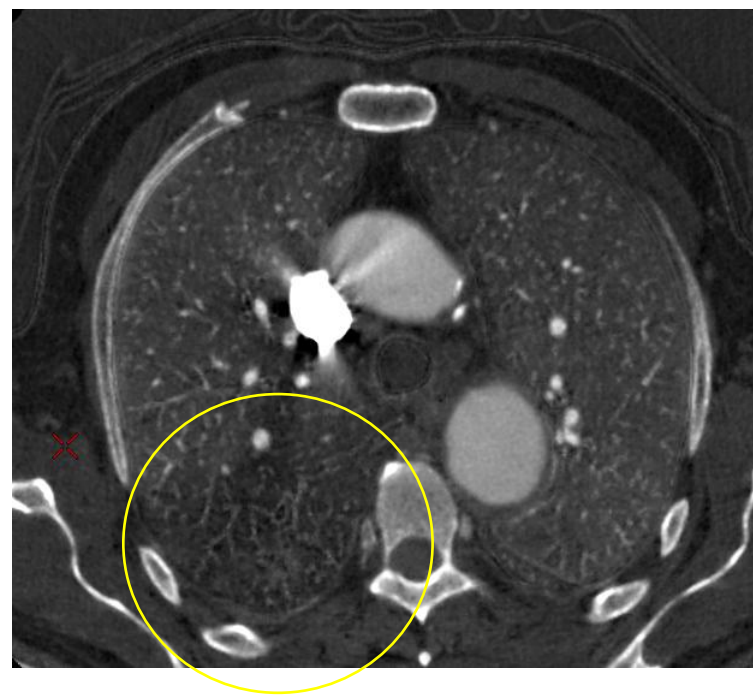
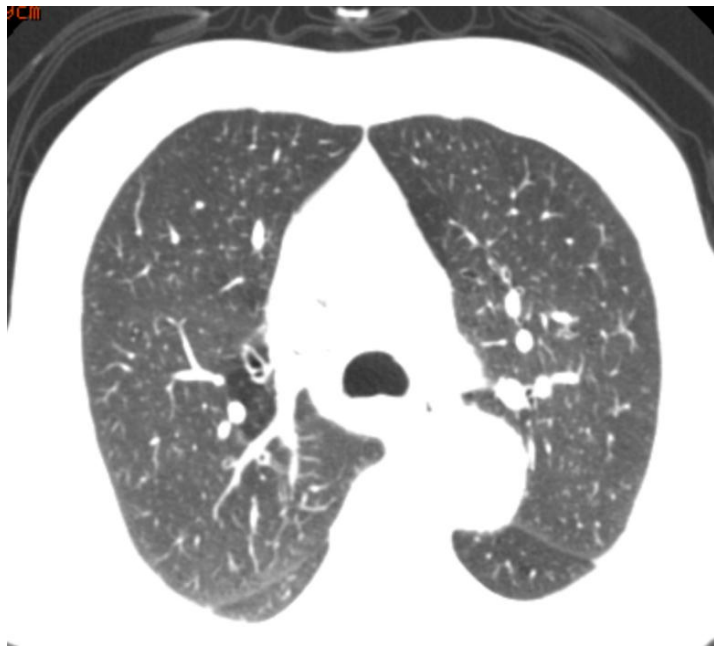


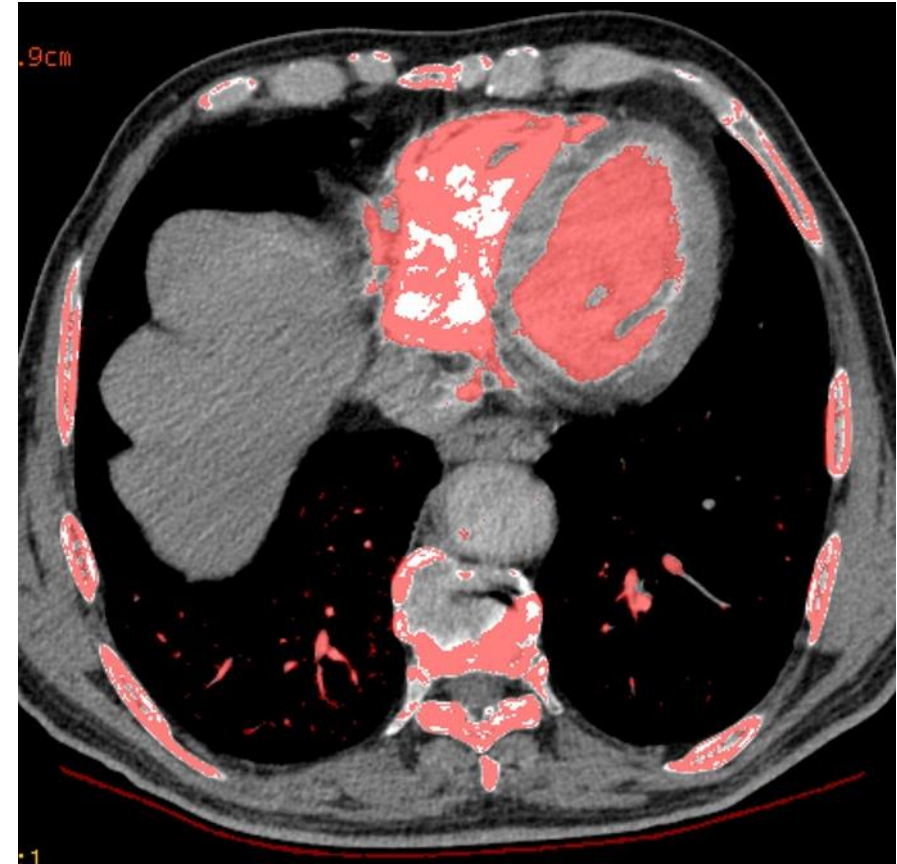
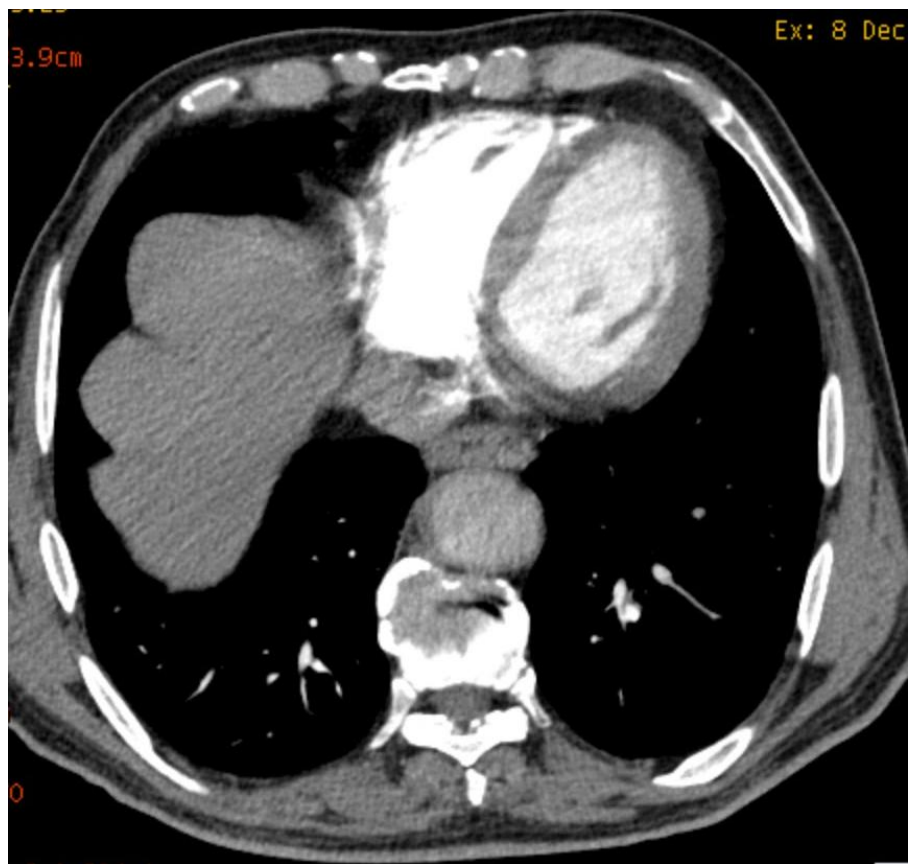
KAVİTER KİTLE, TTİİAB İÇİN UYGUN MU?



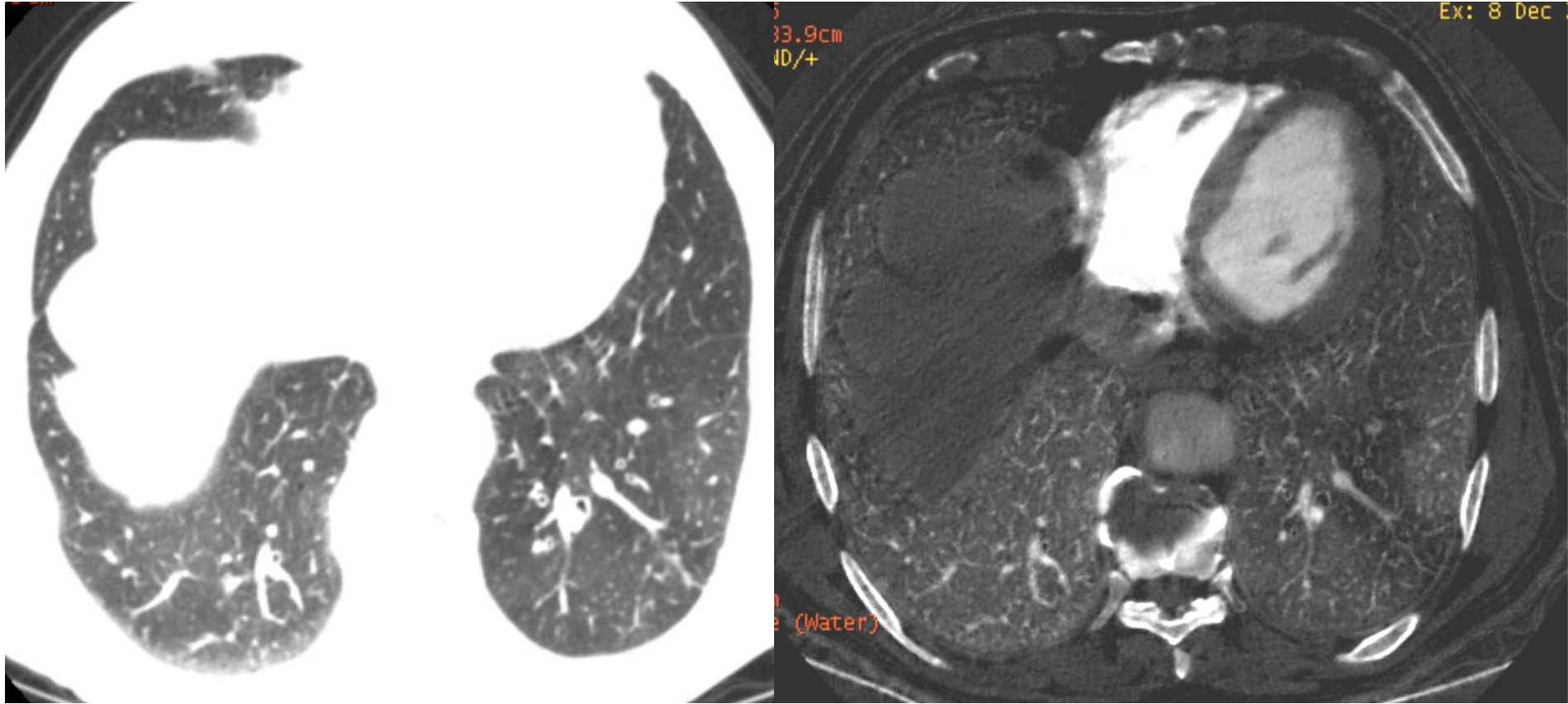






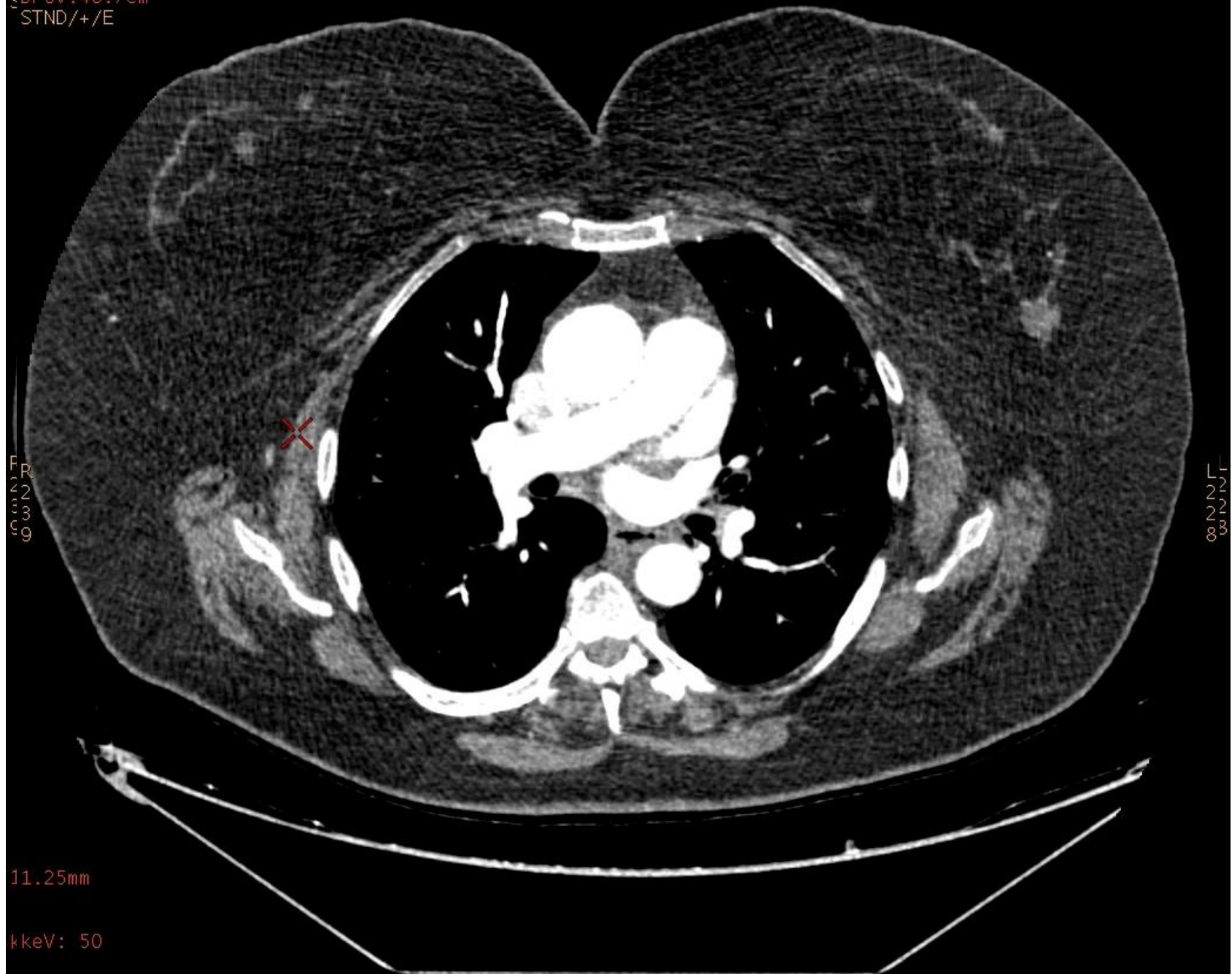






I I: 148.50  
[Im: 92  
s DFOV: 46.7cm  
STND/+ /E

Ex: 30 Oct 2012<sup>2</sup>



R  
2  
3  
9

L  
2  
2  
8  
3

11.25mm

kkeV: 50



MANYETİK REZONANS  
GÖRÜNTÜLEME (MRG) ve  
MR ANJİOGRAFI

# MR/ MR ANJİYOĞRAFI

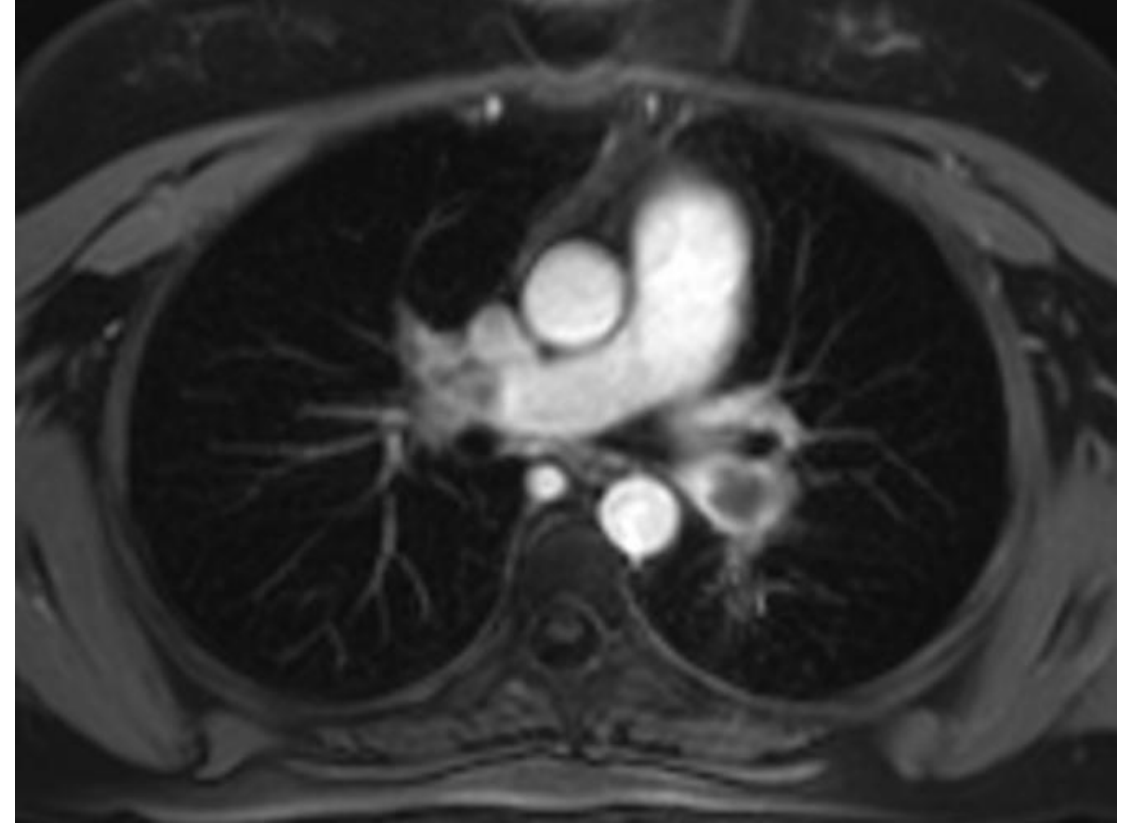
## Avantajlar:

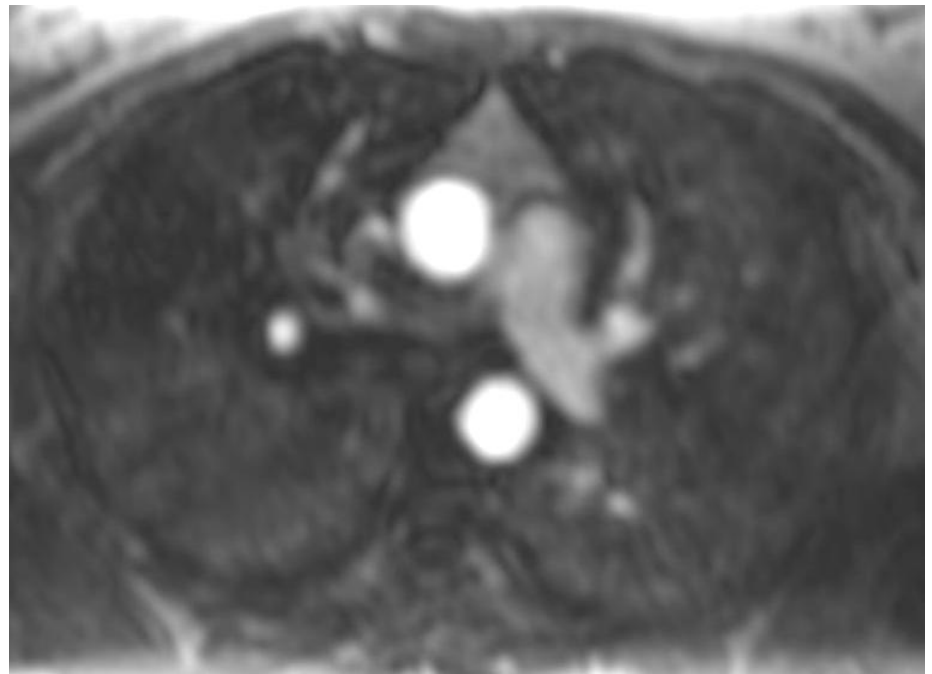
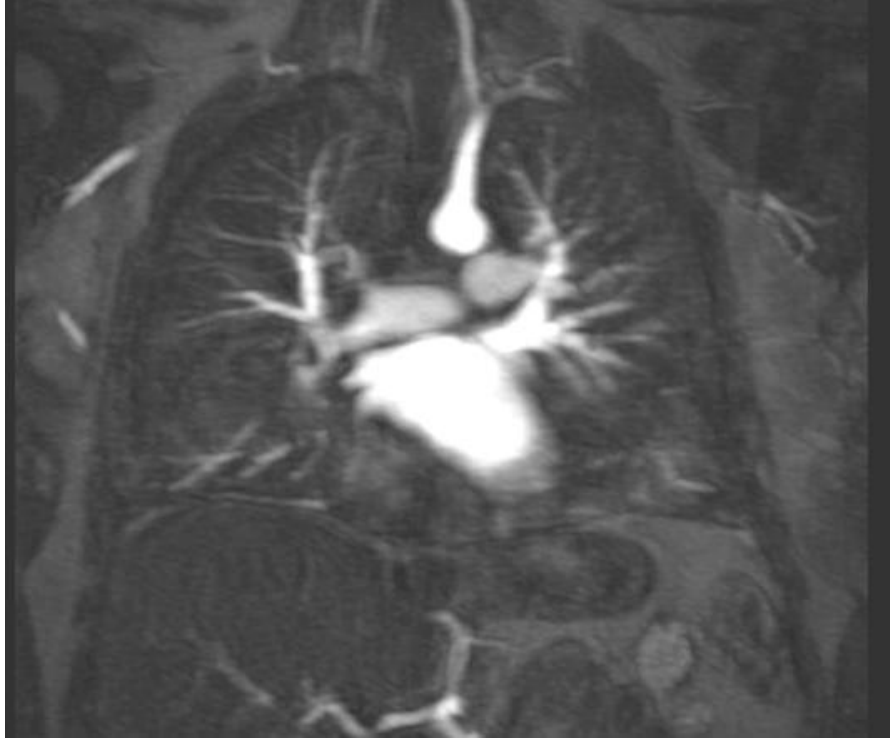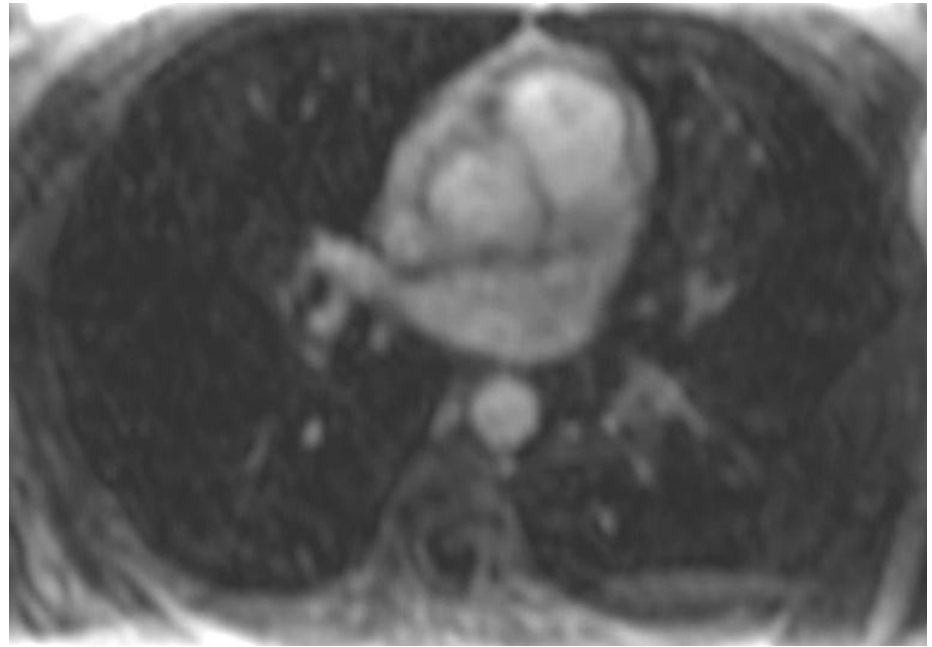
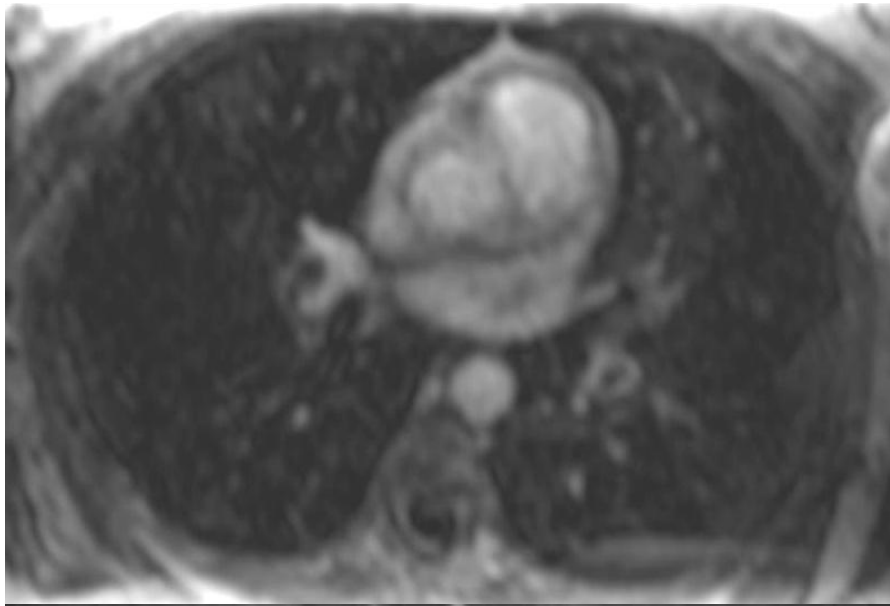
- ☺ İyonizan radyasyon  $\emptyset$
- ☺ Kontrast madde (Gd bazlı)
- ☺ MRA yanısıra perfüzyon bilgisi
- ☺ Sağ kalp fonksiyonları

## Dezavantajlar:

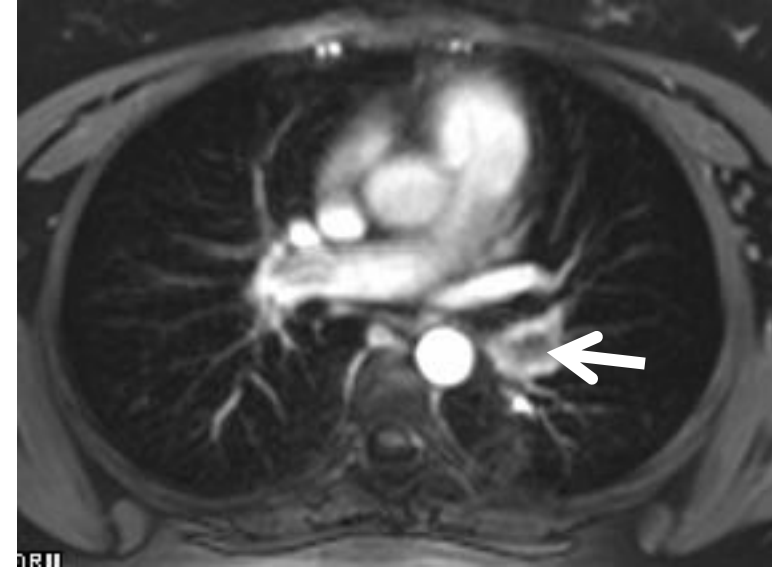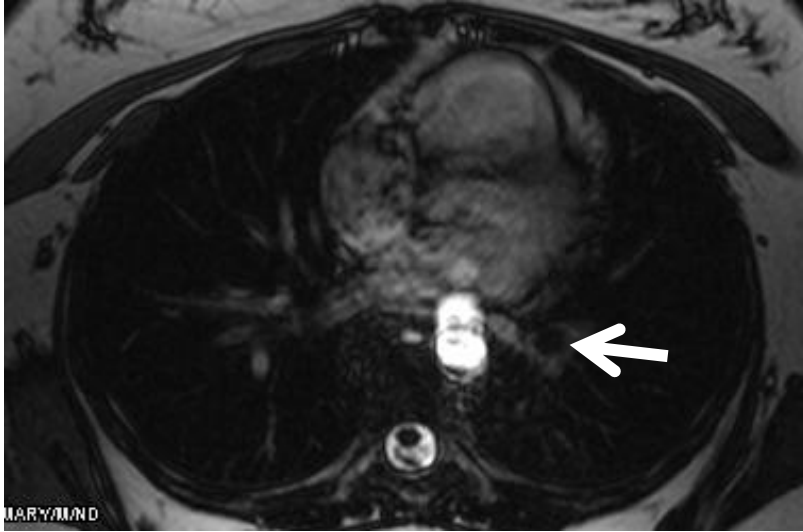
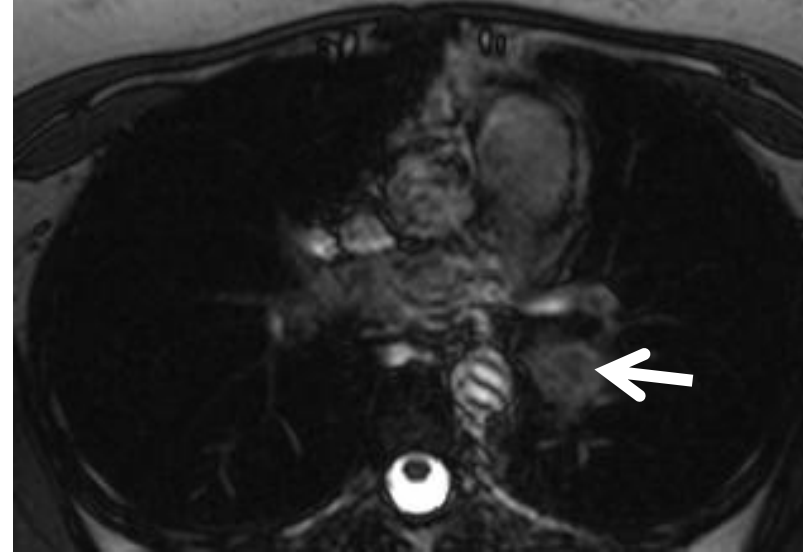
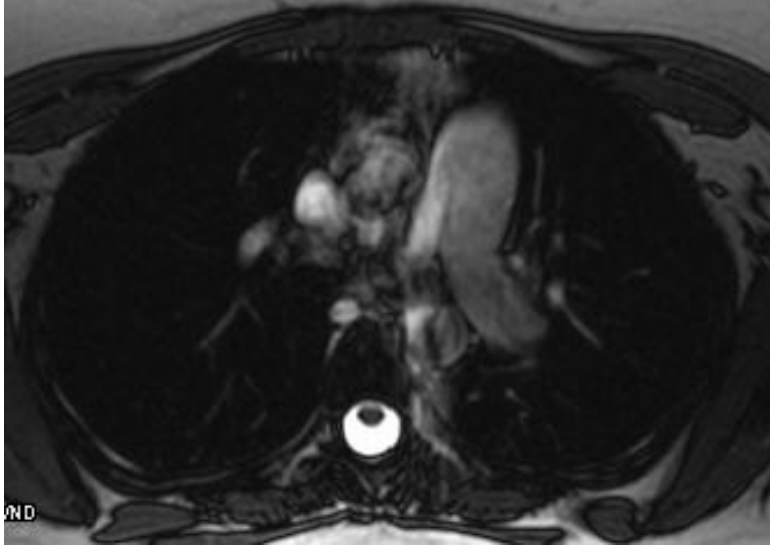
- ☹ Uzun görüntüleme süresi
- ☹ Daha düşük uzaysal çözünürlük
- ☹ Manyetik alana uyumsuz solunum destek cihazları

Başarısı: Ana > Lober > Segmental/subsegmental arter





# MR/ MR ANJIYOGRAFI



Gebe hasta, kontrastsız MRA inceleme, PTE

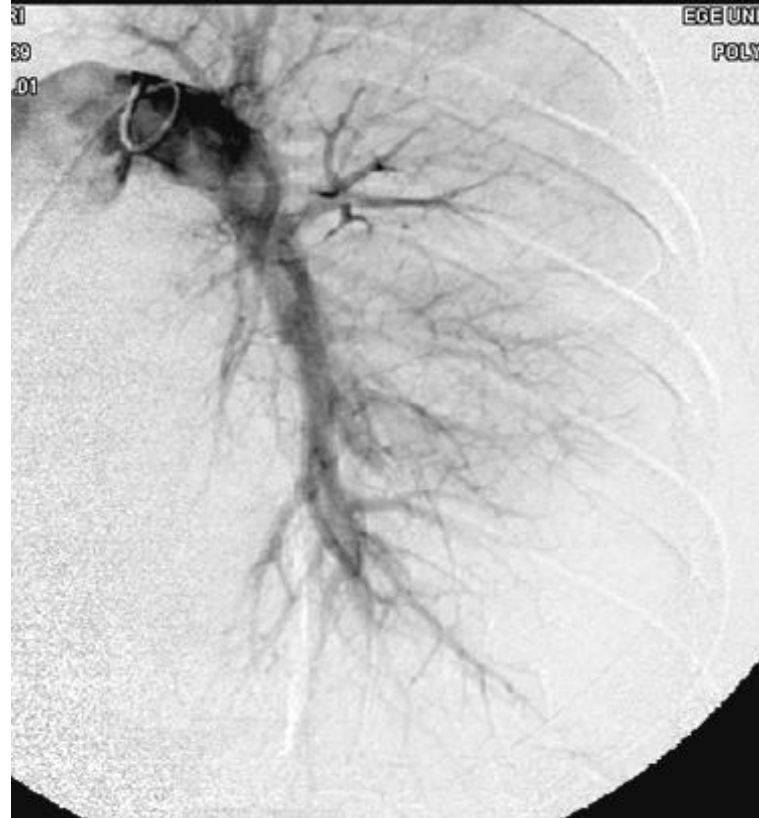ANJIOGRAFI/GİRİŞİMSEL RADYOLOJİ

# Pulmoner tromboembolide

- Tanı amaçlı ( Anjio BT sonrası giderek kullanımı azaldı)
- Tekrarlayan tromboemboli vakalarında kava filtre yerleştirilmesi
- Masif tromboembolide ve/ veya antikoagulan kullanılmayan durumlarda kateter trombolitik tedavi

# PULMONER ANJIYOGRAFİ

- ~~1960 ... PE tanısında altın standart~~





# Pulmoner Anjiografi

## **Direk Bulgular**

Dolma defekti

Akımı devamlılığı +

Santral

Marjinal

Tam tıkanma ve  
kenardan ince  
kontrast sızıntısı

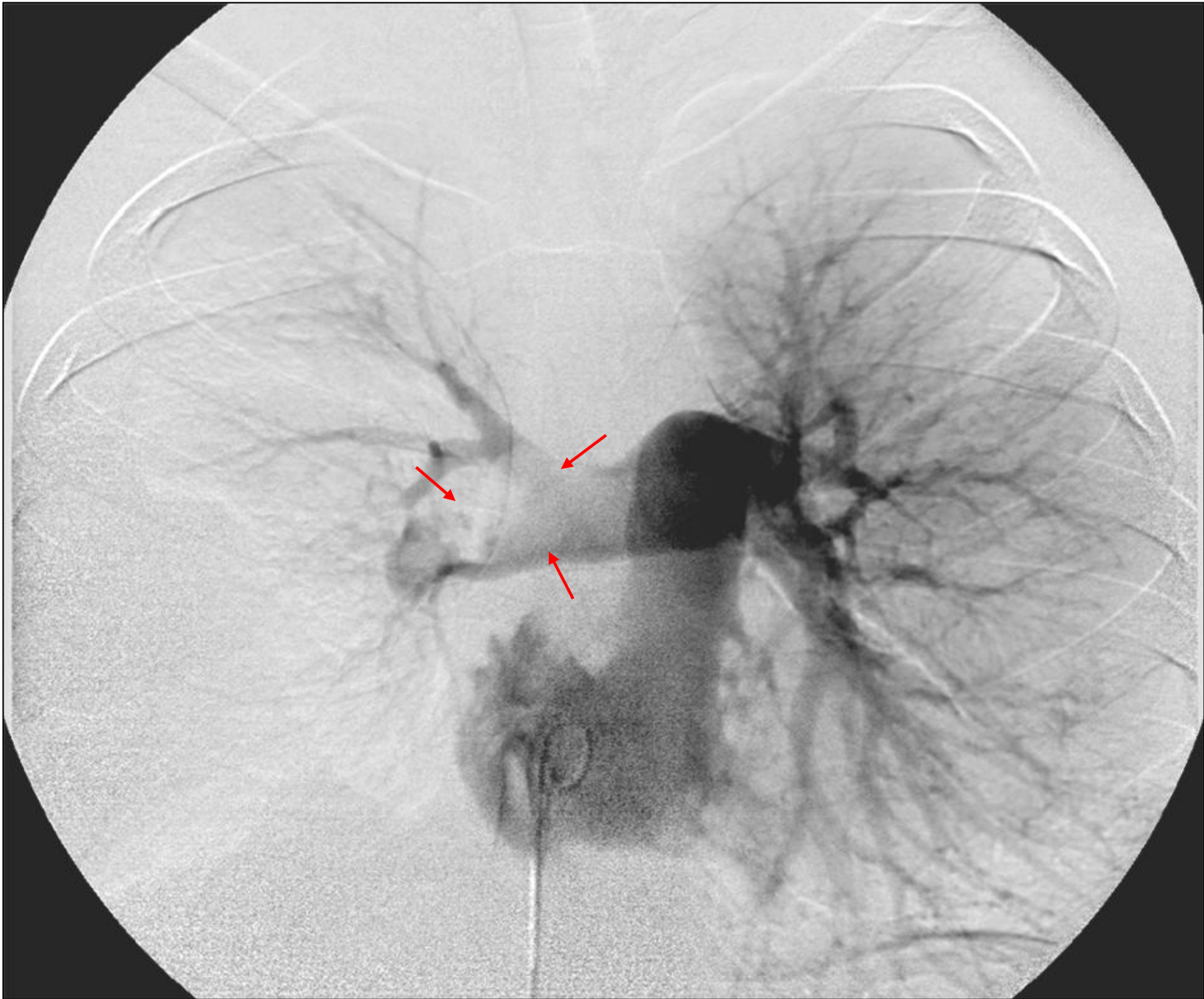
## **İndirek Bulgular**

Arterde tam kesilme

Perfüzyon defekti

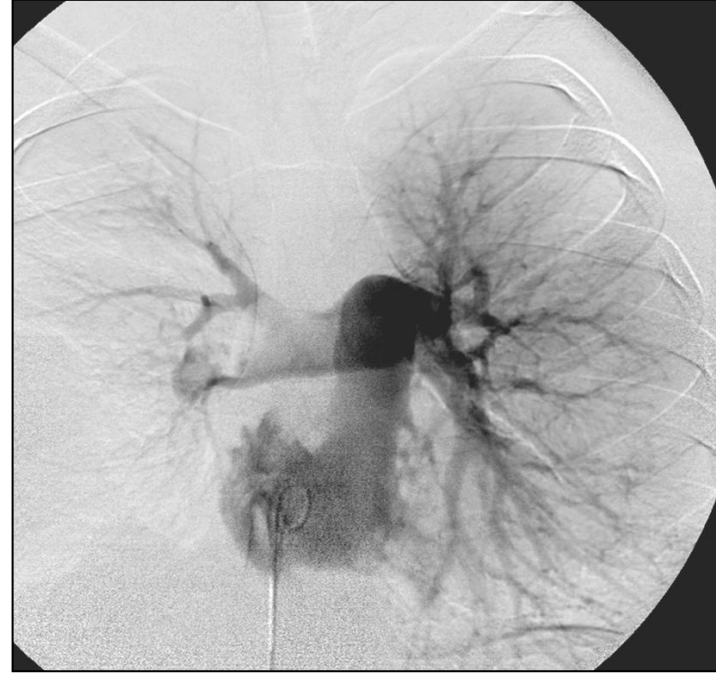
Oligemi / Avaskülarite

Budanmış ağaç



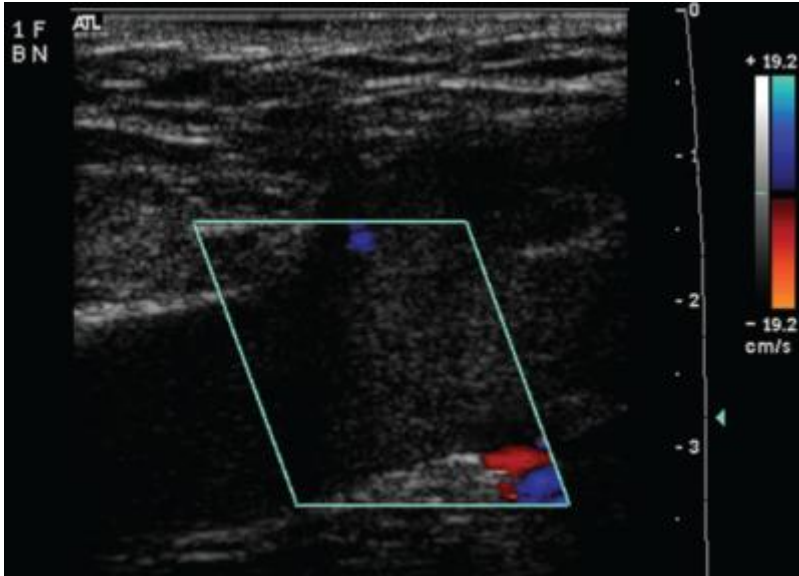
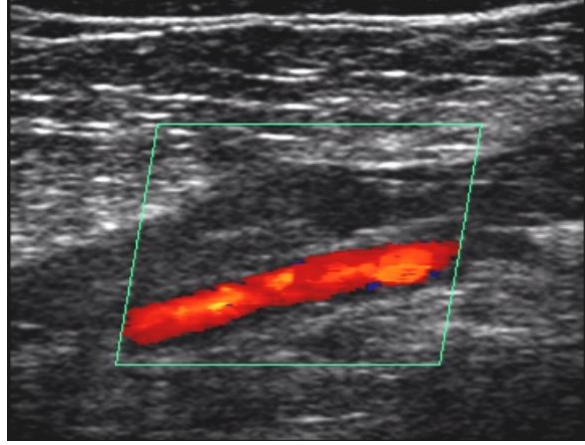
## Dezavantaj:

- ✓ İnvaziv
- ✓ Pahalı
- ✓ Özel ekip
- ✓ Segmental /subsegmental damarları değerlendirmede sınırlı(Gözlemciler arası uyum düşük)
- ✓ Radyasyon



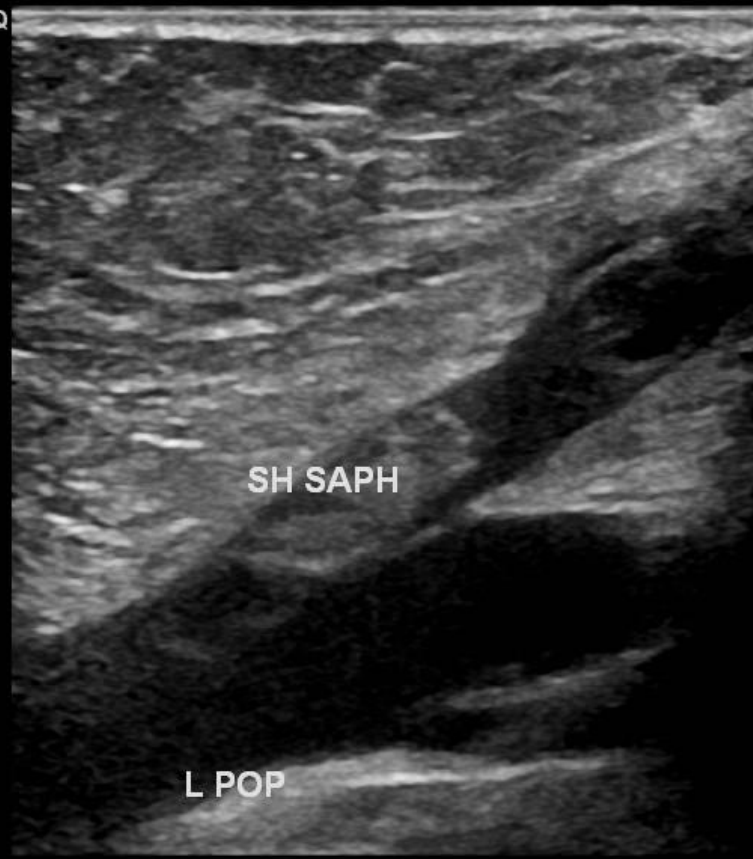# DOPPLER ULTRASONOGRAFİ

# US / Doppler US



- DVT araştırılır
- US normal ise pulmoner emboli yok demek değil
- İzole DVT pelvik venlerde olup alt ekstremitte venleri normal olabilir.

LOGIQ  
E9



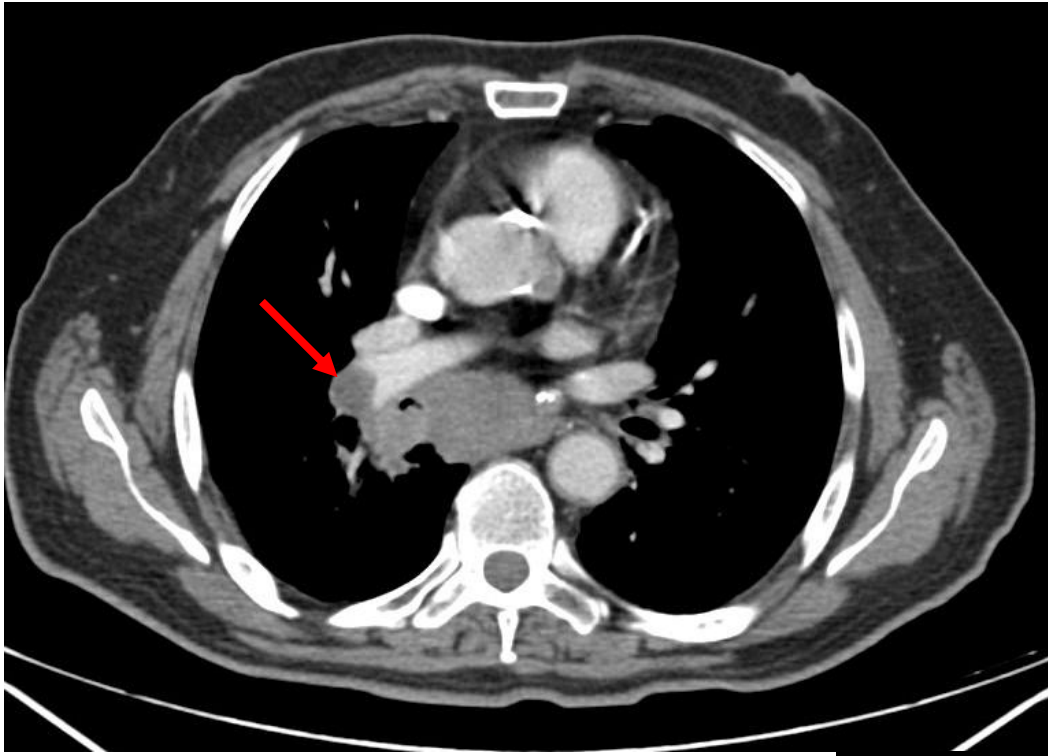
CHI  
Frq 8.4  
Gn 38  
S/A 2/1  
Map H/1  
D 5.0  
DR 69  
AO% 100



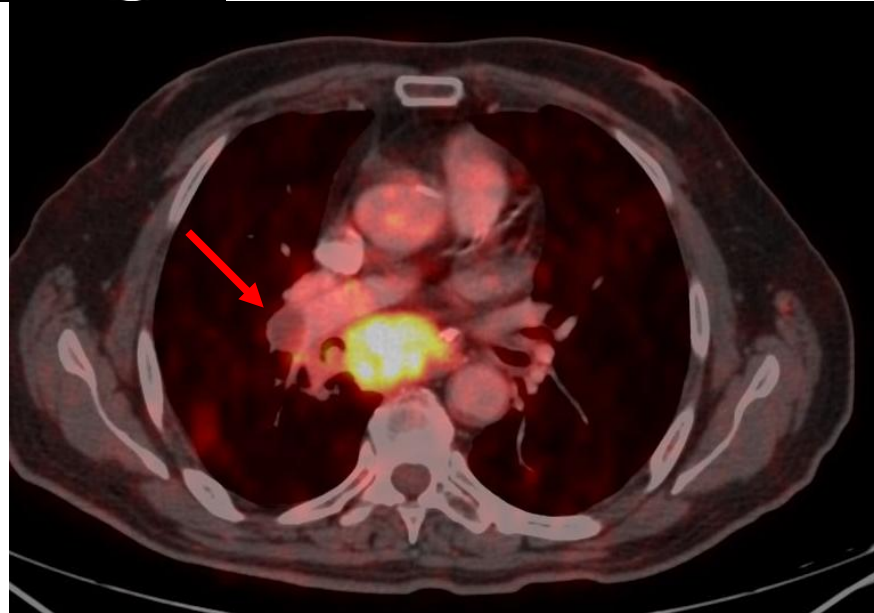
4-

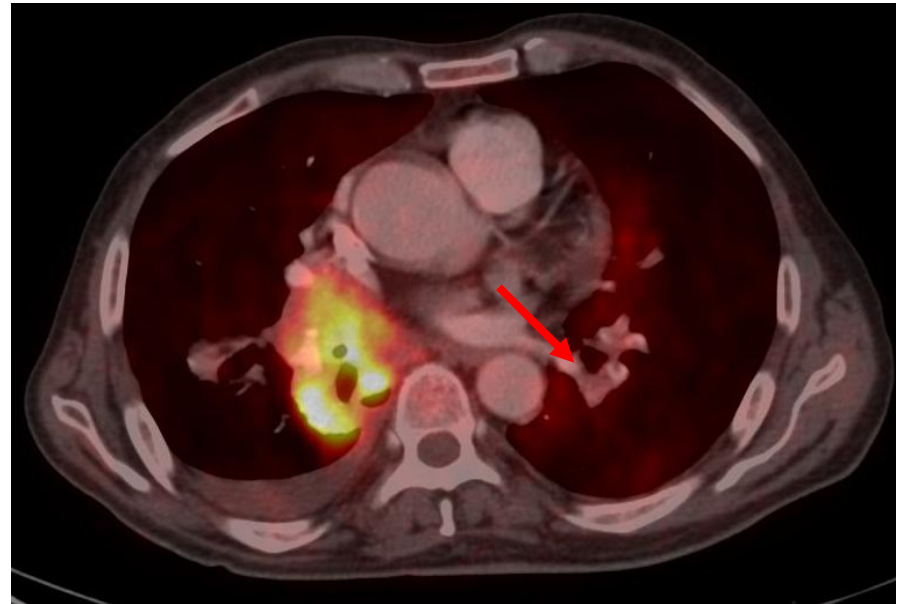
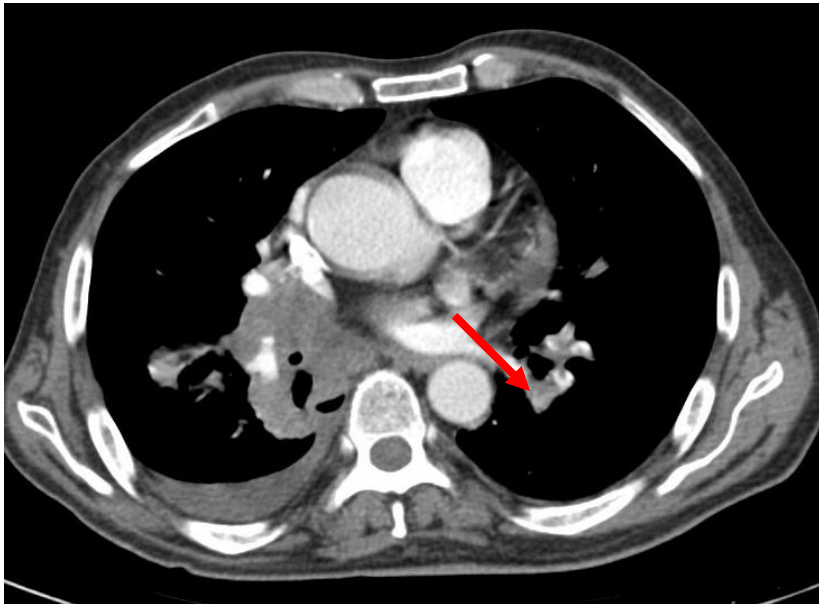
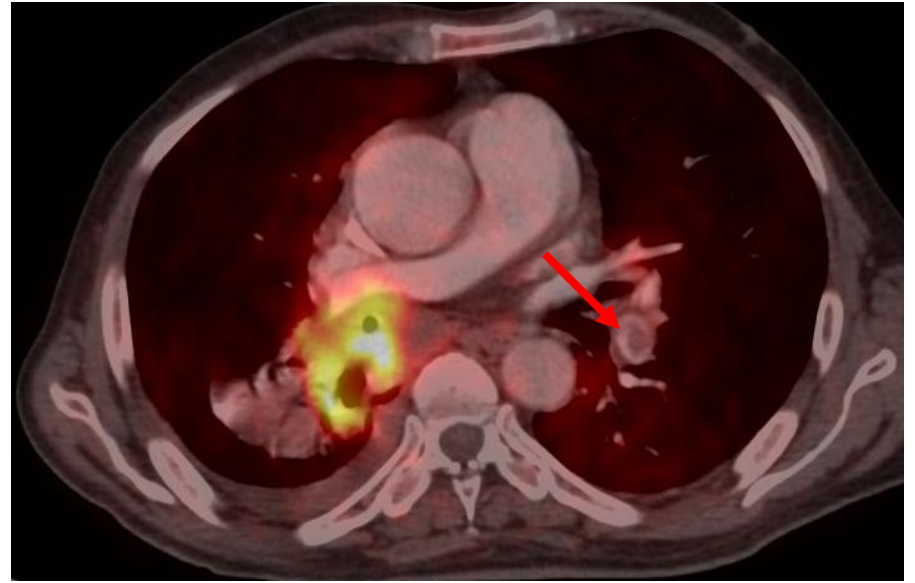
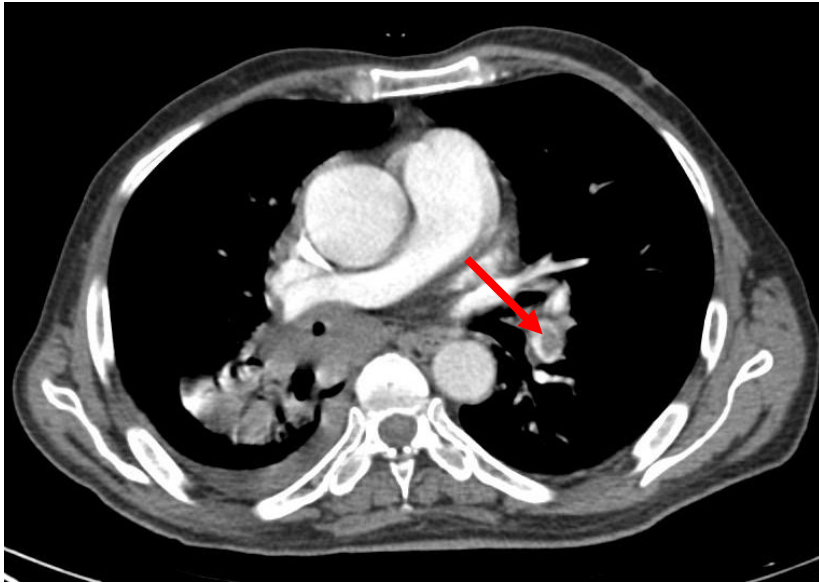


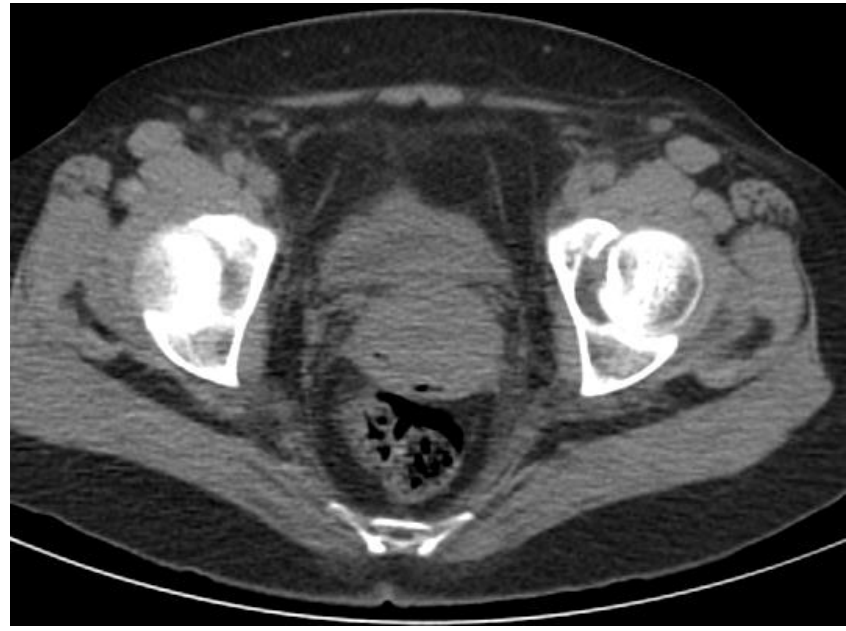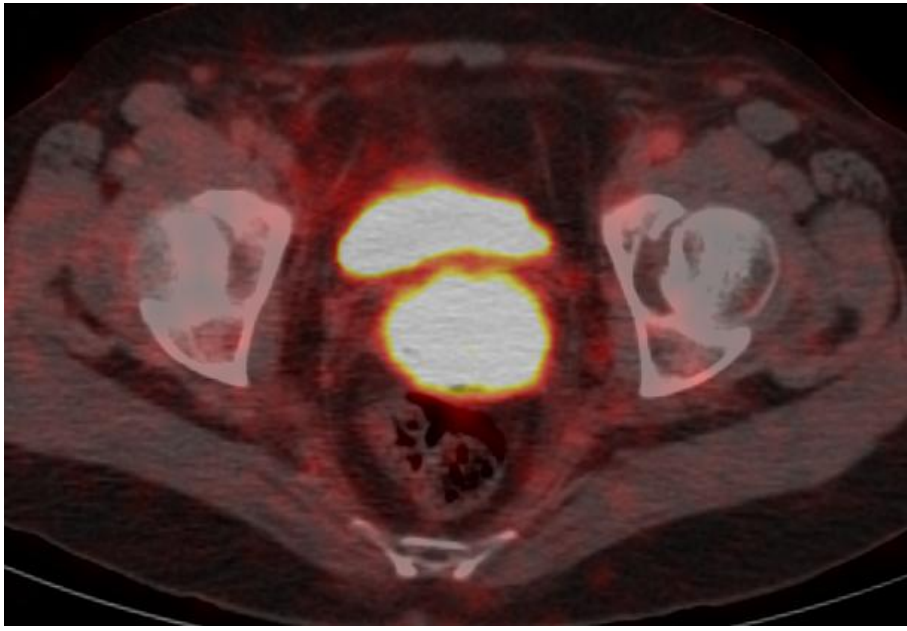
PET/BT



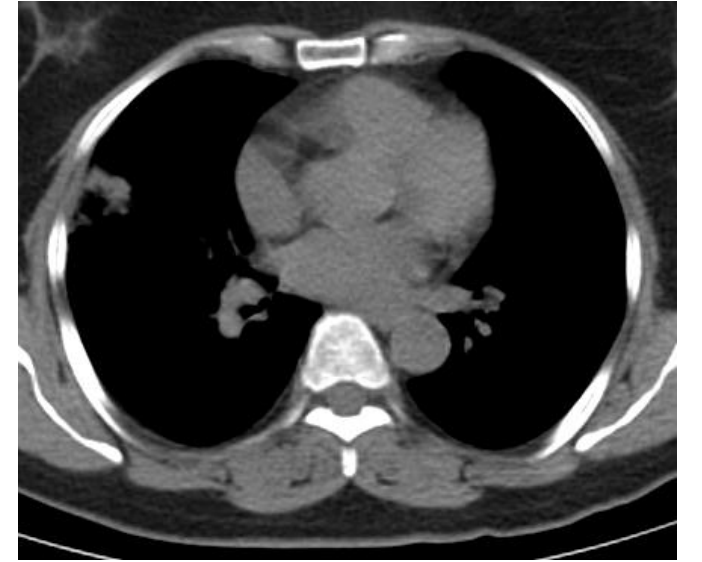
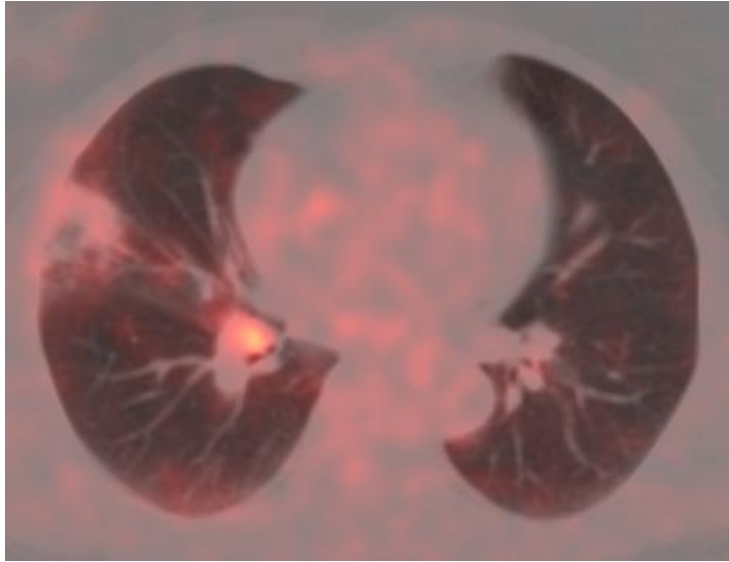
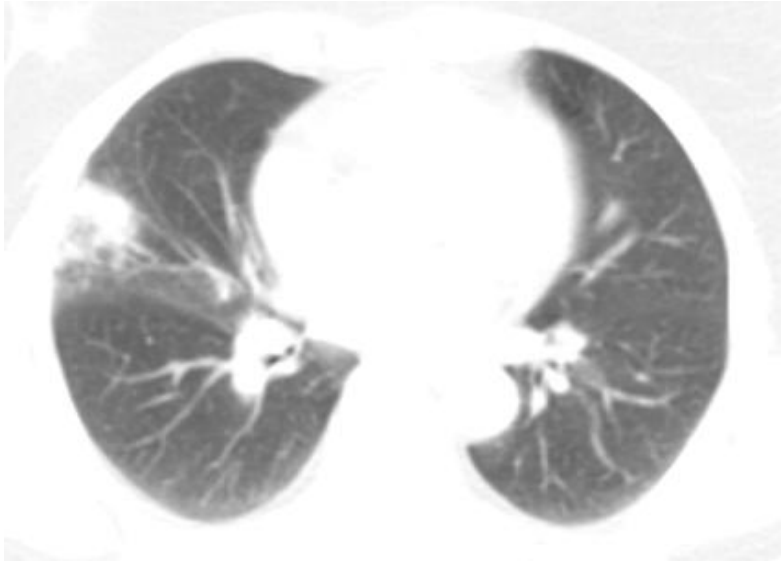
Akciğer kanseri  
Takip hastası





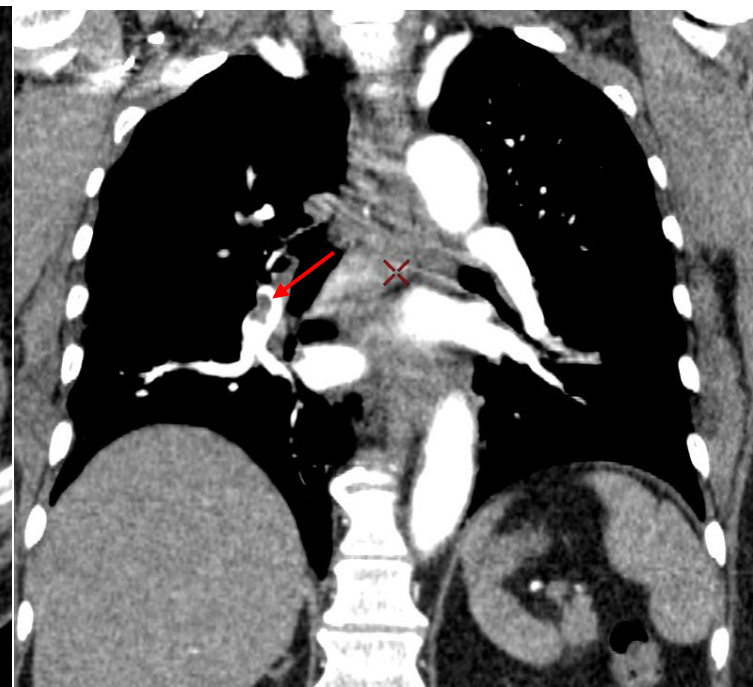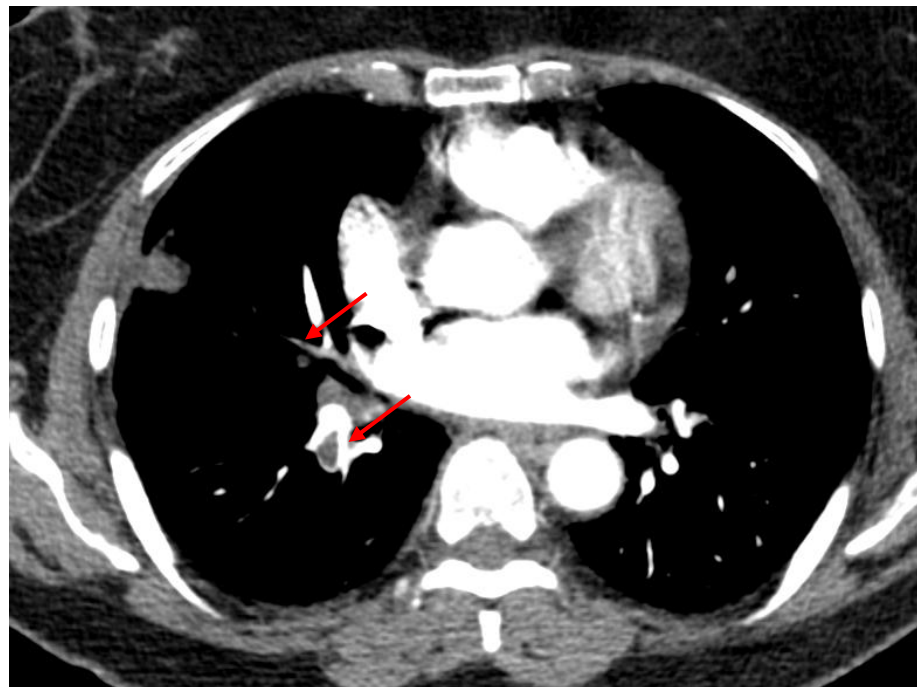
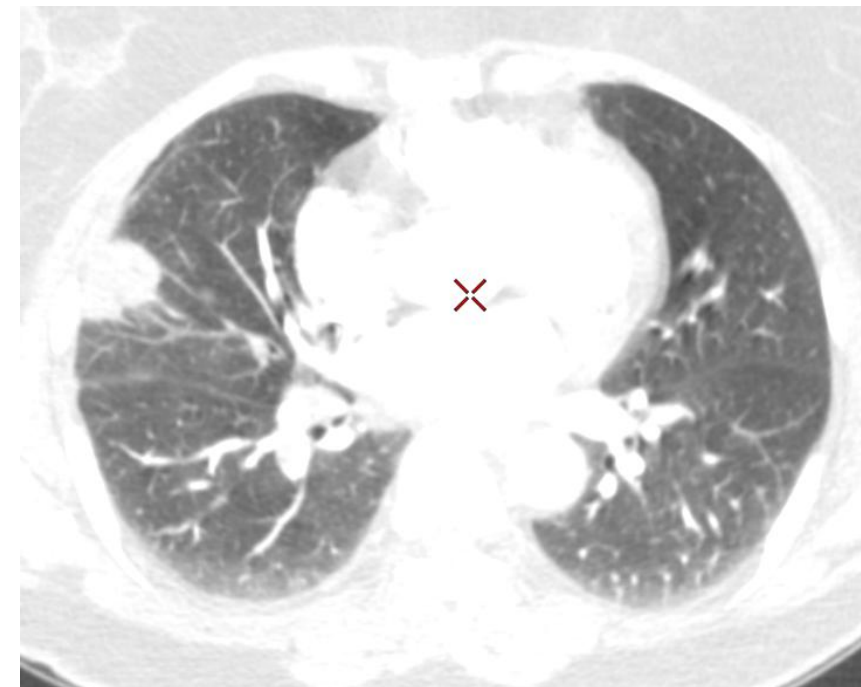


Serviks kanseri



Akciğer metastazı? İkinci primer ?





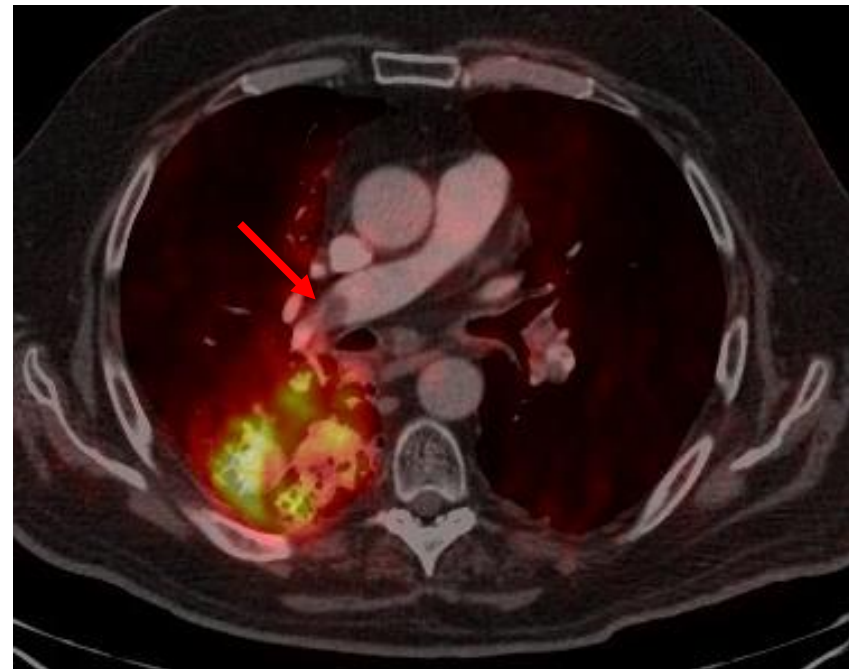
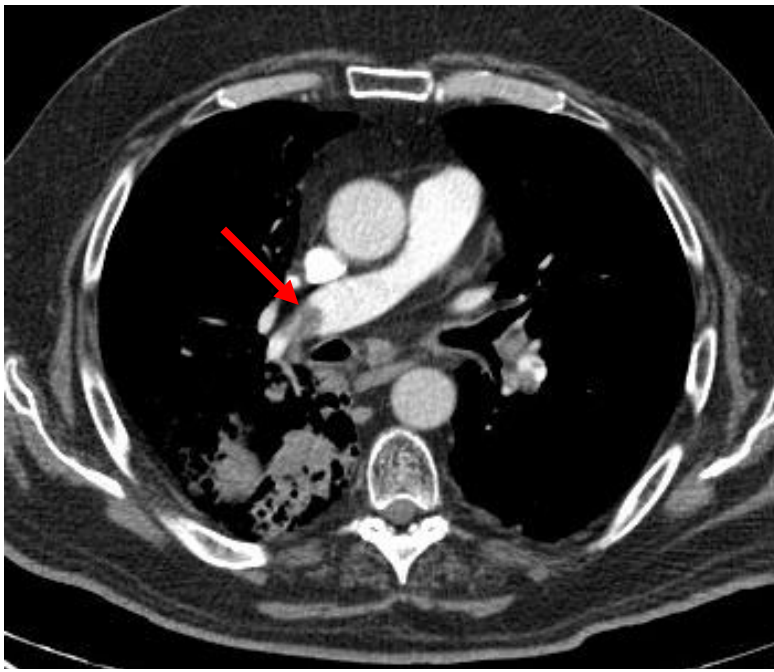
Wells' score for prediction of PE.<sup>4,8</sup> A total score >6 indicates a high probability of a PE, a score of 2-6 moderate probability and a score <2 low probability<sup>4</sup>

Parameter	Score
Clinically suspected DVT	3
Alternative diagnosis less likely than PE	3
Rapid heart rate	1.5
Immobilization within past 4 weeks	1.5
History of DVT	1.5
Haemoptysis	1
Malignancy	1

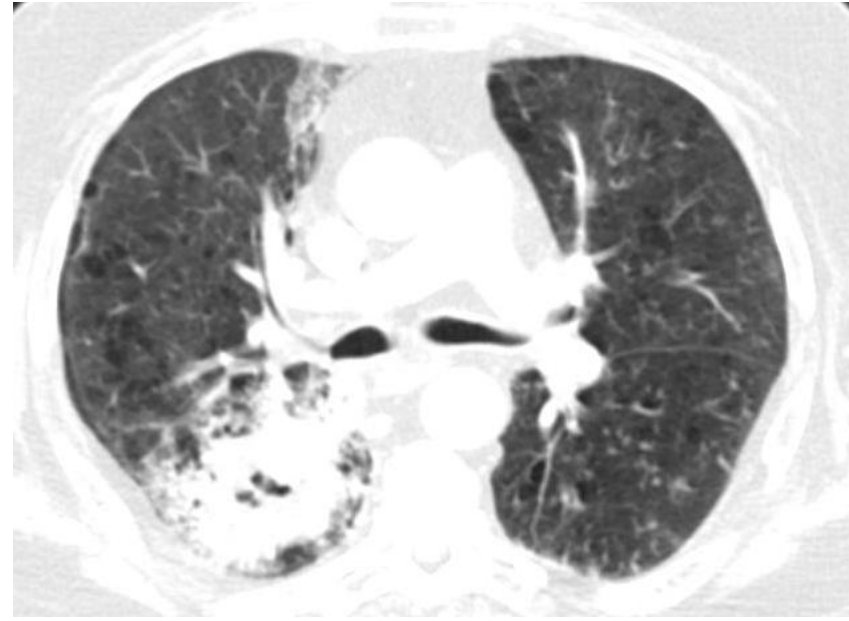
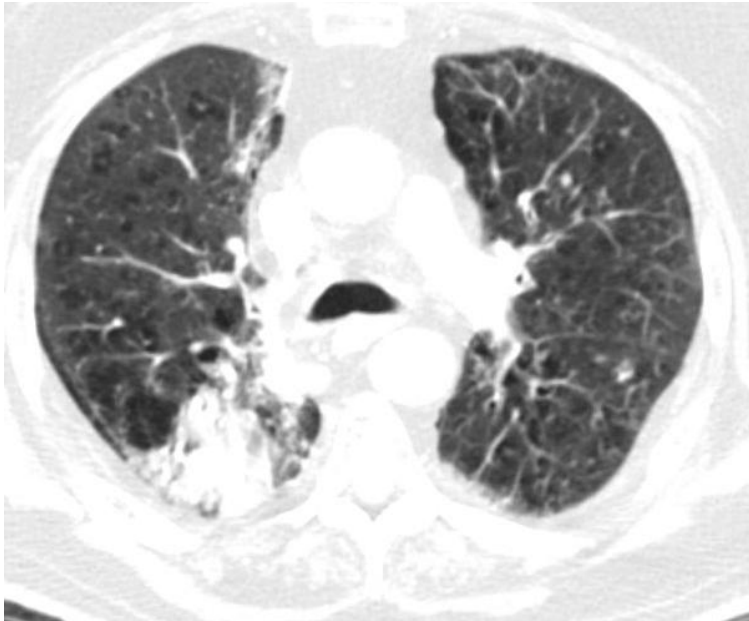


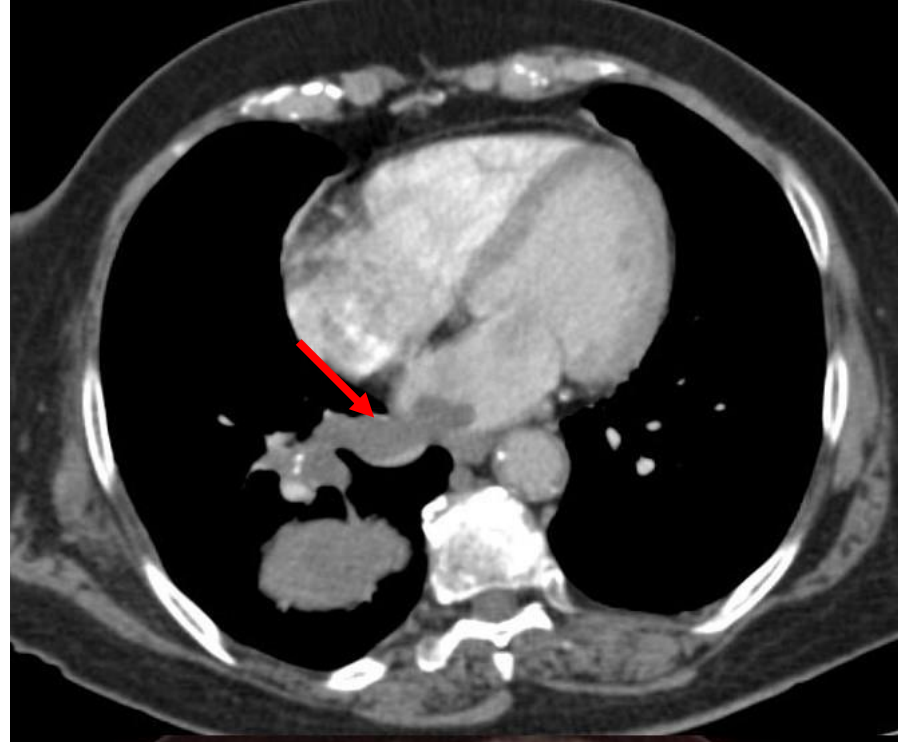
## MESAJ 7

MALİGNİTE HASTALARINDA  
PULMONER TROMBOEMBOLİ  
GELİŞEBİLECEĞİ  
UNUTULMAMALIDIR

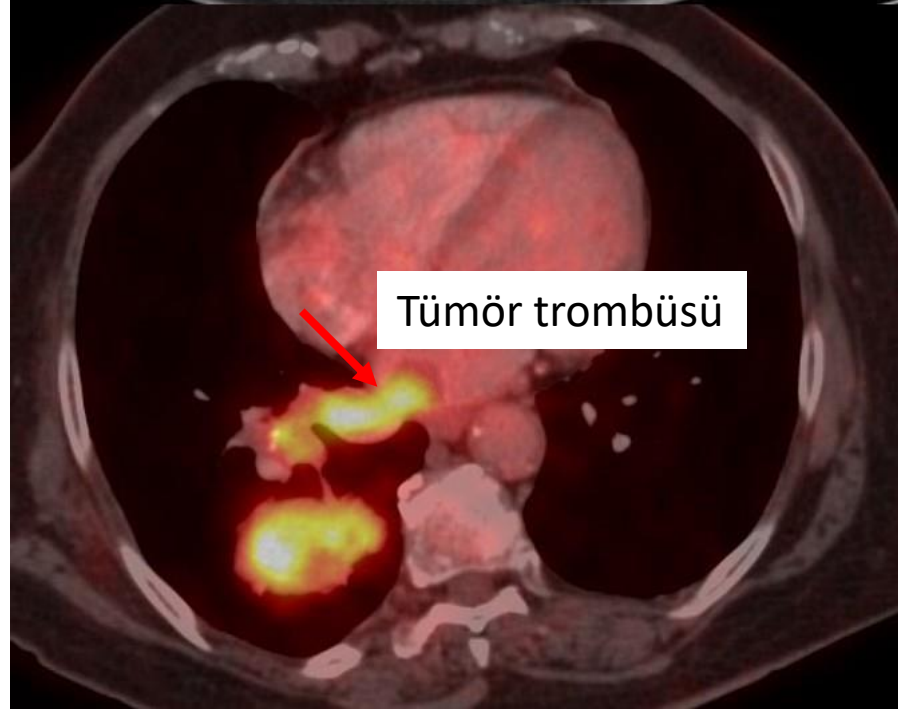


Geçmeyen konsolidasyon nedeniyle Akciğer malignitesi düşünülerek PET/BT istenmiş

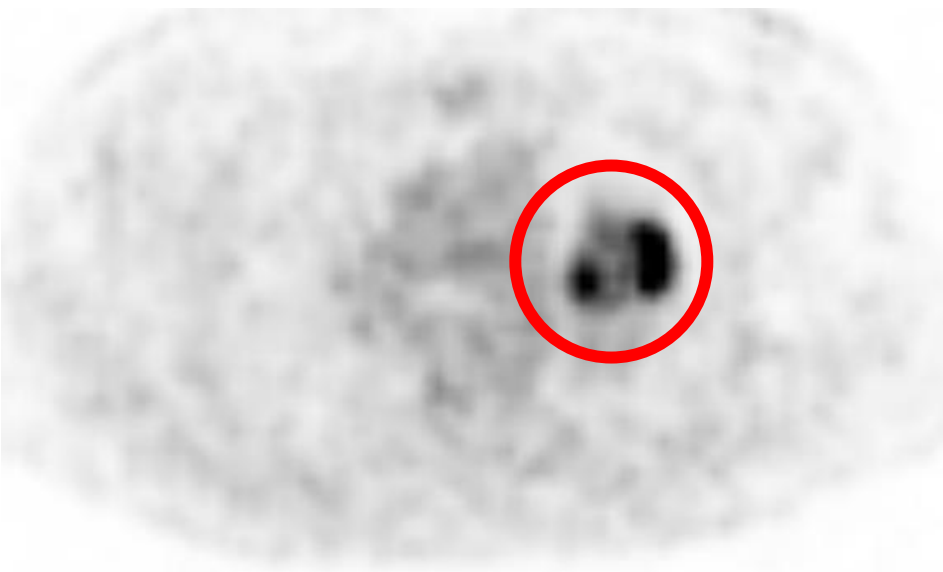
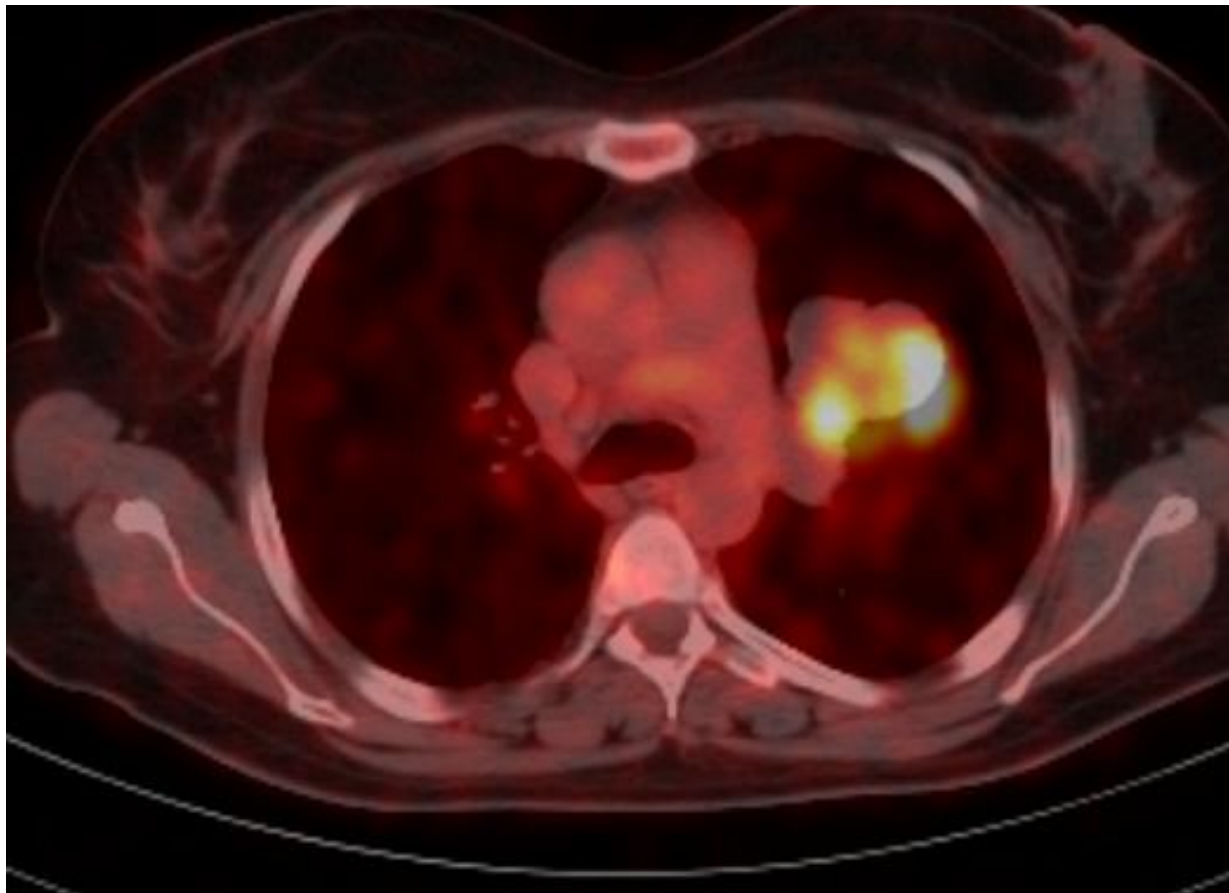
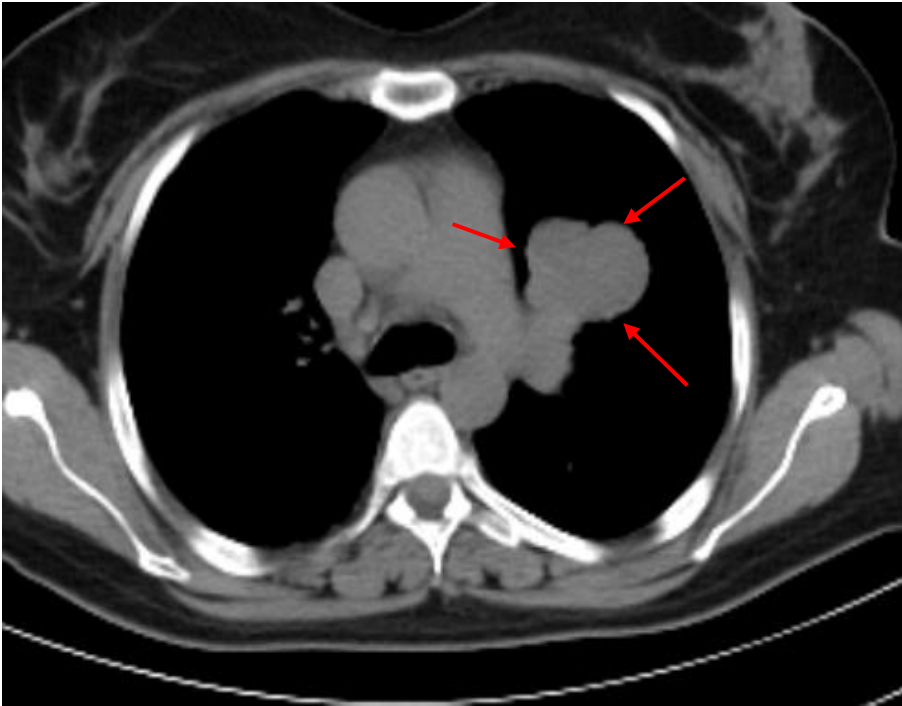




Akciğer kanseri



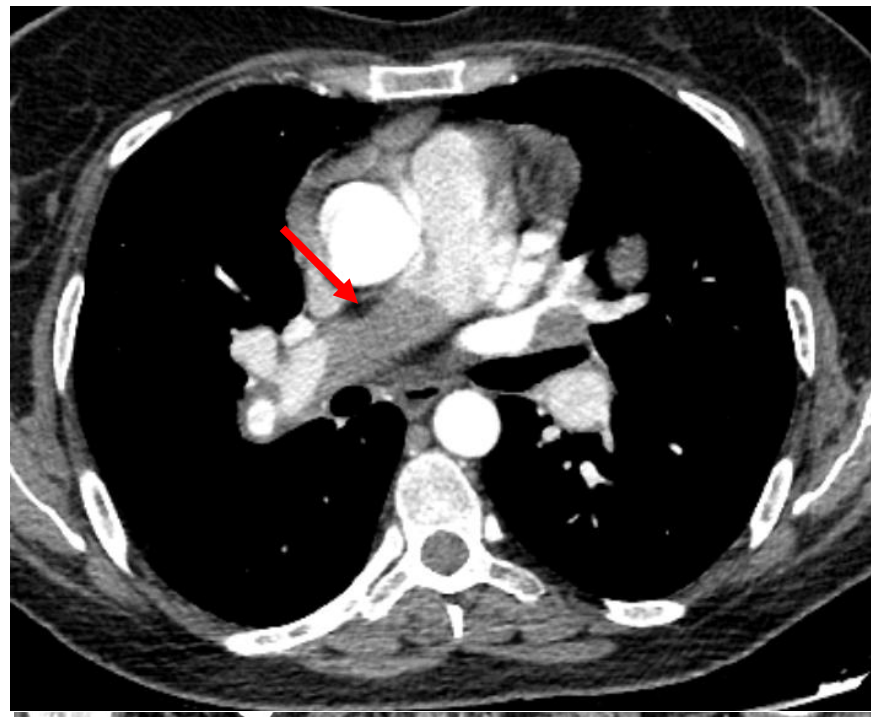
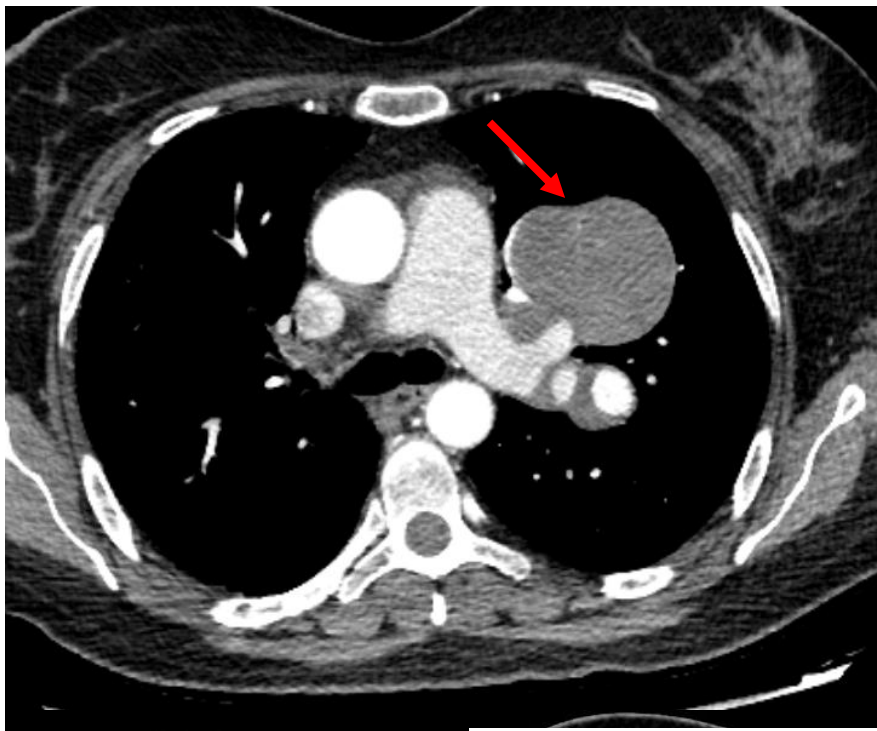
Tümör trombusu



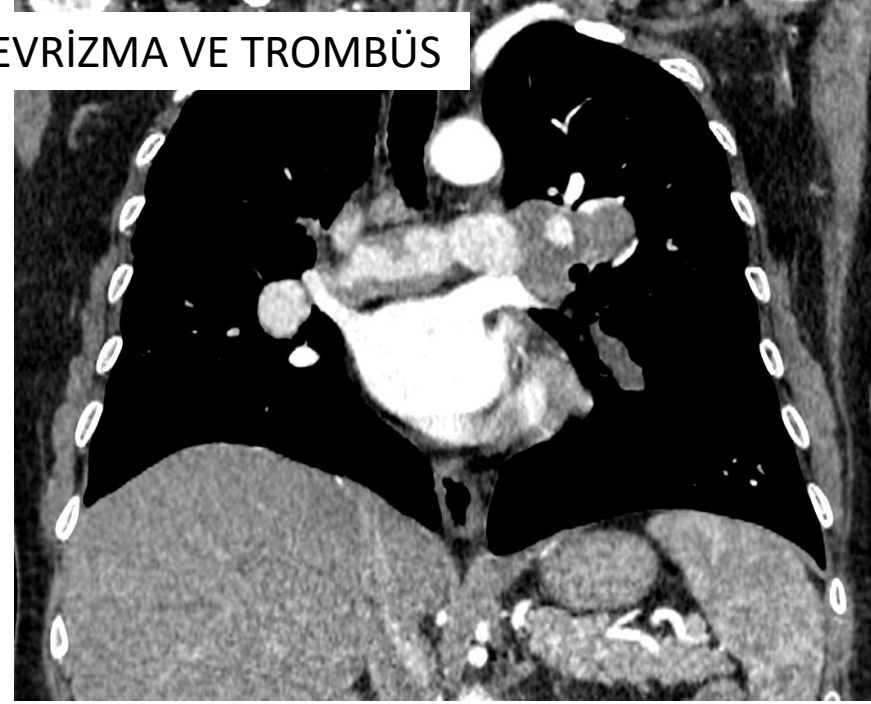
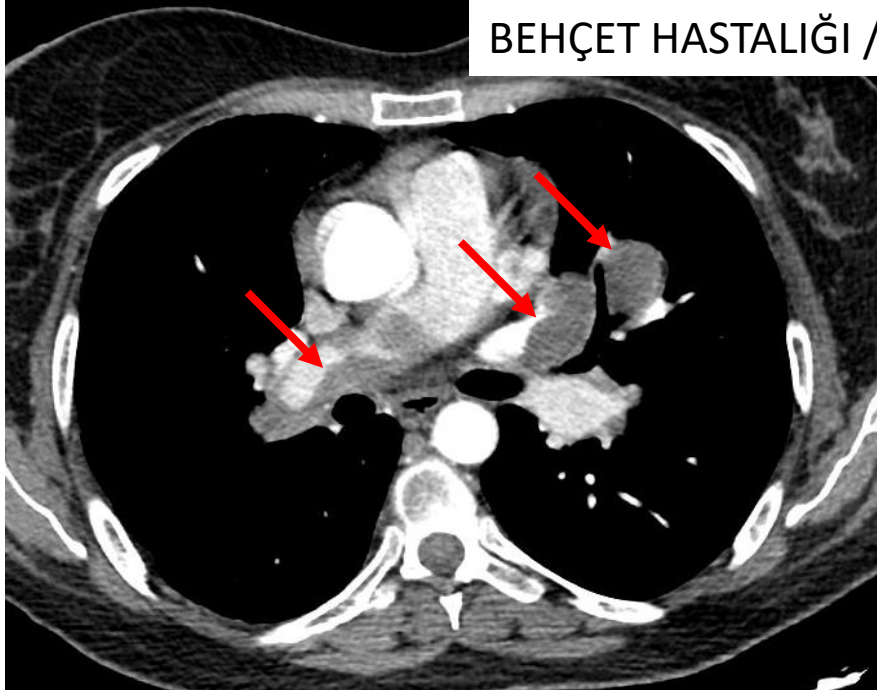
SUVmax: 11.2

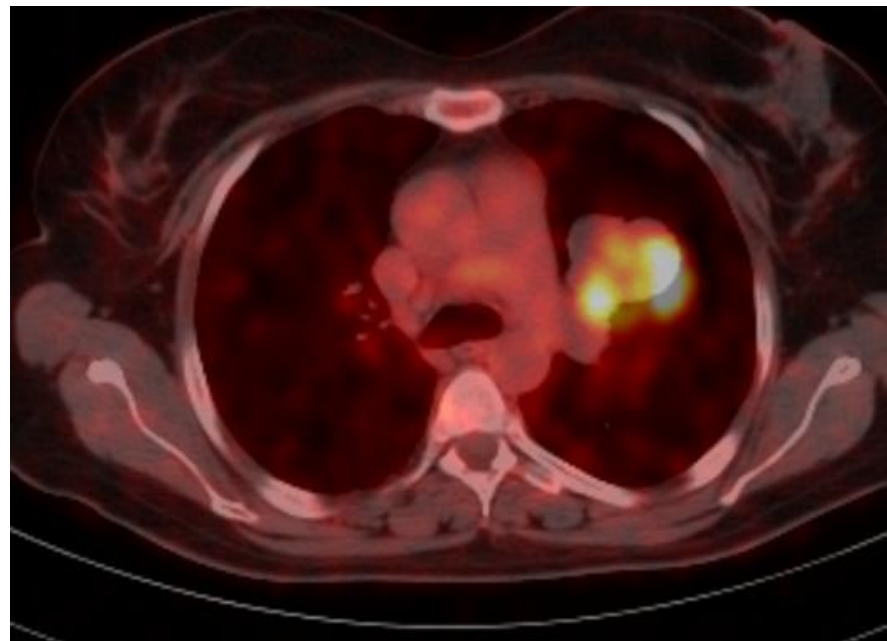
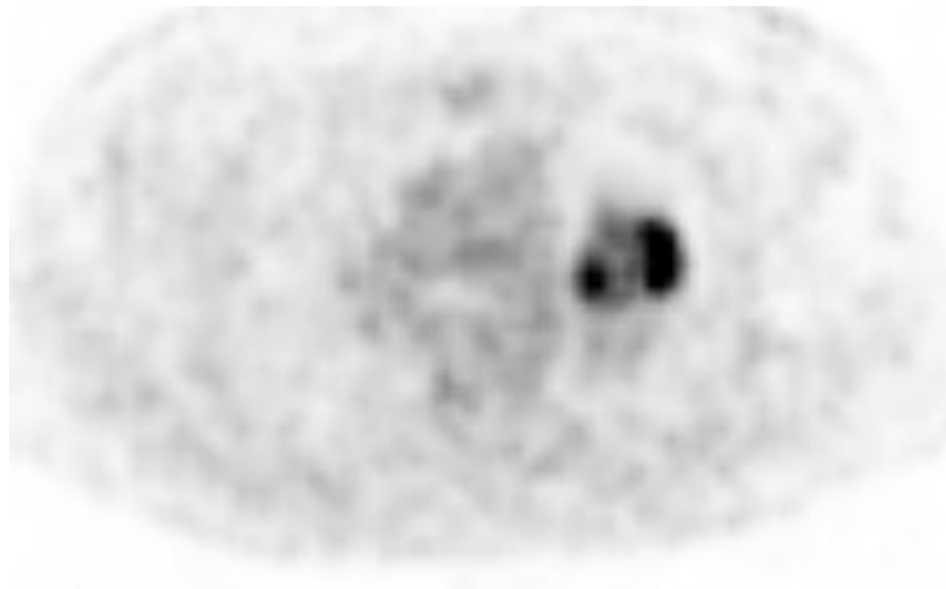
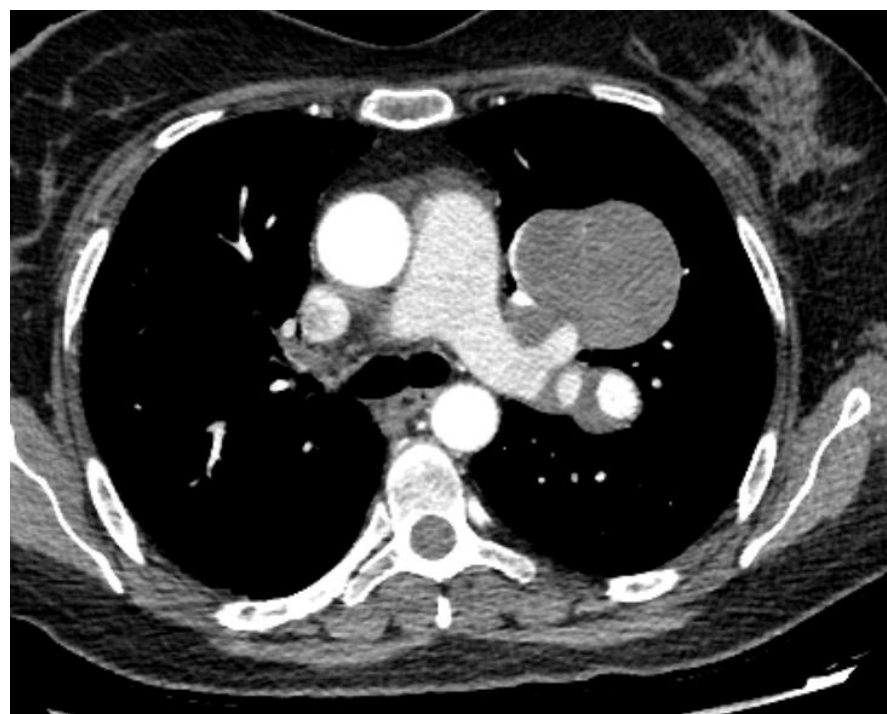
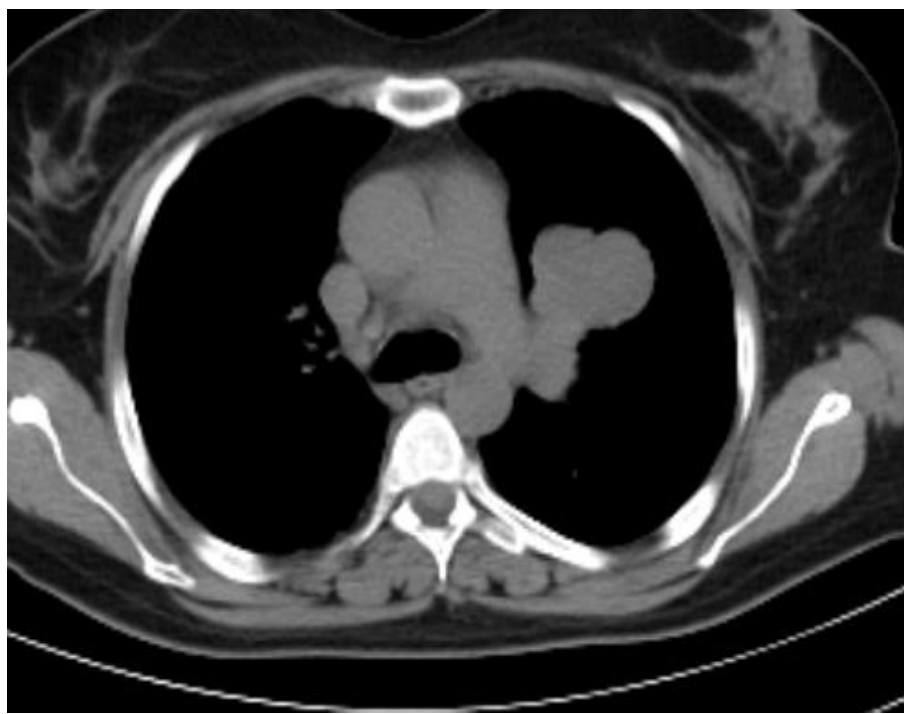
Sol üst lobda malign kitle?  
TTiAB için değerlendirme





BEHÇET HASTALIĞI / ANEVRİZMA VE TROMBÜS





## MESAJ 8

TÜMÖR TROMBÜSÜ VE  
VASKÜLİTE BAĞLI TROMBÜS  
FDG TUTABİLİR VE TEDAVİDE  
ANTİKOAGÜLAN  
KULLANILMAZ



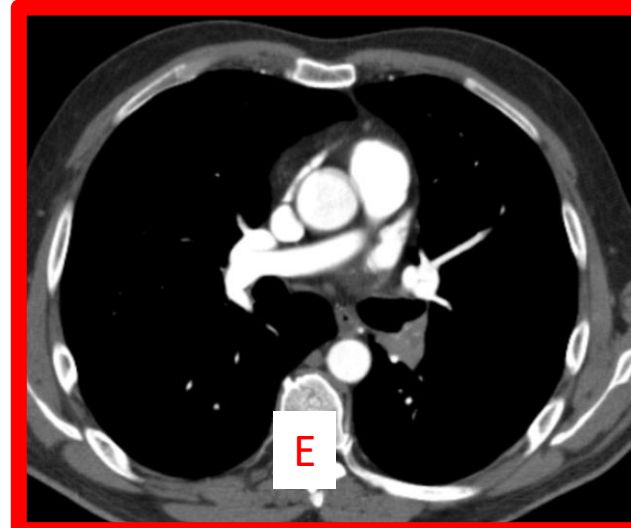
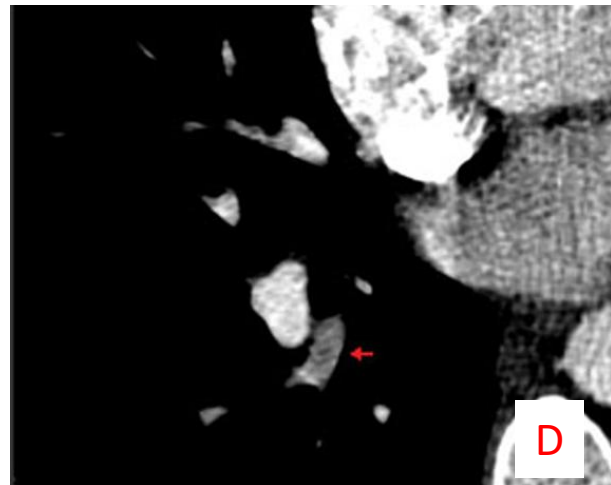
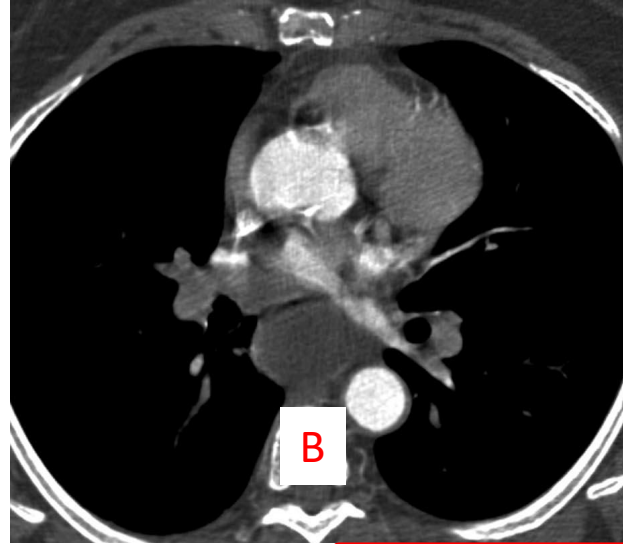
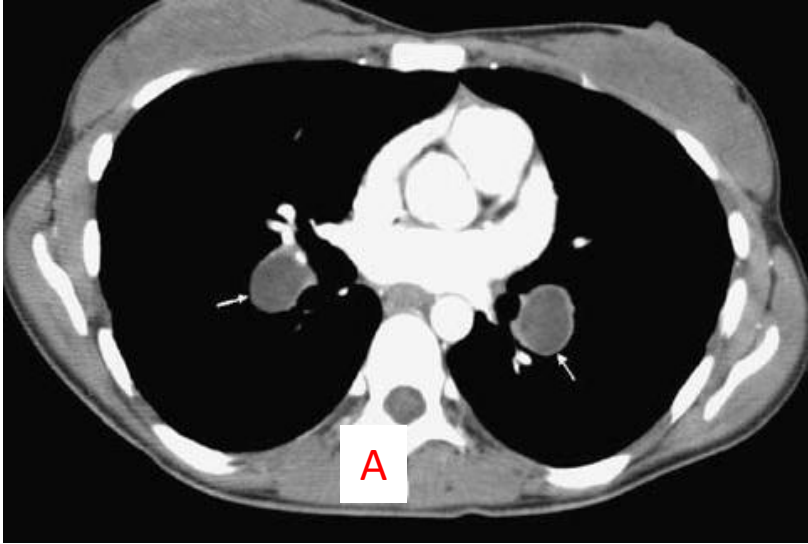
# SONUÇ VE ÖZET:

- PTE' de direk grafi tanıda nonspesifik ancak önemli ipuçları verebilir.
- BT'de ana pulmoner arter dallarında geniş tromboembolilere rağmen infarkt gelişmeyebilir veya parankimal bulgu olmayabilir.
- BT' de iyileşmeyen parankimal konsolidasyonlar progrese oluyorsa emboli ayırıcı tanıda düşünülmelidir.

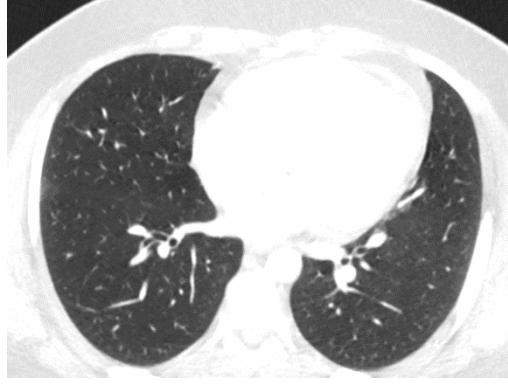
# SONUÇ VE ÖZET:

- Malignite hastalarında pulmoner tromboemboli gelişebileceği unutulmamalıdır.
- **Tümör trombüsü ve vaskülitte bağlı trombüs FDG tutar ve tedavide antikoagülan kullanılmaz (her ikisinde de ana hastalığa yönelik tedavi)**

Hangi görüntü için pulmoner tromboemboli düşünürsünüz ?



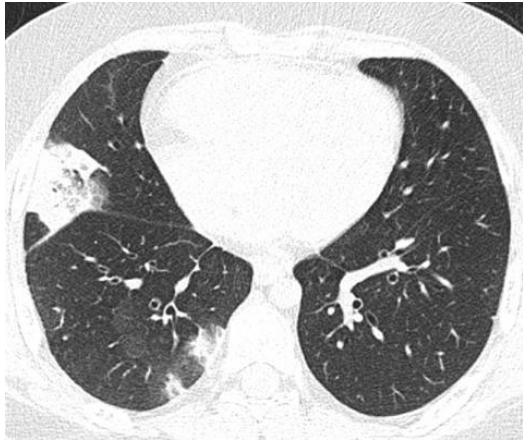
Hangi görüntü için pulmoner tromboemboli düşünmezsiniz ?



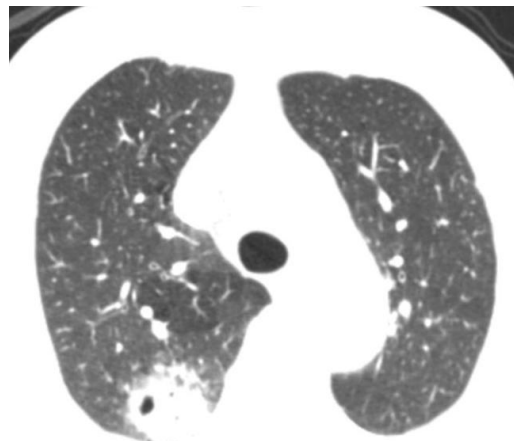
A



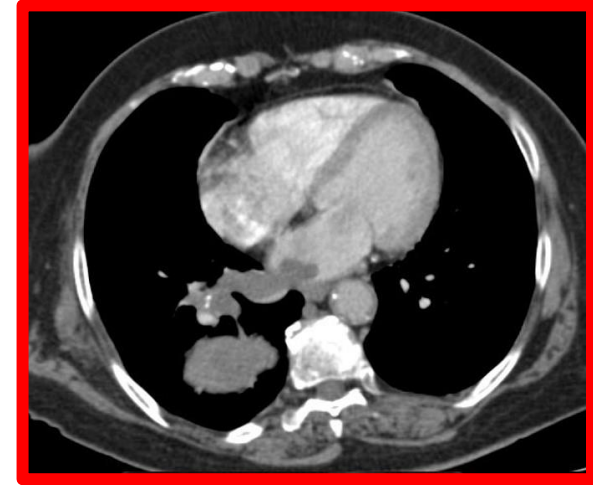
B



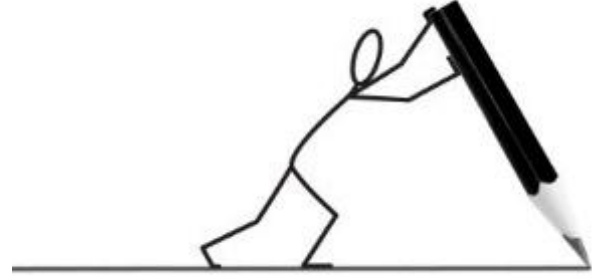
C



D



E



TEŞEKKÜRLER