Bronchoscopic and Surgical Diagnostic Procedures in Fibrotic Lung Diseases

Nuri Tutar, MD

Department of Pulmonology, Faculty of Medicine, Erciyes University



Role of Invasive Diagnostic Procedures in ILD

- Diagnostic probability without invasive methods: **~70%**
- Impact of Tissue Diagnosis:
  - Changes diagnosis in **20% of cases**
  - Increases diagnostic probability by **33%**
  - Alters treatment plan in **34% of cases**

Ryerson et al, AJRCCM 2017
Tomasetti et al, Annals ATS 2022

Diagnostic Invasive Methods

- Bronchoalveolar lavage (BAL)
- Transthorasic biopsy, bronchial biopsy
- Cryo-transbronchial lung biopsy
- Surgical biopsy

Diagnostic Bronchoalveolar Lavage (BAL)

- BAL is a semi-invasive diagnostic method that collects cellular and non-cellular components from distal airways and alveoli with a flexible bronchoscope

These components are

- Interstitial pathologies
- Infectious diseases
- Tuberculosis
- Malignant diseases
- Alveolar filling diseases
- Organic and inorganic dust diseases

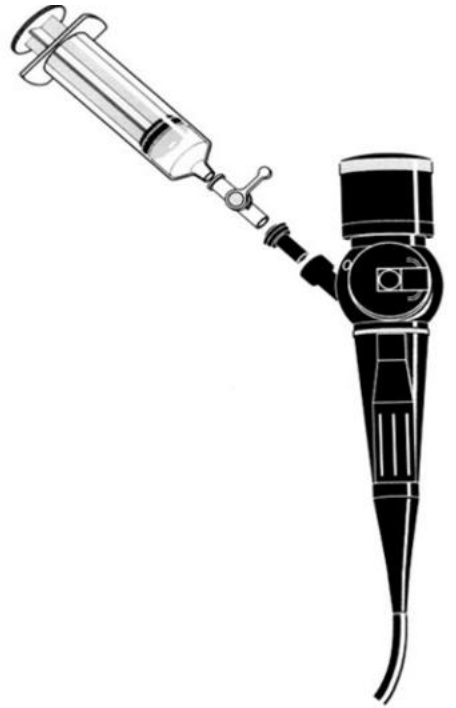

- In diffuse involvement, the bronchoscope is place to the middle lobe and lingula
- In case of localized involvement, the bronchoscope is placed in the relevant segment or subsegment
- A total of **100**-240 ml of sterile saline at body temperature is injected with 20 or 50 ml syringes
- Injected and aspirated through the working channel of the bronchoscope or through a catheter
- At least **30%** of the administered fluid should be taken back

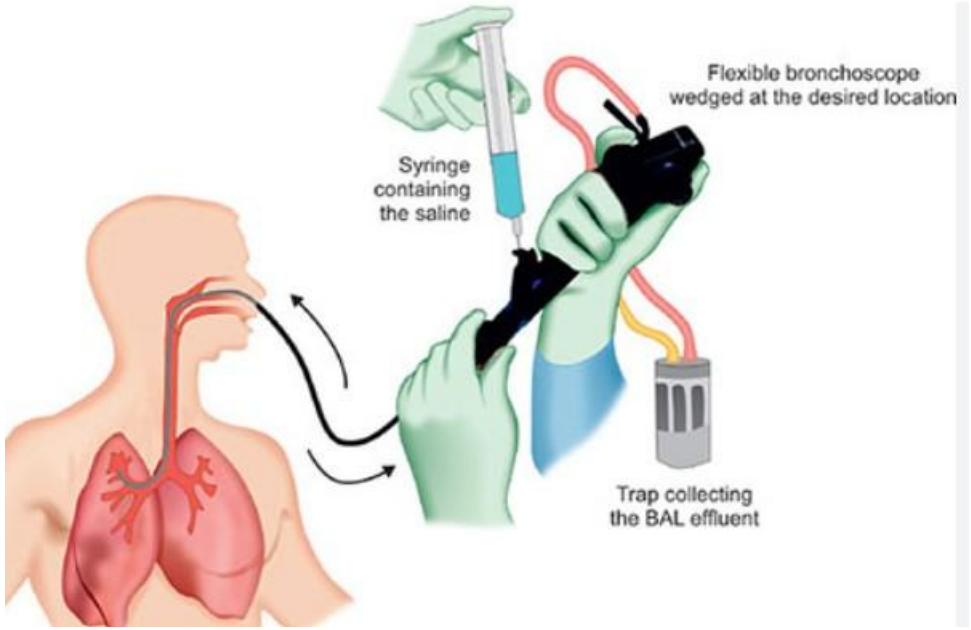

Hogea SP,Expert Rev Respir Med. 2020

BAL Analysis

Cell differential / Cellular profile
Immunocytology (CD4/CD8, CD1)
Cellular morphology
Dust / Mineral particles
Presence of infectious organisms

Normal cellular pattern in BAL

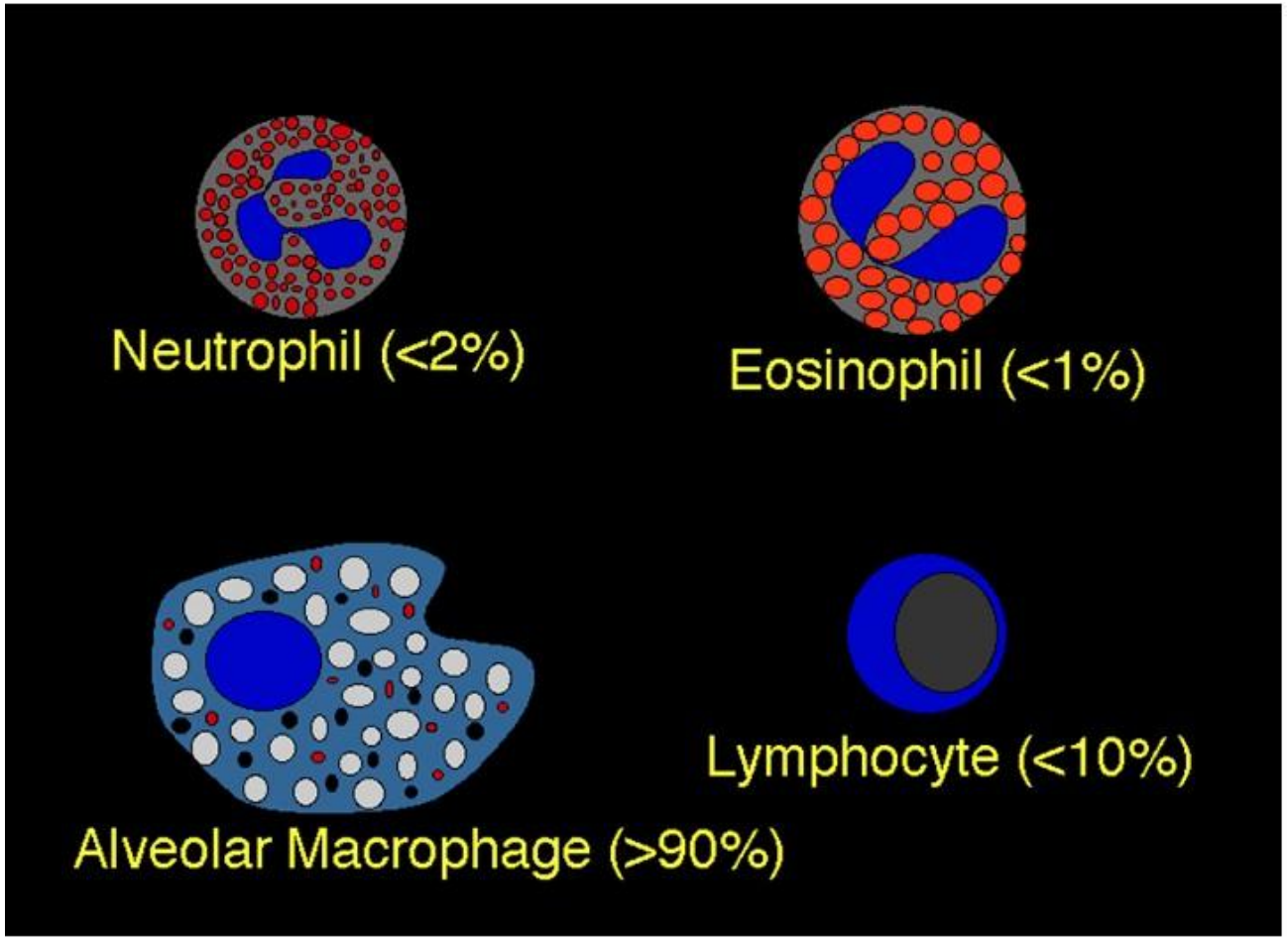

II. Interstitial lung diseases

a. Disorders associated with increased percentage of specific BAL cell types

Lymphocytic cellular pattern	Eosinophilic cellular pattern	Neutrophilic cellular pattern
>15% lymphocytes	>1% eosinophils	>3% neutrophils
Sarcoidosis	Eosinophilic pneumonias	Collagen vascular diseases
Nonspecific interstitial pneumonia (NSIP)	Drug-induced pneumonitis	Idiopathic pulmonary fibrosis
Hypersensitivity pneumonitis	Bone marrow transplant	Aspiration pneumonia
Drug-induced pneumonitis	Asthma, bronchitis	Infection: bacterial, fungal
Collagen vascular diseases	Churg-Strauss syndrome	Bronchitis
Radiation pneumonitis	Allergic bronchopulmonary aspergillosis	Asbestosis
Cryptogenic organizing pneumonia (COP)	Bacterial, fungal, helminthic, *Pneumocystis* infection	Acute respiratory distress syndrome
Lymphoproliferative disorders	Hodgkin's disease	Diffuse alveolar damage (DAD)

CD4/CD8 T lymphocyte ratio in lymphocytic alveolitis and associated diseases

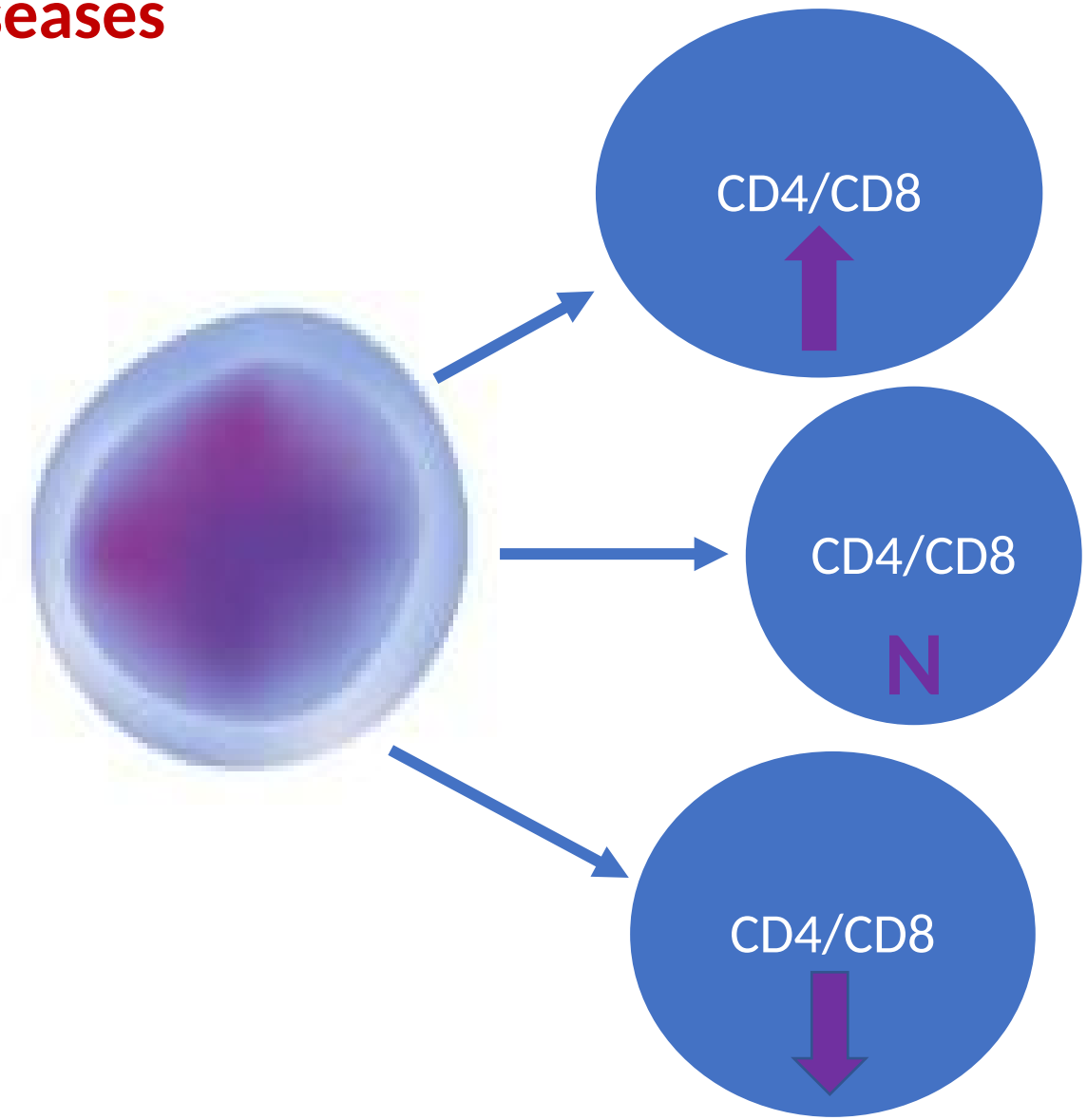

- **Sarcoidosis**
- Beriliosis
- Asbestosis
- Chron disease
- Rheumatoid artiritis

- Tuberculosis
- Lymphangioleiomyomatosis

- Hypersensitivity pneumonitis
- Drug reactions
- Silicosis
- Organising pneumonia
- HIV infection

Transthoracic biopsy

- It is a successful diagnostic method especially in **cryptogenic organizing pneumonia.**
- Diagnostic success of transthoracic biopsy was 87.9% in a study of 108 patients.
- Diagnostic success was 98% when clinical and radiologic findings and biopsy were evaluated.

Lesion with morphologic feature of organizing pneumonia (OP) in CT-guided lung biopsy samples for diagnosis of bronchiolitis obliterans organizing pneumonia (BOOP): a retrospective study of 134 cases in a single center

J Thorac Dis 2014;6(9):1251-1260

- There are case-based studies in pleuroparenchymal fibroelastosis.
- In a 4-case study with 18 G needle
- The diagnosis was made but all 4 cases were ptx and 3 of them had chest tubes.

Insights Imaging (2016) 7:155–162
DOI 10.1007/s13244-015-0448-3

REPORT

Pleuroparenchymal fibroelastosis: role of high-resolution computed tomography (HRCT) and CT-guided transthoracic core lung biopsy

Cátia Esteves[1] · Francisco R. Costa[1] · Margarida T. Redondo[2] · Conceição S. Moura[3,4] ·

Bronchial biopsy

Endobronchial Biopsy for Sarcoidosis*

A Prospective Study

Andrew F. Shorr, MD, MPH; Kenneth G. Torrington, MD, FCCP; and Oleh W. Hnatiuk, MD, FCCP

Study objectives: To determine the yield of endobronchial biopsy (EBB) for suspected sarcoidosis, and to evaluate if EBB increases the diagnostic value of fiberoptic bronchoscopy (FOB) when added to transbronchial biopsy (TBB).
Design: Prospective study of consecutive patients.
Setting: Pulmonary clinic of a tertiary-care, academic medical center.
Patients: Patients consecutively referred for suspected pulmonary sarcoidosis.
Interventions: All patients having FOB performed underwent an evaluation that included history, physical examination, a chest radiograph, and spirometry. During FOB, airway appearance was recorded and both TBB and EBB were performed in a standardized fashion. Six TBB specimens were obtained, as were six EBB samples. For patients with abnormal-appearing airways, four specimens were obtained from the abnormal-appearing airways and two specimens were obtained from the main carina. In patients with normal-appearing airways, four specimens were obtained from a secondary carina and two specimens were obtained from the main carina. A biopsy finding was considered positive if it demonstrated nonnecrotizing granulomas with special stains that were negative for fungal and mycobacterial organisms.
Measurements and results: The study cohort included 34 subjects (mean ± SD age, 37.9 ± 6.8 years; 58.8% were male; 64.7% were African American) EBB findings were positive in 61.8% of patients, while TBB showed nonnecrotizing granulomas in 58.8% of subjects. The addition of EBB increased the yield of FOB by 20.6%. Although EBB findings were more frequently positive in abnormal-appearing airways ($p = 0.014$), EBB provided diagnostic tissue in 30.0% of patients with normal-appearing endobronchial mucosa. There were no complications resulting from the addition of EBB to TBB.
Conclusions: Endobronchial involvement is common in sarcoidosis. EBB has a yield comparable to TBB and can safely increase the diagnostic value of FOB. Pulmonologists should consider routinely performing EBB in cases of suspected sarcoidosis. *(CHEST 2001; 120:109–114)*

Cobblestone Appearence

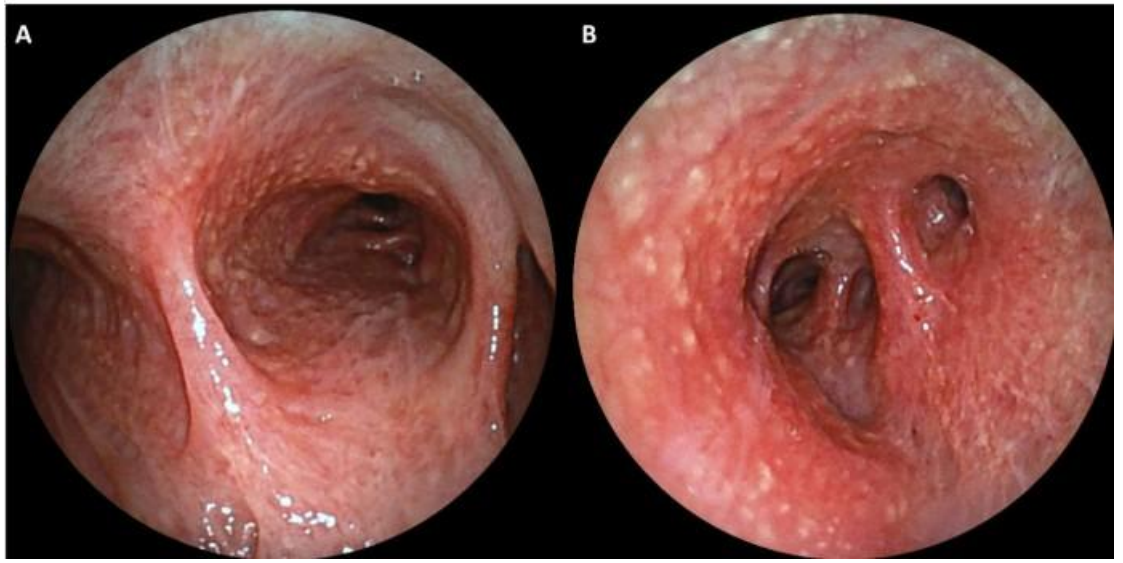

In recent years, it has become an alternative to surgical biopsy with its diagnostic success, which eliminates these disadvantages.

Transbronchial Lung Cryobiopsy



Journal List > Am J Respir Crit Care Med > PMC9851481

American Thoracic Society
Publisher's Version of Article
Issue Featuring Article
Submissions
American Journal of Respiratory and Critical Care Medicine®

Am J Respir Crit Care Med. 2022 May 1; 205(9): e18–e47.
Published online 2022 May 1. doi: 10.1164/rccm.202202-0399ST
PMCID: PMC9851481
PMID: 35486072

Idiopathic Pulmonary Fibrosis (an Update) and Progressive Pulmonary Fibrosis in Adults: An Official ATS/ERS/JRS/ALAT Clinical Practice Guideline

Ganesh Raghu,✉ Martine Remy-Jardin, Luca Richeldi, Carey C. Thomson, Yoshikazu Inoue, Takeshi Johkoh, Michael Kreuter, David A. Lynch, Toby M. Maher, Fernando J. Martinez, Maria Molina-Molina, Jeffrey L. Myers, Andrew G.

We suggest that TBLC be regarded as an acceptable alternative to SLB for making a histopathological diagnosis in patients with ILD of undetermined type in medical centers with experience performing and interpreting TBLC (conditional recommendation, very low quality evidence).

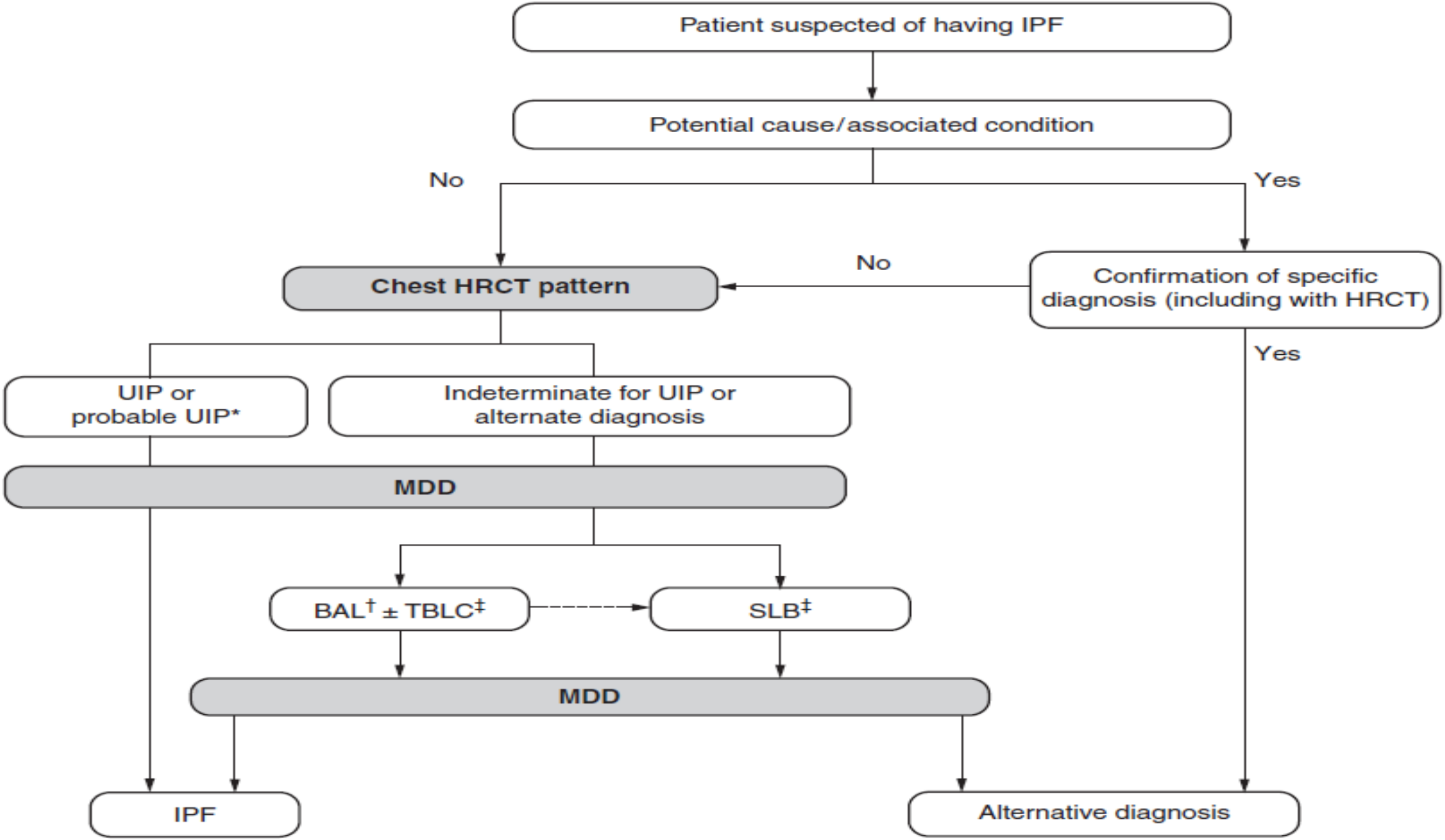
Patient suspected of having IPF
Potential cause/associated condition
No
Yes
Chest HRCT pattern
No
Confirmation of specific diagnosis (including with HRCT)
Yes
UIP or probable UIP*
Indeterminate for UIP or alternate diagnosis
MDD
BAL† ± TBLC‡
SLB‡
MDD
IPF
Alternative diagnosis

Contraindications

- FVC < 50%
- DLCO < 35%
- Moderate or severe pulmonary hypertension (Systolic PAB > 40 mmHg)
- Uncorrectable bleeding risk
- Significant hypoxemia (PaO2,55–60mmHg)
- Tendency to bleeding (INR > 1.5, Platelet count <50.000)
- Cardiac arrhytmia and unstabil angina

EUROPEAN RESPIRATORY journal
FLAGSHIP SCIENTIFIC JOURNAL OF ERS

tice Guideline > Eur Respir J. 2022 Nov 10;60(5):2200425.
. 10.1183/13993003.00425-2022. Print 2022 Nov.

European Respiratory Society guidelines on transbronchial lung cryobiopsy in the diagnosis of interstitial lung diseases

Daniël A Korevaar [1], Sara Colella [2], Markus Fally [3], Juliette Camuset [4], Thomas V Colby [5], Lars Hagmeyer [6 7], Juergen Hetzel [8 9], Fabien Maldonado [10], Antonio Morais [11 12 13], Claudia Ravaglia [14 15], René Spijker [16 17], Sara Tomassetti [15 18], Lauren K Troy [19 20], Johny A Verschakelen [21], Athol U Wells [22 23], Thomy Tonia [24], Jouke T Annema [1 25], Venerino Poletti [26 15 25]

- ***This guideline provides evidence-based clinical practice recommendations on the role of transbronchial lung cryobiopsy in reaching a tissue diagnosis in undiagnosed ILD***

EUROPEAN RESPIRATORY journal
FLAGSHIP SCIENTIFIC JOURNAL OF ERS

1) *Cryo-TBB* is recommended as an **alternative** in patients for whom surgical biopsy is appropriate
2) *Cryo-TBB* is recommended in patients for **whom surgical biopsy is not appropriate**
3) *Surgical biopsy* is recommended as an additional test in patients with **non-diagnostic cryo-TBB results**
4) For or against a second cryo-TBB in patients with a non-diagnostic cryo-TBB result no recommendation is made
5) The bronchoscopist should be trained for cryo-TBB, but no recommendations have been made for the type of training required

Diagnostic accuracy

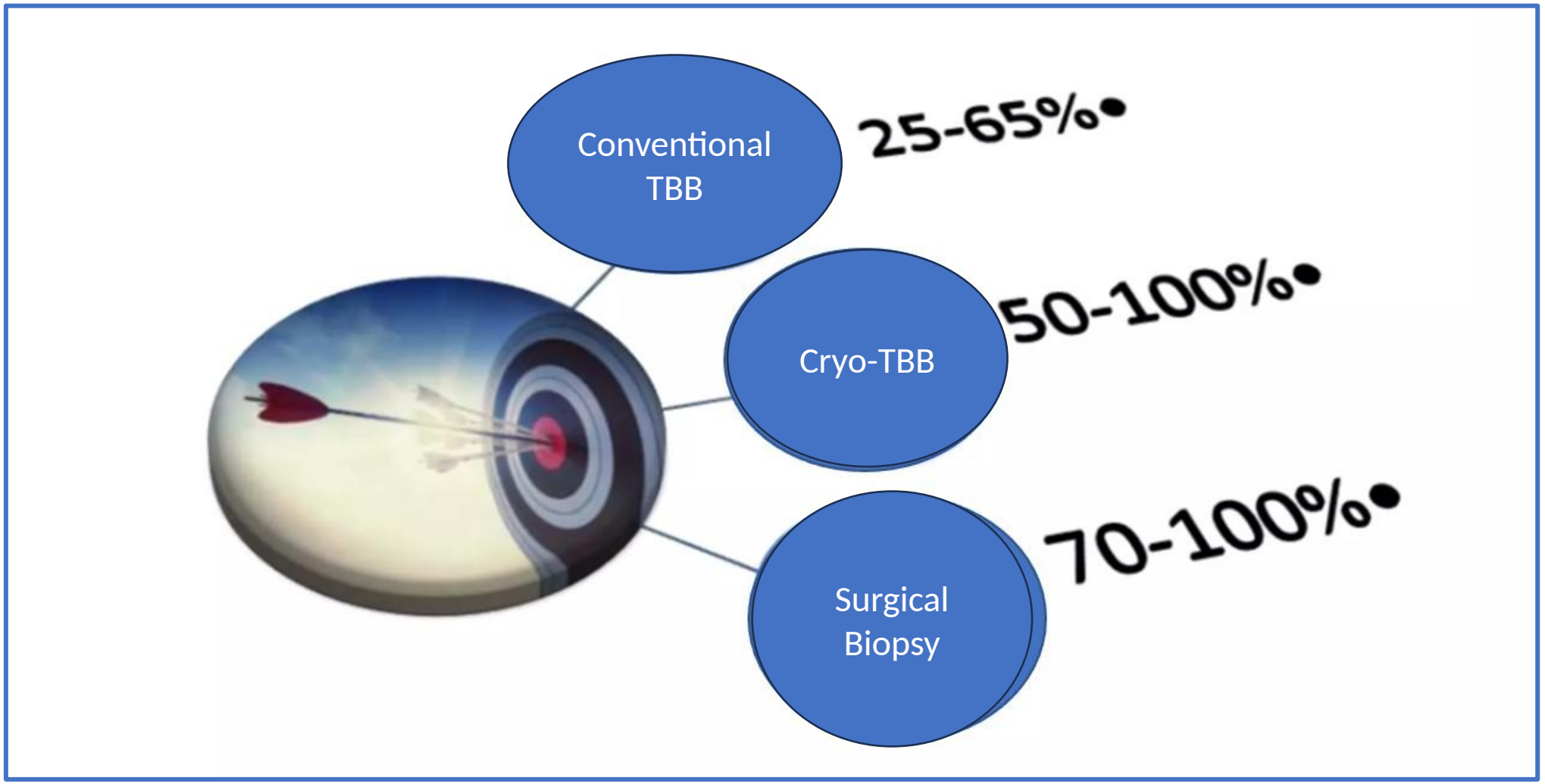

Hetzel, Respiration, 2018

30 Day Mortality

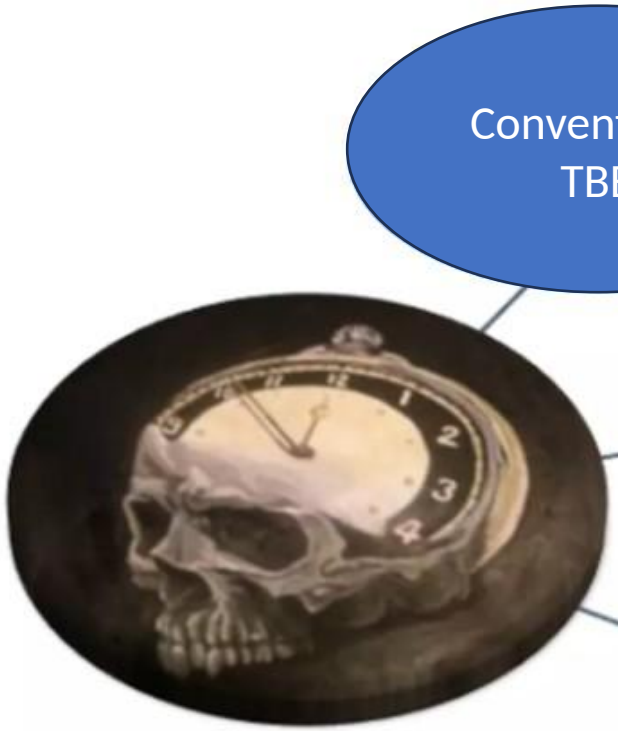

Conventional TBB

0%

Cryo-TBB

<2%

Surgical Biopsy

9%

Hetzel, Respiration, 2018

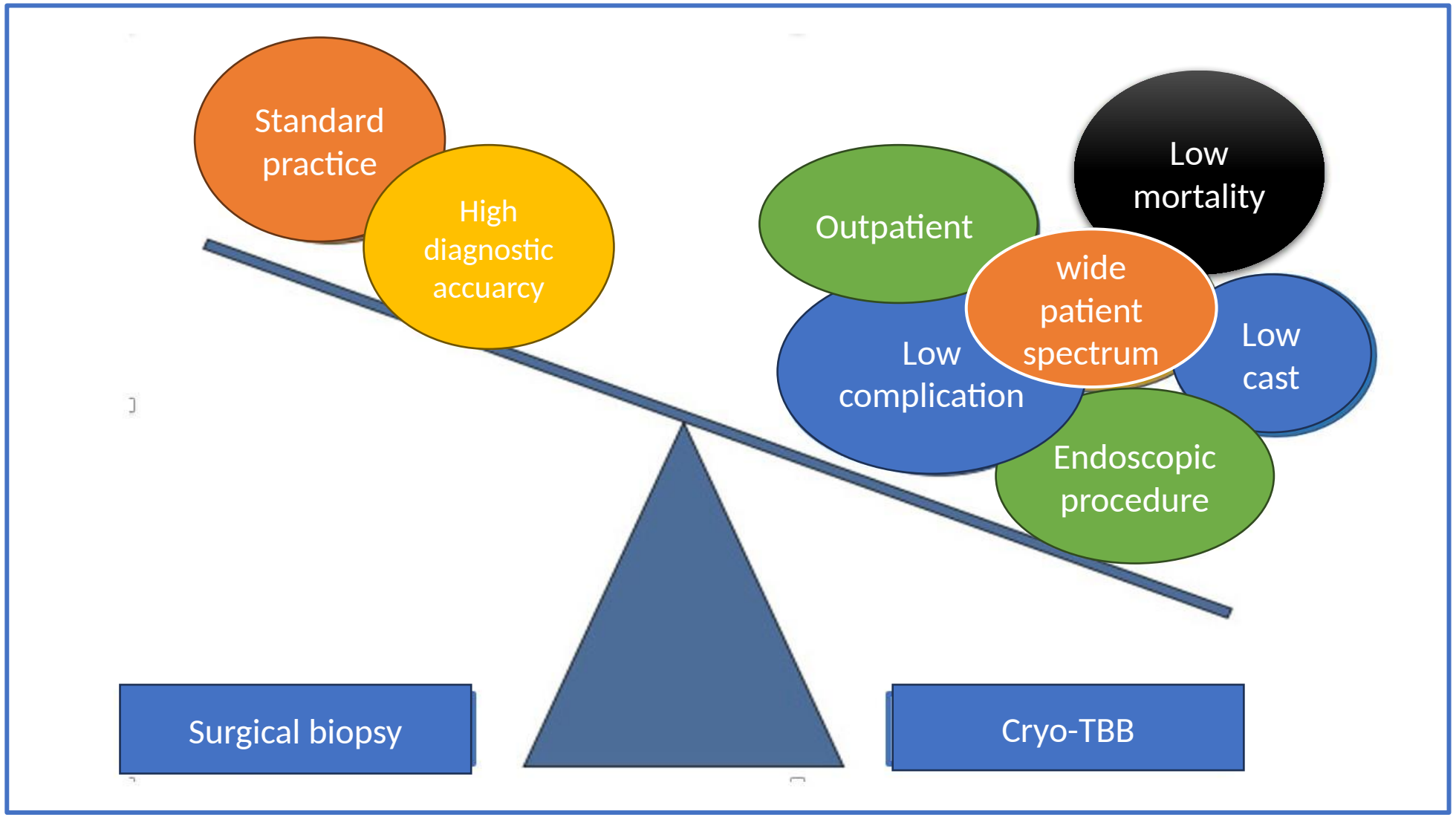
Standard practice
High diagnostic accuarcy
Outpatient
Low mortality
wide patient spectrum
Low complication
Low cast
Endoscopic procedure
Surgical biopsy
Cryo-TBB

Cryo-TBB/Technic

- Under general anestesia
- Rigid scopy

/endotracheal tube

- Scopy??
- Cryoprobe
- Fogarty balloon
- Experienced center

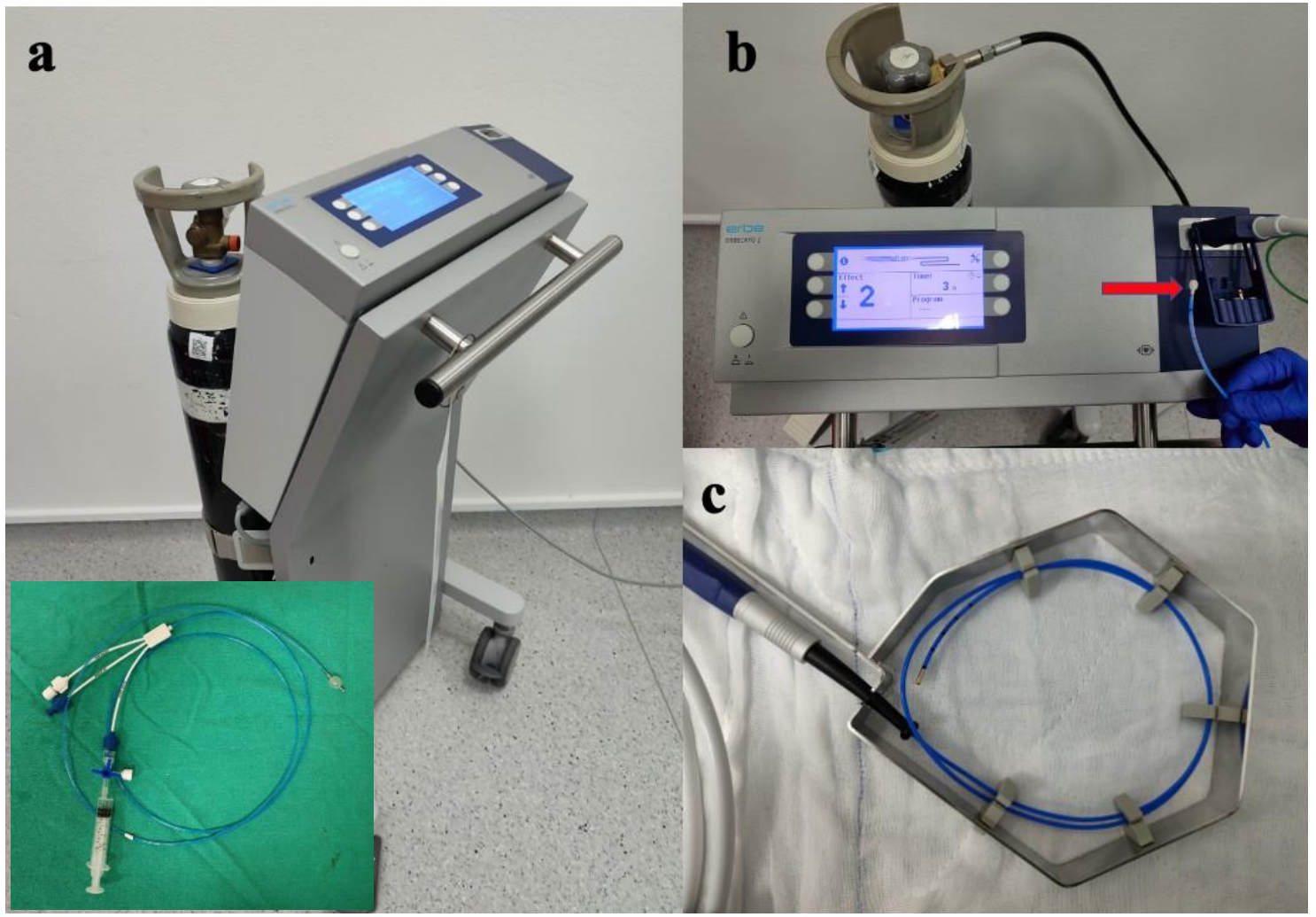


ALM
ID. No :
Sex : Age :
D. O. Birth :
Name :
01/01/96
00:27:40
SCV------1
Comment :

- Cryobiopsy is a method of taking tissue biopsies by freezing
- Gases used Nitrous oxide (-89) or CO2(-79)
- Cryoprobe 1.1 mm, 1.9 mm, 2.4 mm
- Freezing time 3-8 sec
- Number of biopsies 3-6
- Distance of the probe tip from the pleura 10-20 mm

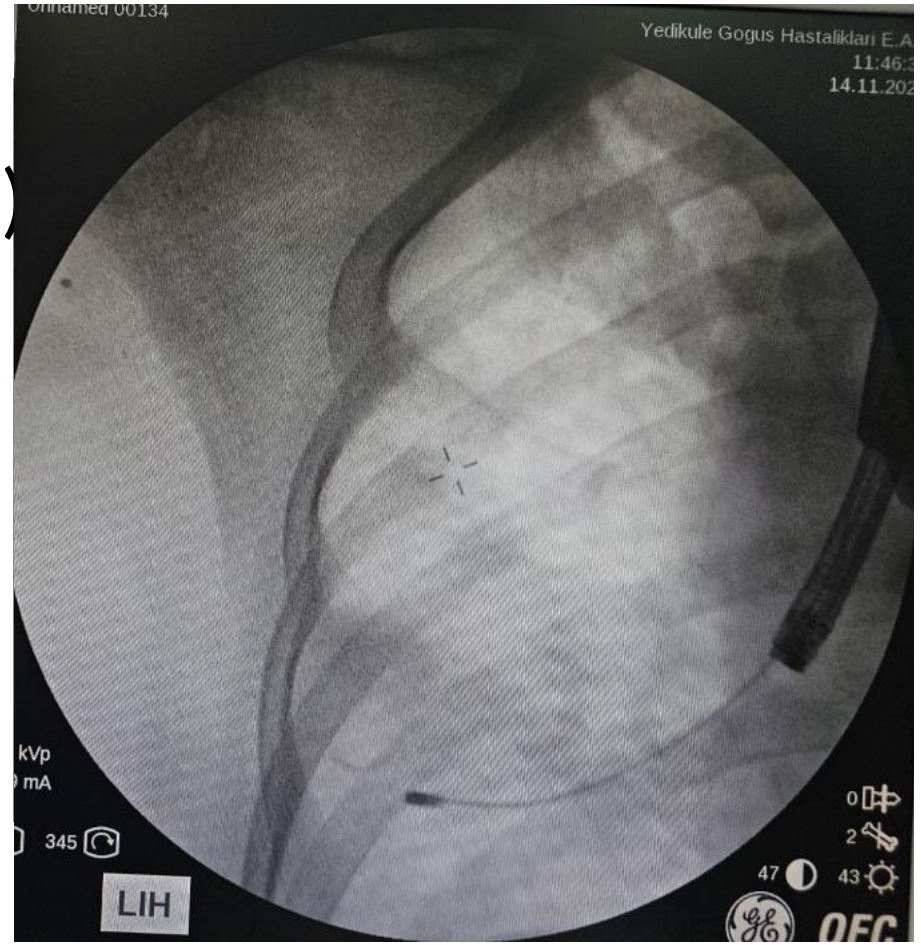

Cryo-TBB

- Diffuse pattern: Lower lob posterior/lateal segm
- Localised pattern: Related segment
- Risk of pneumothorax: Middle lobe / lingula
- Unilateral biopsy: **2 different lobes/segments**
- **Bilateral biopsy is contraindicated!!!**
- 2 or more biopsies have high diagnostic success

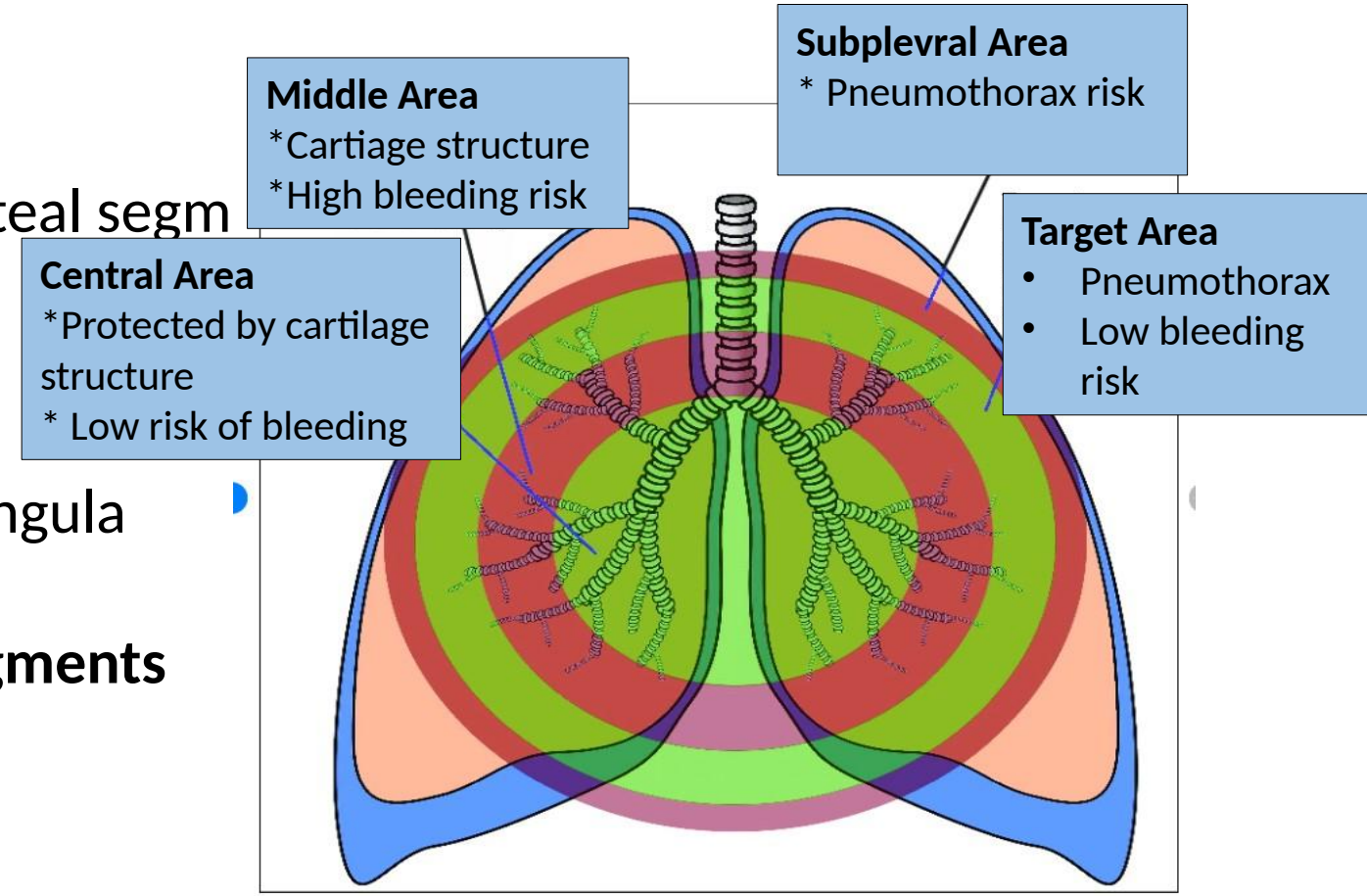

Ravaglia, Respiration 2017
Hetzel, Respiration 2018

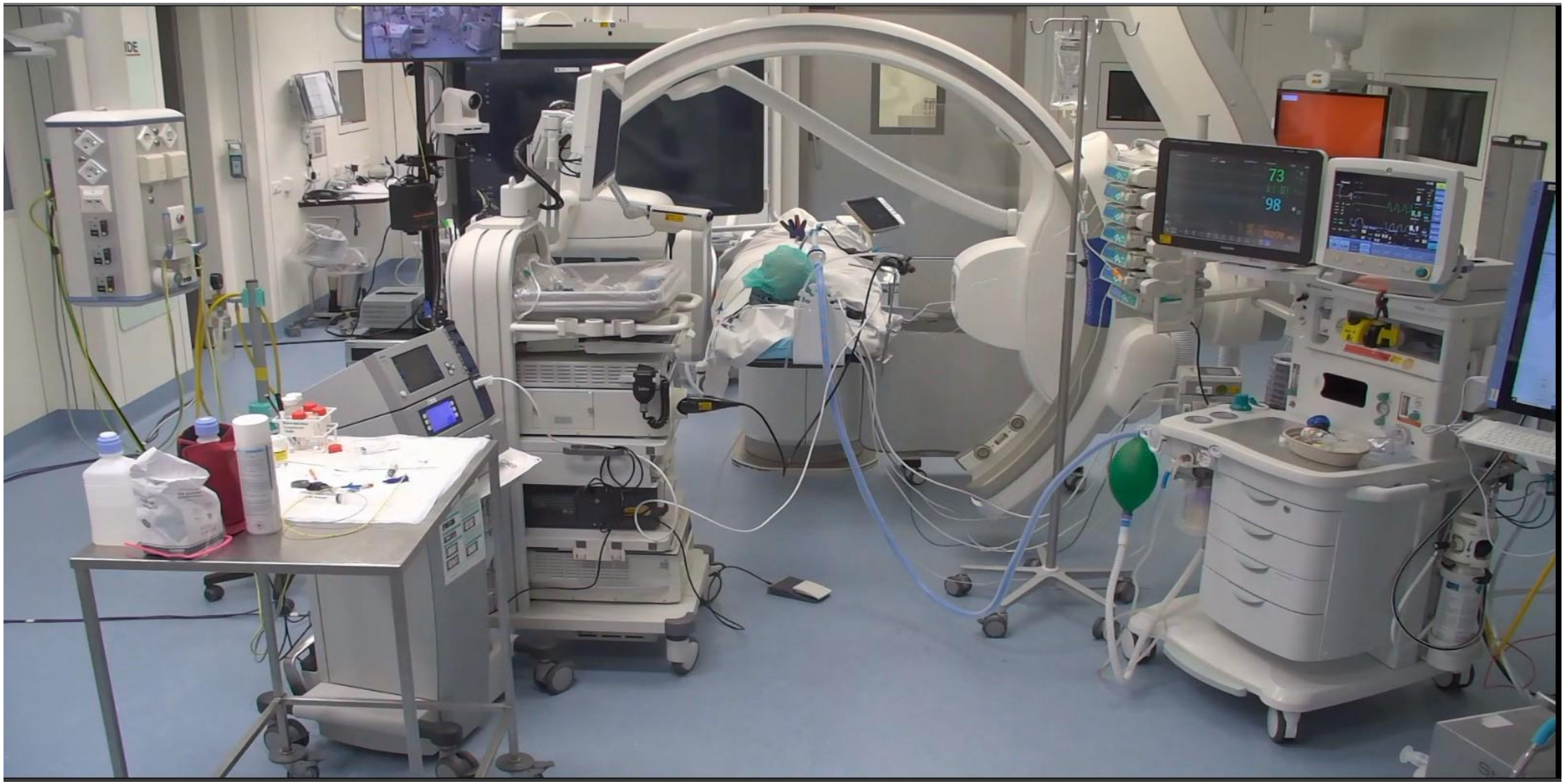
73
98



› Sarcoidosis Vasc Diffuse Lung Dis. 2021;38(1):e2021004. doi: 10.36141/svdld.v38i1.11029.
Epub 2021 Mar 31.

Transbronchial cryobiopsy for diagnosing parenchymal lung diseases: real-life experience from a tertiary referral center

Demet Turan [1], Efsun Gonca Uğur Chousein [1], Aysu Sinem Koç [2], Mustafa Çörtük [1], Zeynep Yıldırım [1], Bariş Demirkol [1], Mehmet Akif Özgül [1], Halit Çınarka [1], Neslihan Akalın [3], Aytül Hande Yardımcı [4], Erdoğan Çetinkaya [1]

	Overall diagnostic yield (%)	1-2 biopsy	(diagnostic yield)	(n=31)	3 biopsy (diagnostic yield) (n=116)	p value*
Pathological diagnosis	66.6	20 (64.51%)			78 (67.2%)	0.995
		1 biopsy (n=10) 5 (50%)	2 biopsy (n=21) 15 (71.4%)	p=0.244*		
Diagnosis with Multidisciplinary comittee	74.1	23 (74.1%)			86 (74.1%)	0.775
		1 biopsy (n=10) 5 (50%)	2 biopsy (n=21) 18 (85.7%)	p=0.034*		

Complications	n (%)
Pneumothorax	23/147 (total)
Oxygen therapy	9 (39.1)
Tube Thoracostomy	14 (60.9)
Hemorrhage	Grade 1: 28/147 (19) Grade 2: 19/147 (12.9) Grade 3: 0/147
Respiratory failure	3/147 (2.0)
Mortality within 30 days	1/147 (0.7)
Length of Hospital stay	
Discharged same day	114 (77.5)
Discharged next day	
1-3 days	33/147 (22.4)
>4 days	
Hospital stay (mean days±SD)	15/33 (45.5)
	18/33 (54.5)
	4.3±2.8

Transbronchial cryobiopsy followed by as-needed surgical lung biopsy versus immediate surgical lung biopsy for diagnosing interstitial lung disease (the COLD study): a randomised controlled trial

Kirsten A Kalverda, Maarten K Ninaber, Lizzy Wijmans, Jan von der Thüsen, René E Jonkers, Johannes M Daniels, Jelle R Miedema, Chris Dickhoff, Jürgen Hölters, David Heineman, Merijn Kant, Teodora Radonic, Ghada Shahin, Danielle Cohen, Bart Boerrigter, Suzan Nijman, Esther Nossent, Jerry Braun, Bas Mathot, Venerino Poletti, Jürgen Hetzel, Marcel Dijkgraaf, Daniel A Korevaar, Peter I Bonta, Jouke T Annema

Lancet Respir Med 2024

Published Online
April 16, 2024
https://doi.org/10.1016/S2213-2600(24)00074-2

- The COLD study was a multicentre, randomised controlled trial in six hospitals across the Netherlands. They included patients with ILD with an indication for lung biopsy as assessed by a multidisciplinary team discussion.
- Patients were randomly assigned in a 1:1 ratio to the step-up or immediate SLB strategy, with follow-up for 12 weeks from the initial procedure.

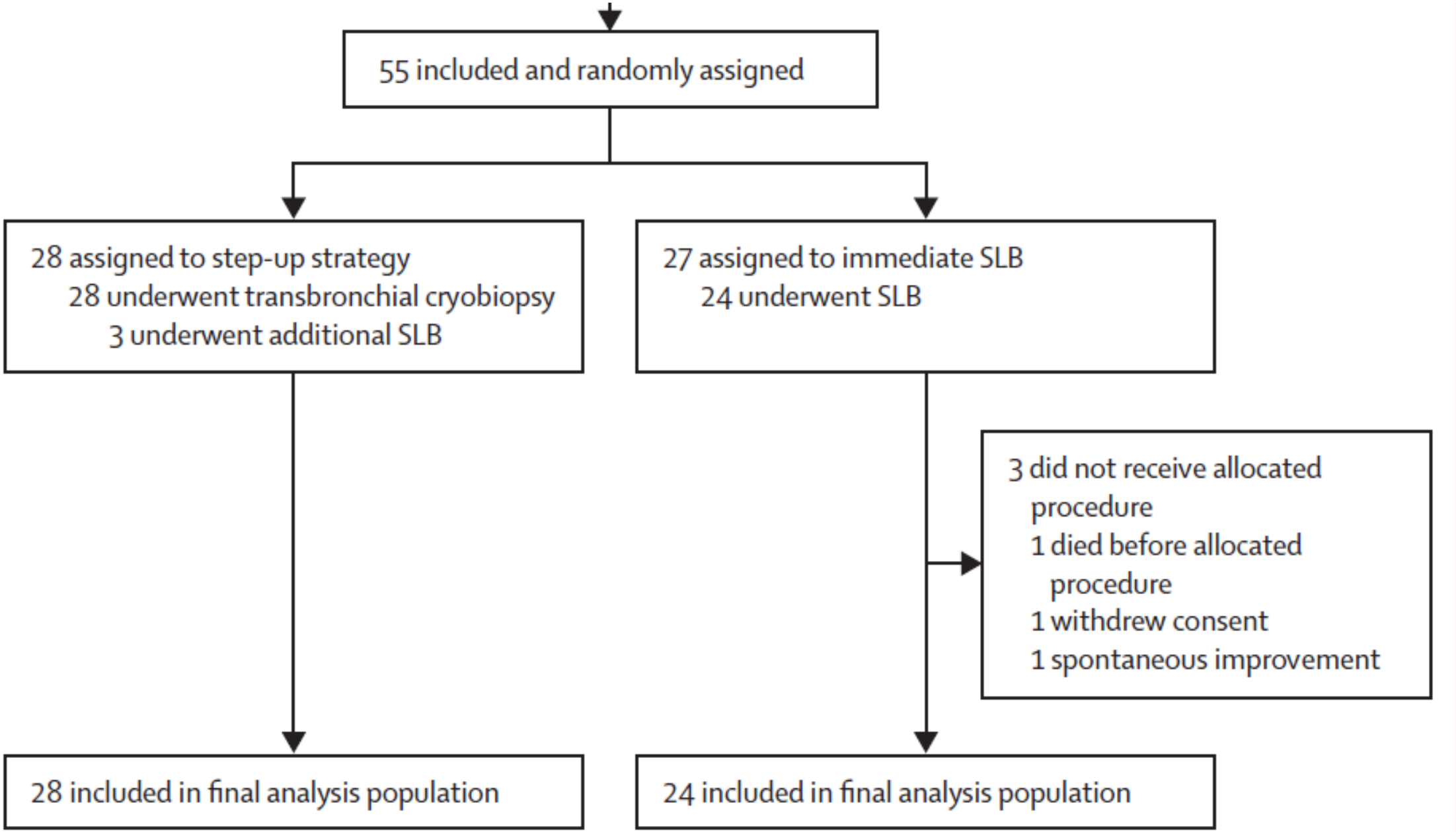
55 included and randomly assigned
28 assigned to step-up strategy
28 underwent transbronchial cryobiopsy
3 underwent additional SLB
27 assigned to immediate SLB
24 underwent SLB
3 did not receive allocated procedure
1 died before allocated procedure
1 withdrew consent
1 spontaneous improvement
28 included in final analysis population
24 included in final analysis population

	Step-up strategy (n=28)	Immediate SLB (n=24)	p value
Diagnostic yield	89% (73–96)	88% (69–97)	0·841
Diagnostic yield after transbronchial cryobiopsy alone	82% (64–92)	..	..
Total need for a chest tube	4 (14%)	24 (100%)	<0·0001
After transbronchial cryobiopsy	1 (4%)	..	..
After SLB	3 (11%)	24 (100%)	..
Unexpected chest tube*	3 (11%)	11 (46%)	0·0058
After transbronchial cryobiopsy	1 (4%)	..	..
After SLB	2 (7%)	11 (46%)	..
Chest tube in situ			
<24 h	1 (4%)	13 (54%)	..
24–36 h	2 (7%)	7 (29%)	..
36–48 h	0	1 (4%)	..
>48 h	1 (4%)	3 (13%)	..
Total in-hospital stay	1 (1–1)	5 (4–6)	<0·0001
Completed visual analogue scale pain score on day 1	25 (89%)	20 (83%)	..
Visual analogue scale	15 (0–38)	45 (21–50)	0·0057

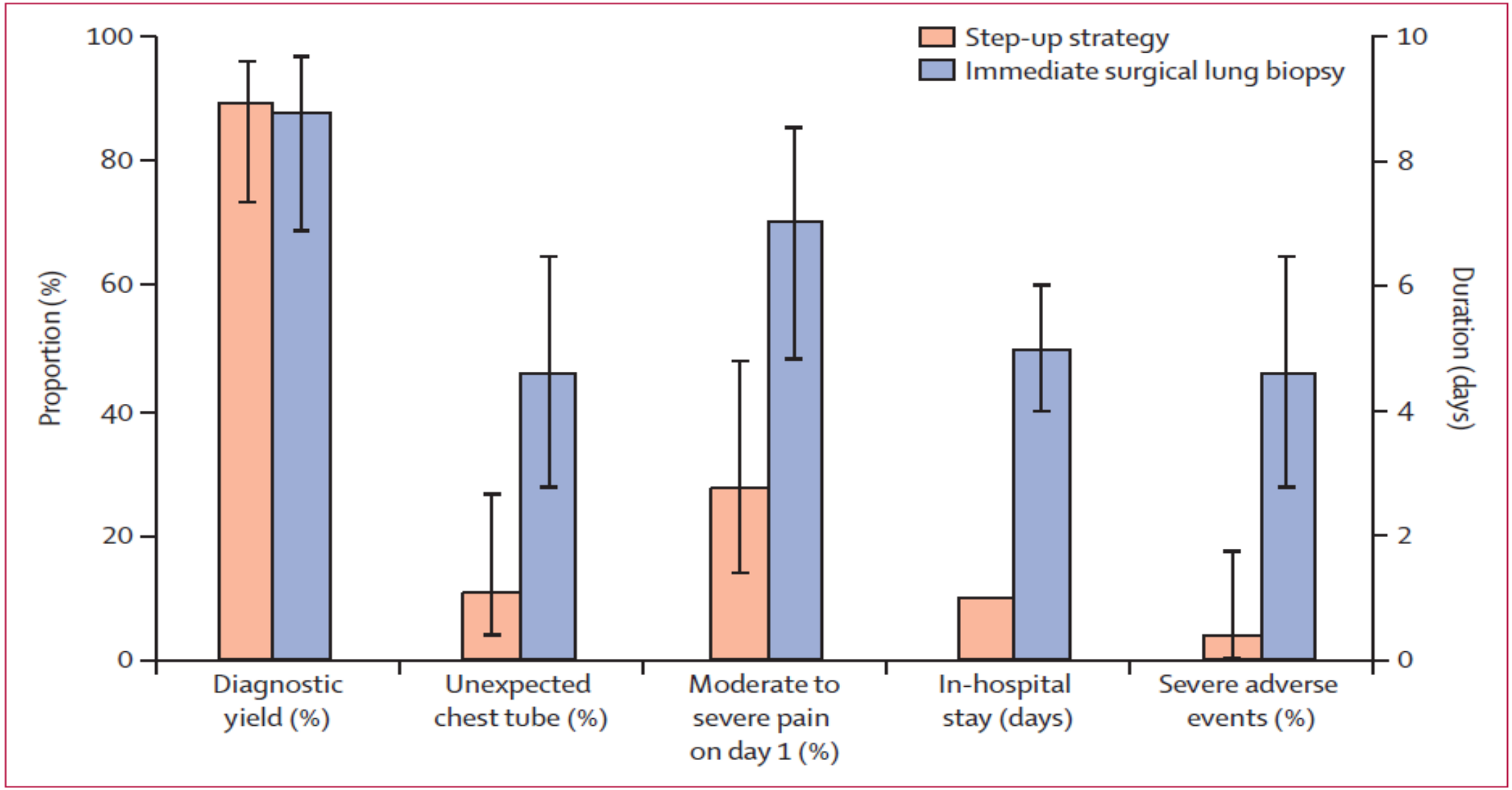

Figure 2: **Primary and secondary endpoints**

Yield and safety of different biopsy types in interstitial lung disease: a systematic review and meta-analysis

Elad Mor [1,2,3], Luca Alessandro Belmonte[4], Mauro Degrassi[4], Daniel-Costin Marinescu[1,5] and Christopher J. Ryerson[1]

[1]Department of Medicine and Centre for Heart Lung Innovation, University of British Columbia, Vancouver, BC, Canada. [2]Pulmonary Institute, Rambam Health Care Campus, Haifa, Israel. [3]Ruth and Bruce Rappaport Faculty of Medicine, The Technion - Israel Institute of Technology, Haifa, Israel. [4]Respiratory Unit, ASST Santi Paolo e Carlo, Milan, Italy. [5]Centre for Lung Health, Vancouver General Hospital, Vancouver, BC, Canada.

Corresponding author: Christopher J. Ryerson (Chris.Ryerson@hli.ubc.ca)

Check for updates

Shareable abstract (@ERSpublications)
Multidisciplinary yield of TBLC and SLB is equivalent, with both offering an acceptable safety profile and potentially lower procedural burden for TBLC. Decision for the initial diagnostic tool should be based on patient–physician shared decision-making. https://bit.ly/4rWr1p3

Cite this article as: Mor E, Belmonte LA, Degrassi M, *et al*. Yield and safety of different biopsy types in interstitial lung disease: a systematic review and meta-analysis. *Eur Respir Rev* 2026; 35: 260044 [DOI: 10.1183/16000617.0044-2026].

TABLE 2 Lung biopsy outcomes in all studies and limited to those comprising ⩾80% fibrotic interstitial lung disease (ILD)

Biopsy method	Multidisciplinary yield	Histopathologic yield	Severe bleeding	Clinically relevant bleeding	PTX	PTX requiring chest drainage	AE-ILD	Pneumonia	30-day mortality
TBB									
All ILD	35.3%	49.8%	0%	6.3%	2.9%	1.1%	0%[#]	NR	0%[#]
Fibrotic ILD	12.5%[#]	34.4%	0%	6.2%[#]	9.2%[#]	2.0%[#]	NR	NR	NR
TBLC									
All ILD	84.3%	78.7%	0.6%	17.3%	8.1%	4.3%	0.6%	1.2%	0.8%
Fibrotic ILD	87.6%	85.7%	0.5%	18.2%	11.9%	7.5%	1.0%	2.1%	1.1%
SLB									
All ILD	88.6%	95.6%	NA	NA	NA	NA	1.9%	2.7%	0.8%
Fibrotic ILD	87.3%	98.4%	NA	NA	NA	NA	1.9%	2.5%	0.1%

AE: acute exacerbation; NA: not applicable; NR: not reported; PTX: pneumothorax; SLB: surgical lung biopsy; TBB: transbronchial biopsy; TBLC: transbronchial lung cryobiopsy. [#]: Fewer than five studies reported this outcome.

Conclusions

- BAL processing appears to be helpful in the diagnosis of **hypersensitivity pneumonitis or sarcoidosis**.
- TTLB can be used to diagnose **COP and pleuroparenchymal fibroelastosis.**
- TBBx is **not** a very successful method for diagnosing ILD.
- TB Cryobiopsy seems to be the **most successful** method in the diagnosis of ILD when the profit-loss ratio is evaluated.
- In the light of these informations, VATS biopsy should be used in cases **where cryobiopsy is not diagnostic.**

Case

- 50-year-old male, religious official
- Presenting with cough
- No history of exposure to birds, pigeons, or occupational agents
- Non-smoker
- No underlying comorbidities
- Visual impairment (+)
- External center CT

20.11.2023

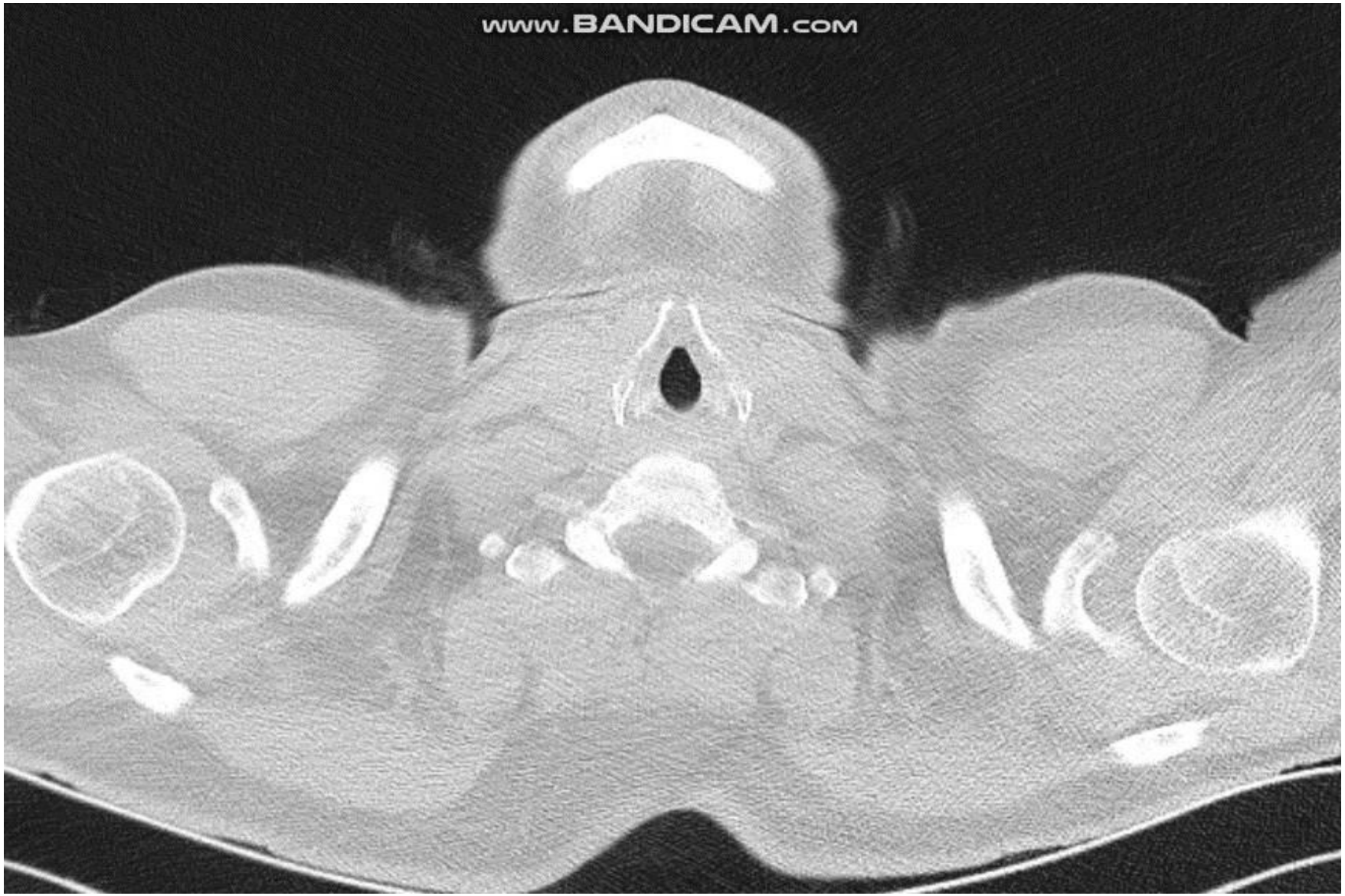

- Crp, sedim, tit results were normal,
- Connective tissue markers were negative,
- ACE negative
- Bronchoscopy was performed

Numune Türü	Tetkik Istem Zamanı	29.01.2024 11:30	Numune Kabul Zamanı	29.01.2024 13:05
	Numune Alma Zamanı	29.01.2024 11:30	Uzman Onay Zamanı	05.02.2024 11:16
Eski Biyopsi No	B-8324-2025, S-856-2024, B-14182-2024,			

KLİNİK BİLGİ:

BT DE İAH? OLAN HASTAYA SAĞ AKCİĞER ALT LOB POSTEROBAZALDEN TBBX ALINDI.

MAKROSKOPİ:

Biyopsi kayıtlı tüpte gönderilen büyüğü 0,3x0,3x0,3 cm küçüğü 0,1x0,1x0,1 cm ölçülerinde toplam 12 adet dokuların tamamı AC1,2,2 kasette takibe alındı. fs/ sd

TANI (ICD-O kodları)

BRONŞ EPİTEL DOKULARI, BRONŞ BİYOPSİSİ, SAĞ AKCİĞER TRANSBRONŞİAL BİYOPSİSİ

ARŞ.GÖR.SEVİL DEMİRAY

Dipl Tescil No 194291

PROF. DR.OLGUN KONTAŞ

Dipl Tescil No 37872

CD4/CD8= 0.75

Numune Türü	Tetkik Istem Zamanı	29.01.2024 11:33	Numune Kabul Zamanı	29.01.2024 13:07
	Numune Alma Zamanı	29.01.2024 11:33	Uzman Onay Zamanı	31.01.2024 15:25
Eski Biyopsi No	B-8324-2025, B-14182-2024, B-2267-2024,			

KLİNİK BİLGİ:

SAĞ ALT LOB POSTEROBAZALDEN 10 ADET TBBX ALINDI. LAVAJ YAPILDI.

MAKROSKOPİ:

20ML KIRMIZI

MİKROSKOPİ:

Sitolojik incelemede, periferik kan elemanları ile kaplı zeminde lenfositler, makrofajlar bronş epitel hücreleri izlendi.

TANI (ICD-O kodları)

CLASS II, BRONKOALVEOLER LAVAJ

ARŞ.GÖR.SEVİL DEMİRAY

Dipl Tescil No 194291

PROF. DR.OLGUN KONTAŞ

Dipl Tescil No 37872

- Alveolar sarcoidosis? COP??
- Rheumatology consultation: Normal findings
- Methylprednisolone: 32 mg for 2 weeks, 24 mg for 2 weeks, 16 mg for 1 month, then 8 mg
- Follow-up CT after 3 months of treatment

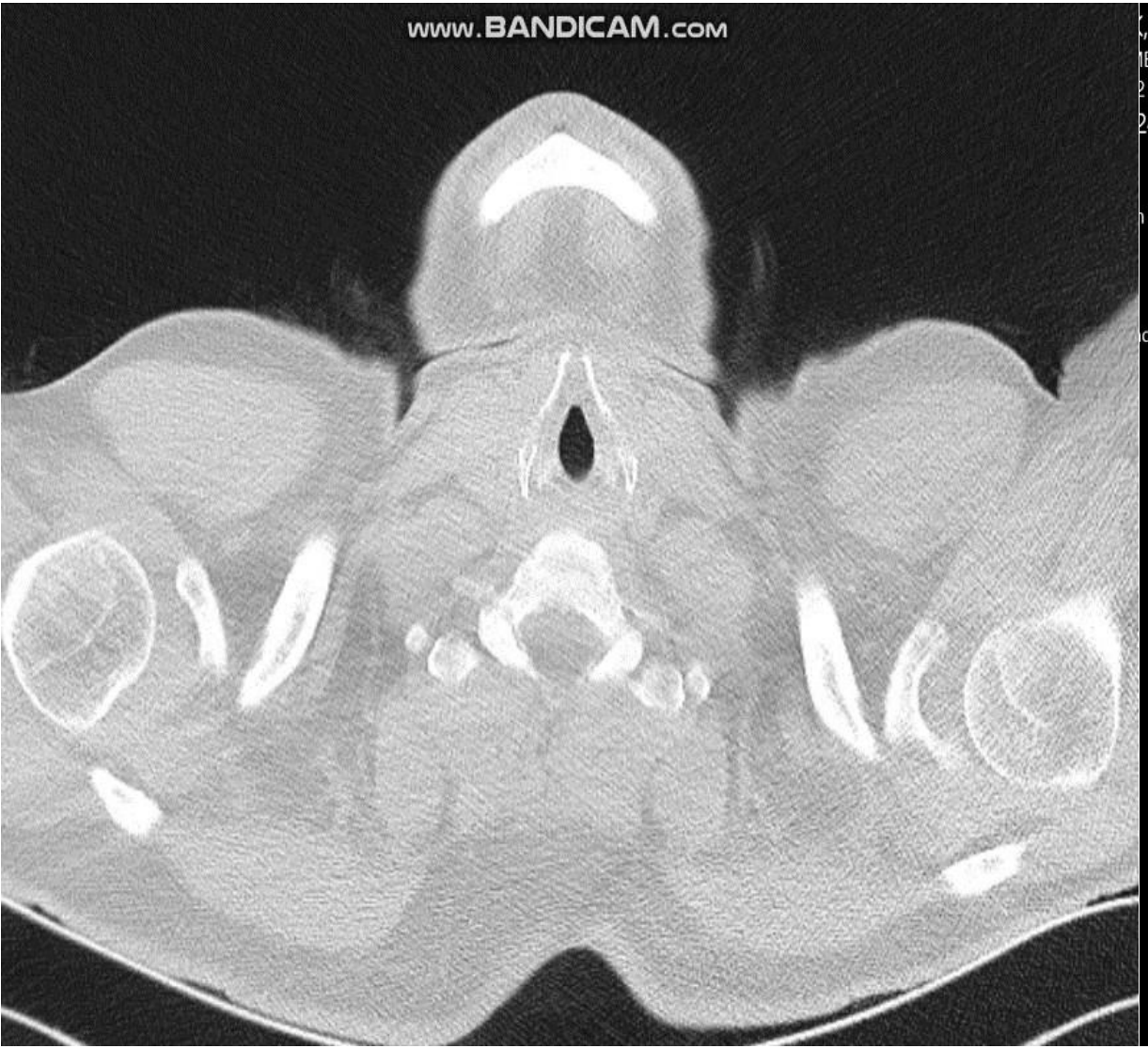

20.11.2023

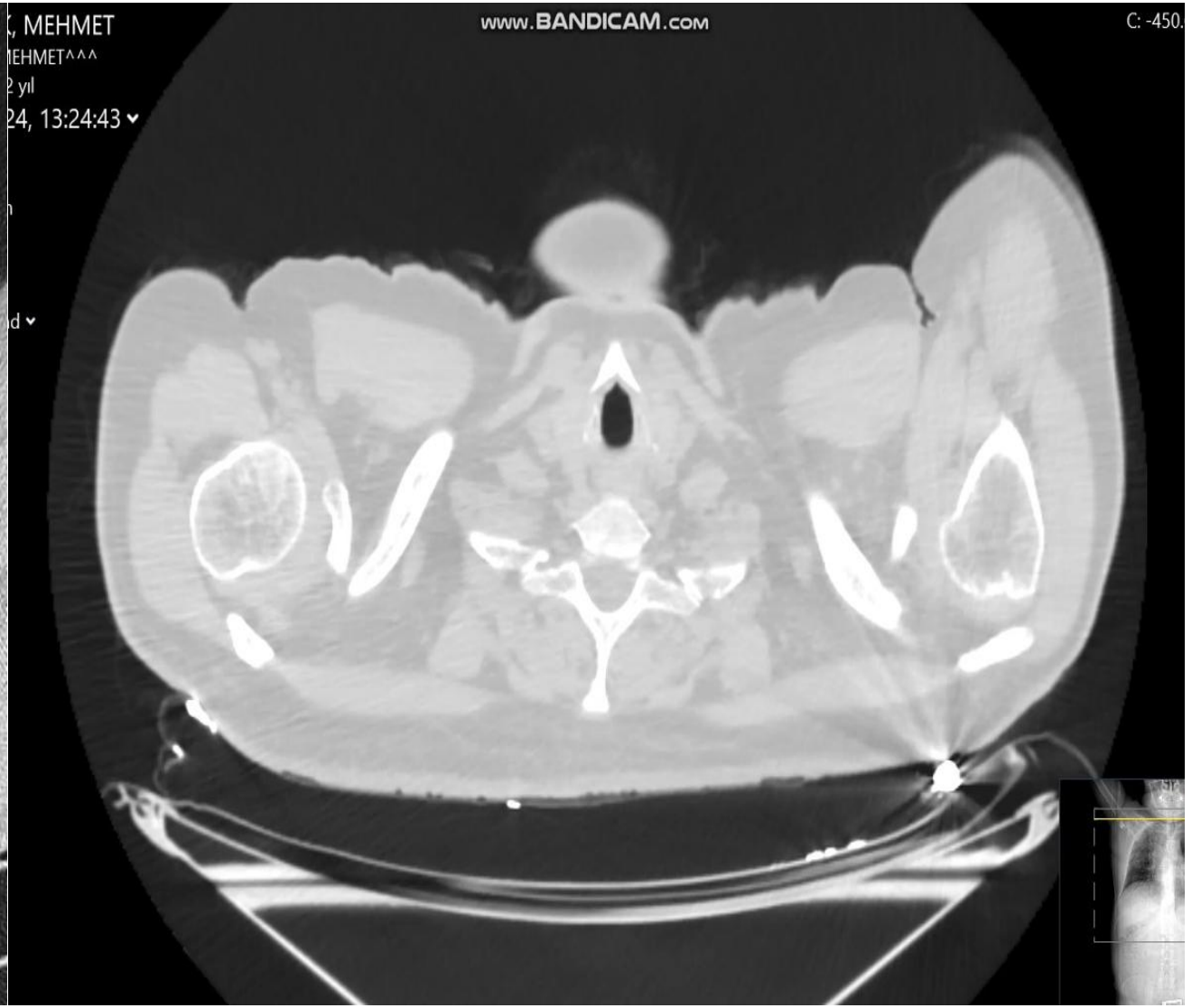

25.04.2024

RADYOLOJİ RAPORU

25.04.2024, 13:22, BT, TORAKS, KONTRASTSIZ

Eski tarihli toraks BT si olmadığından karşılaştırma yapılamamıştır.

MEDİASTEN PENCERESİ:
Trakea ve ana bronşlar açıktır.
Kalp normal büyüklükte olup Perikardiyal veya Plevral mayi artışı saptanmamıştır.
Mediastende Birden fazla kompartmanda benign kaba kalsifik lenf nodları mevcuttur (geçirilmiş granülomatöz hastalık?), Mediastende ayrıca en büyüğü sağ alt subkarinal 17x8 mm ölçüsünde olmak üzere çoğunun kısa aksı 1 cm den küçük birden fazla sayıda oval şekilli muhtemel reaktif lenf nodları mevcuttur.
Her iki aksiller bölgede patolojik boyut ve görünümde lenf nodu saptanmamıştır.

PARANKİM PENCERESİ:
Her iki akciğerde yaygın periferlerin kısmen korunduğu ve bazallerde daha belirgin yaygın kaldırım taşı paternine ait nonspesifik dansite değişiklikleri mevcuttur.
Her iki akciğer alanlarında yaygın fissüral ve subplevral mikronodülariteler mevcuttur. Ayrıca dağınık yerleşimli 5 mm'den küçük birden fazla sayıda nonspesifik solid nodüller izlenmektedir.
Her iki akciğer alanlarında malignite veya metastaz lehine değerlendirilen bulgu saptanmamıştır.
Her iki akciğer alanlarında akut enfeksiyon lehine değerlendirilen bulgu saptanmamıştır.

KEMİK PENCERESİ:
Toraks alanına giren kemik yapılarda malignite veya metastaz lehine değerlendirilen bulgu saptanmamıştır. Torakal vertebralarda birden fazla seviyede osteofitler mevcuttur.Torakal bölgede hafif derecede skolyoz mevcuttur.

SONUÇ: Nonspesifik kaldırım taşı paterni, mediastinel kalsifk lenf nodları ve perilenfatik mikronodüller patern olması sarkoidozu ön planda

ERCIYES UNIVERSITESI HASTANESI
GOGUS HASTALIKLARI BOLUMU
KAYSERI

Date: 08/07/2024
Id: 5241276008

Age: 51 Race: Caucasian Gender: Male
Temp: 24 PBar: 680
Height(cm): 180

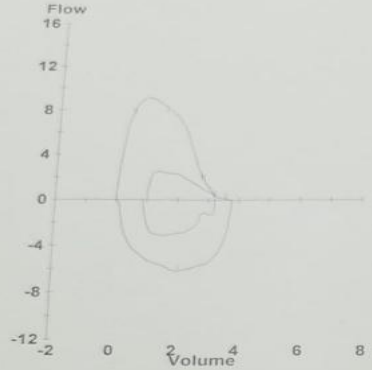

Spirometry

		Ref	Pre Meas	Pre % Ref	Post Meas	Post % Ref	Post % Chg
FVC	Liters	4.70	3.77	80			
FEV1	Liters	3.77	3.25	86			
FEV1/FVC	%	78	86				
FEF25-75%	L/sec	4.00	5.50	138			
PEF	L/sec	9.01	9.65	107			
FET100%	Sec		7.34				
FIVC	Liters	4.70	3.71	79			
FIF50%	L/sec		6.20				
FVL ECode			000010				
MVV	L/min						

Diffusion

Hb: 13.0



DLCO	mL/mmHg/min	31.7	17.9	57
DL Adj	mL/mmHg/min	31.7	18.8	59
VA	Liters	7.30	4.17	57
DLCO/VA	mL/mHg/min/L	4.34	4.29	99
DL/VA Adj	mL/mHg/min/L	4.34	4.51	104
IVC	Liters		2.99	

Version: IVS-0101-21-2B

PF Reference: ERS1993 Update + Zaplet

6 DAKİKA YÜRÜME TESTİ

Tarih:08/07/2024

0 NEFES DARLIĞI YOK (BAŞLANGIÇ) (BİTİŞ)
0,5 ÇOK ÇOK HAFİF
1 ÇOK HAFİF
2 HAFİF
3 ORTA
4 BİRAZ CİDDİ
5 CİDDİ
6 ÇOK CİDDİ
7 .....
8 ÇOK ÇOK CİDDİ
9 MAKSİMAL

Başlangıç saturasyonu: 95
Bitiş saturasyonu:86
Başlangıç kalp hızı:106
Test sonucu kalp hızı:143

HASTANIN ADI SOYADI: MEHMET KARAÇELİK
DOSYA NO:5241276008

Yürüme mesafesi: 40 M
Yürüme zamanı: 0,23 DK

Yorum:HASTANIN YÜRÜMENİN 0,23 DK'SINDA SATURASYON 86 ÖLÇÜLDÜĞÜ İÇİN TEST SONLANDIRILDI.

Testi Uygulayan: DAVUT DURAN

- No improvement, progression?
- Planning cryobiopsy
- Continuing steroid at 8 mg



Numune Türü	Tetkik Istem Zamanı	10.07.2024 16:10	Numune Kabul Zamanı	10.07.2024 16:17
	Numune Alma Zamanı	10.07.2024 16:10	Uzman Onay Zamanı	31.07.2024 14:29
Eski Biyopsi No	B-8324-2025, S-856-2024, B-2267-2024,			

KLİNİK BİLGİ:

BİLİNEN KRONİK HASTALIK YOK .İPF? NSİP? COP? ALVEOLER SARKOİDOZ?

MAKROSKOPİ:

Kayıtsız tüpte gönderilen en küçüğü 0,5x0,5x0,5 cm en büyüğü 0,9x0,6x0,6 cm ölçülerinde 4 adet doku AC1,2,2 kasette takibe alındı. fs/ ega

MİKROSKOPİ:

Kesitlerde, alveol yapıda belirgin bozulma izlenmiştir. MT ile kollojen bağ doku artışı görülmüştür. Tip2 pönomositlerde belirgin proliferasyon mevcuttur. TTF1 ile alveollerde pozitif boyanma görülmüş olup MT ile fibröz artış dikkat çekmiştir.Belirgin inflamatuar reaksiyon izlenmemiştir.

TANI (ICD-O kodları)

İNTERTİSYEL AKCİĞER HASTALIĞI İLE UYUMLU BULGULAR, AKCİĞER SAĞ ALT LOB, KRİYO BİYOPSİ MATERYALİ

ARŞ. GÖR.EZGİ GİZEM ABAT

Dipl Tescil No 160853

PROF. DR.OLGUN KONTAŞ

Dipl Tescil No 37872

- Antifibrotic therapy added due to absence of inflammation and predominance of fibrosis, while continuing Prednol at 8-4 mg
- Follow-up CT in 1 year



25.04.2024

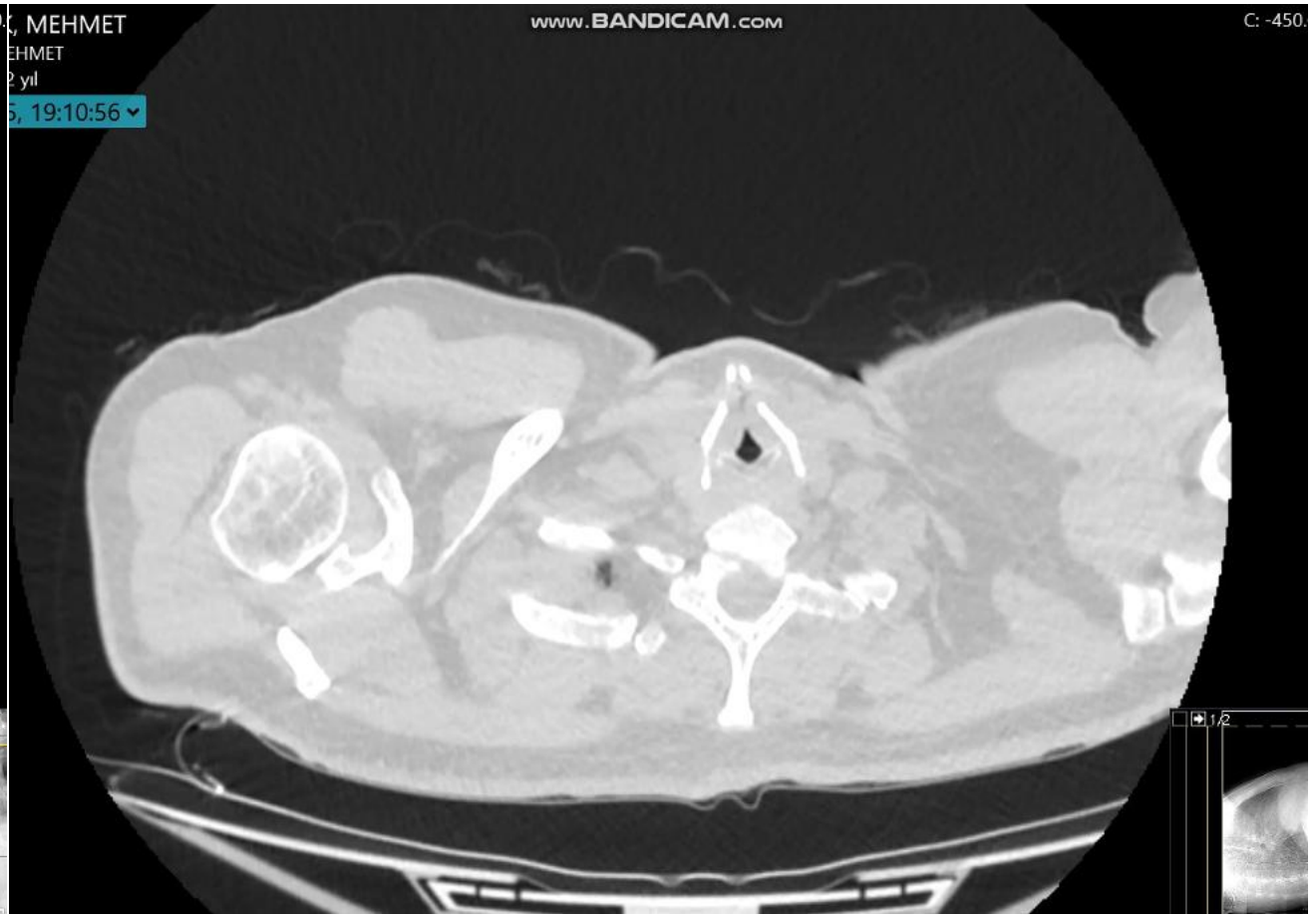

14.04.2025

PARANKİM PENCERESİ:
Her iki akciğerde yaygın periferlerin kısmen korunduğu ve bazallerde daha belirgin yaygın kaldırım taşı paternine ait nonspesifik dansite değişiklikleri mevcuttur. Önceki incelemesine kıyasla fibrozise eşlik eden buzlu cam alanlarında artış izlendi.(NSIP?, Sarkoidoz?)
Her iki akciğer alanlarında yaygın fissüral ve subplevral mikronodülariteler mevcuttur. Ayrıca dağınık yerleşimli 5 mm'den küçük birden fazla sayıda nonspesifik solid nodüller izlenmektedir.
Her iki akciğer alanlarında akut enfeksiyon lehine değerlendirilen bulgu saptanmamıştır.

- Multidisciplinary team decision: Open lung biopsy

Numune Türü	Tetkik Istem Zamanı	17.04.2025 09:45	Numune Kabul Zamanı	17.04.2025 09:55
	Numune Alma Zamanı	17.04.2025 09:45	Uzman Onay Zamanı	24.04.2025 12:54
Eski Biyopsi No	S-856-2024, B-14182-2024, B-2267-2024,			

KLİNİK BİLGİ:

WEDGE REZ..

MAKROSKOPİ:

Hastaya ait materyaller 3 adet poşette gönderilmiştir
A- Alt lob lateral bazal kayıtlı poşette gönderilen 6x2,3x1,8 cm ölçülerinde wedge rezeksiyon materyalidir. Materyal üzerinde 6,5 cm uzunluğunda stapler hattı izlenmiştir. Materyalin dış yüzü sarı renkli, stapler hattı altı cerrahi sınır kırmızı renkli doku boyasıyla boyandı. Materyal iç yüzü parankim yüzeyi kanamalı görünümde izlendi, aşikar lezyon izlenmedi. Materyalden alınan parçalar 2 parça A1-A2 2 kasette takibe alındı.
B- Üst lob apikoposterior kayıtlı poşette gönderilen 6,5x2,5x0,8 cm ölçülerinde wedge rezeksiyon materyalidir. Materyal üzerinde 7,5 cm uzunluğunda stapler hattı izlendi. Materyale kesitler yapıldı birkaç alanda hafif kanama odakları görüldü. Materyalden alınan 4 parça B1-B2 2 kasette takibe alındı.
C- Parsiyel dekortikasyon kayıtlı poşette gönderilen 2,6x1,5x0,5 cm ölçülerinde dokunun tamamı 1 kasette takibe alındı. ÜB/ BA

TANI (ICD-O kodları)

1- YAYGIN FİBROİNFLAMATUAR DEĞİŞİKLİKLER, SON DÖNEM AKCİĞER HASTALIĞI İLE UYUMLU BULGULAR, SOL ALT LOB, SAĞ ÜST LOB, WEDGE REZEKSİYON MATERYALLERİ
2- NONSPESİFİK DEĞİŞİKLİKLER, PARSİYEL DEKORTİKASYON MATERYALİ

ARŞ. GÖR. DR.BÜŞRA AKSOY

Dipl Tescil No 201963

PROF. DR.OLGUN KONTAŞ

Dipl Tescil No 37872

SFT LABORATUVARI

Last Name:	KARACELIK	Identification:	5241276008
First Name:	MEHMET	Age:	52 Years
Height:	180 cm	Date of Birth:	01/06/1973
Weight:	95.0 kg	Gender:	male
BMI:	29 kg/m²	Operator:	KOC ENGIN SAADET

Diffusion SB

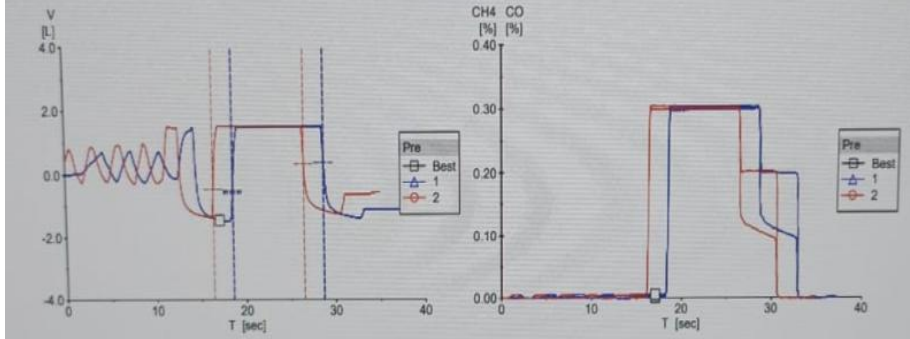

Diffusion - Graph

	Pred	Best	%Best/Pred	Trial 1	Trial 2	Trial 3
DLCO Single Breath	10.54	3.72	35	3.71	3.73	
DLCO_SB / VA	1.44	1.00	69	0.98	1.02	
VA Single Breath	7.15	3.72	52	3.79	3.65	
Hb	14.60	14.60	100	14.60	14.60	
DLCOc Single Breath	10.54	3.72	35	3.71	3.73	
DLCOc_SB / VA	1.44	1.00	69	0.98	1.02	
Breath-hold time		10.11		10.14	10.08	
VIN Single Breath	4.87	3.00	62	3.00	2.89	
TLC Single Breath	7.30	3.93	54	3.99	3.86	
FRC Single Breath	3.59	2.40	67	2.28	2.63	
ERV Single Breath	1.32	1.47	112	1.29	1.66	
RV Single Breath	2.27	0.92	41	0.99	0.97	
RV % TLC Single Breath	34	24	69	25	25	
Level date		14.07.25				
Level time		11:37				

Cooperation: good ( ) moderate ( ) bad ( )

Comment

SFT LABORATUVARI

Last Name:	KARACELIK	Identification:	5241276008
First Name:	MEHMET	Age:	52 Years
Height:	180 cm	Date of Birth:	01/06/1973
Weight:	95.0 kg	Gender:	male
BMI:	29 kg/m²	Operator:	KOC ENGIN SAADET

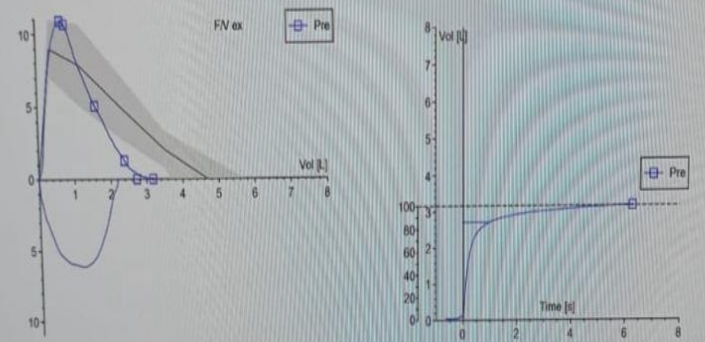

	Pred	Pre	%(Pre/Pred)
FVC	4.68	3.17	68
FEV 1	3.74	2.72	73
FEV 1 % FVC	77.85	85.73	110
PEF	8.97	10.84	121
MMEF 75/25	3.96	3.89	98
MEF 75	7.85	10.62	135
MEF 50	4.86	5.05	104
MEF 25	2.01	1.28	64
FEF 75/85	0.94	0.68	73
MFEF 75/25	3.96	3.89	98
FET 100		6.21	
FET		6.28	
Level date		14.07.25	
Level time		11:37	

Cooperation: good ( ) moderate ( ) bad ( )

6 DAKİKA YÜRÜME TESTİ

Tarih:14/07/2025

0 NEFES DARLIĞI YOK (BAŞLANGIÇ)
0,5 ÇOK ÇOK HAFİF
1 ÇOK HAFİF (BİTİŞ)
2 HAFİF
3 ORTA
4 BİRAZ CİDDİ
5 CİDDİ
6 ÇOK CİDDİ
7 .....
8 ÇOK ÇOK CİDDİ
9 MAKSİMAL

Başlangıç saturasyonu: 93
Bitiş saturasyonu:82
Başlangıç kalp hızı:111
Test sonucu kalp hızı:154

HASTANIN ADI SOYADI: MEHMET KARAÇELİK
DOSYA NO:5241276008

Yürüme mesafesi: 500 M
Yürüme zamanı: 6 DK

Yorum:

Testi Uygulayan: SAADET KOÇ ENGİN

- Steroid discontinued, antifibrotic therapy continued

T.C.
ERCİYES ÜNİVERSİTESİ
TIP FAKÜLTESİ HASTANELERİ

K-O TSE-ISO-EN 9000

TIBBİ GENETİK ANABİLİM DALI LABORATUVAR SONUÇ BELGESİ

Protokol No	:	**Rapor Onay Tarihi**	: 13.02.2026 14:43
Dosya Numarası	: 524*****008	**Başvuru Numarası**	: 21671602
Adı Soyadı	: MEHMET KARAÇELİK	**Cinsiyet / Yaş**	: E / 52
Istem Tarihi	: 10.10.2025 10:21	**Isteyen Hekim**	: HATİCE BERRA ŞAHİN
Bölümü	: TIBBİ GENETİK ANABİLİM DALI	**Numune Kabul Tar.**	: 10.10.2025 13:26
		Ruhsat No	: **GHDM-SM/38.03/01**

Sonuç :

ÇALIŞILAN TEST: HORİZONTAL NİSTAGMUS VE GENİŞLETİLMİŞ PULMONER HASTALIK PANELİ
ENDİKASYON: NİSTAGMUS, OKULER ALBİNİZM, PULMONER FİBROZİS
SONUÇ

GEN/TRANSKRİPT/LOKASYON: *HPS1* / NM_000195.5 / EKZON 7
VARYANT: c.641A>C p.His214Pro
MUTASYON TİPİ: MİSSENSE
ZİGOSİTE: HOMOZİGOT
SINIFLANDIRMA: ÖNEMİ BİLİNMEYEN VARYANT

HPS1 (OMIM: 604982) genindeki patojenik ve muhtemel patojenik değişimler otozomal resesif kalıtılan Hermansky-Pudlak syndrome 1 (OMIM: 203300) ile ilişkilendirilmiştir. Otozomal resesif kalıtılan hastalıklarda muhtemel patojenik veya patojenik varyantların hastalığı gösterebilmesi için homozigot veya başka bir patojenik varyant ile birleşik (compound) heterozigot olması gerekir. Hastanın kliniğini ile birlikte değerlendirilmesi önerilmektedir.

American Journal of Case Reports

e-ISSN 1941-5923
© Am J Case Rep, 2025; 26: e945175
DOI: 10.12659/AJCR.945175

Received: 2024.05.15
Accepted: 2025.01.15
Available online: 2025.01.27
Published: 2025.03.11

Hermansky-Pudlak Syndrome Type 1 Presenting with Interstitial Lung Disease: A Report of a Rare Case from Saudi Arabia

Patient: Male, 48-year-old
Final Diagnosis: Hermansky-Pudlak syndrome
Symptoms: Dyspnea
Clinical Procedure: —
Specialty: Pulmonology

Objective: Rare disease

Background: Hermansky-Pudlak syndrome (HPS) is a rare autosomal recessive disorder characterized by oculocutaneous albinism, bleeding diathesis, and potential multi-organ involvement such as pulmonary fibrosis and granulomatous colitis. While its incidence is globally low, it may be under-reported, particularly in regions with high rates of consanguinity, such as the Middle East. By reporting this case, we aim to increase awareness of this condition as well as its association with ILD.

Case Report: Herein, we present the case of a 48-year-old Saudi man of Arab descent with a 2-year history of progressive exertional dyspnea that recently worsened over the last 6 months, resulting in a Modified Medical Research Council (MMRC) dyspnea scale score increase from 2 to 3. Examination revealed signs consistent with albinism, accompanied by bibasilar end-inspiratory crackles on chest auscultation. Further evaluations revealed CT imaging consistent with non-specific interstitial lung pneumonia pattern (NSIP) with associated precapillary pulmonary hypertension. Notably, the patient exhibited oculocutaneous albinism, prompting consideration of Hermansky-Pudlak syndrome. Genetic testing confirmed an autosomal recessive HPS type 1 variant, a rarity in the Middle East.

Conclusions: HPS1 with ILD is rare in Saudi Arabia. This report describes such a case, offering important insight into its clinical presentation. Clinical management entails a multidisciplinary approach, including supportive care, preventive measures, and consideration of lung transplantation for severe cases. Consanguinity and endogamy, which are quite prevalent in the Middle East, probably means there is more prevalence of HPS and HPS-associated ILD than is recognized. Heightened awareness among healthcare providers is paramount for early diagnosis and optimal management of HPS-associated complications.



Patient consent was obtained for sharing the image

Positive findings	Negative findings
Ocular albinism, nystagmus	No cutanous albinism
HPS1, C641A>C variant	No platelet dysfunction or bleeding history
Pulmonary Fibrosis	

Although the diagnosis of Hermansky–Pudlak syndrome (HPS) has not been definitively established, the patient was referred for lung transplantation.

Multidisciplinary Team

